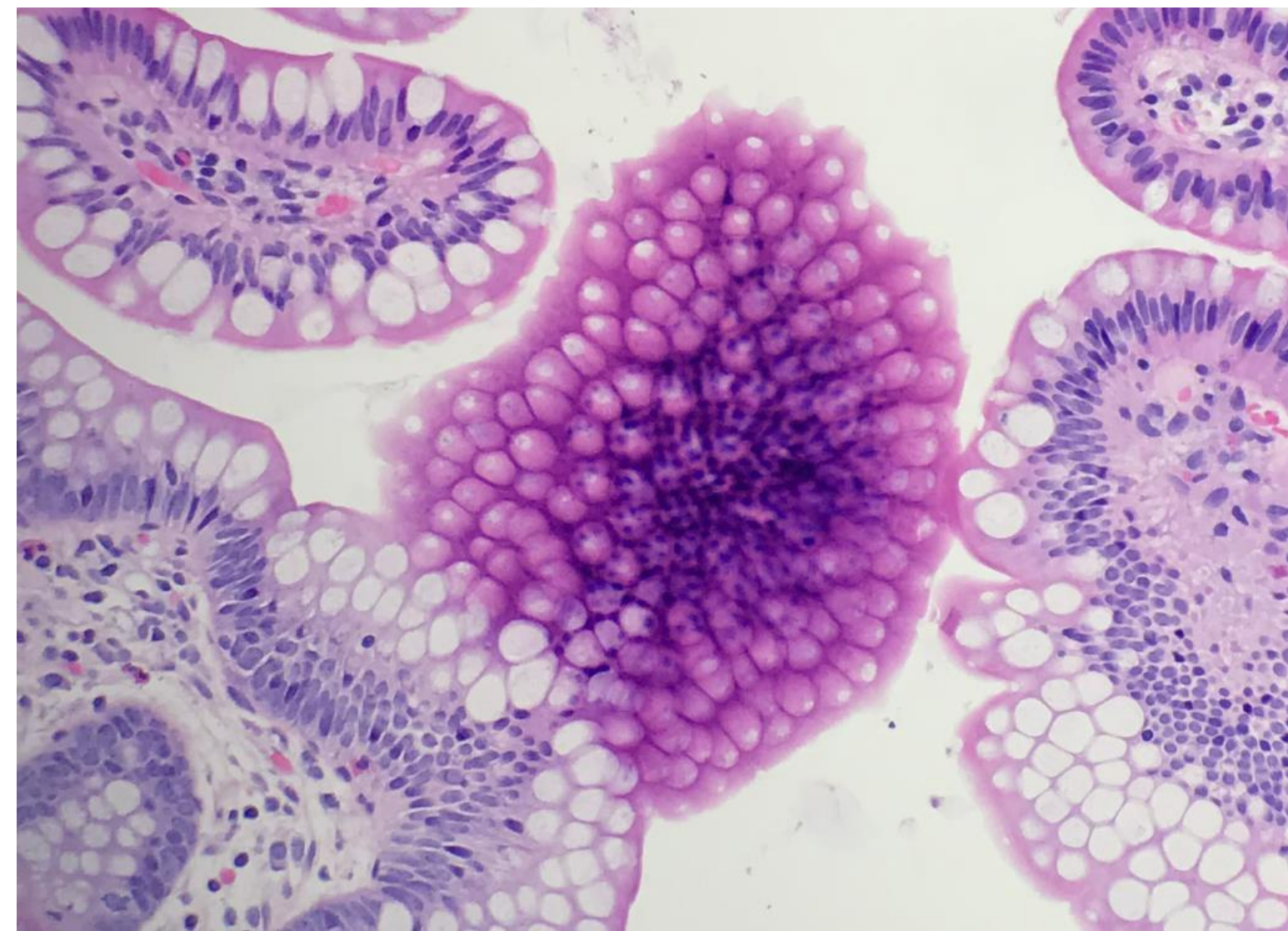

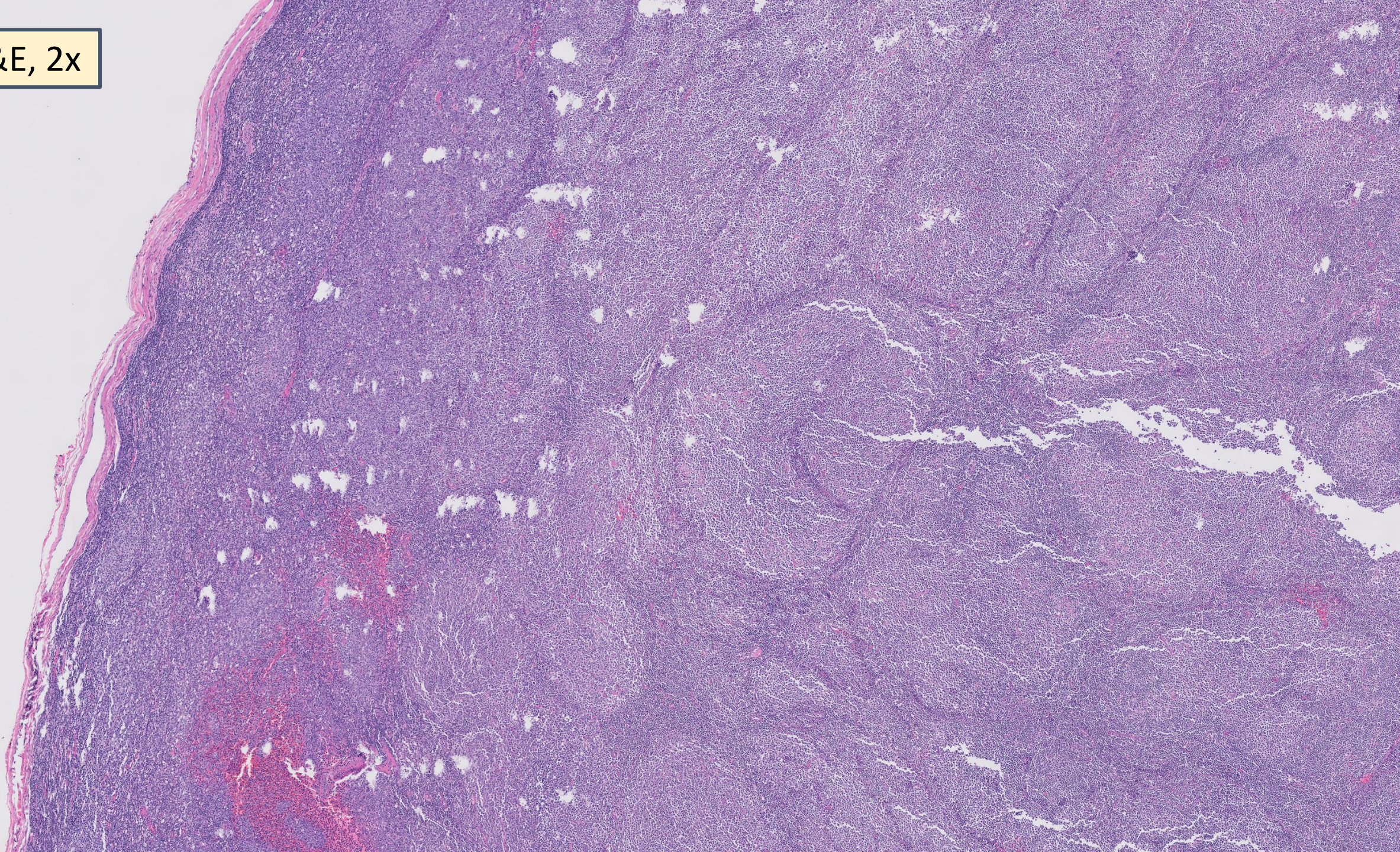
South Bay
Pathology
Society
June 2026

26-0601

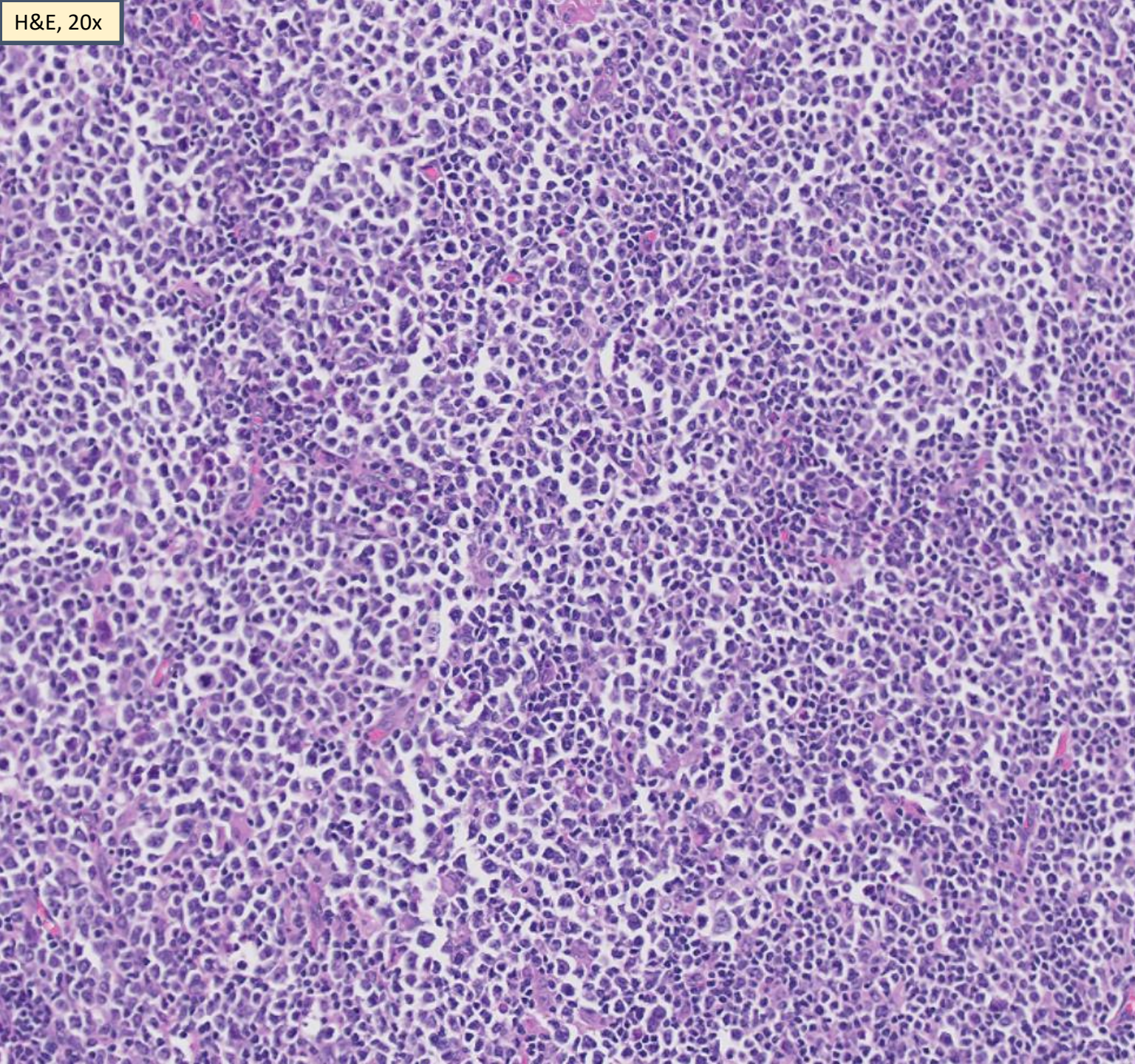
Alex Chen and Anjanaa Vijayanarayanan; UCSF

66 yo woman presenting with a nontender left inguinal mass. MRI showed a T1 hypointense, T2 hyperintense, 4.2cm homogeneously enhancing lesion favored to reflect a pathologic lymph node. Adjacent multiple enlarged smaller lymph nodes, largest measuring 1.5 cm. The patient undergoes left inguinal lymph node excisional biopsy.

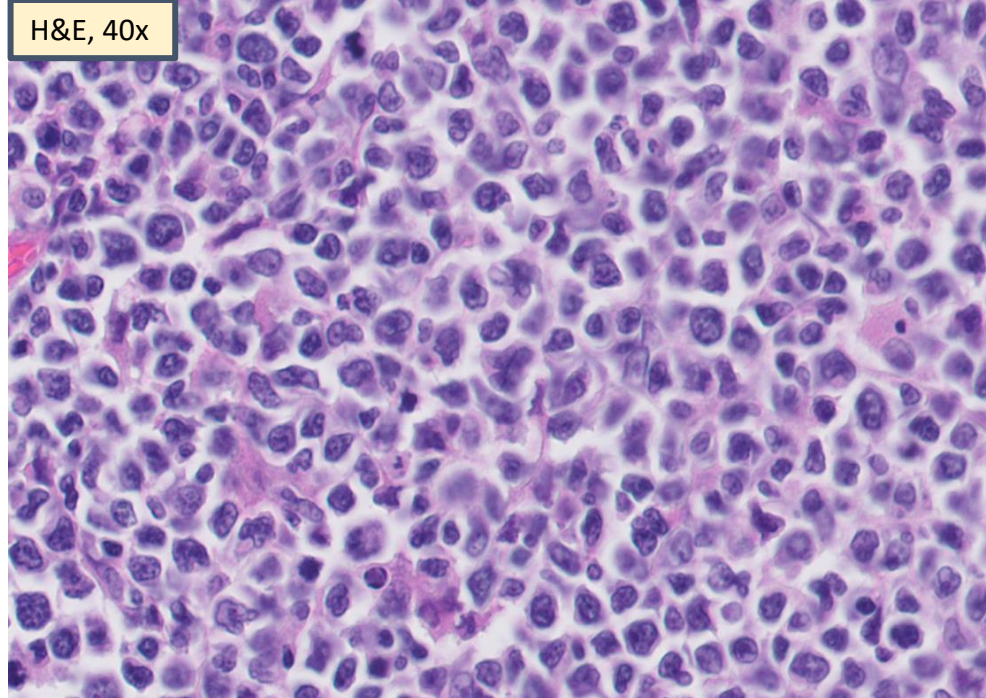
H&E, 2x



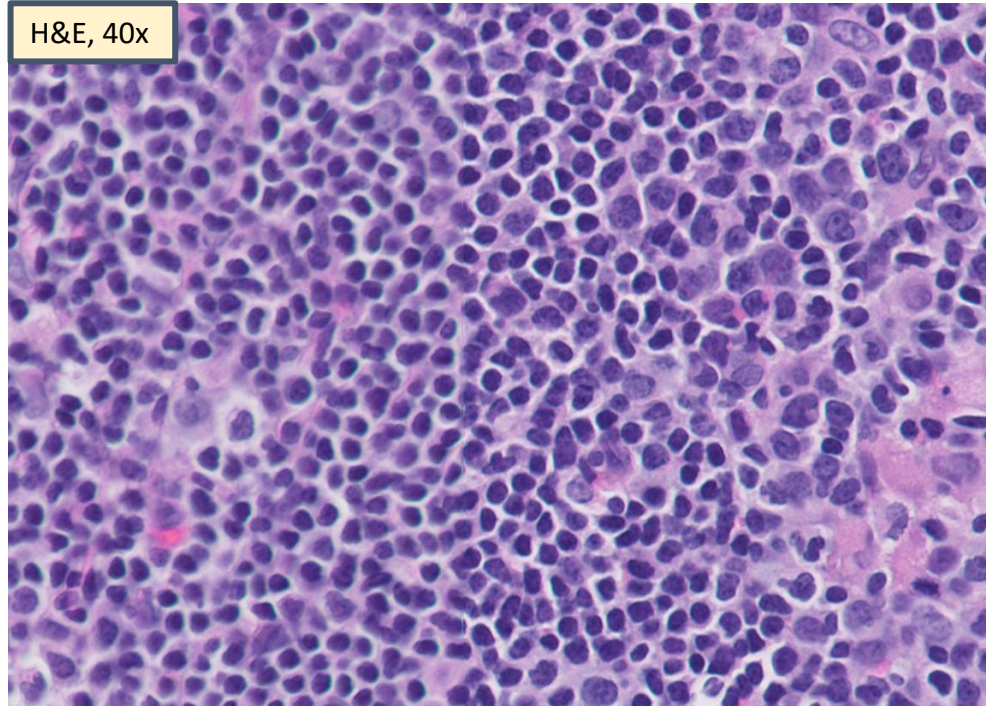
H&E, 20x



H&E, 40x



H&E, 40x



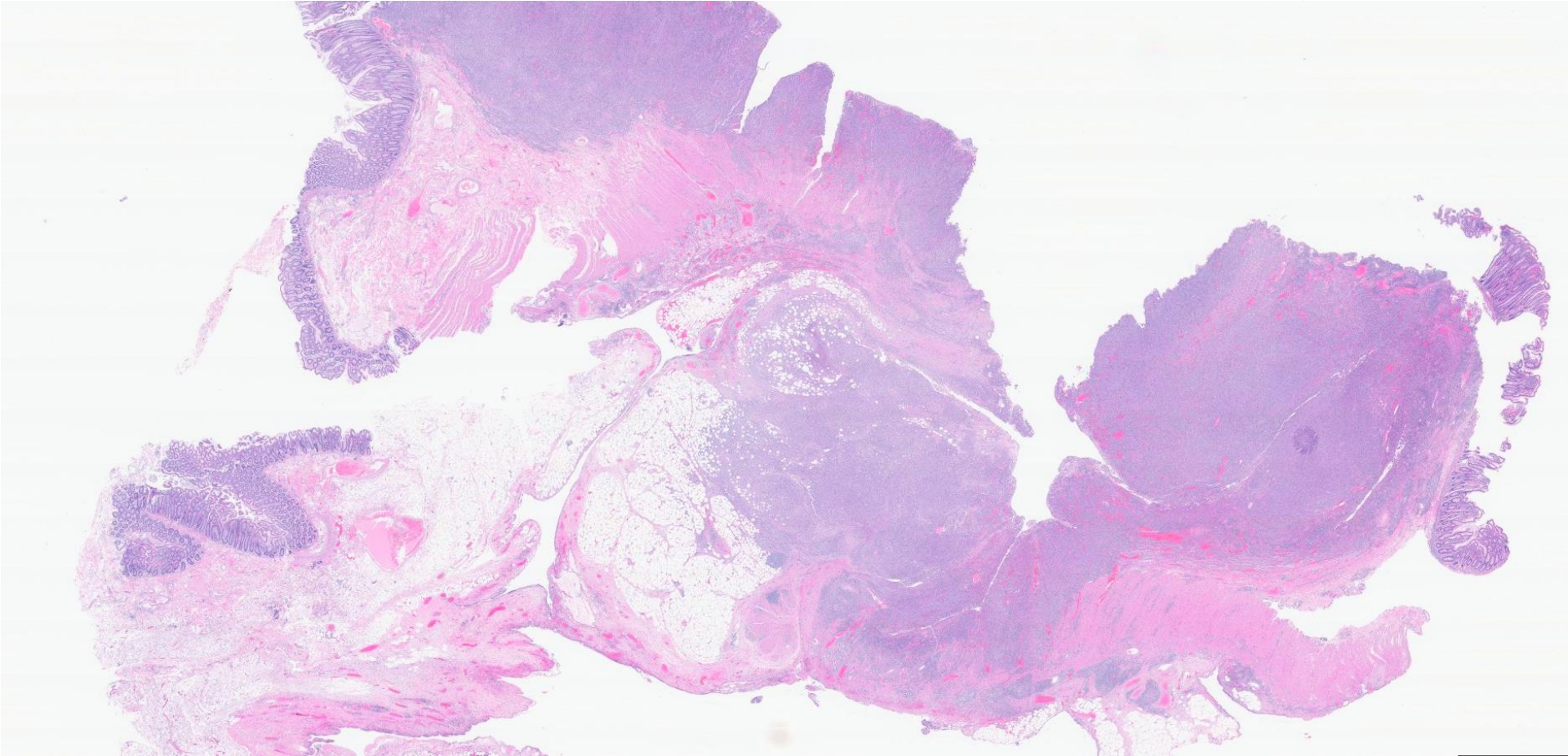
DIAGNOSIS?



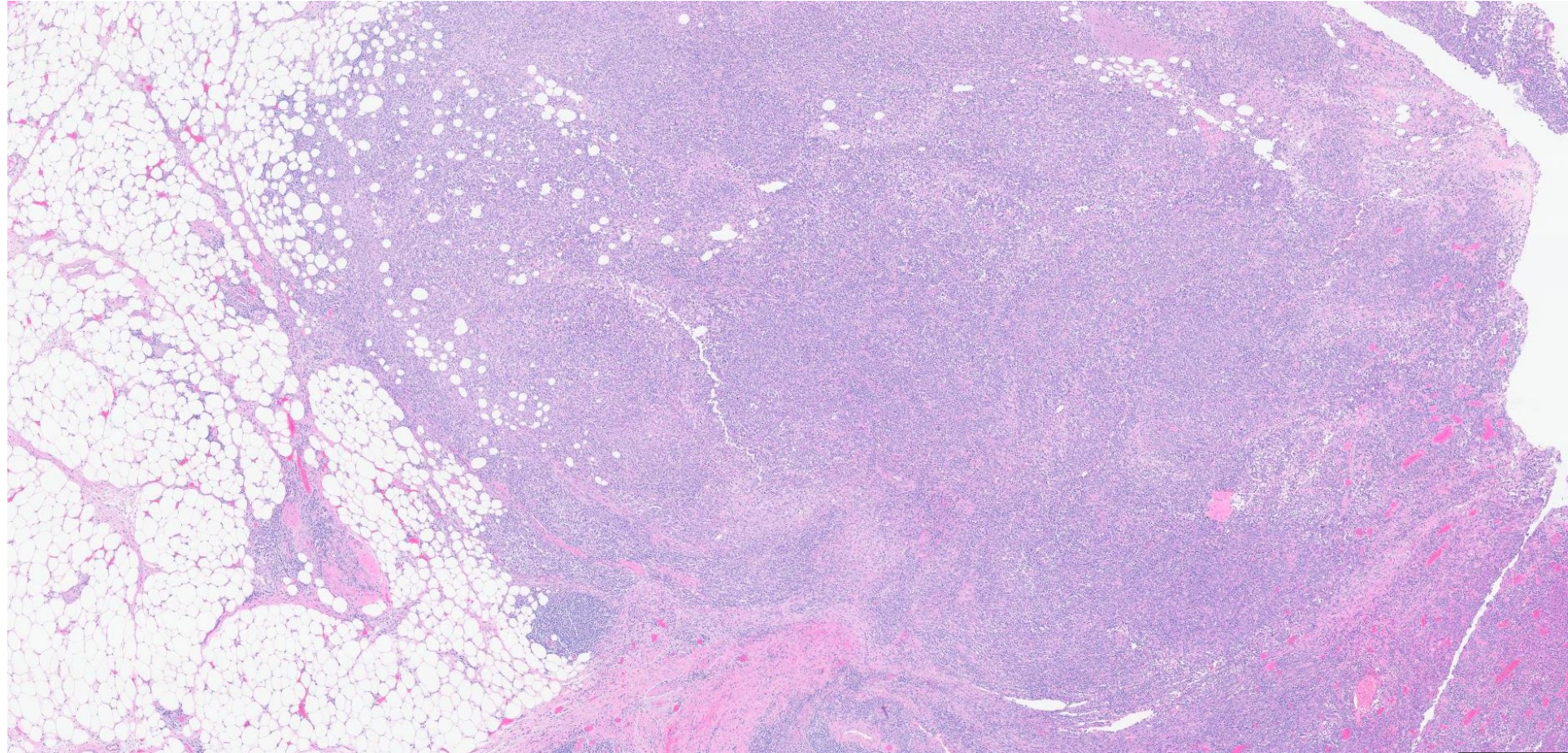
26-0602

Andrew Xiao and David Bingham; Stanford

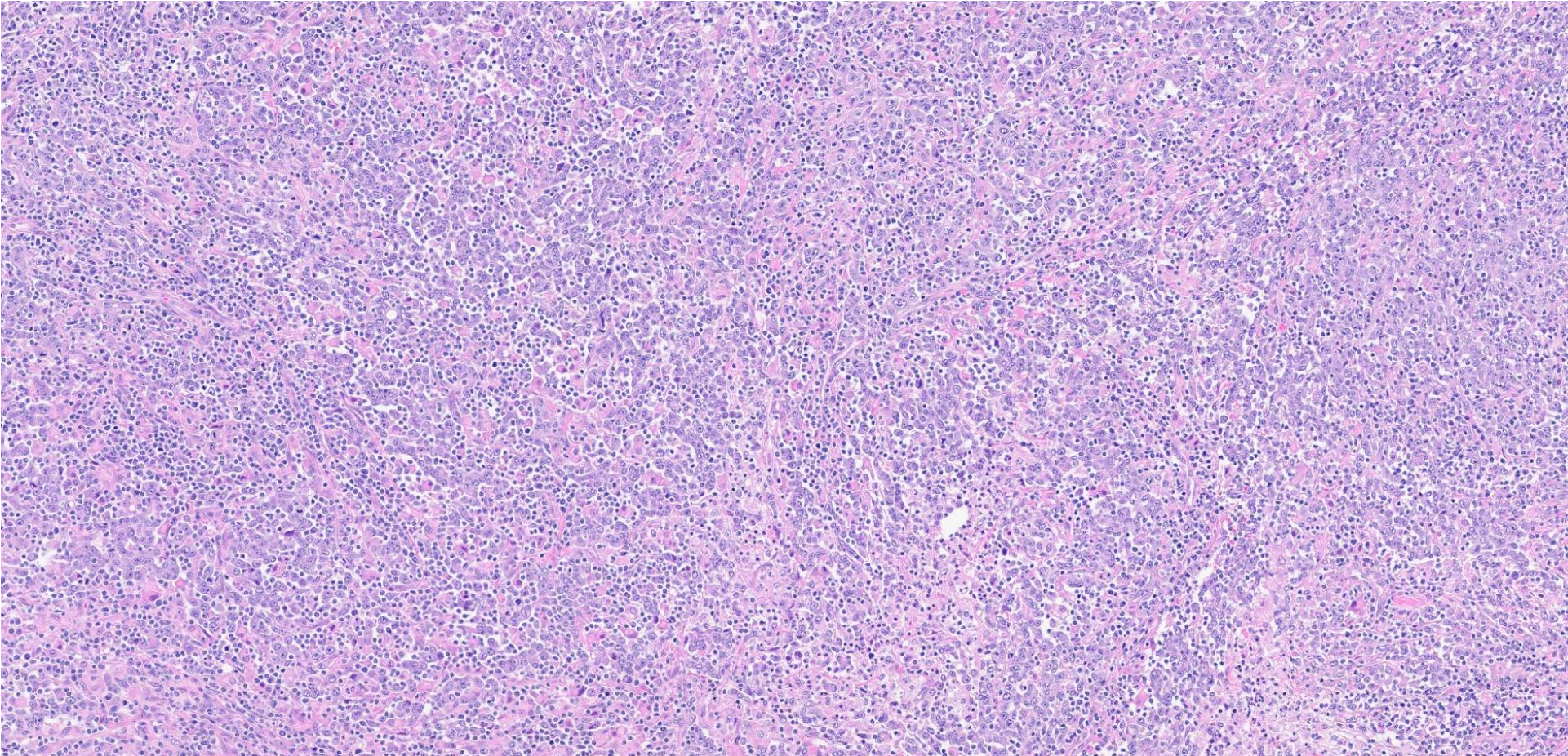
80-ish female with 4 cm pancreatic uncinata cyst underwent Whipple procedure and was found to have a right colon mass which was also resected.



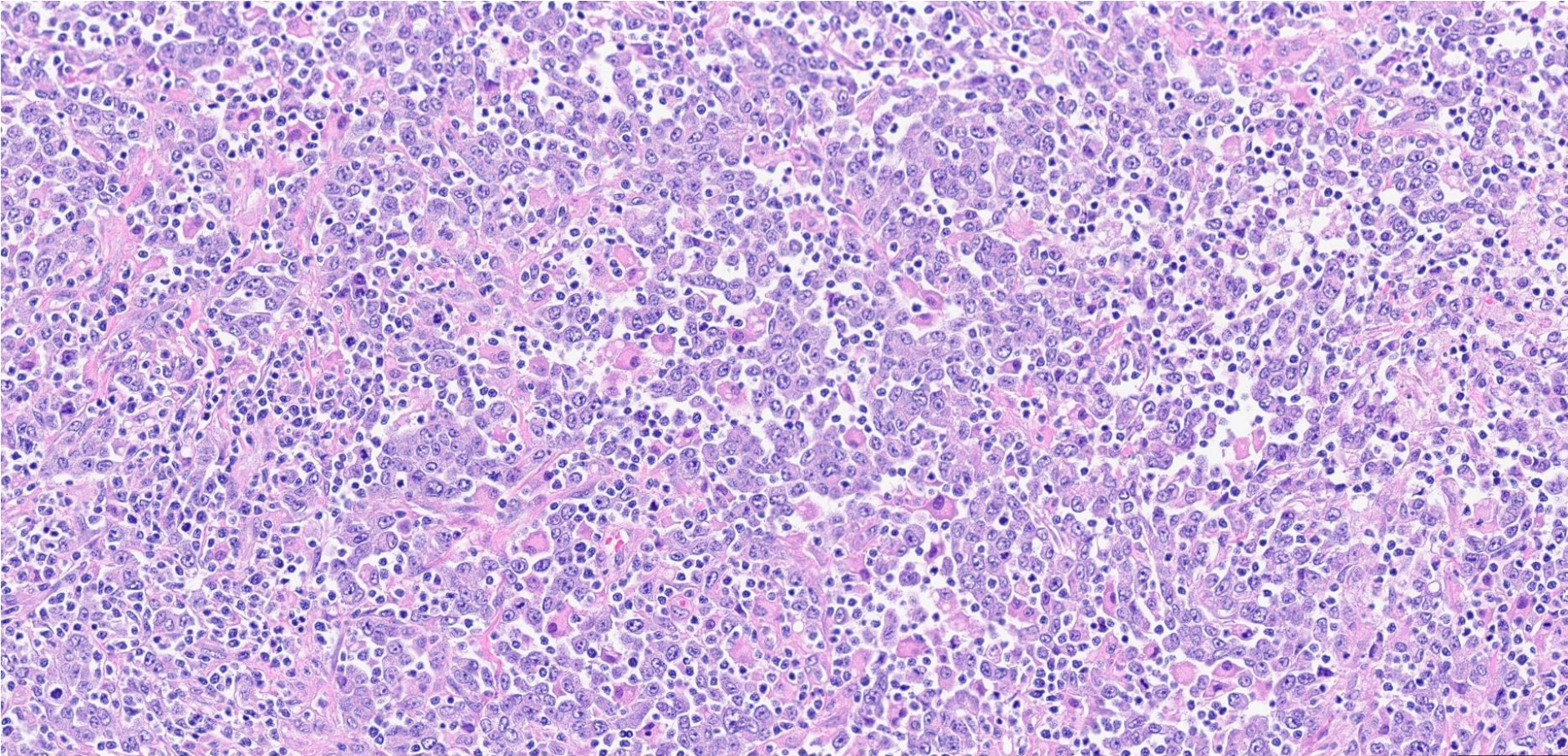
0.6x



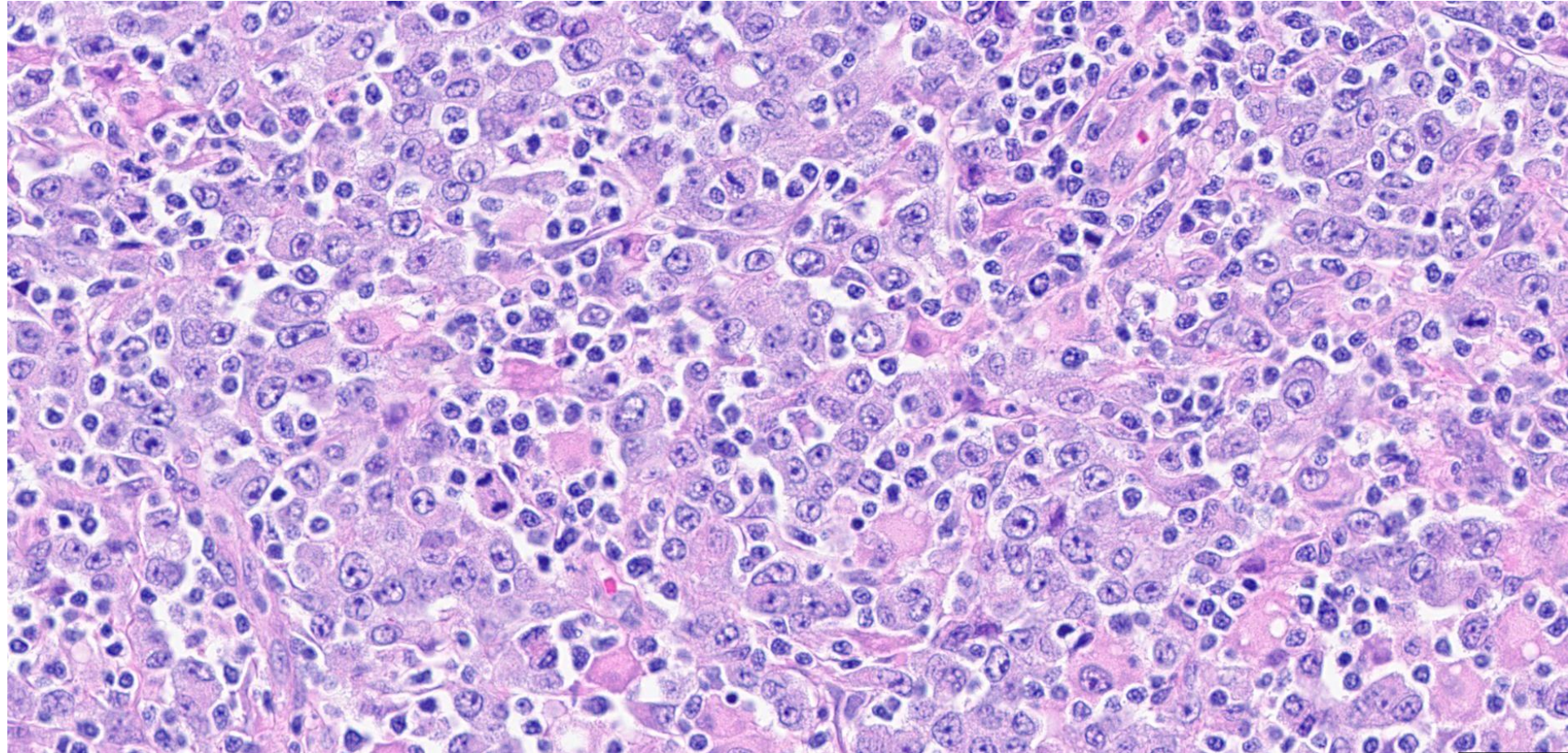
2.5x



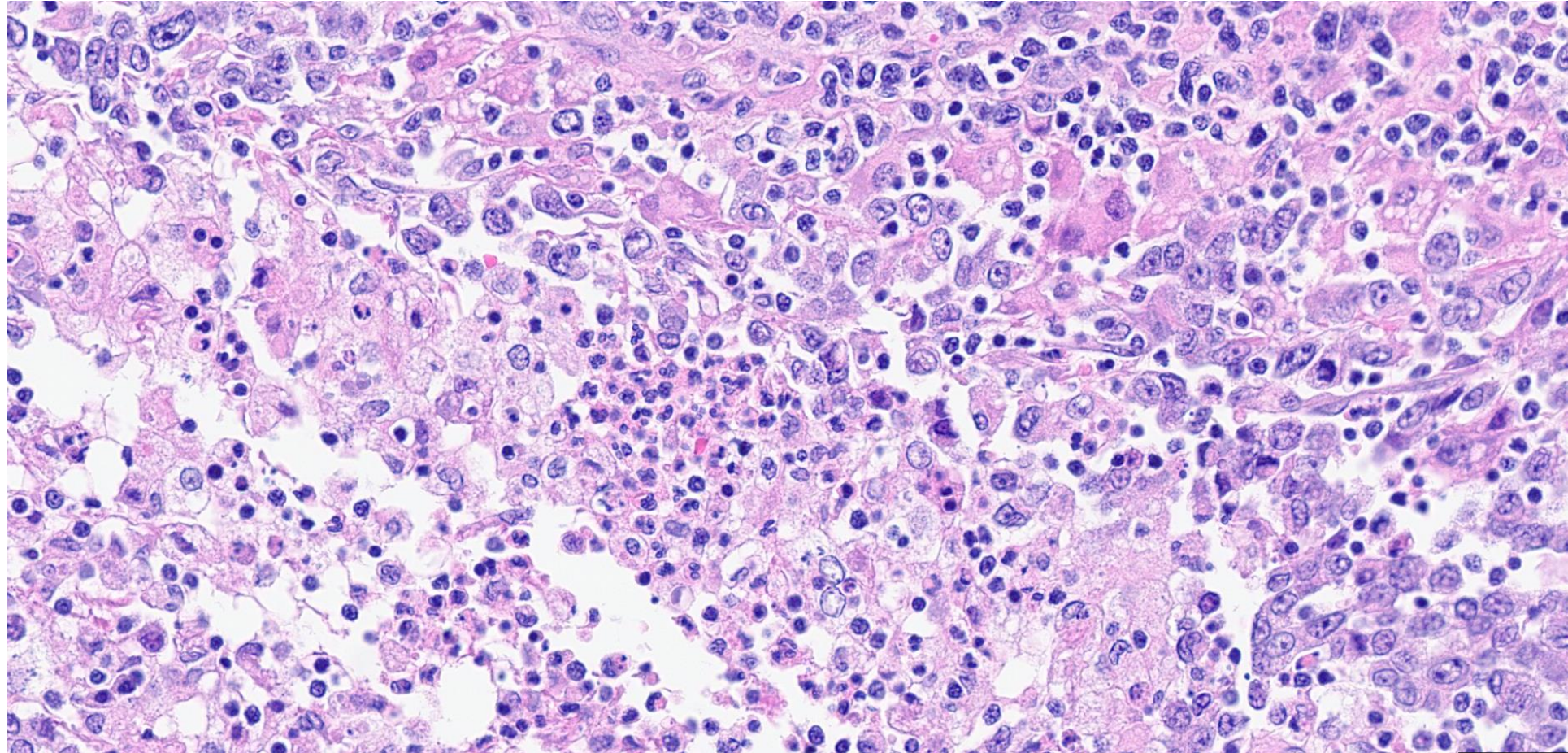
10x



20x



40x



40x

DIAGNOSIS?



26-0603

Christine Heisen and Josh Menke; Stanford

16M transferred from OSH with hyperleukocytosis and cardiogenic shock secondary to suspected eosinophilic myocarditis

Peripheral Blood

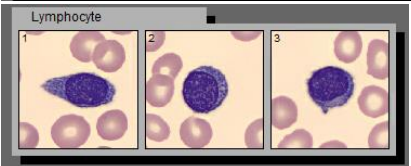
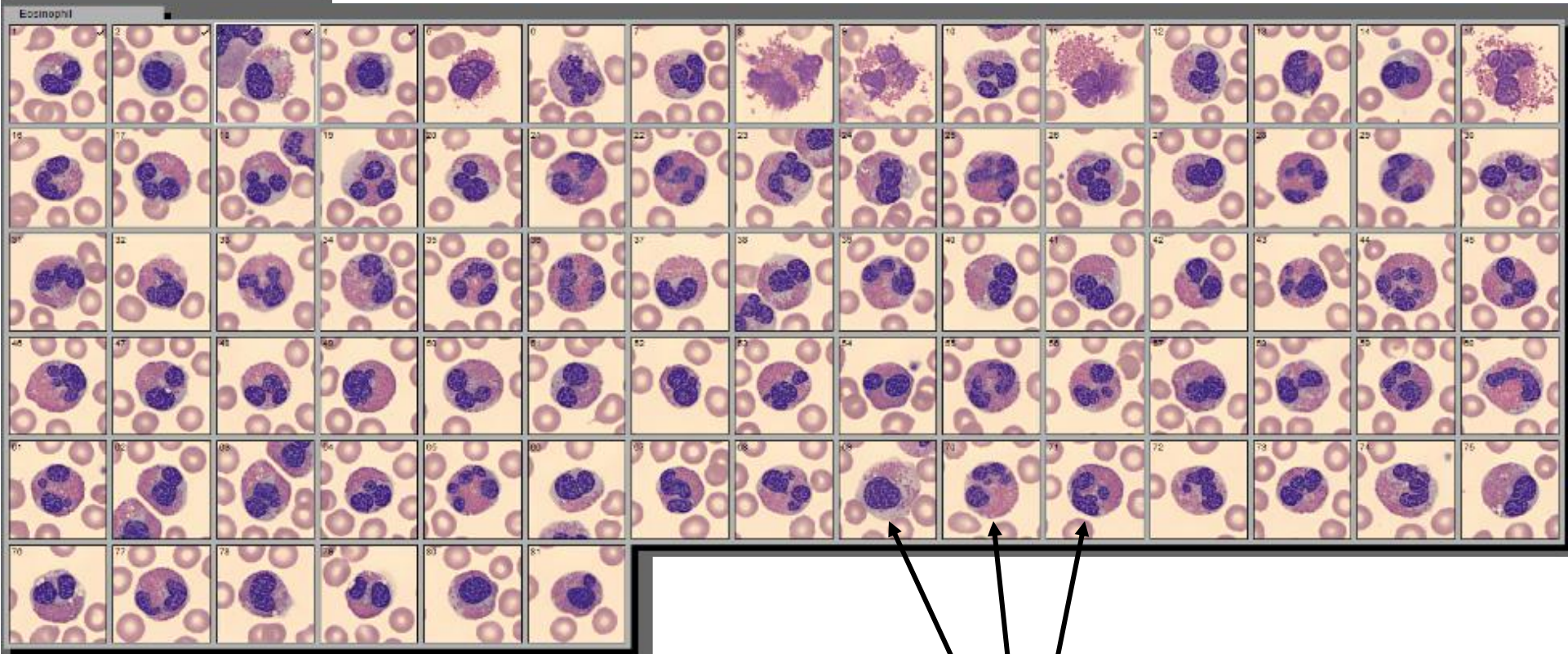
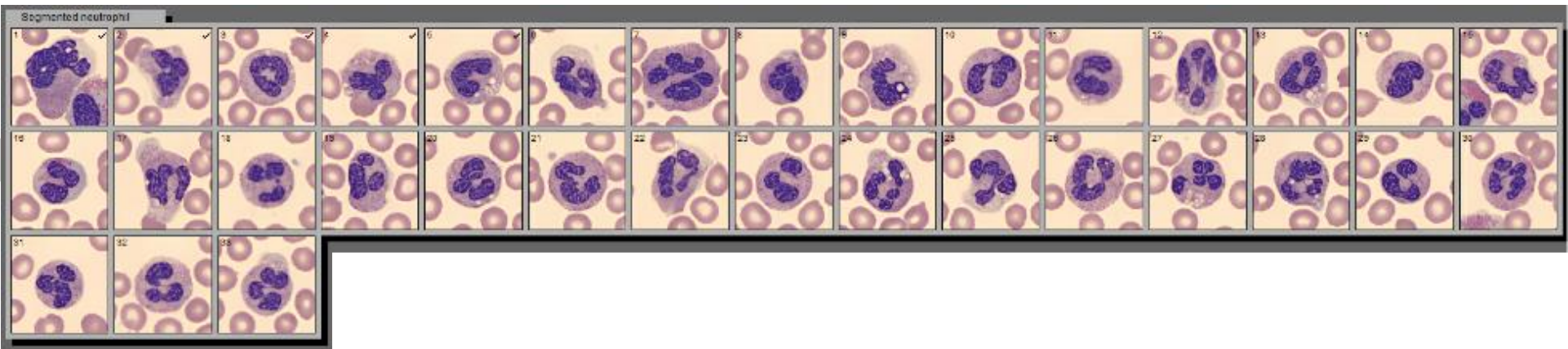
WBC: **45.8 k/uL** (4.0 - 11.0)

Hgb: **8.2 g/dL** (13.5-17.7)

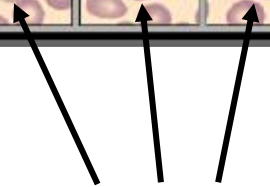
Plt: 194 k/uL (150-400)

Differential	Abs k/uL	Diff %
neutrophils	22.4 (1.8 - 8.0)	51 (34.0 - 64.0)
lymphocytes	1.37 (1.50 - 6.50)	3 (28.0 - 48.0)
monocytes	0.46 (0.00 - 0.40)	1 (0.0 - 12.0)
eosinophils	20.6 (0.00 - 0.20)	45 (0.0 - 7.0)
“others”/blasts	0	0

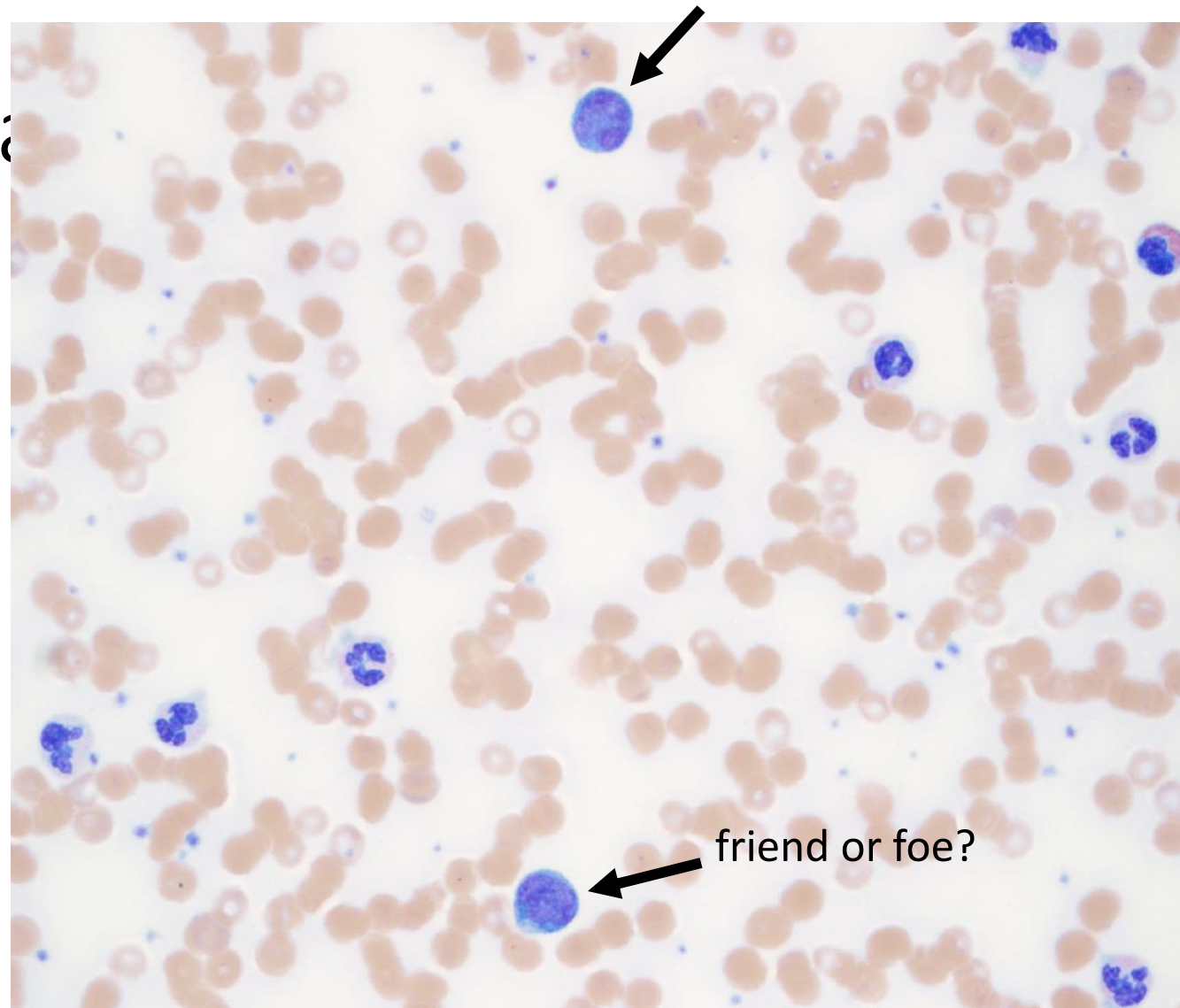
Pe



are some of these abnormal?



Periphera



flow pending...

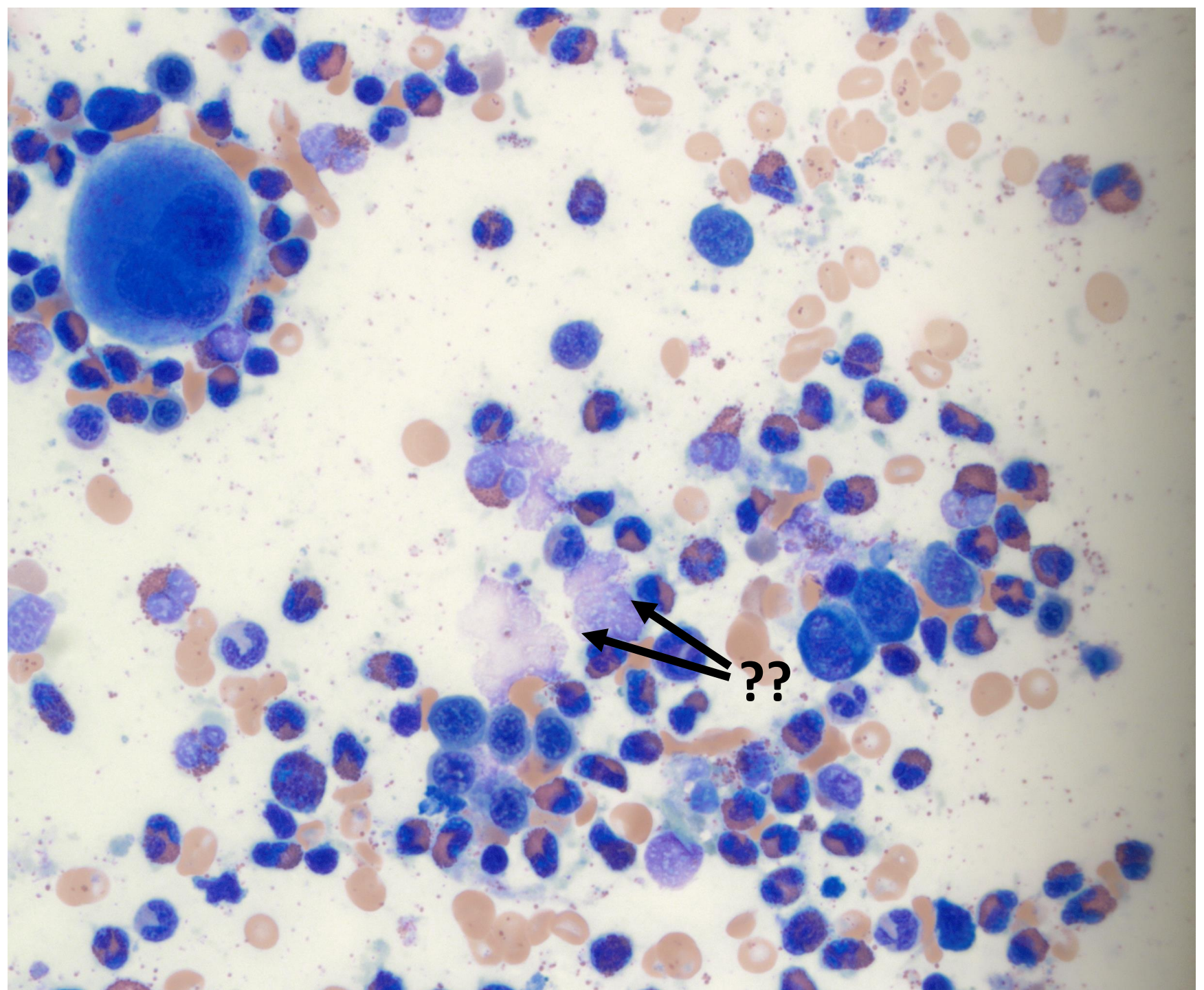
Bone Marrow Aspirate

Manual differential

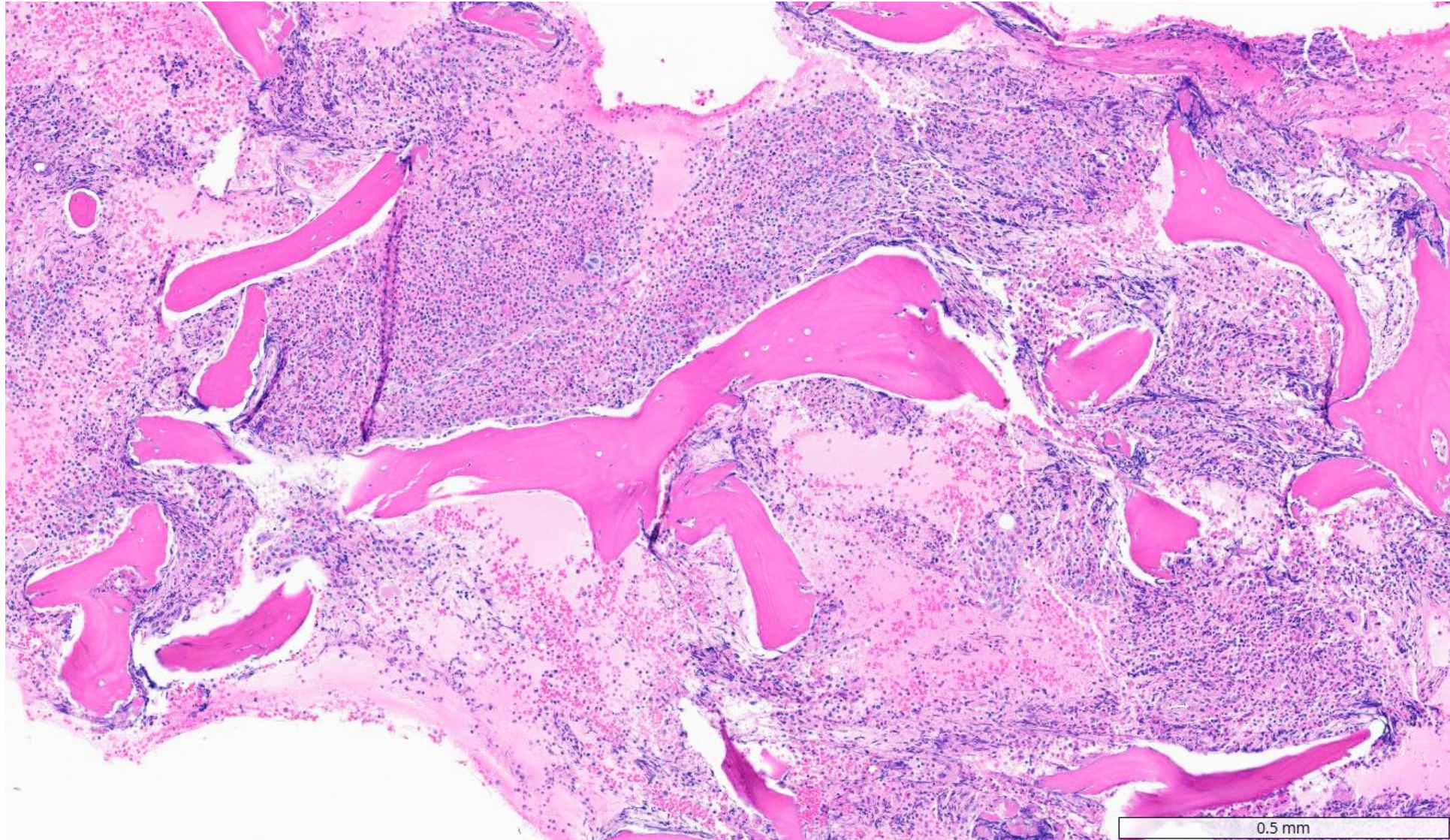
- blasts 9% (↑)
- eosinophils 60.5% (↑↑) with other myeloid precursors/neutrophils proportionally reduced
- erythroids 4.5% (↓)
- lymphocytes 6%

M:E Ratio: ~8:1 (↑)

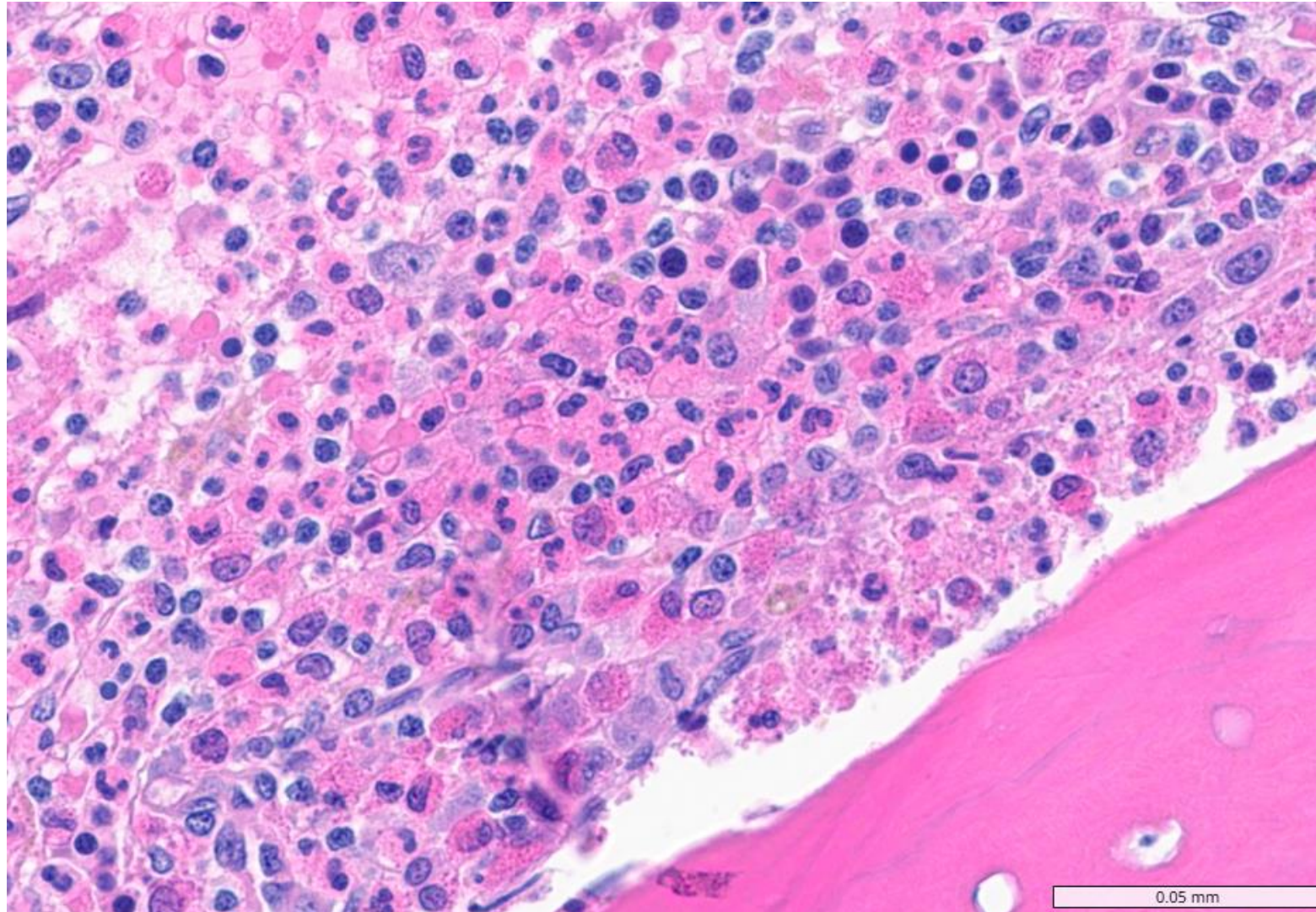
Bone Marrow Aspirate



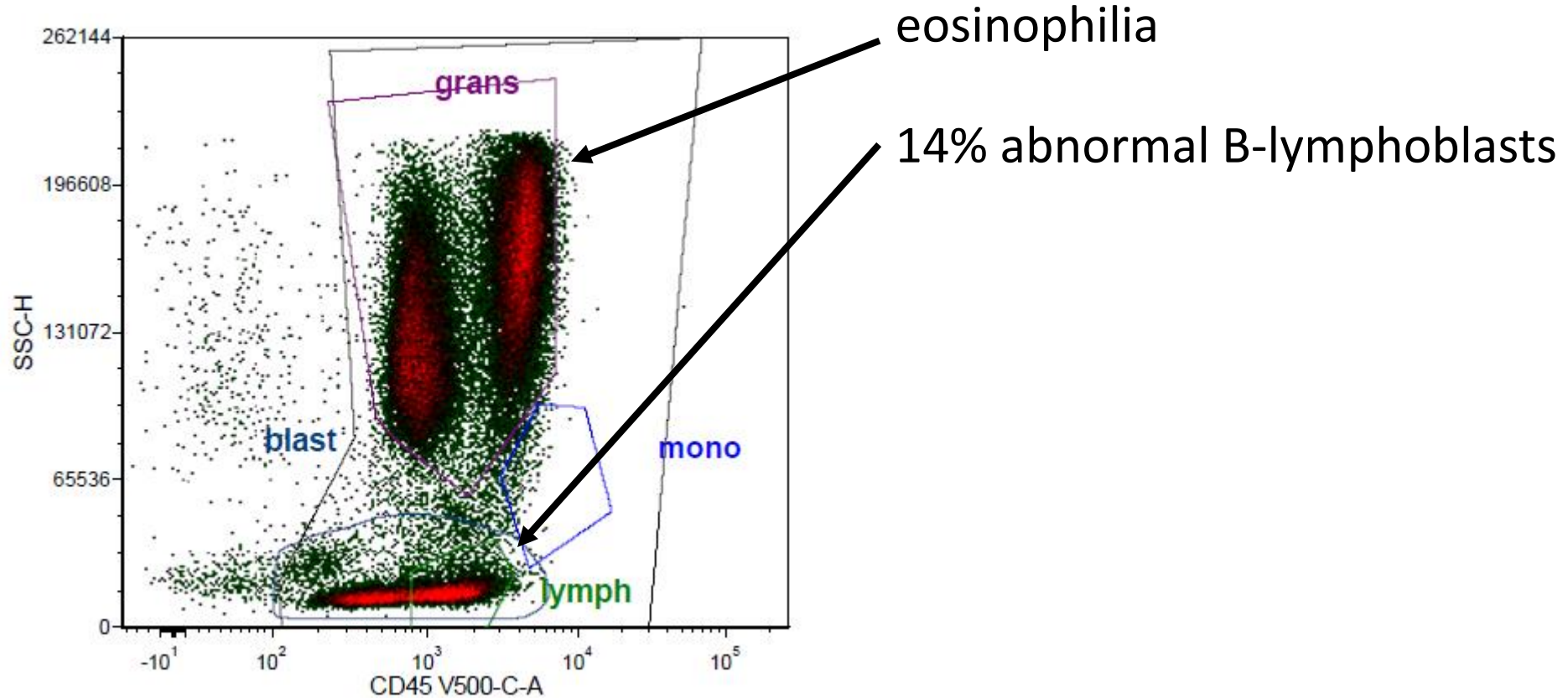
Bone Marrow Core H&E



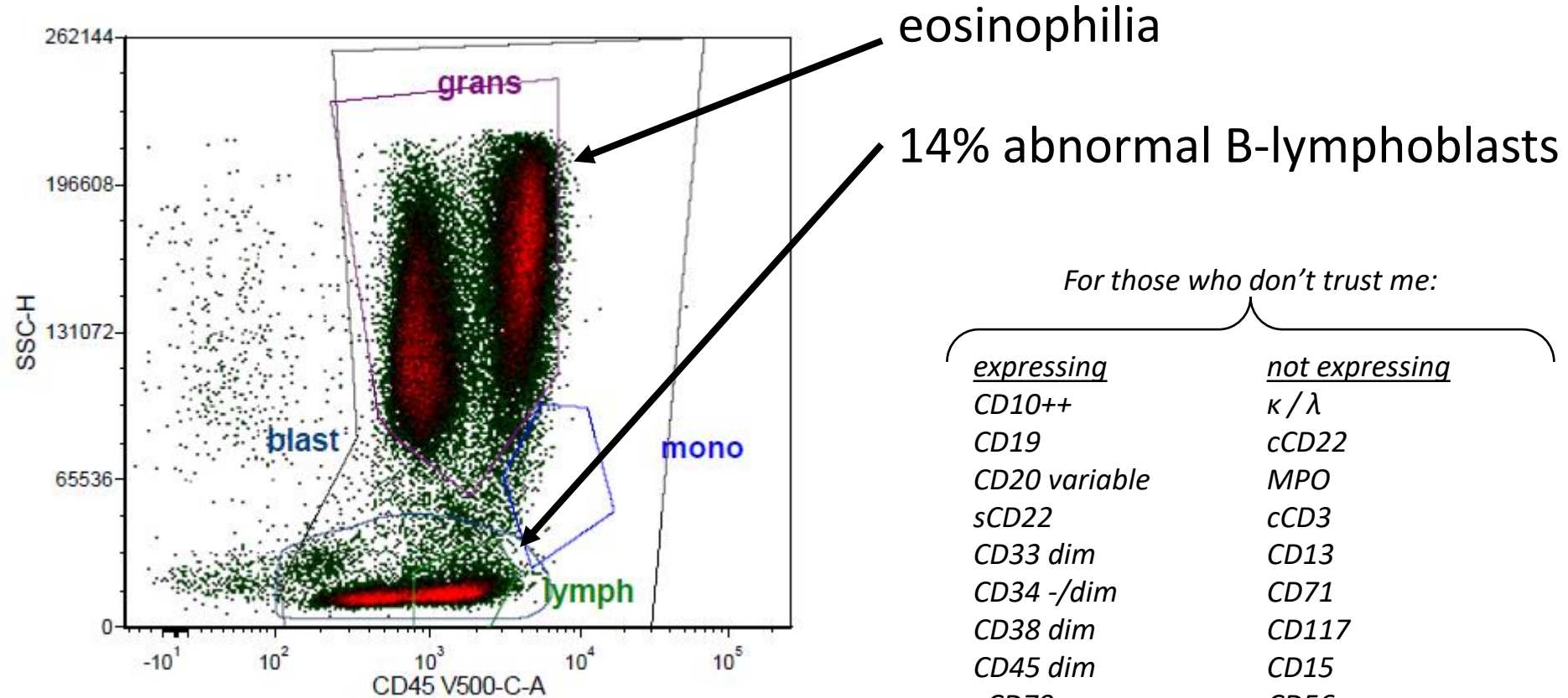
Bone Marrow Core H&E



Bone Marrow Flow Cytometry



Bone Marrow Flow Cytometry



For those who don't trust me:

expressing

CD10++

CD19

CD20 variable

sCD22

CD33 dim

CD34 -/dim

CD38 dim

CD45 dim

cCD79a

CD123 subset

TdT

HLA-DR variable

not expressing

κ / λ

cCD22

MPO

cCD3

CD13

CD71

CD117

CD15

CD56

CD11b

CD14

CD16

CD64

other T-cell antigens

Peripheral Blood Flow Cytometry

- 2.8% abnormal immature B-lymphoblasts with same immunophenotype as marrow flow

DIAGNOSIS?

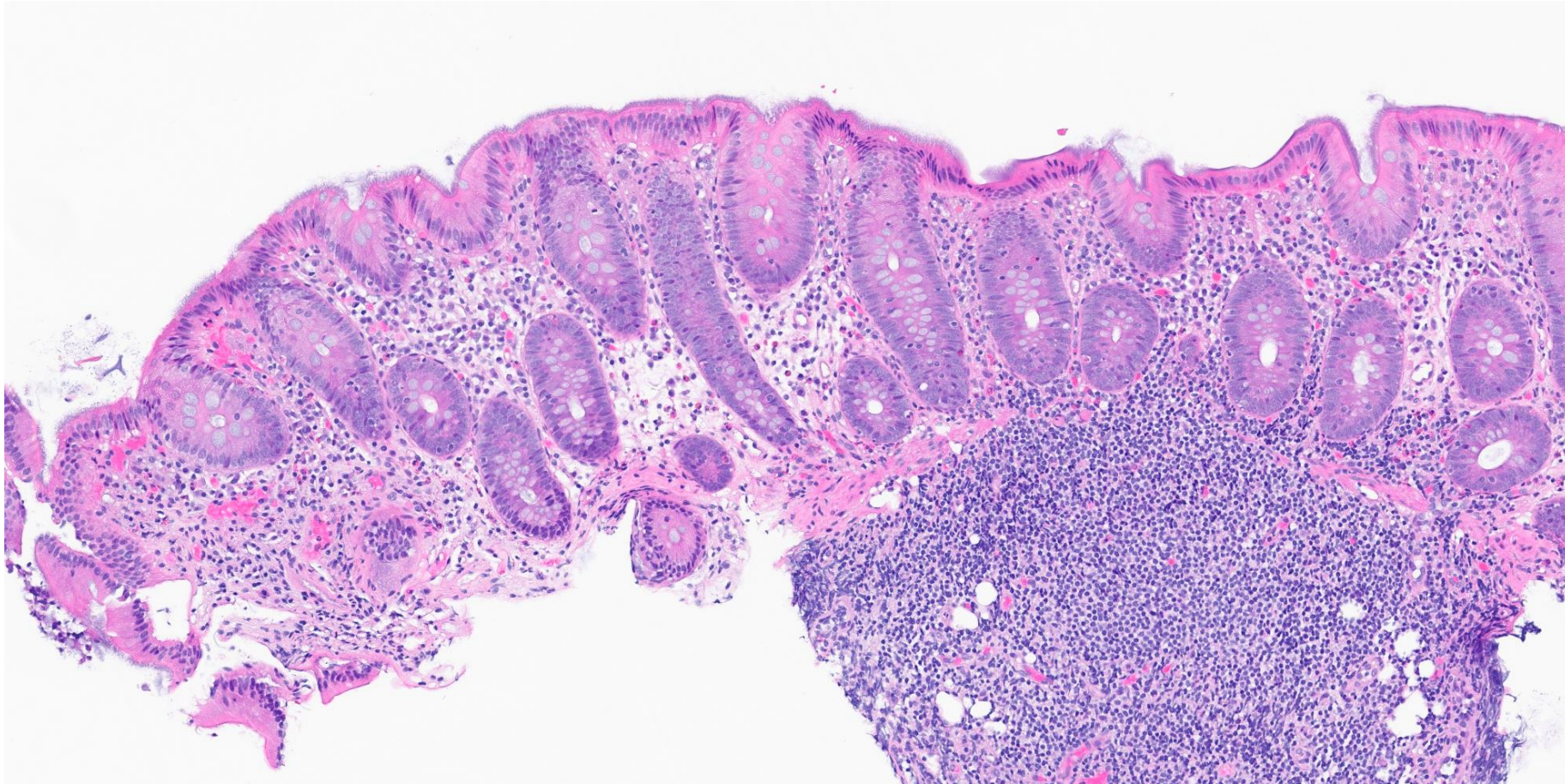


26-0604

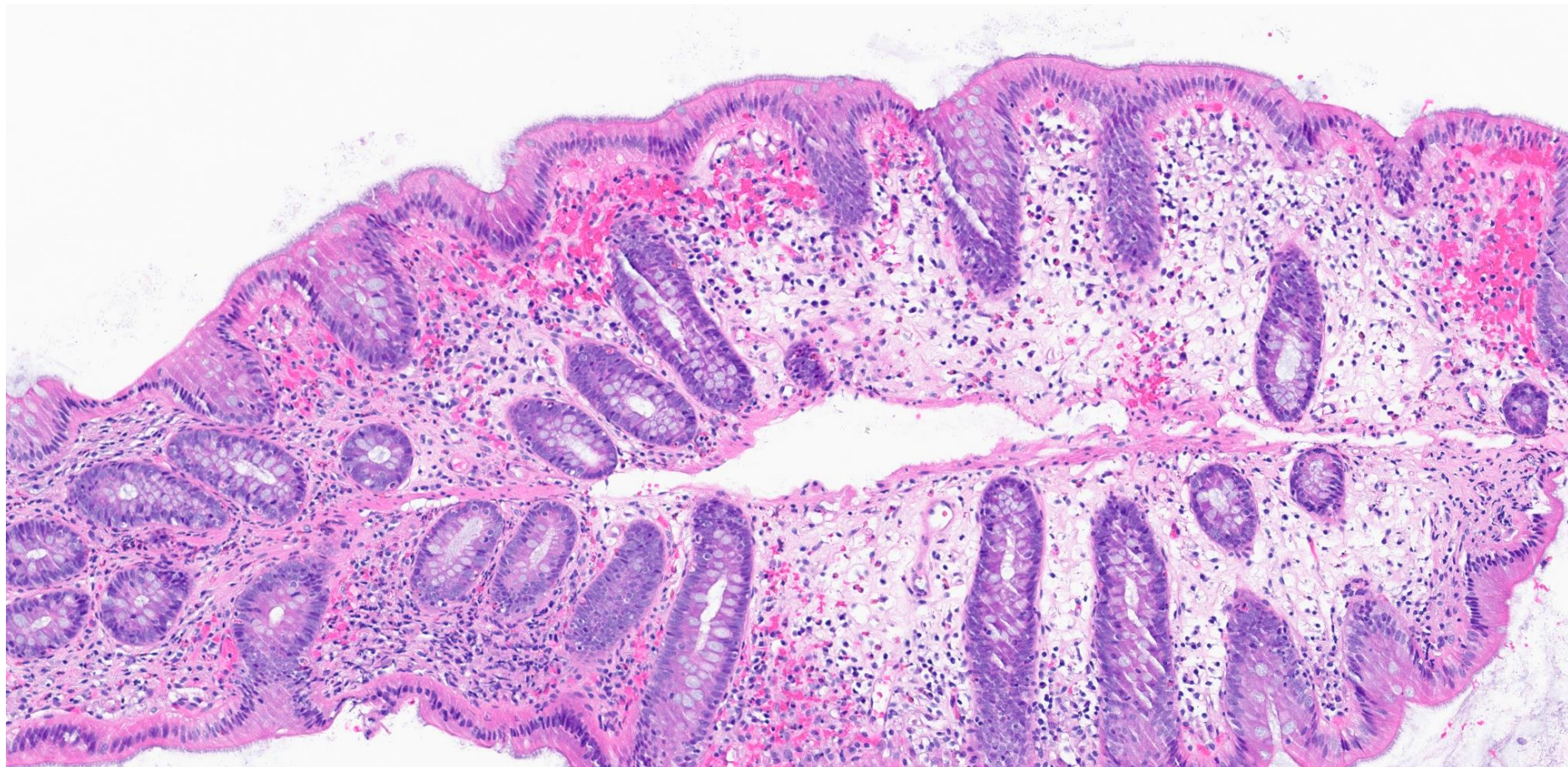
Eric Ollila; Stanford

24 yo M Hispanic field worker. History of perianal abscess I&Dx2 presenting with non-healing perianal wound, daily diarrhea, and hematochezia. Physical exam revealed complex perianal fistula tracts and two small rectal polyps. Colonoscopy otherwise normal

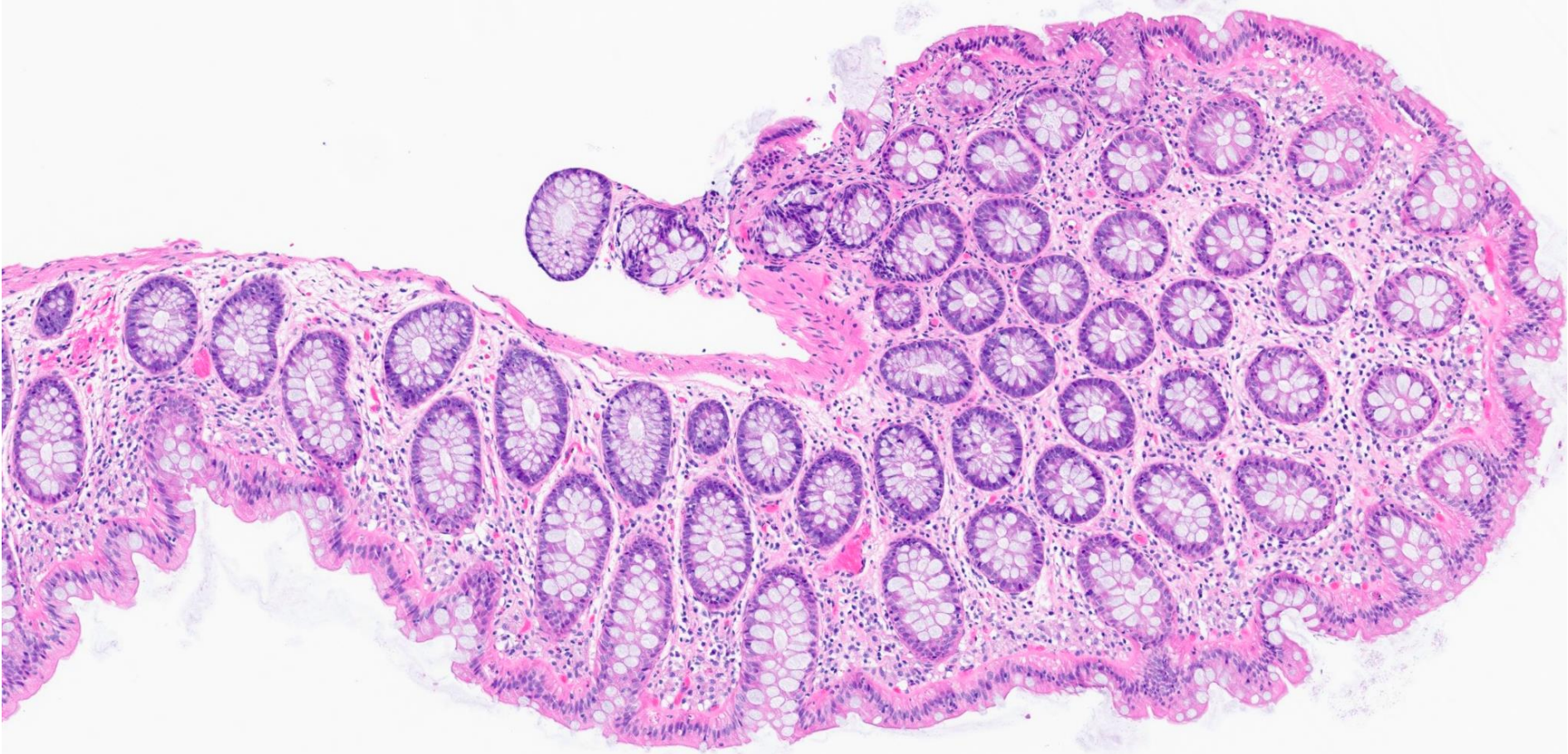
Cecum



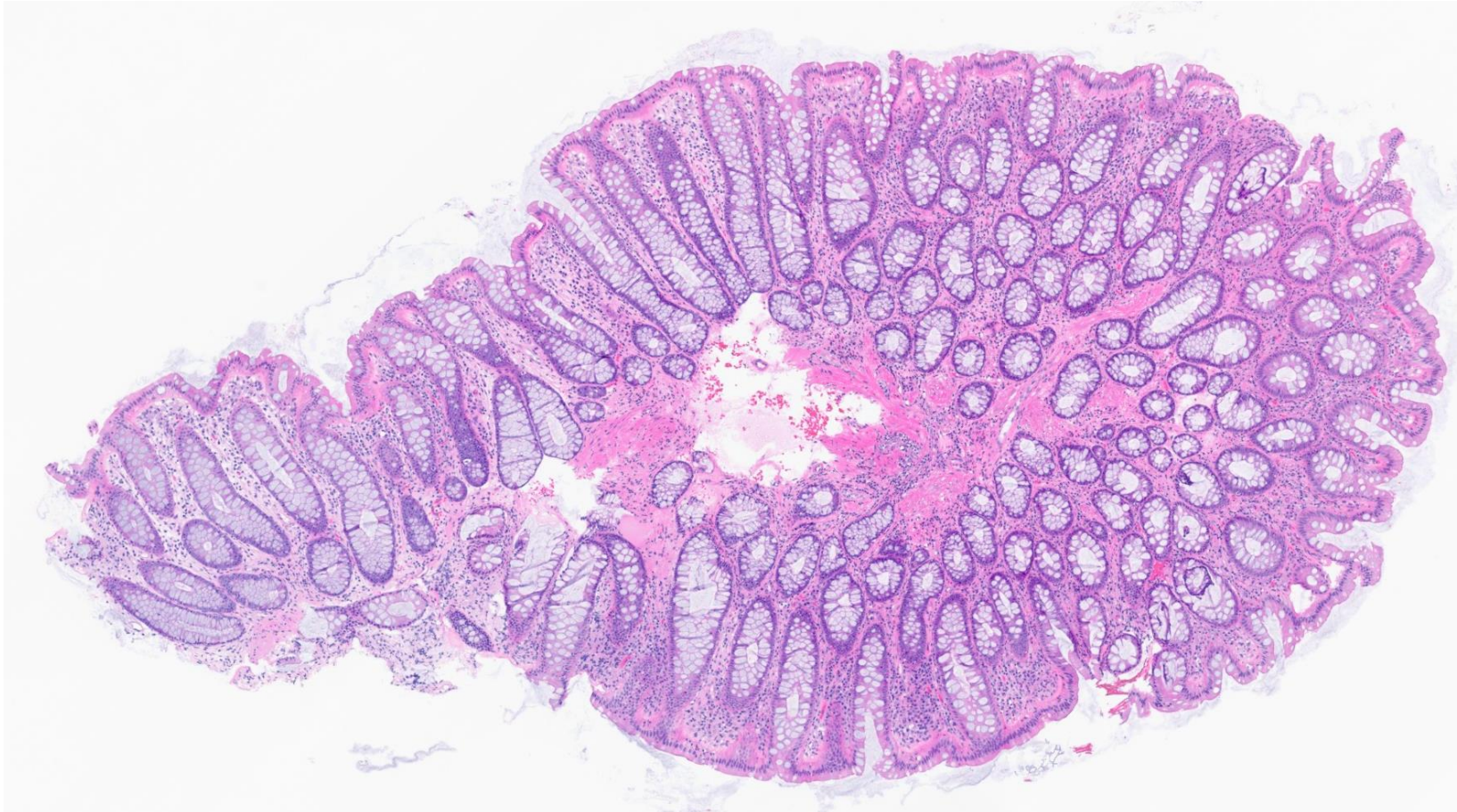Ascending colon



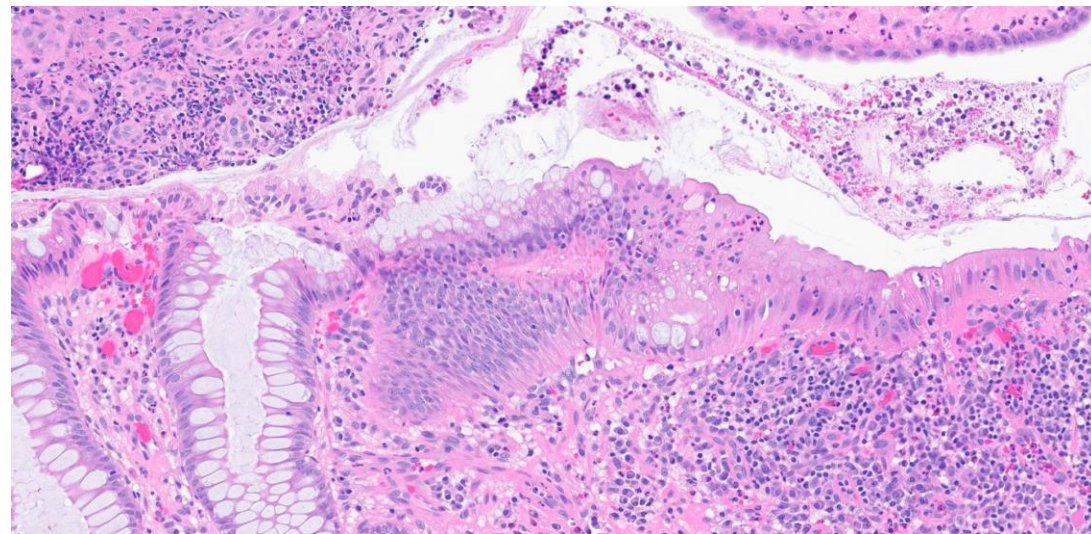
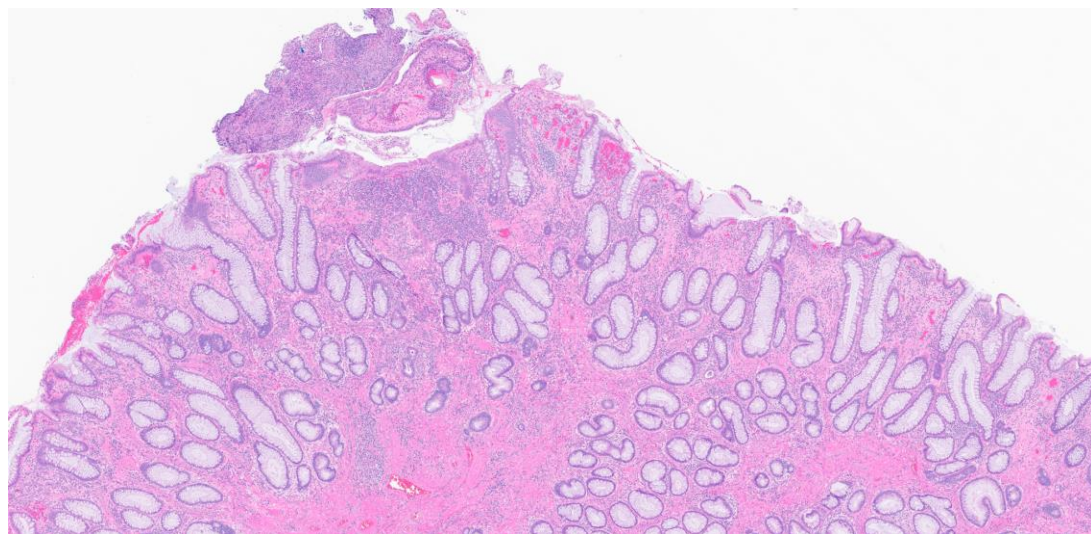
Sigmoid colon



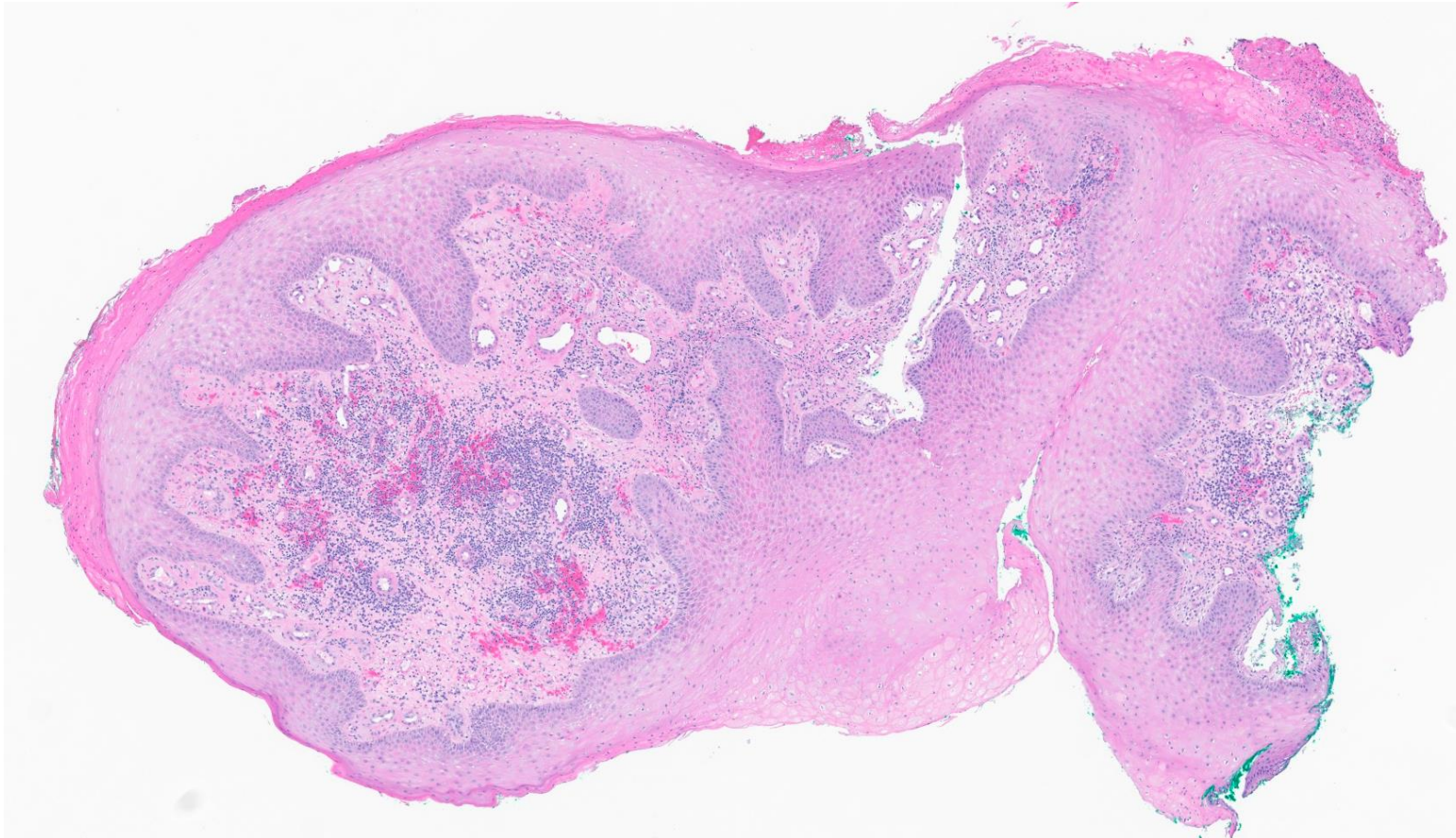
Rectal polyp



Rectal polyp #2



Perirectum, left lateral opening



DIAGNOSIS?

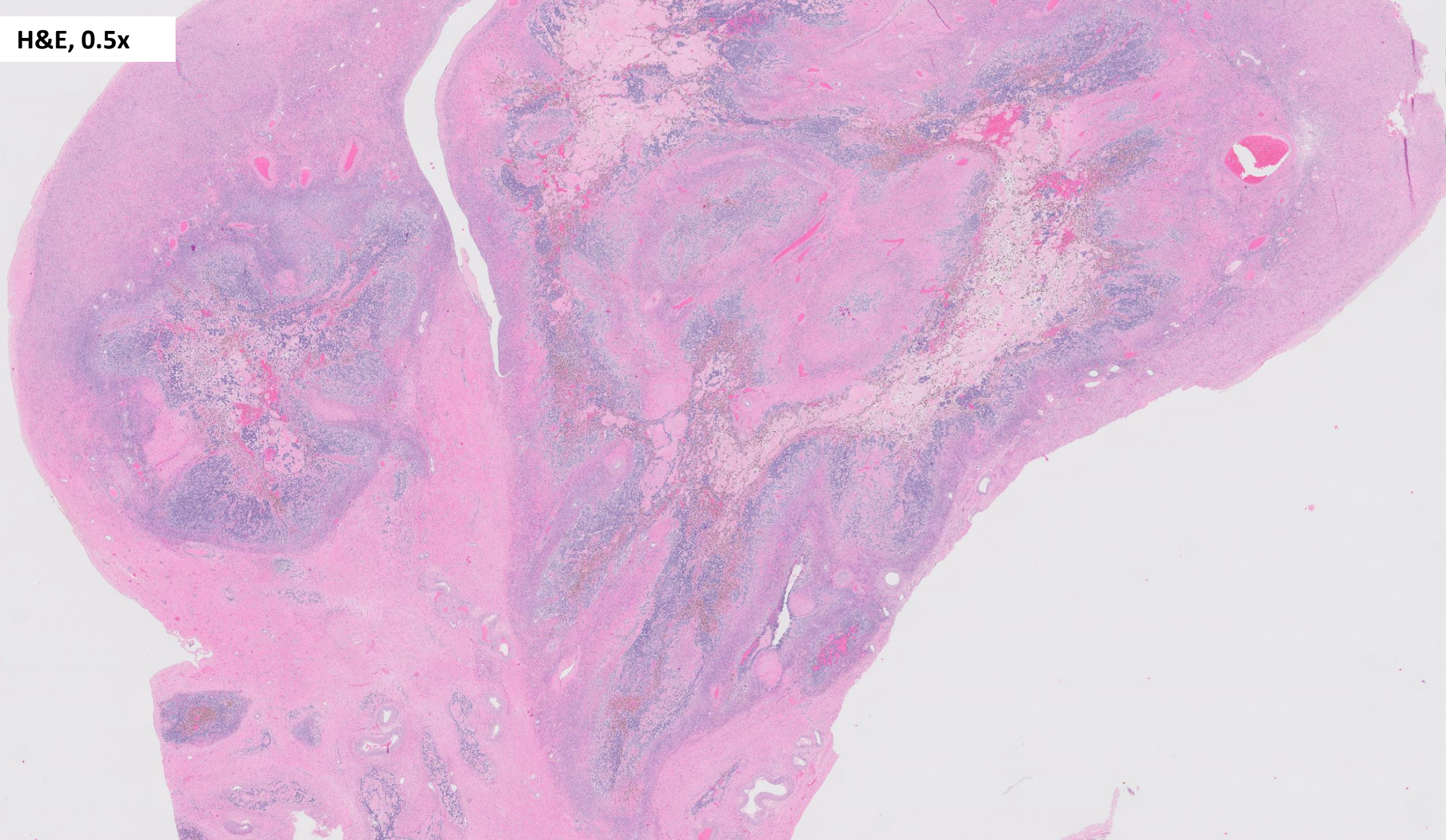


26-0605

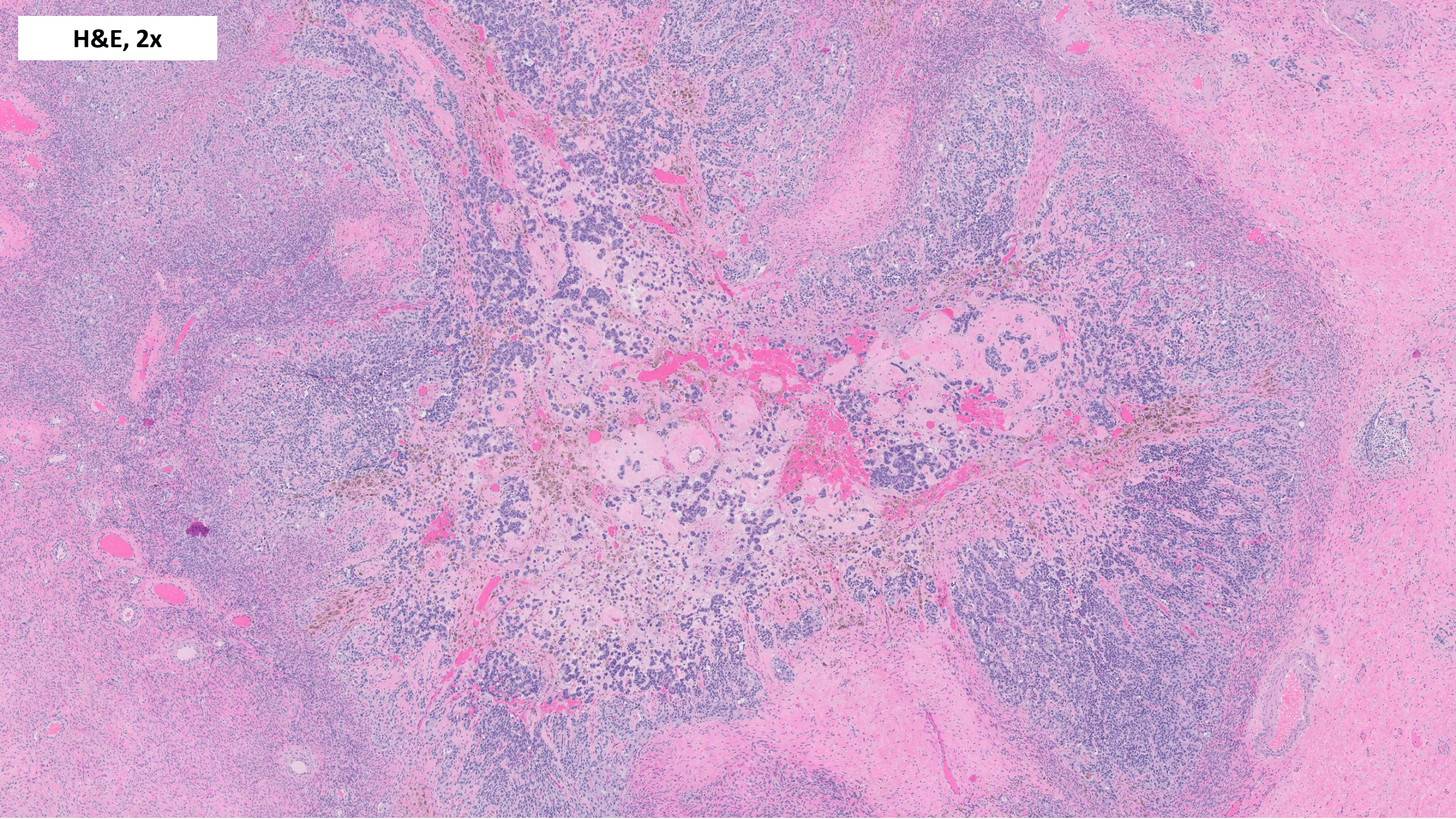
Natalia Sanchez, MD and Kevin Lu; UCSF

63-year-old female with bloating, dysphagia, and dyspnea. CT showing ascites, peritoneal carcinomatosis, multiple bilateral pulmonary nodules, and a 13 cm cystic pelvic mass. CA-125 elevated (91 U/mL). On gross evaluation, right ovarian cyst with serous content and a 3 cm brown-orange solid area.

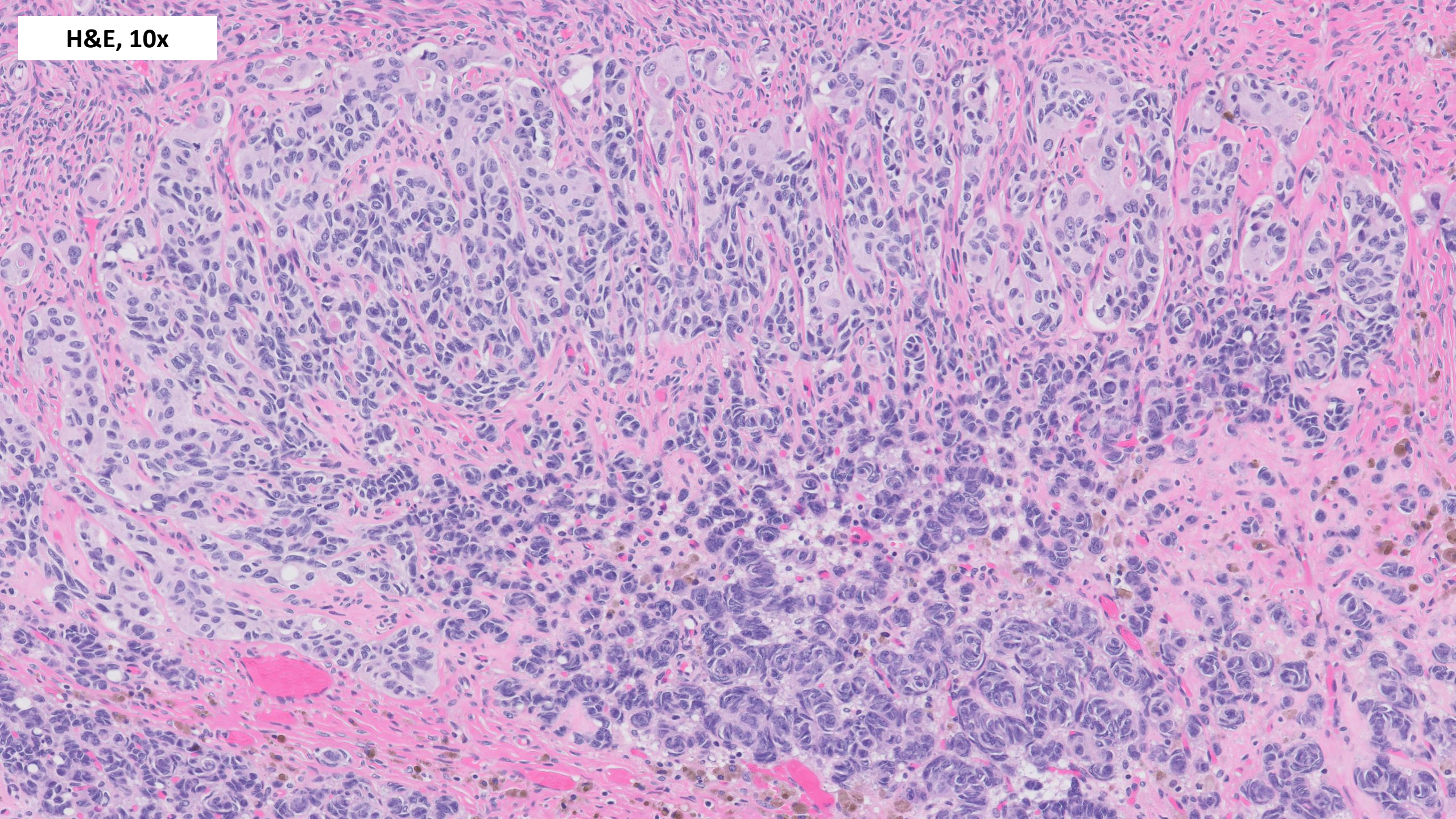
H&E, 0.5x



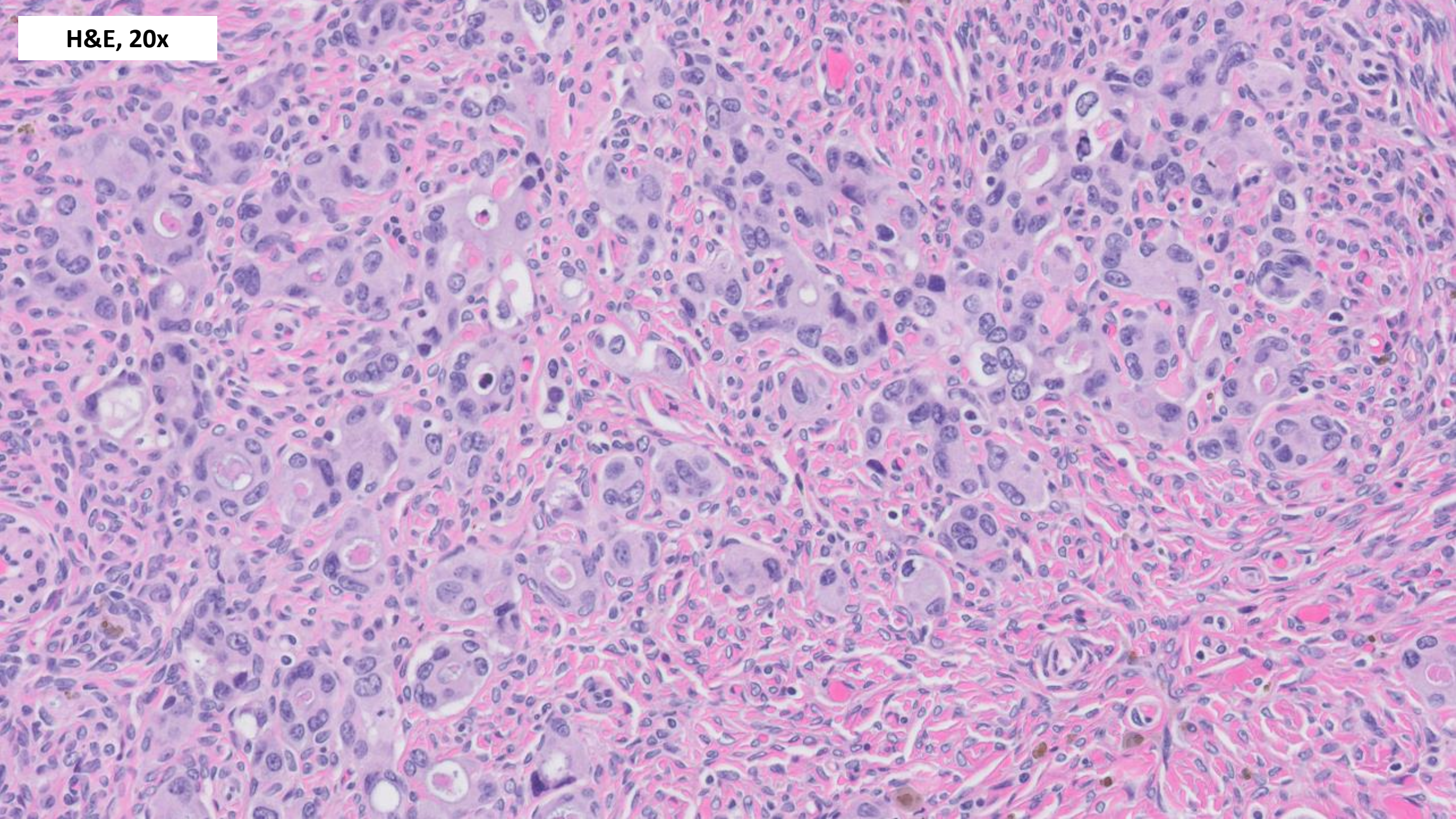
H&E, 2x



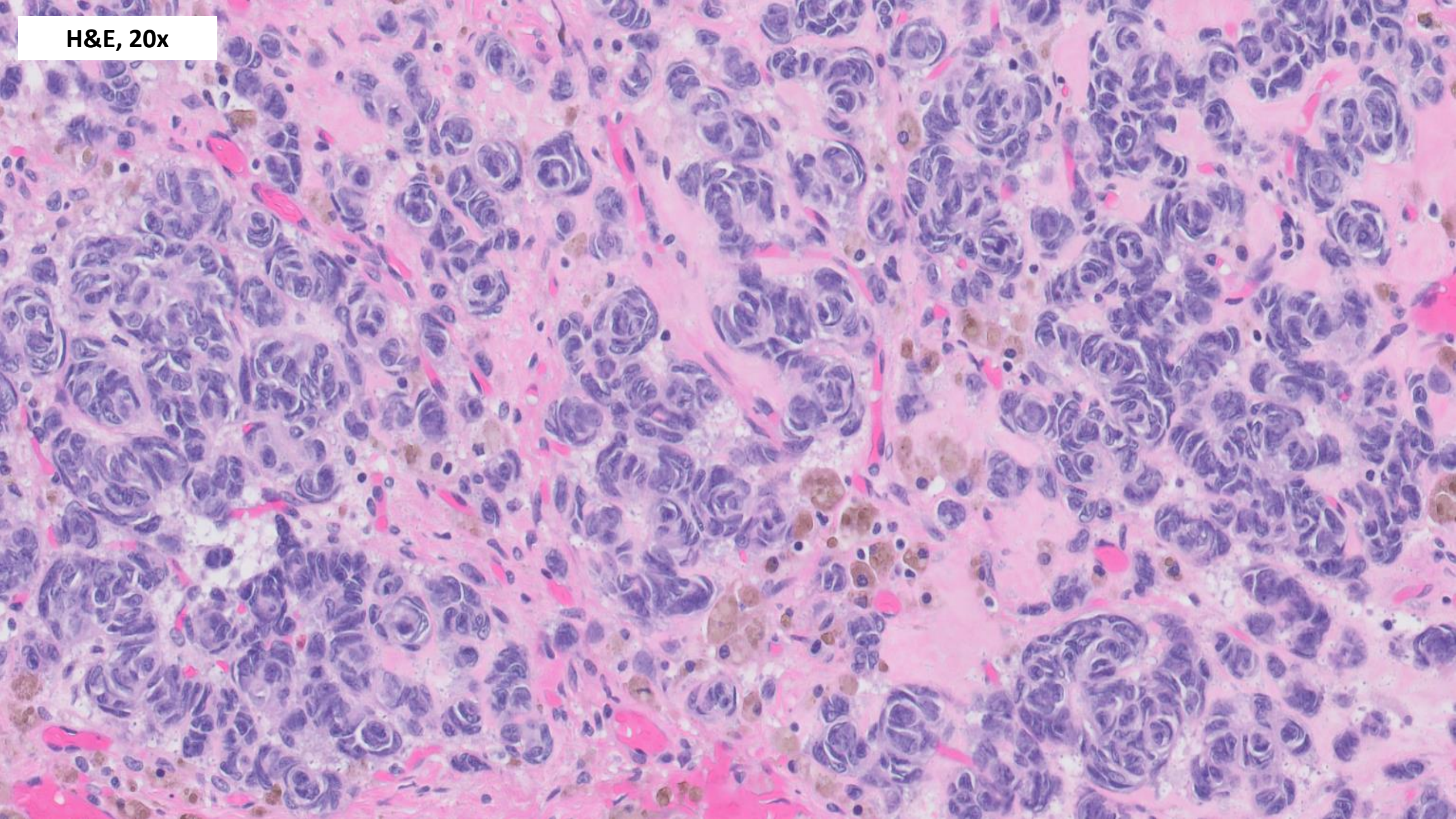
H&E, 10x



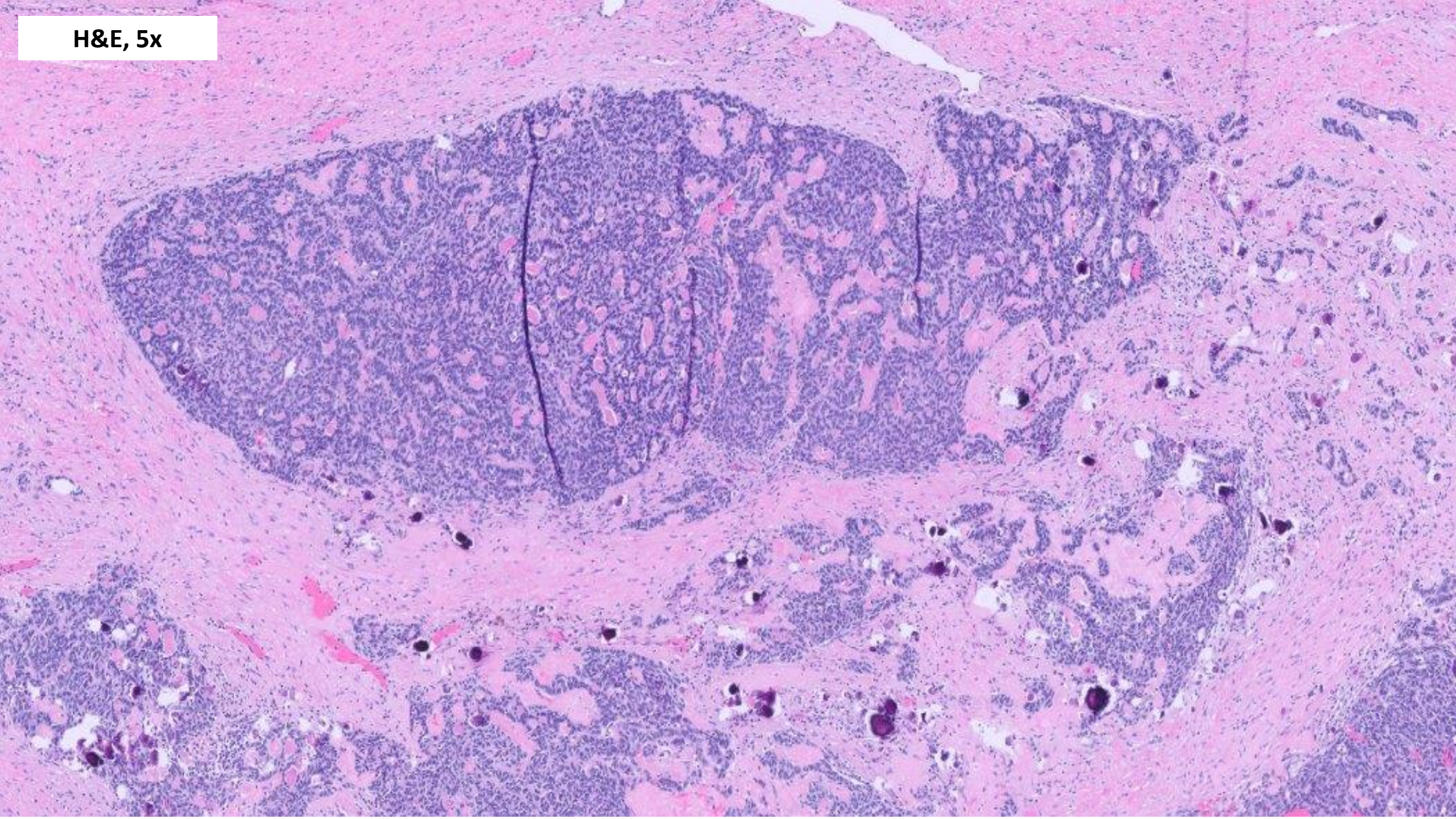
H&E, 20x



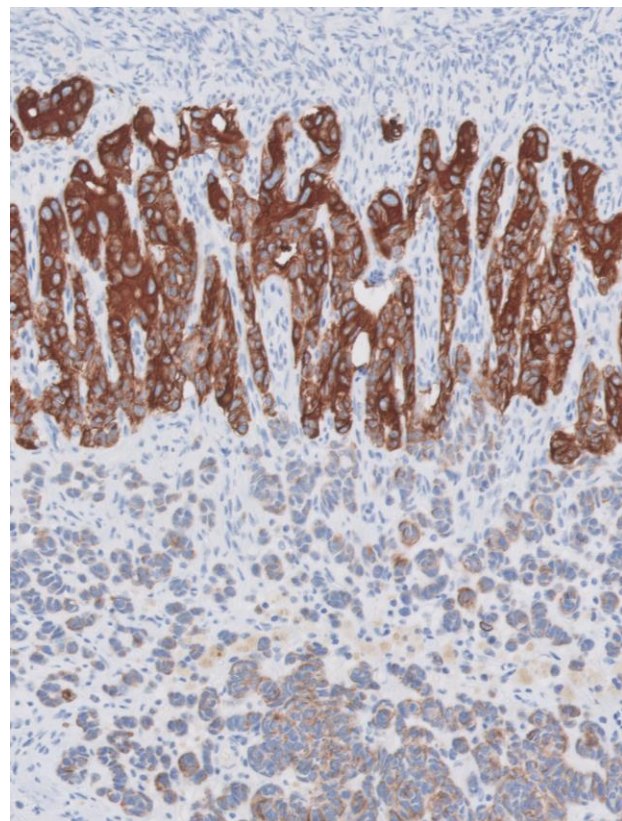
H&E, 20x



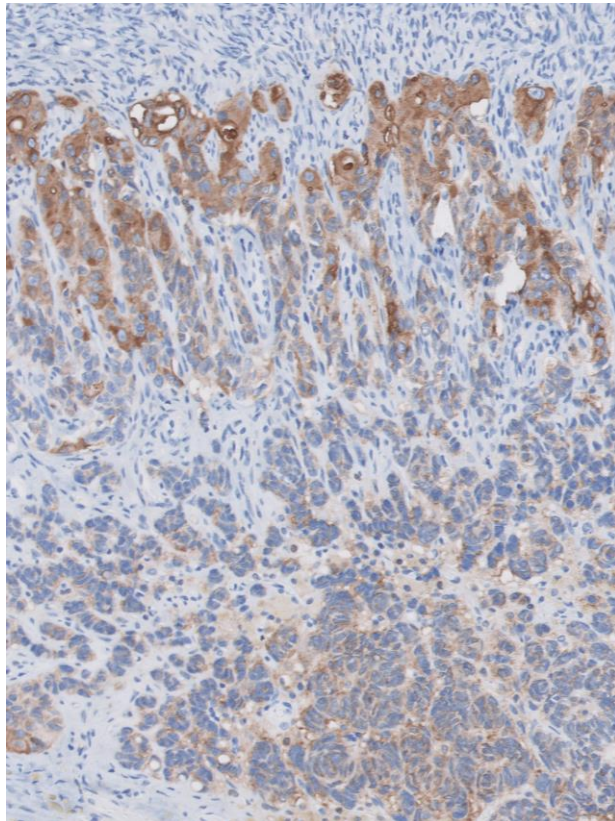
H&E, 5x



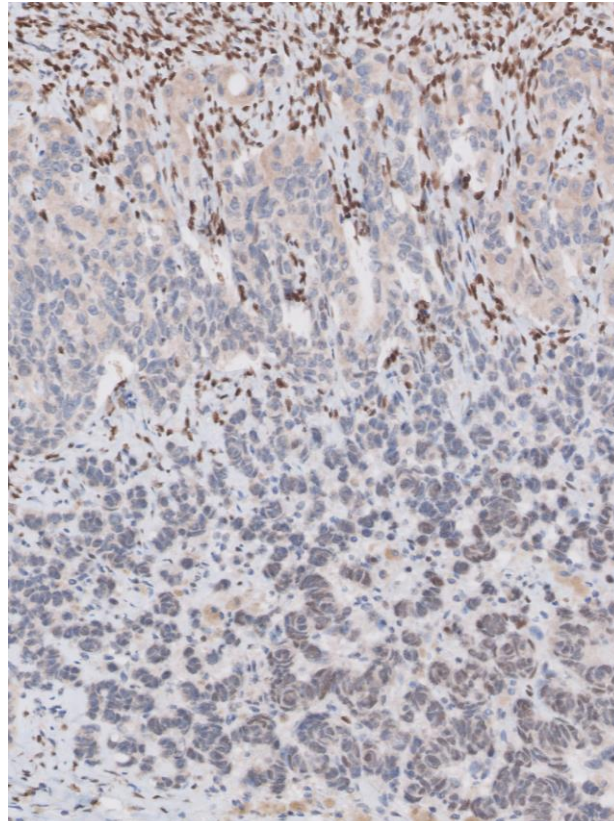
PanCK, 10x



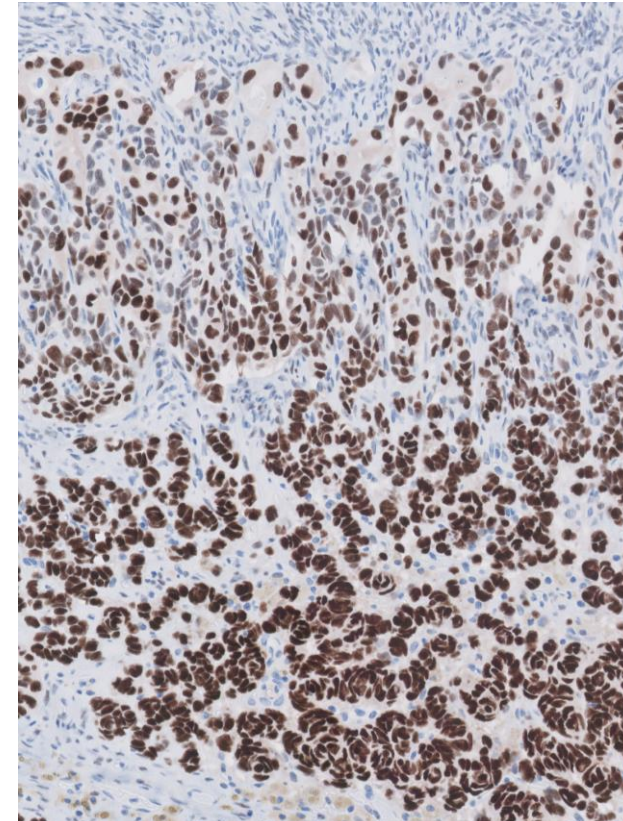
EMA, 10x



FOXL2, 10x



ER, 10x



Negative stains: PAX8, SF1, calretinin, inhibin

DIAGNOSIS?

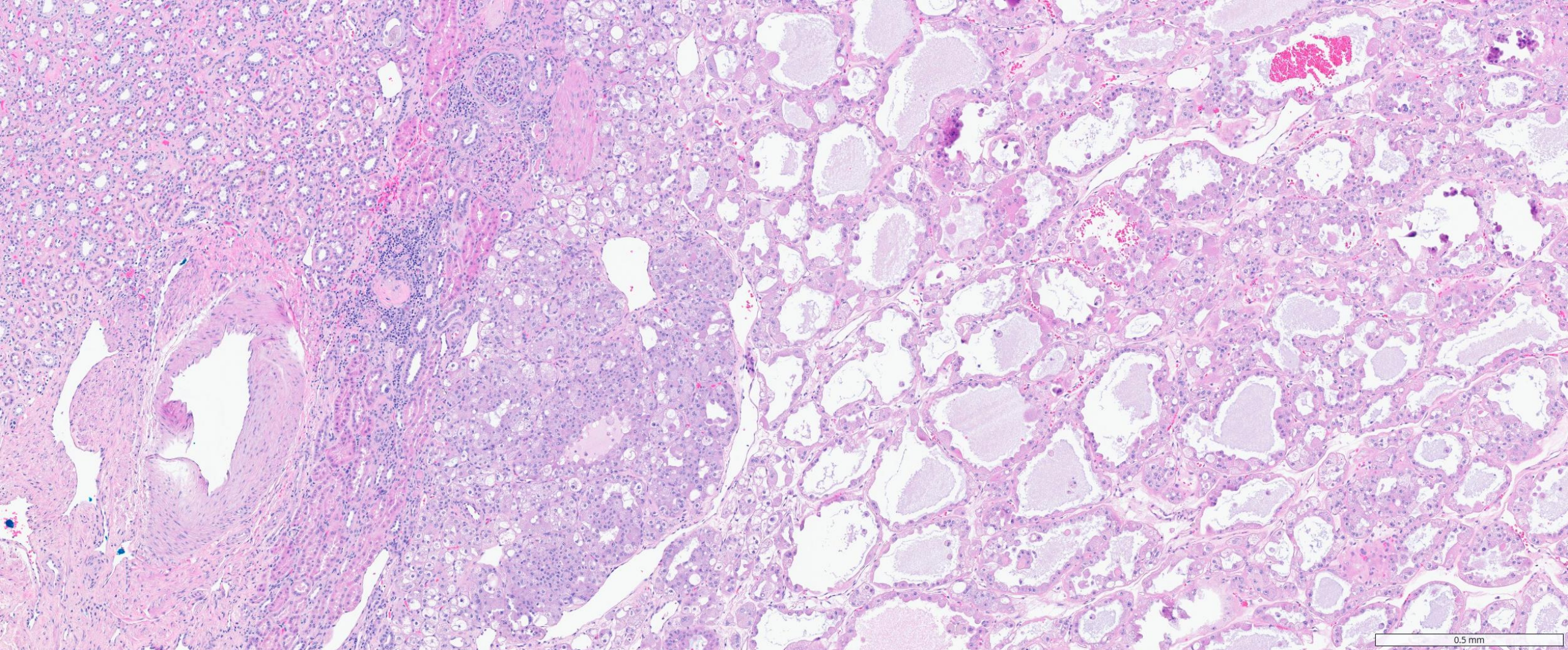


26-0606

Conan Juan and Ankur Sangoi; Stanford

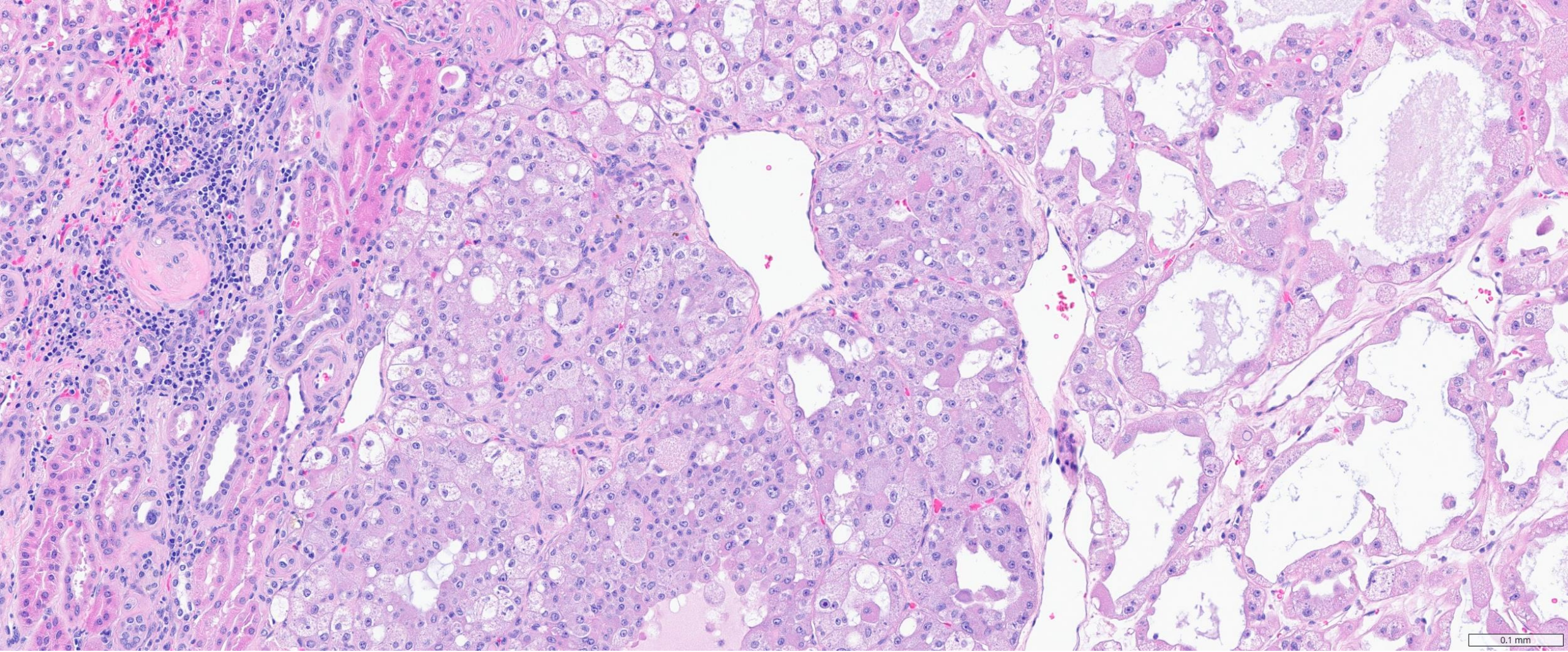
68 yo F with a 3 cm left renal mass suspicious for RCC on imaging.

Kidney, left partial nephrectomy



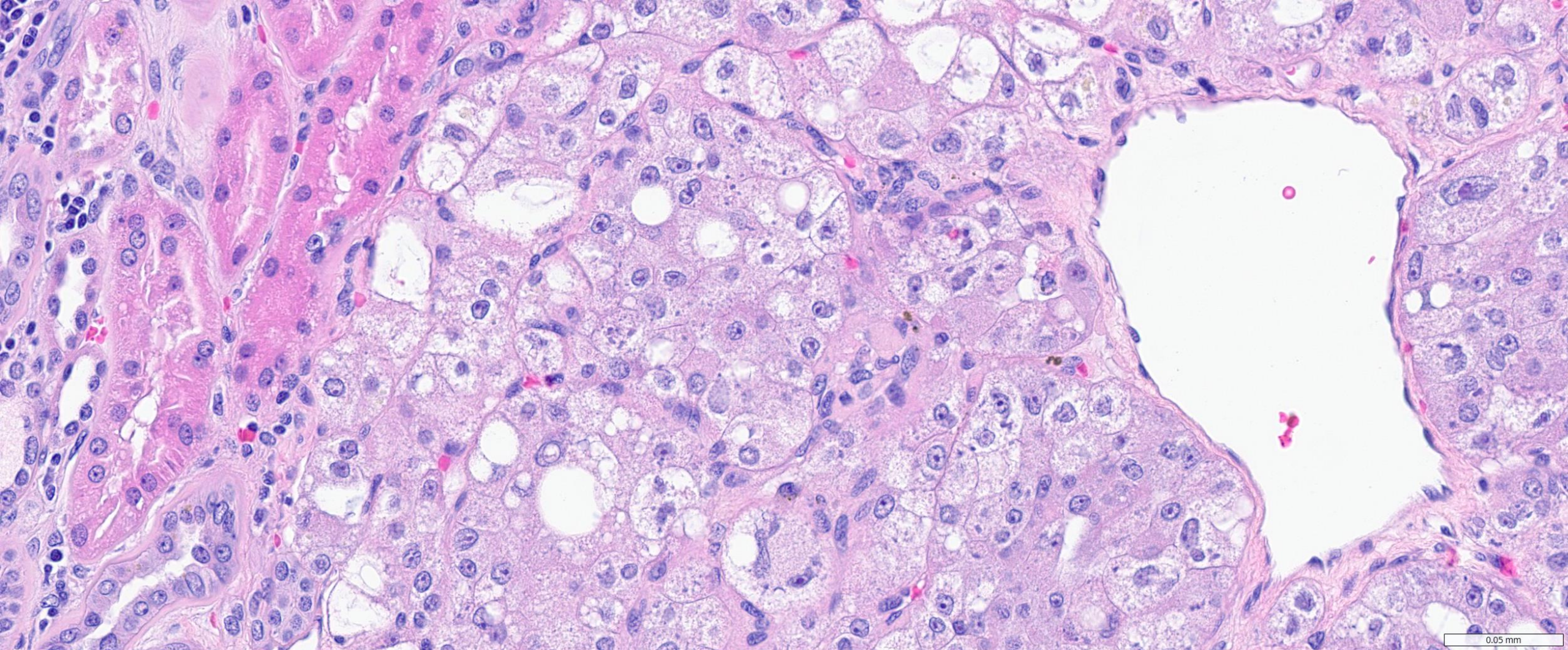
Low power

Kidney, left partial nephrectomy, med mag



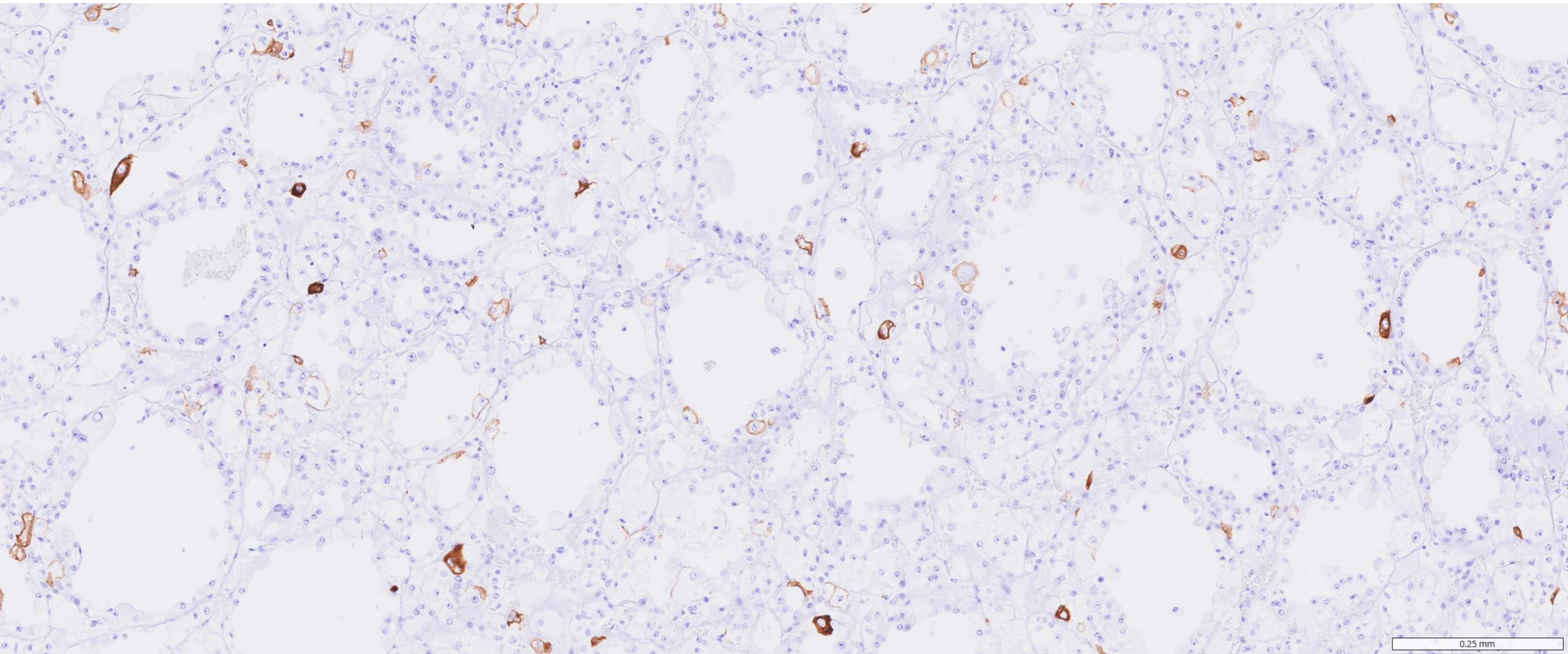
Med power

Kidney, left partial nephrectomy



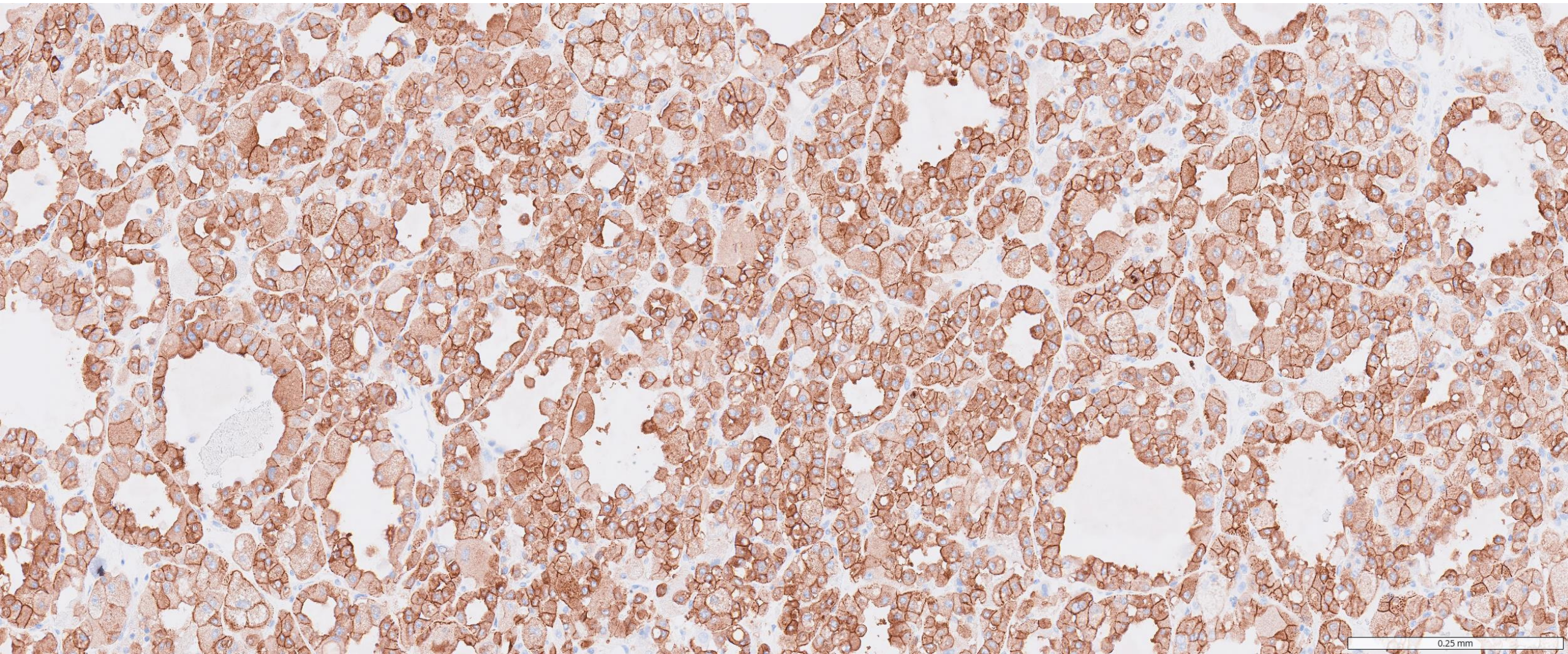
High power

CK7



0.25 mm

CD117



Diagnosis? What other stains do you want to order?

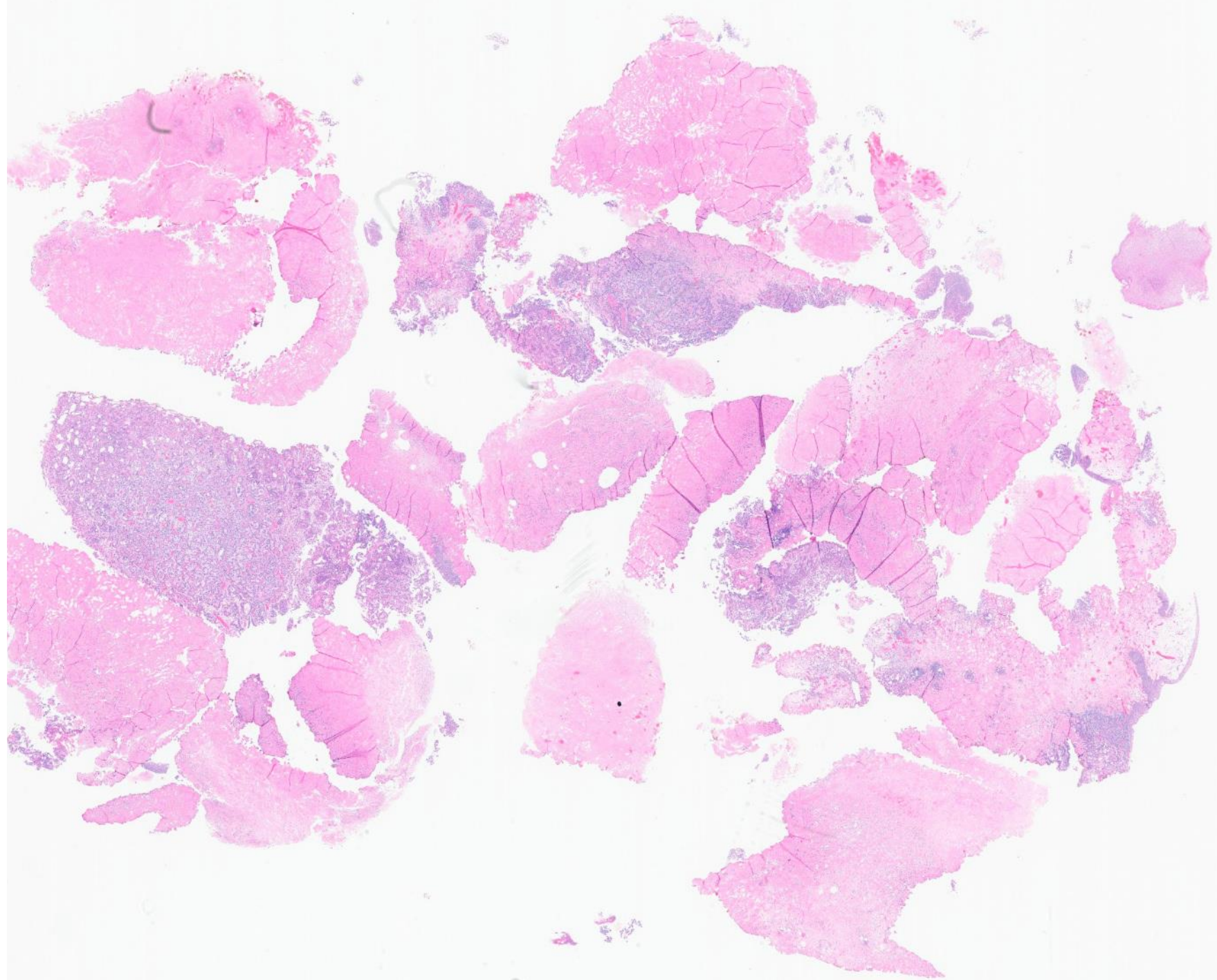
DIAGNOSIS?

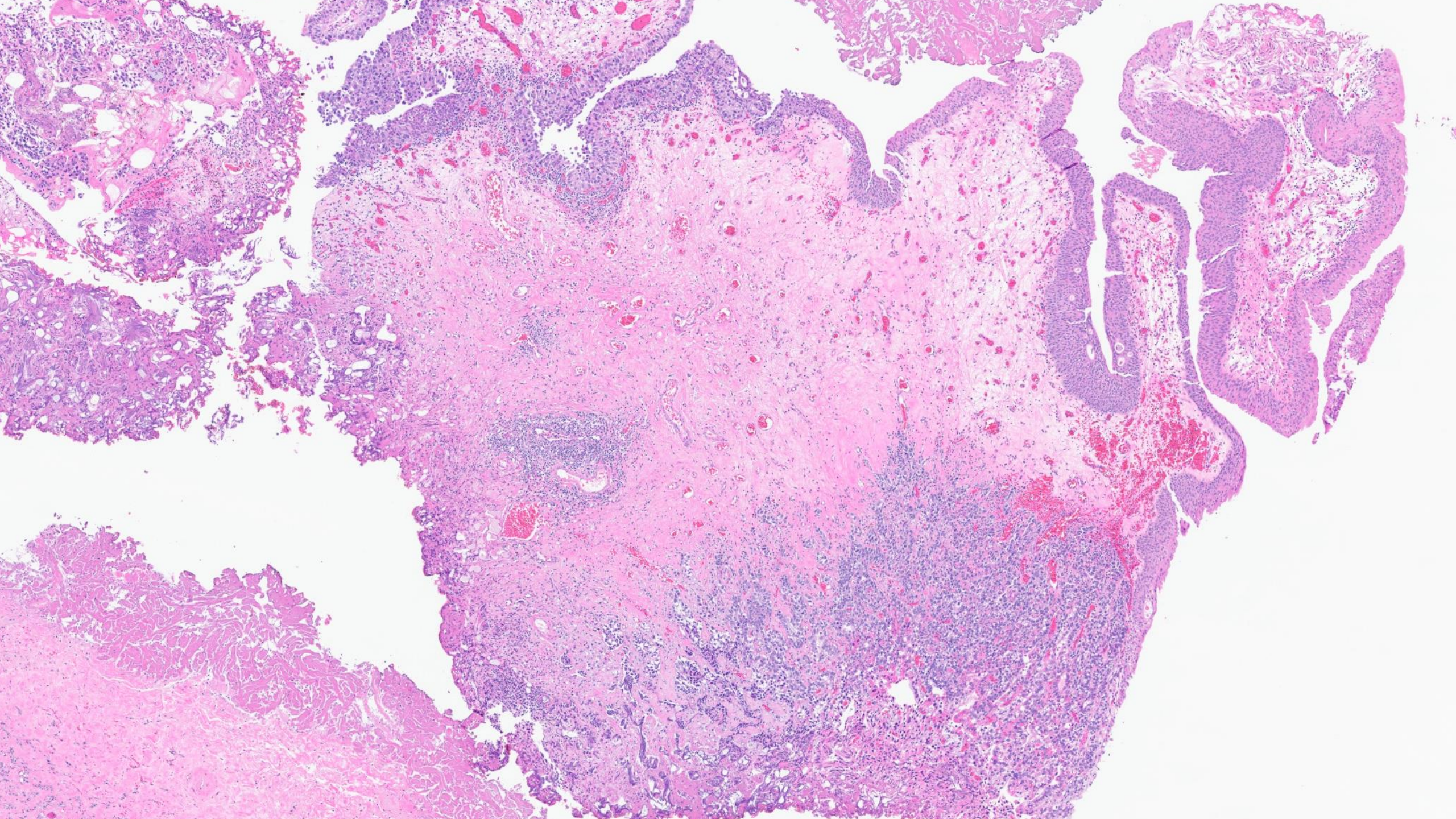


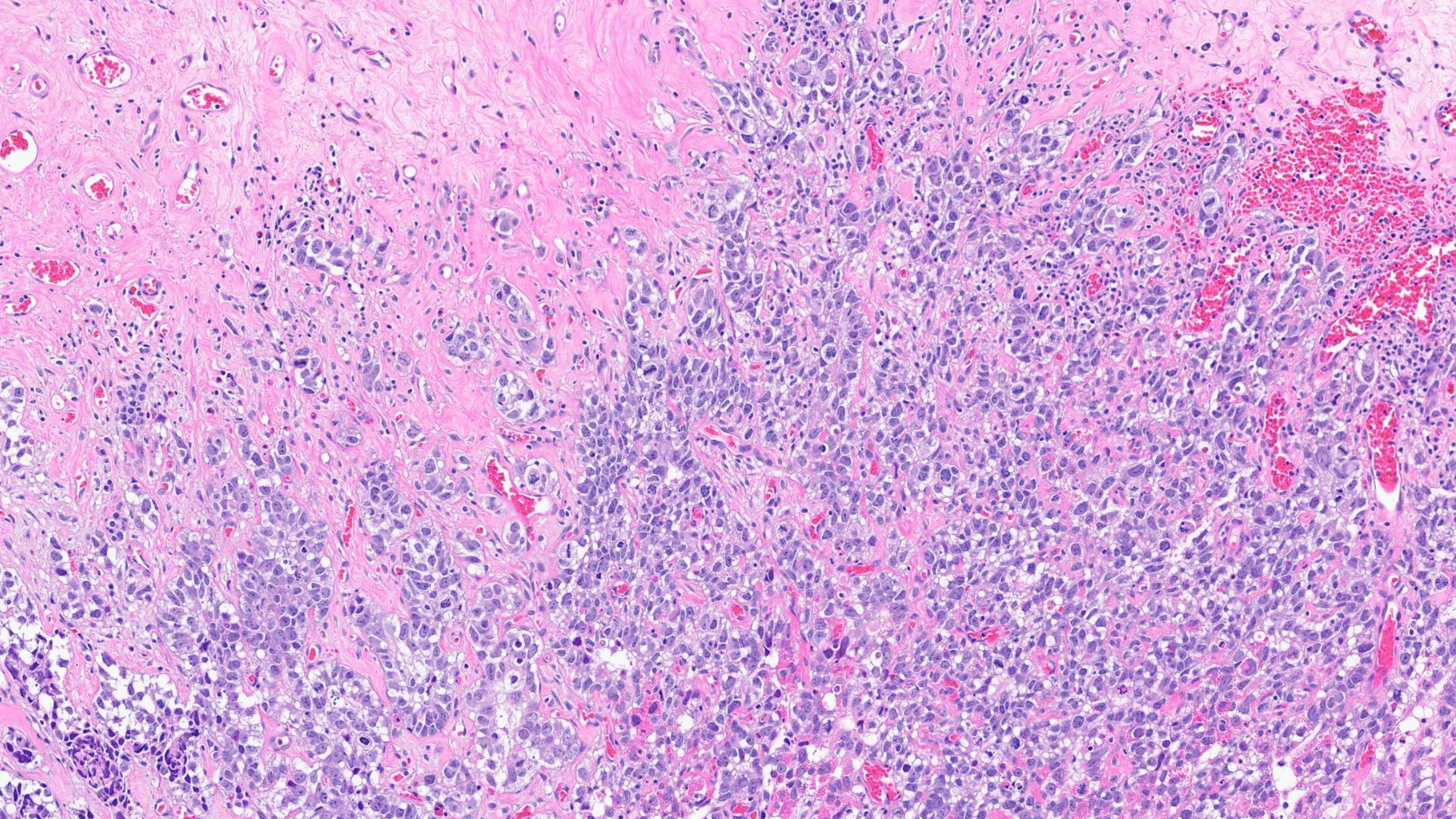
26-0607

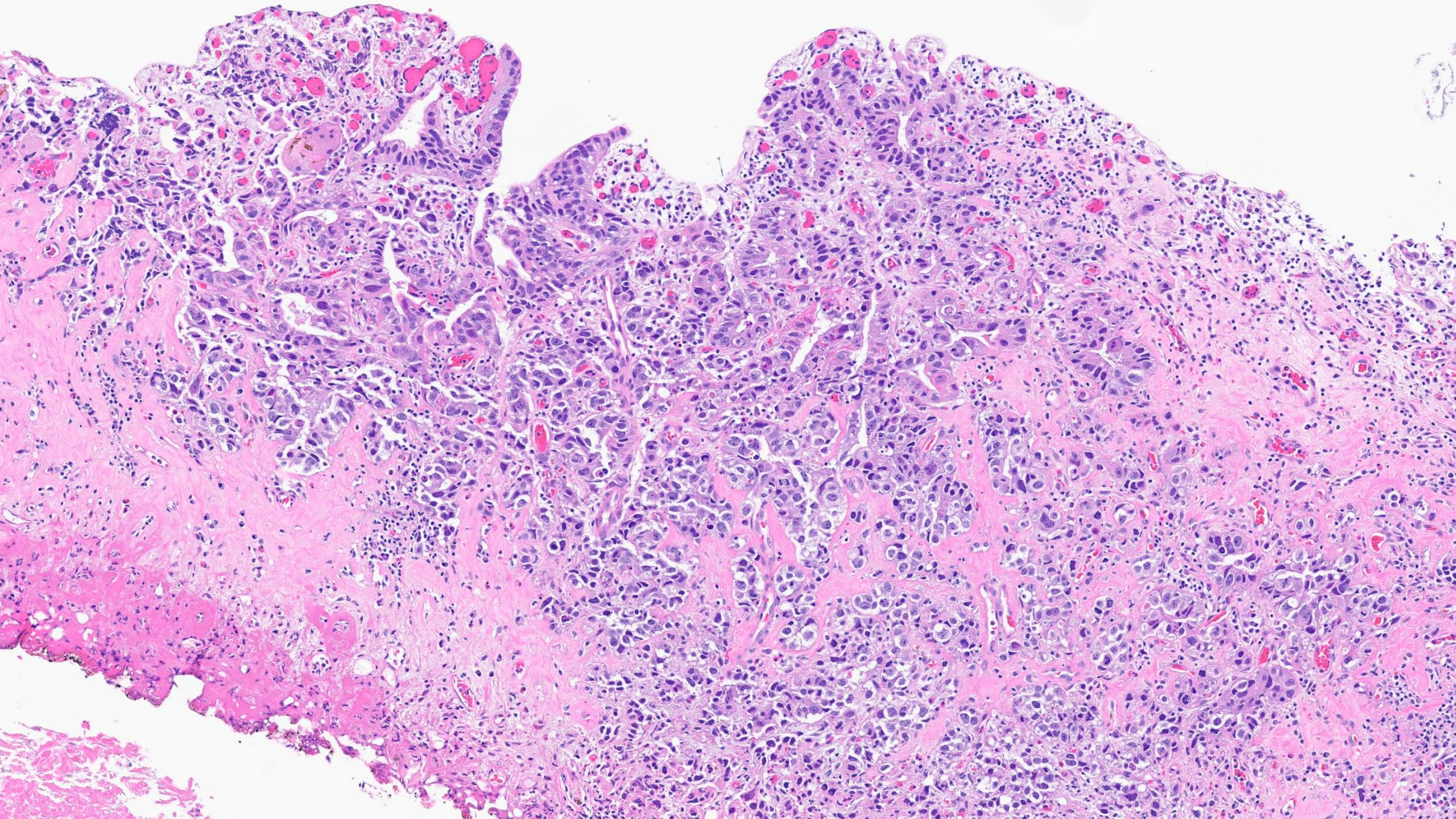
Rich Pacheco and Emily Chan; Stanford

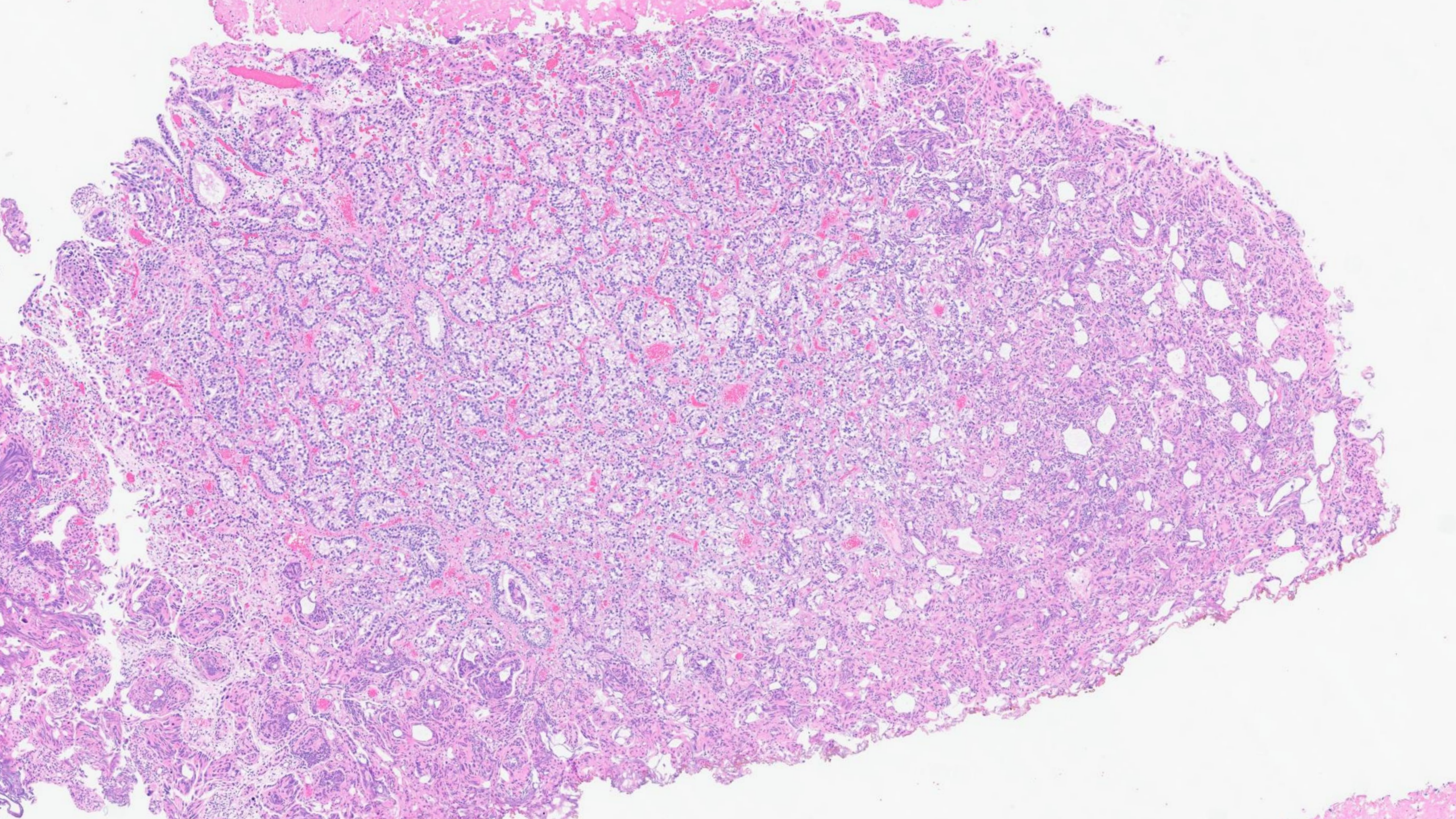
59-year-old man with hematuria. Cystoscopy shows a >5cm tumor

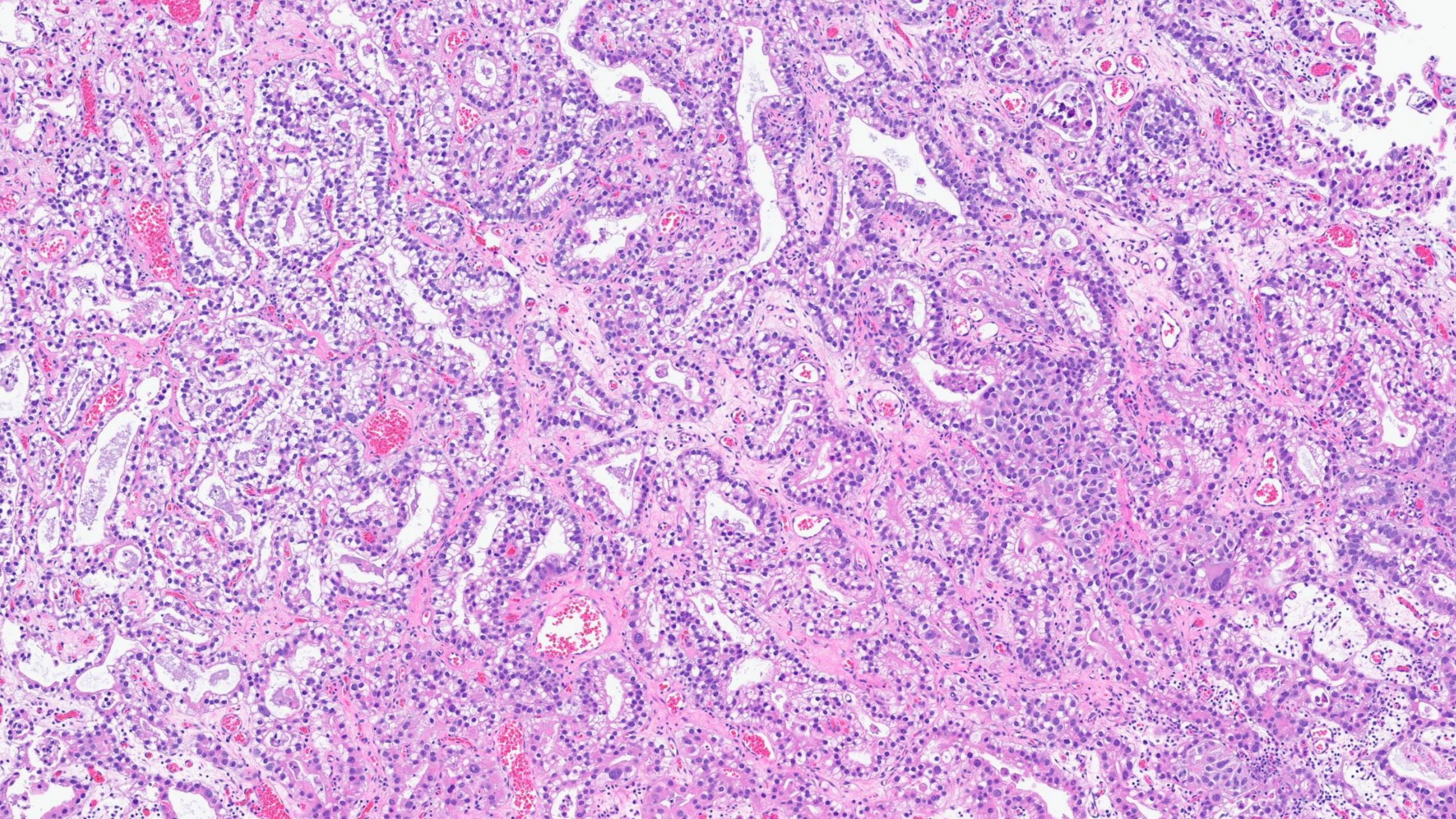


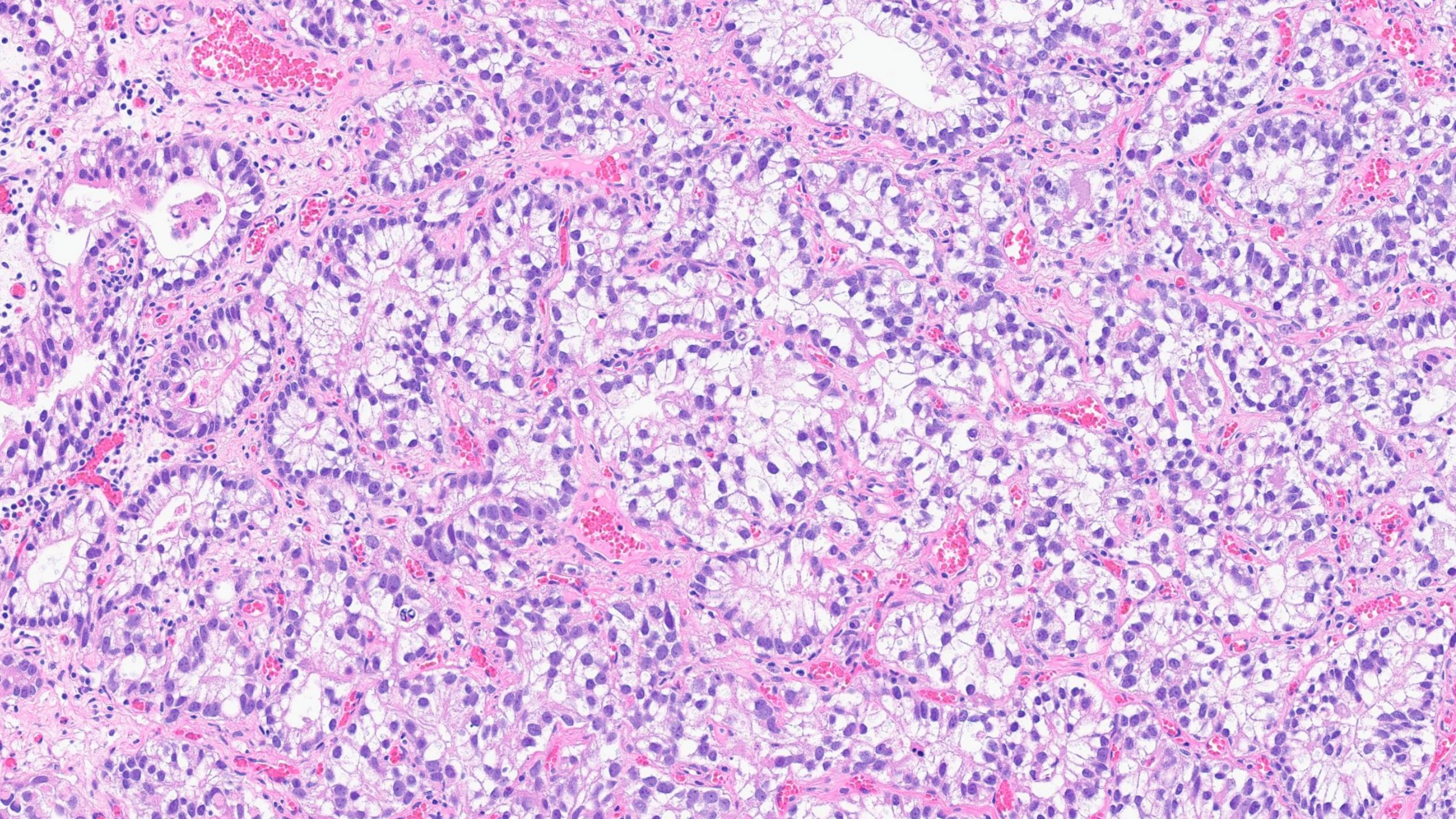


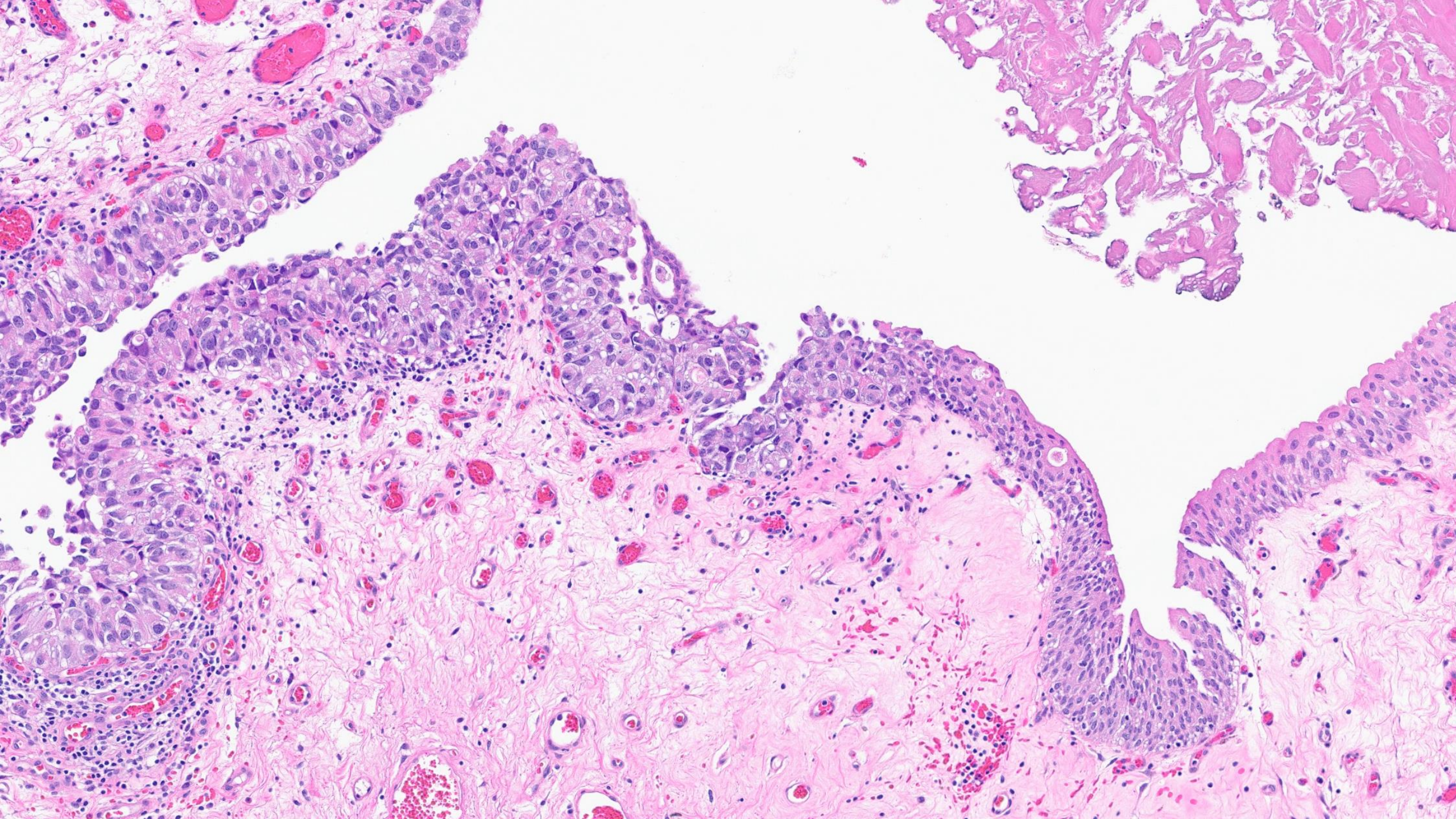


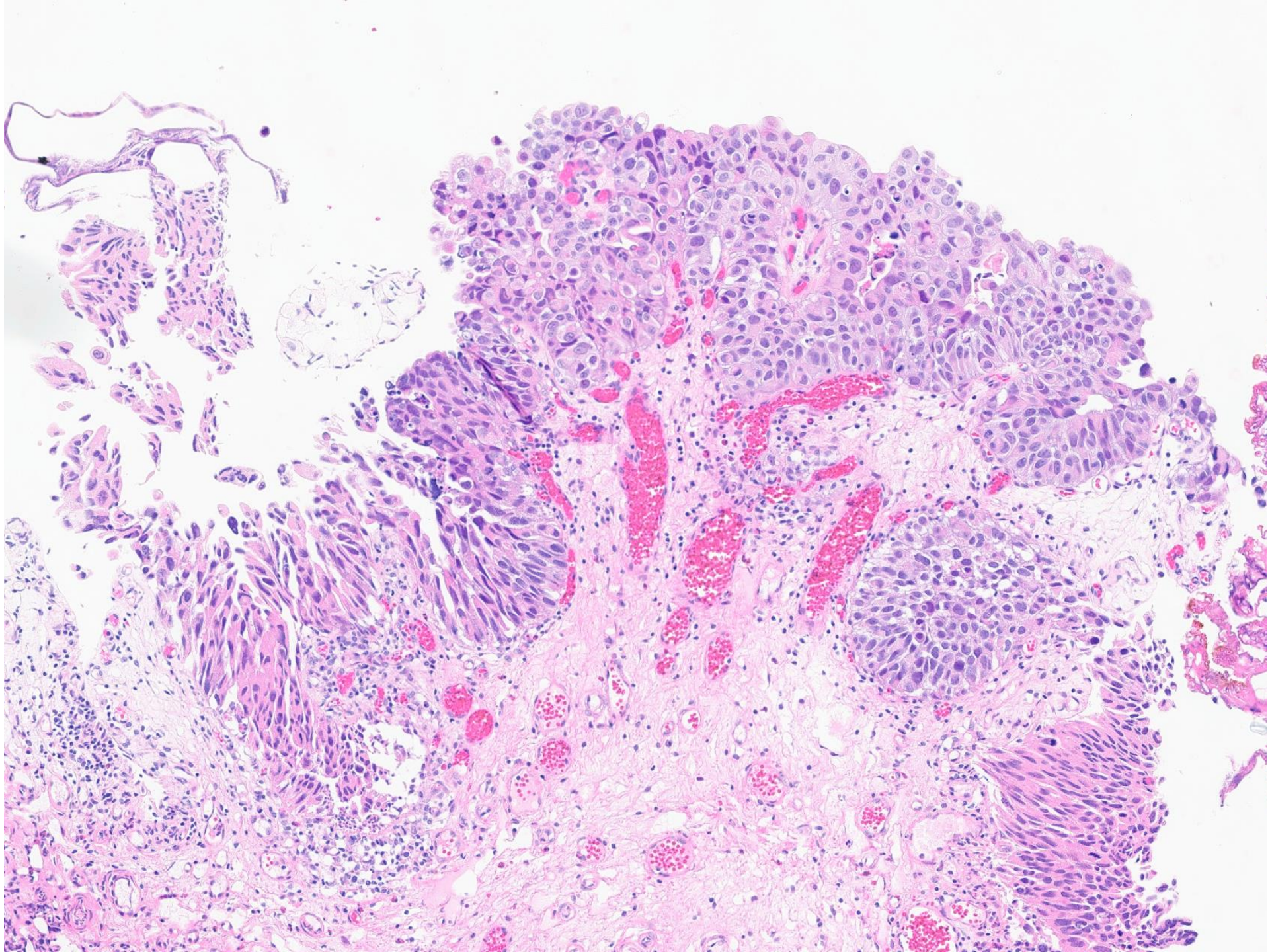












DIAGNOSIS?

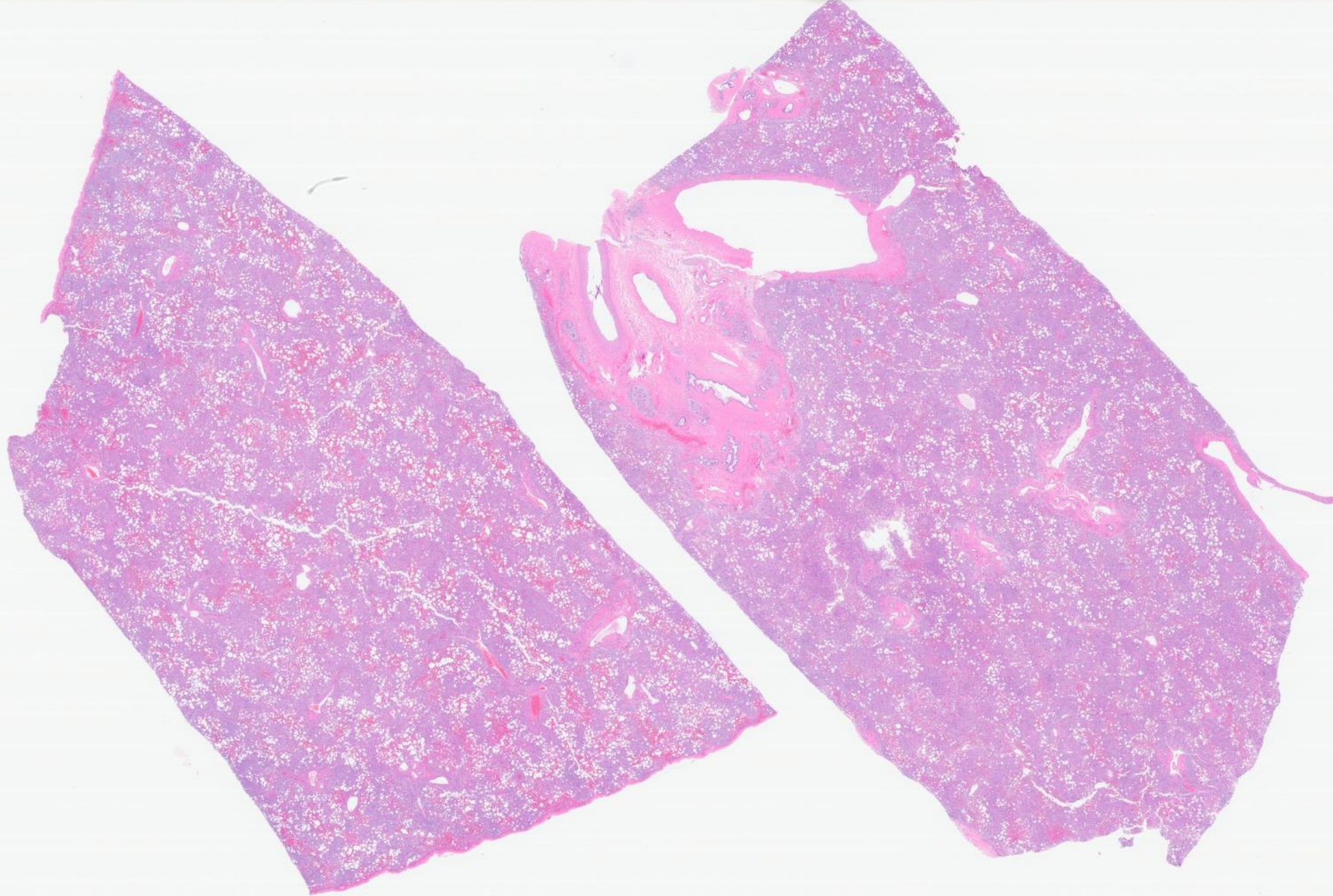


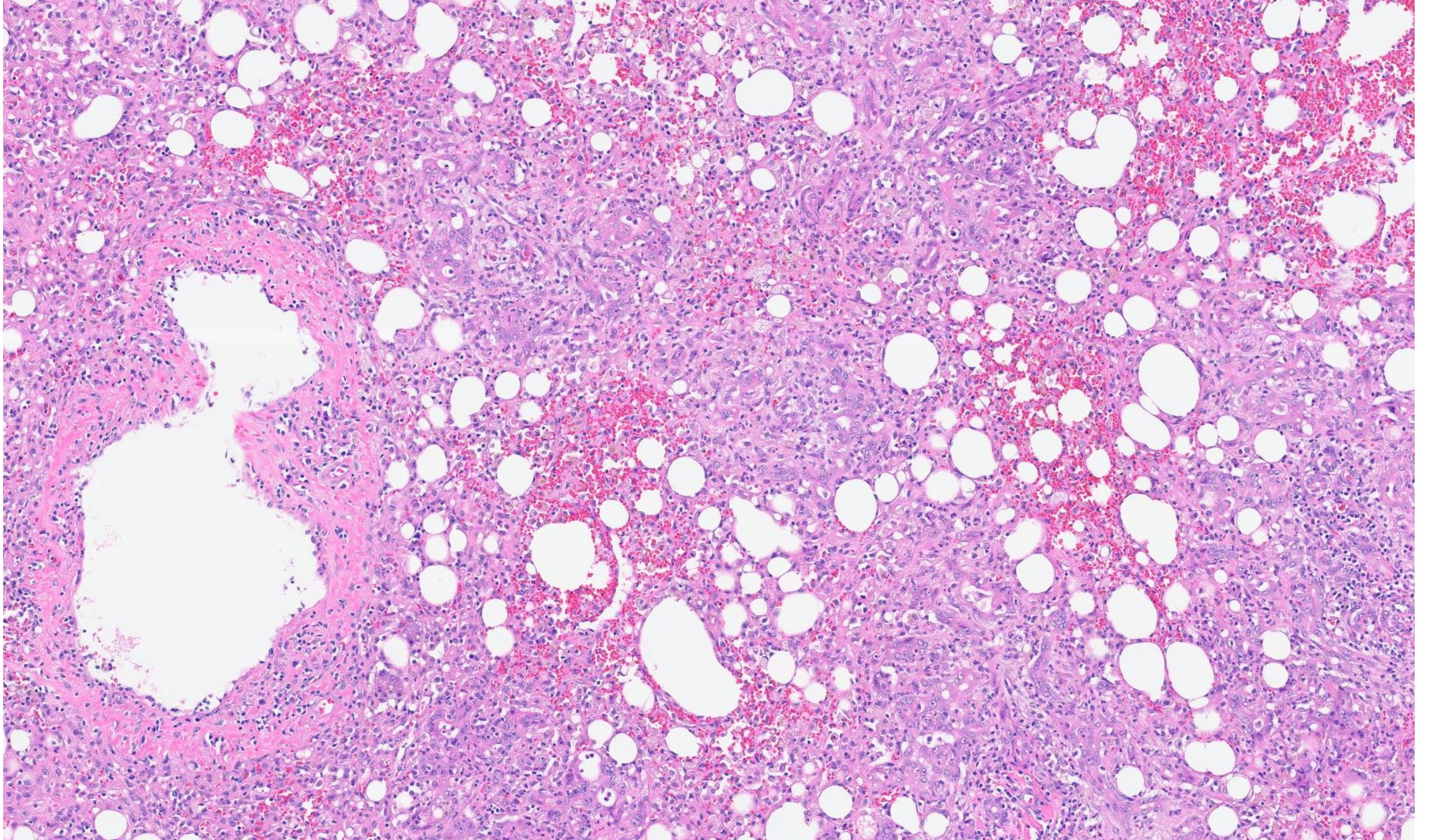
26-0608

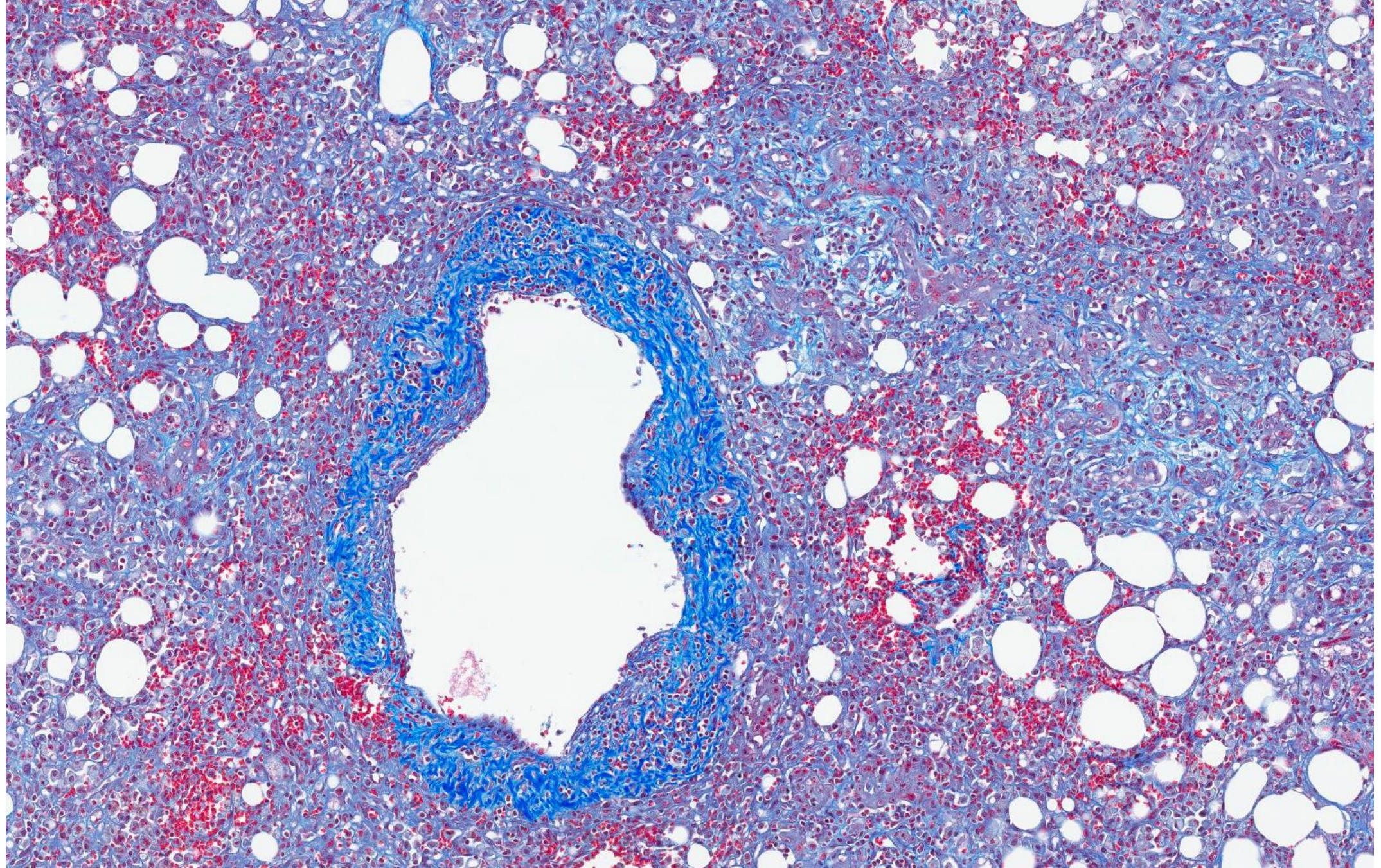
Tom Watkins and Walden Browne; Stanford

50 yr old man from Mexico with no past medical history, presents to the emergency department with vomiting, diarrhea, and abdominal pain

- Total Bilirubin 0.5
- Alkaline Phosphatase 121
- ALT (SGPT) 49
- AST 50 (*)







DIAGNOSIS?



