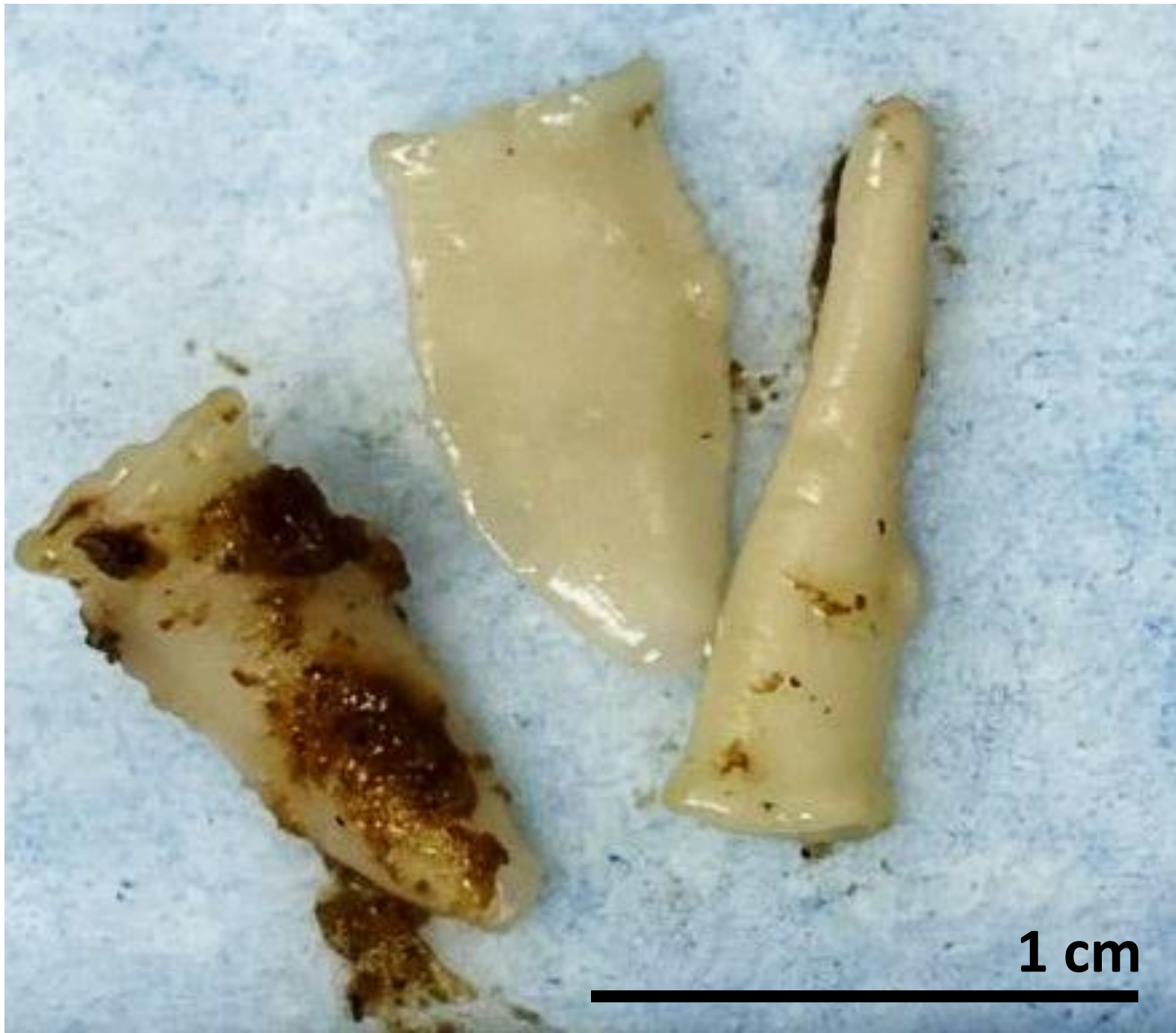

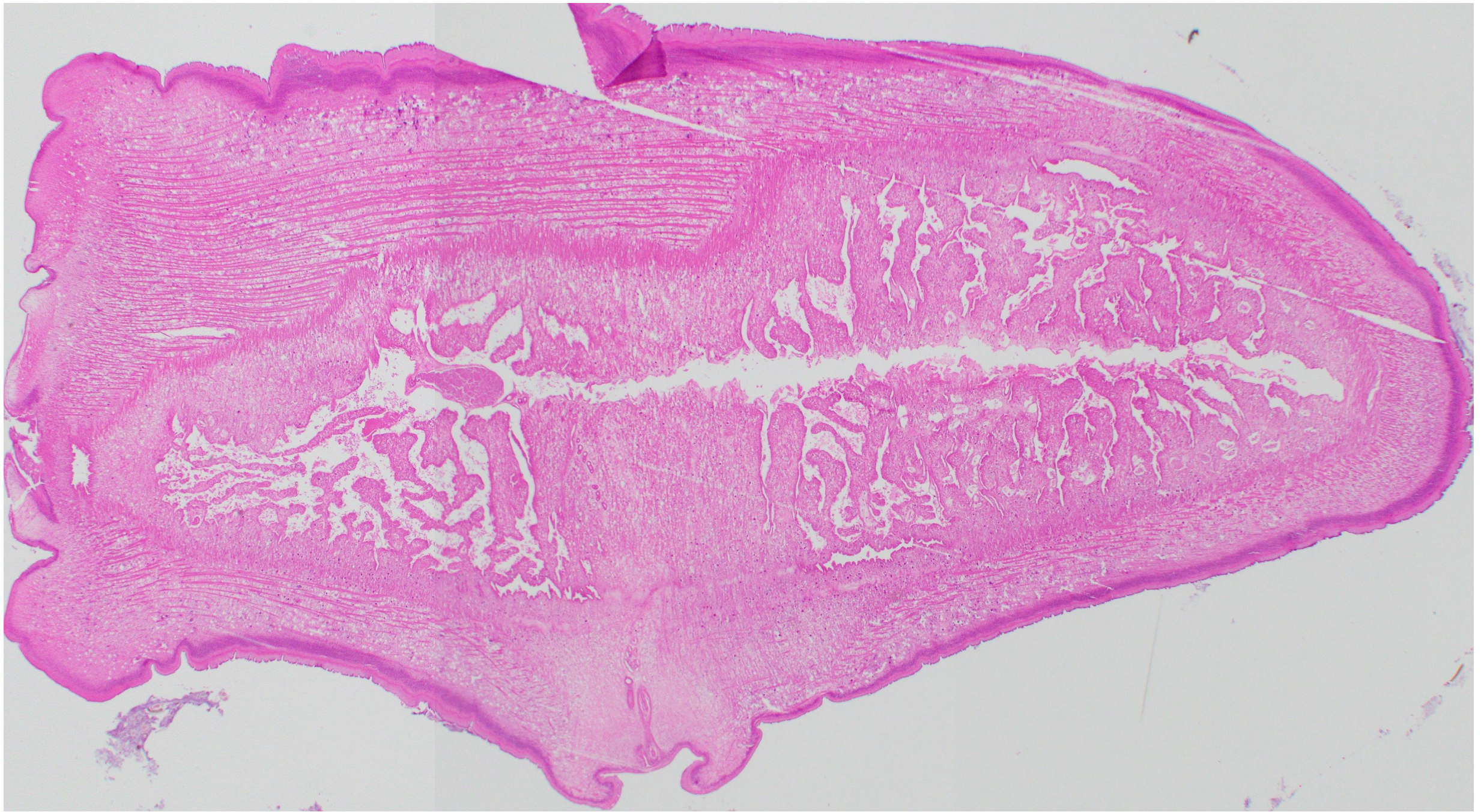
South Bay October 2024 Webcases

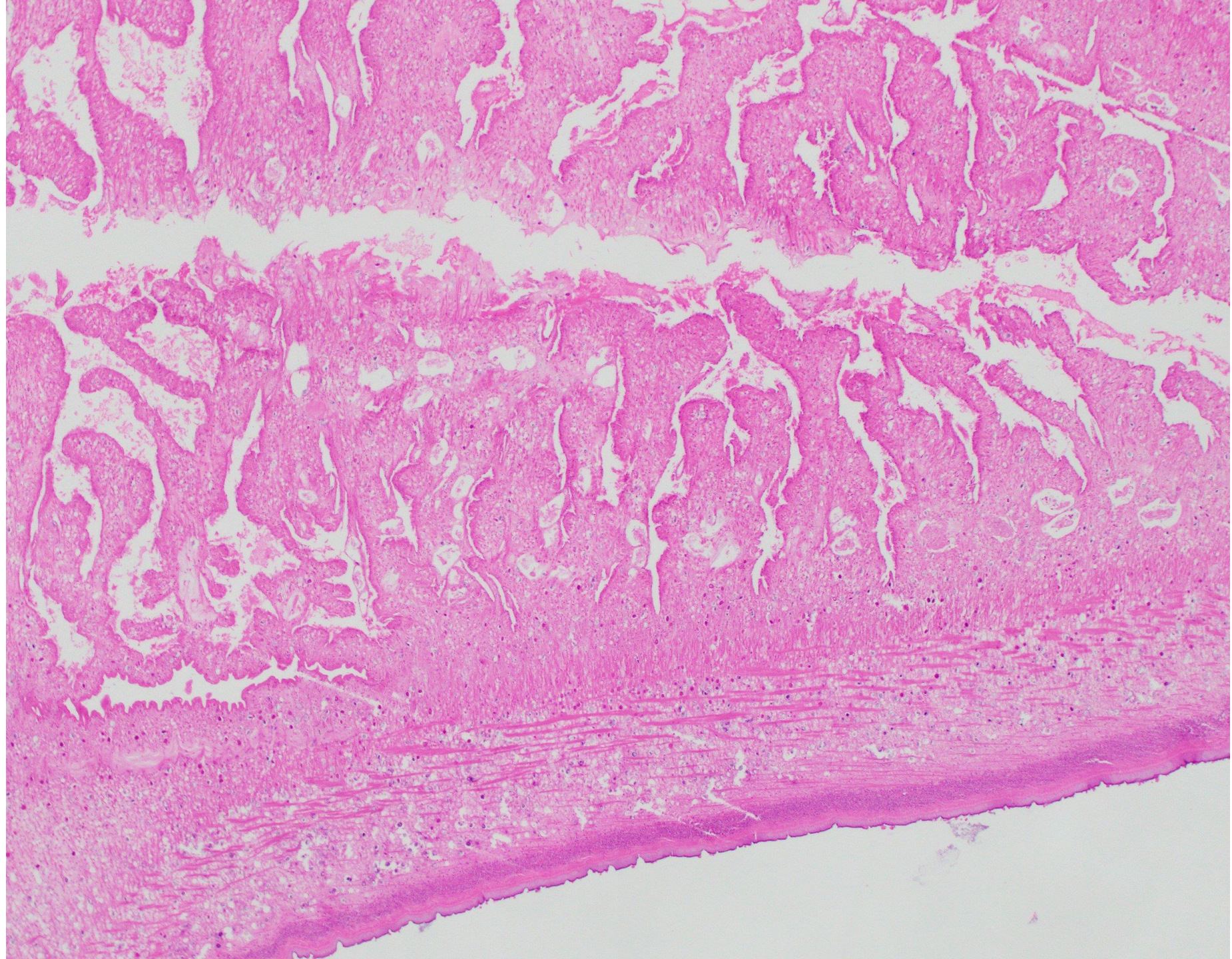
24-1001

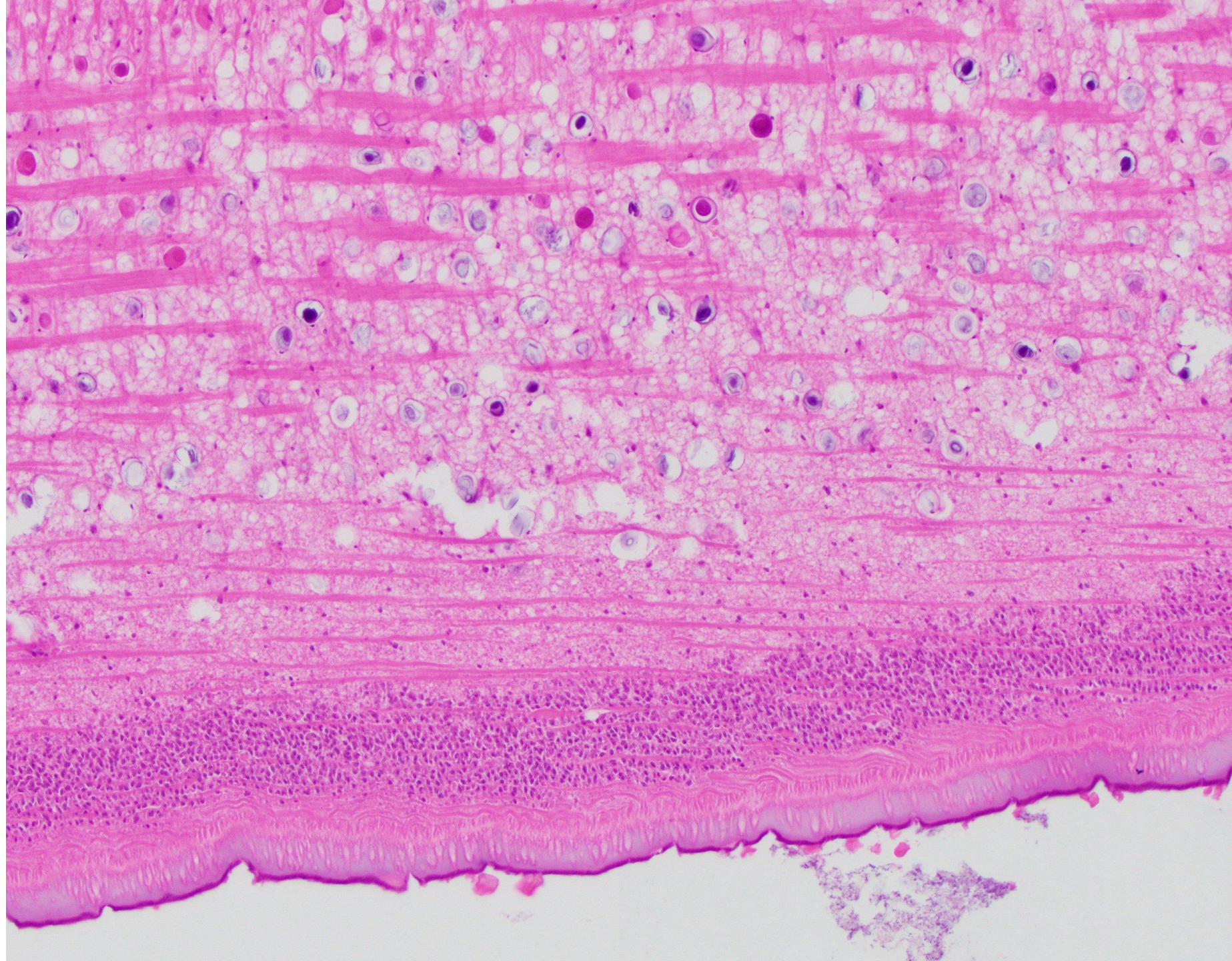
24-1001 - Anne Cheng and Hubert Lau: Stanford and Palo Alto VA

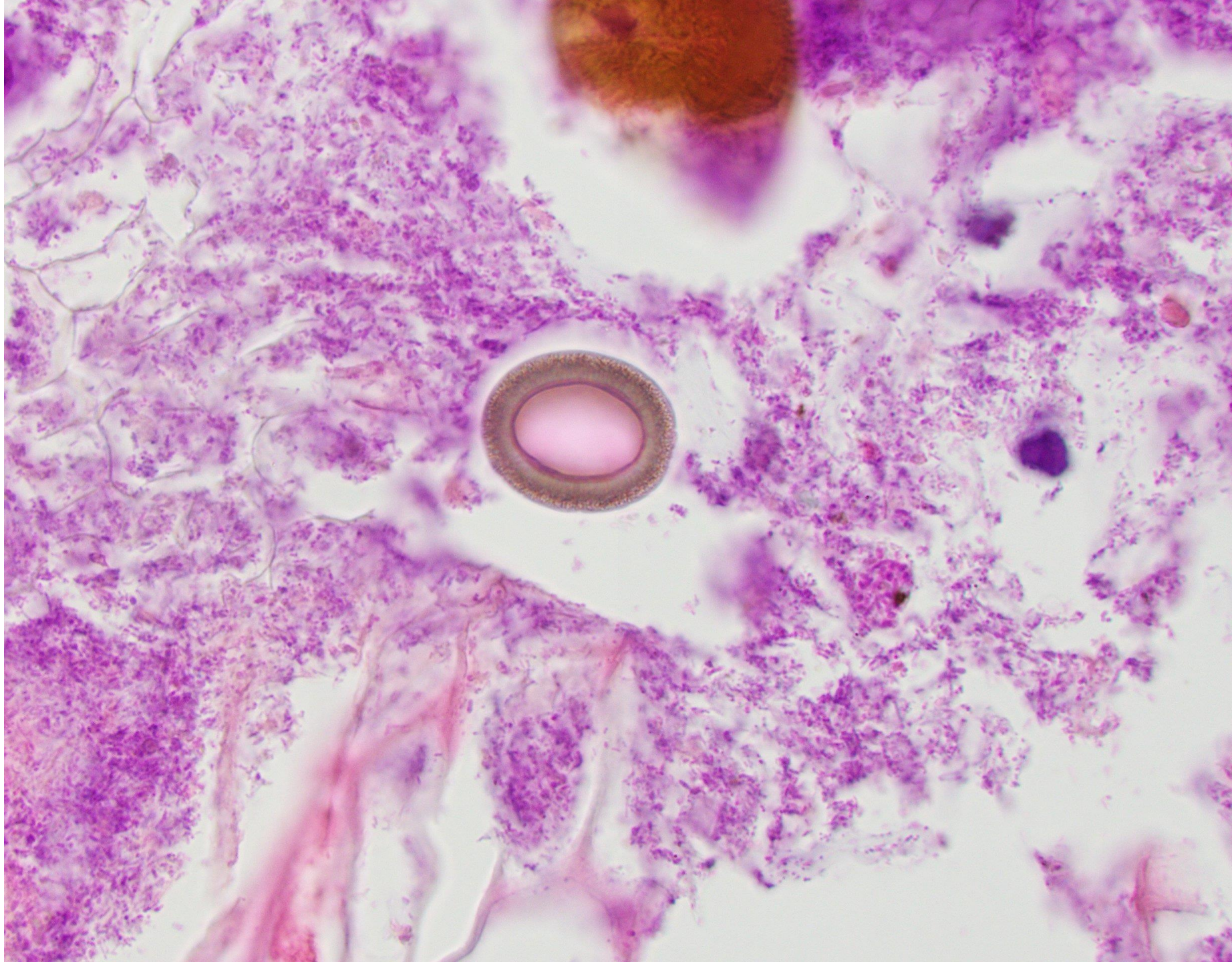
~50-year-old man who contacted primary care provider about gas and something “coming from my anus and moving down my leg.” Recent travel to Ethiopia. Endorses upset stomach, nausea, and diarrhea while he was there. CBC shows microcytic RBCs (MCV 71 fL) and mild relative monocytosis (11%) and eosinophilia (9%). Stool sample sent for surgical pathology.











DIAGNOSIS?

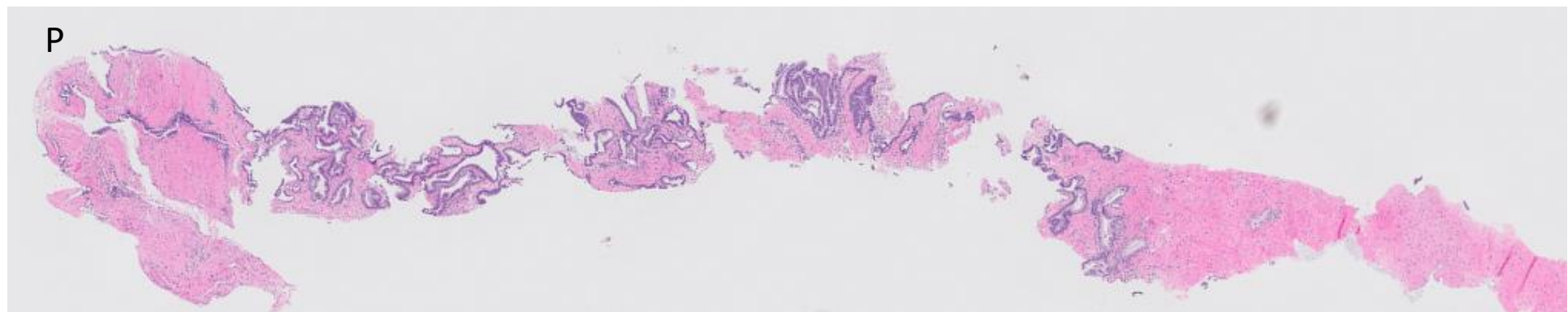
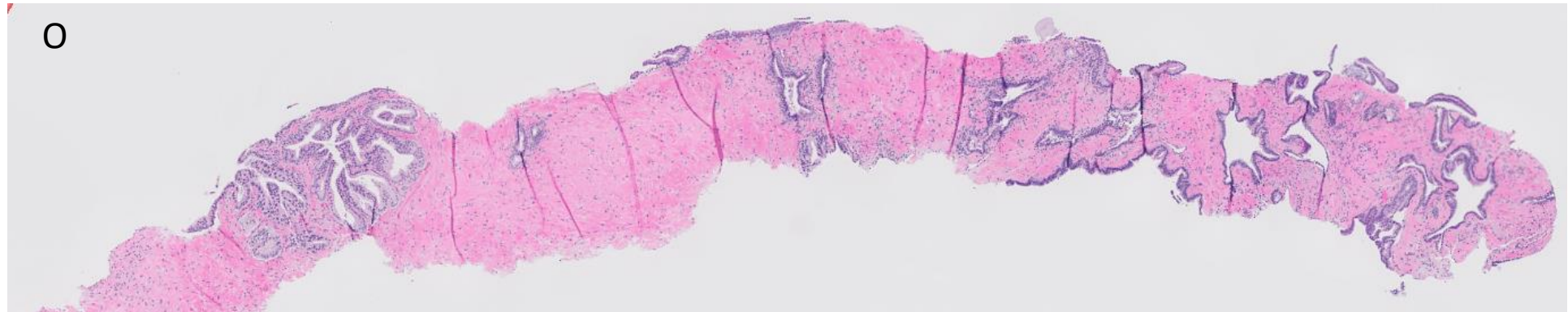
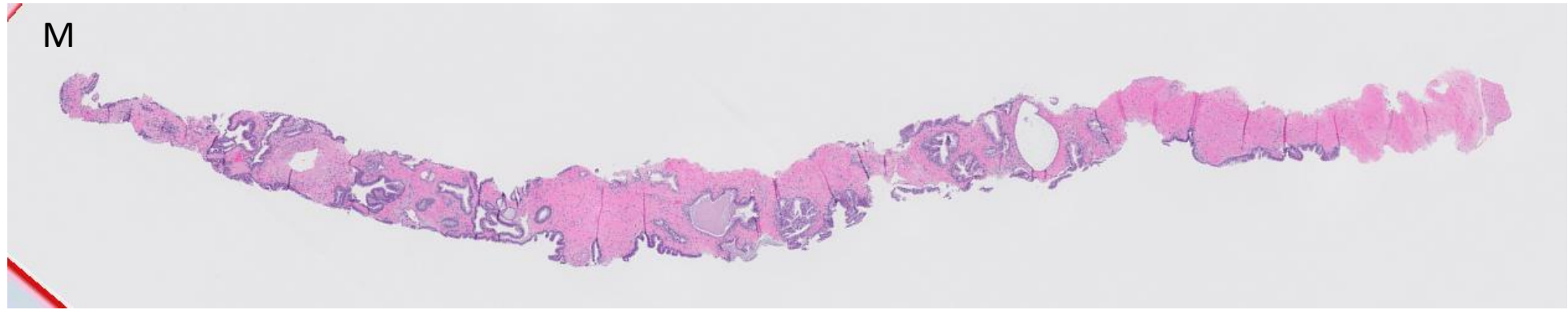


24-1002

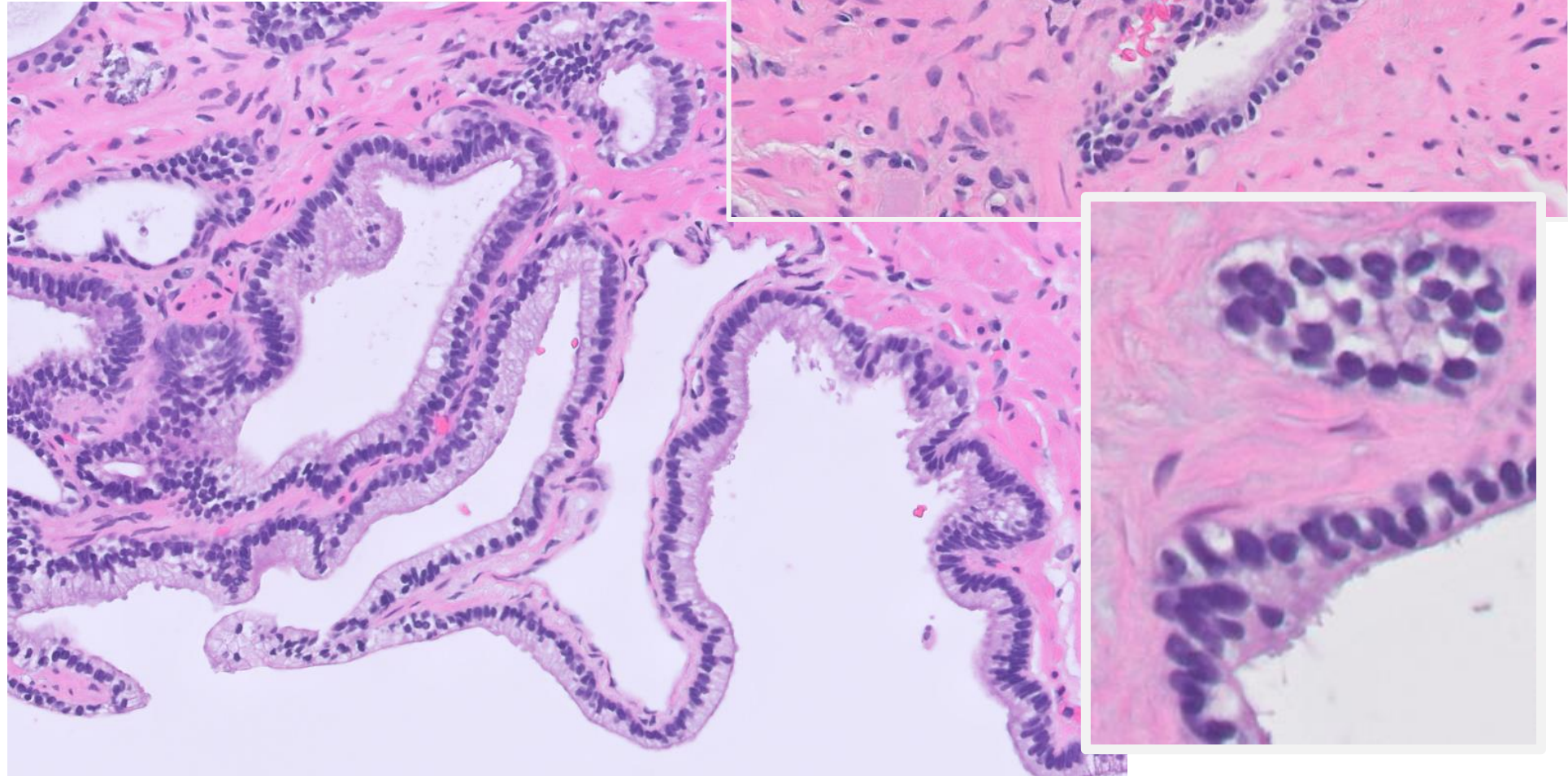
Anne Cheng and Emily Chan: Stanford

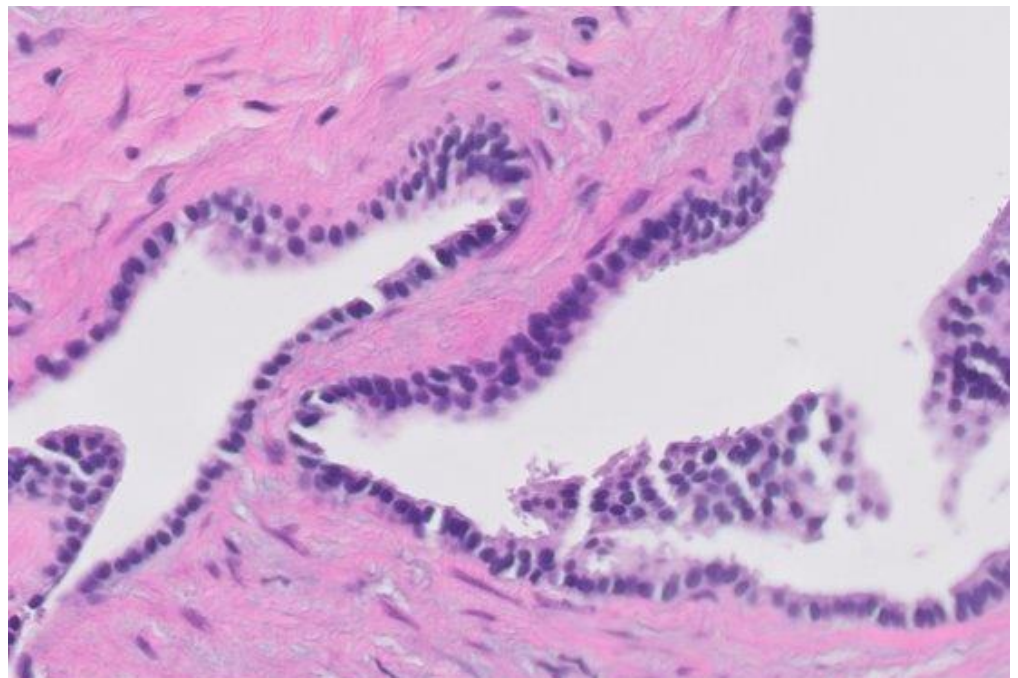
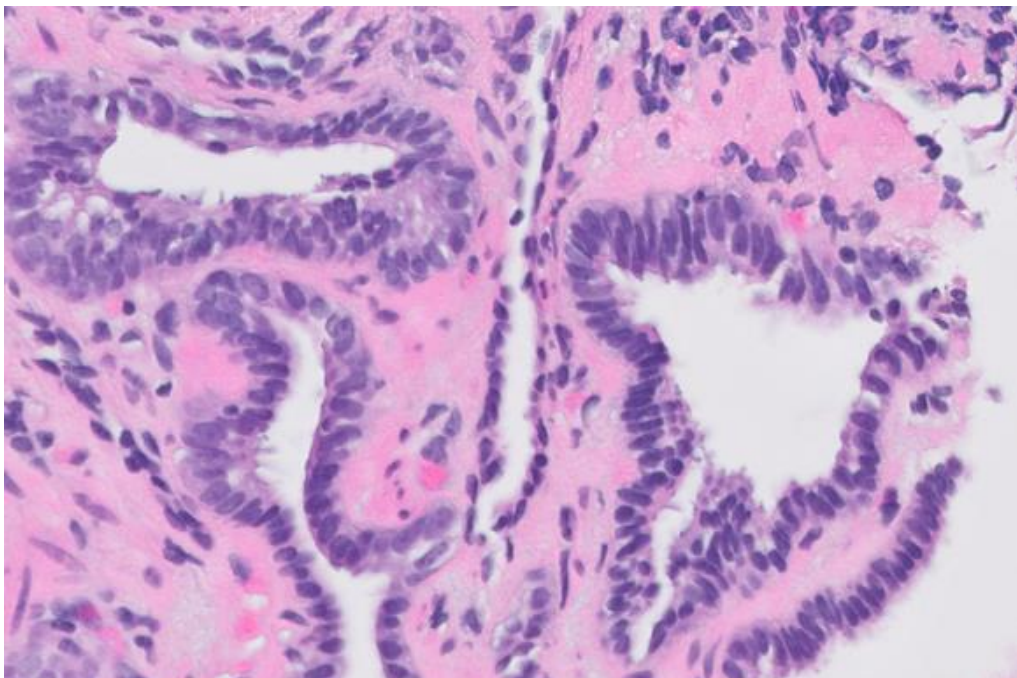
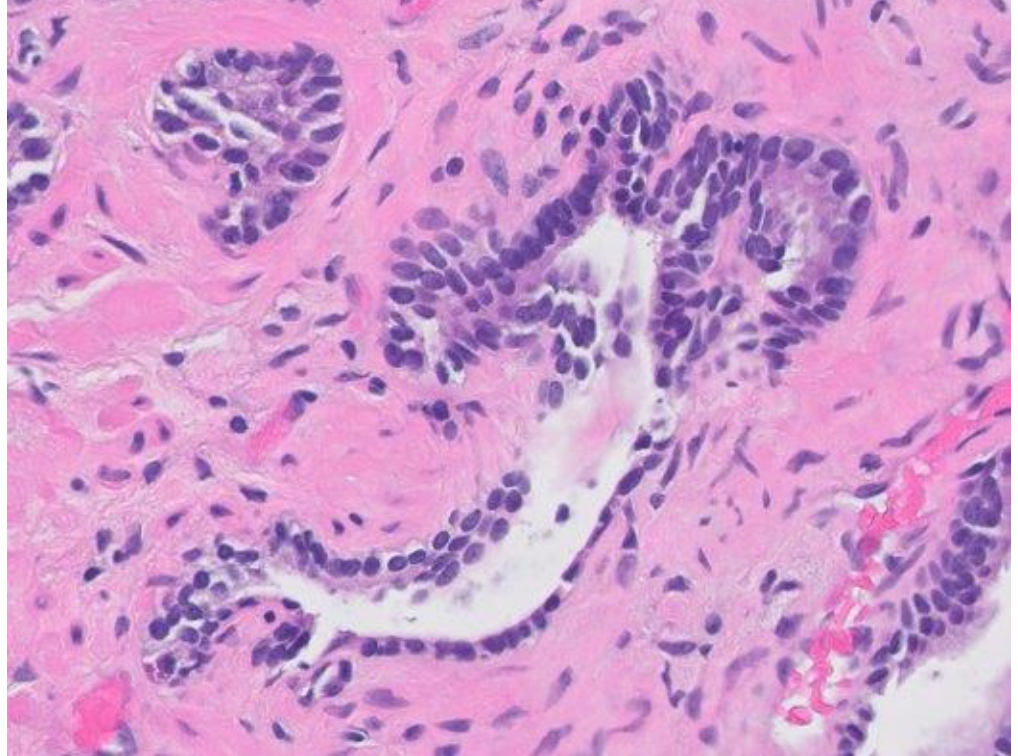
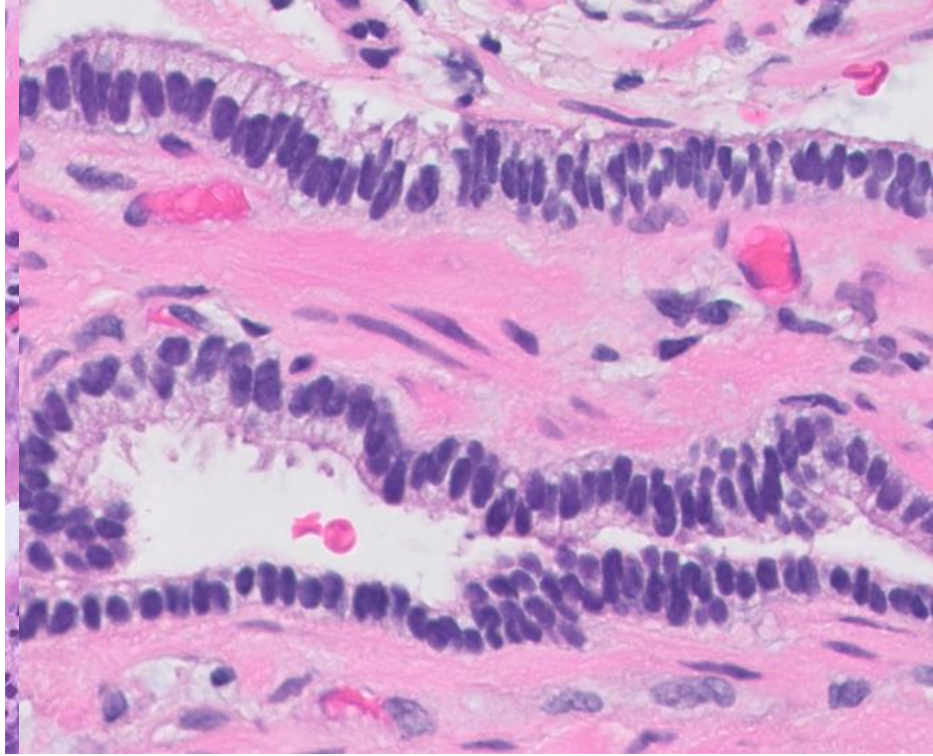
72-year-old man with PSA of 5.3. No prior prostate biopsies.

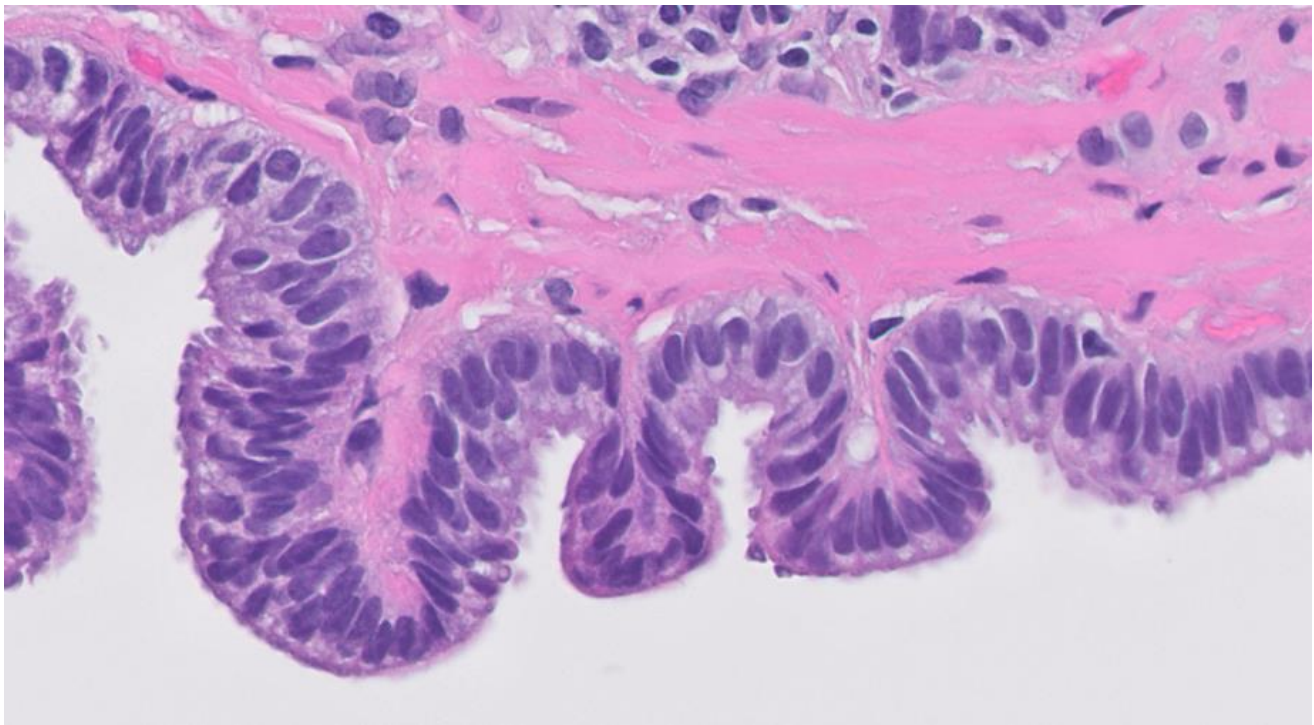
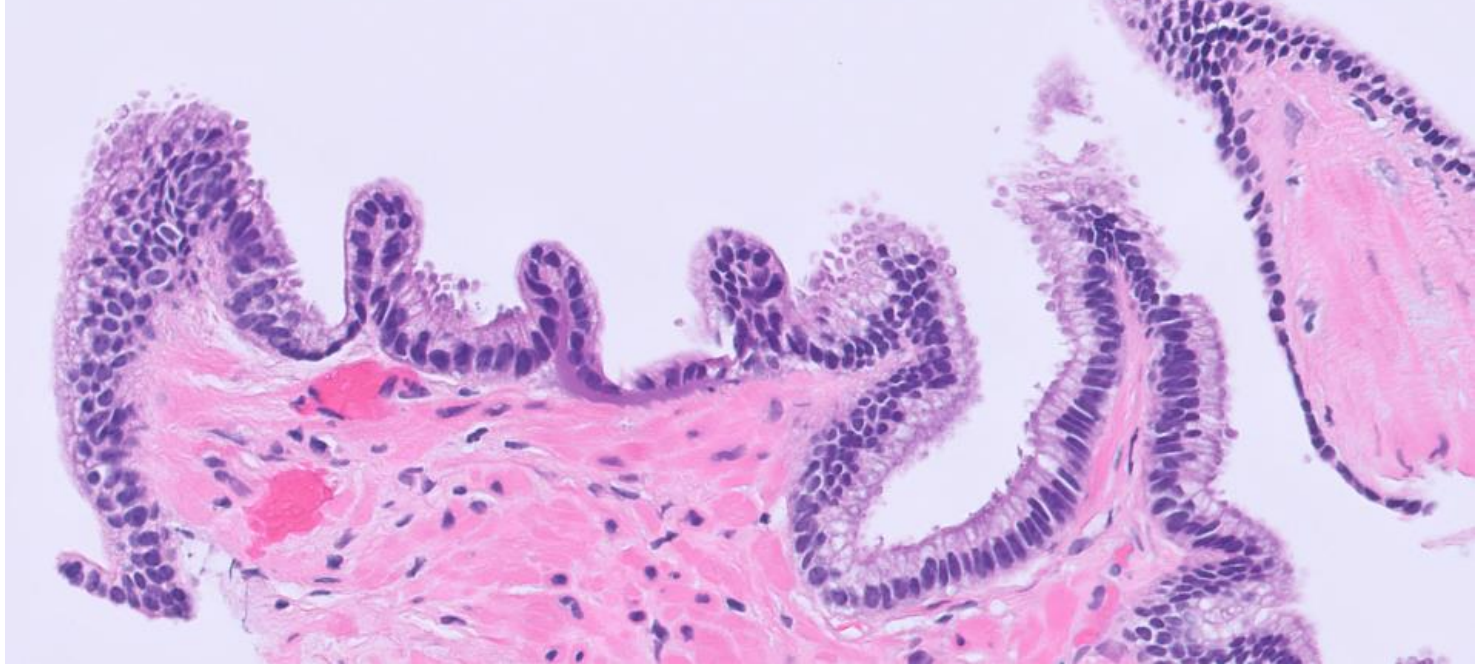Low Power View



High power view







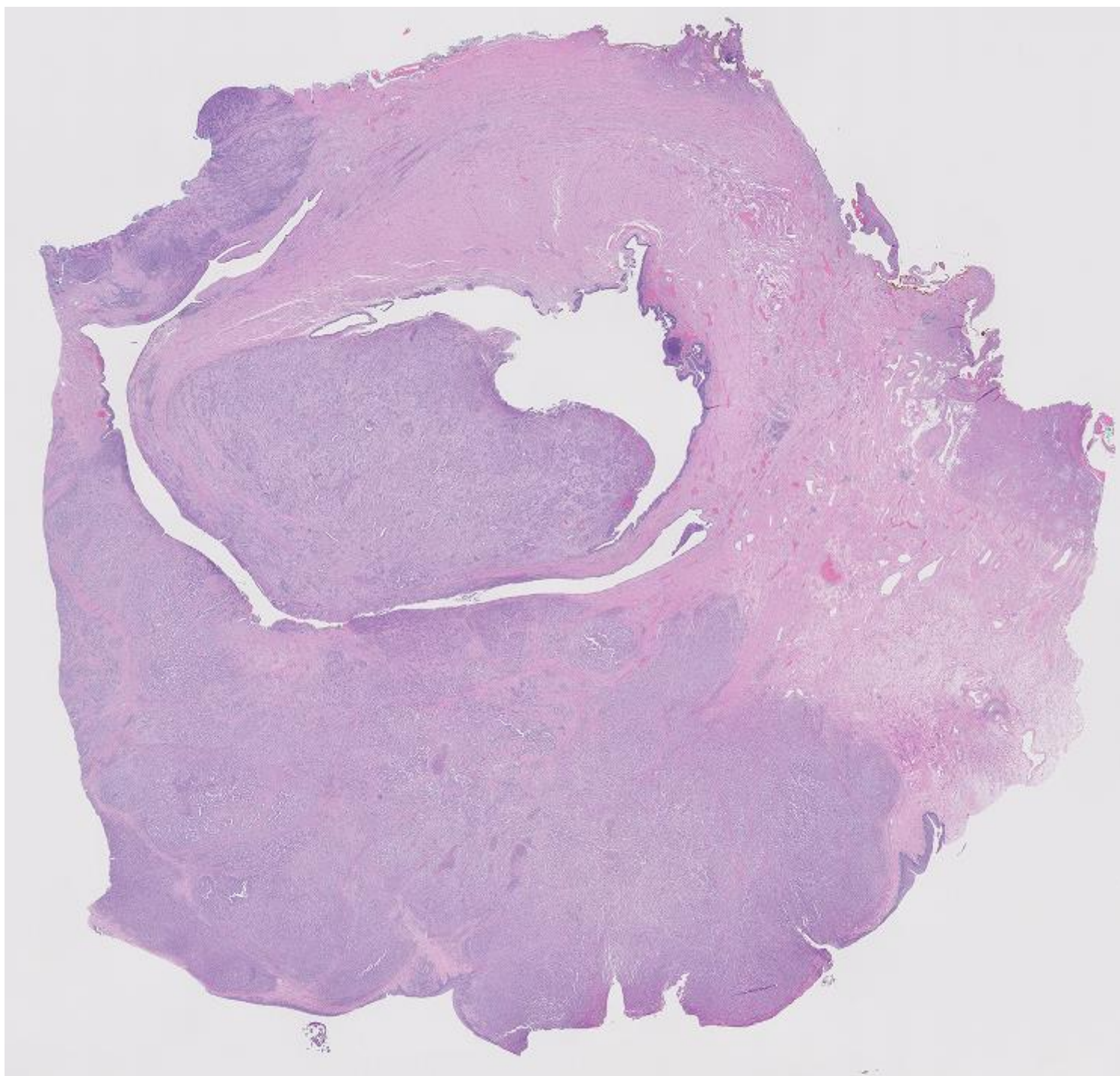
DIAGNOSIS?



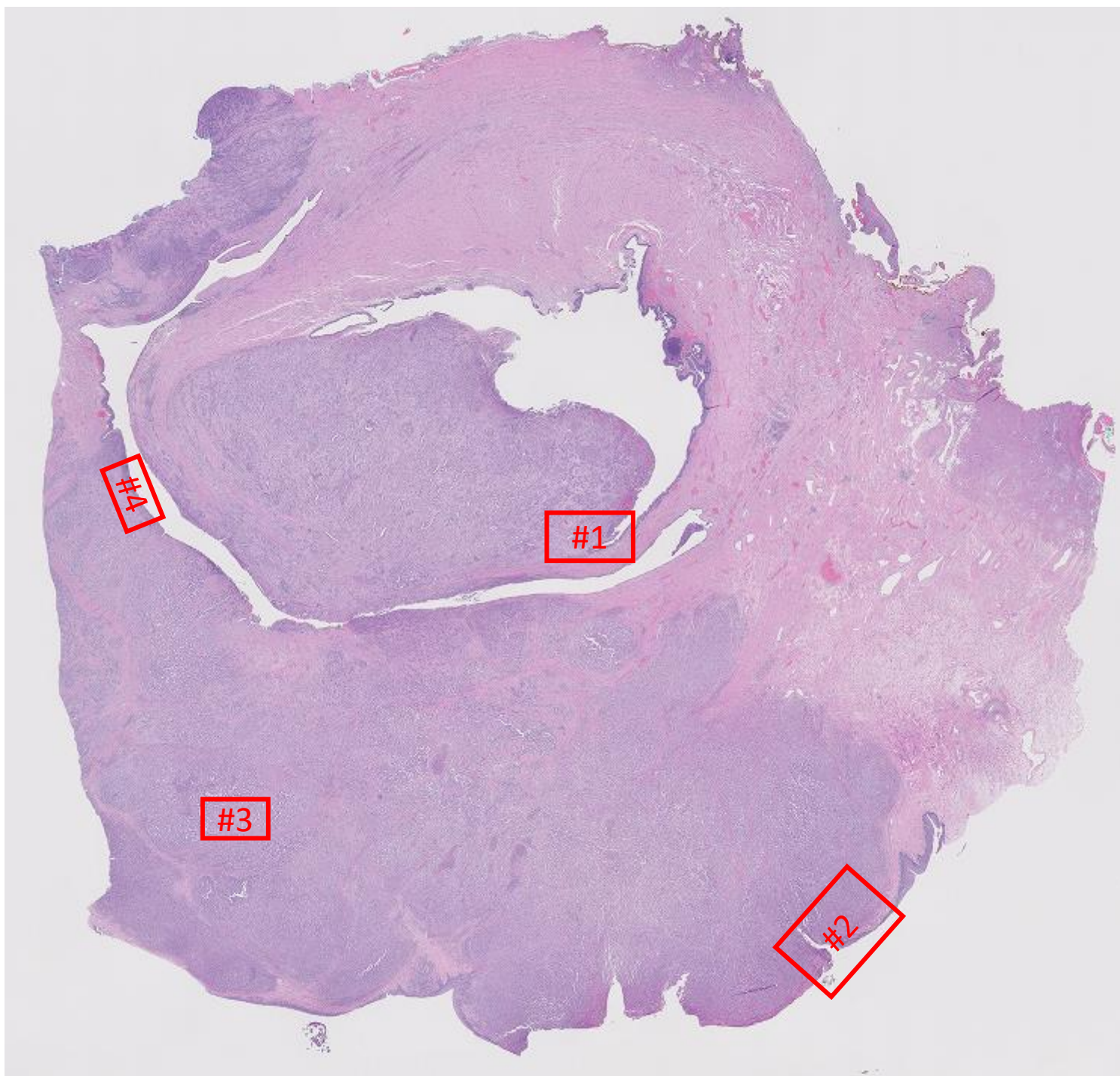
24-1003

Brooke Liang and Emily Chan; Stanford

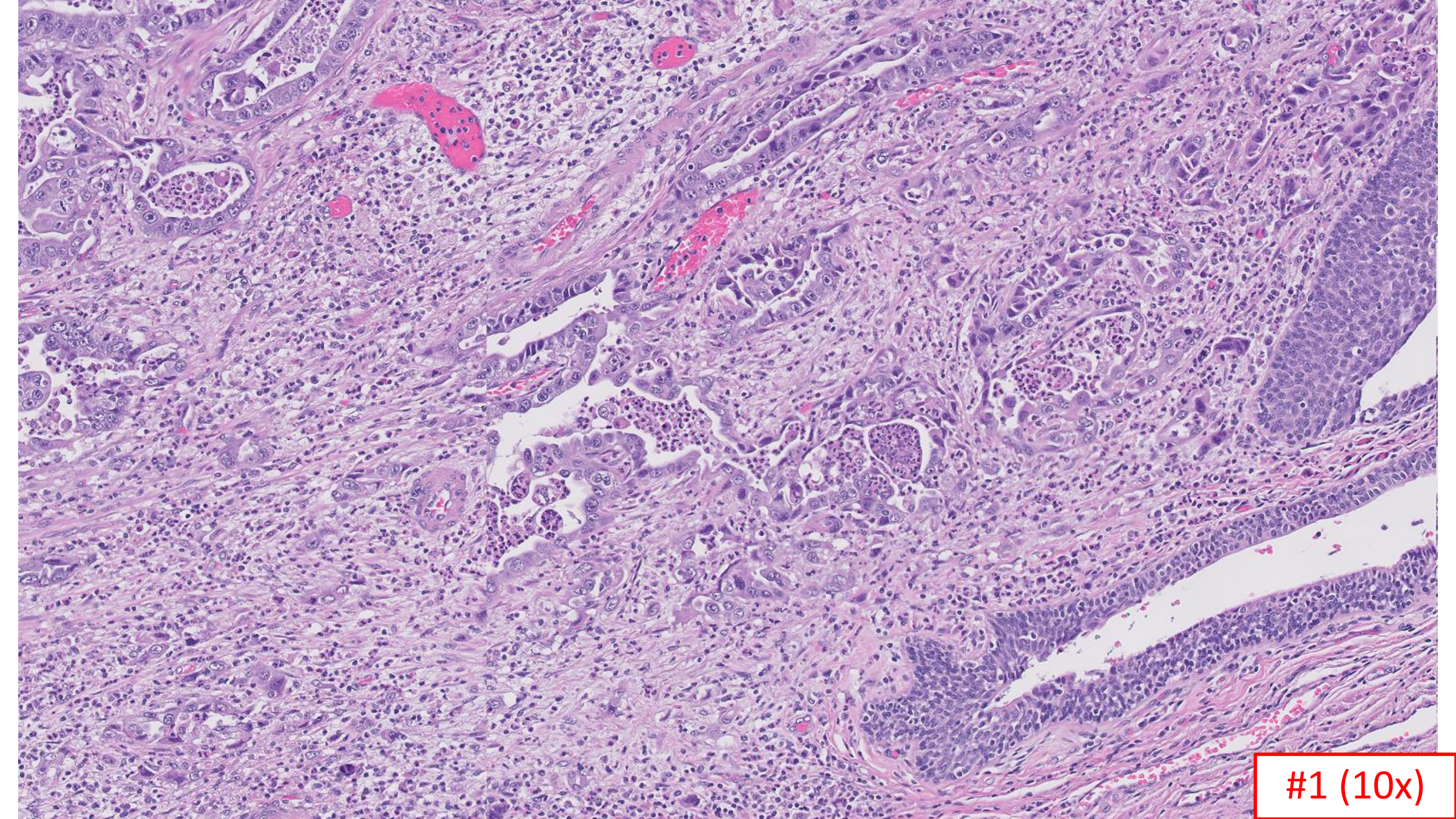
65-year-old female with a history of hypercholesterolemia, GERD, chronic UTIs and endometriosis found to have a posterior urethral mass



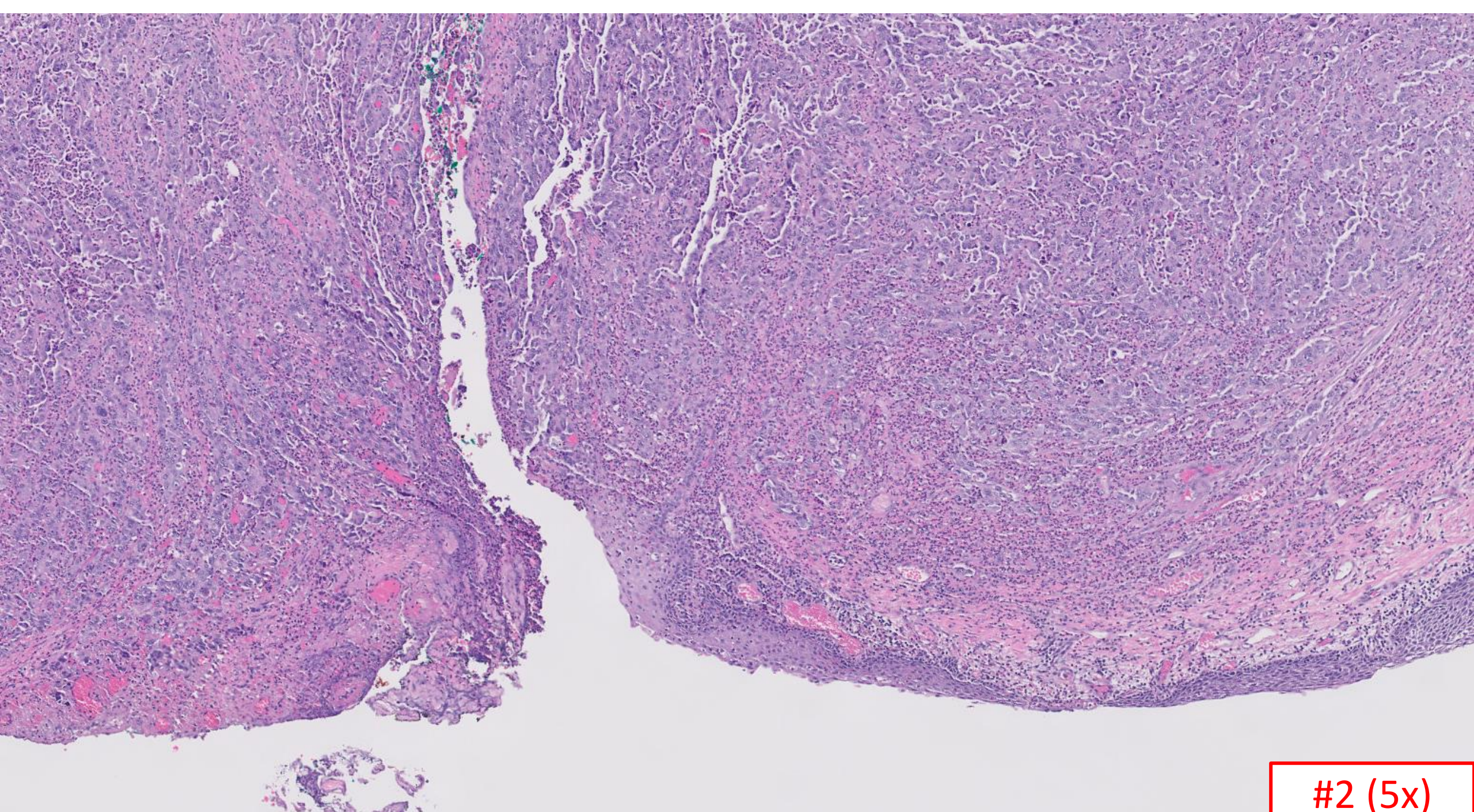
0.25x



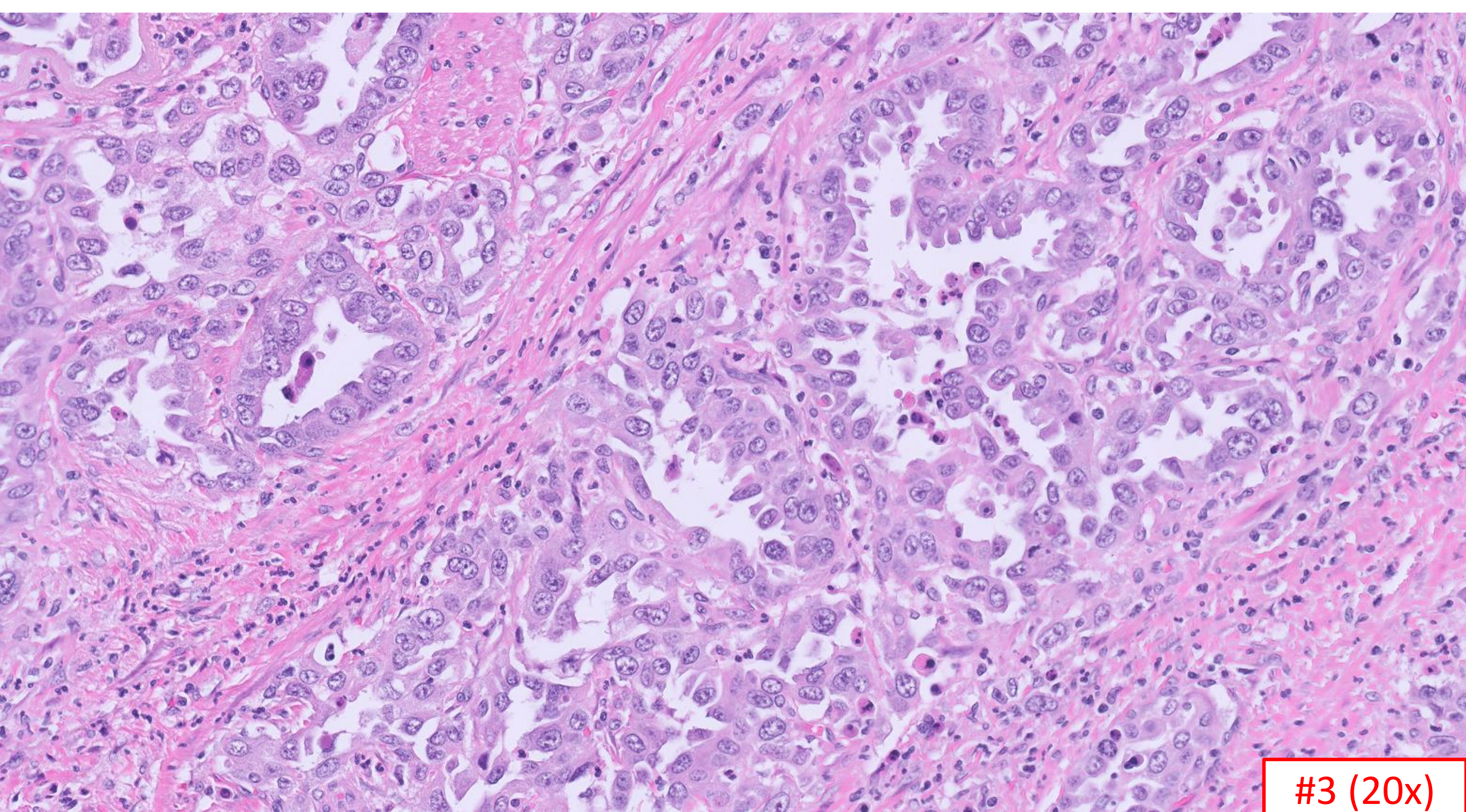
0.25x



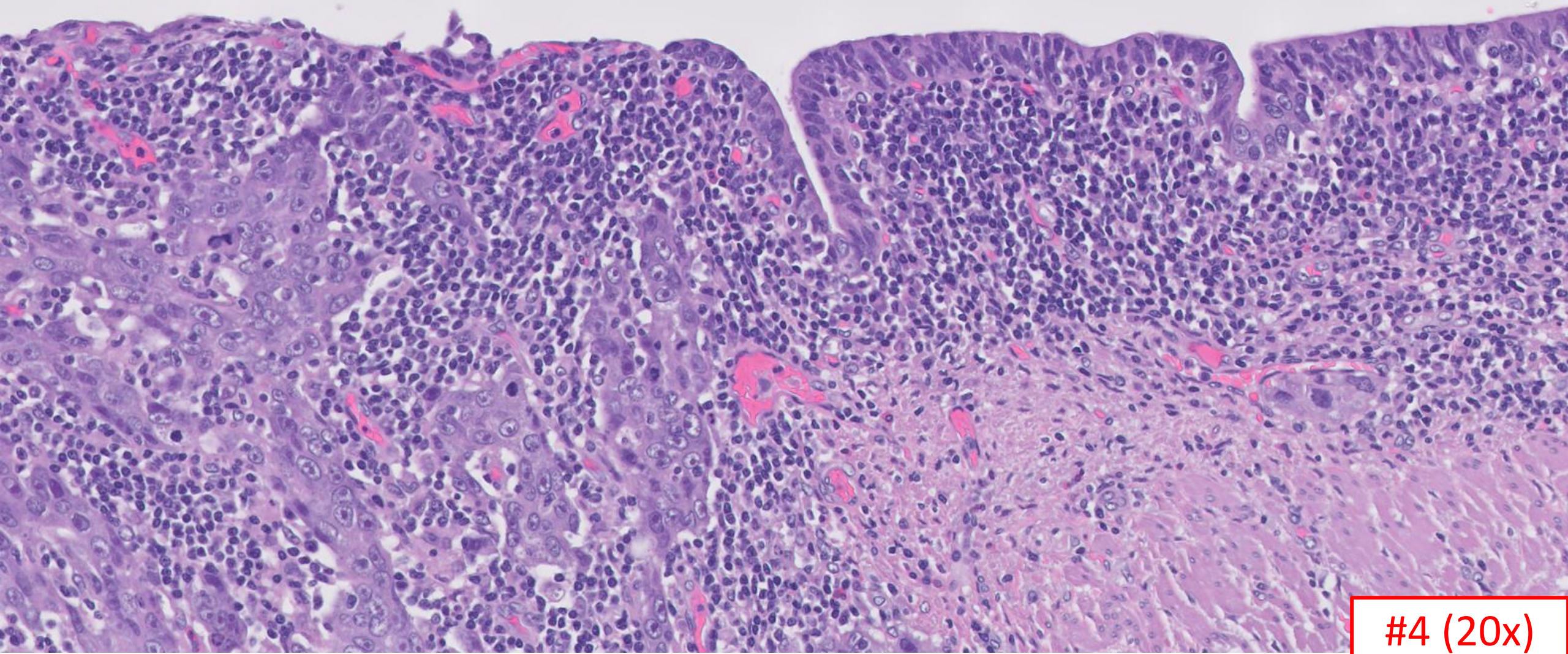
#1 (10x)



#2 (5x)



#3 (20x)



#4 (20x)

DIAGNOSIS?



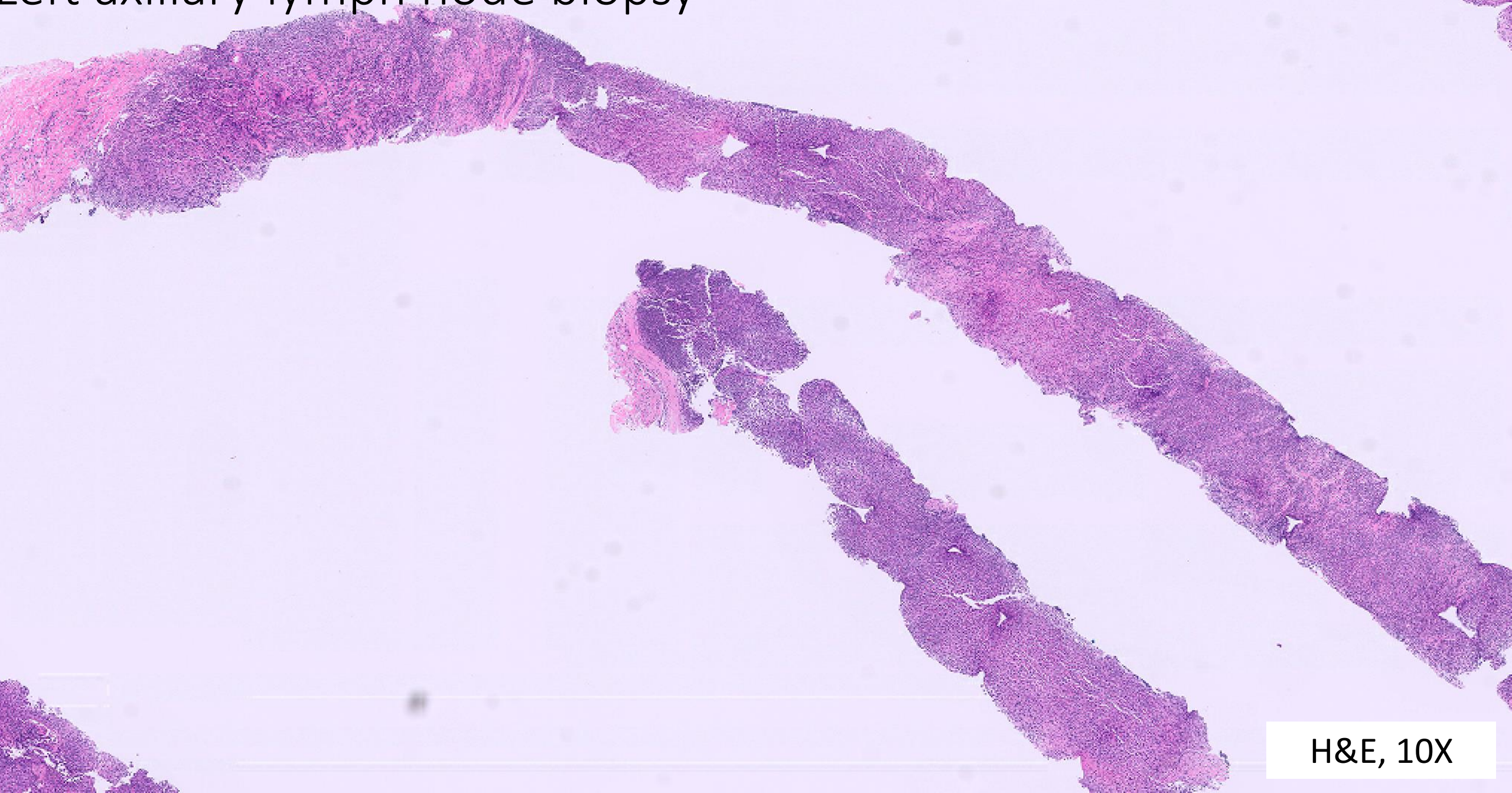
24-1004

Nivaz Brar, and Jason Kurzer; Stanford

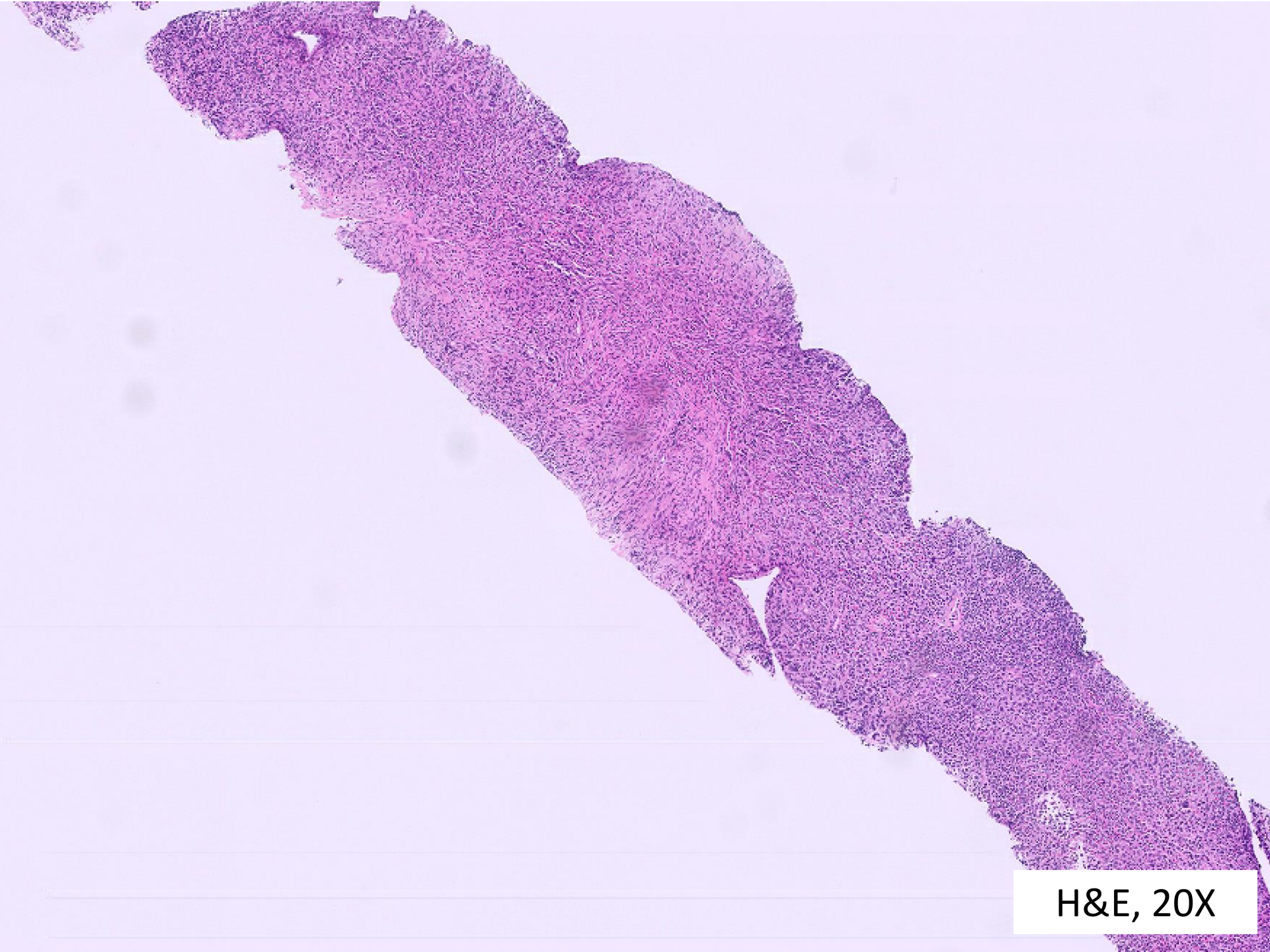
36-year-old female with a history of breast cancer presenting with bilateral axillary lymphadenopathy.

PET-CT imaging shows mediastinal lymphadenopathy and profound lymphadenopathy above and below the diaphragm.

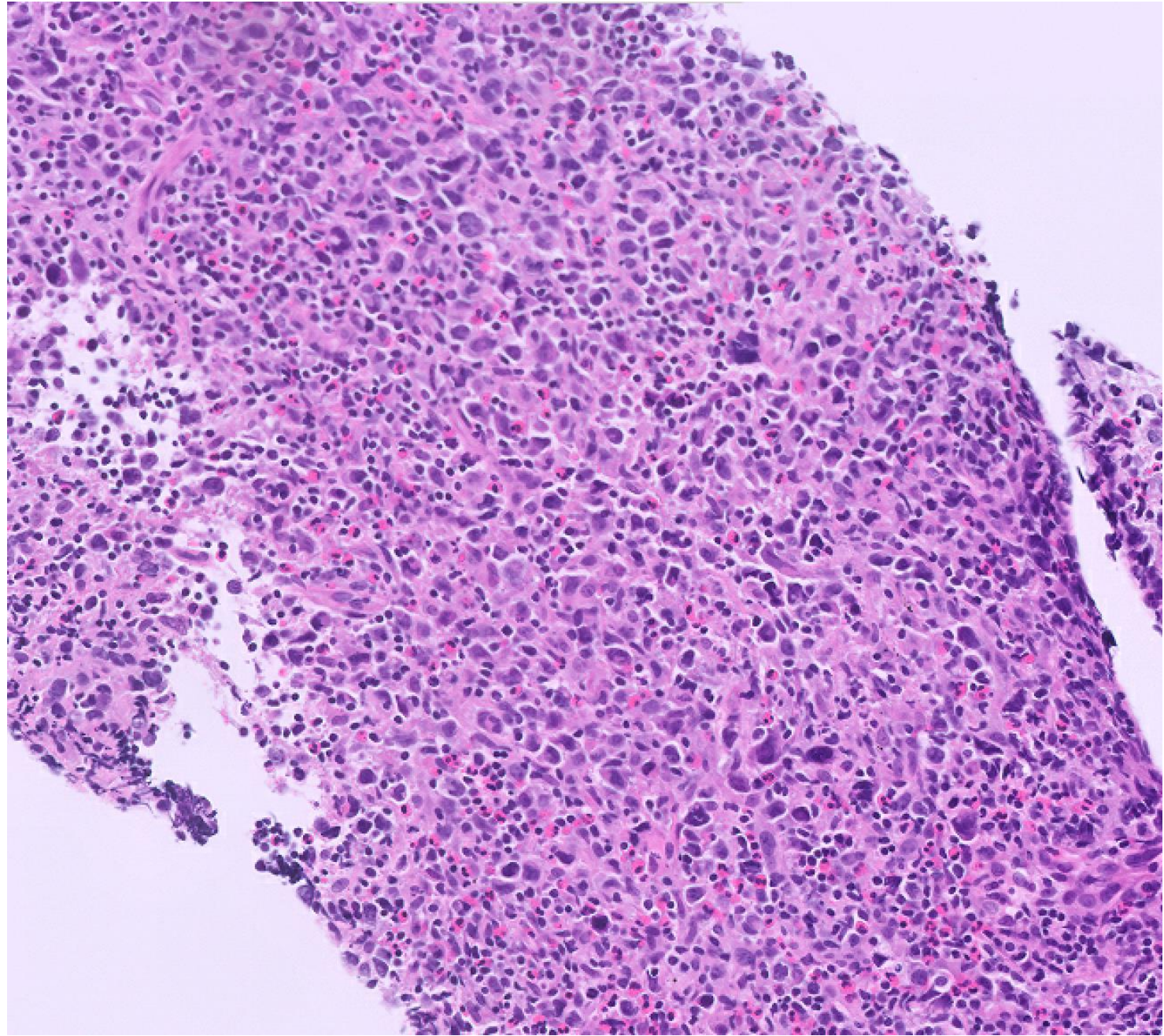
Left axillary lymph node biopsy

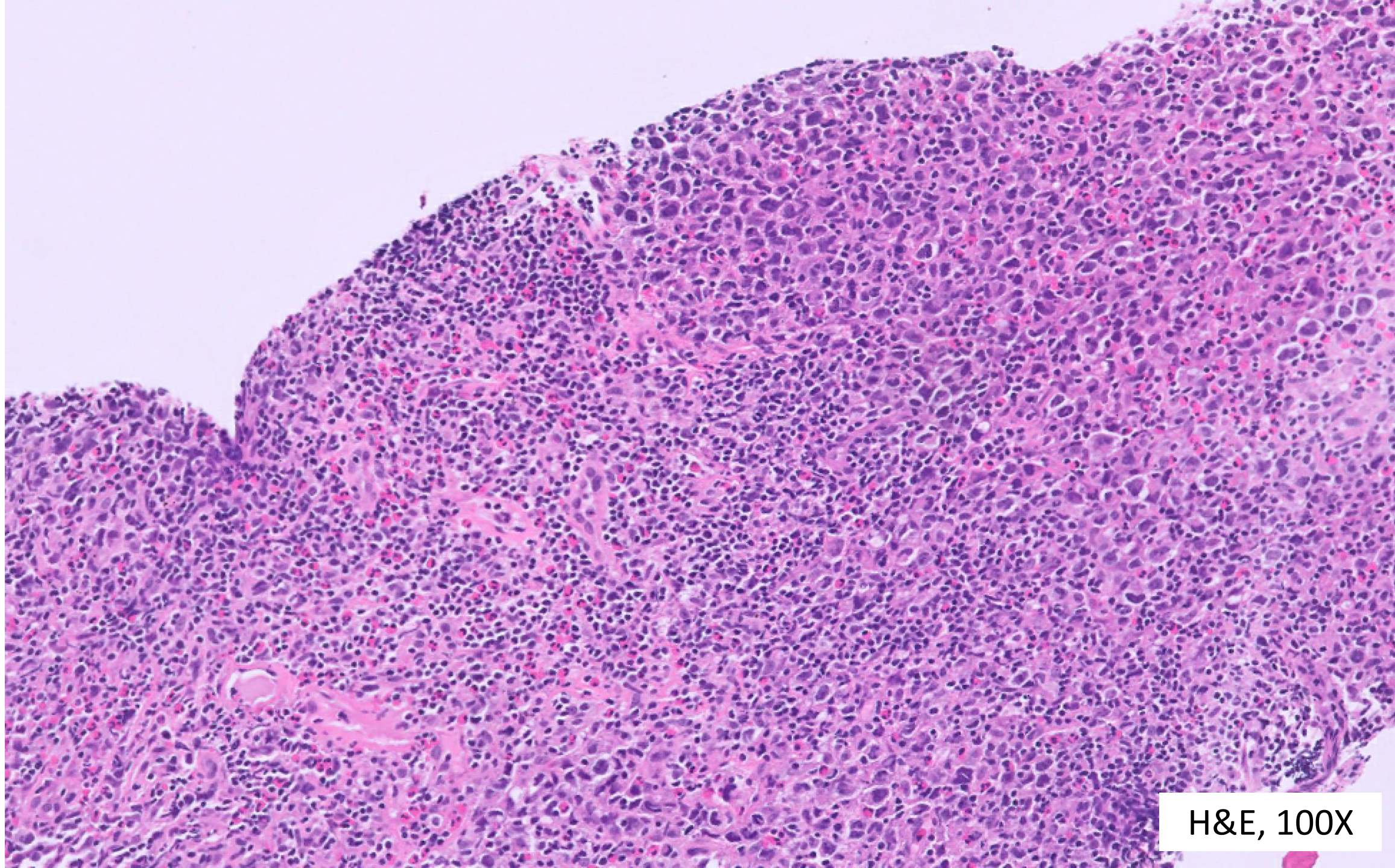


H&E, 10X

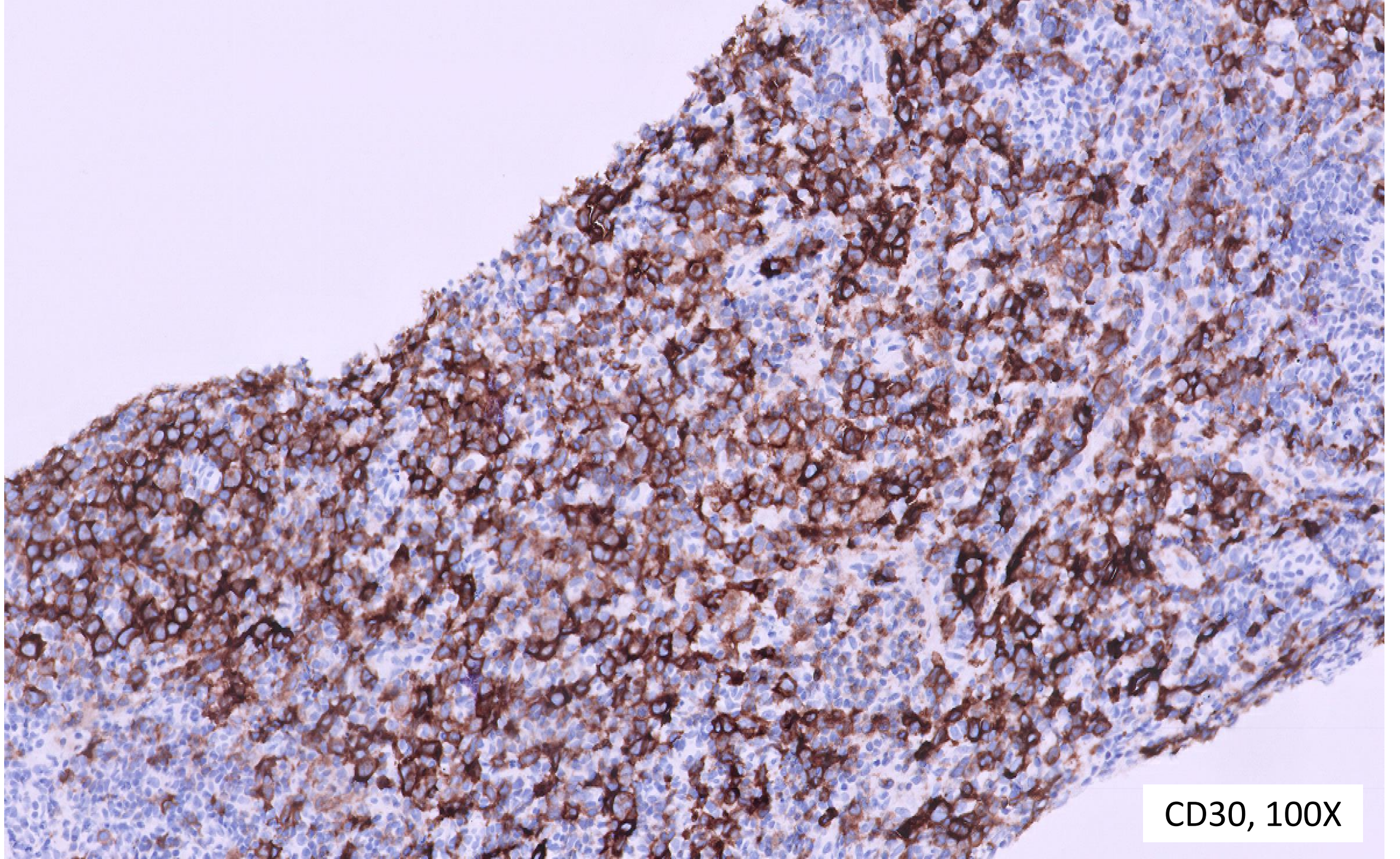


H&E, 20X

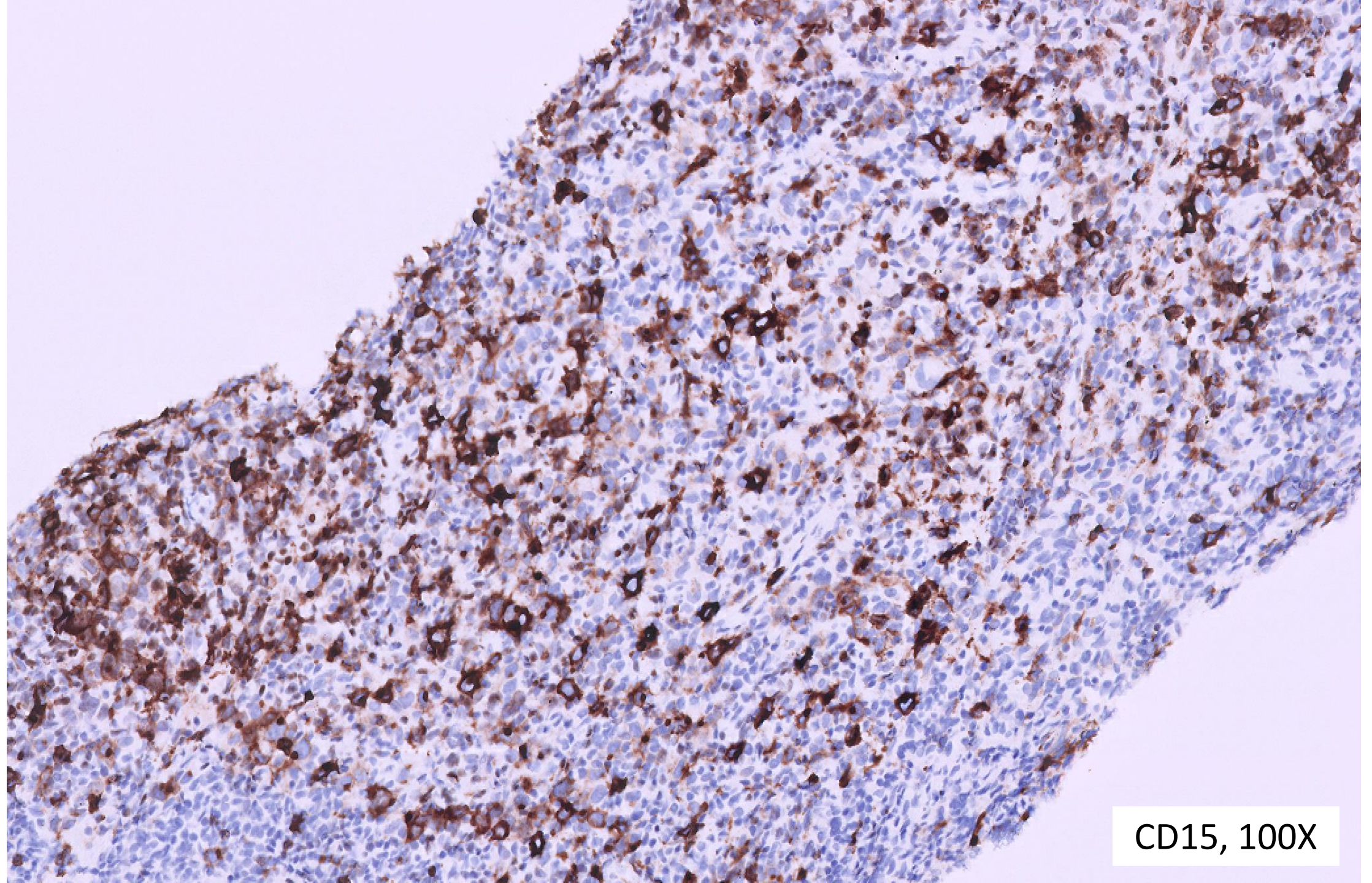




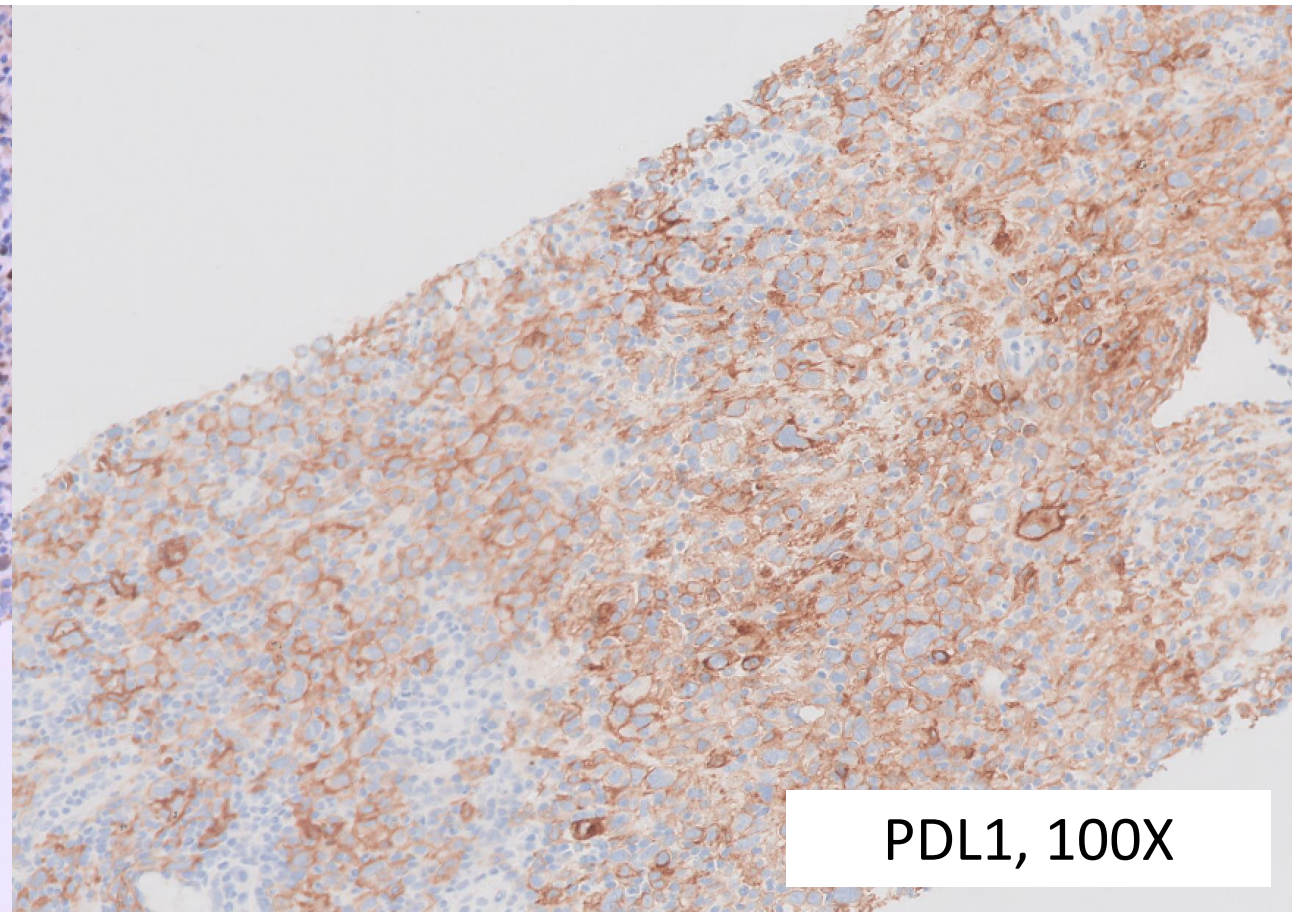
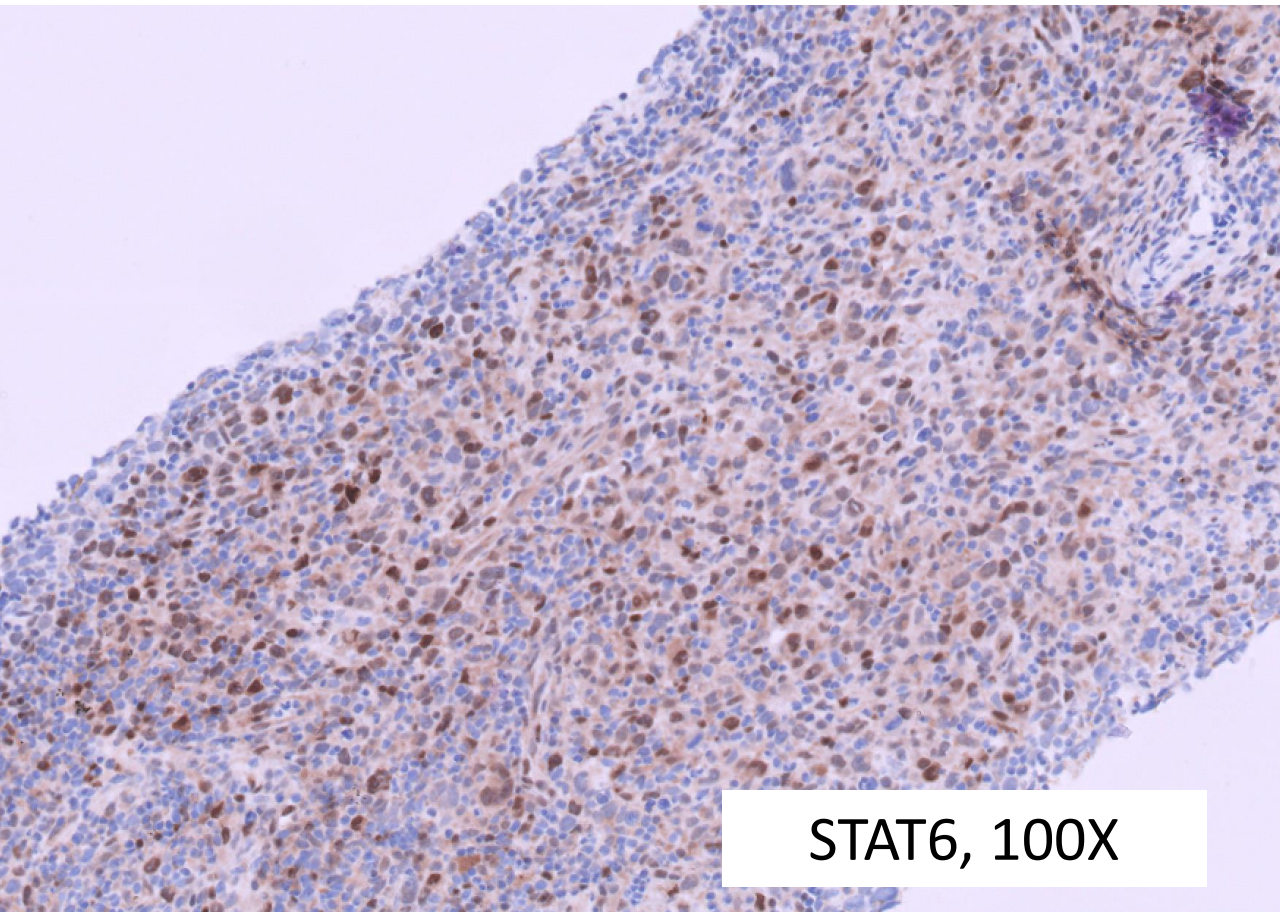
H&E, 100X

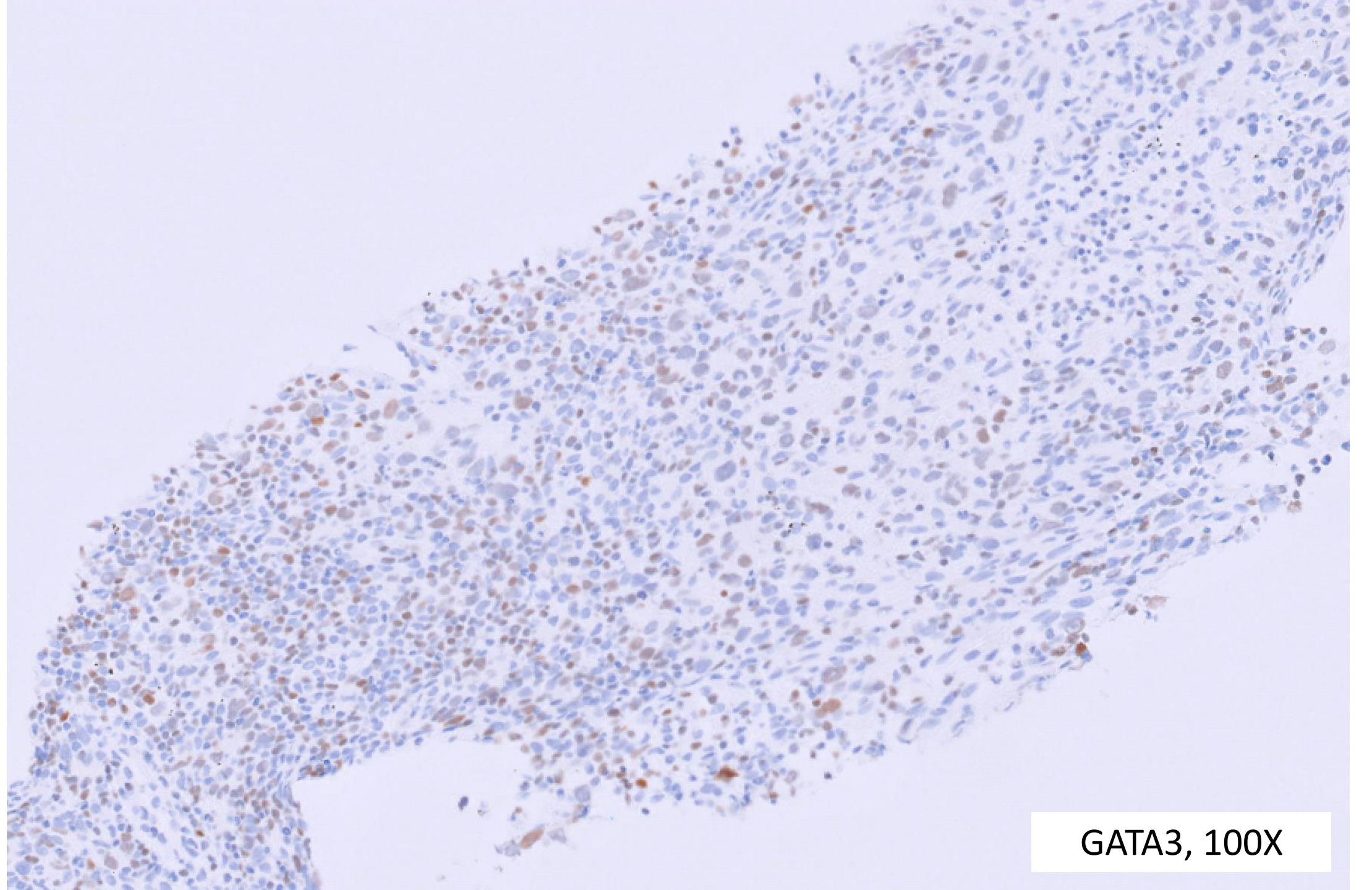


CD30, 100X



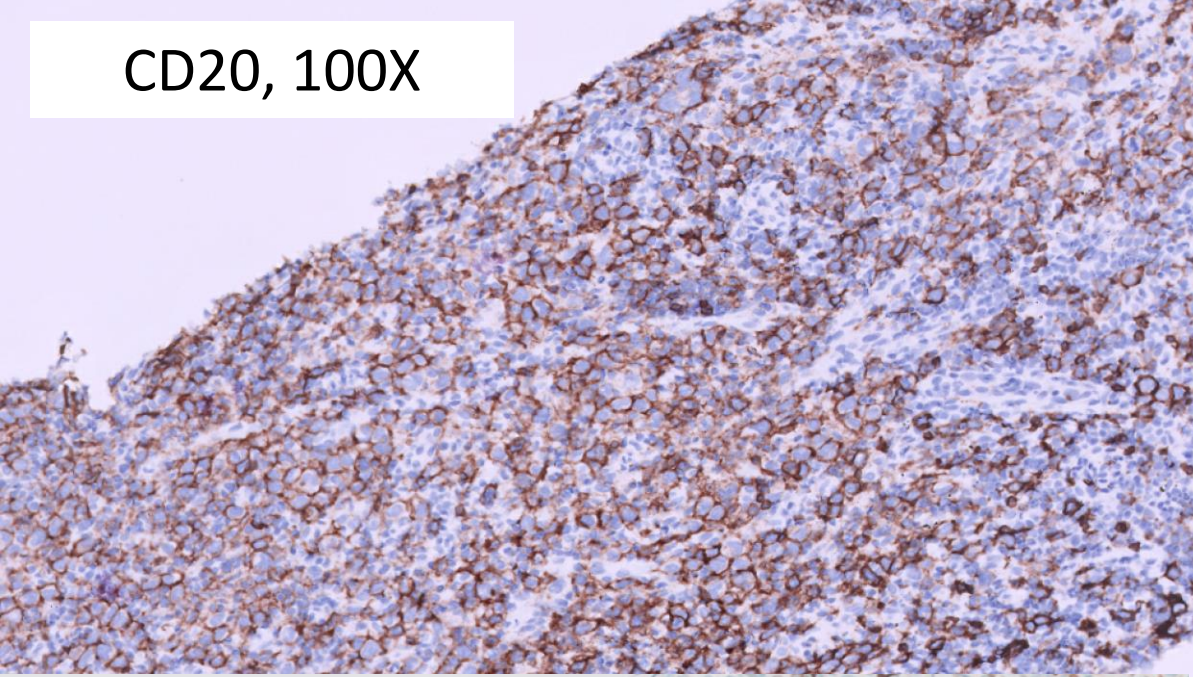
CD15, 100X



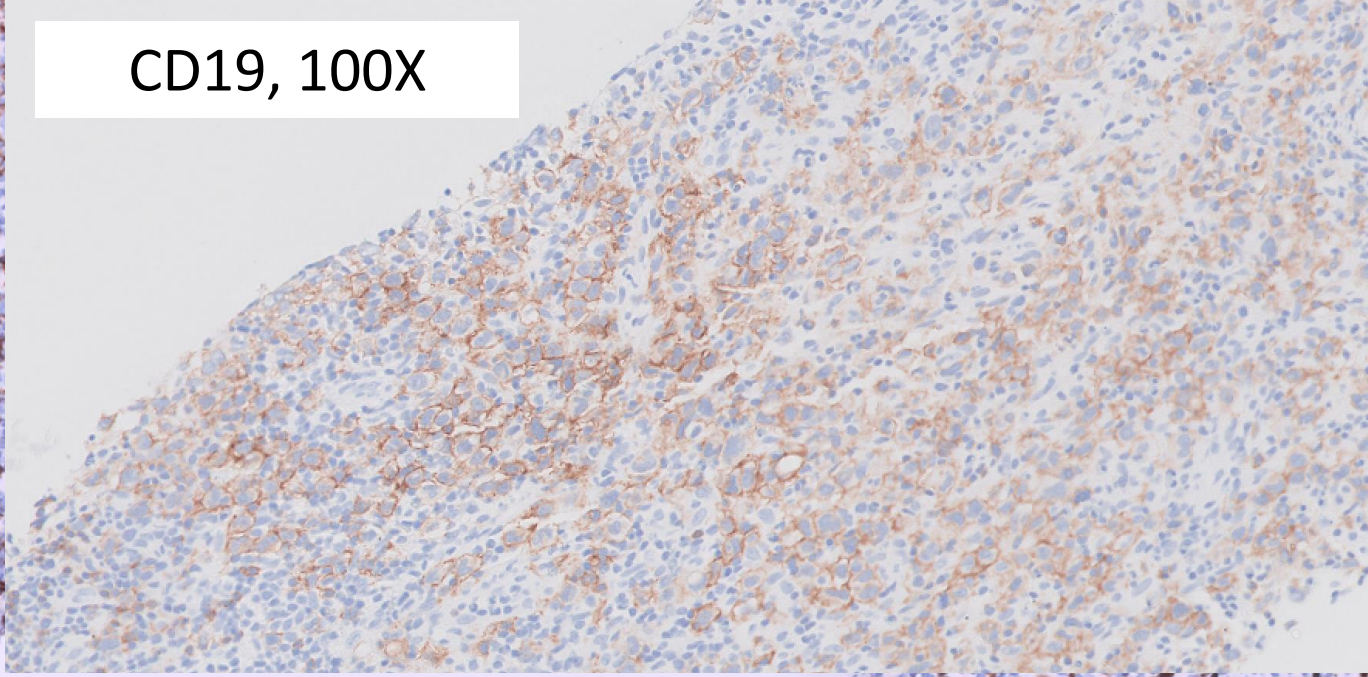


GATA3, 100X

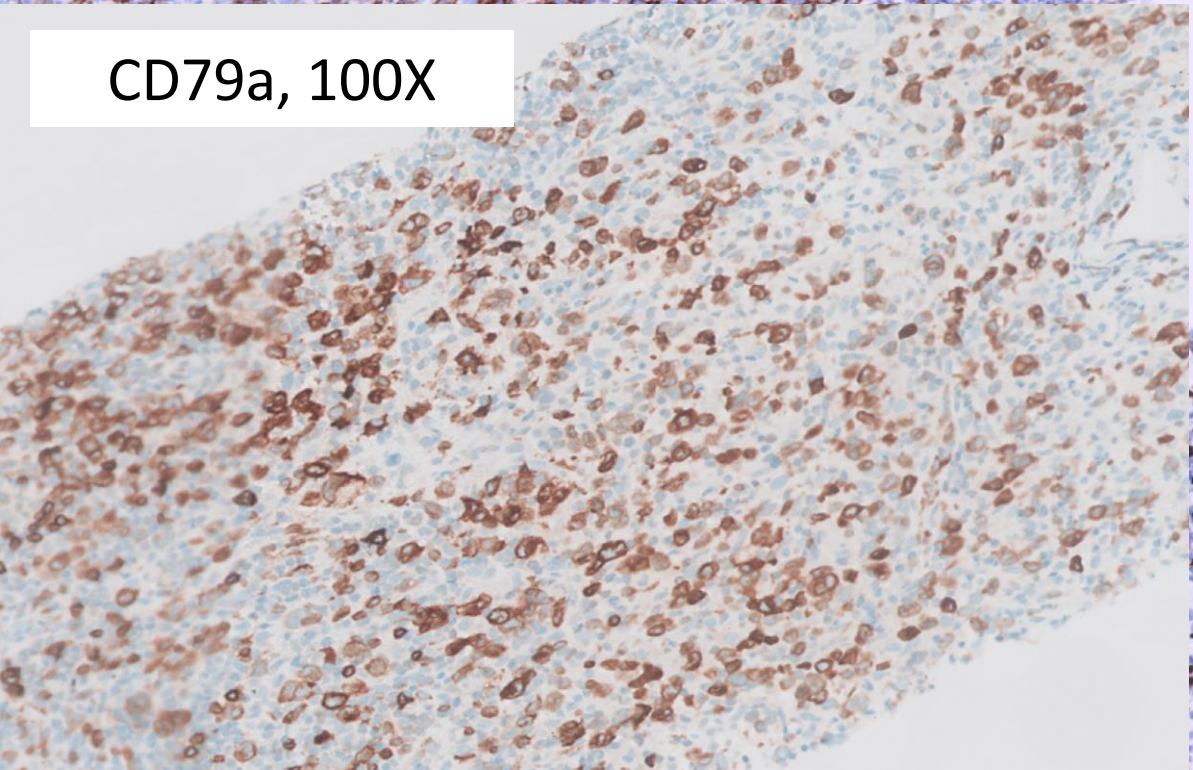
CD20, 100X



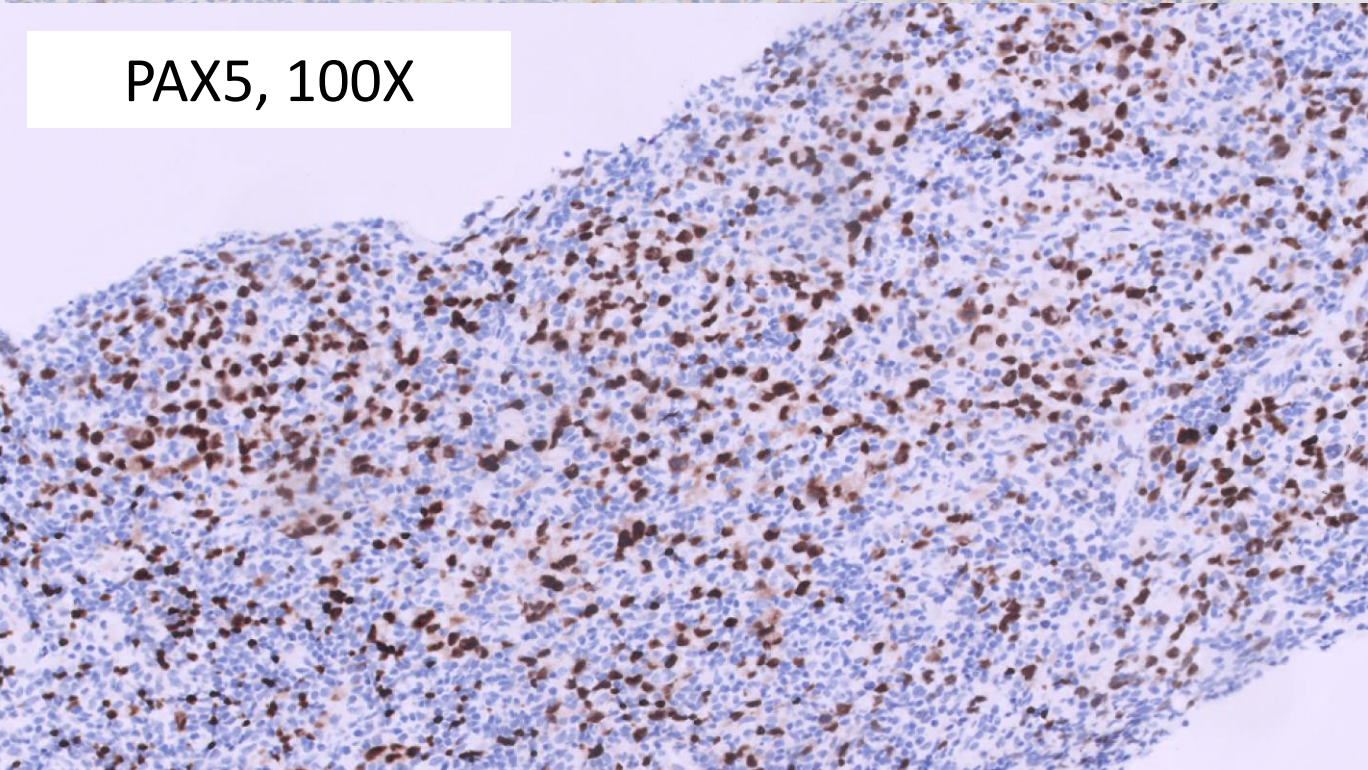
CD19, 100X

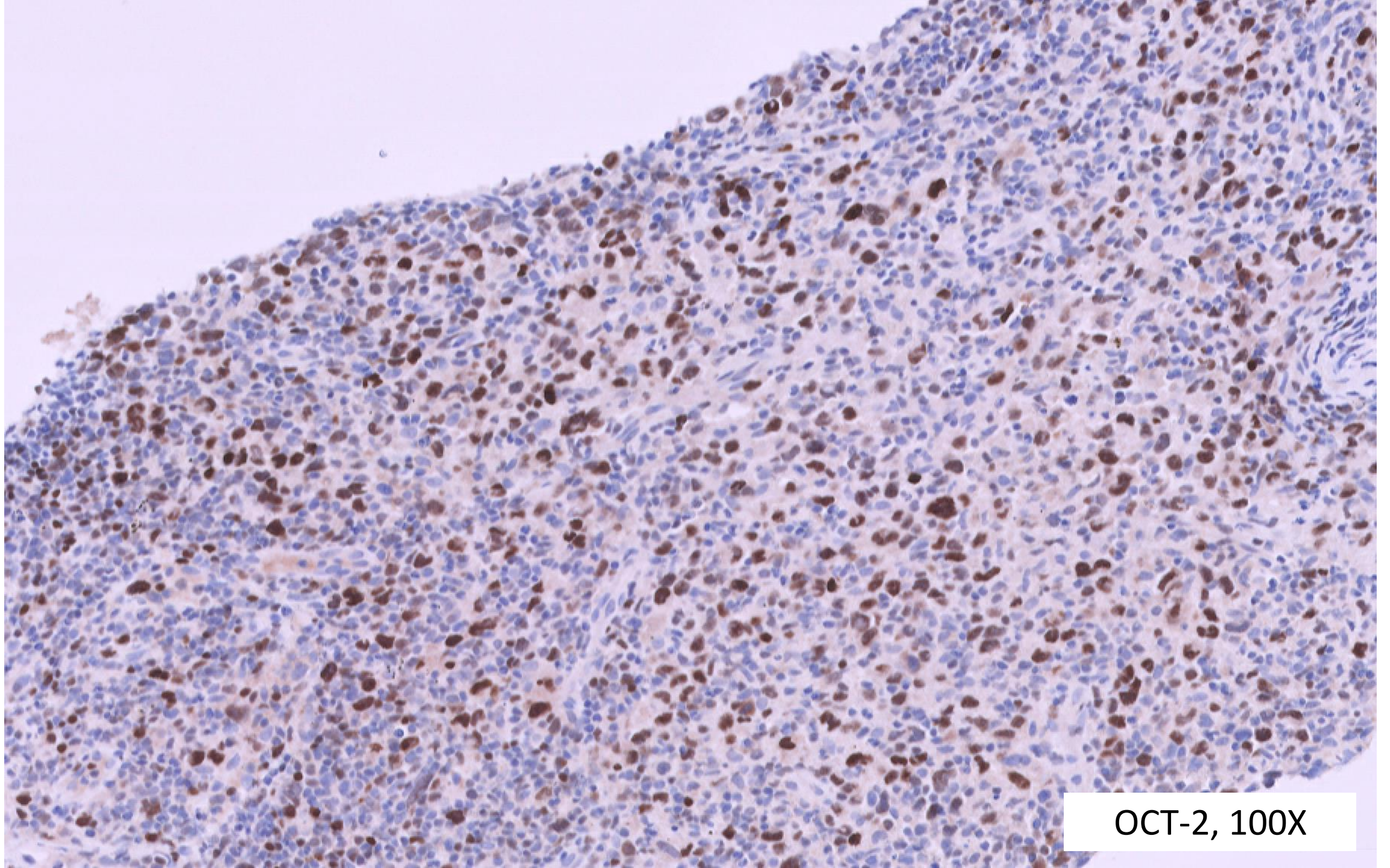


CD79a, 100X

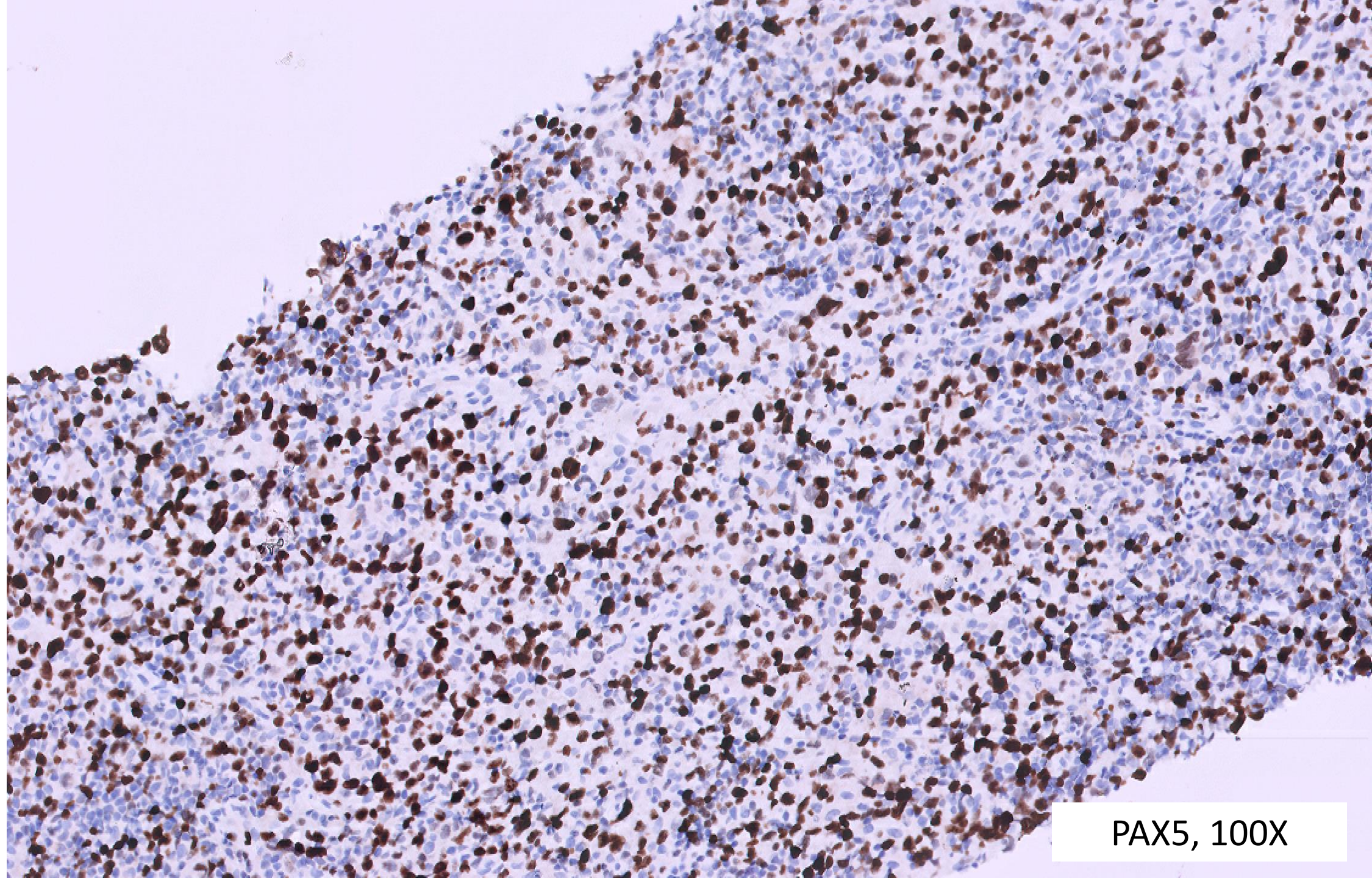


PAX5, 100X





OCT-2, 100X



PAX5, 100X

IHC

- Positive for:

- CD30, CD15, STAT6, PDL1, GATA3, CD20, CD19, CD79a, PAX5, OCT-2, BOB1, MUM1
- Ki67 >90%

- Negative for:

- EBV, MEF2B, CD22, CD10 and BCL6
- Kappa/lambda show polytypic expression

DIAGNOSIS?



24-1005

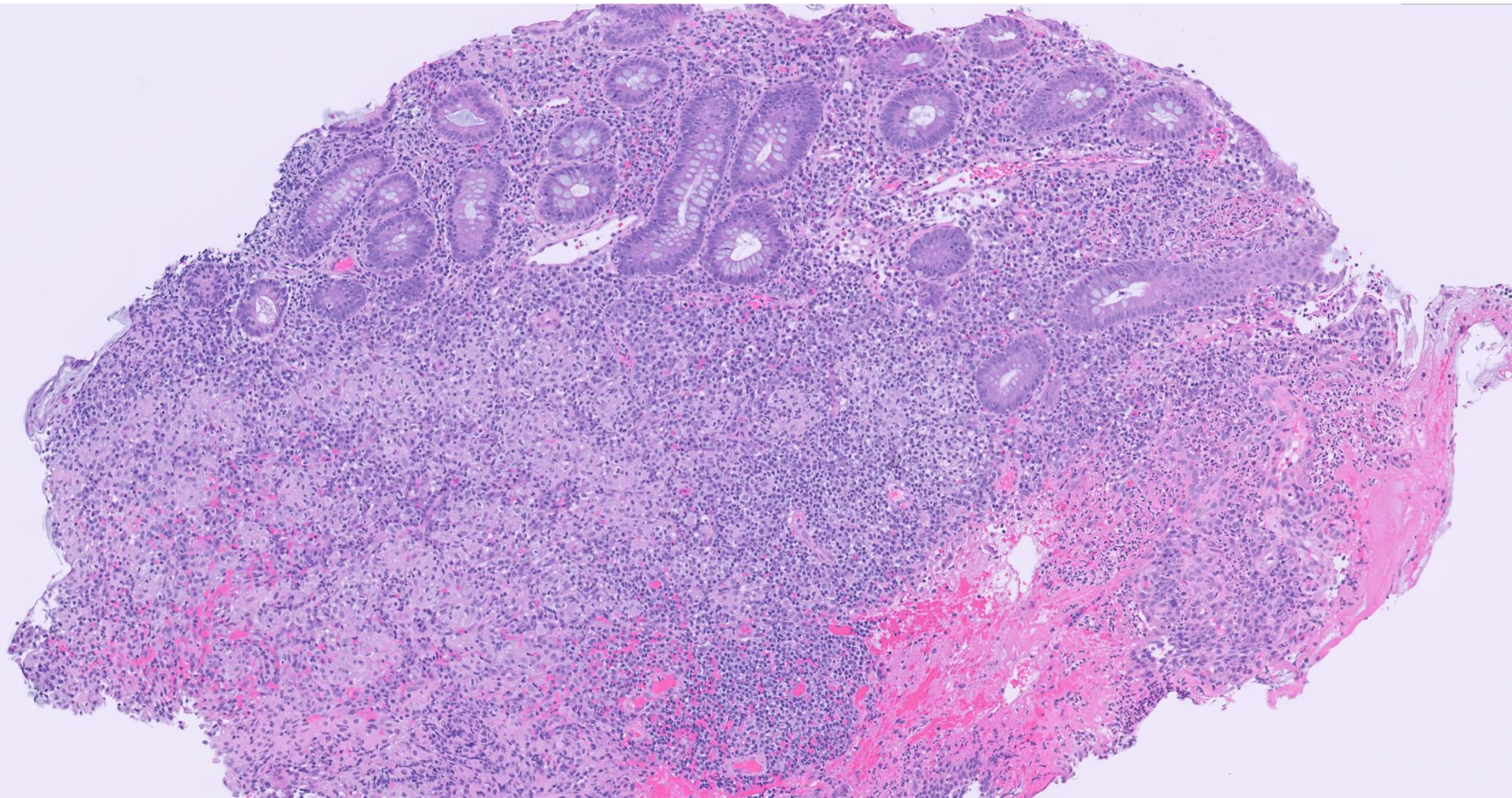
**Polina Burov/ Steven Morrow Chirieleison/
David Bingham; Stanford**

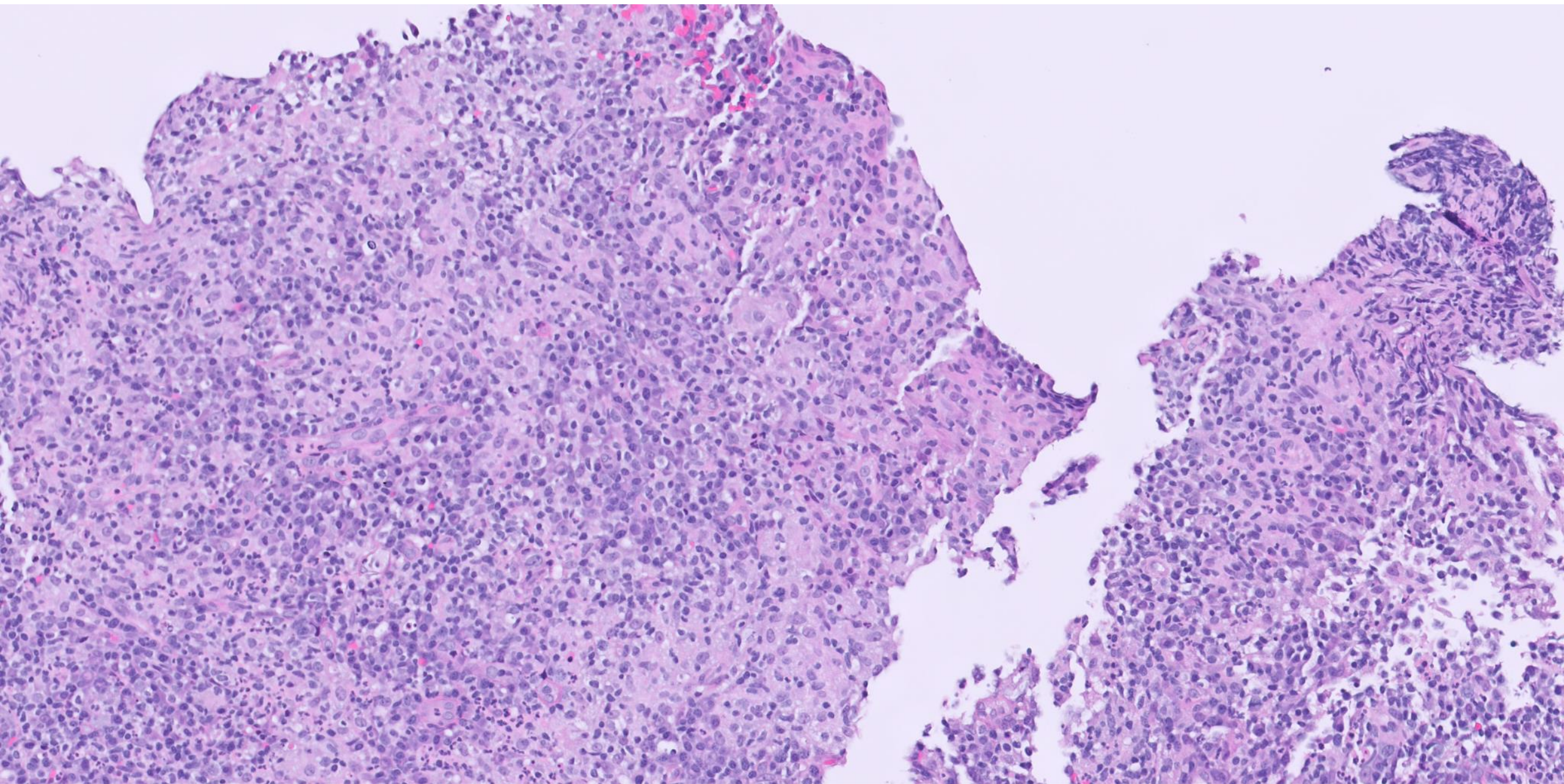
18 y.o. female with ongoing Crohn's disease underwent routine follow-up

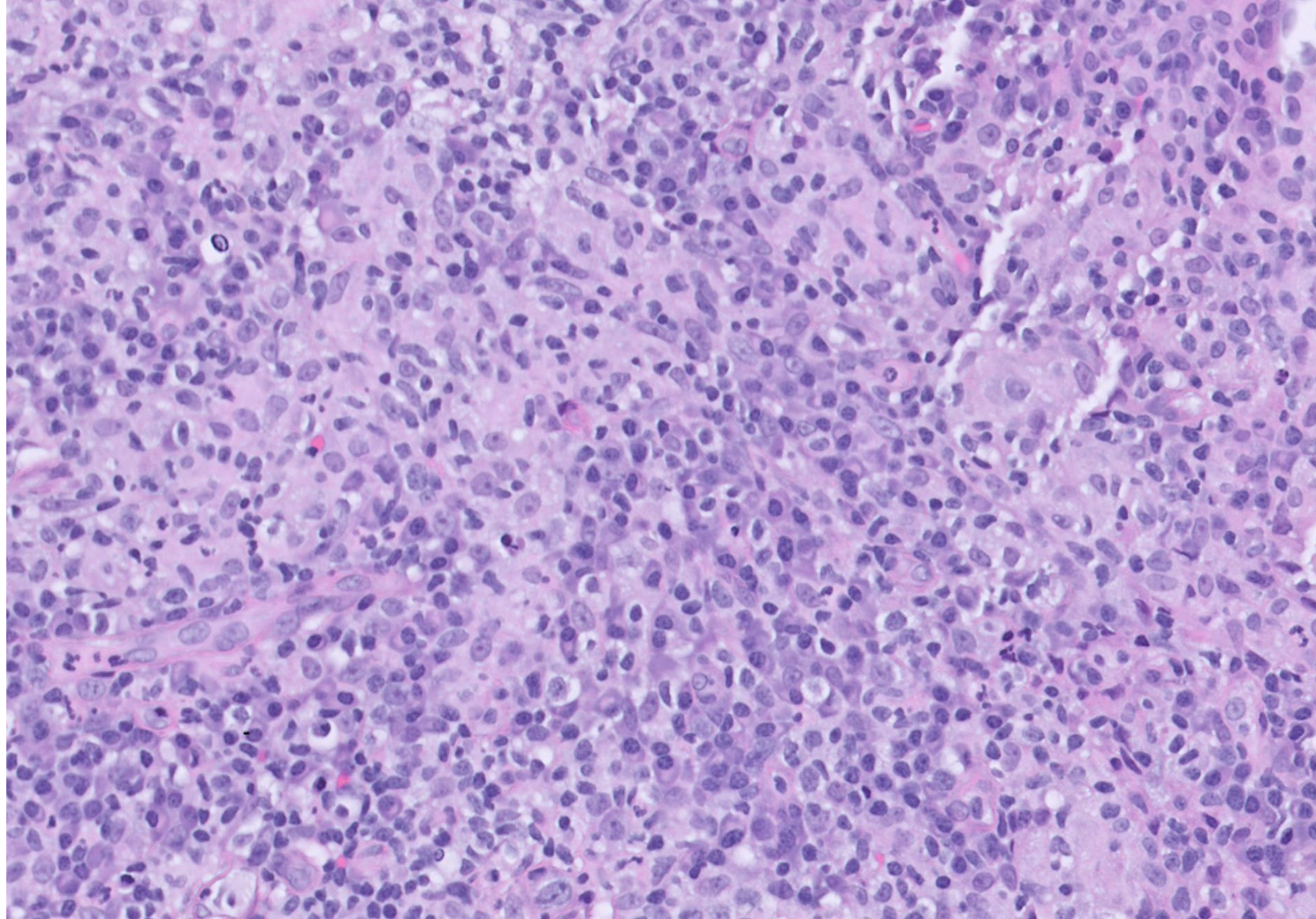
Colonoscopy: Small polypoid lesions (~1cm) were detected in 3 distinct areas.
Two nodules with ulcerated top at 45 cm and 65 cm to the anus were biopsied.
No symptoms, the patient was in clinical remission.

Previous diagnosis: Crohn's disease involving terminal ileum 06/22/2023

Medications (for the past 3 years): infliximab, methotrexate







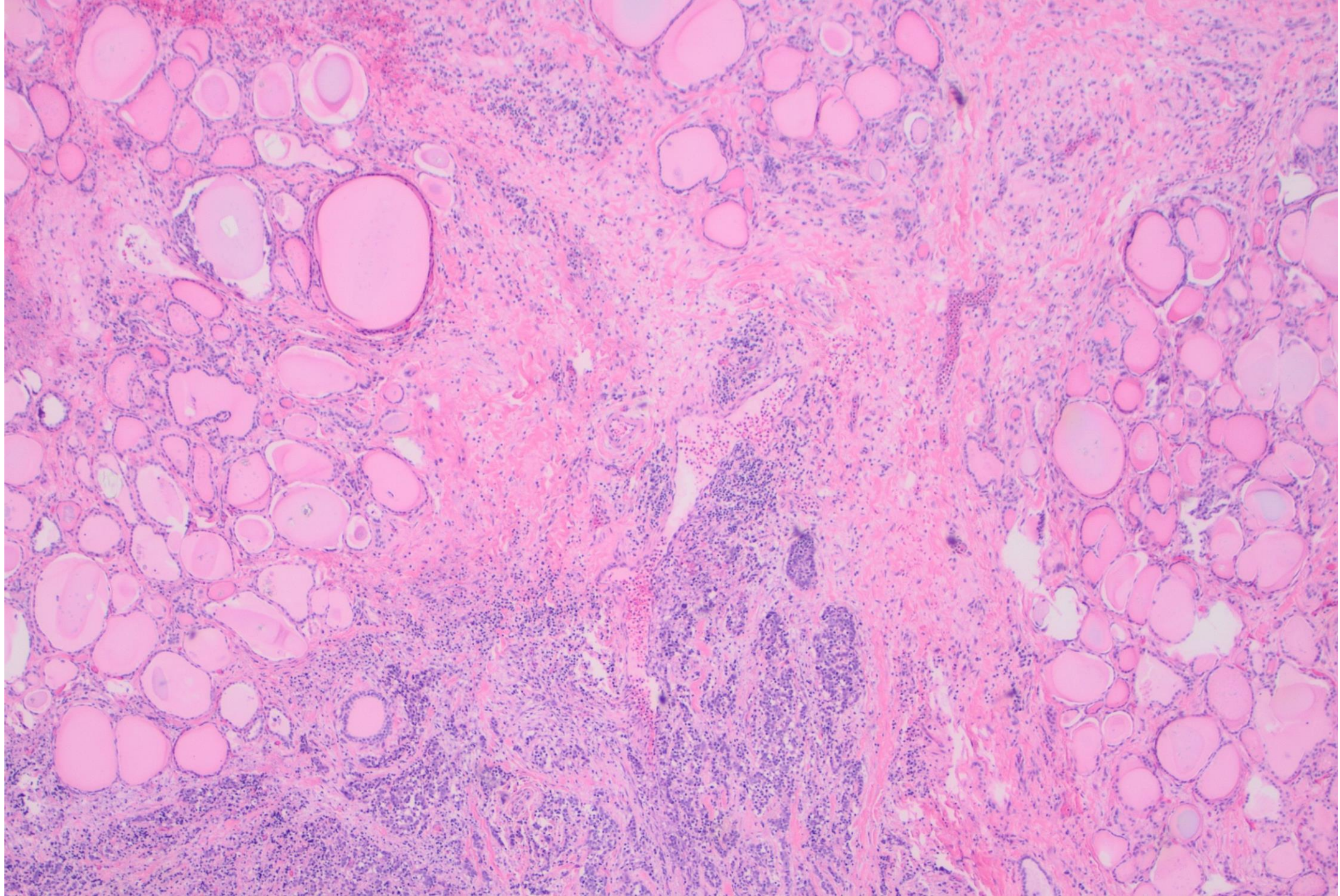
DIAGNOSIS?

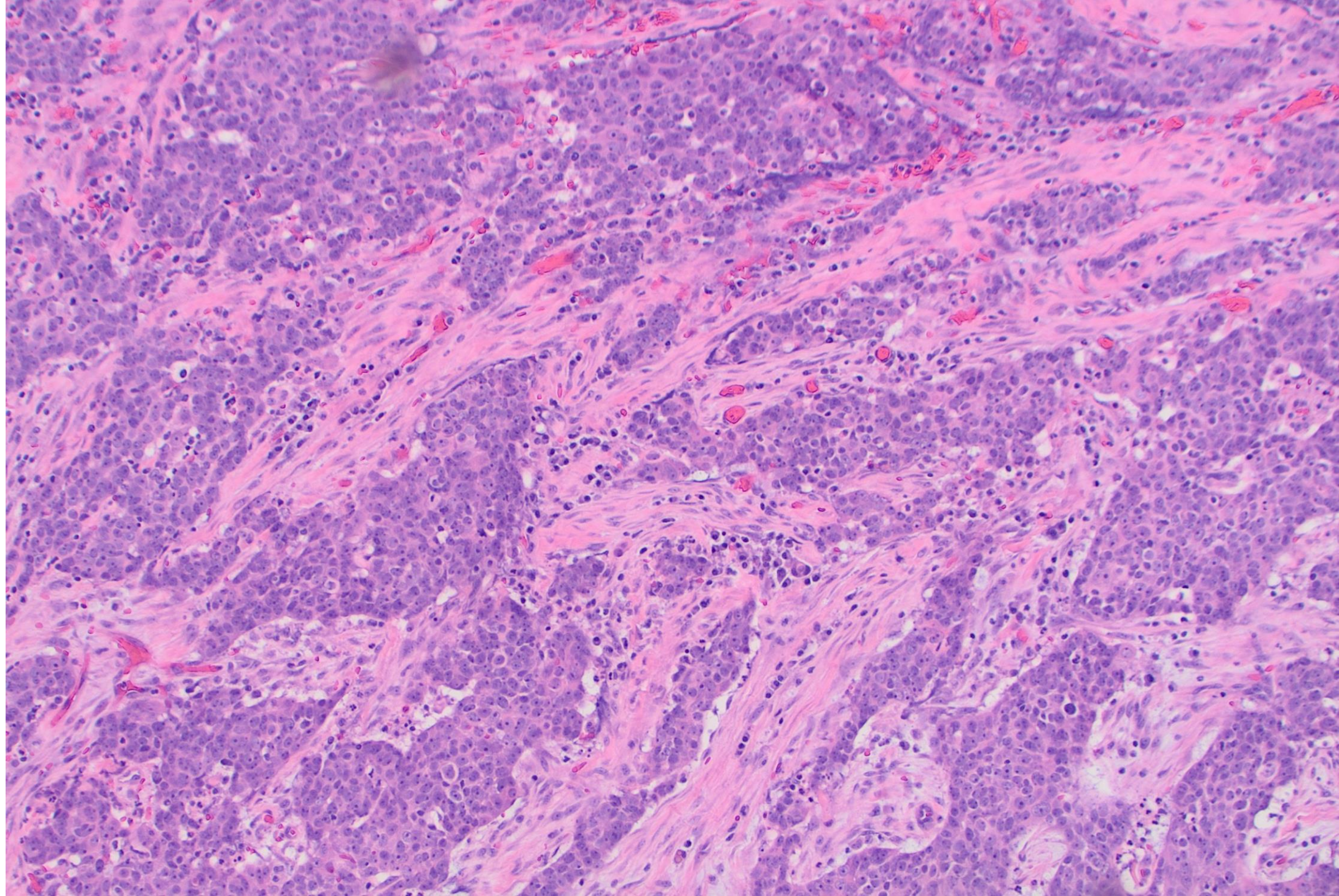


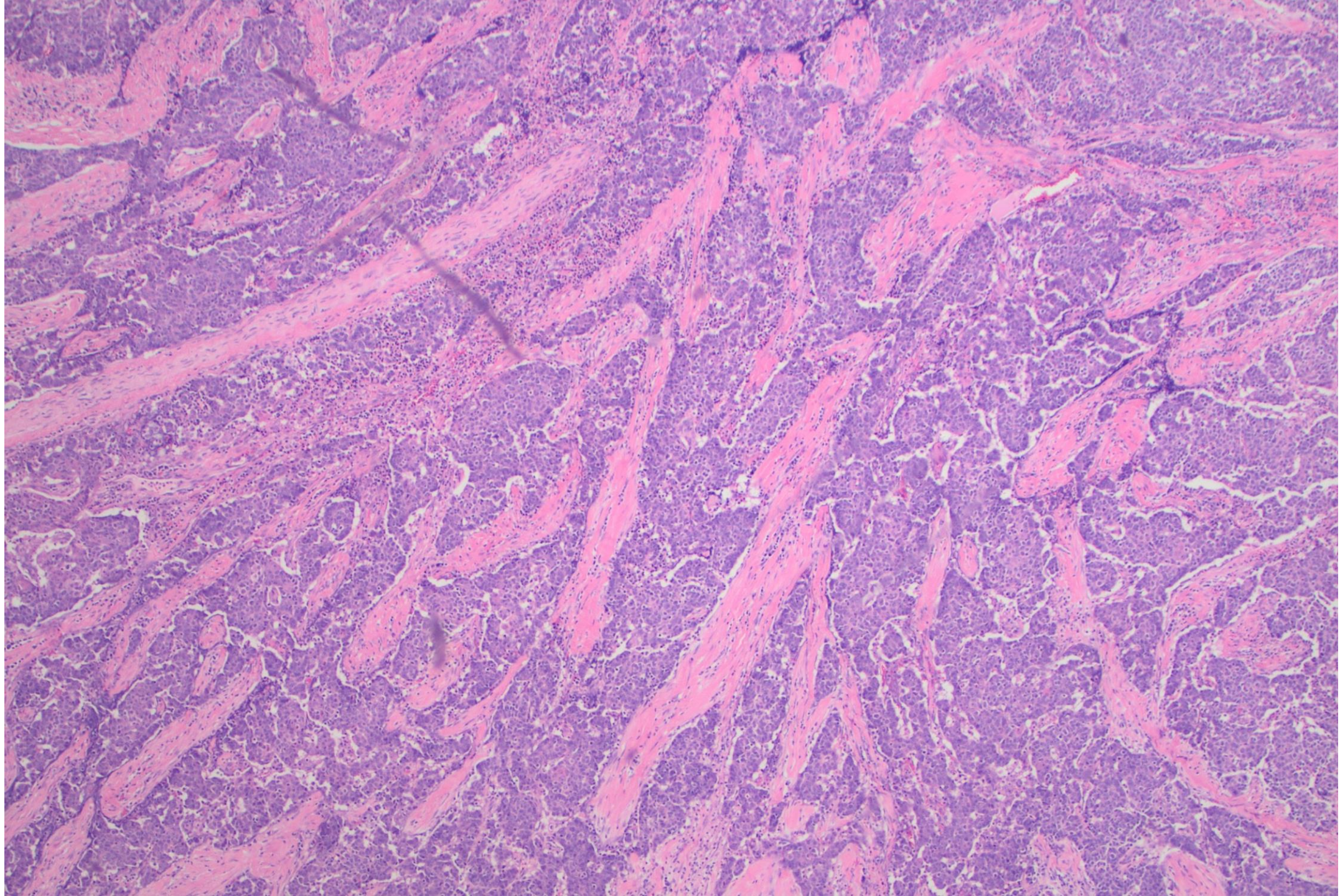
24-1006

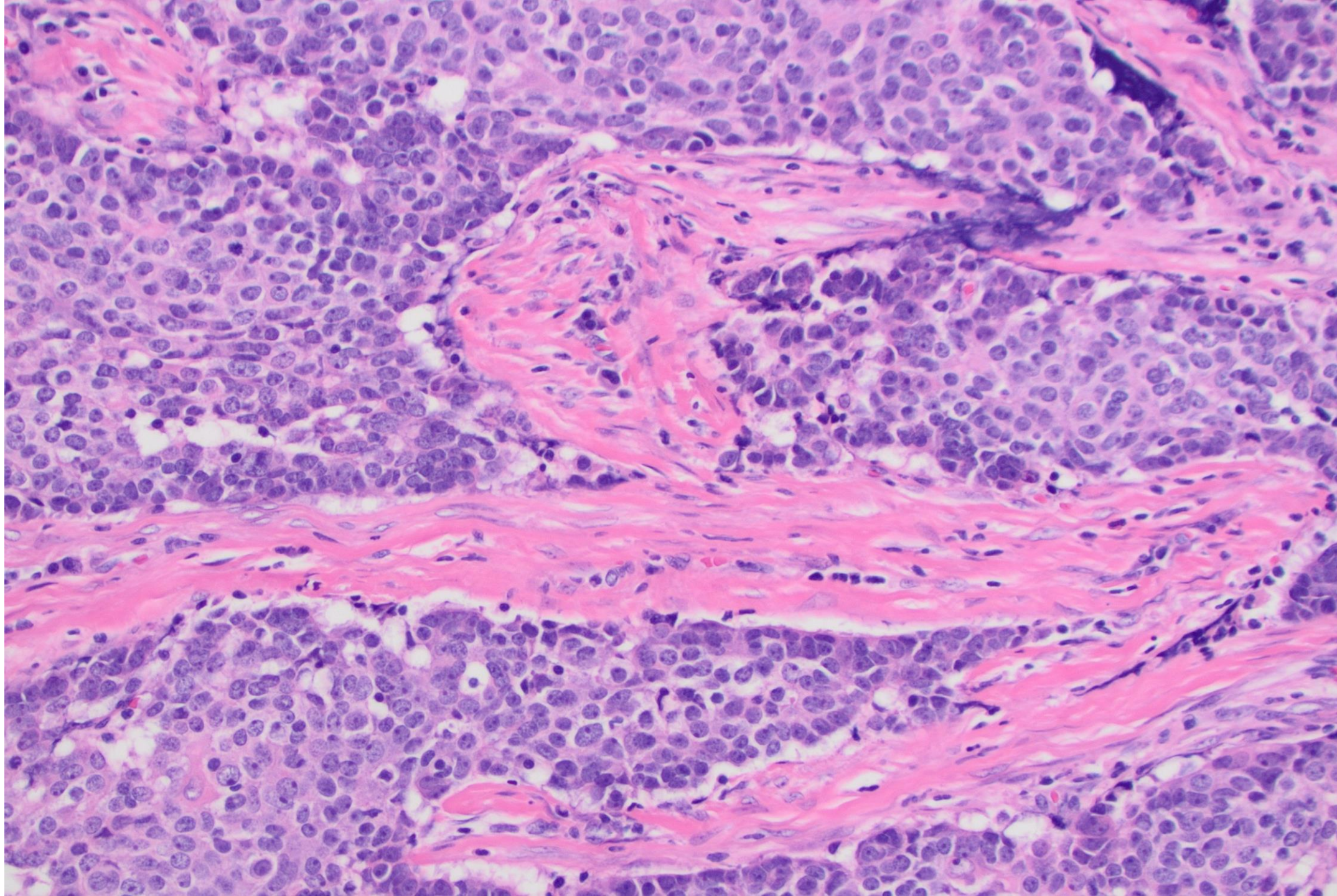
Gregory J. Rumore M.D; The Permanente Medical Group

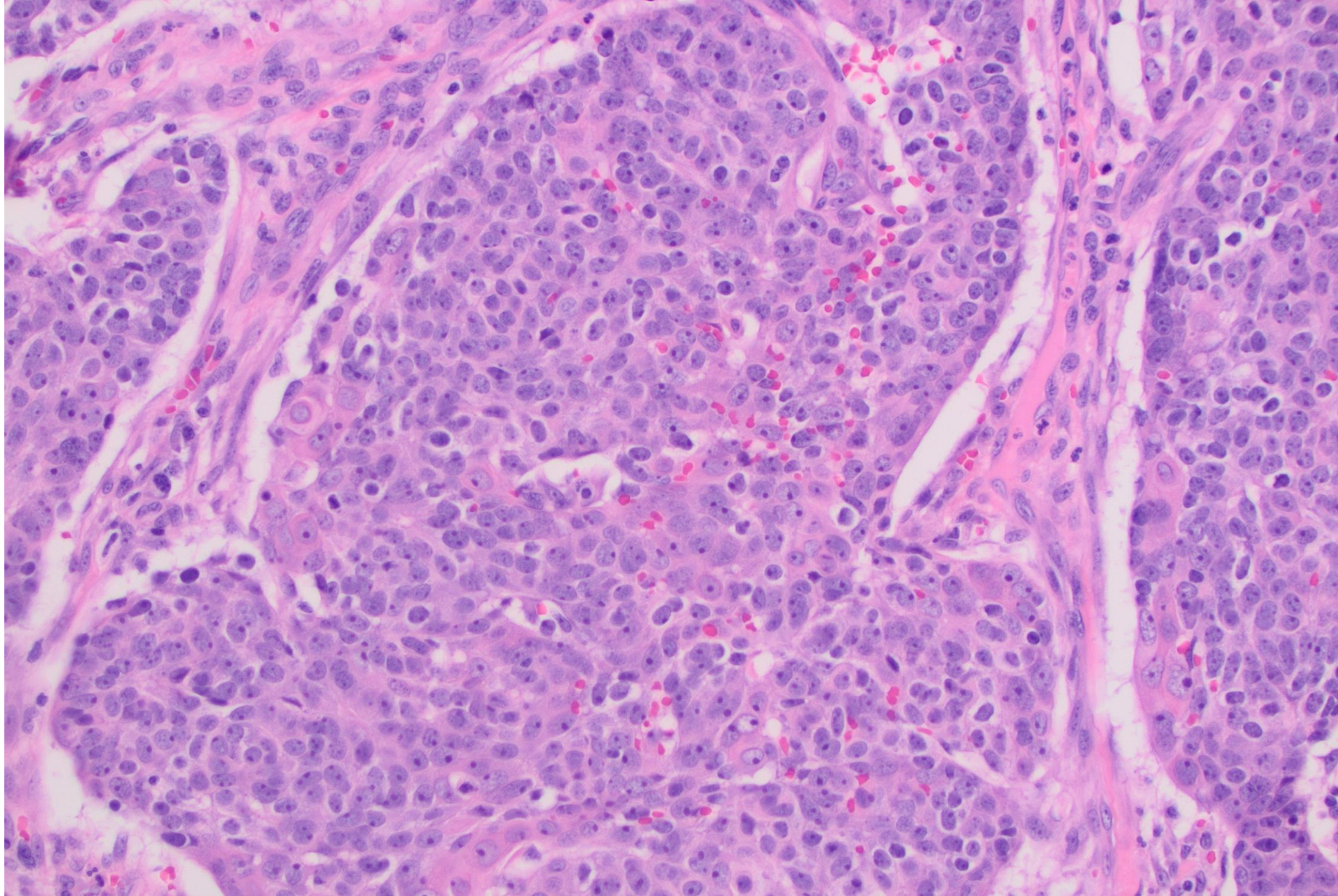
67 y.o. female with 5cm mass R lower pole of thyroid

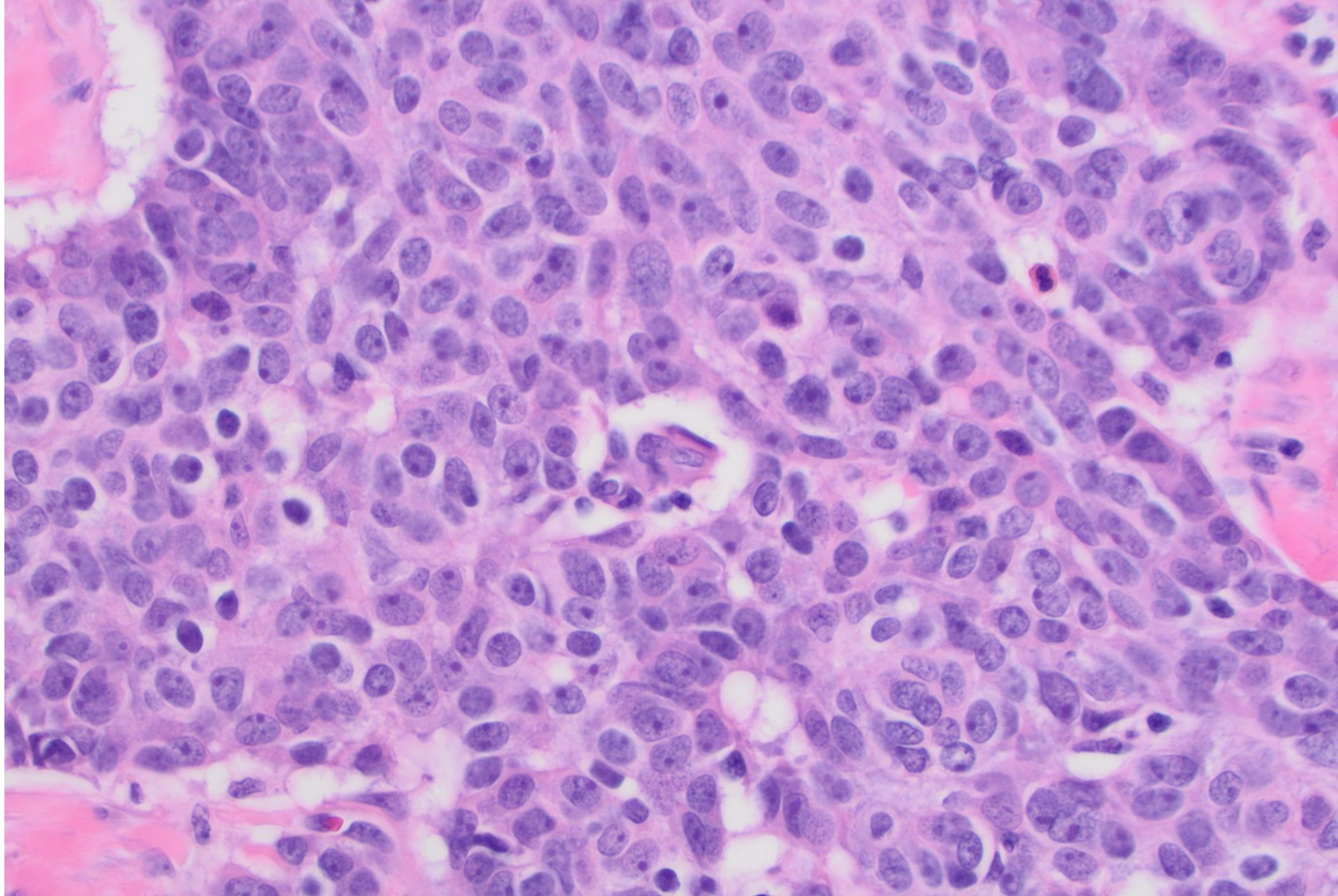


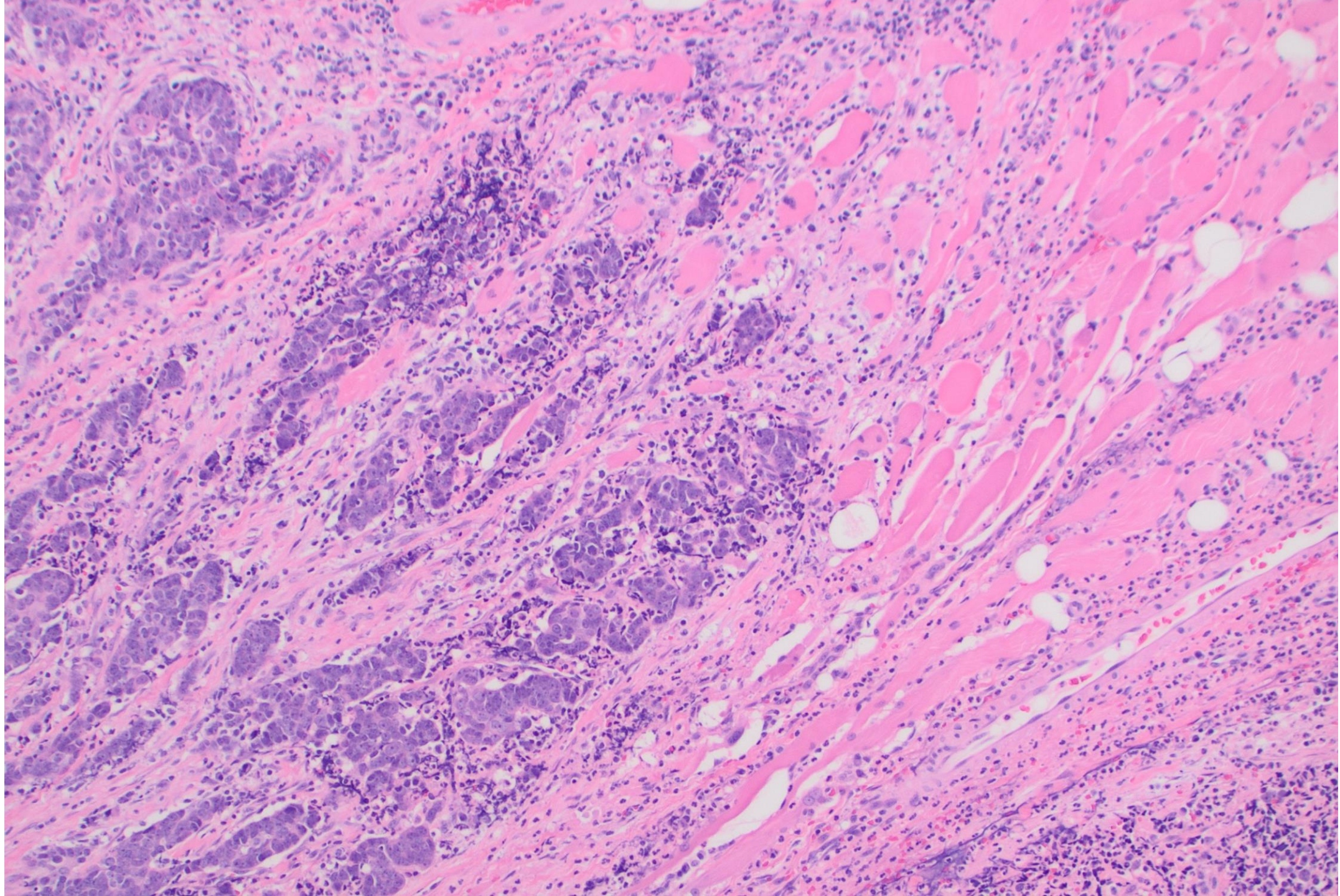












DIAGNOSIS?



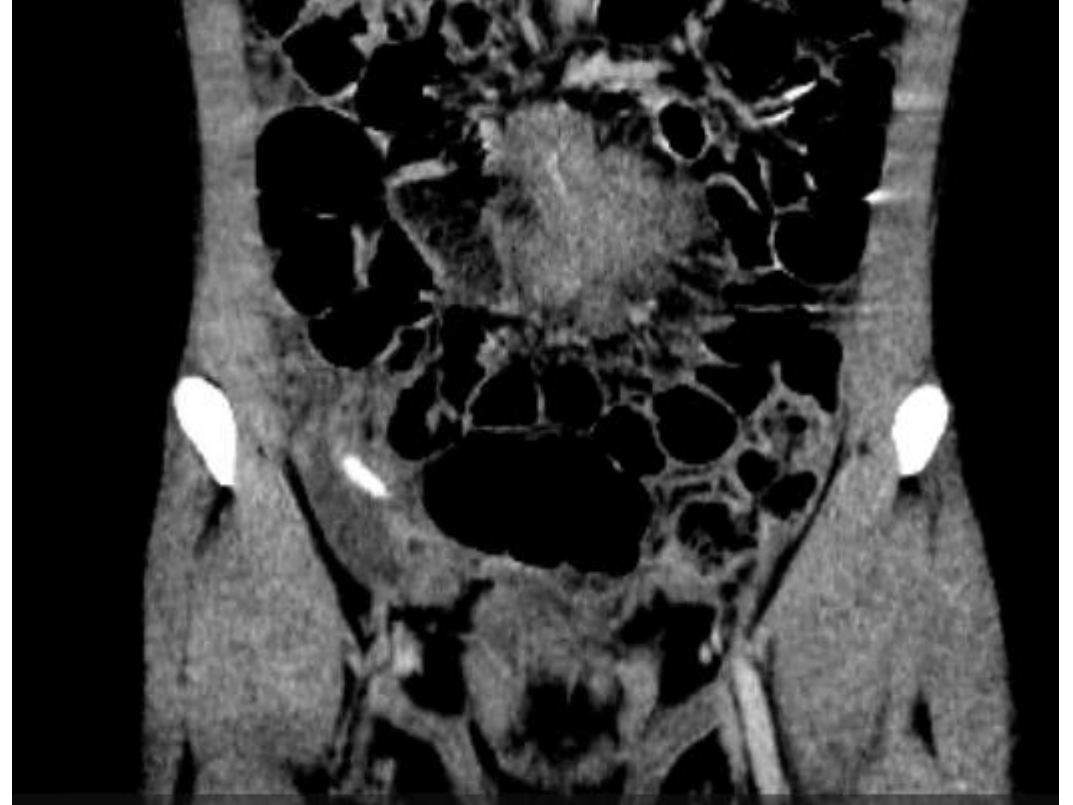24-1007

Ruobin Wu; UCSF

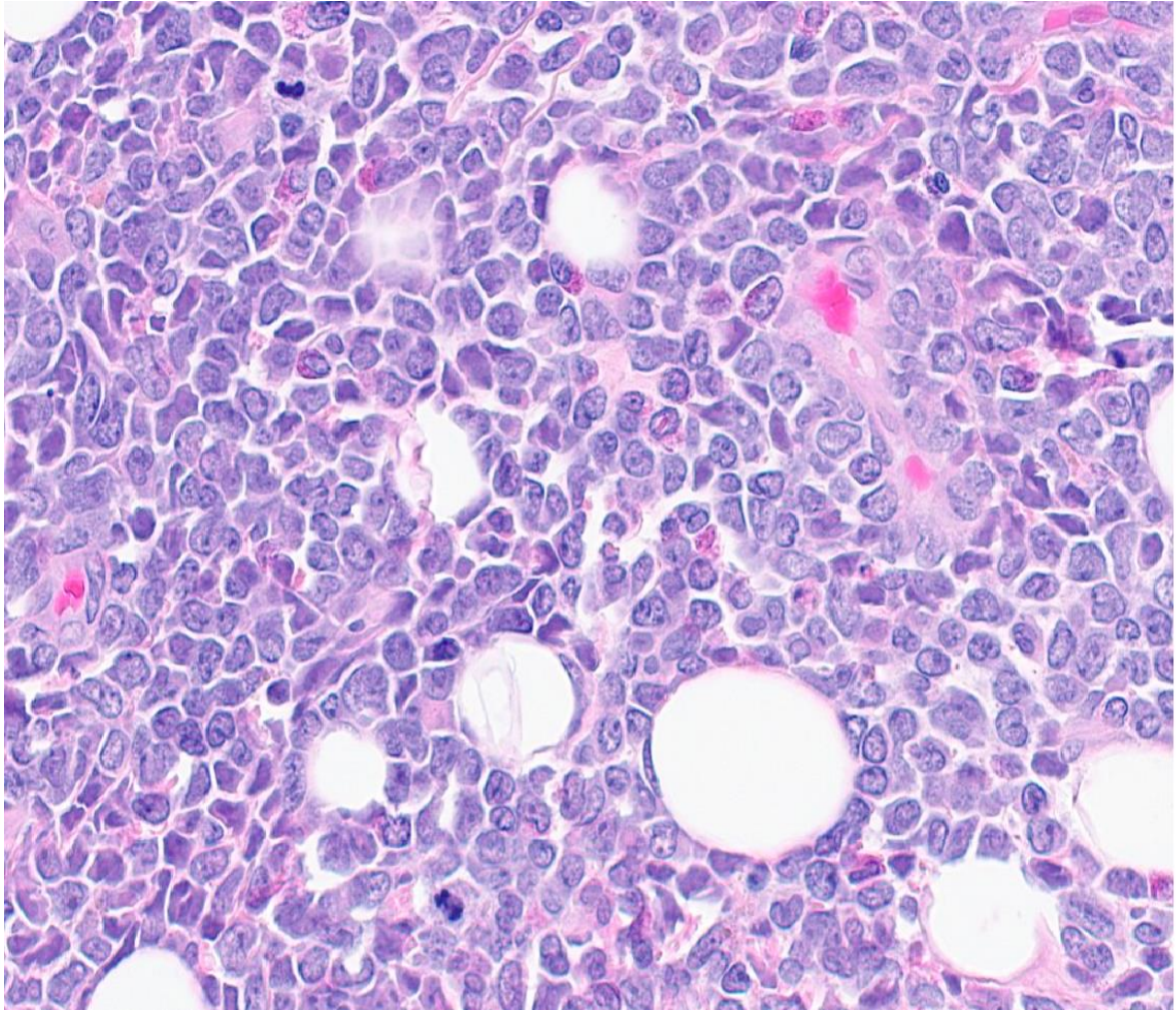
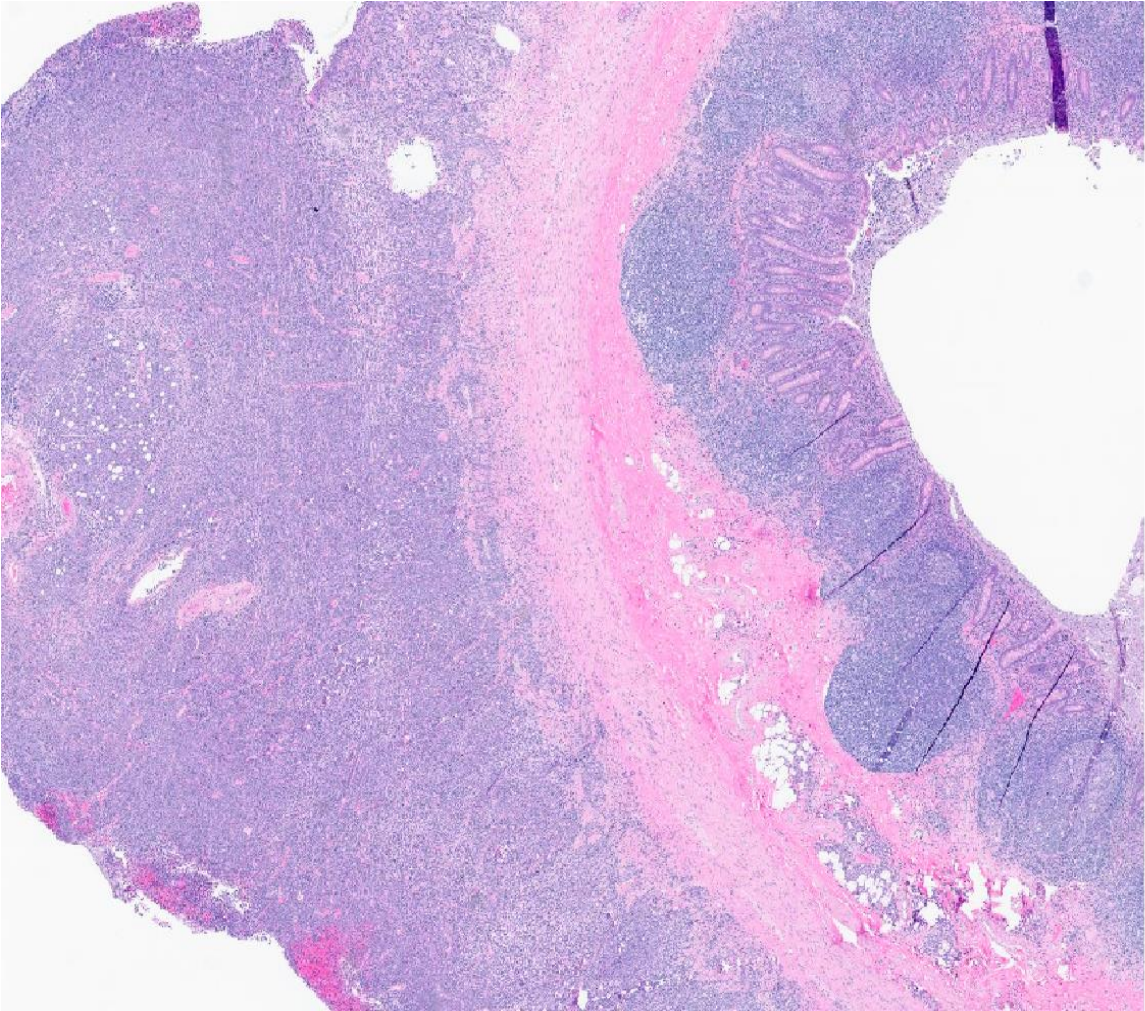
22-year-old patient with abdominal pain

Case presentation

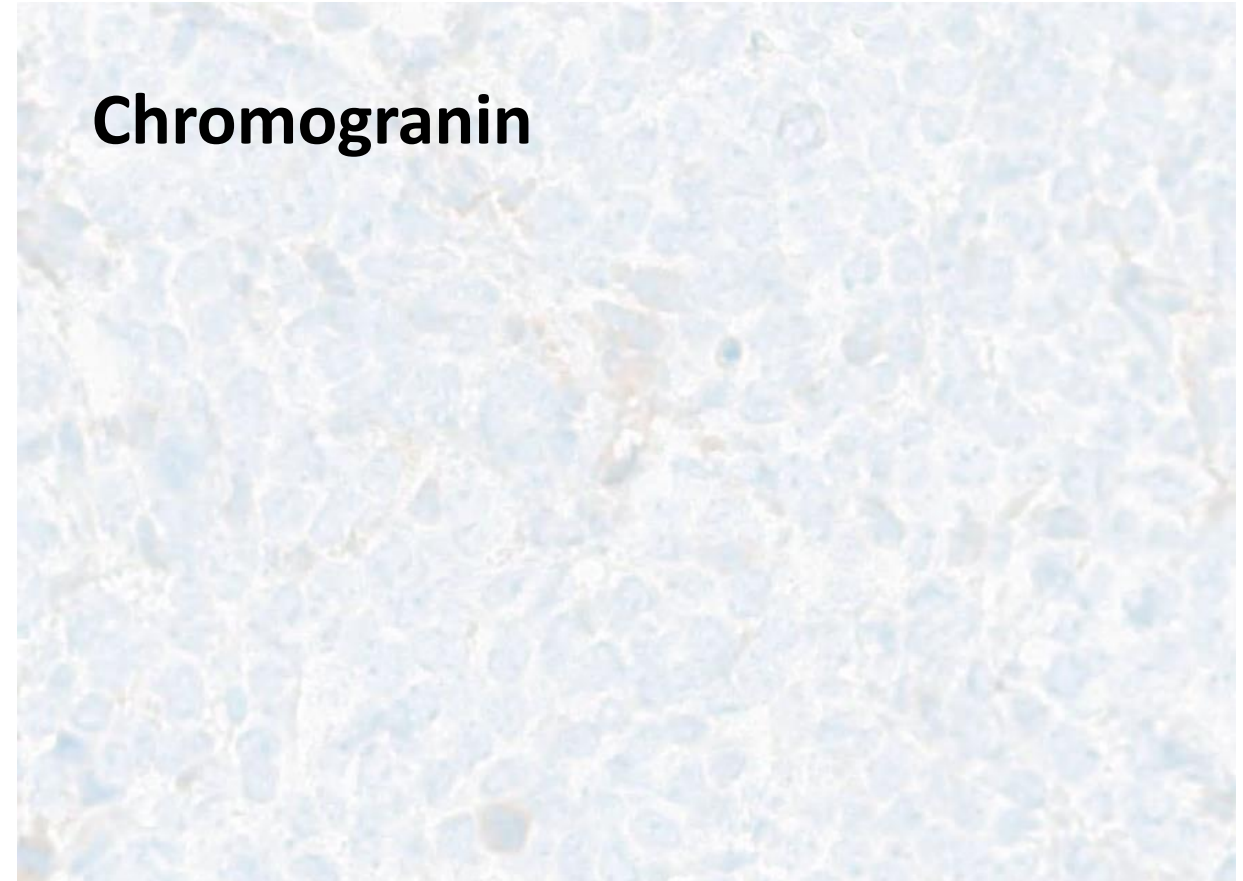
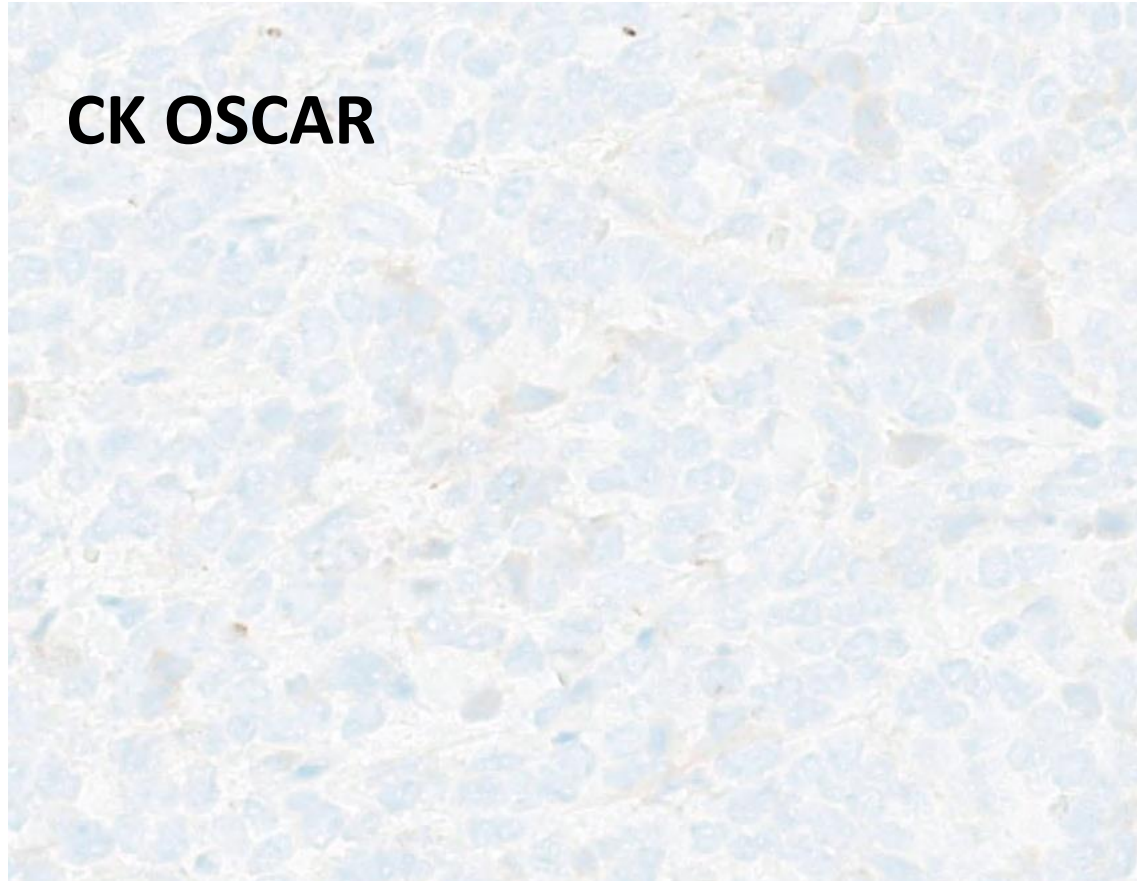
- 3/7/24 – Presented with abdominal pain, N/V
 - Imaging showed SBO
- 3/28/24 – Returns with diffuse lower abd pain, N/V, anorexia
 - CT concerning for appendicitis, periappendicitis
- Appendectomy performed



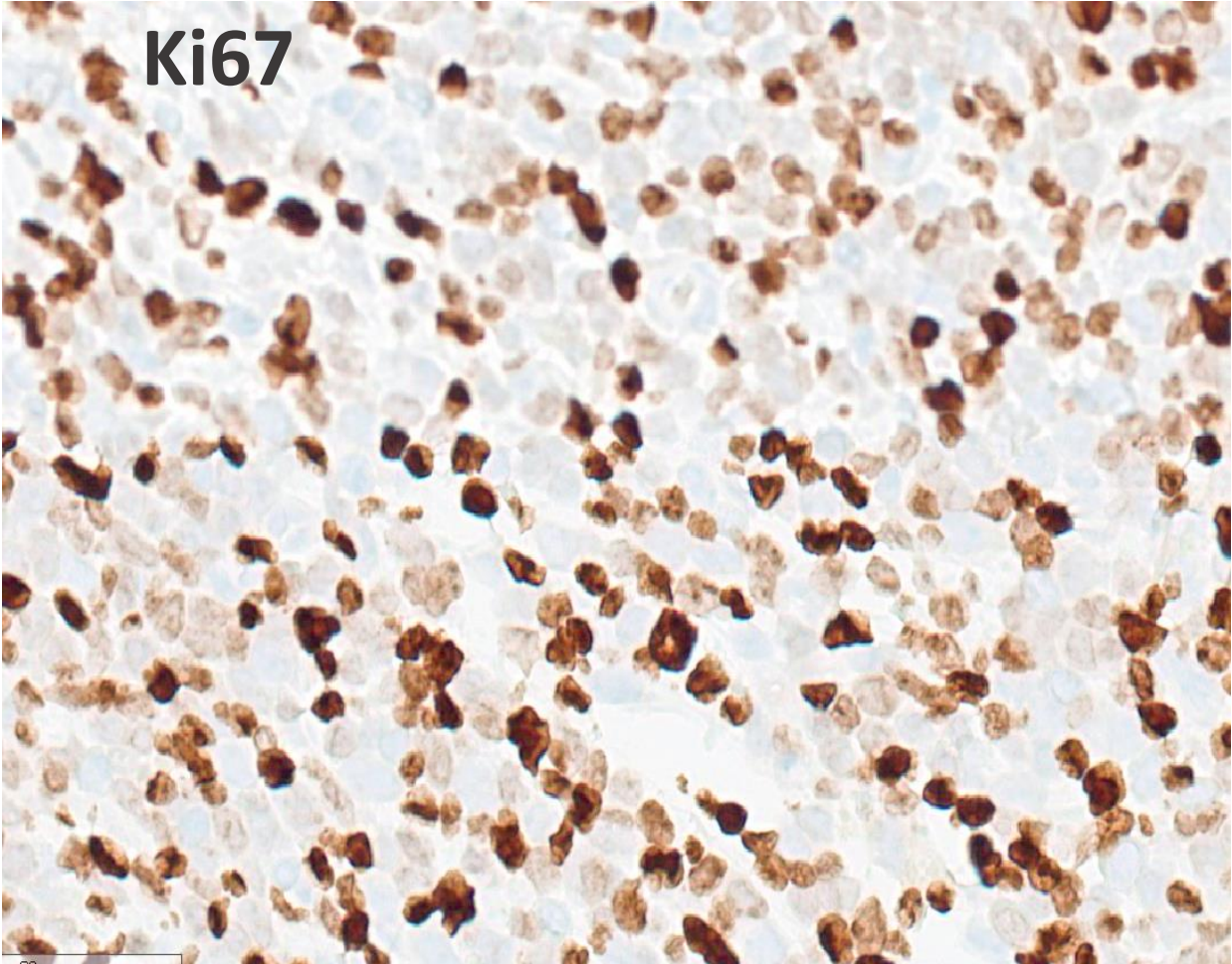
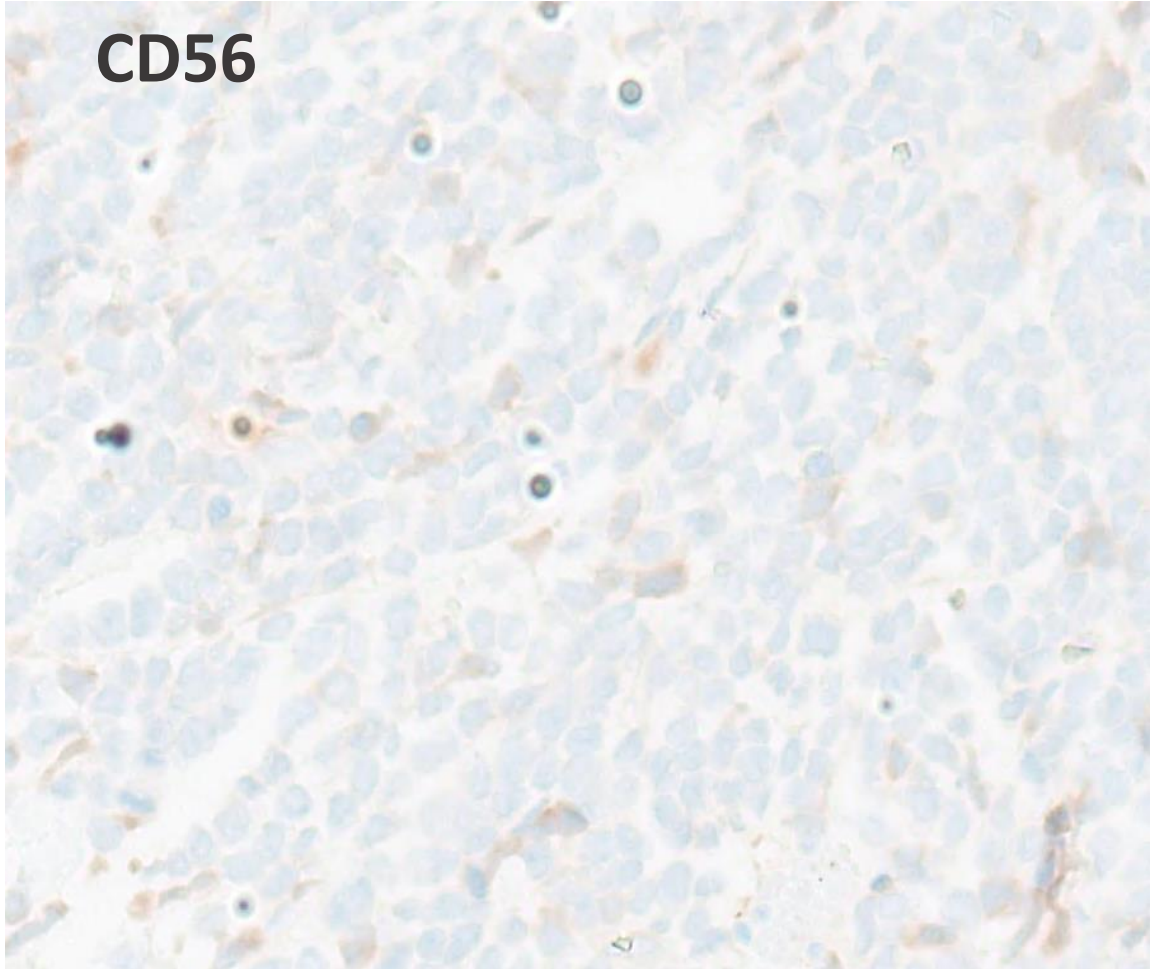
Appendix



Appendix – IHC



Appendix – IHC



DIAGNOSIS?



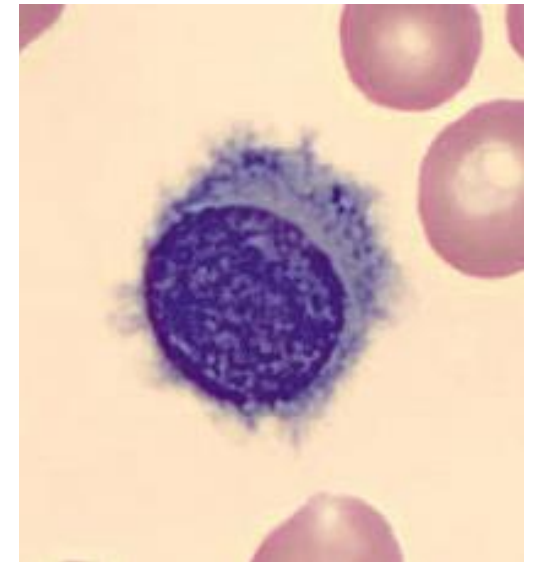
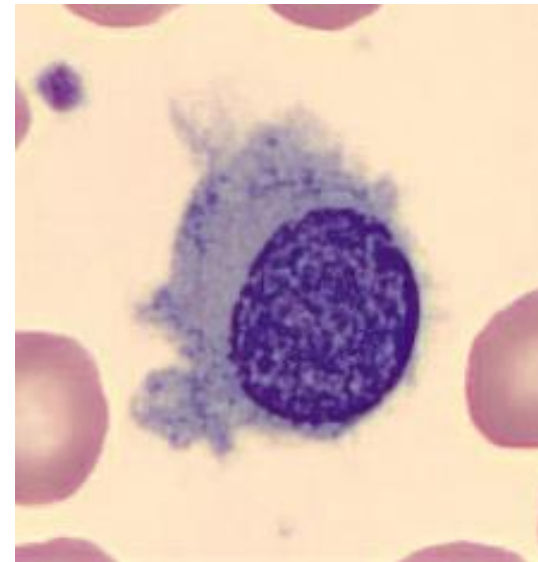
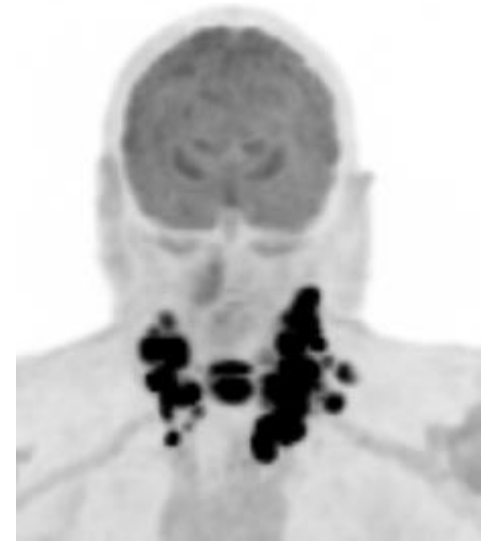
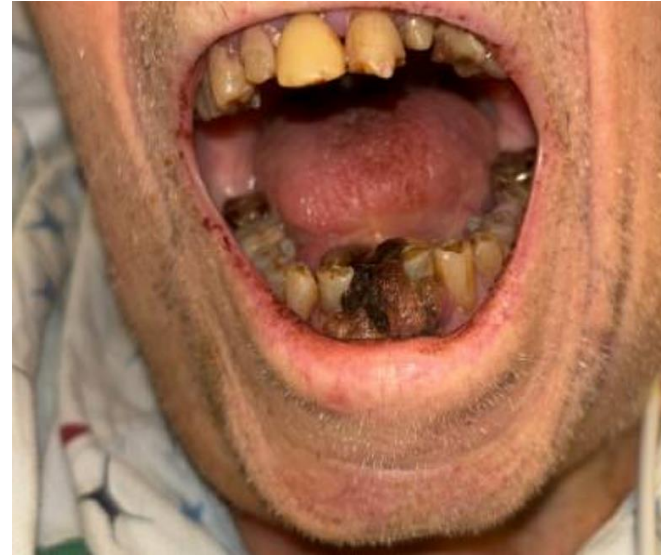24-1008

Vaishali Masatkar and Oscar Silva; Stanford

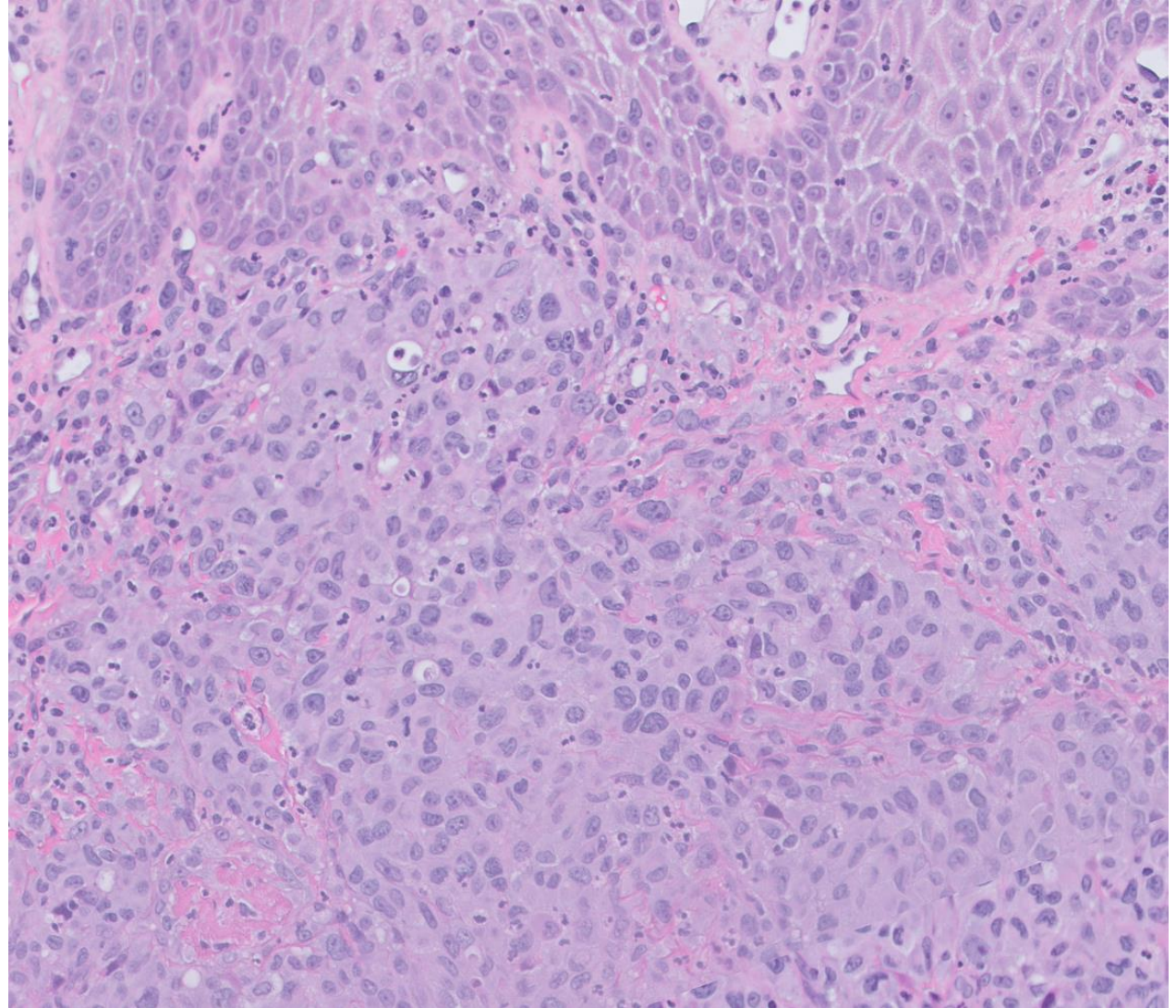
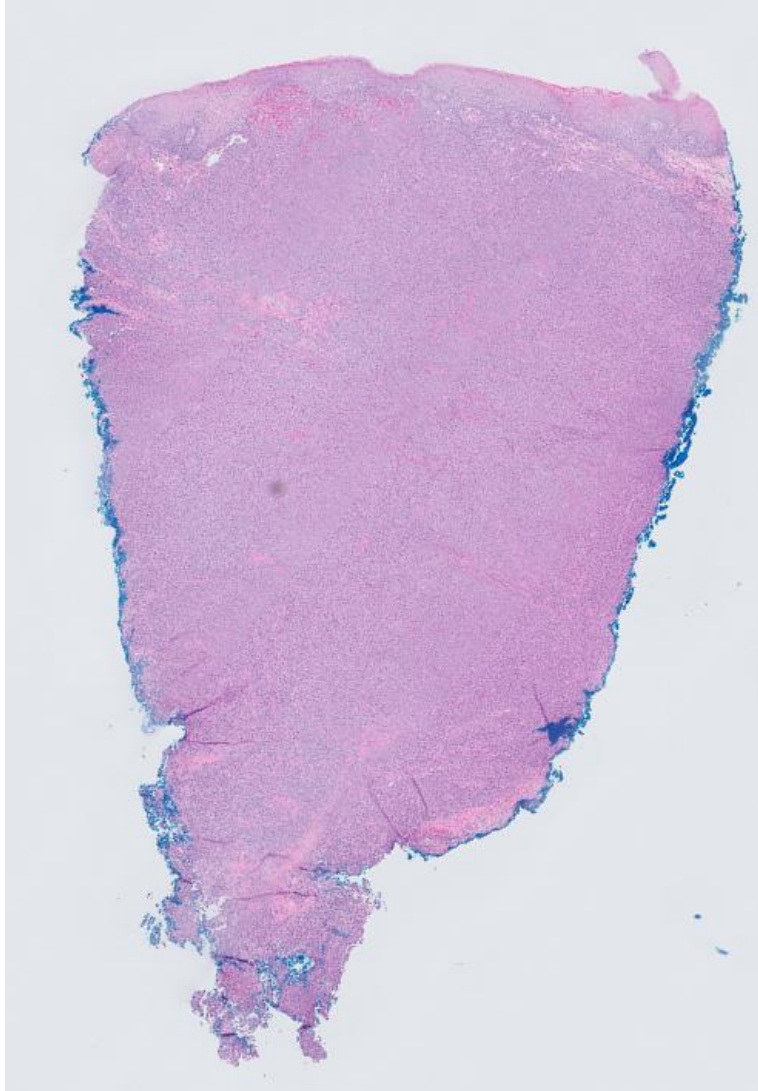
- 93-year-old male with history of **hairy cell leukemia** admitted with pancytopenia and rapidly growing oral mass
- PET/CT – Increase uptake in cervical lymph nodes
- Peripheral blood flow in July, 2023 - Kappa-restricted B-cell population (90.3% of CD45+ events) expressing CD19, CD20 (bright), CD25, CD103, CD200a and CD11c; negative for CD5 and CD10

Clinical history

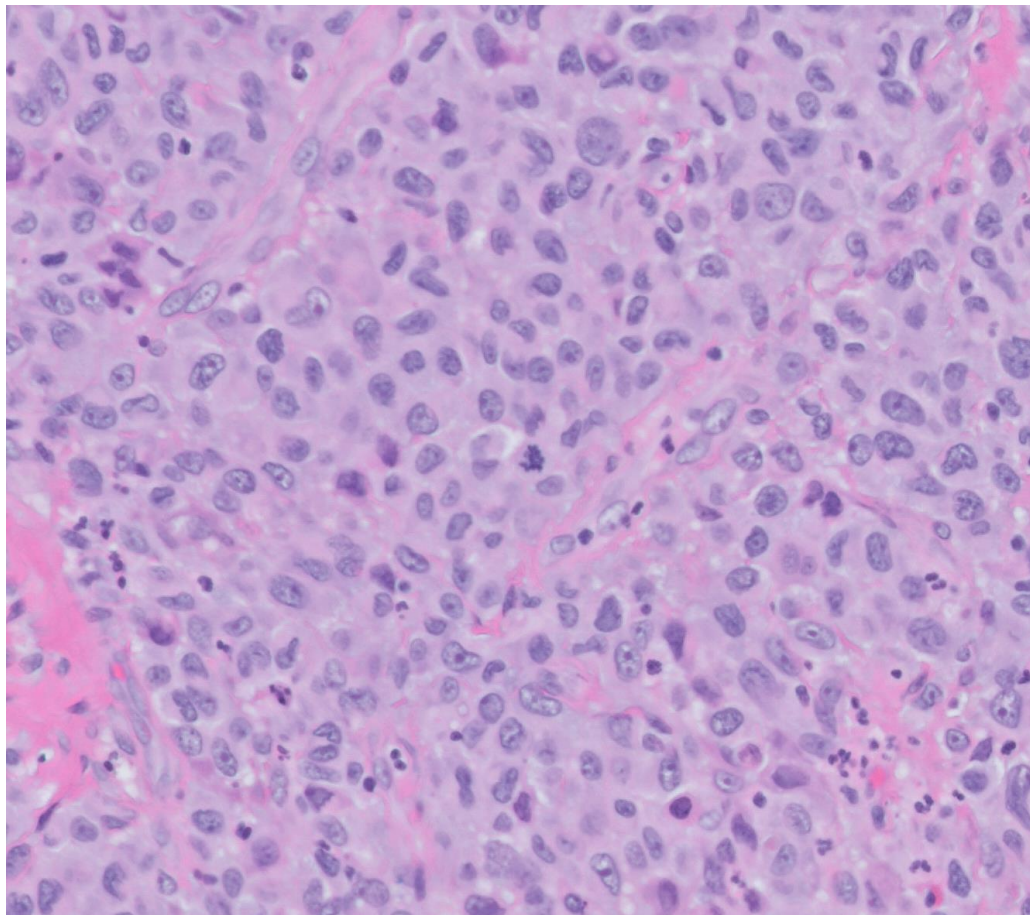
- 93-year-old male with history of **hairy cell leukemia** admitted with pancytopenia and rapidly growing oral mass
- PET/CT – Increase uptake in cervical lymph nodes
- Peripheral blood flow in July, 2023
- Kappa-restricted B-cell population (90.3% of CD45+ events) expressing CD19, CD20 (bright), CD25, CD103, CD200a and CD11c; negative for CD5 and CD10



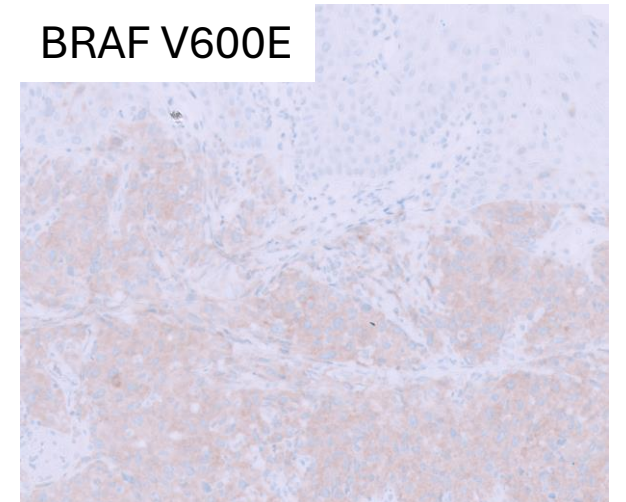
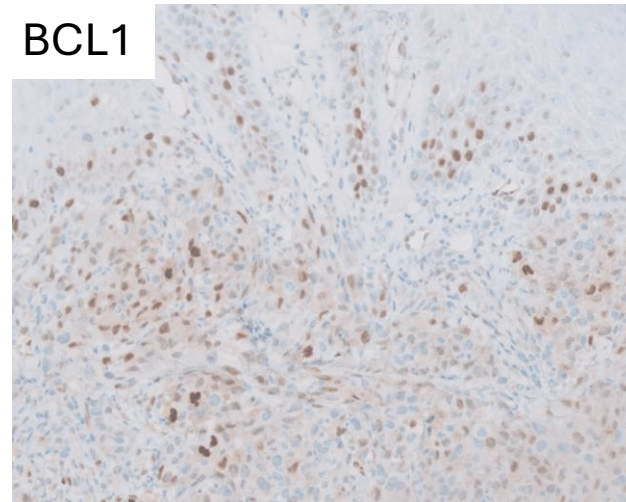
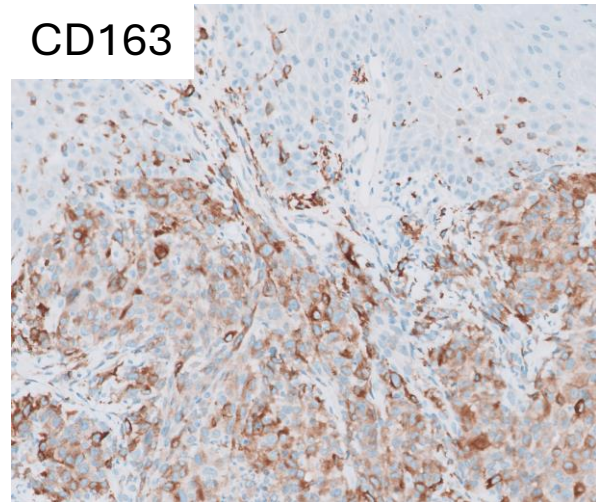
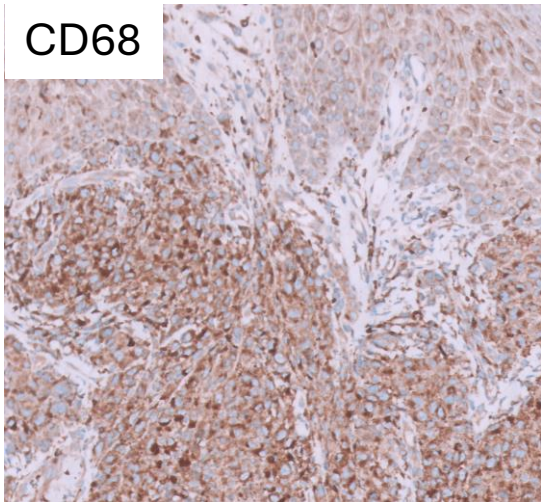
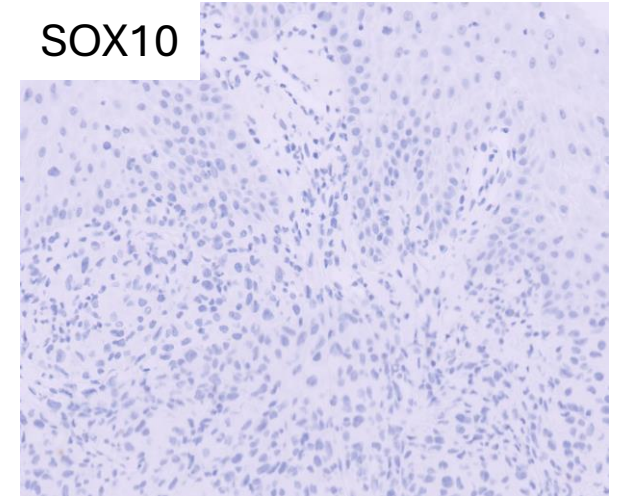
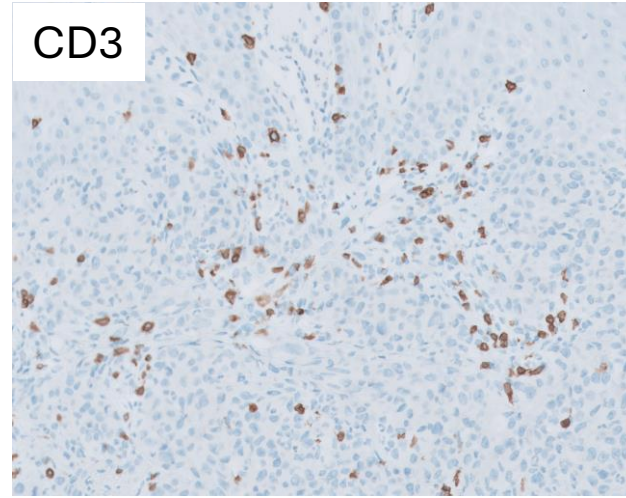
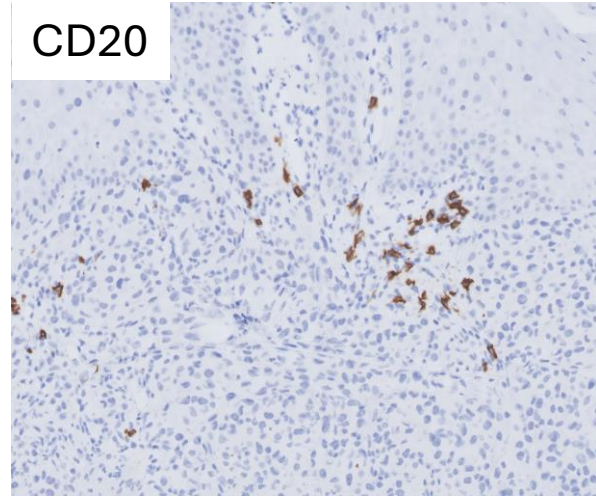
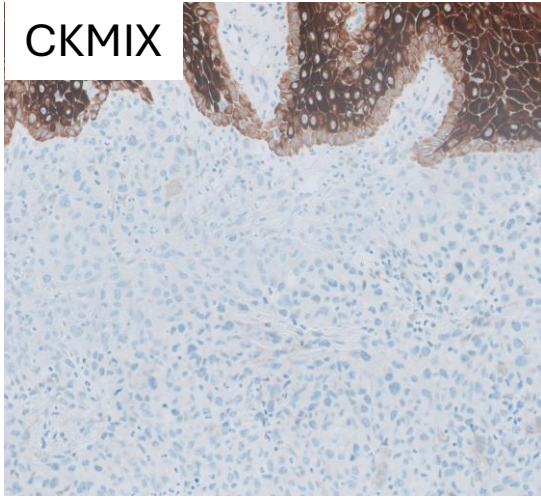
Oral Biopsy: H&E



Oral biopsy: H&E

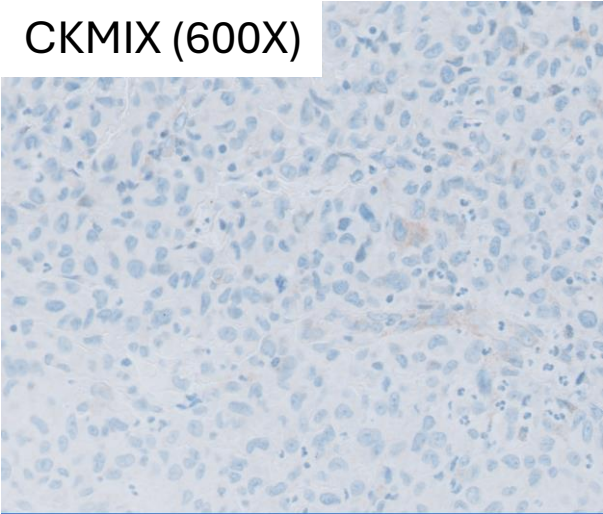


Oral Biopsy: IHC

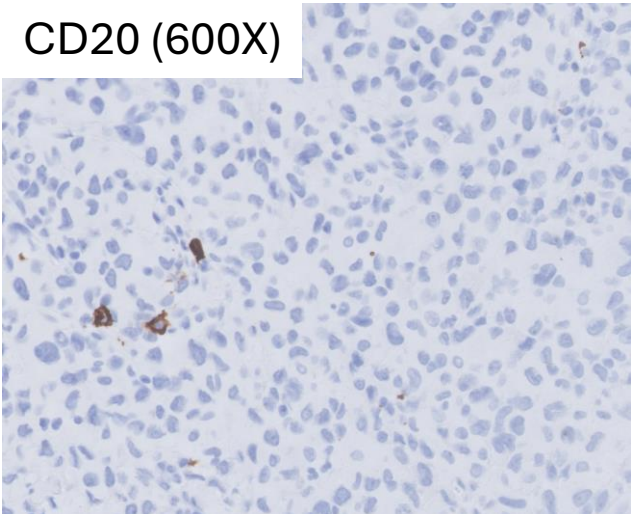


Oral Biopsy: IHC

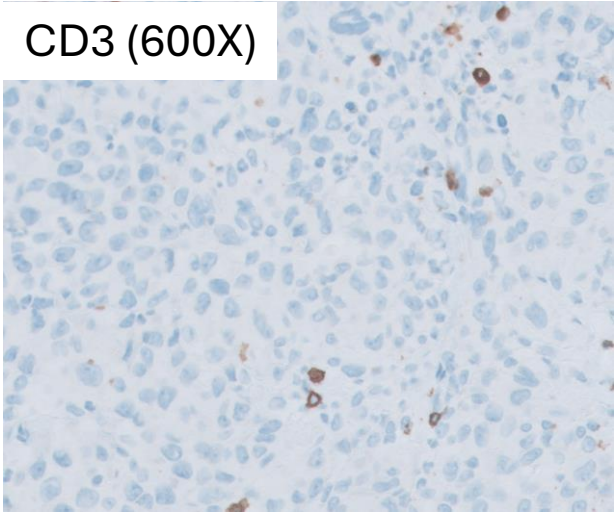
CKMIX (600X)



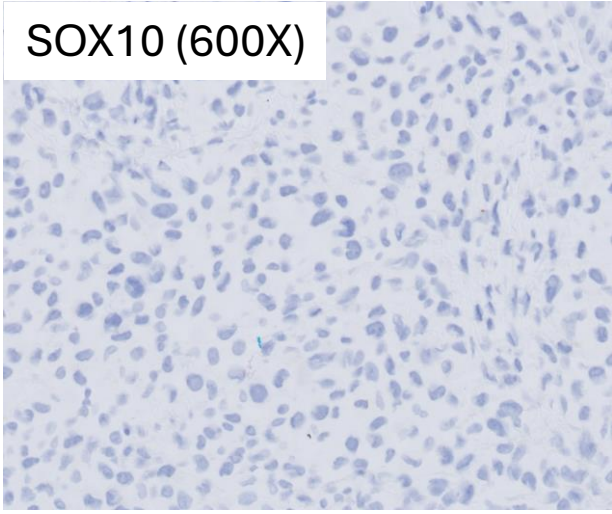
CD20 (600X)



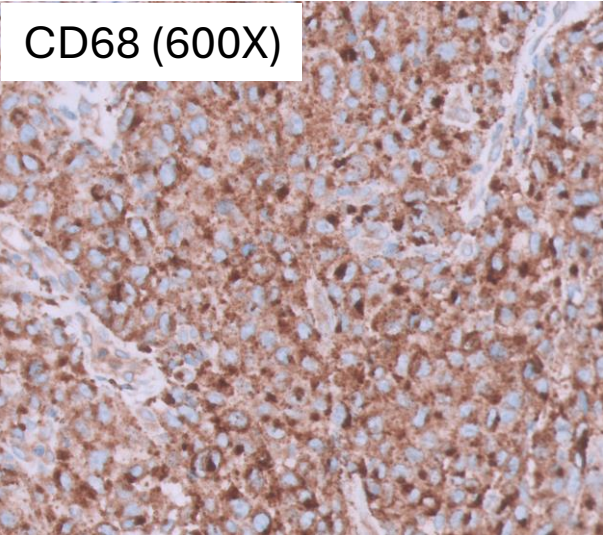
CD3 (600X)



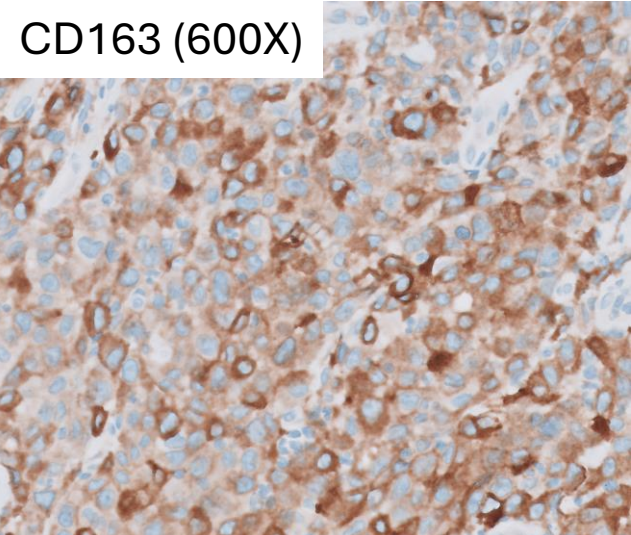
SOX10 (600X)



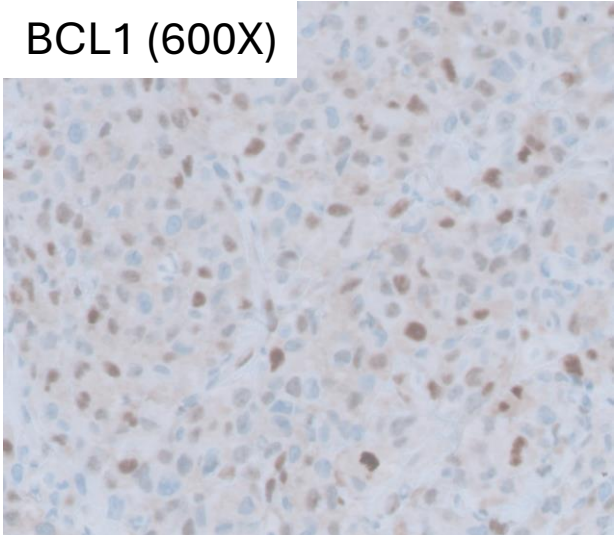
CD68 (600X)



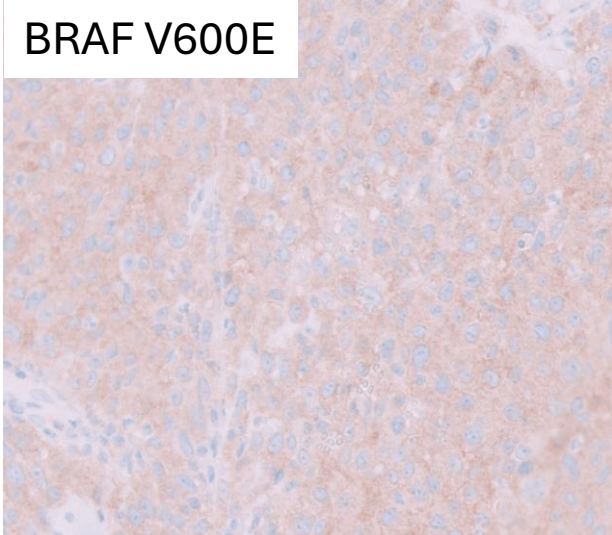
CD163 (600X)



BCL1 (600X)



BRAF V600E



DIAGNOSIS?

