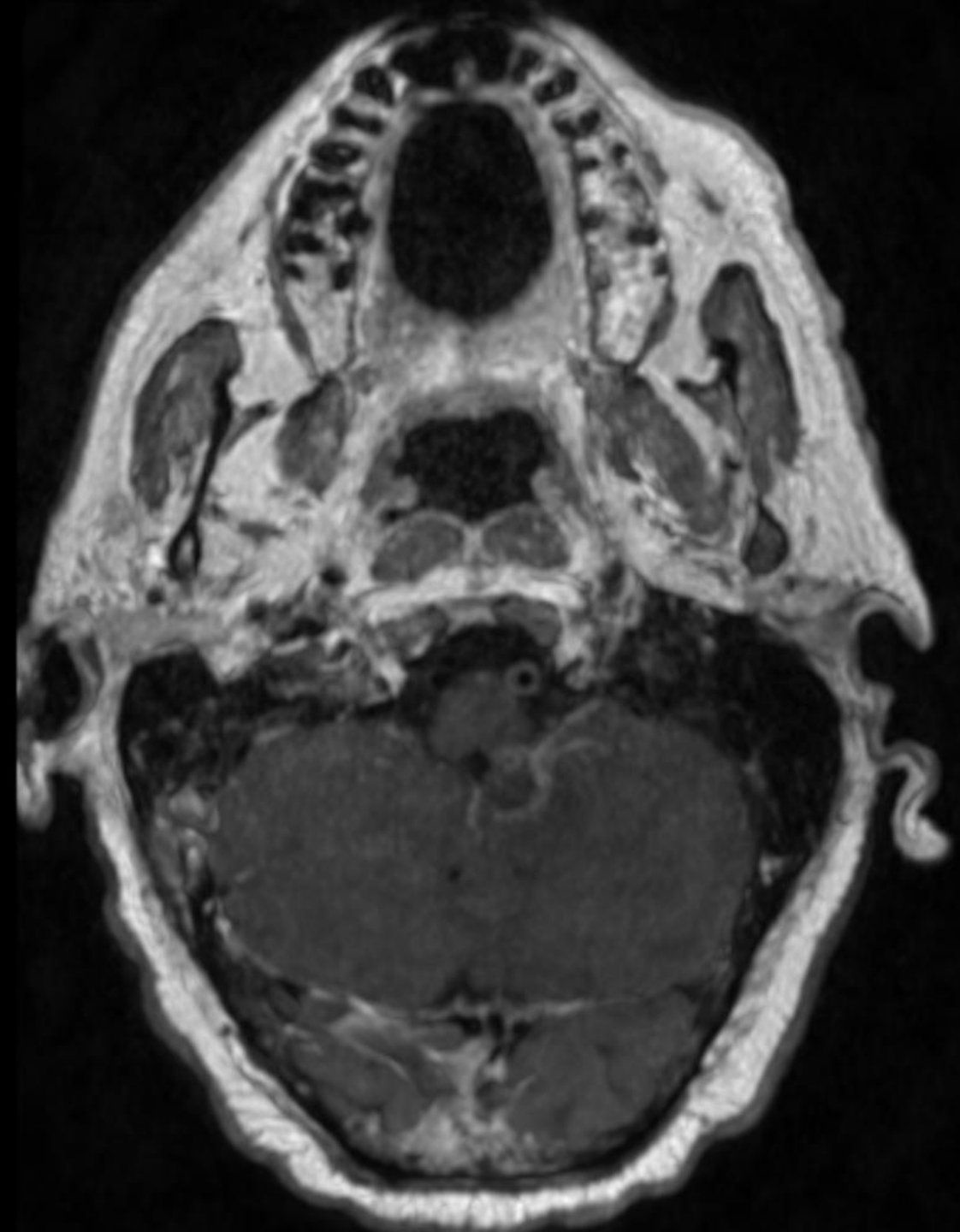
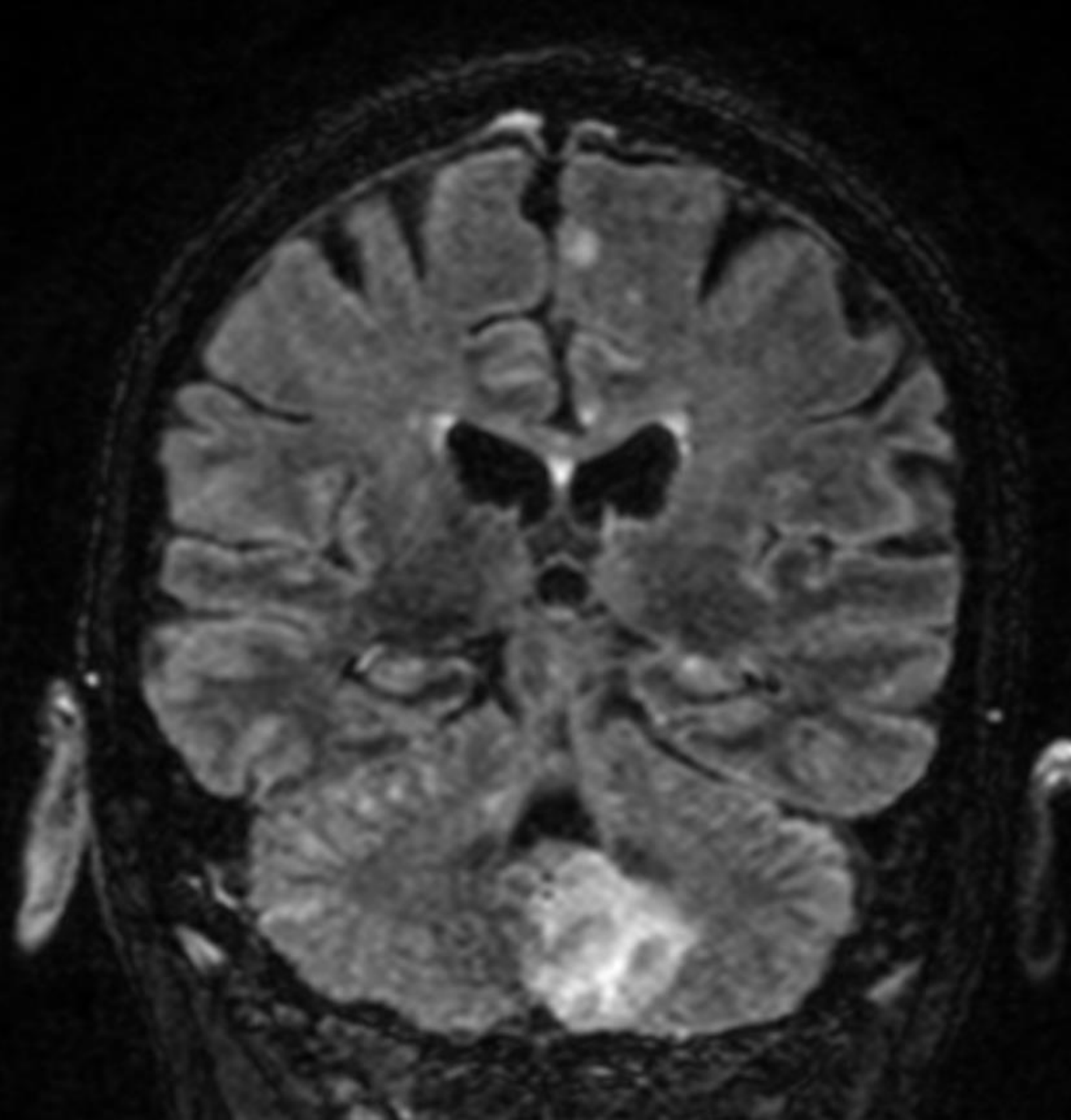


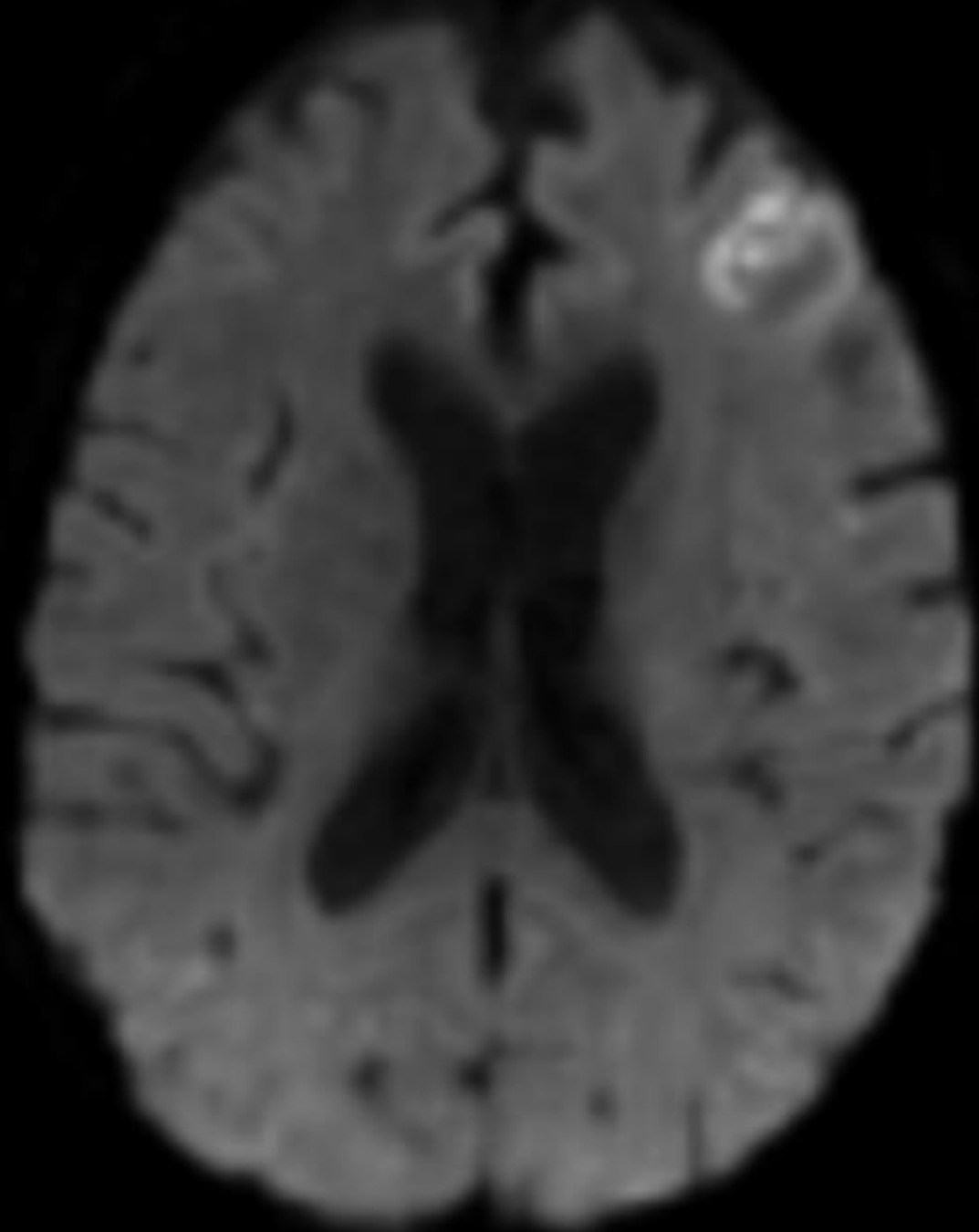
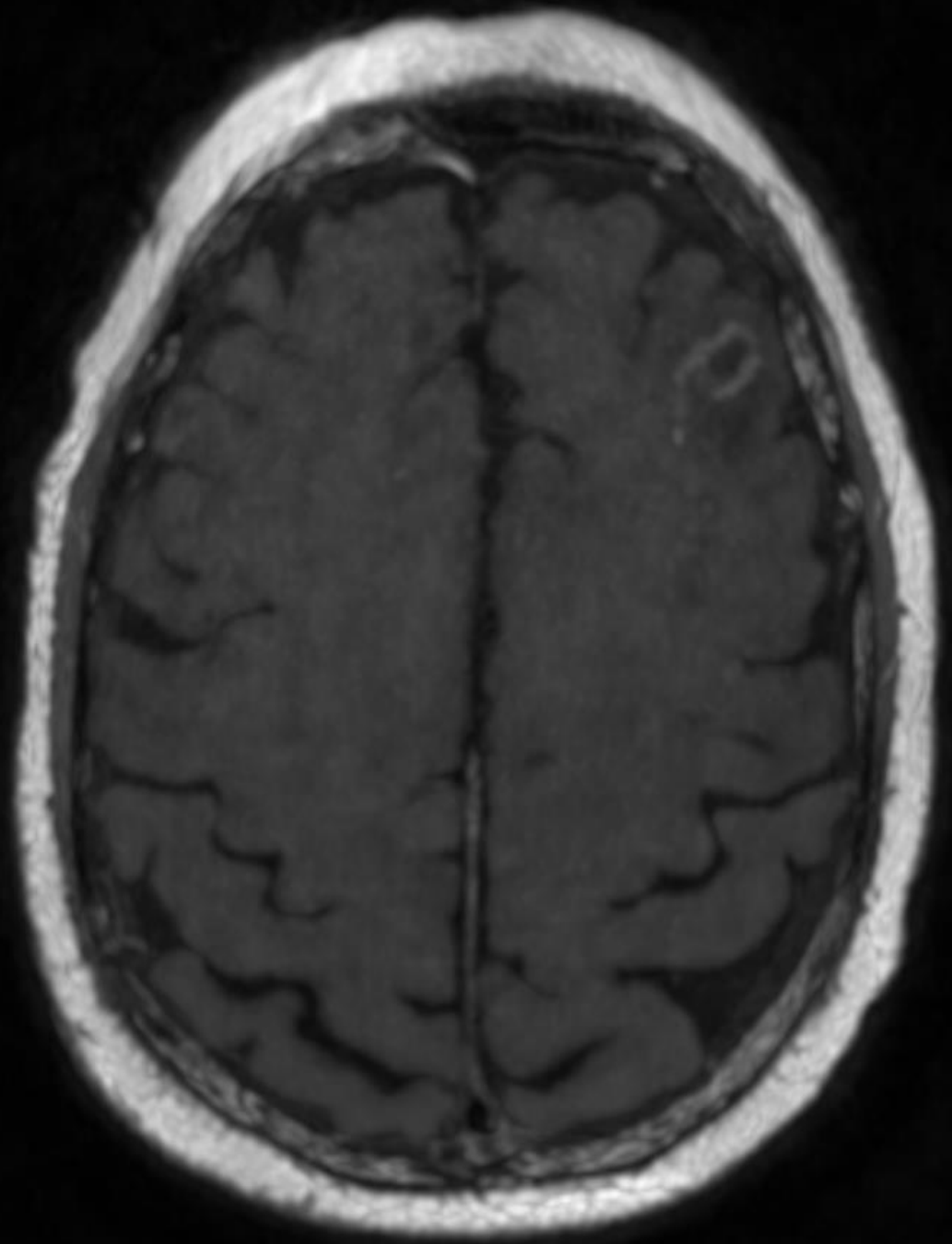
South Bay July 2024 Webcases

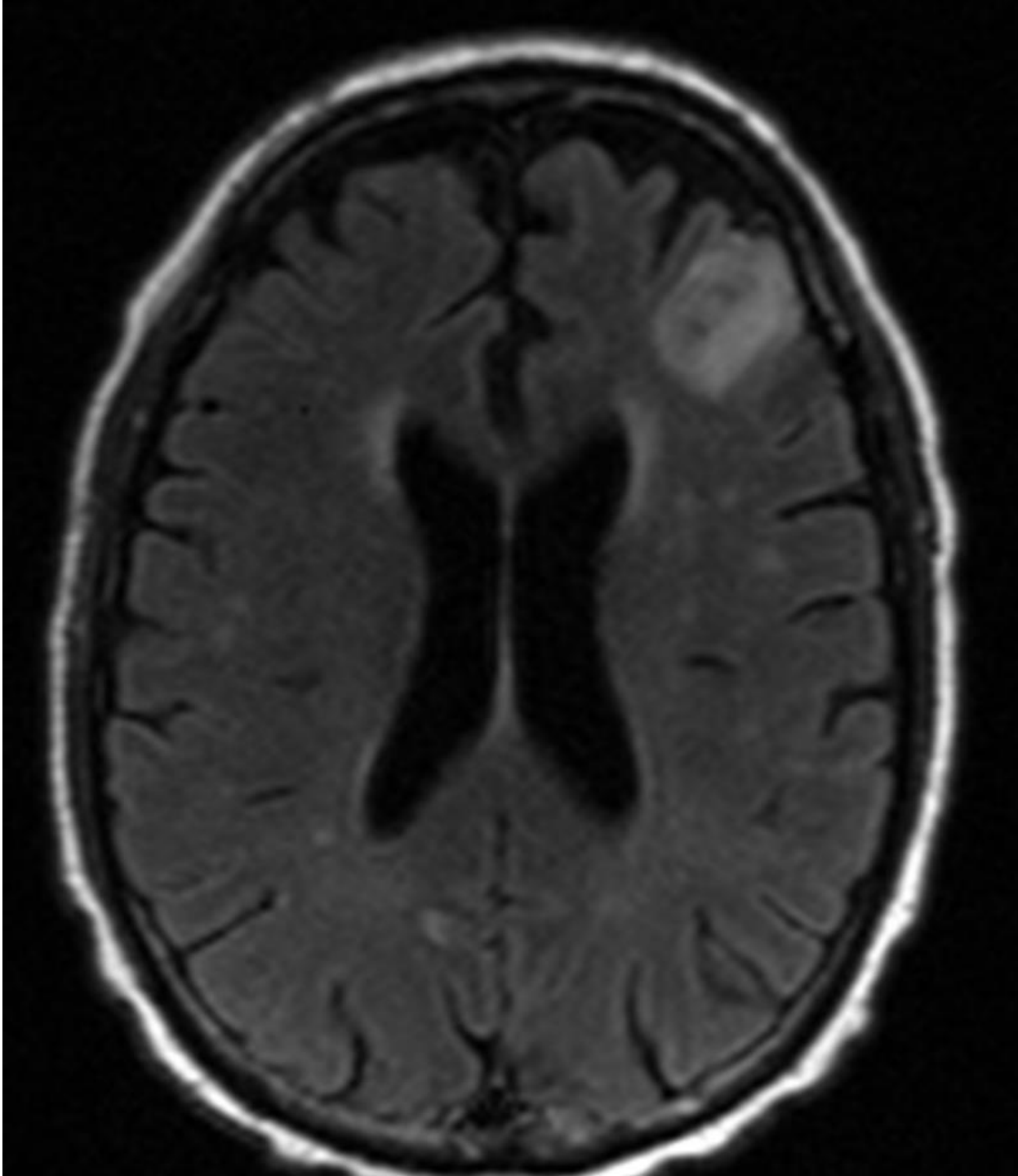
24-0701

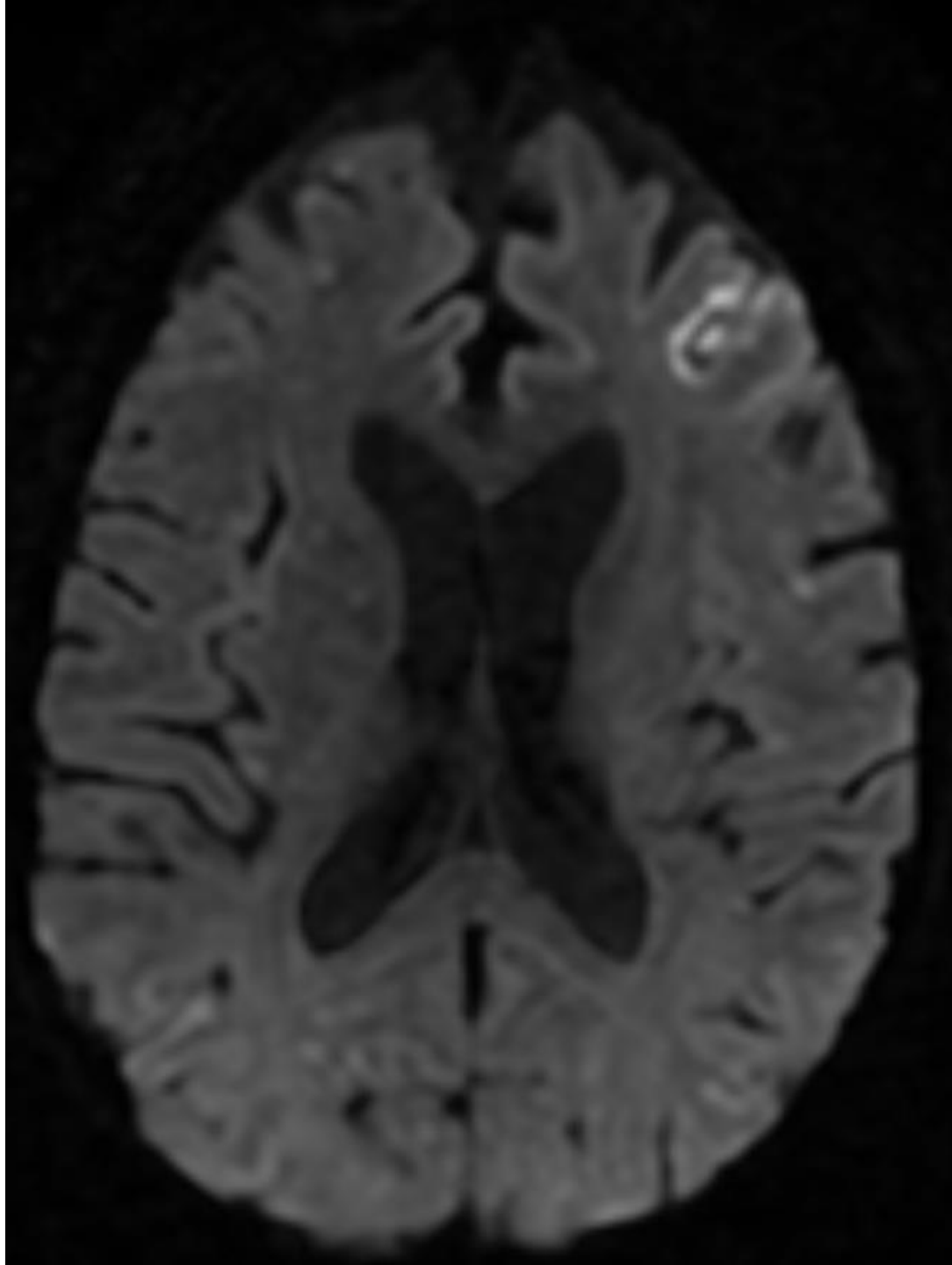
**Adebola Adeniyi, Lisa Friedman, Sebastian Fernandez-Pol;
Stanford**

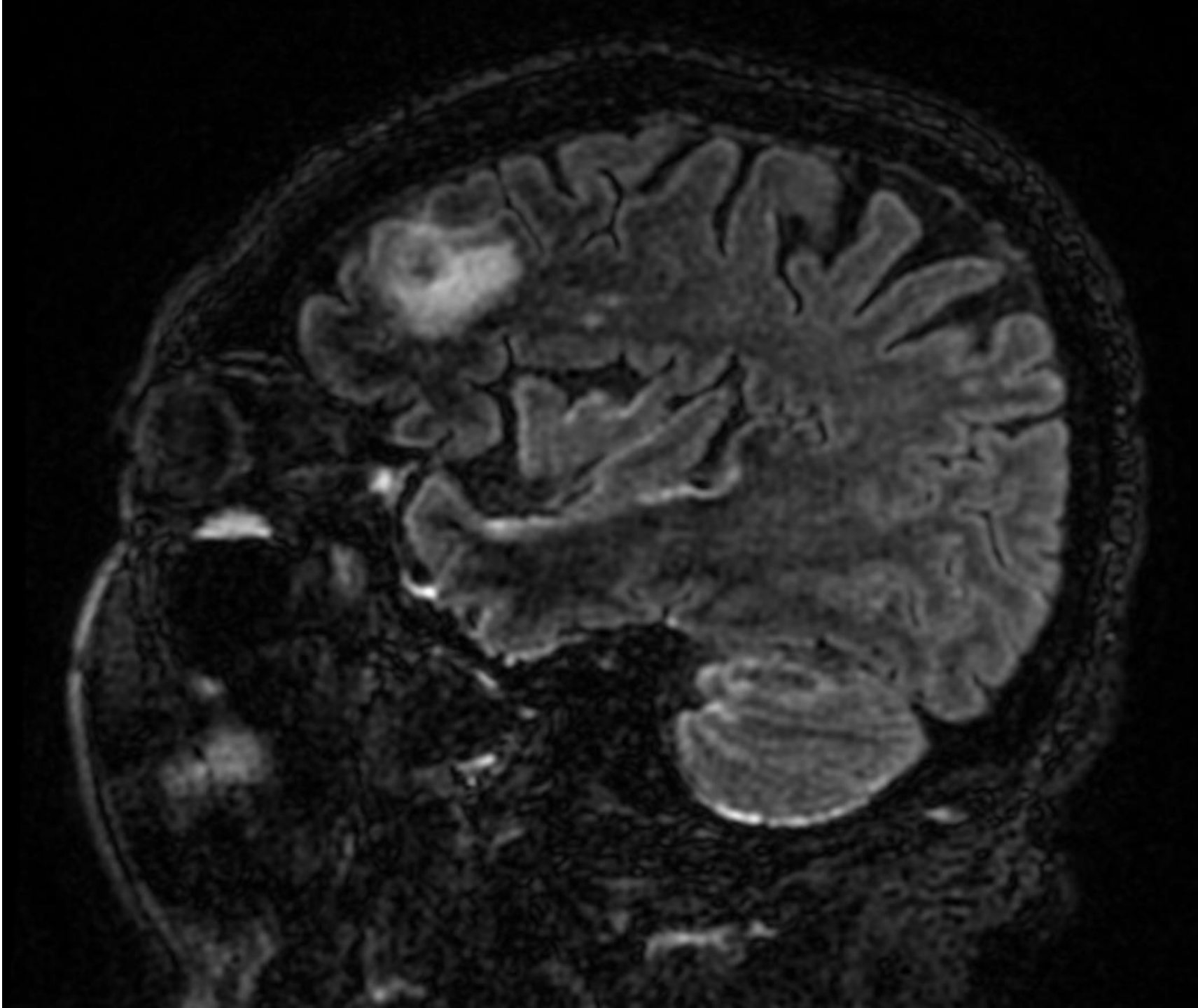
67Y male with PMHx of HTN, MM s/p auto transplant in 2020 with maintenance therapy c/b therapy-related B-ALL and t-MN s/p therapy, now admitted for haploidentical transplant on 4/23/24. Stroke code on 5/30 for AMS. MRI with enhancing left frontal and left cerebellar lesions. Neurocritical Care consulted for AMS and c/f meningoencephalitis vs malignancy.

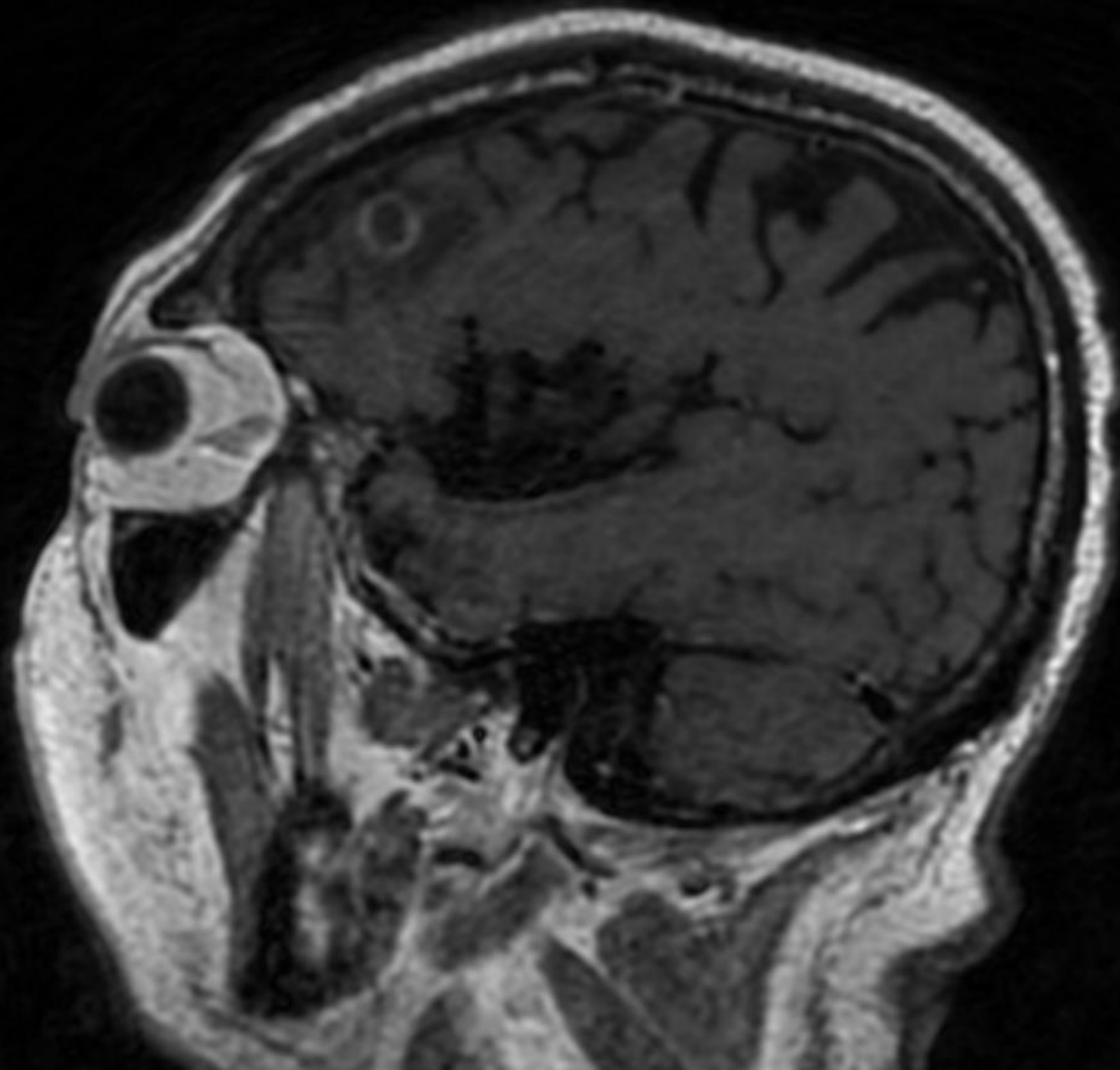


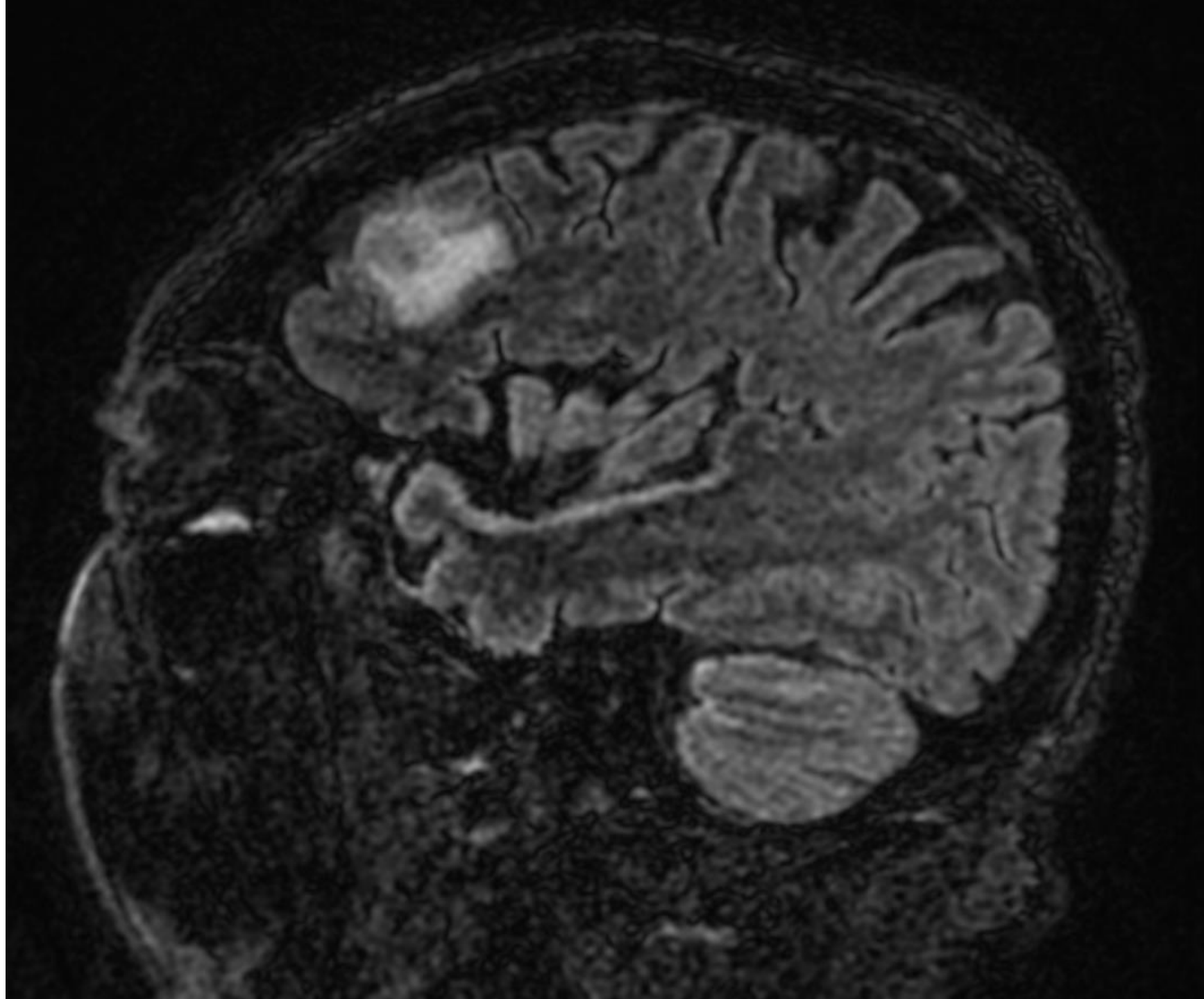


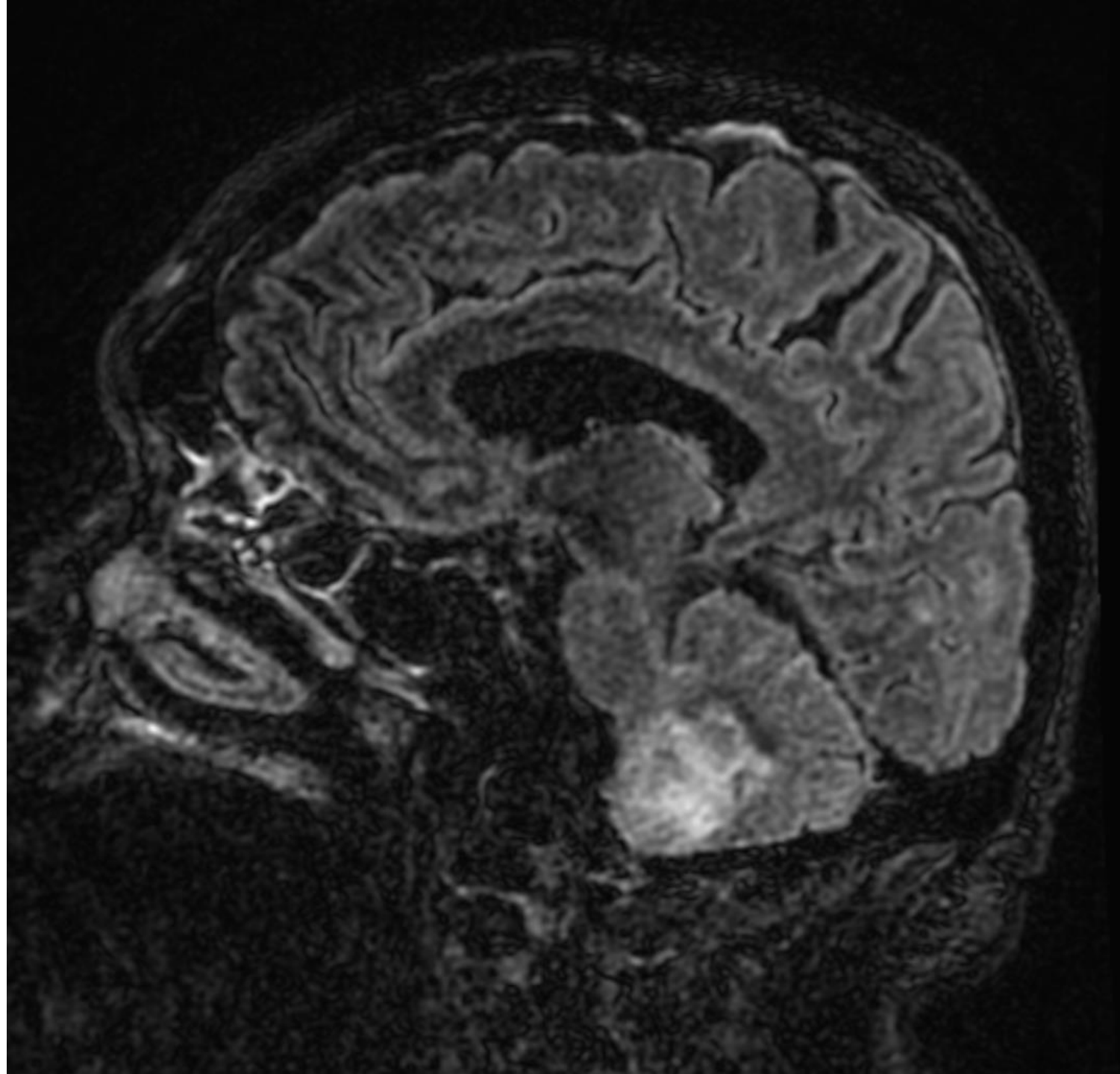


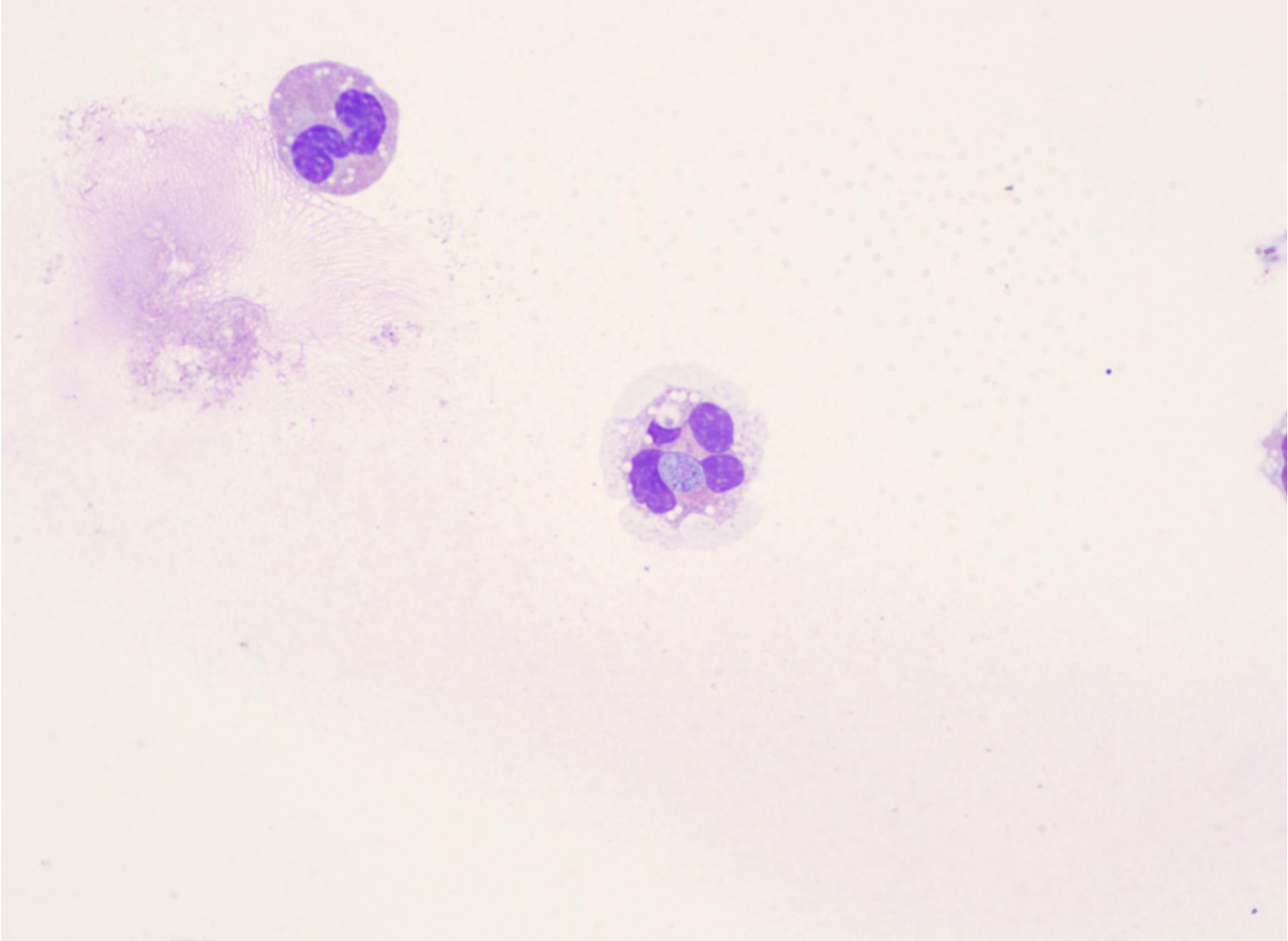


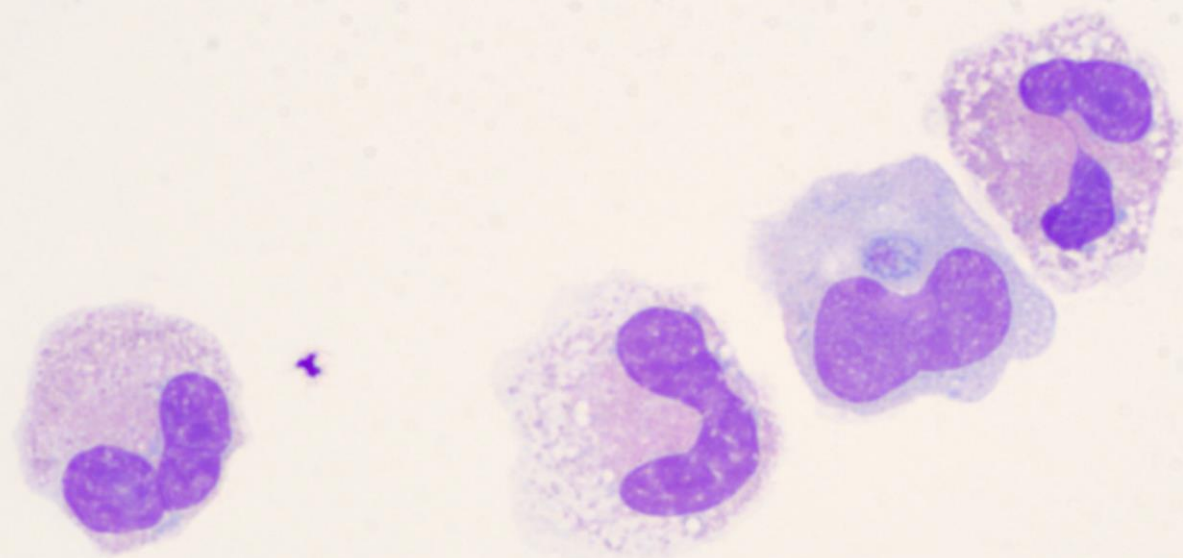


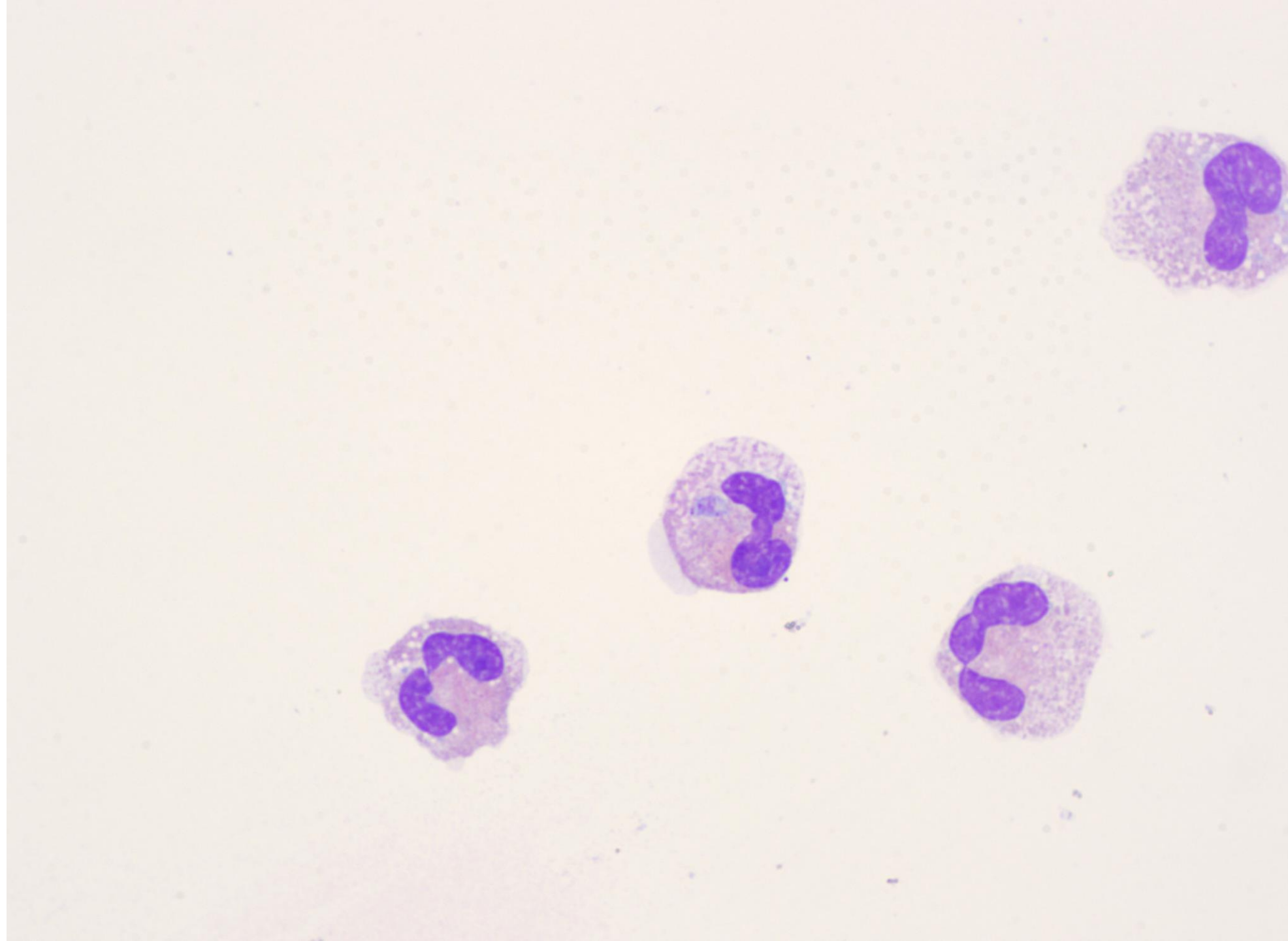


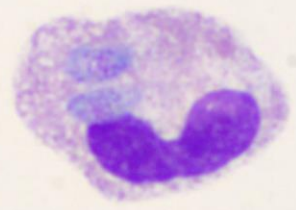
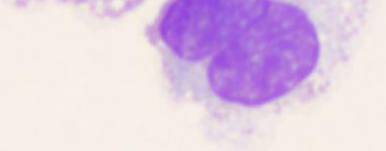
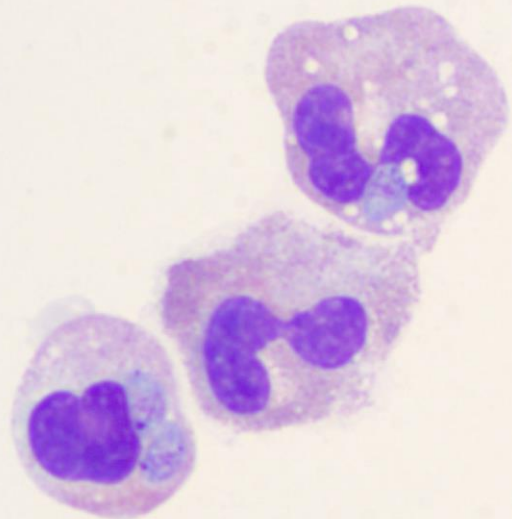


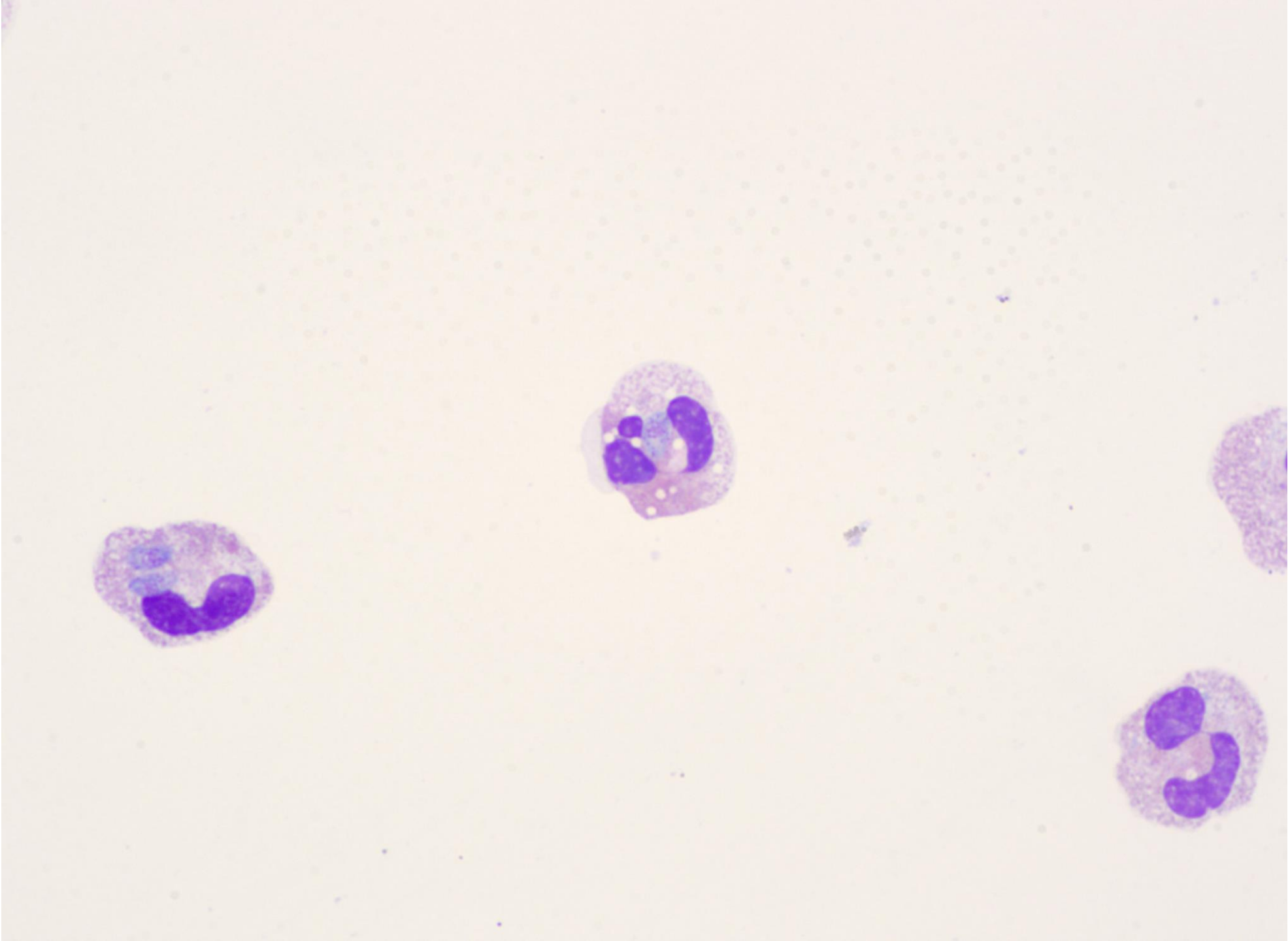


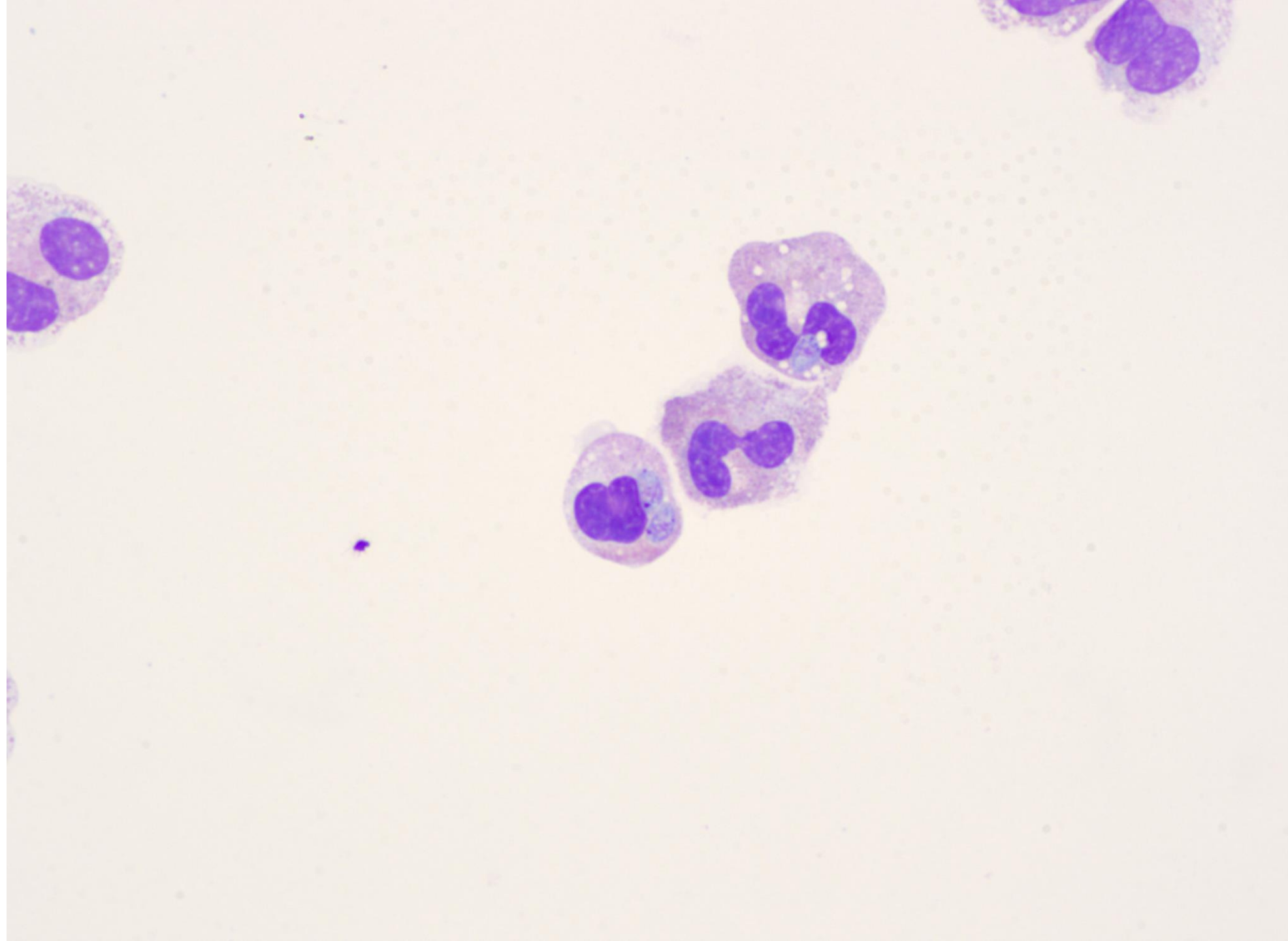


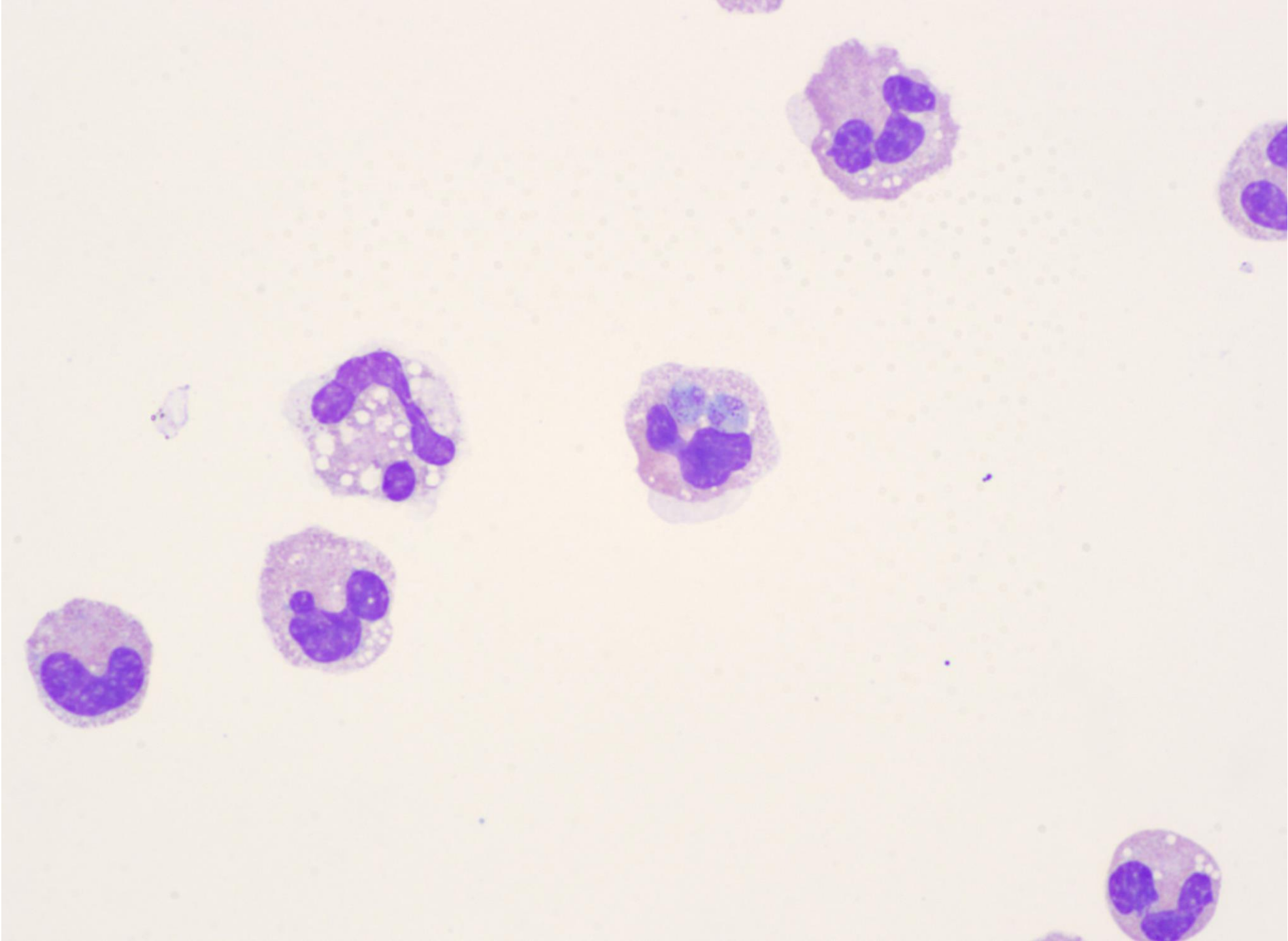


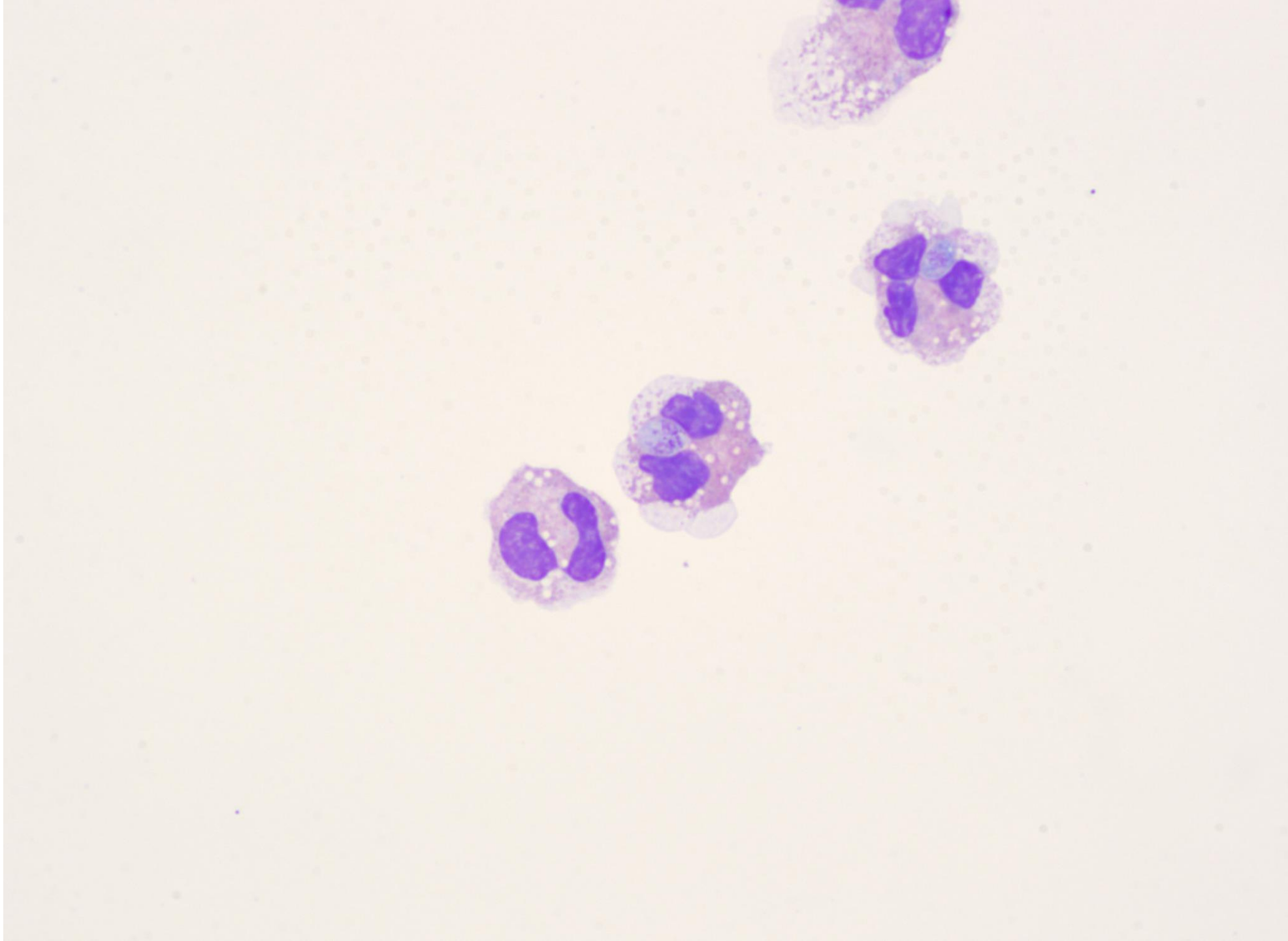


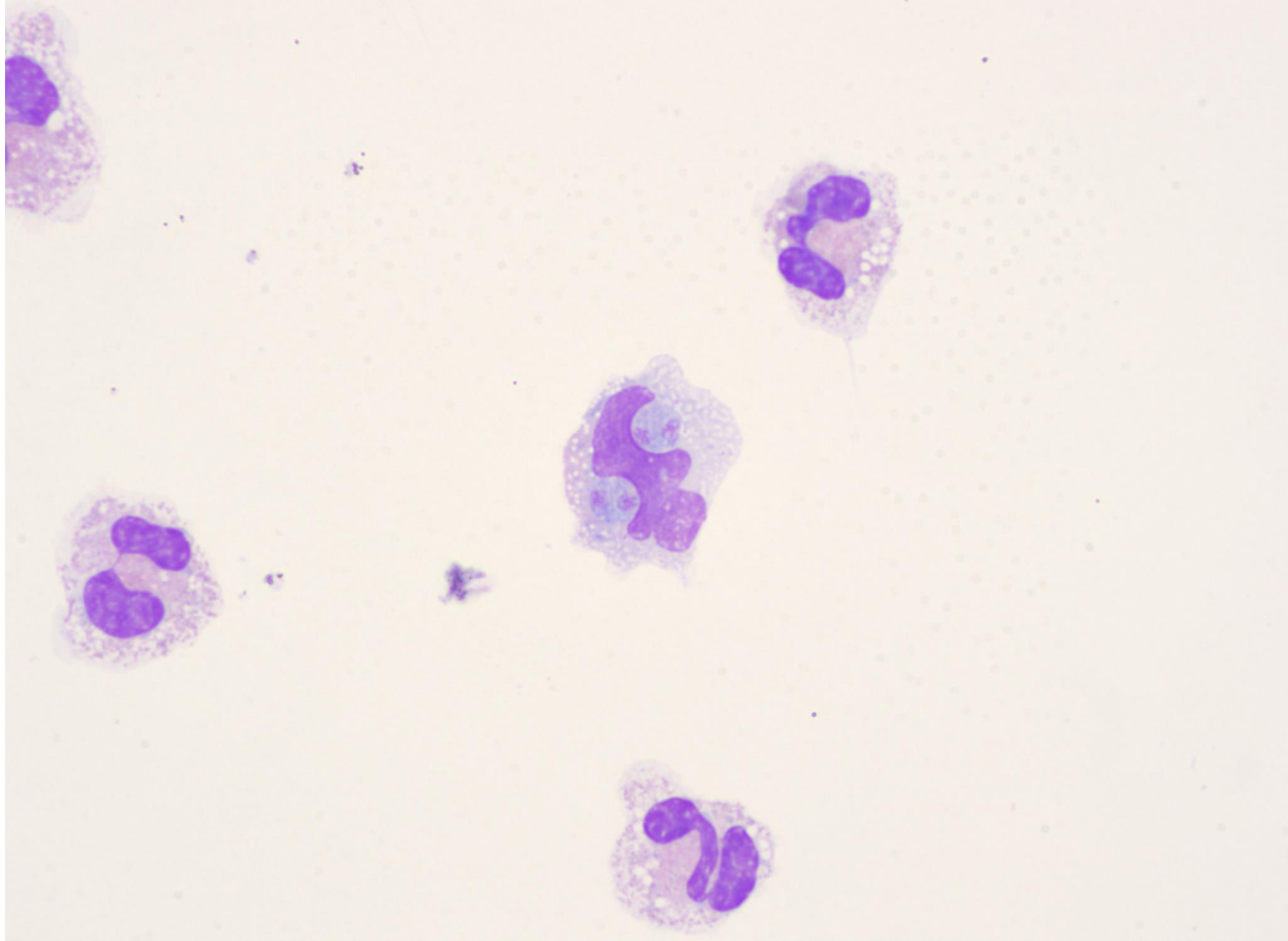












DIAGNOSIS?

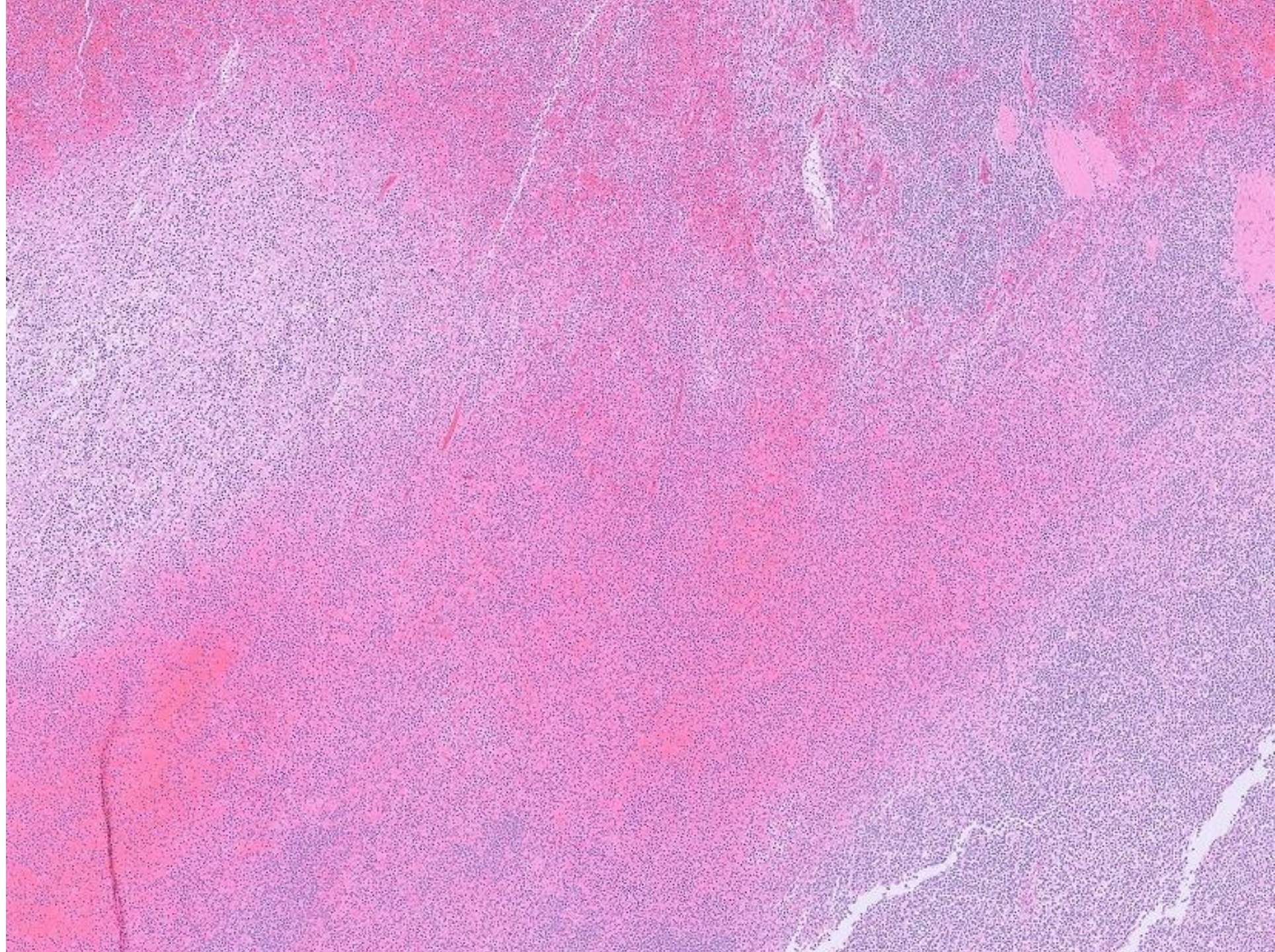

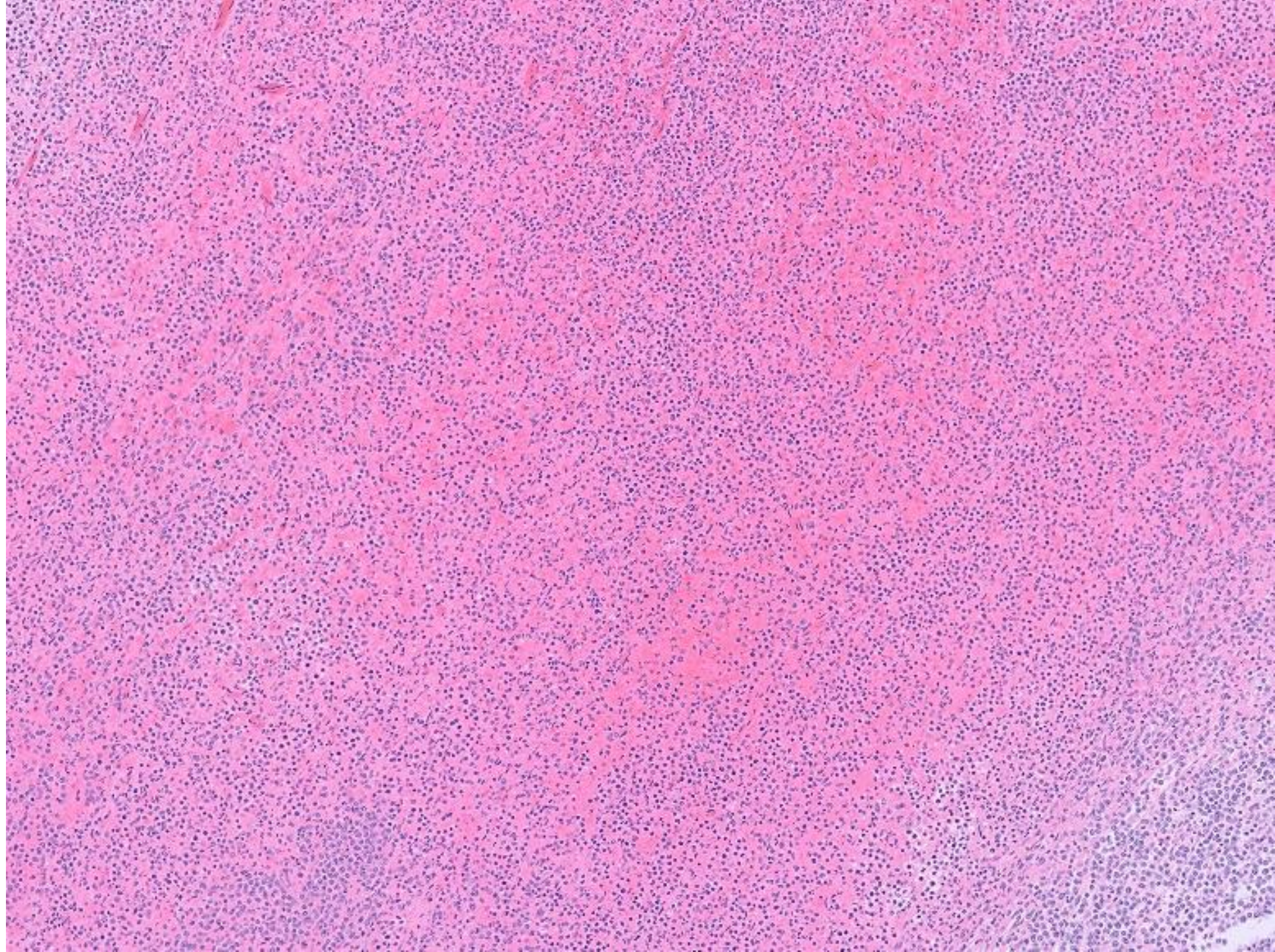
24-0702

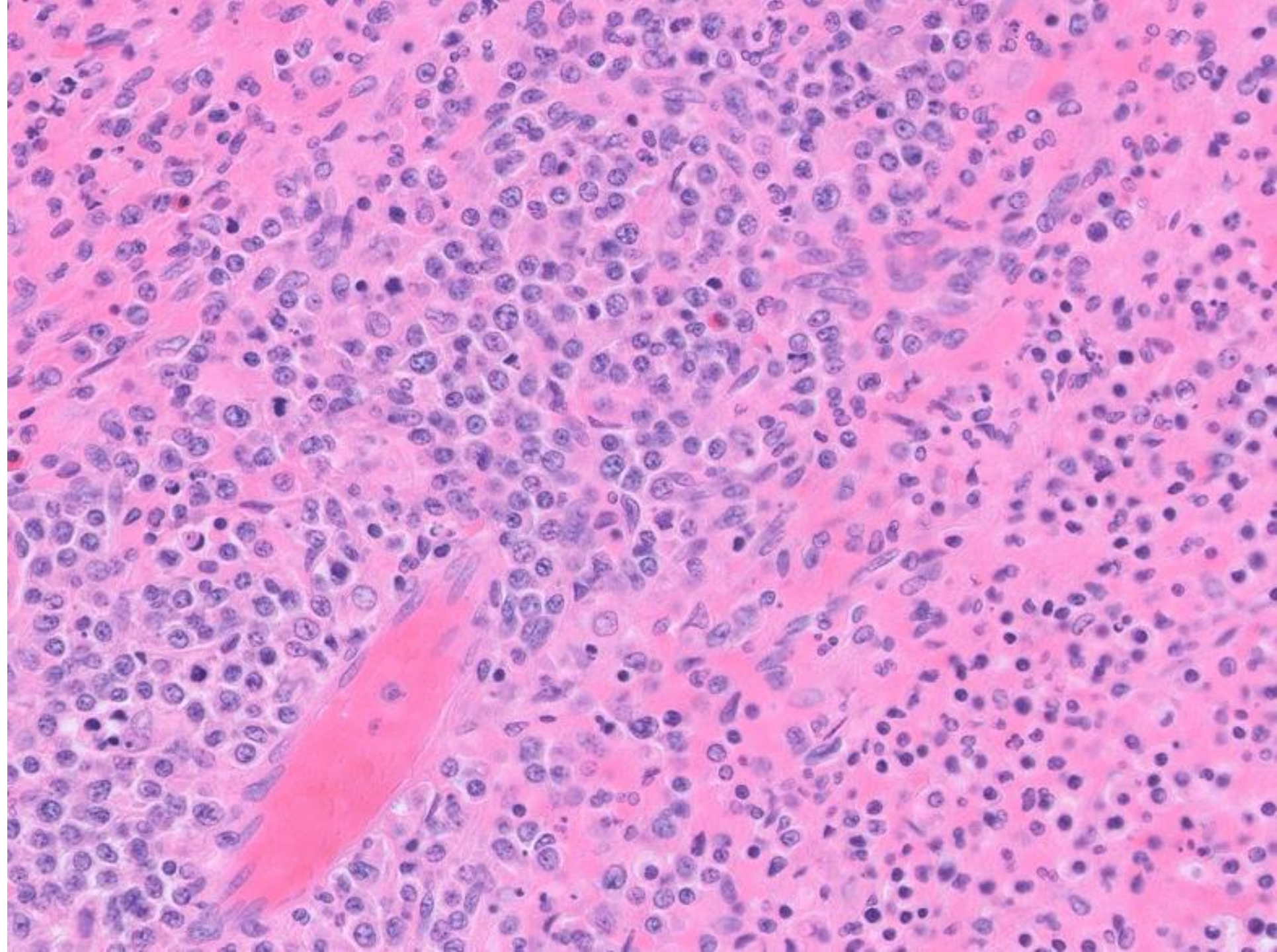
Andrew Xiao and Karthik Ganapathi; UCSF

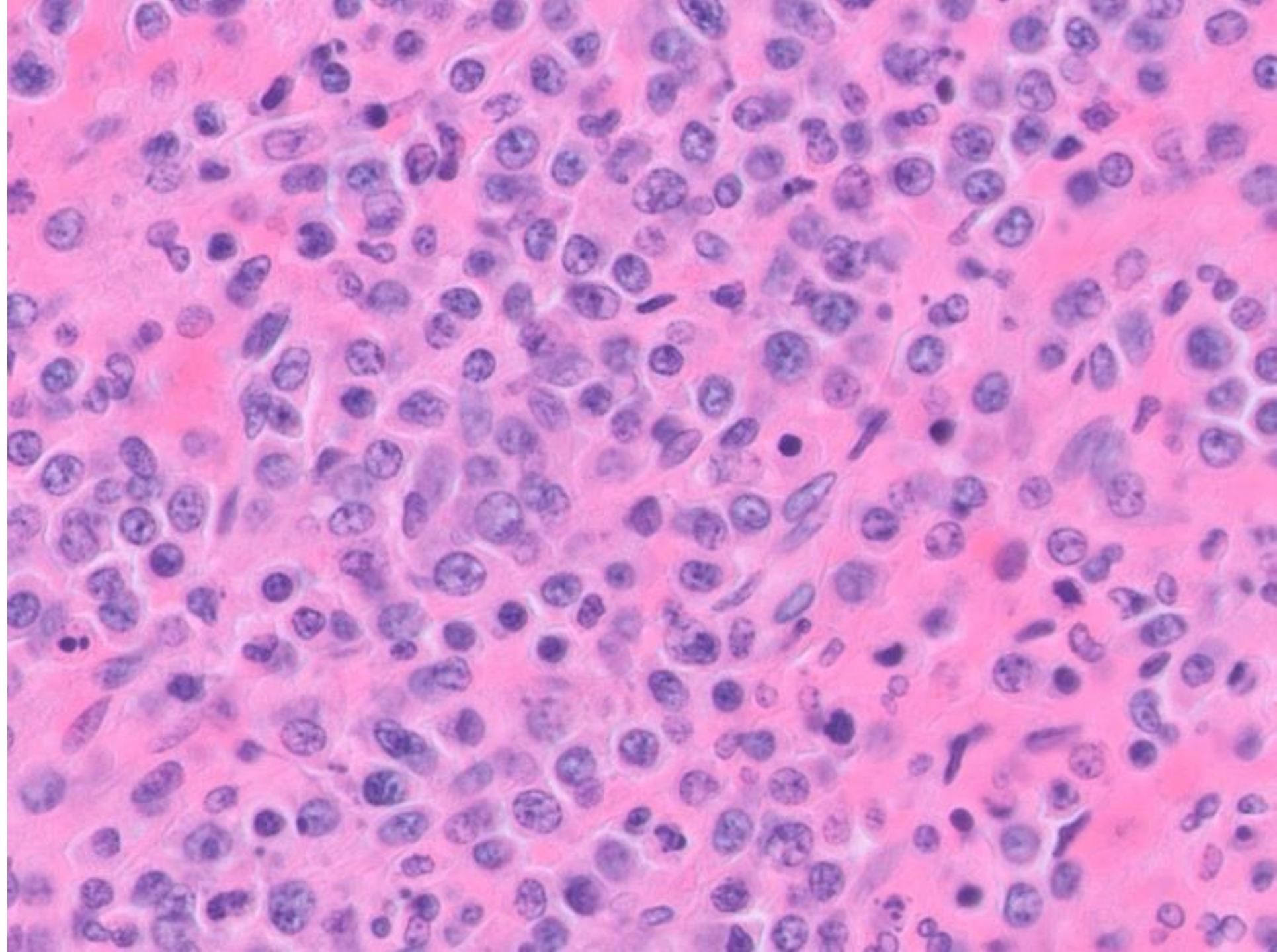
24 year old male with scrotal pain and was found to have thrombocytopenia, neutropenia, and massive splenomegaly on imaging.

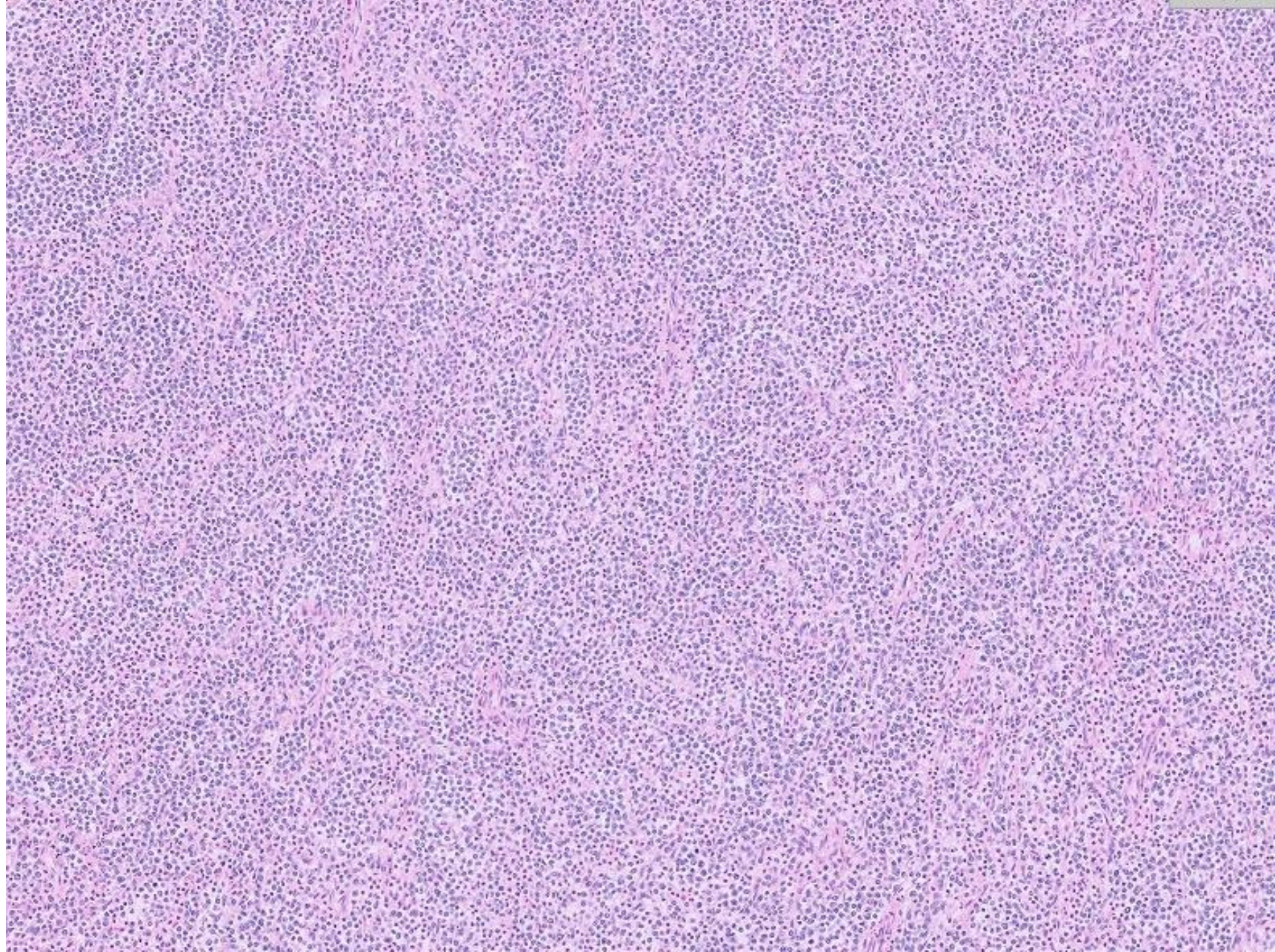Spleen

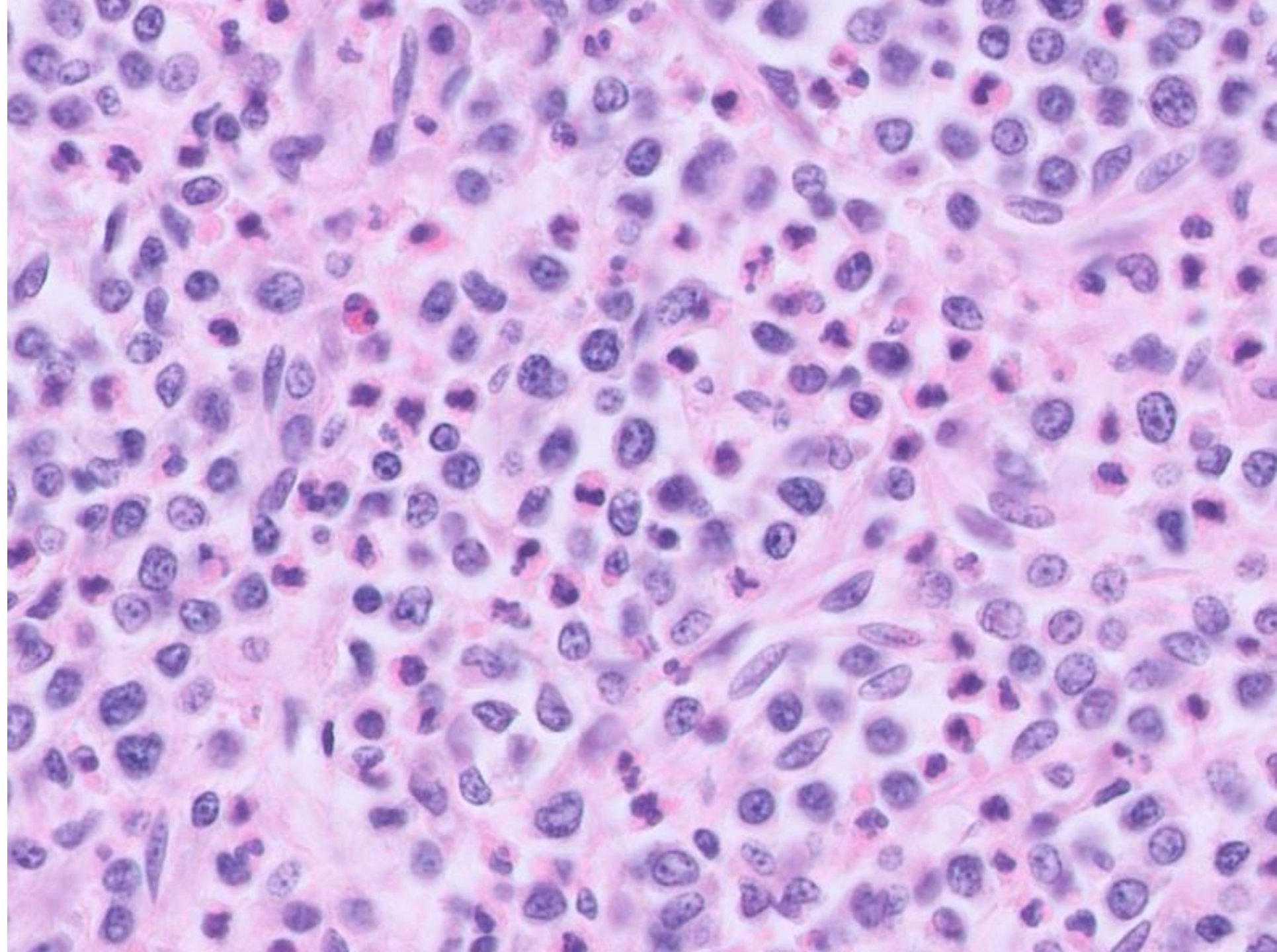




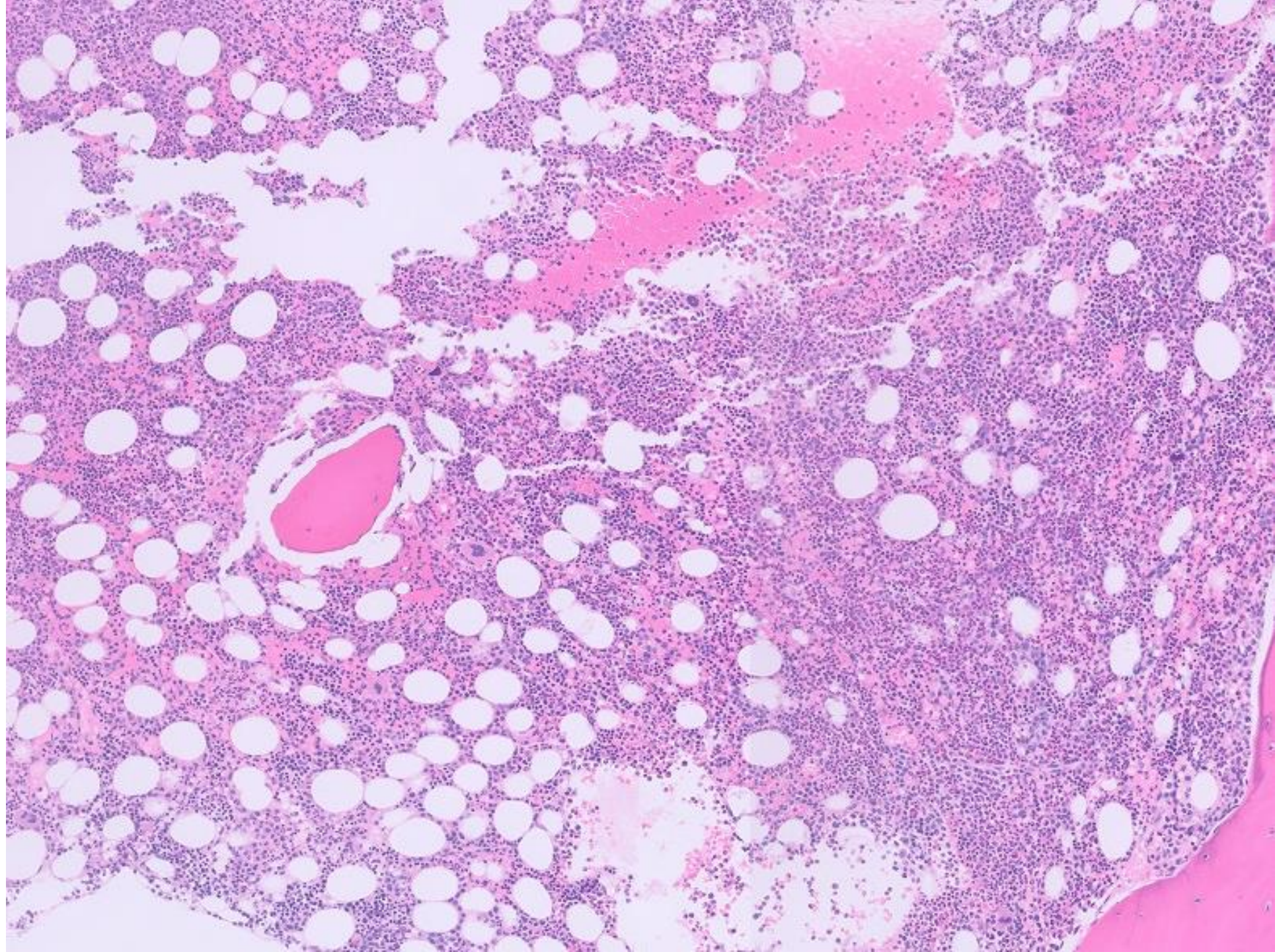


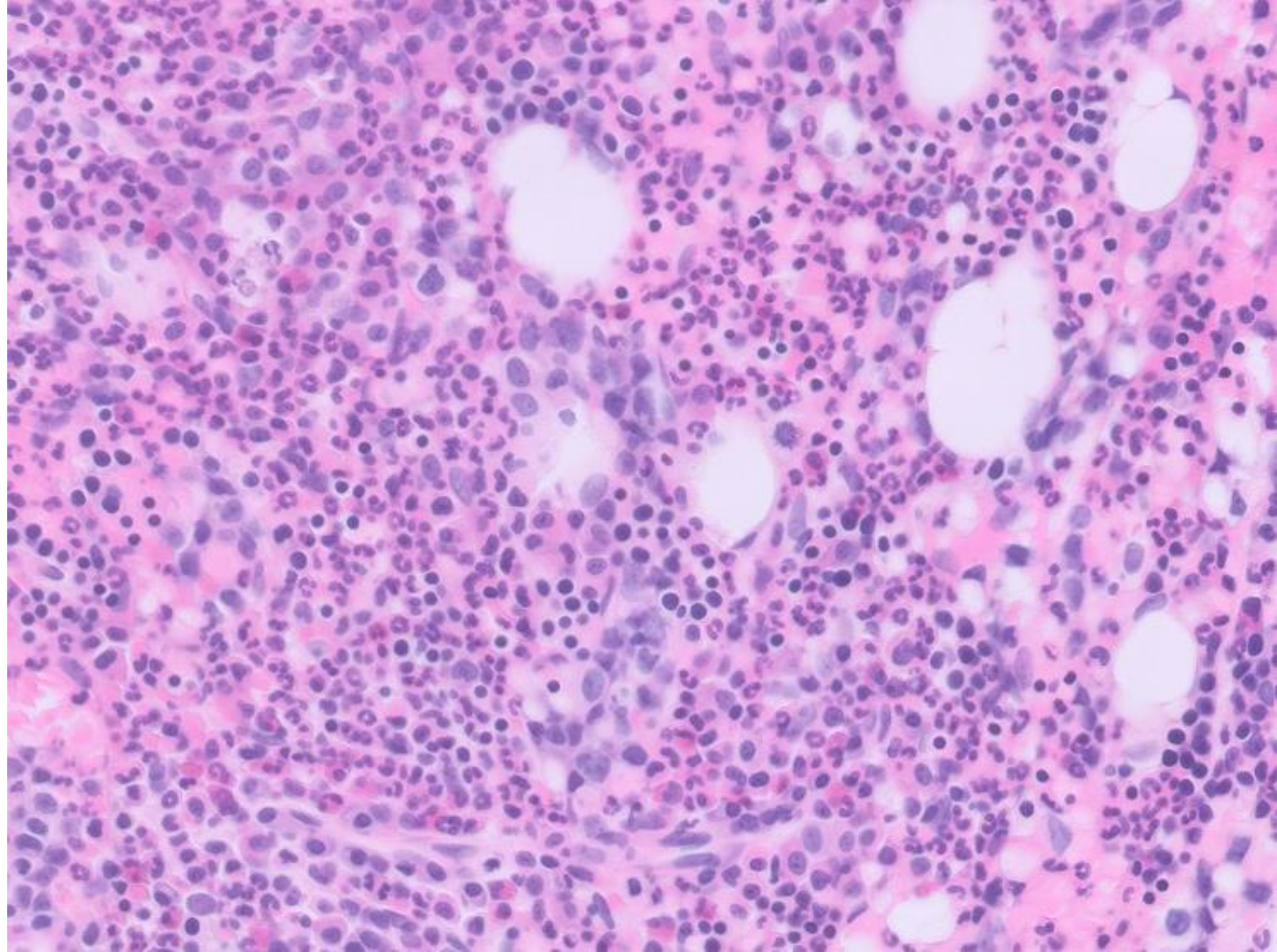


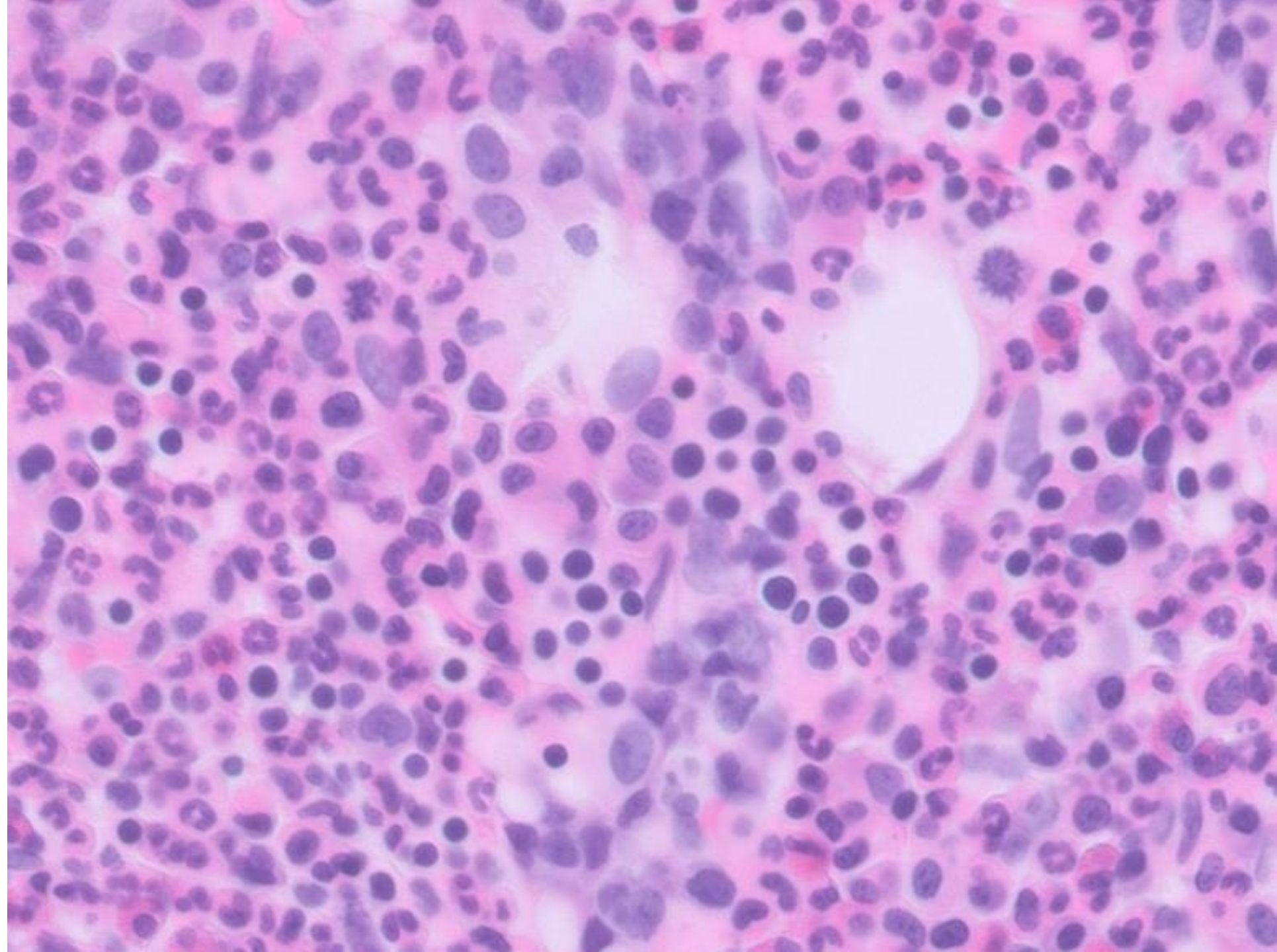




Bone Marrow







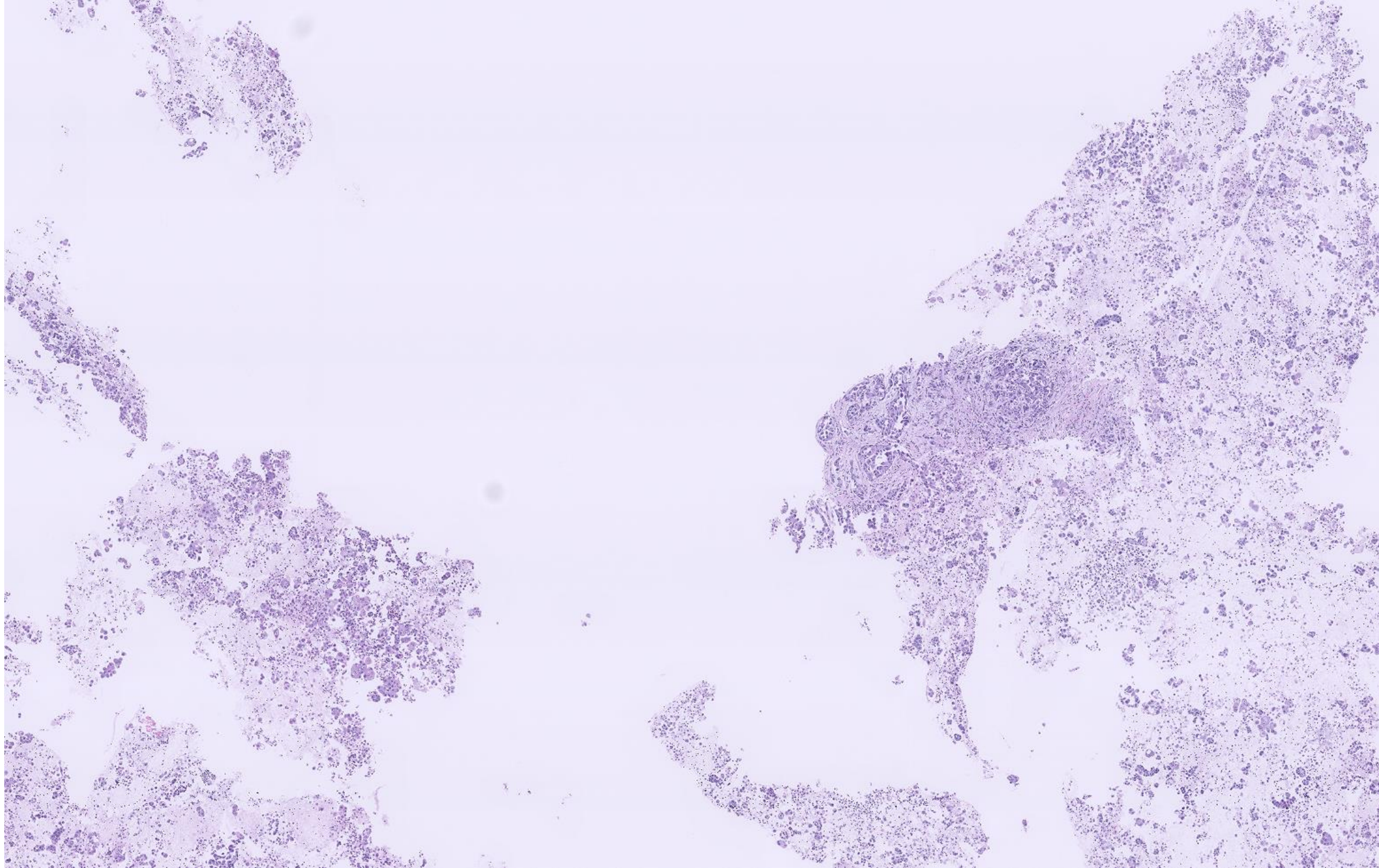DIAGNOSIS?

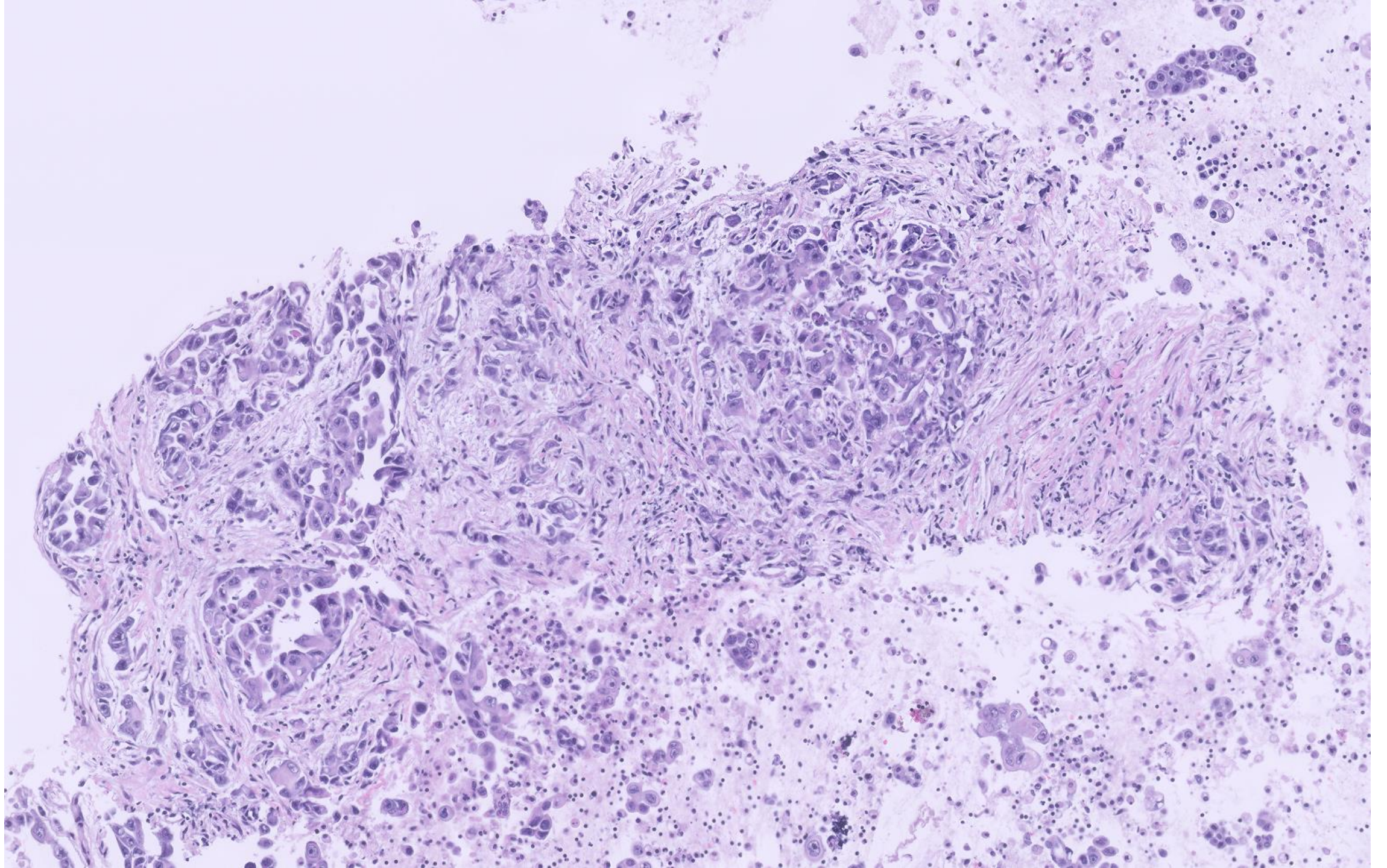


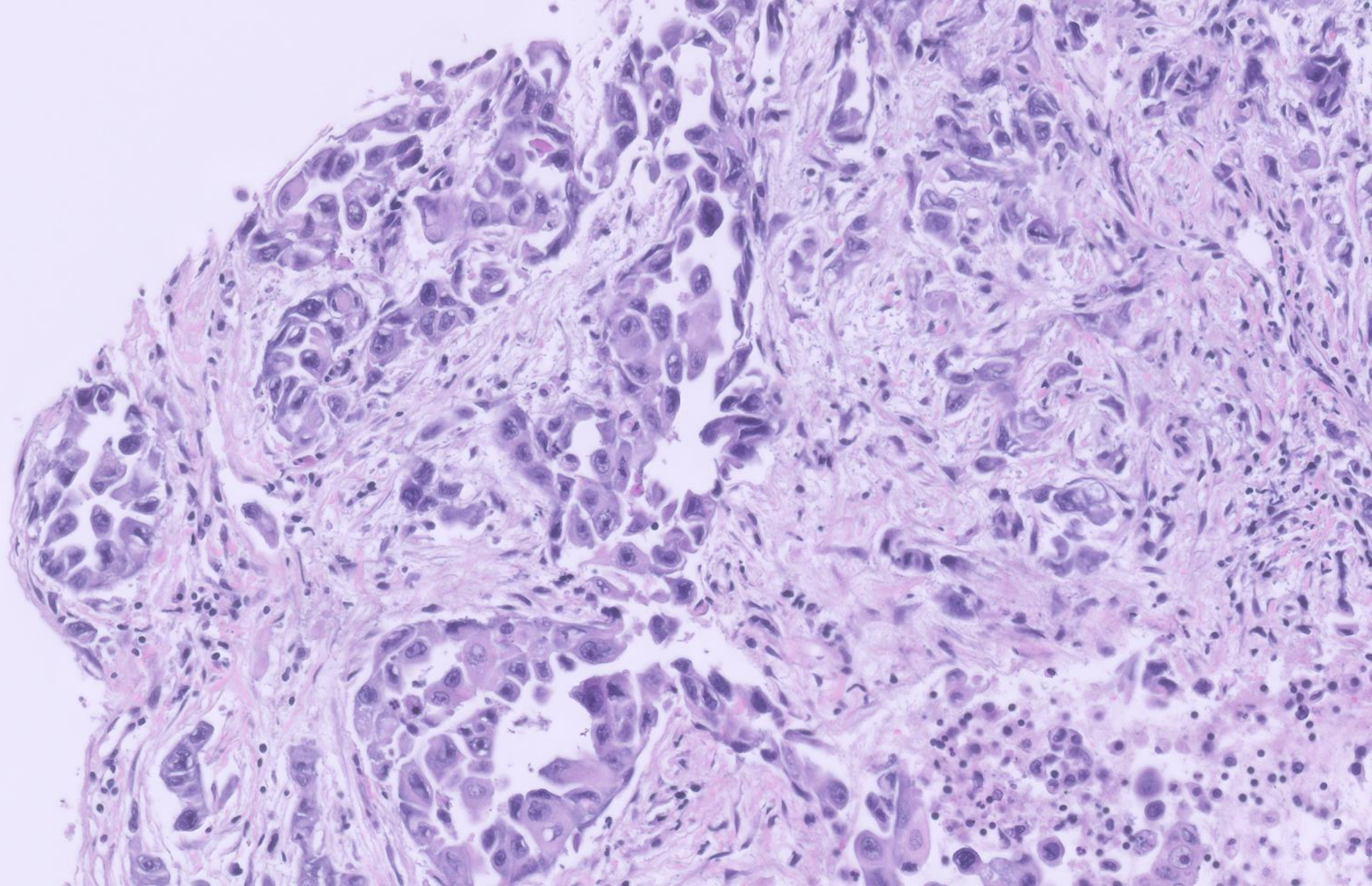
24-0703

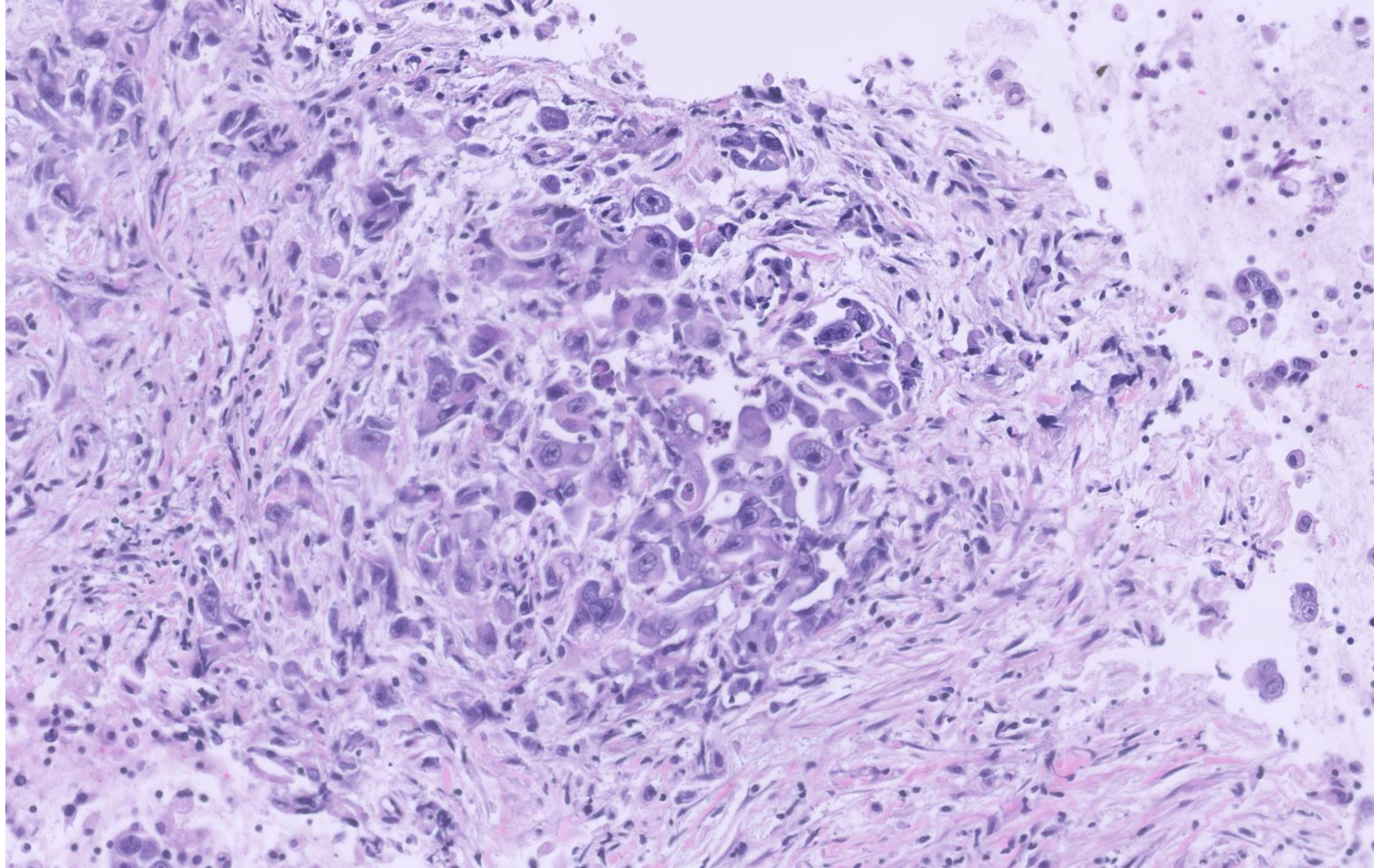
Douglas Wu, Ankur Sangoi; Stanford

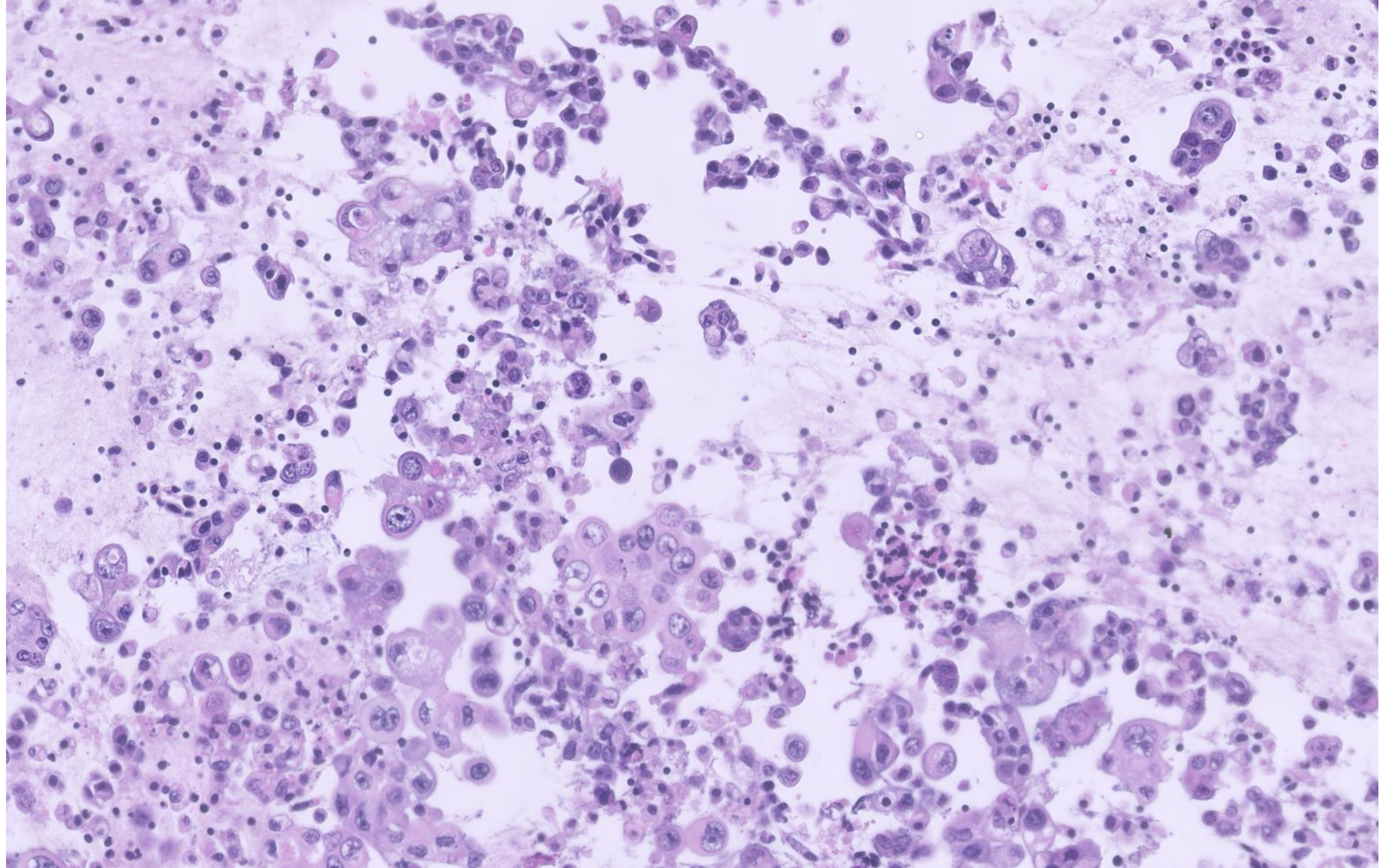
Teenage male who presented with a 5.5cm right kidney mass as well as mediastinal/hilar lymphadenopathy and multiple pulmonary nodules seen on imaging. A hilar lymph node was biopsied











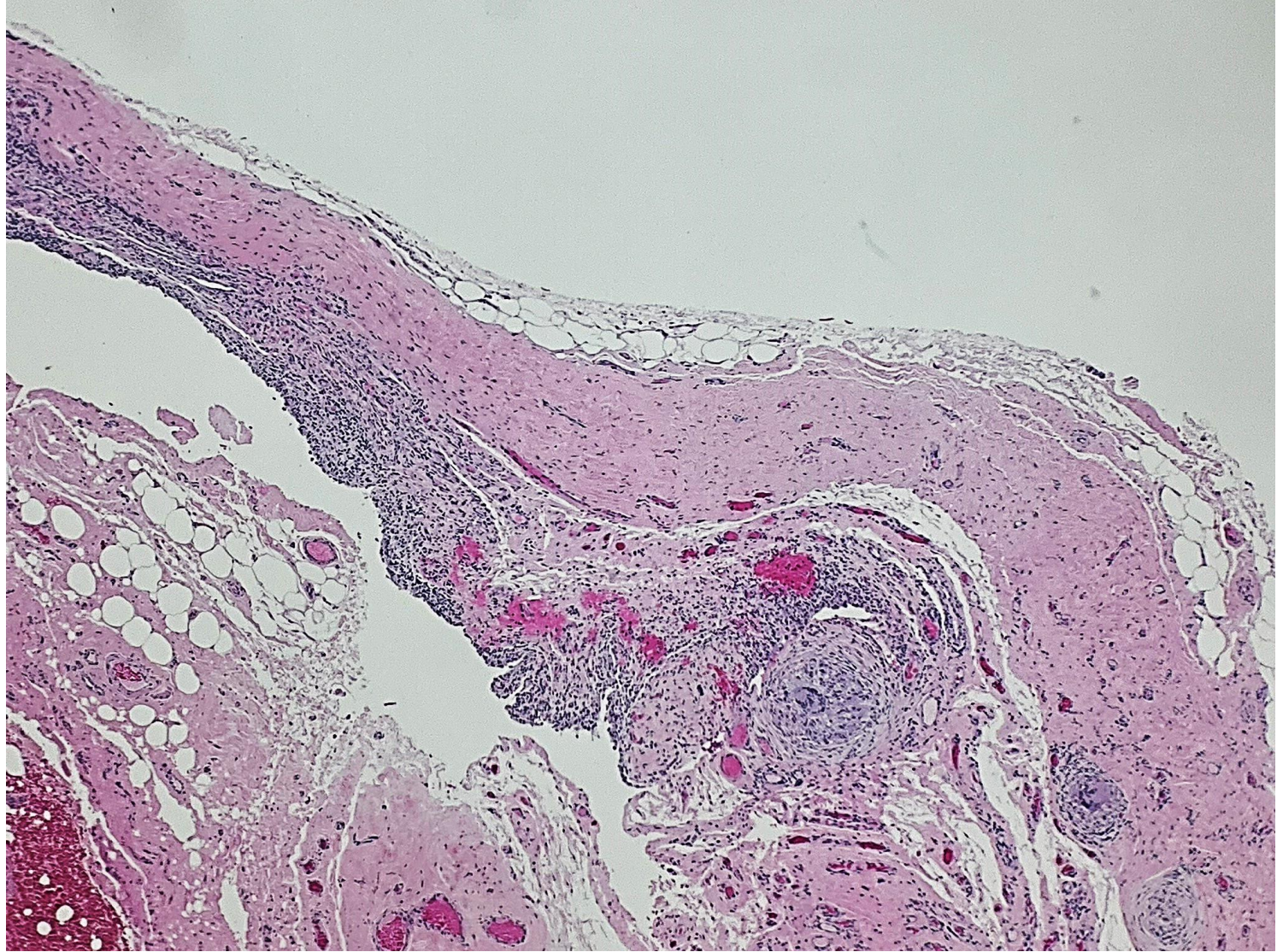
DIAGNOSIS?

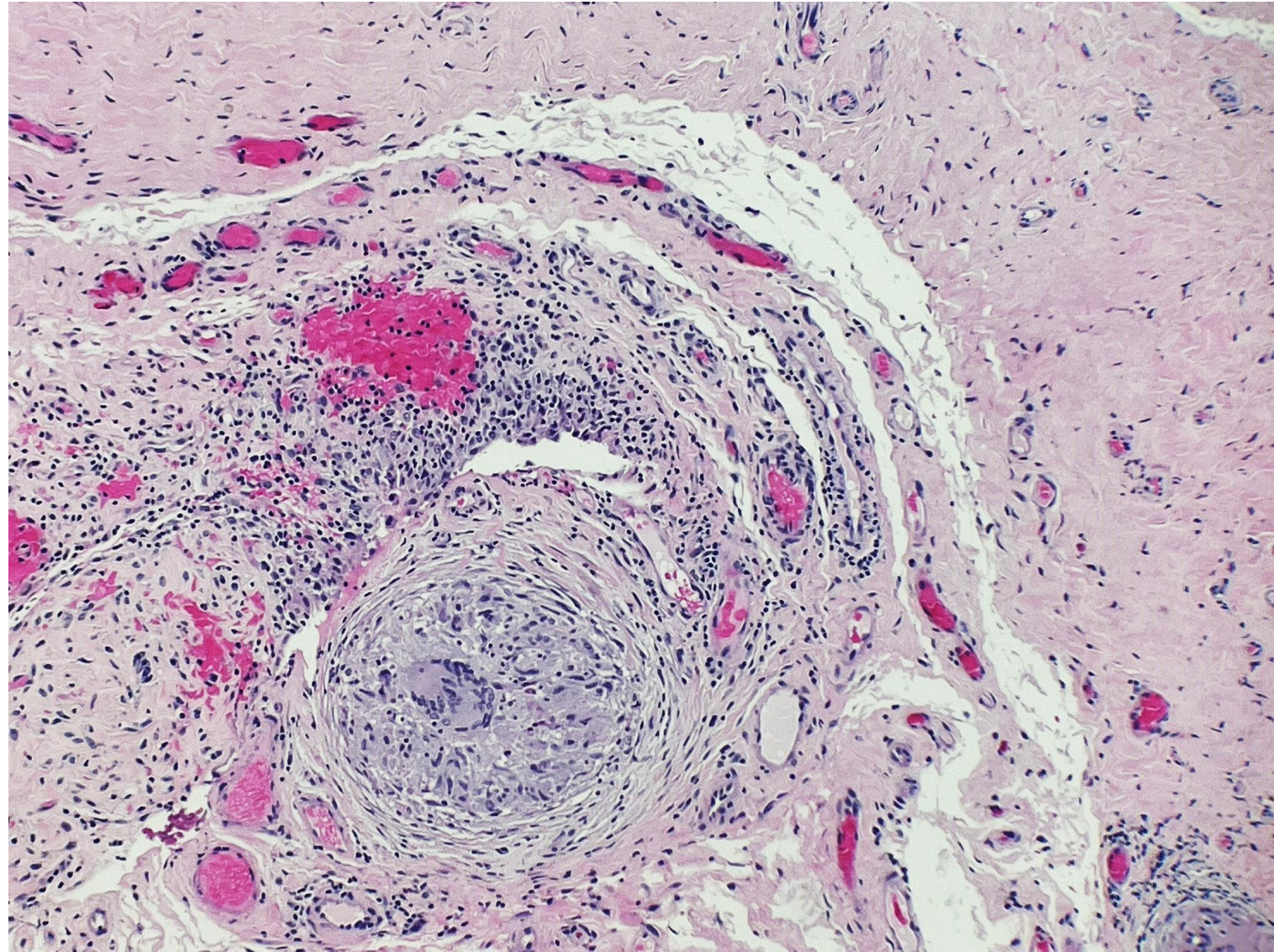


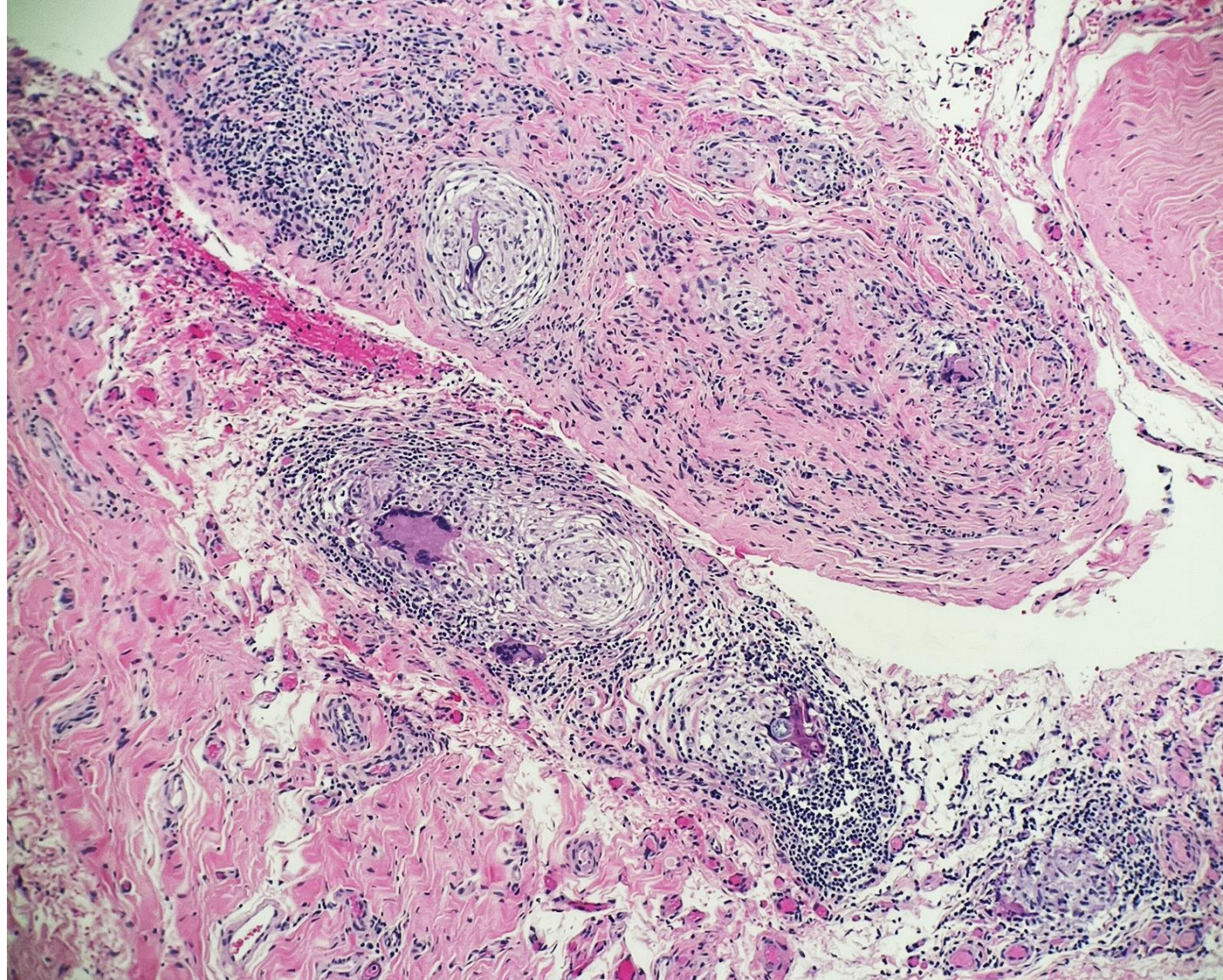
24-0704

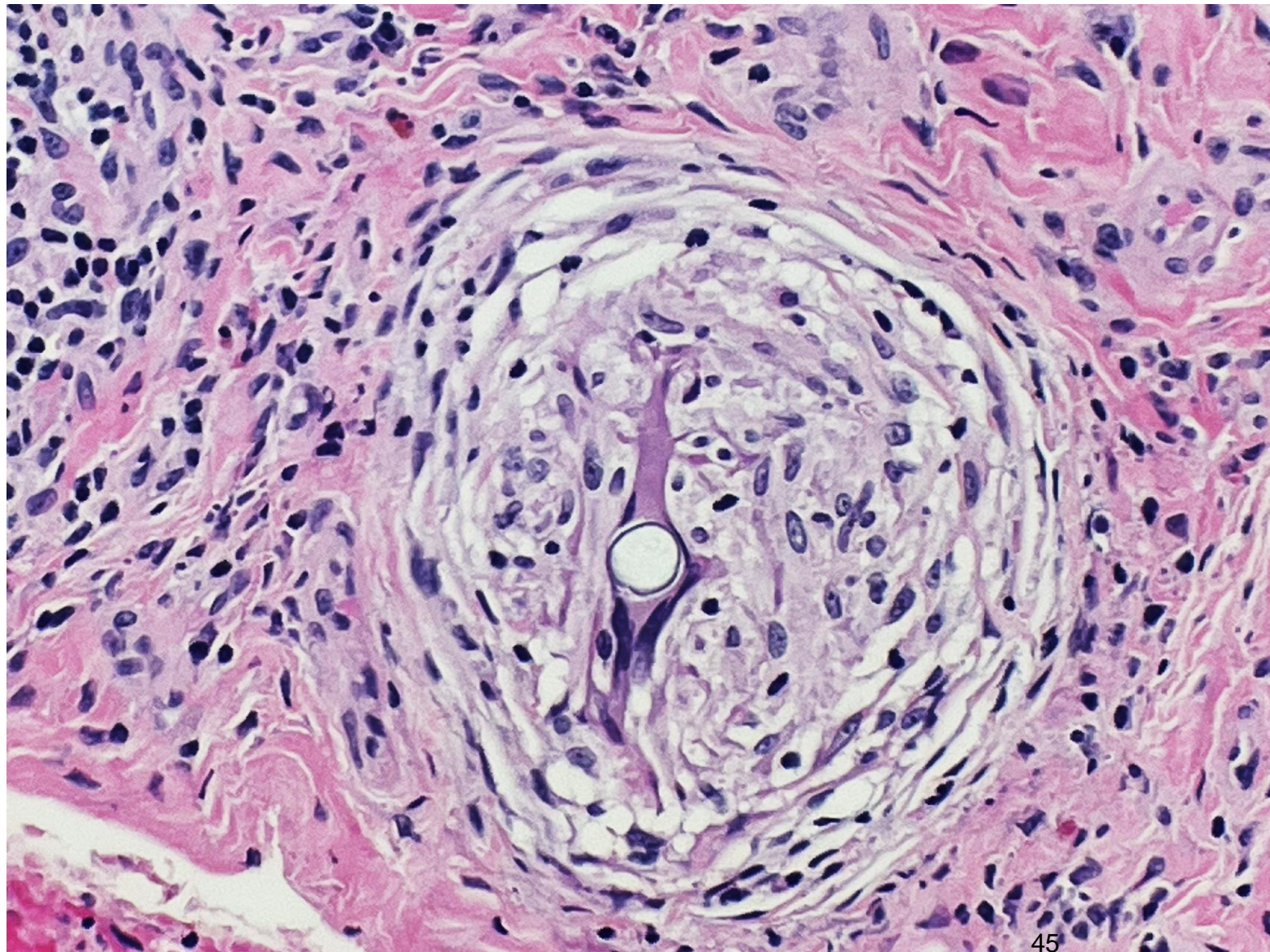
Harris Goodman

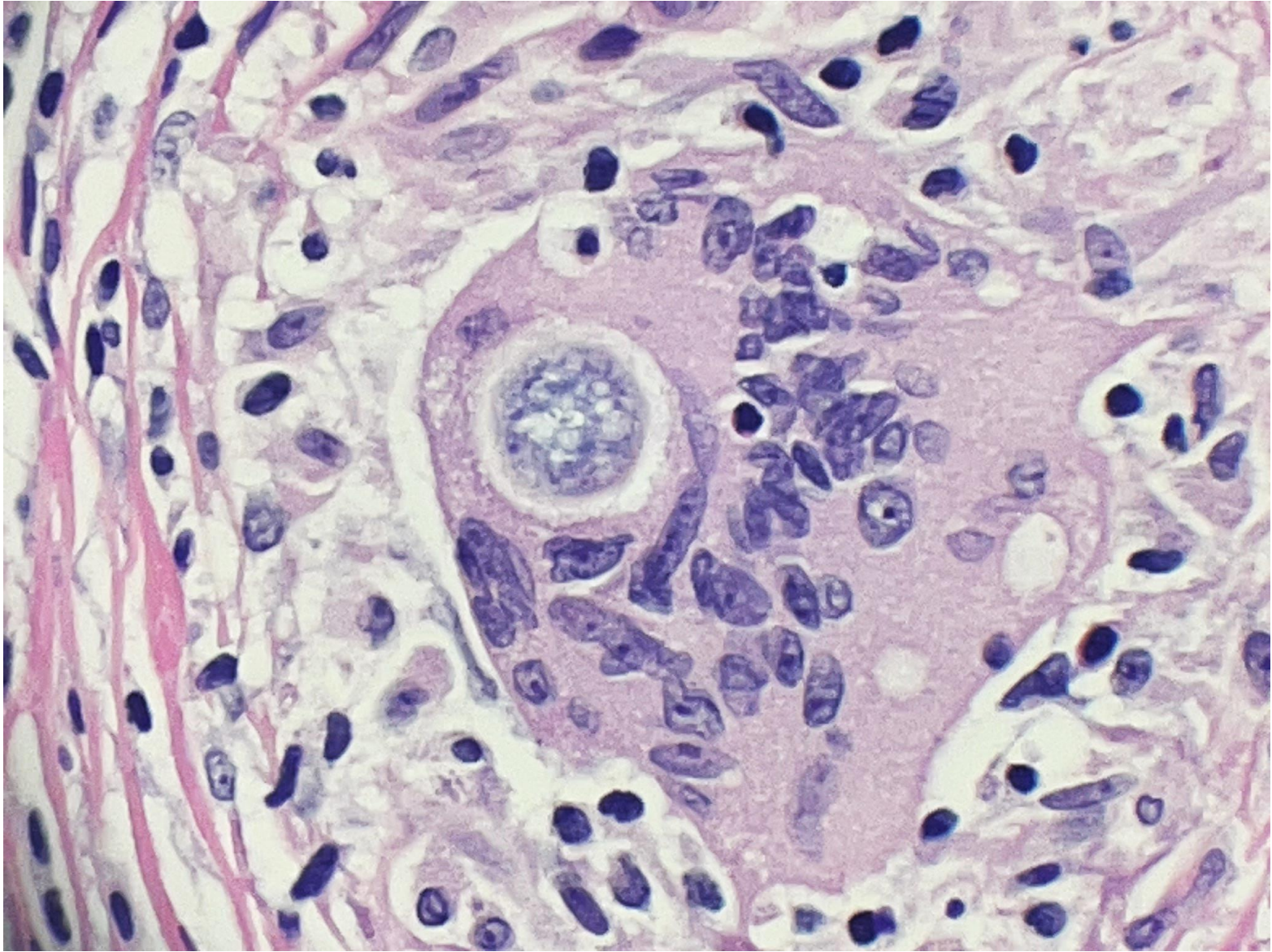
60-70 year old man with “symptomatic R inguinal hernia, PMHx significant for CAD s/p remote stent placement on DAPT. The hernia sac was dissected carefully off of the cord structures. A cord lipoma was noted and resected.”











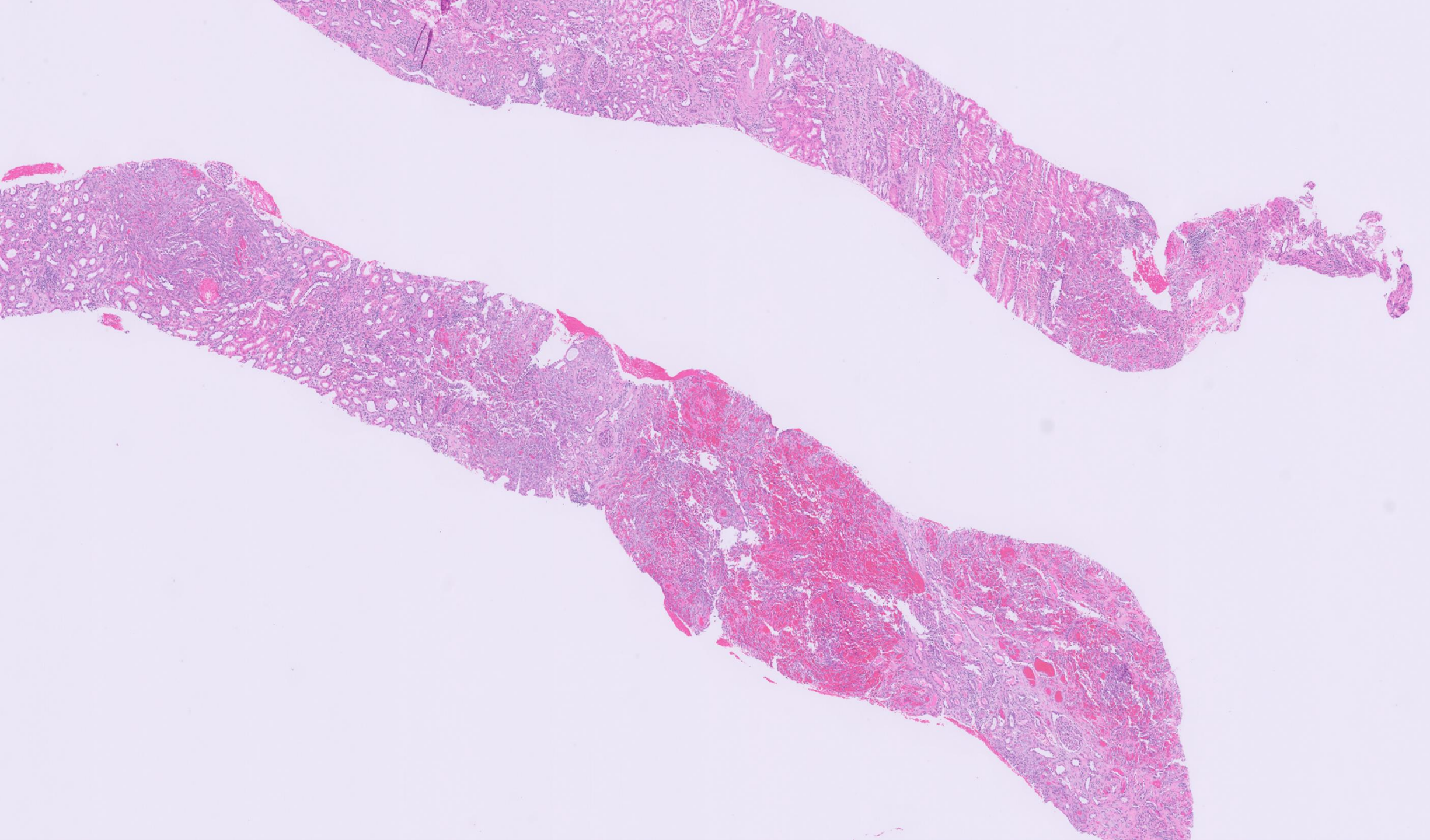
DIAGNOSIS?

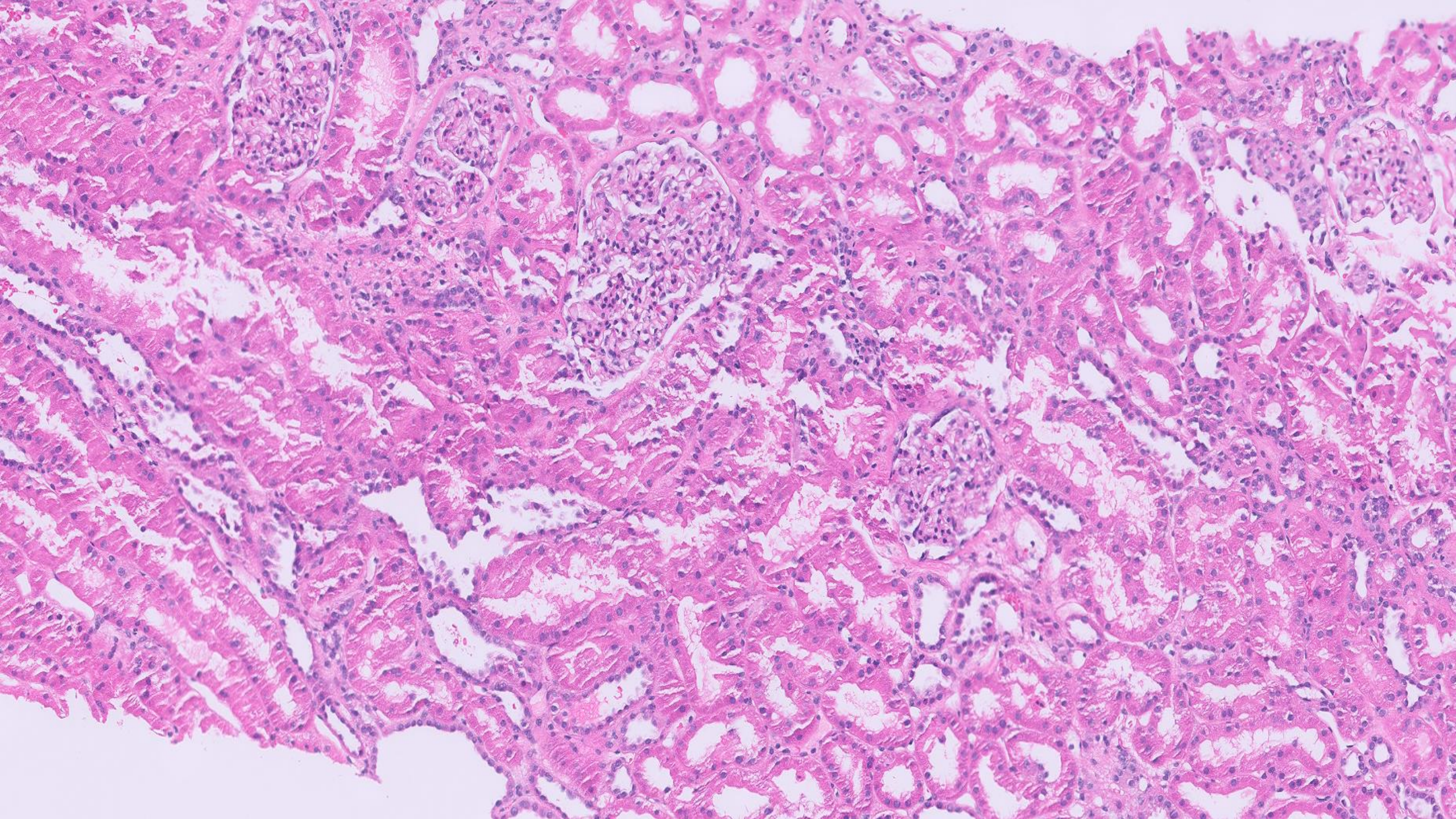


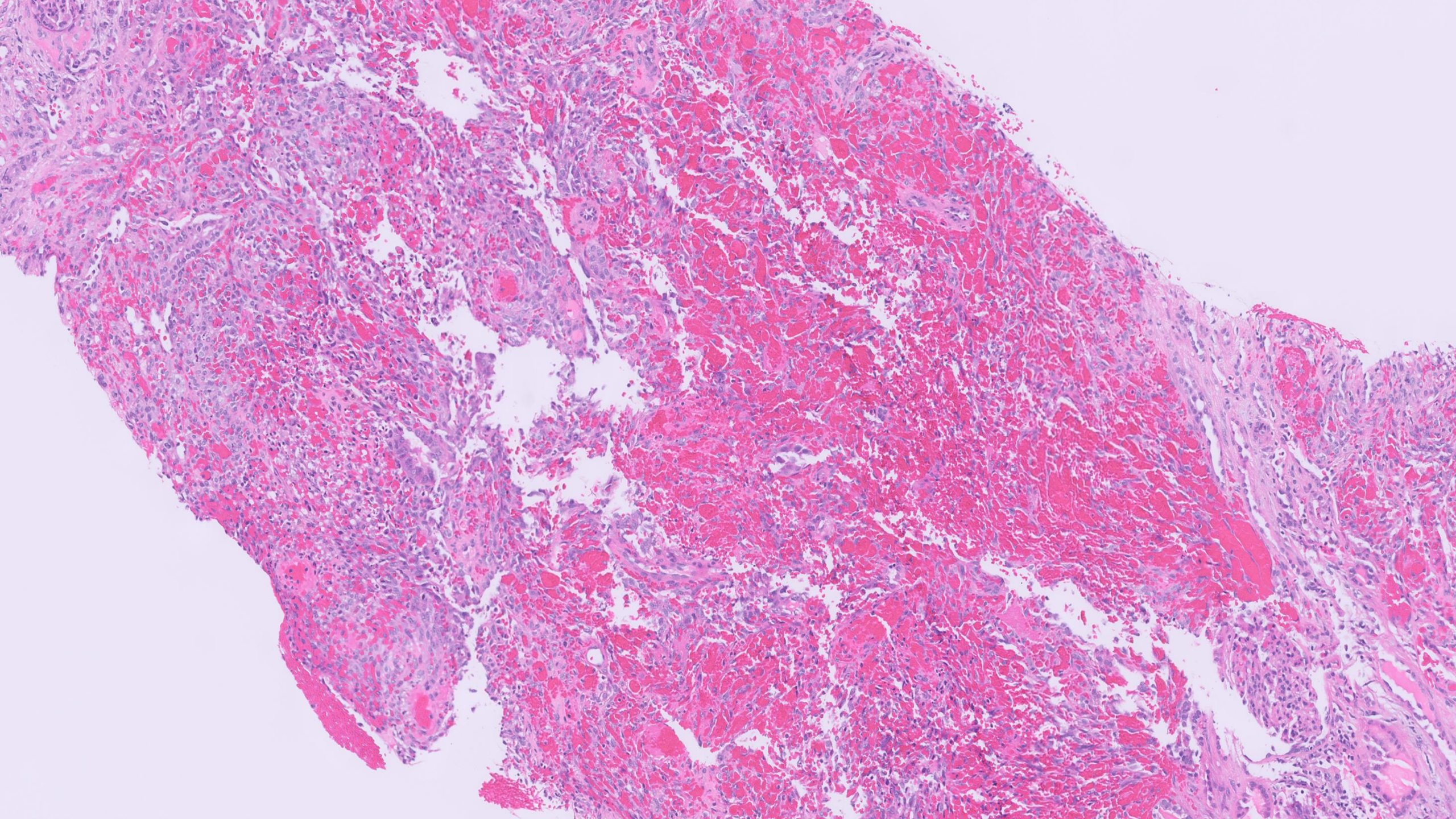
24-0705

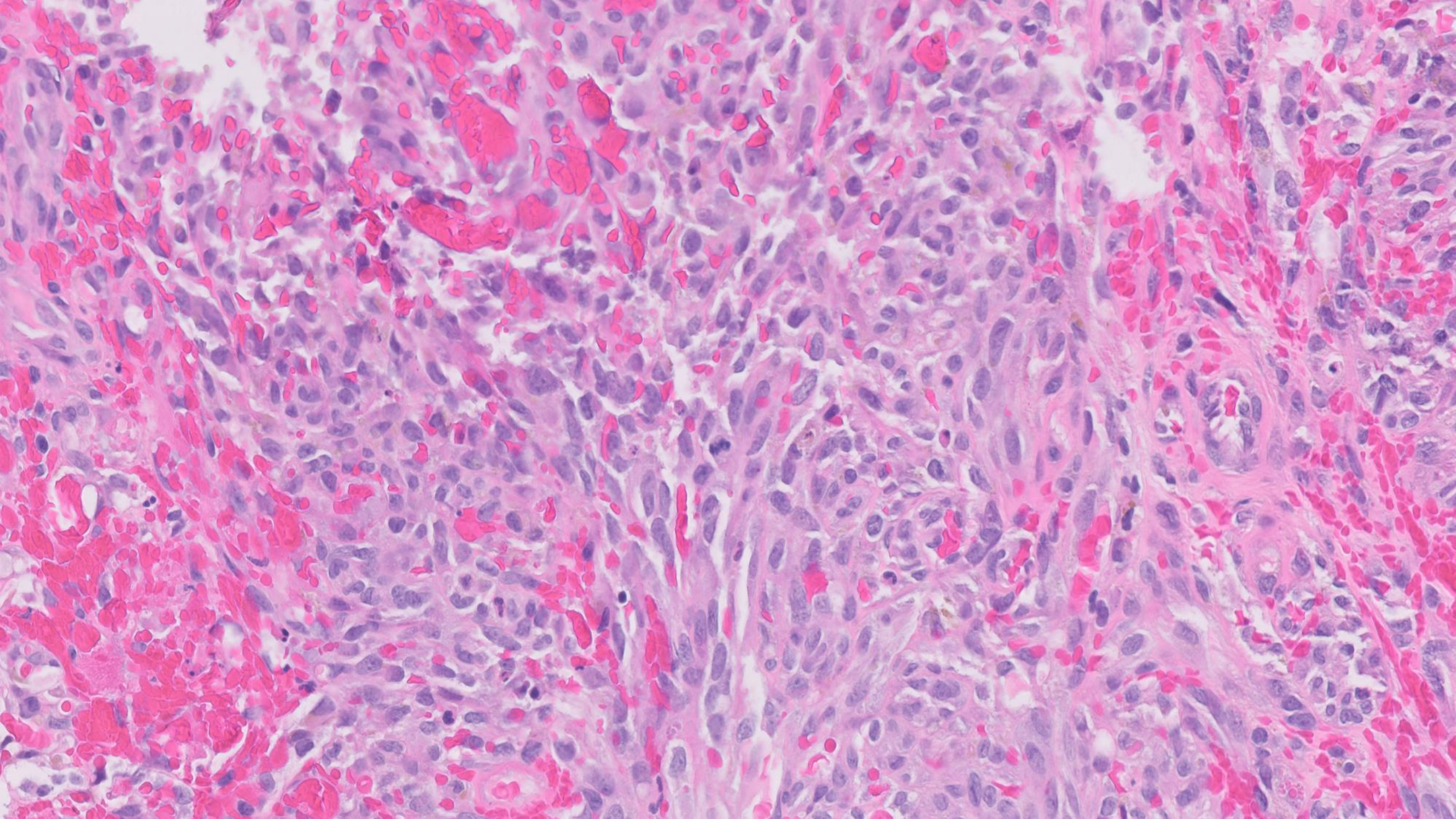
**Cooper Rutland, MD (Stanford Surgical Pathology Fellow), Megan Troxell,
Stanford, Lucy Han, MD (CPMC, Sutter Health)**

39 year old male with history of kidney and pancreas transplant with a recent rise in creatinine.









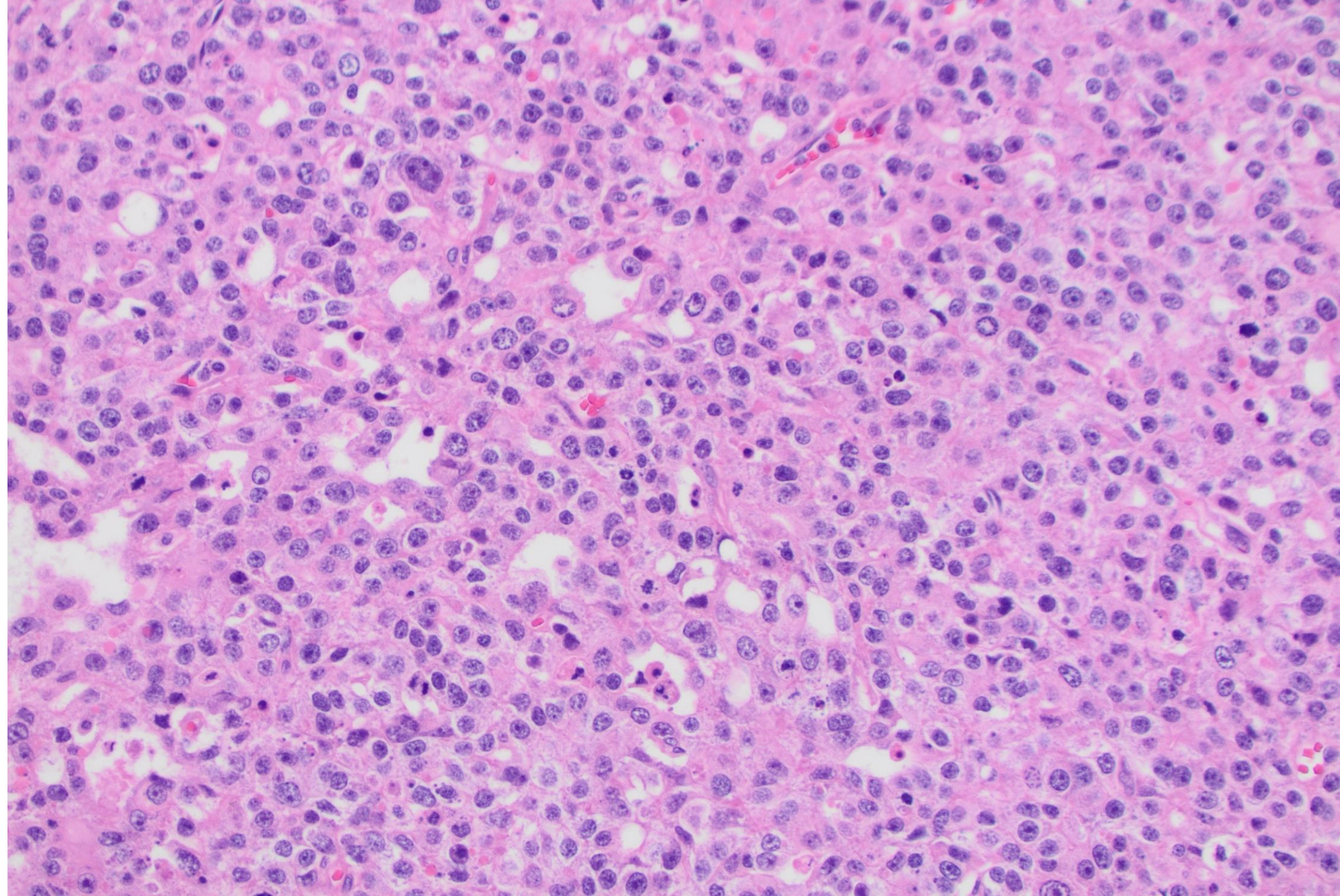
DIAGNOSIS?

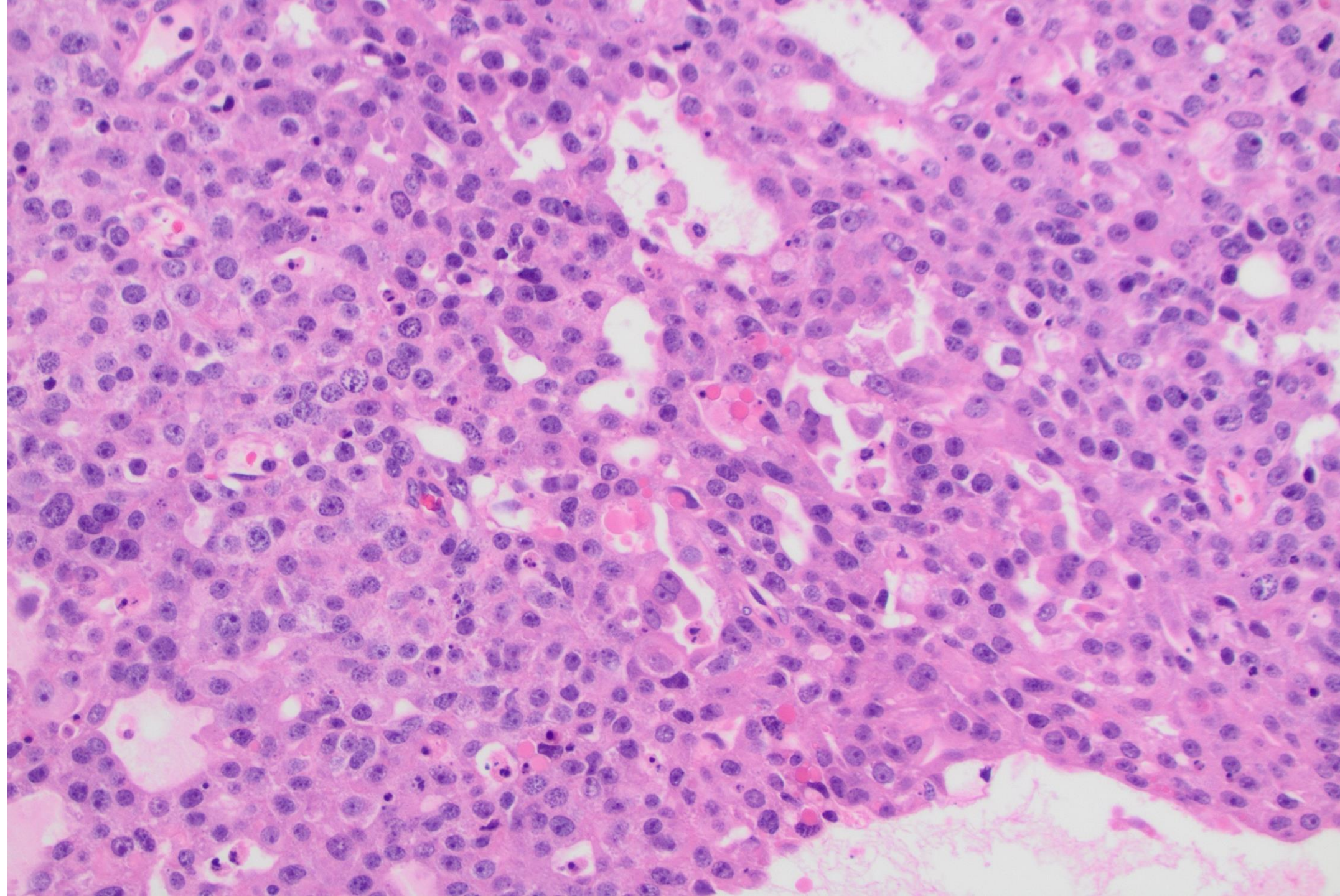


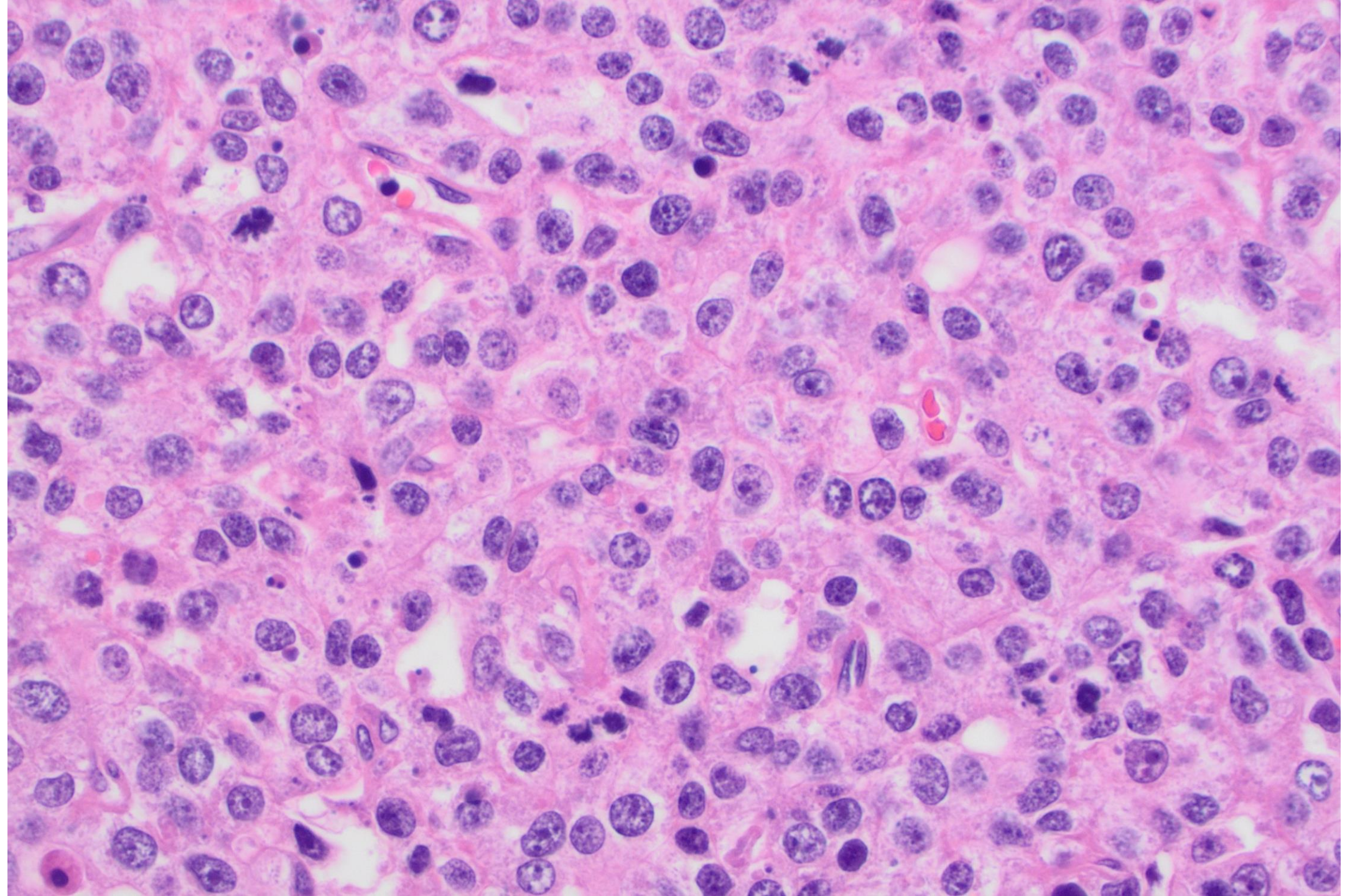
24-0706

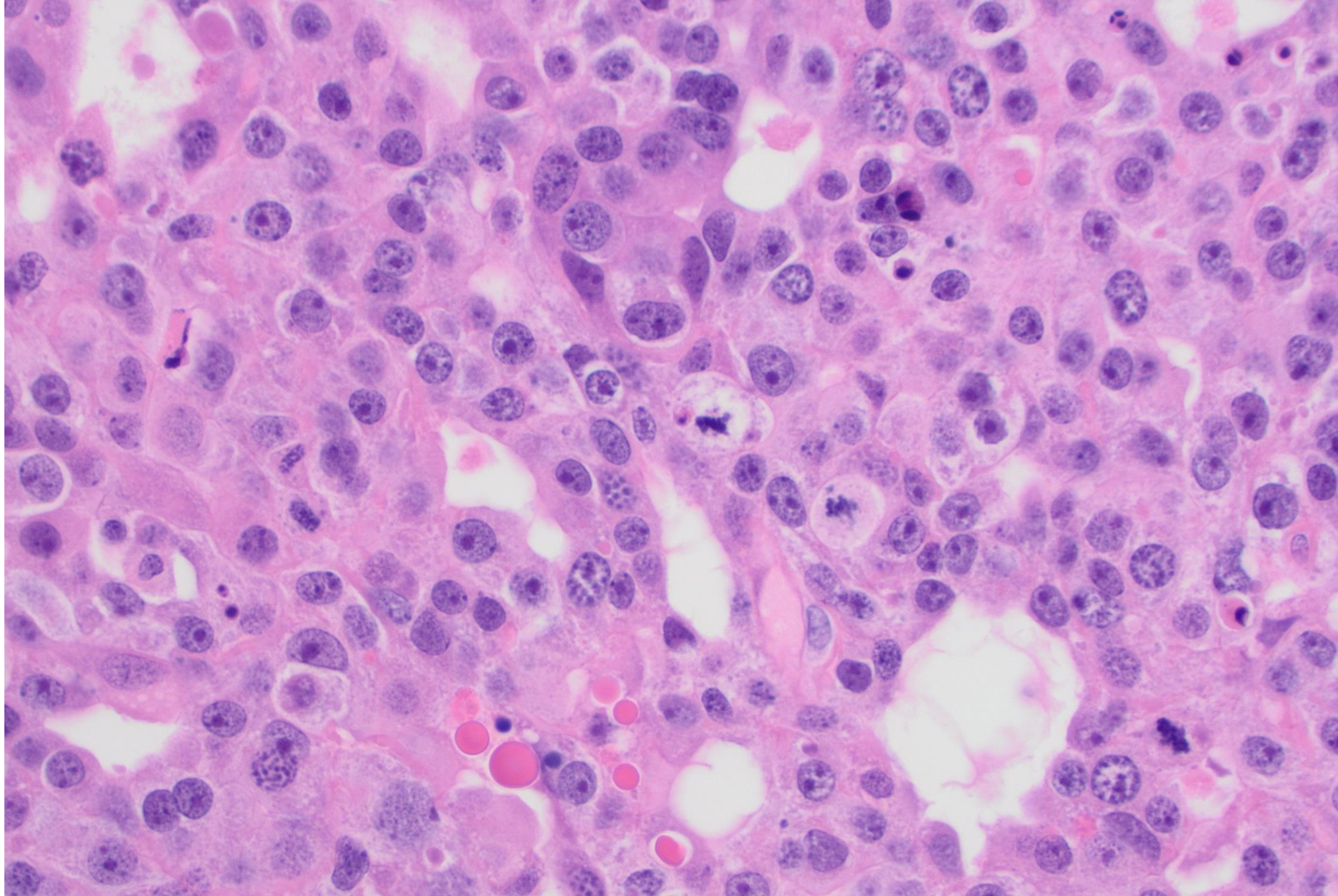
Greg Rumore; The Permanente Medical Group

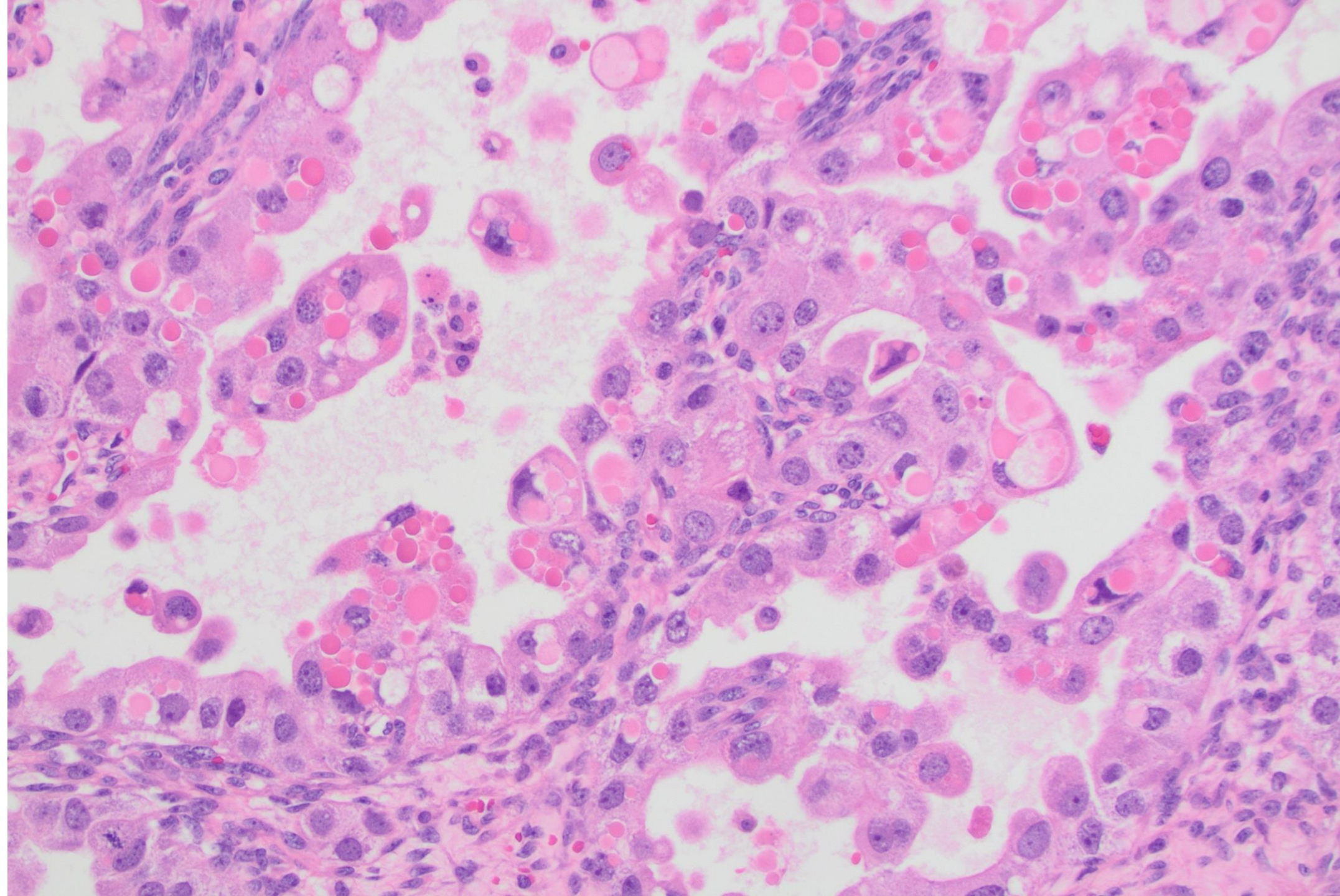
70ish woman with 22 cm R ovarian mass adherent to adjacent structures











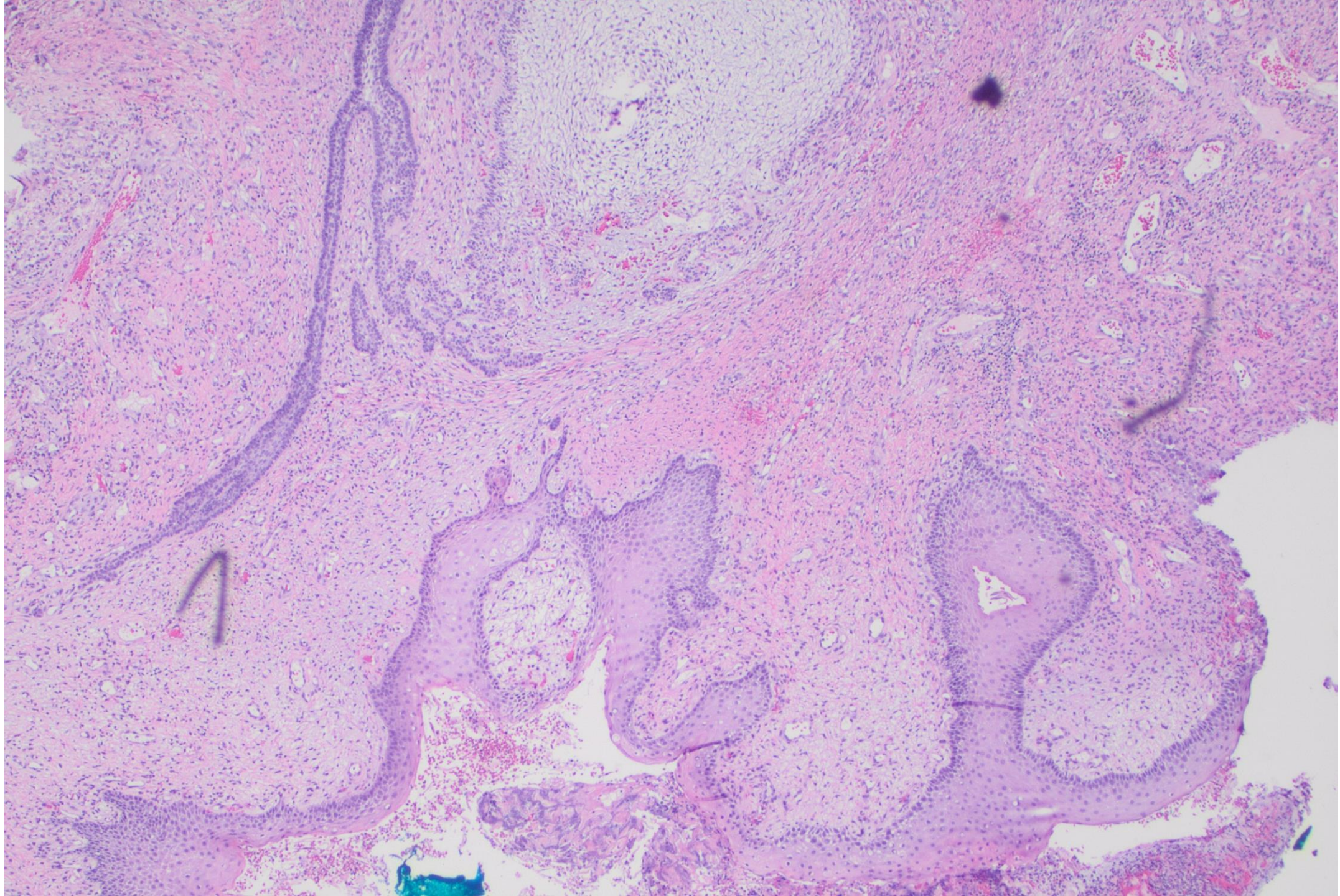
DIAGNOSIS?

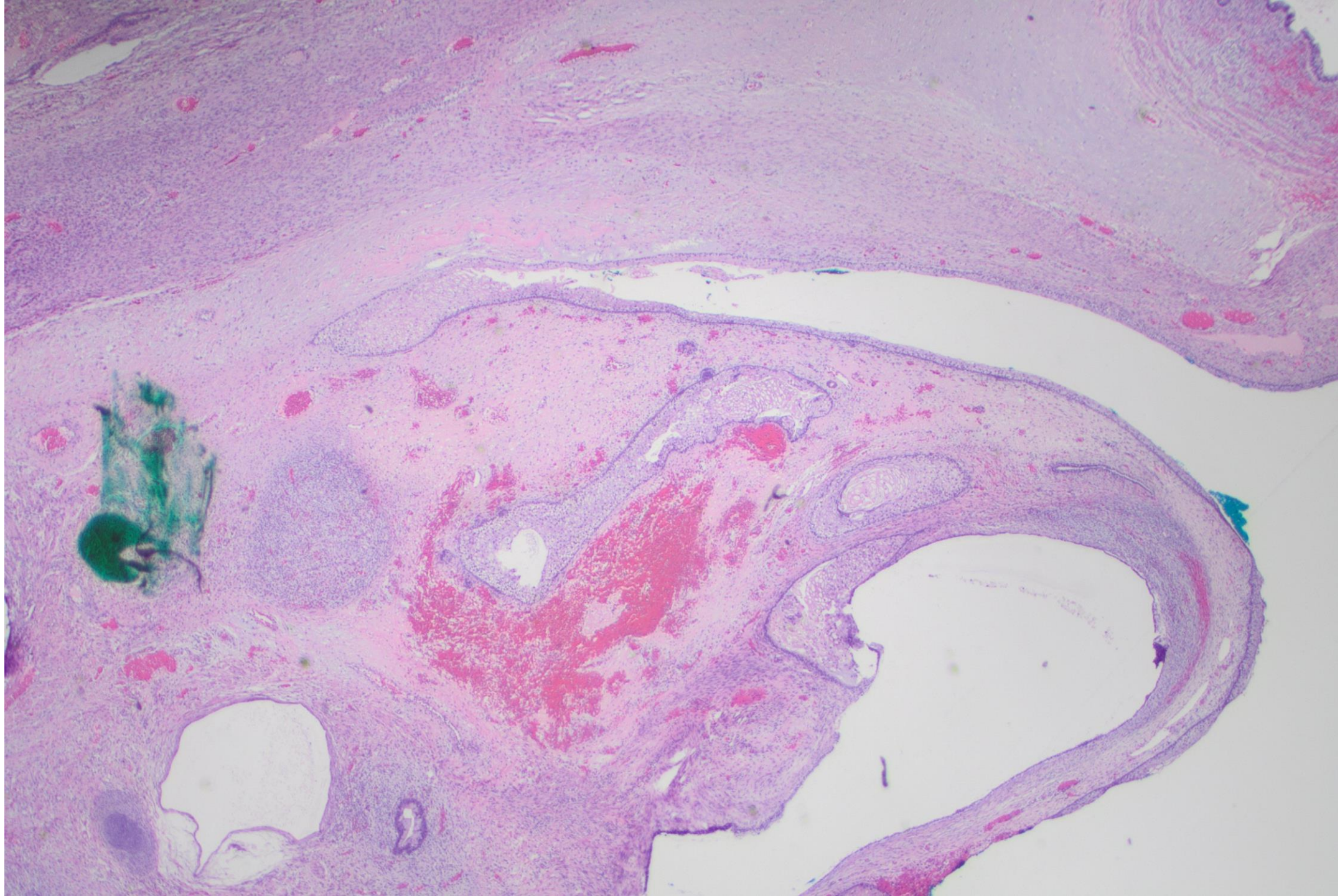


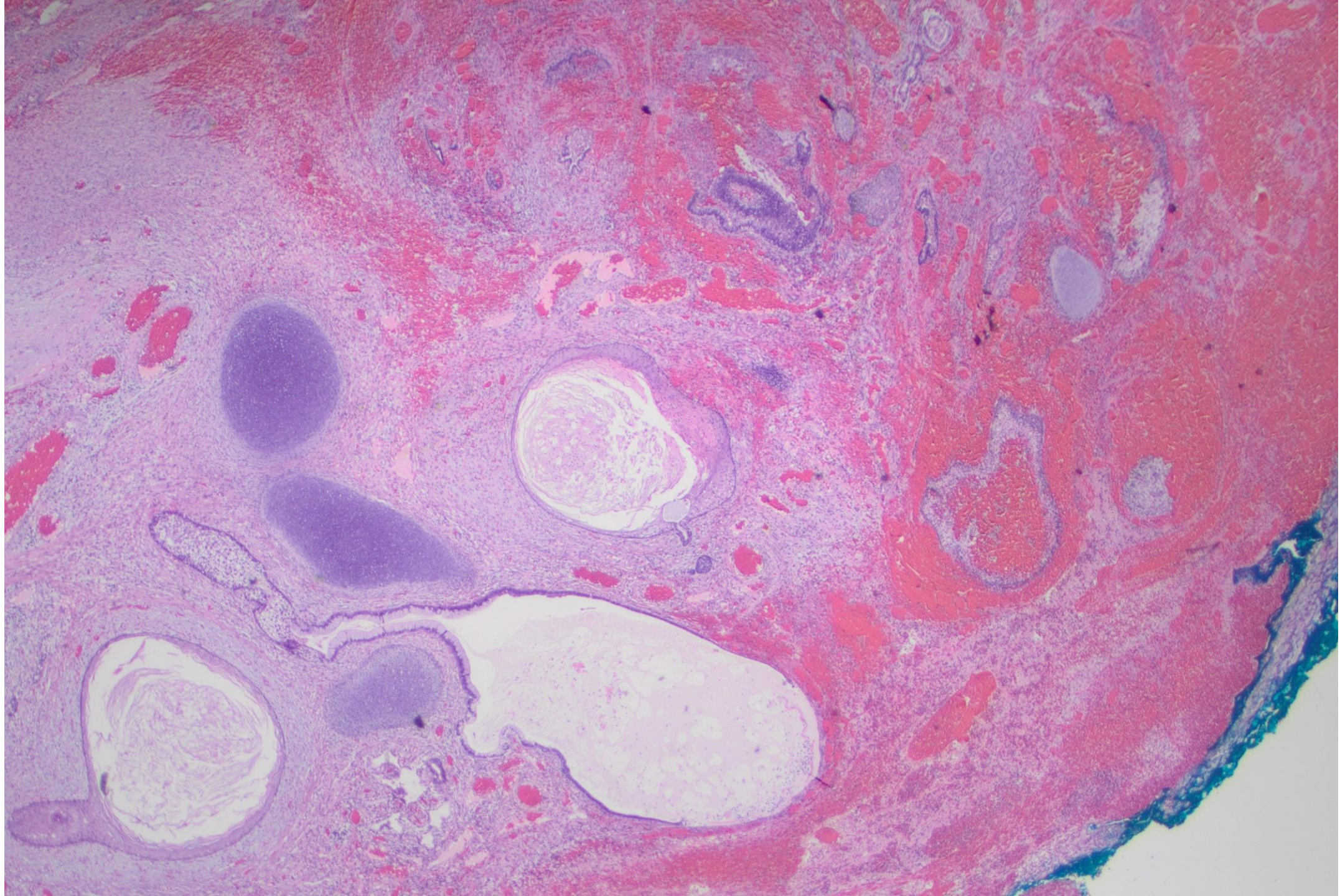
24-0707

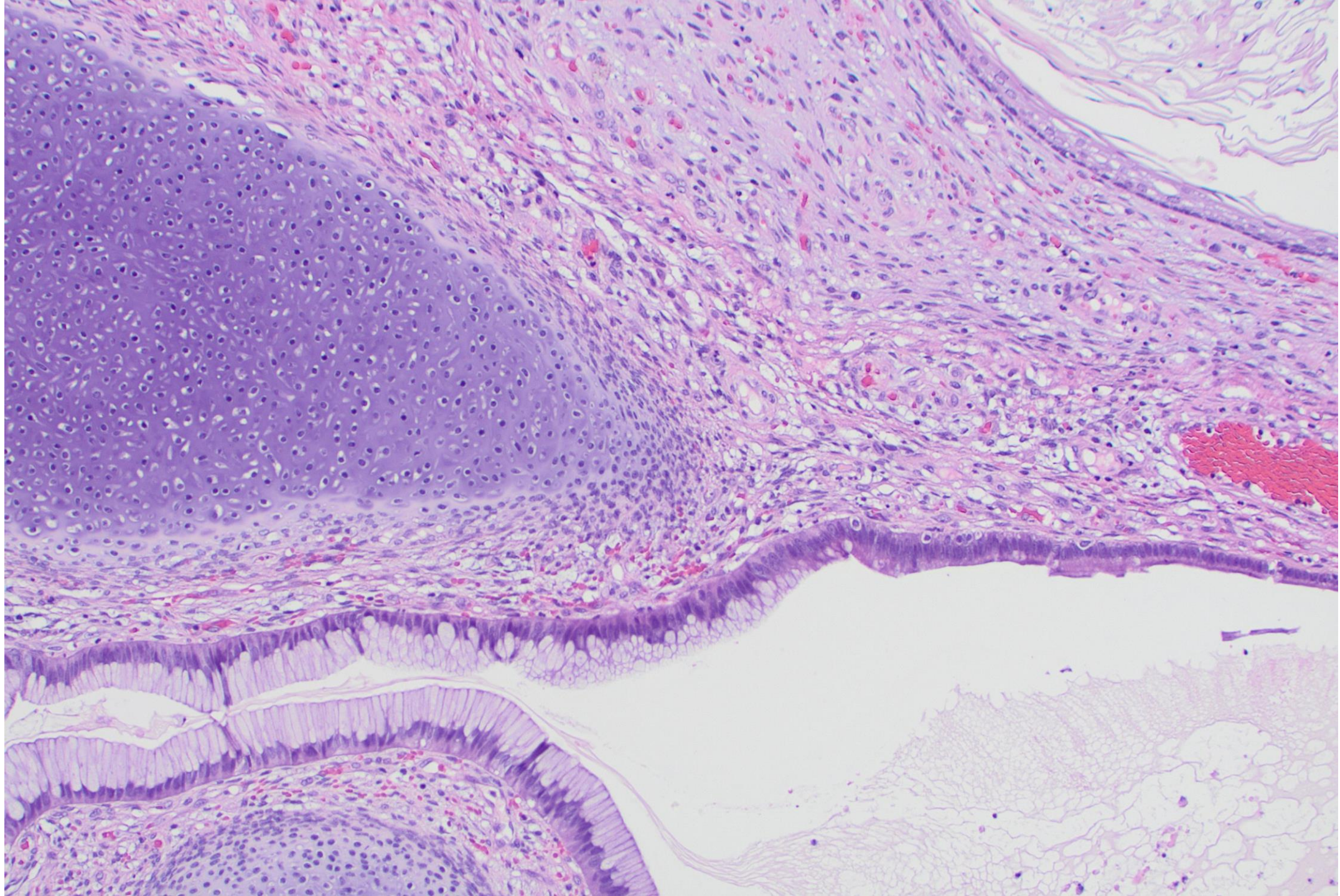
Greg Rumore; The Permanente Medical Group

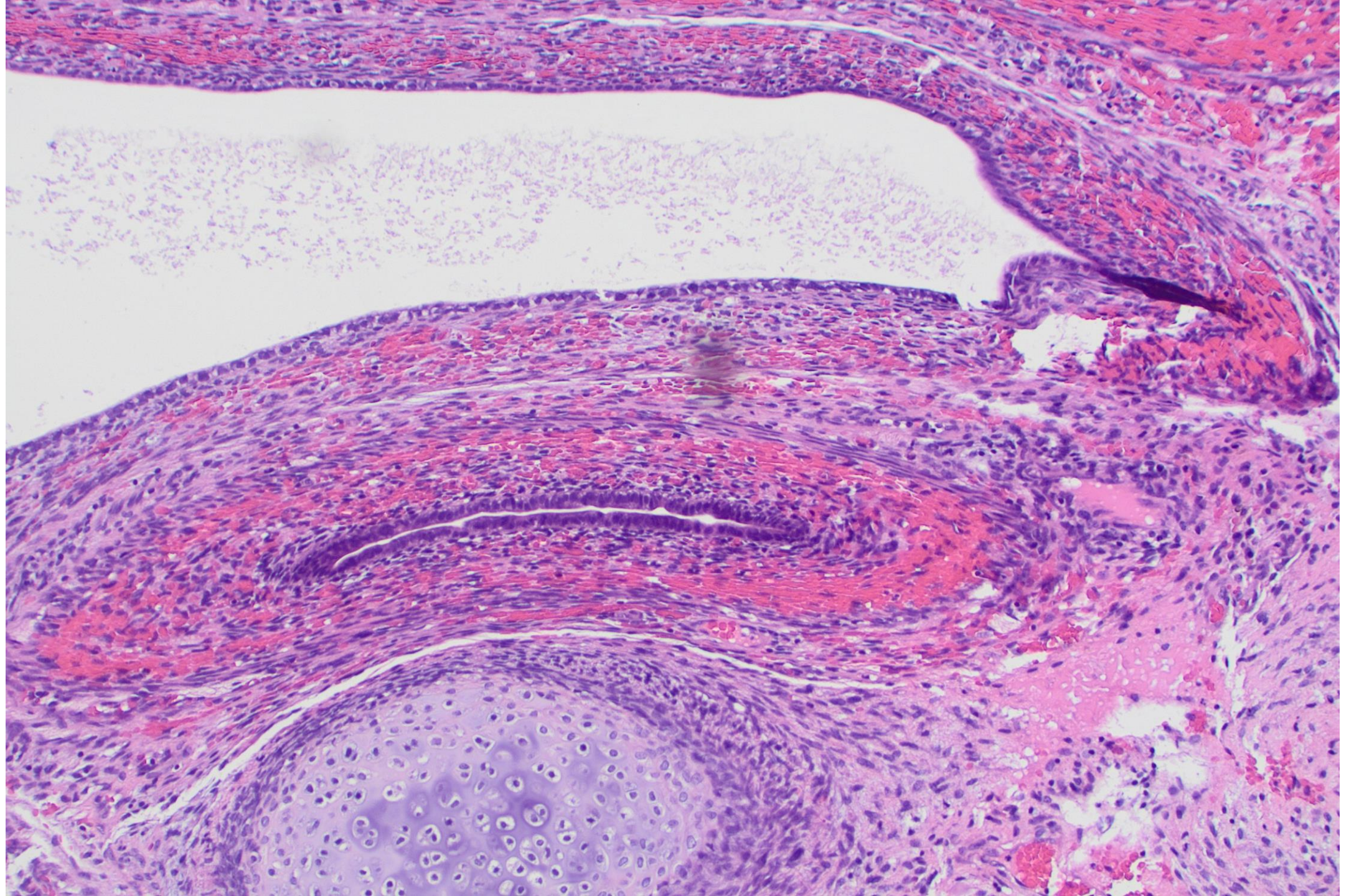
27 y.o. with prolonged heavy periods. U/S- endometrial and LUS polyps. Ovaries WNL.

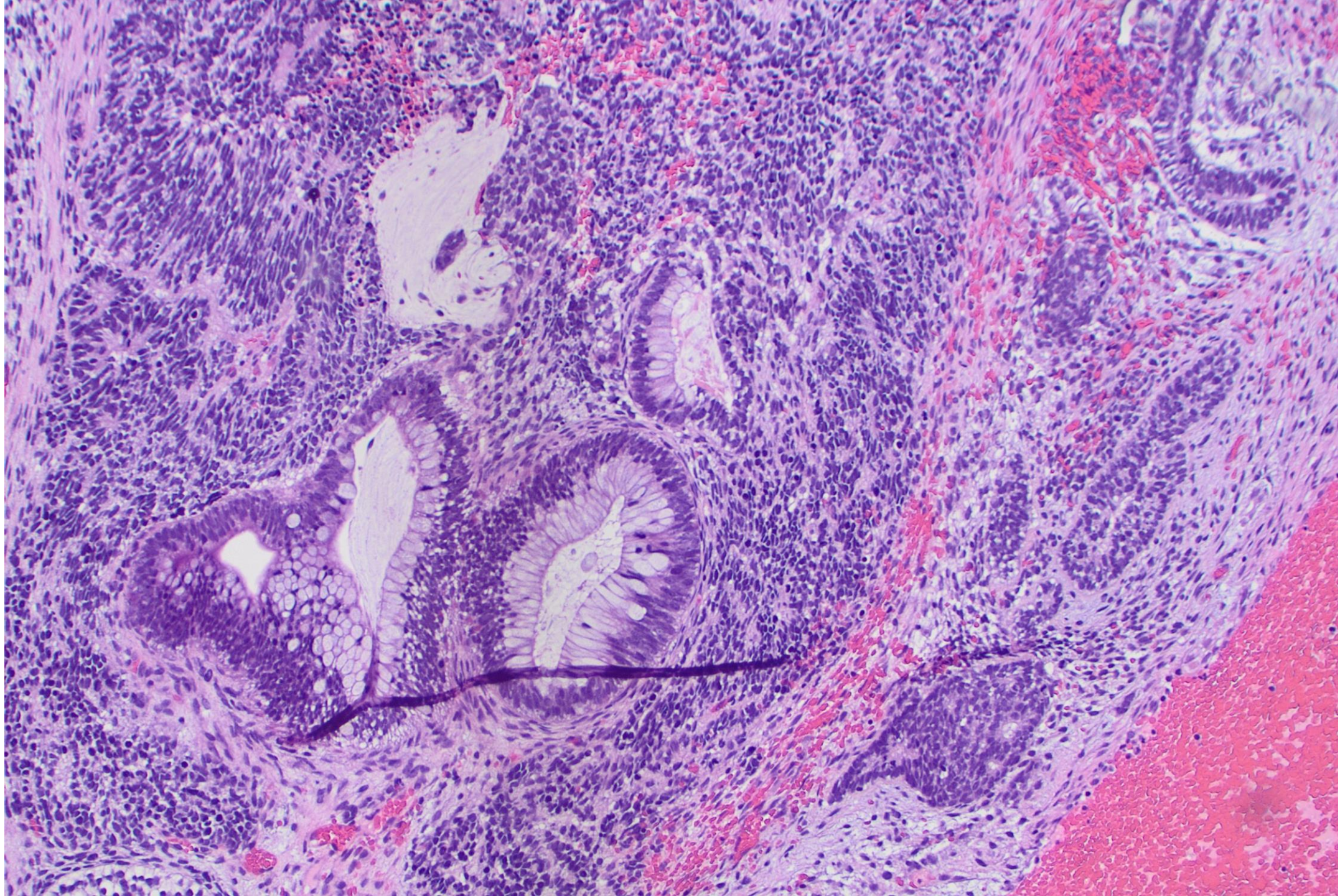


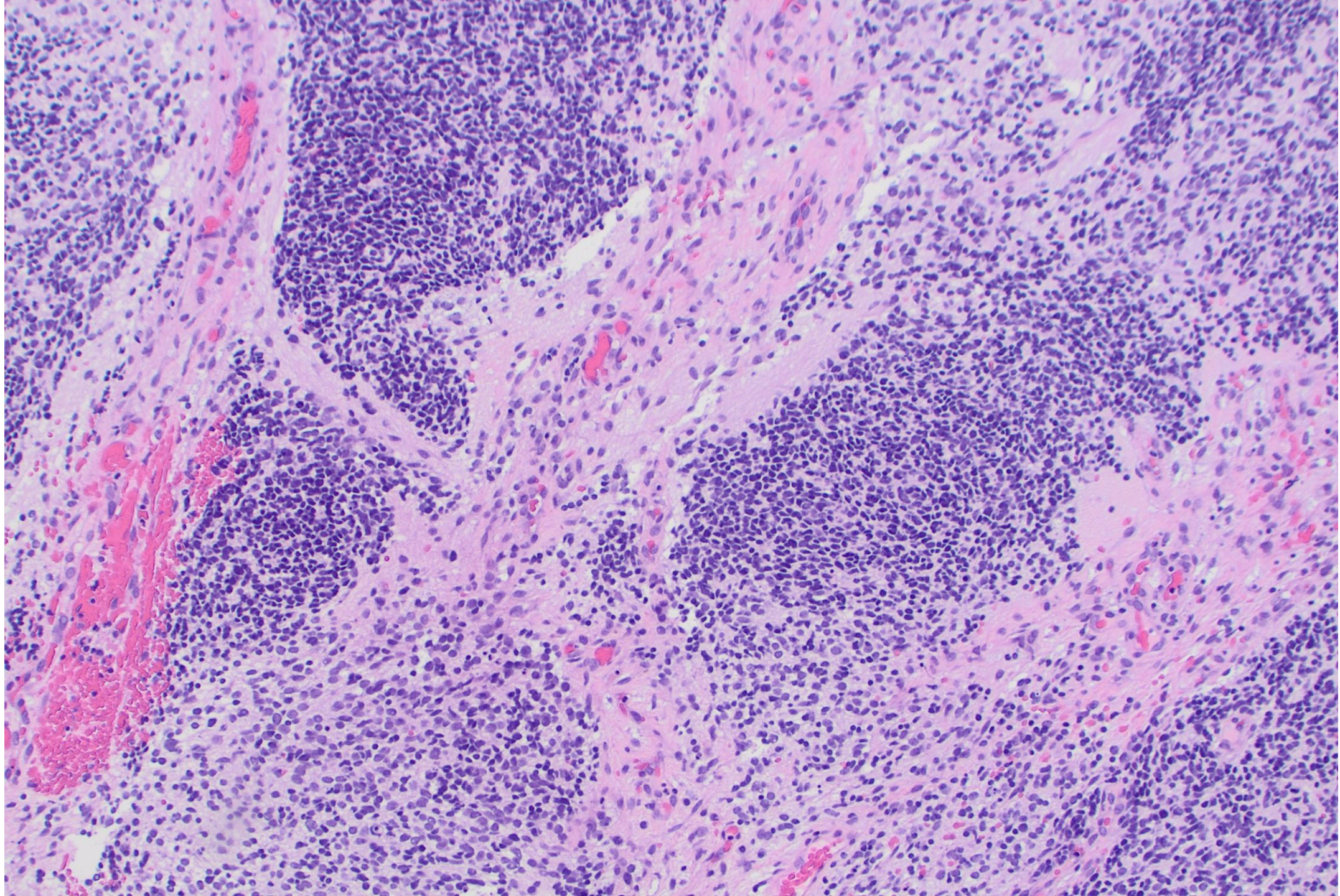


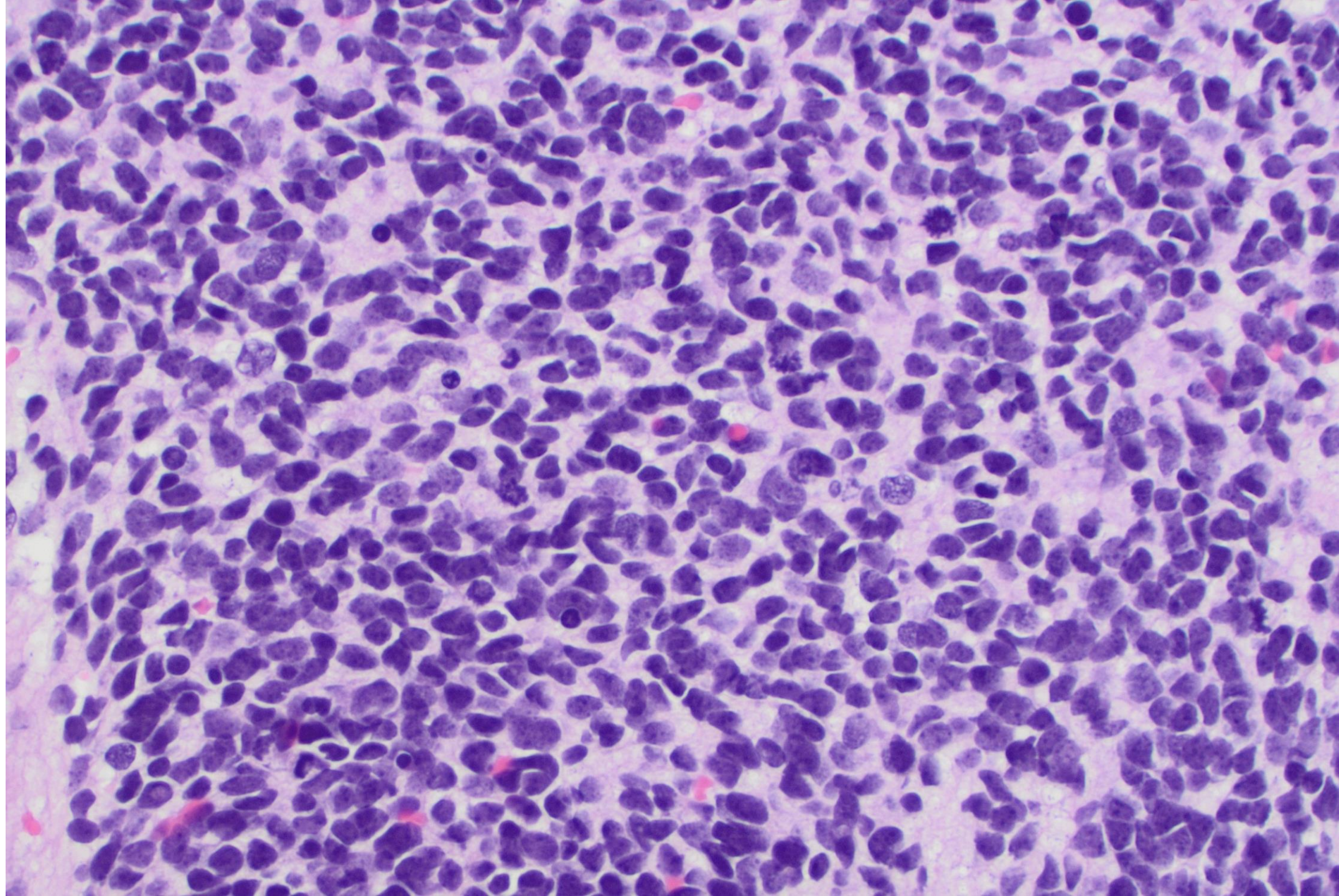


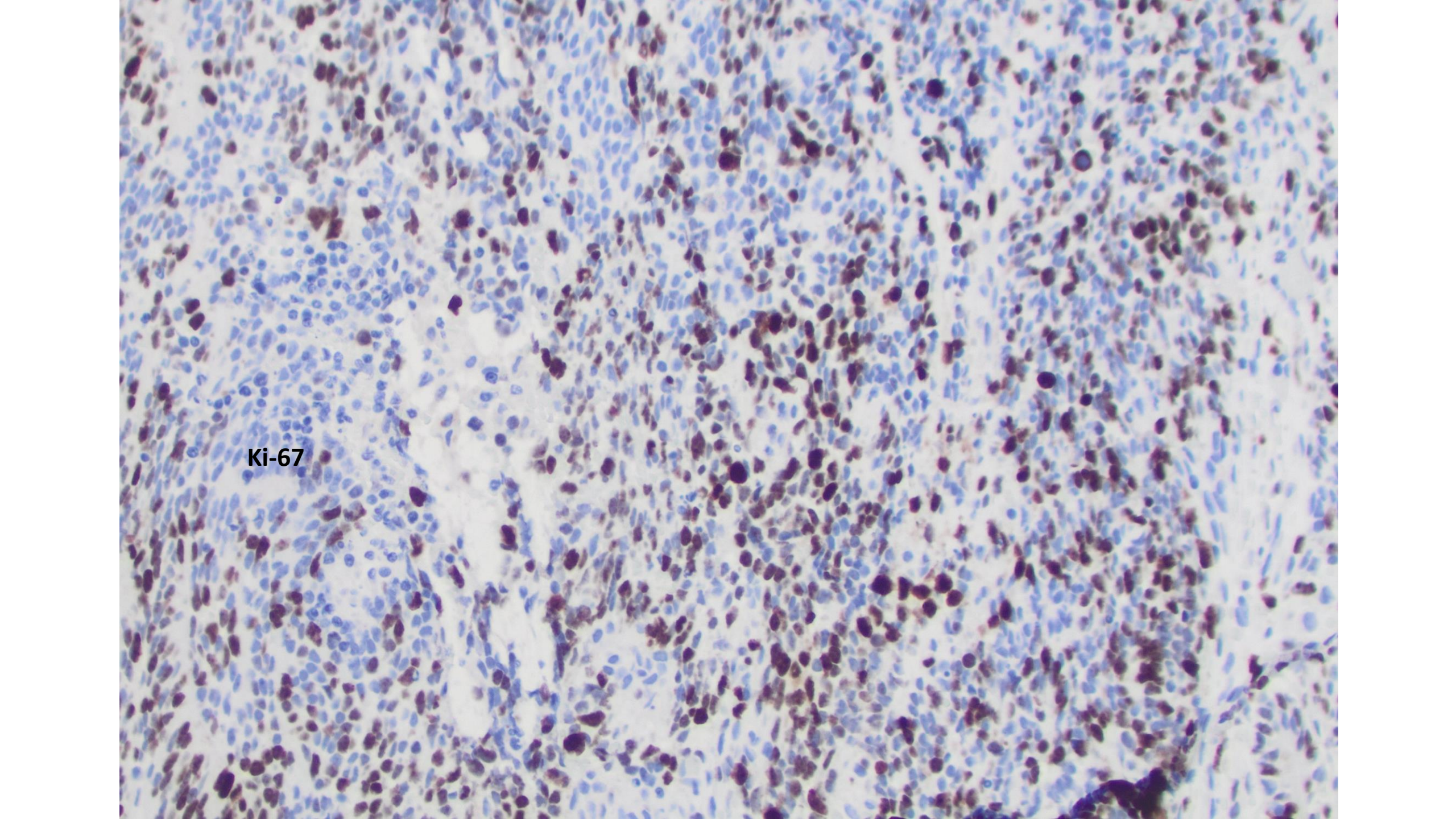












Ki-67

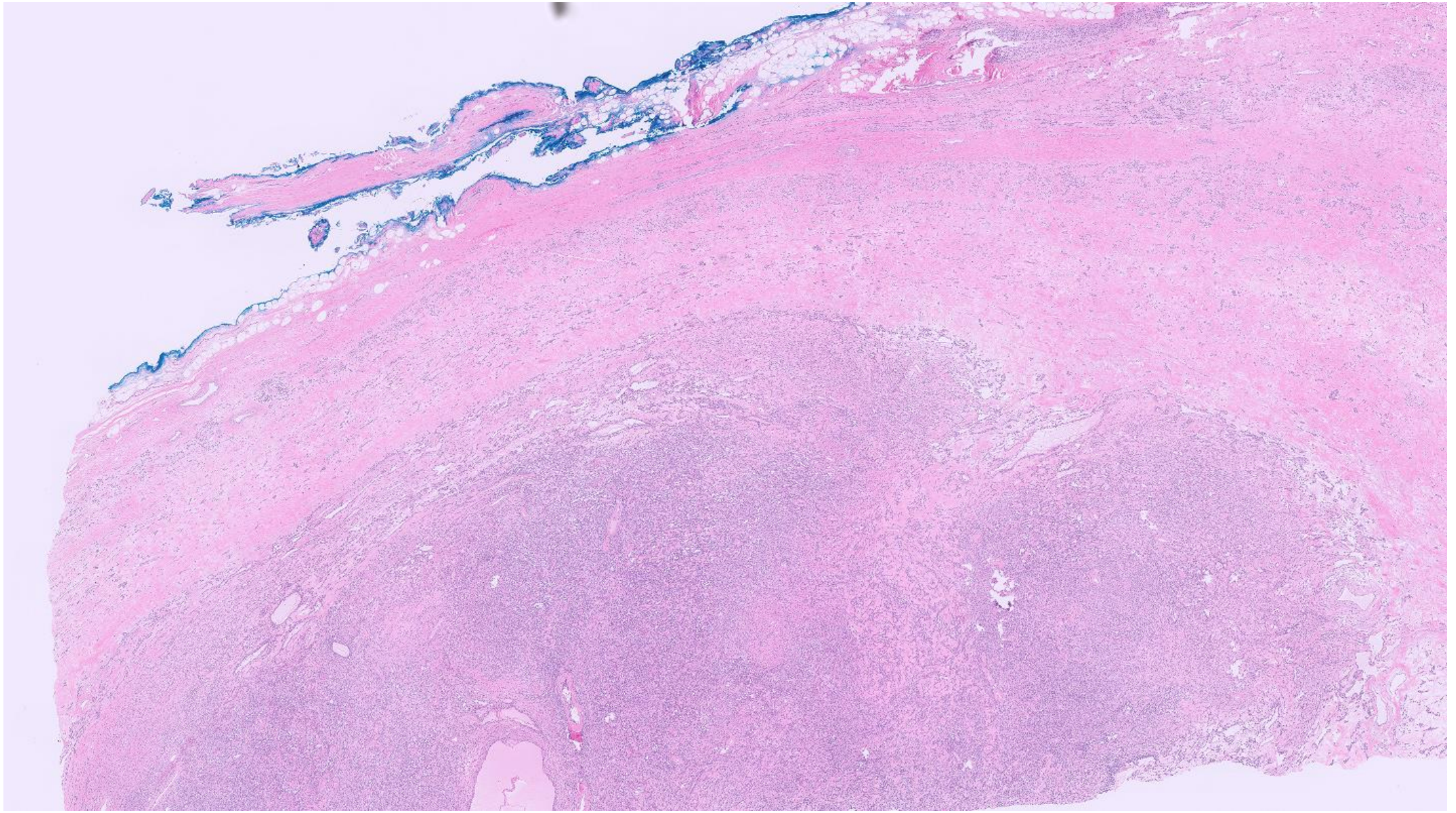
DIAGNOSIS?

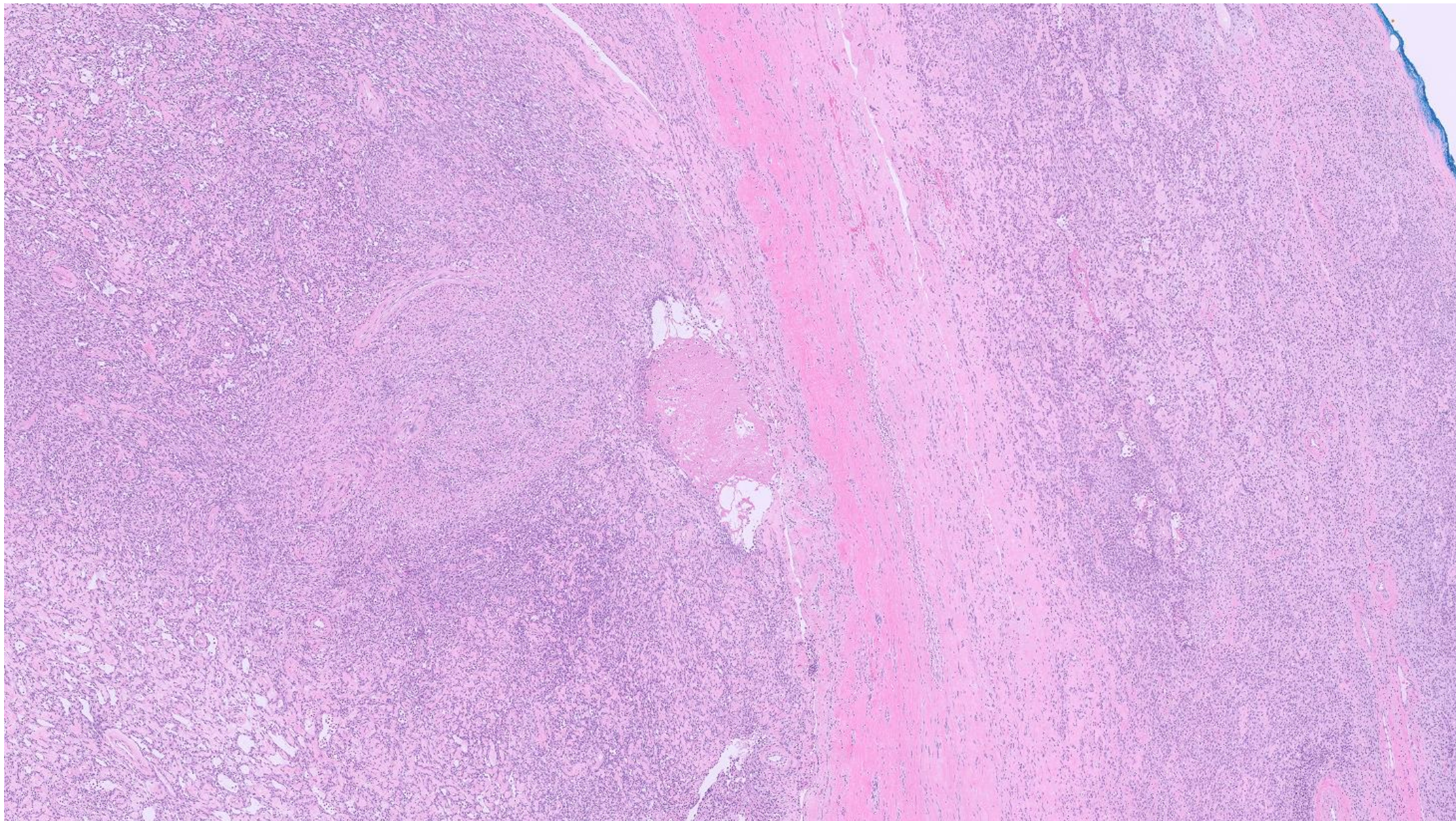


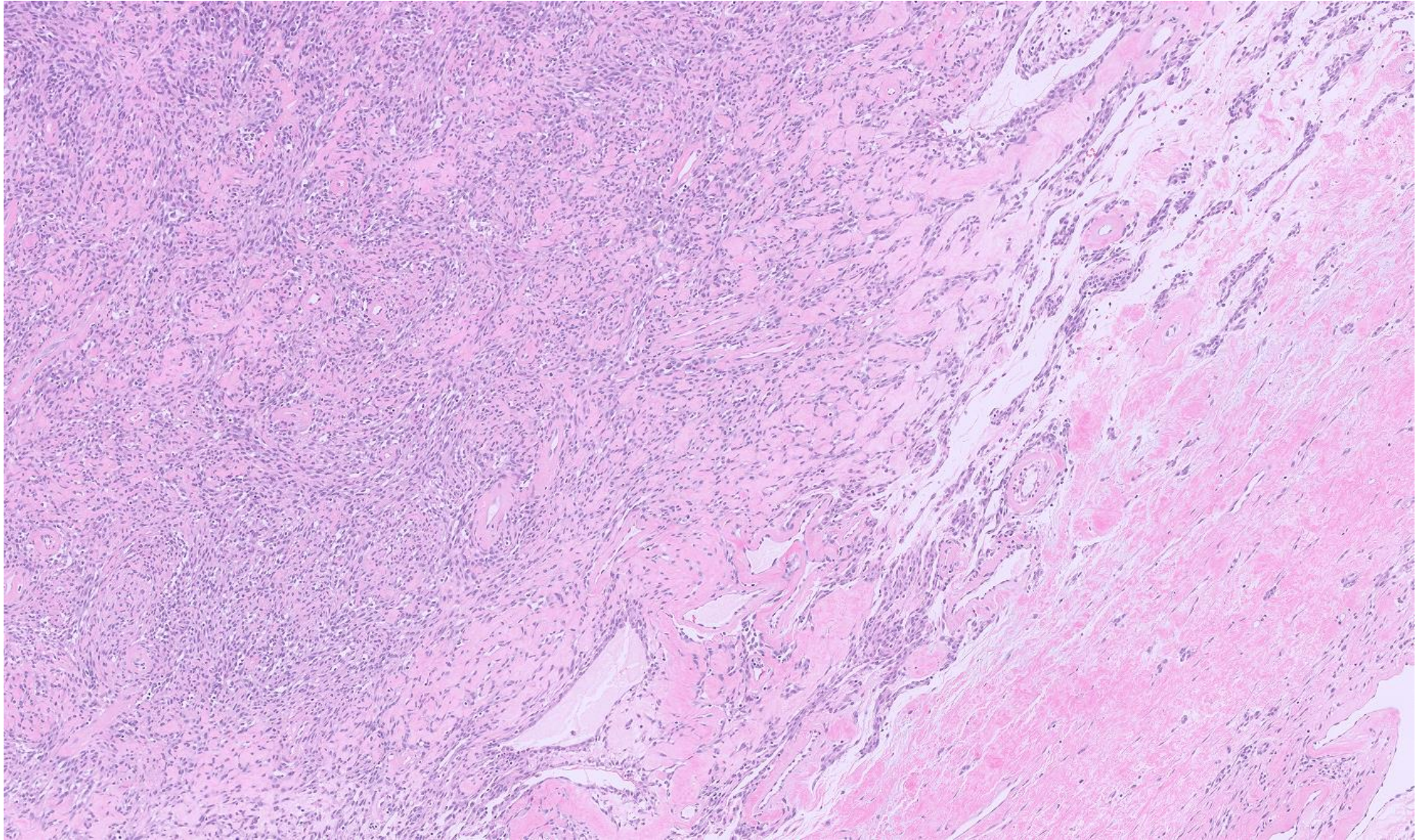
24-0708

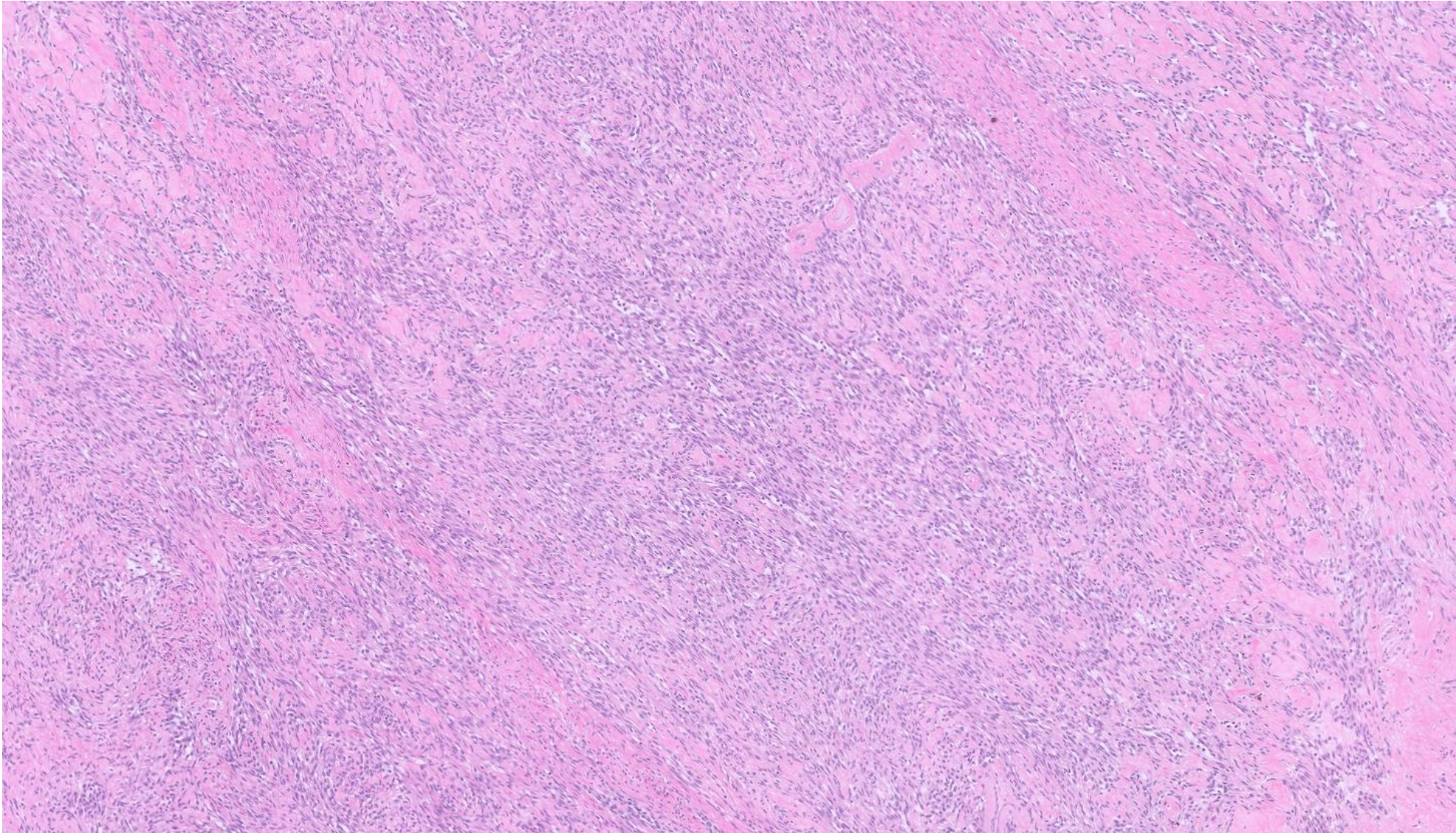
Sheren Younes, Brooke Howitt; Stanford

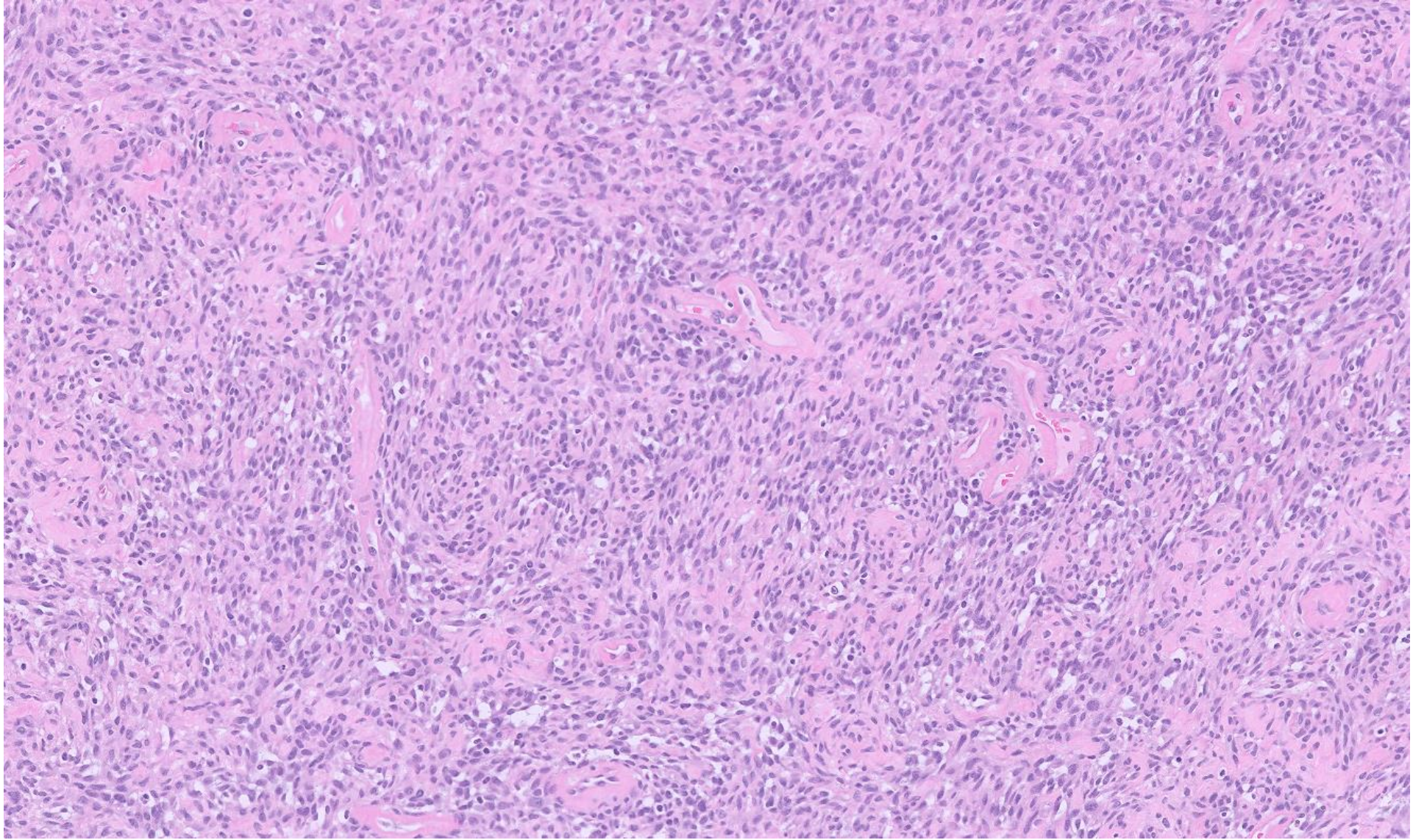
35-year-old female with a “brachial plexus” mass. She had a biopsy of the mass which was consistent with a bland spindle cell lesion and underwent surgical excision

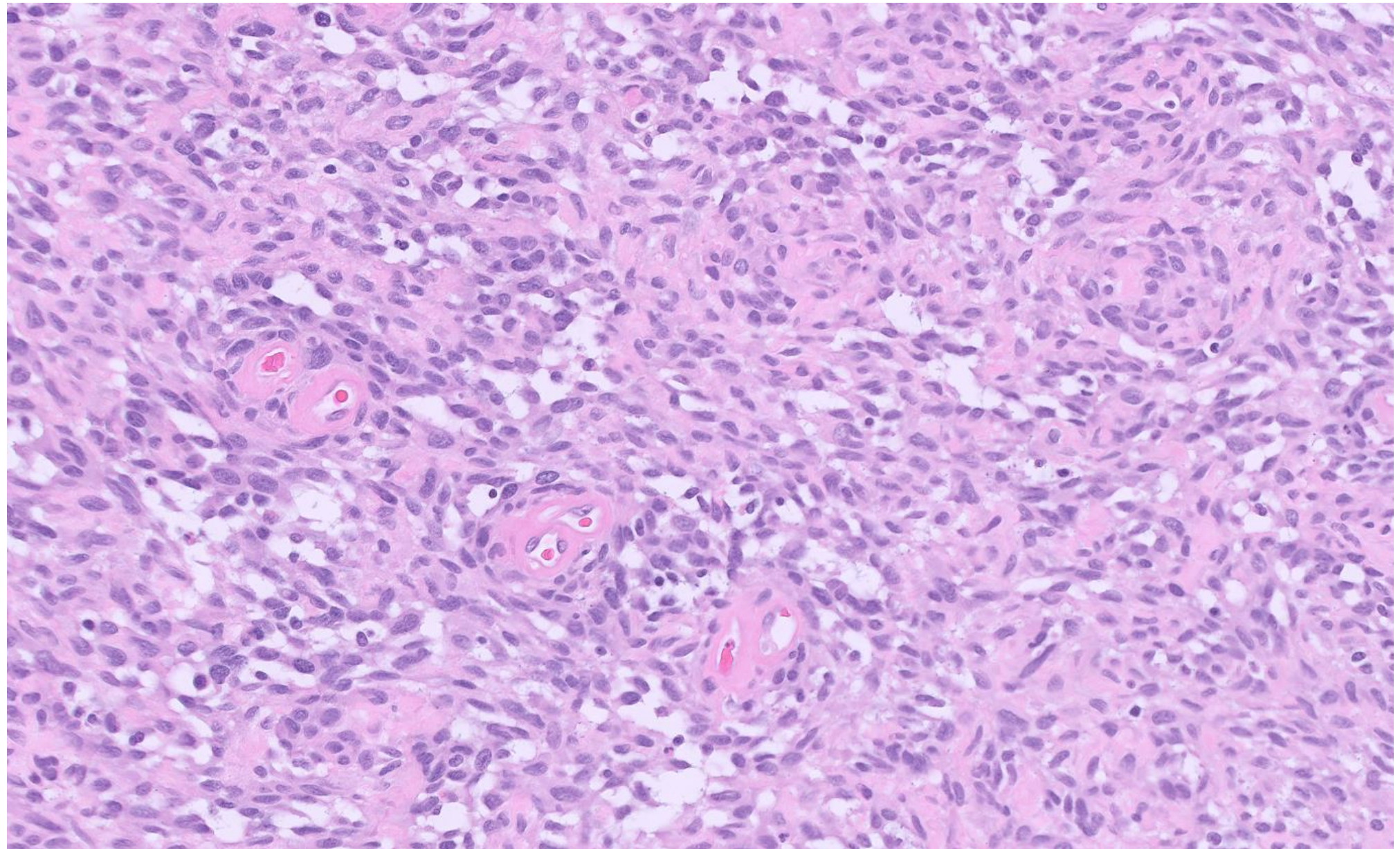


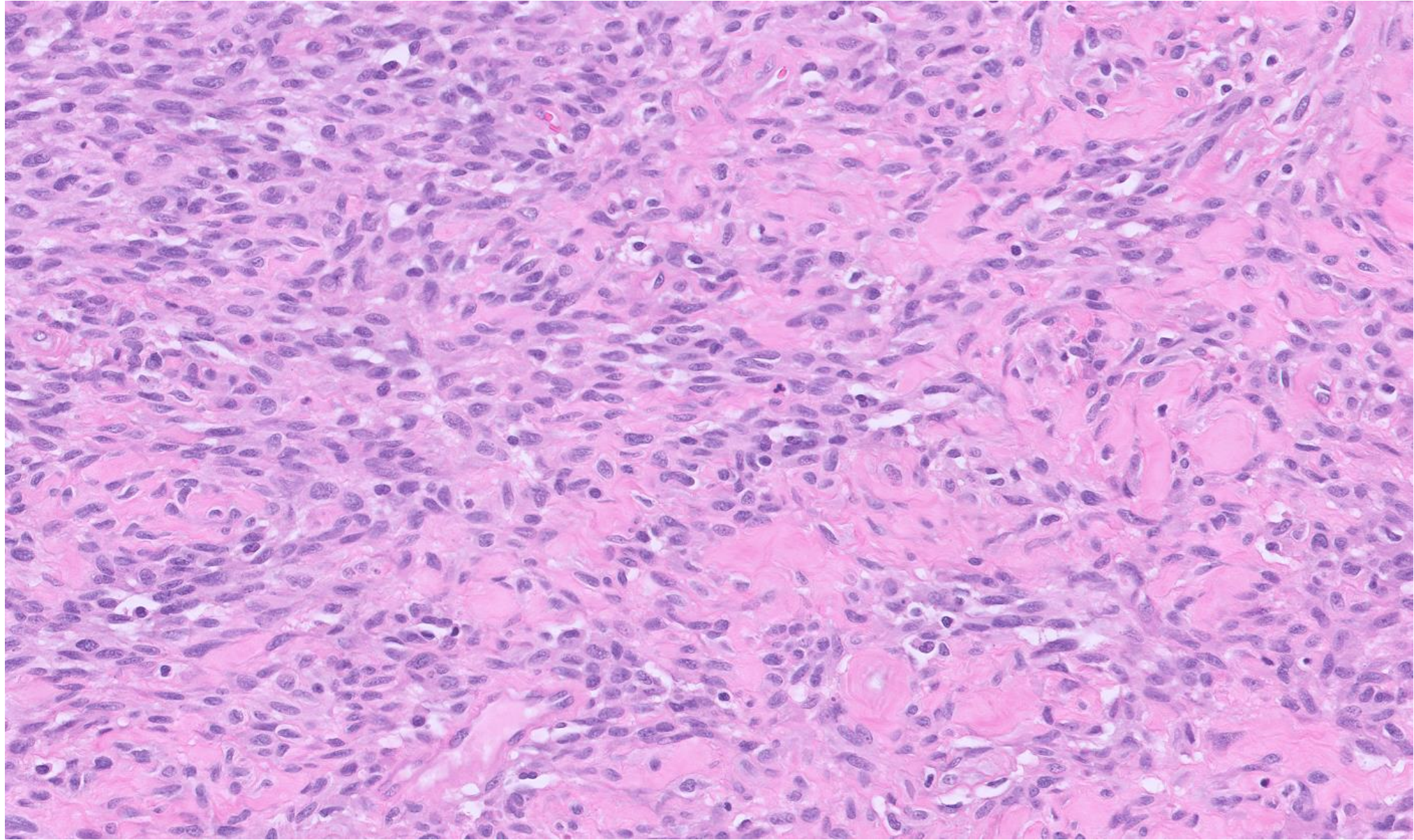


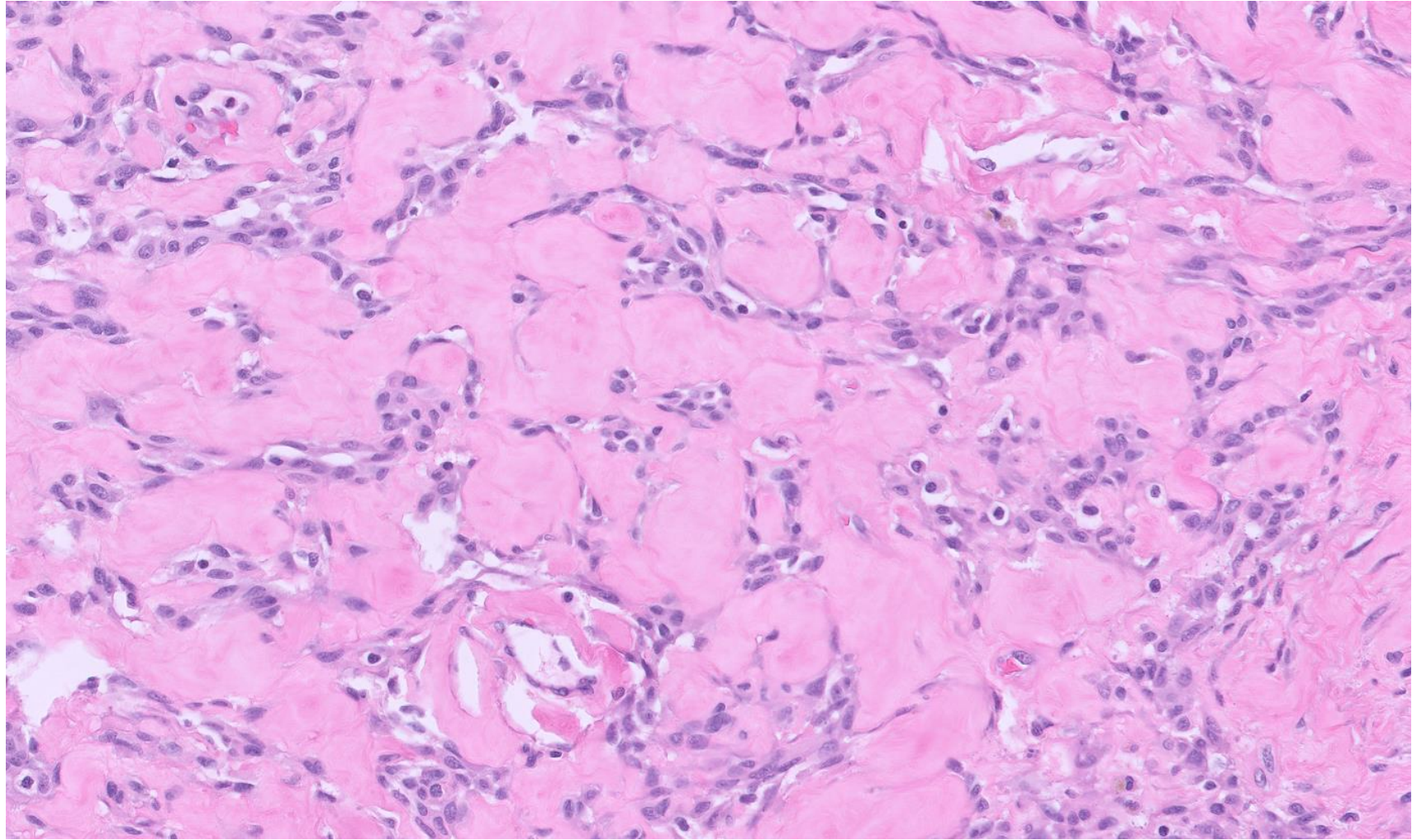


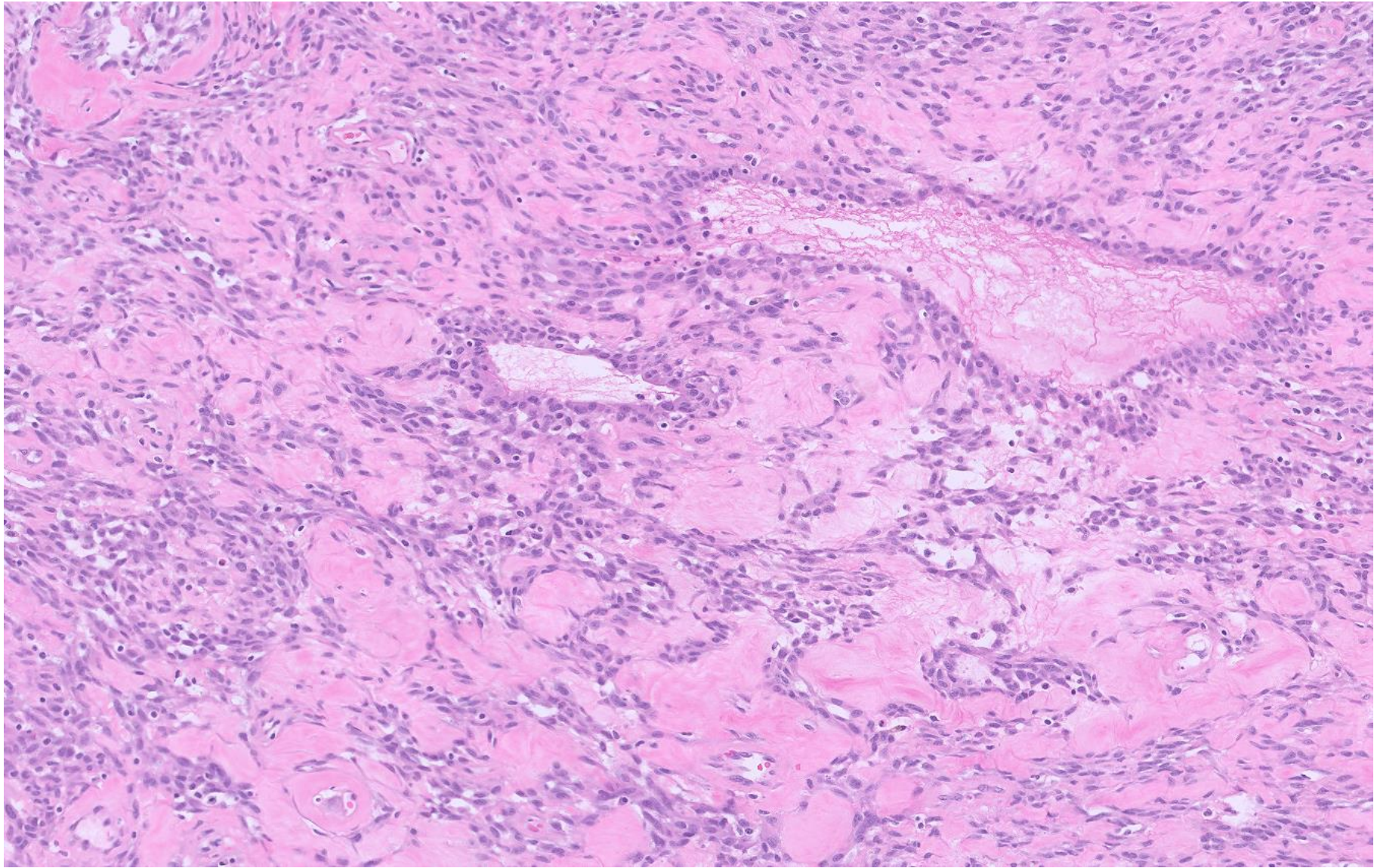


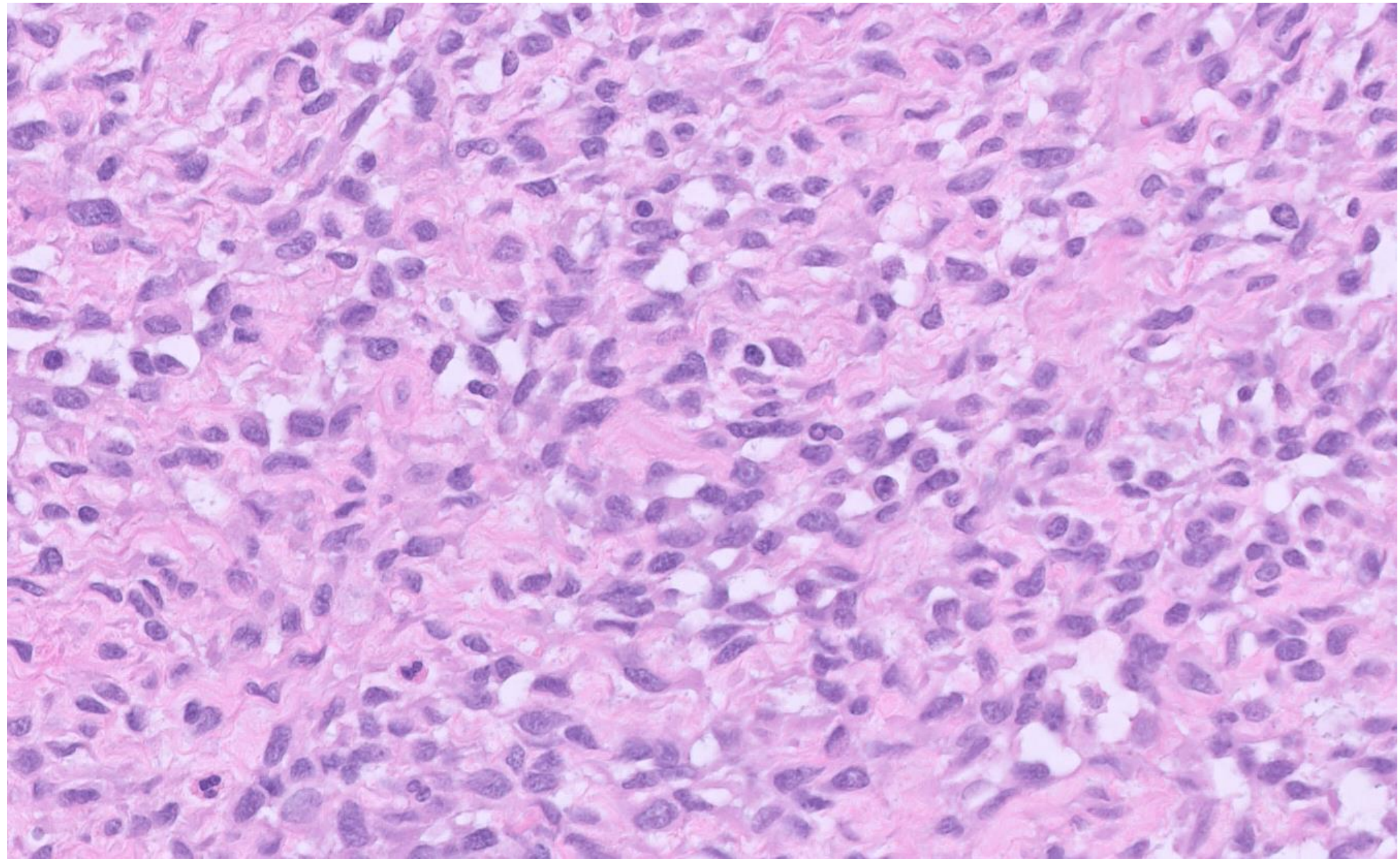


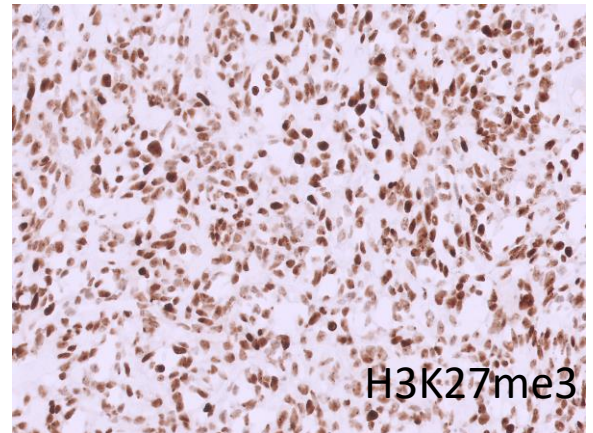
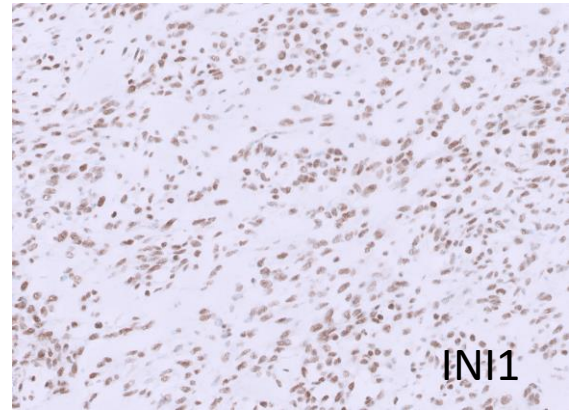
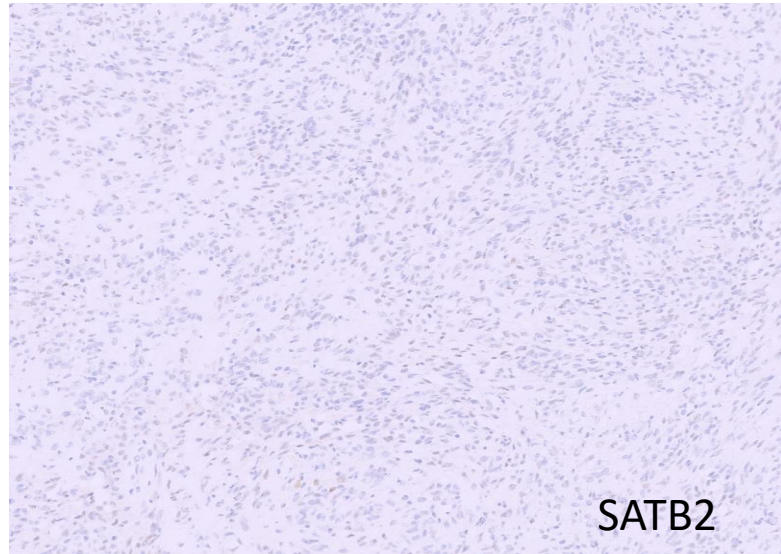
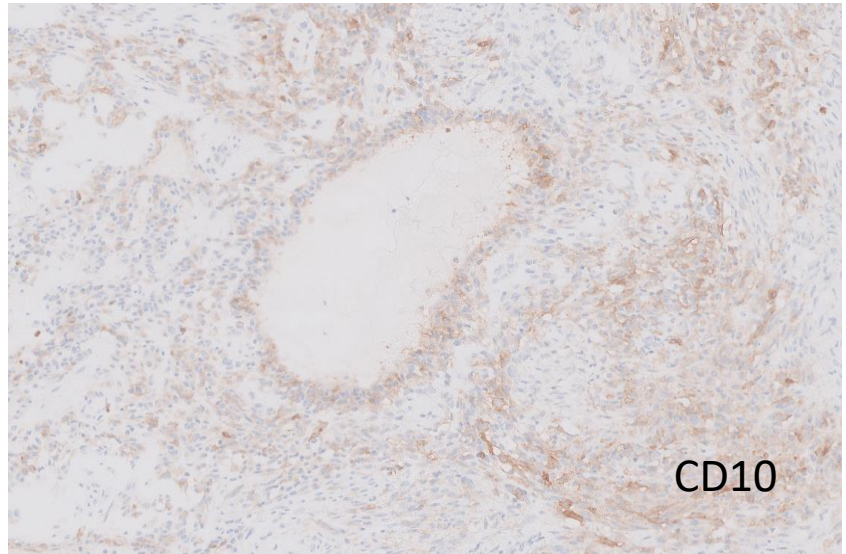
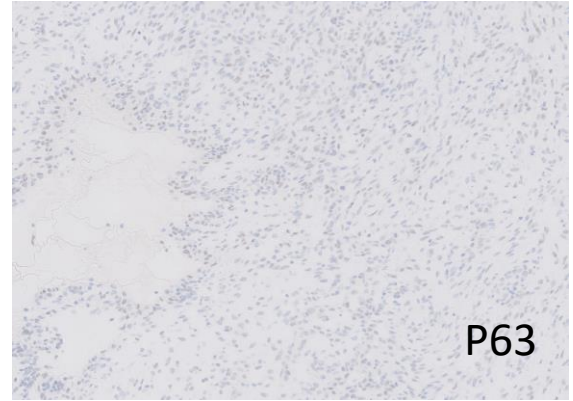
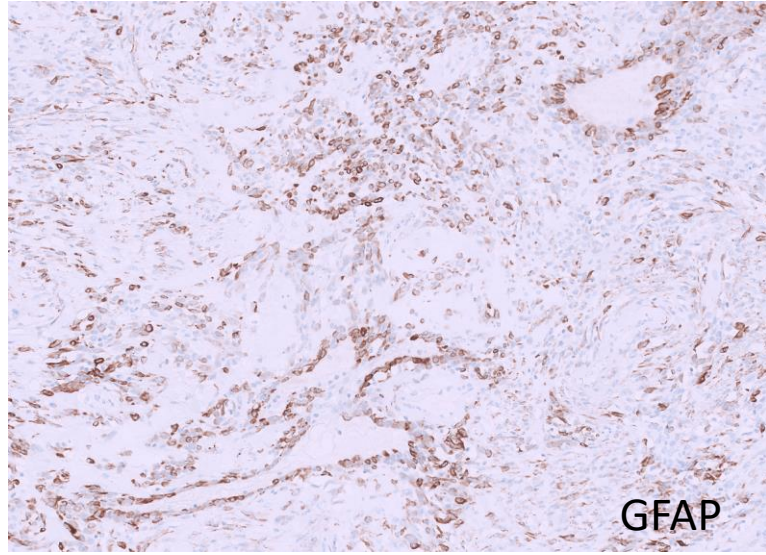
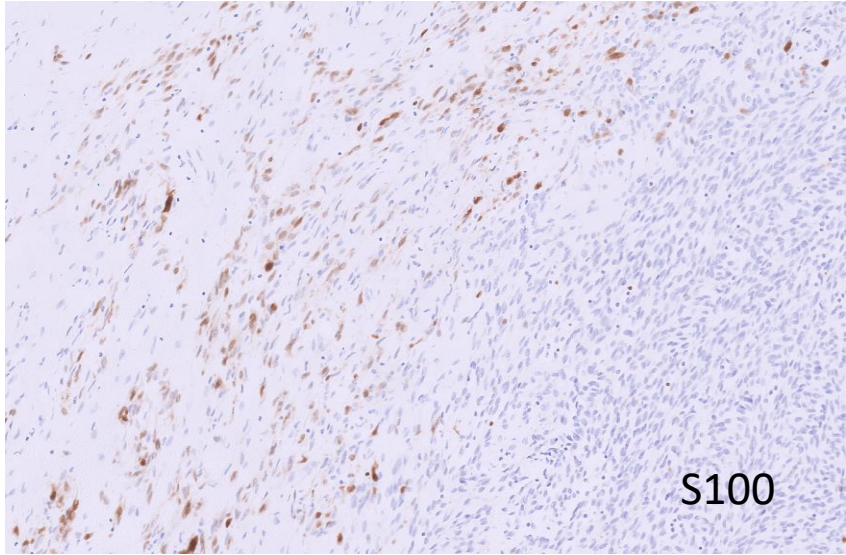












Negative stains

- CKMIX
- EMA
- ERG
- CD34
- SOX10
- SMA

DIAGNOSIS?

