

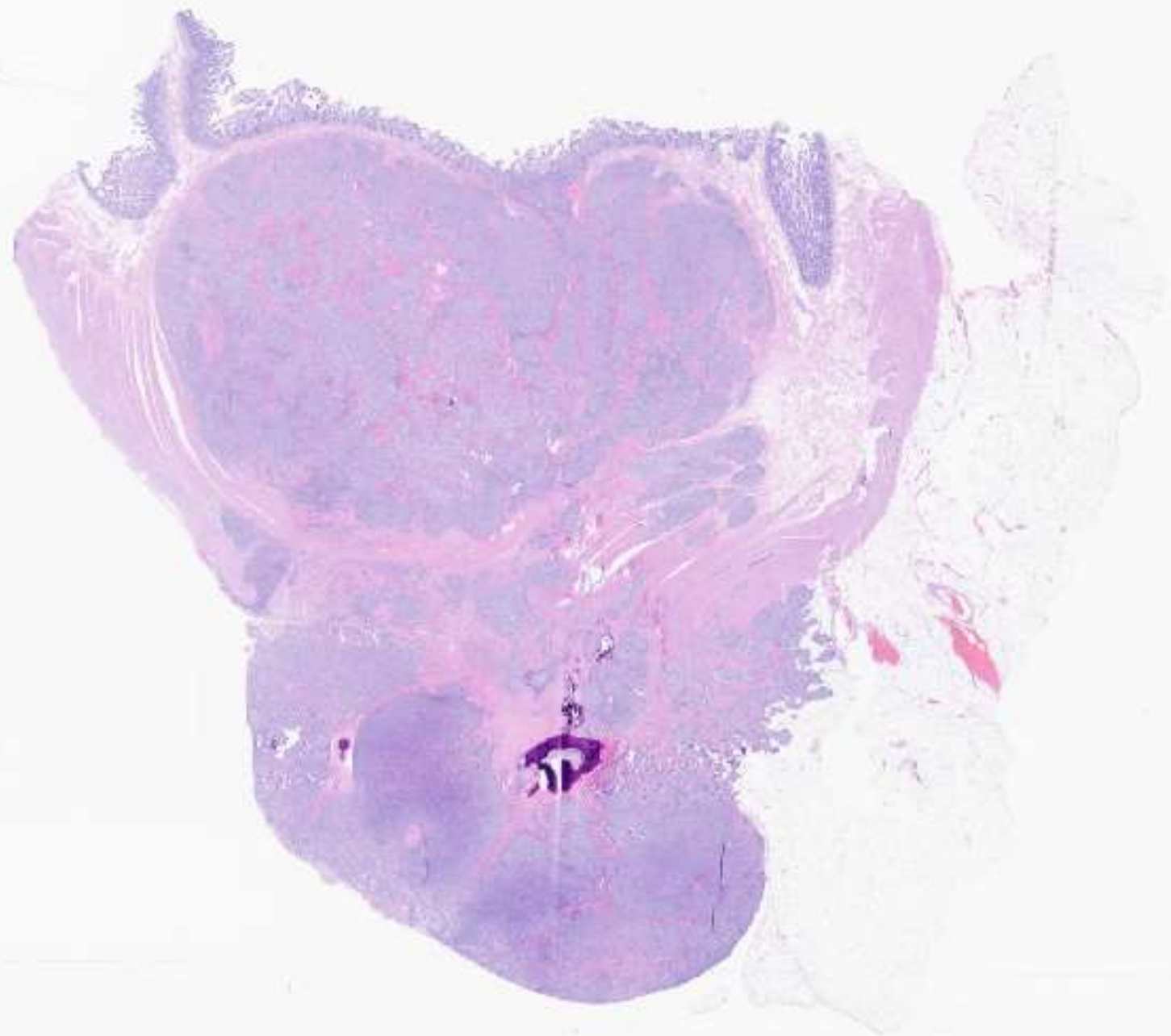
South Bay Pathology Society

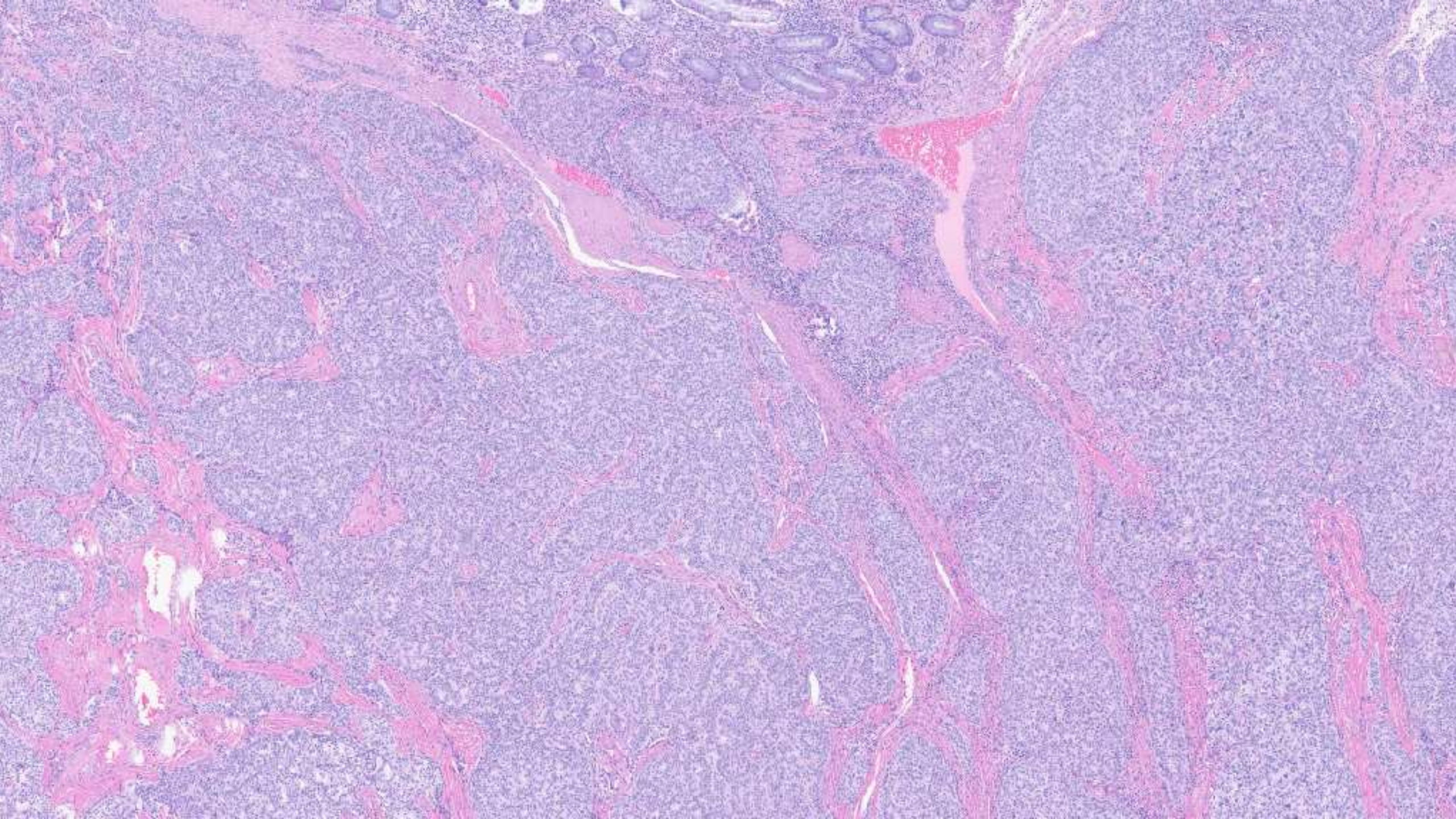
2024 Spring Meeting

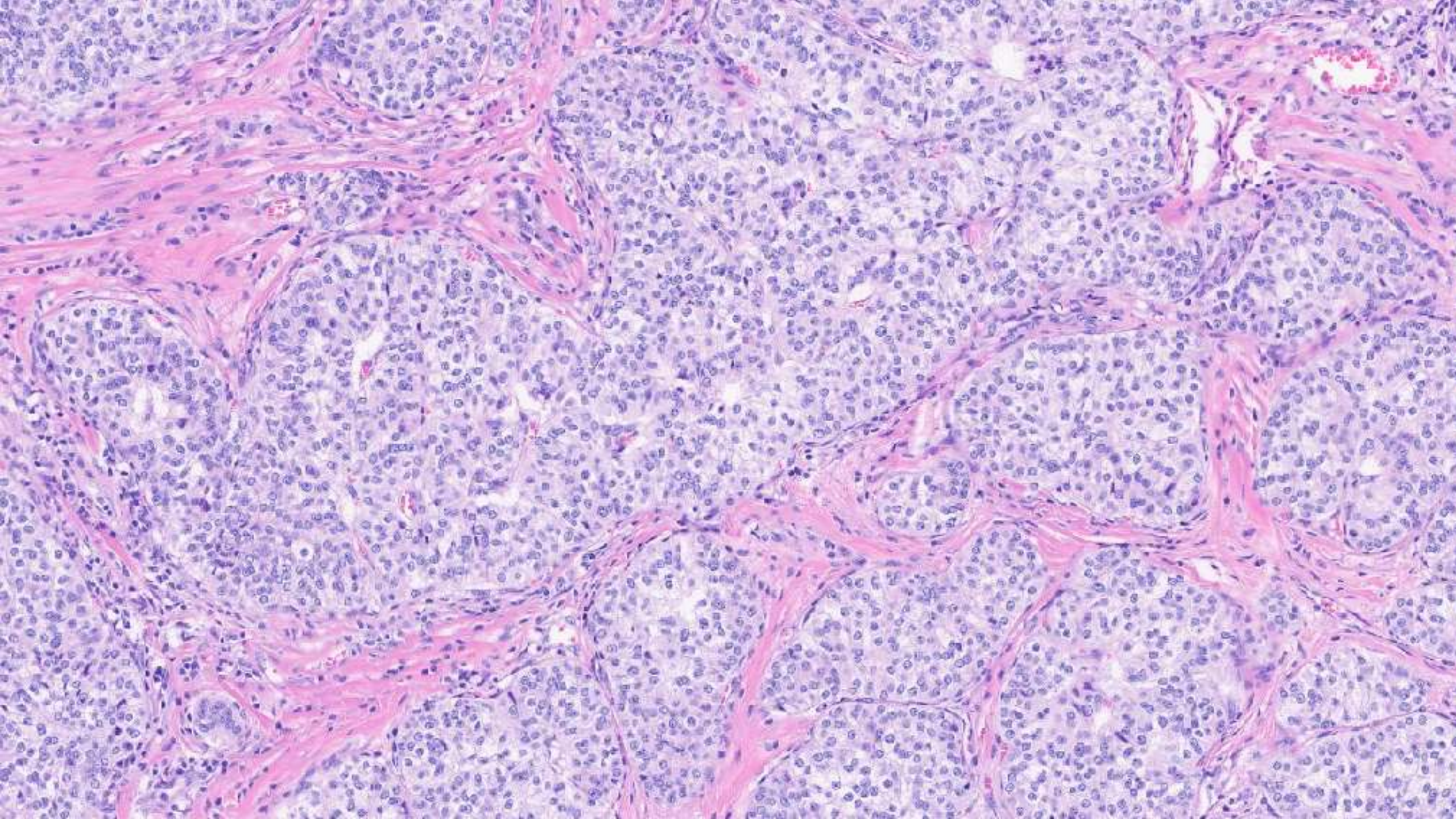
Case History and Images
Sanjay Kakar, UCSF

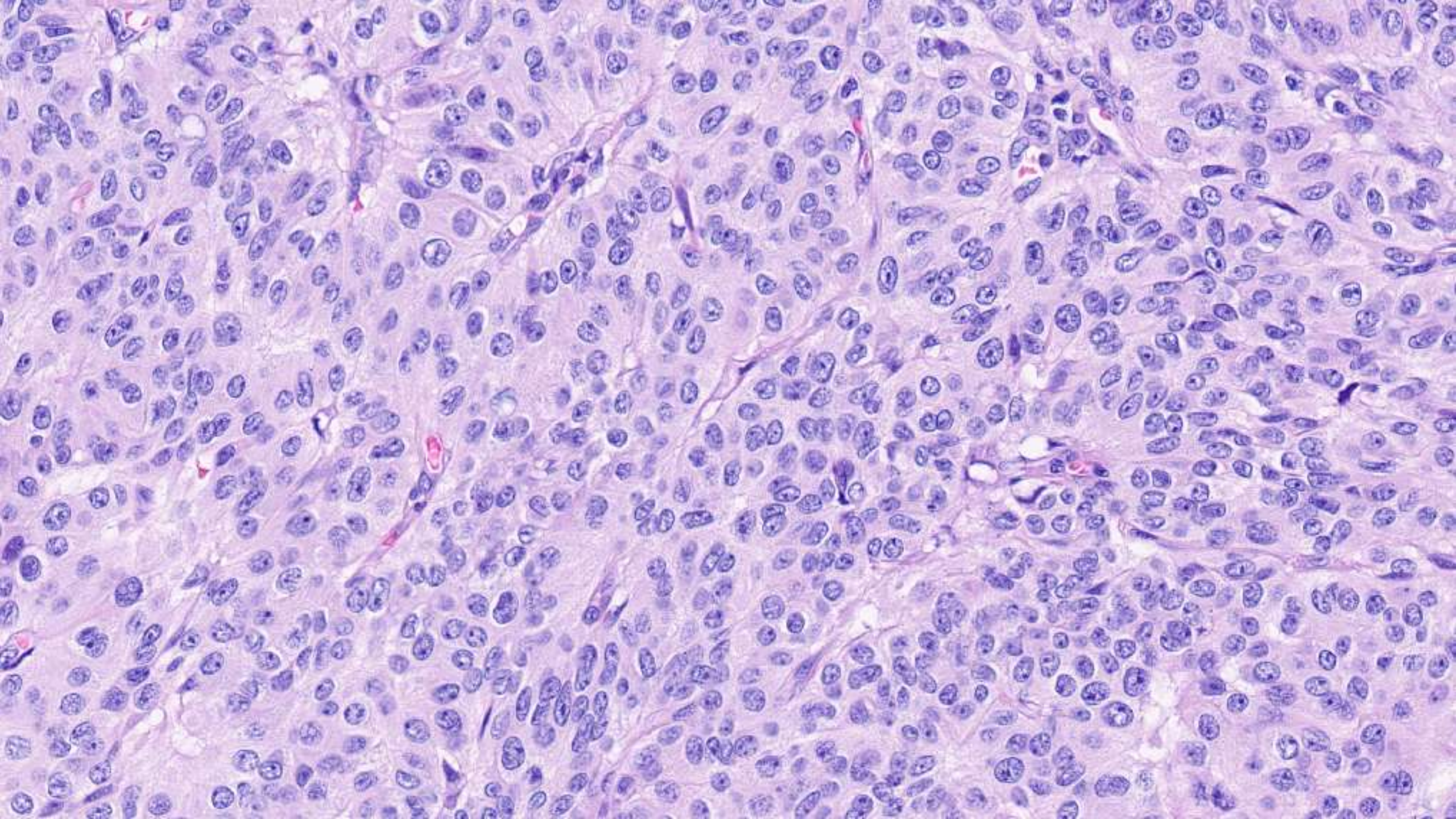
Case 1

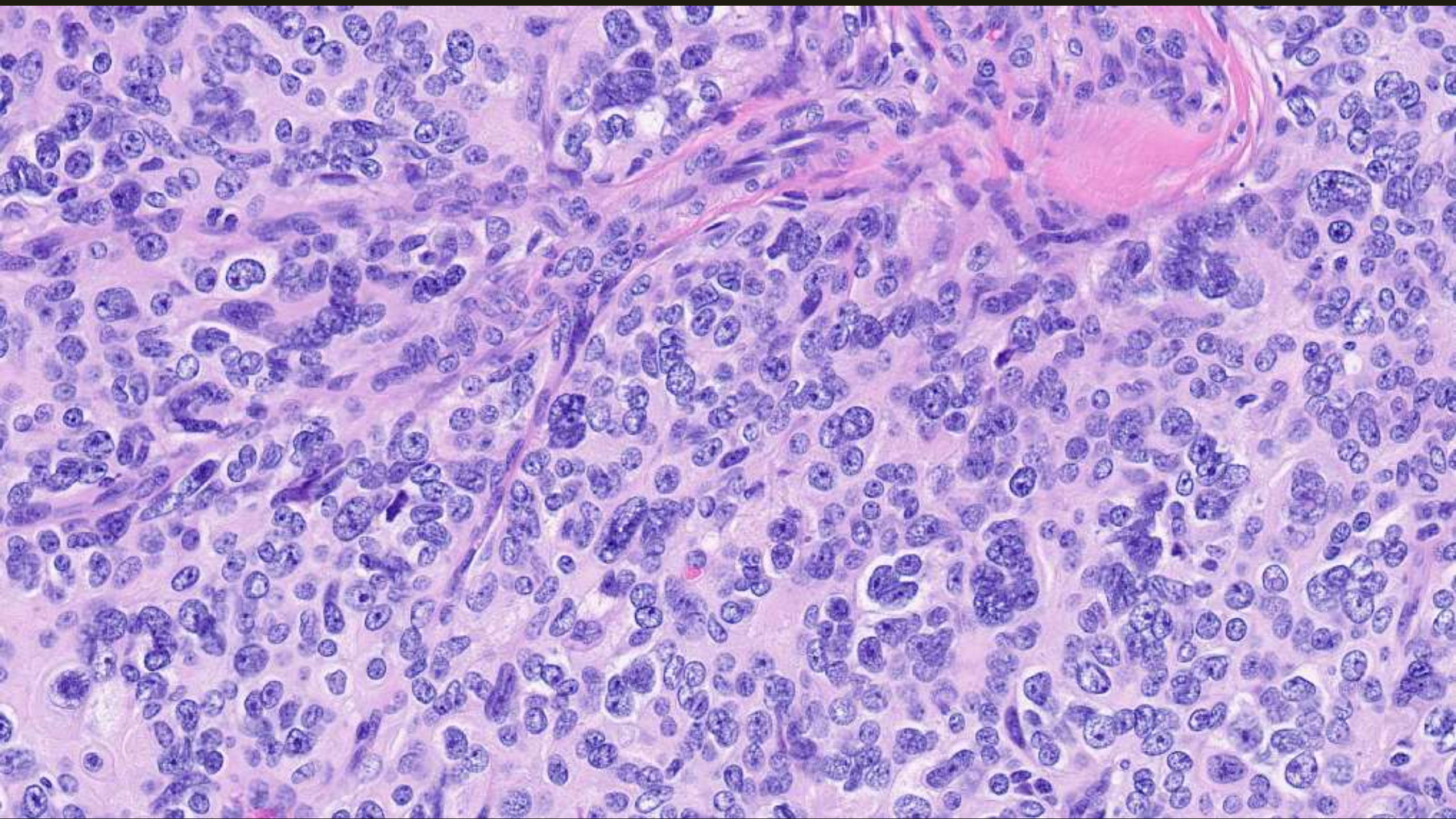
- 60/F with a 3 cm jejunal mass
- Segmental resection was performed



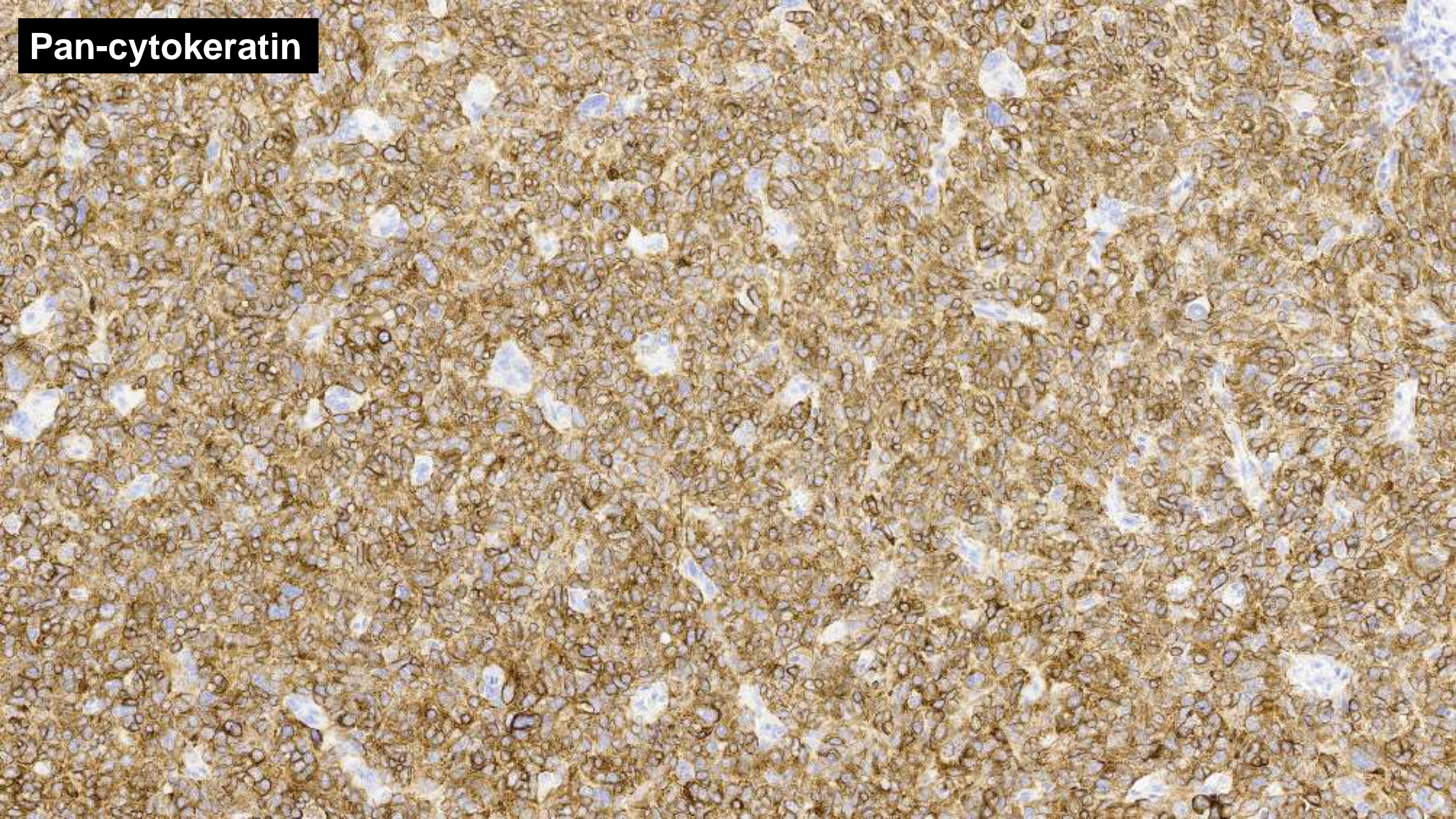




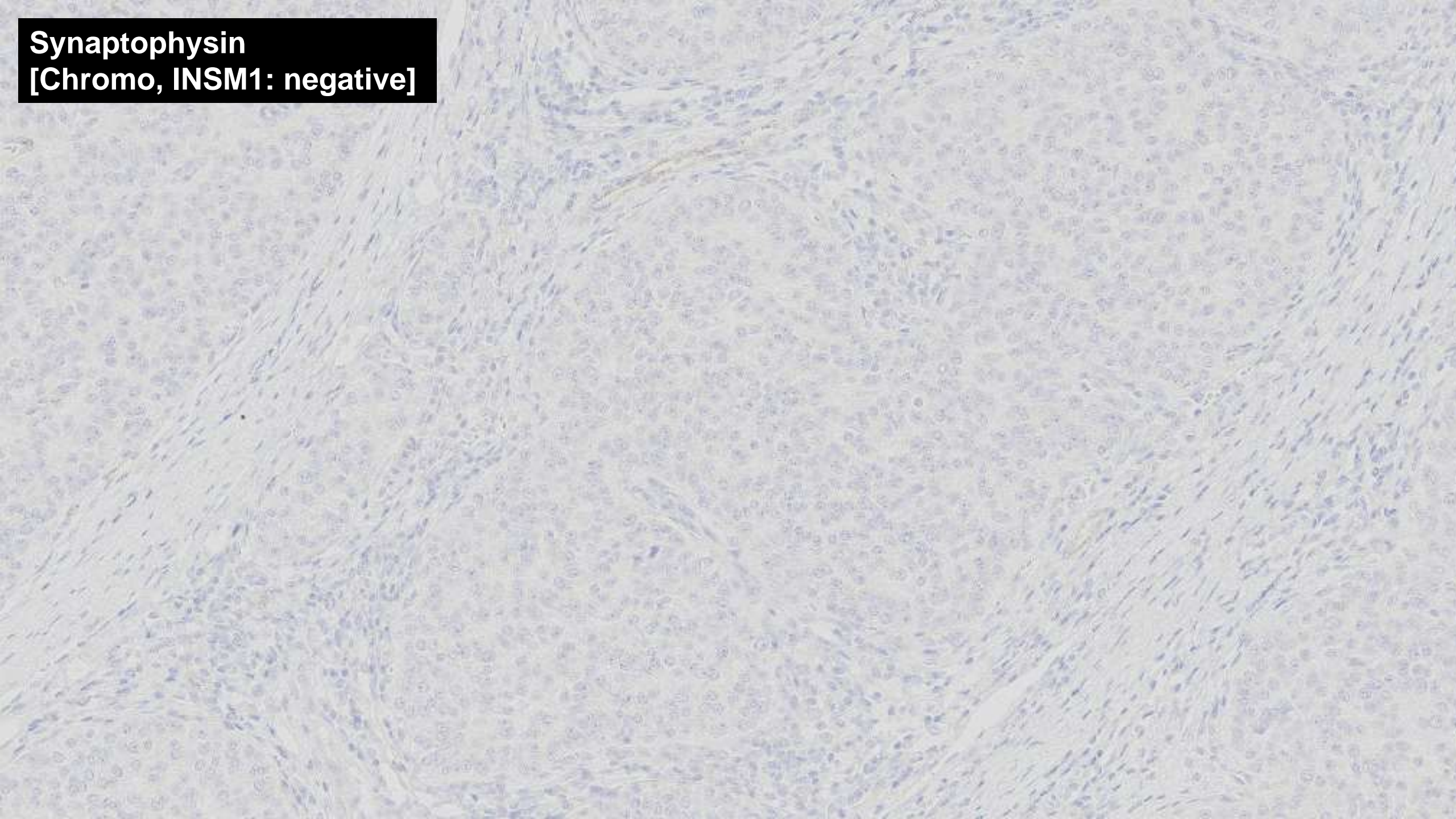




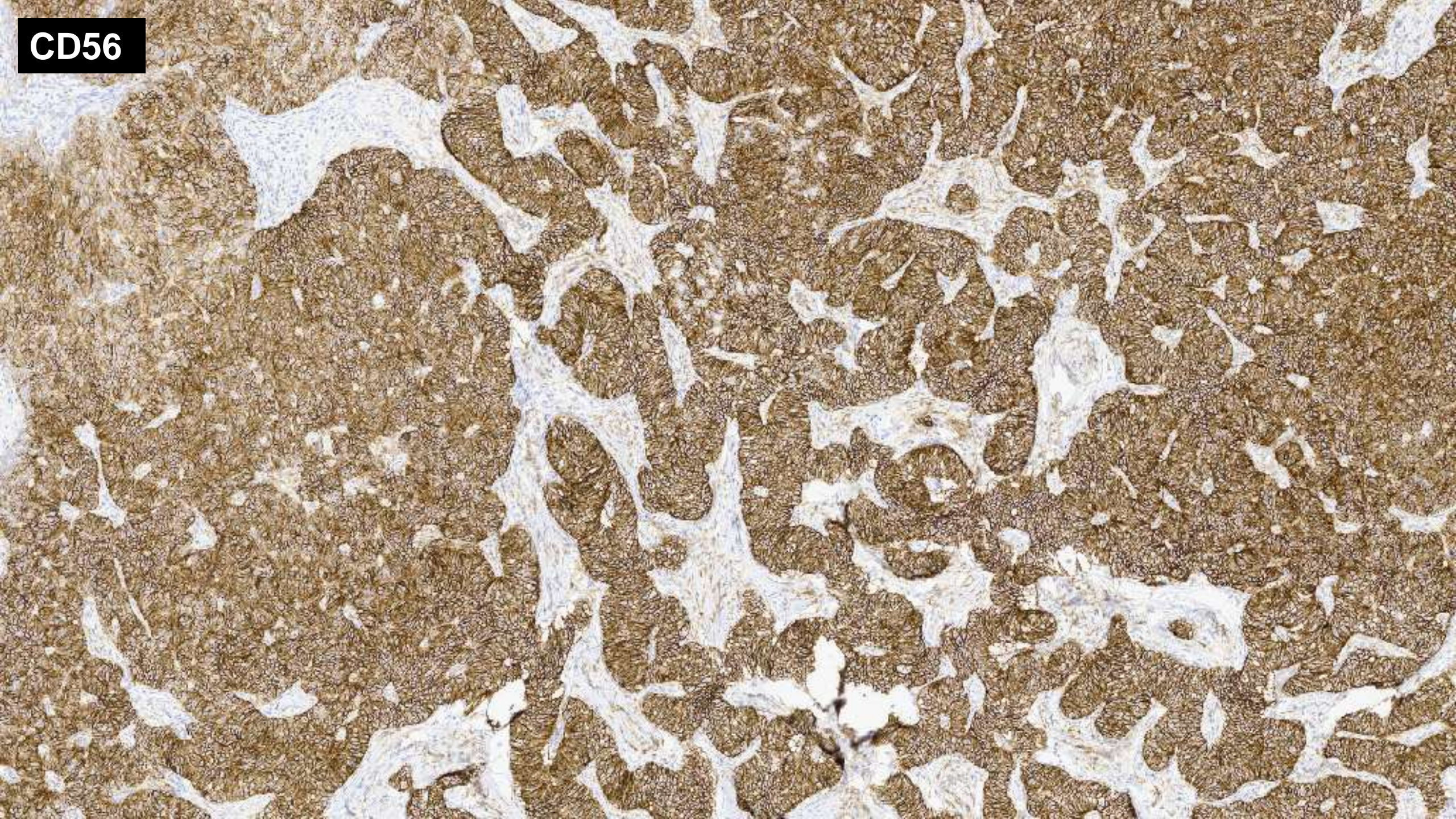
Pan-cytokeratin



Synaptophysin
[Chromo, INSM1: negative]

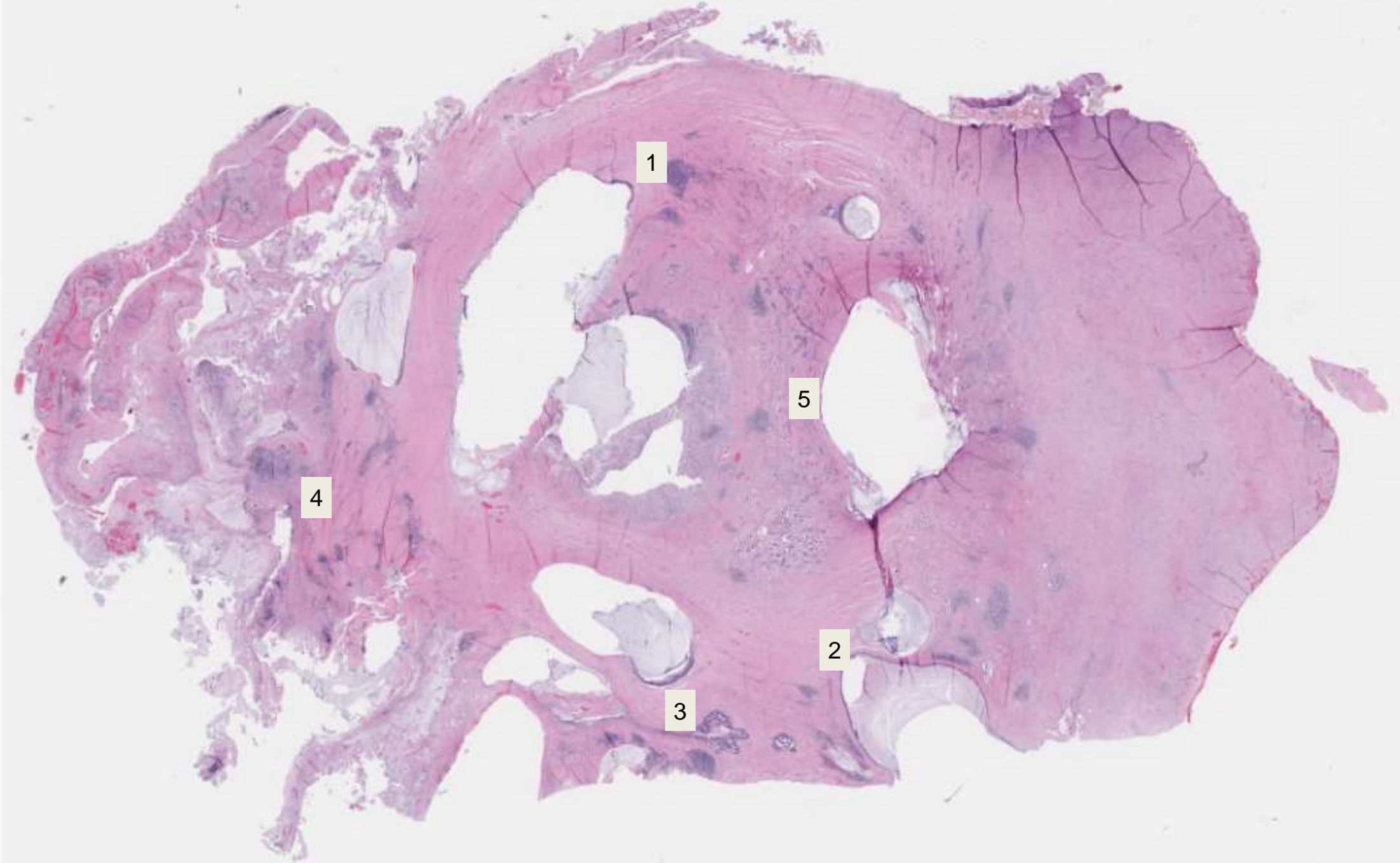


CD56

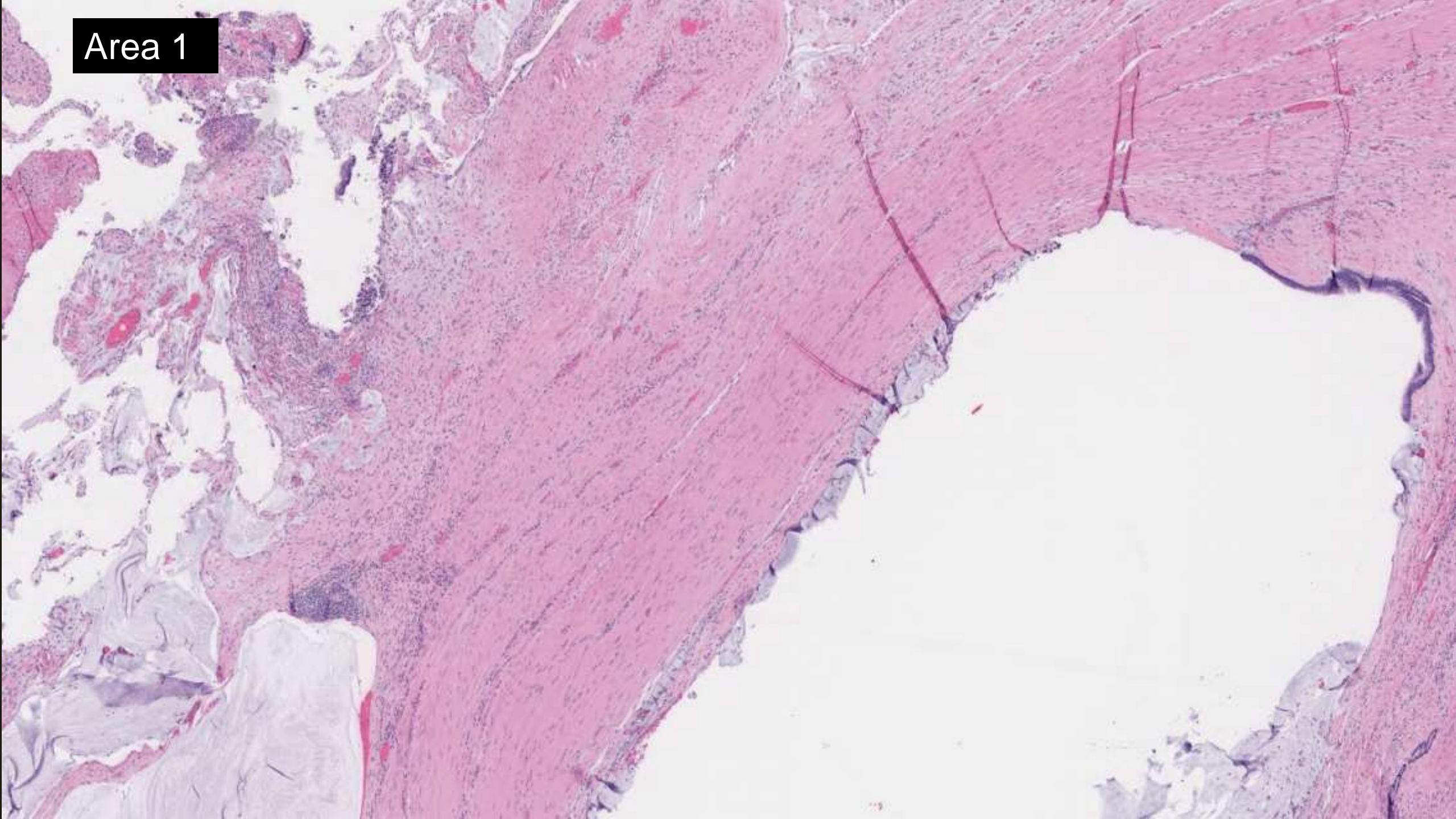


Case 2

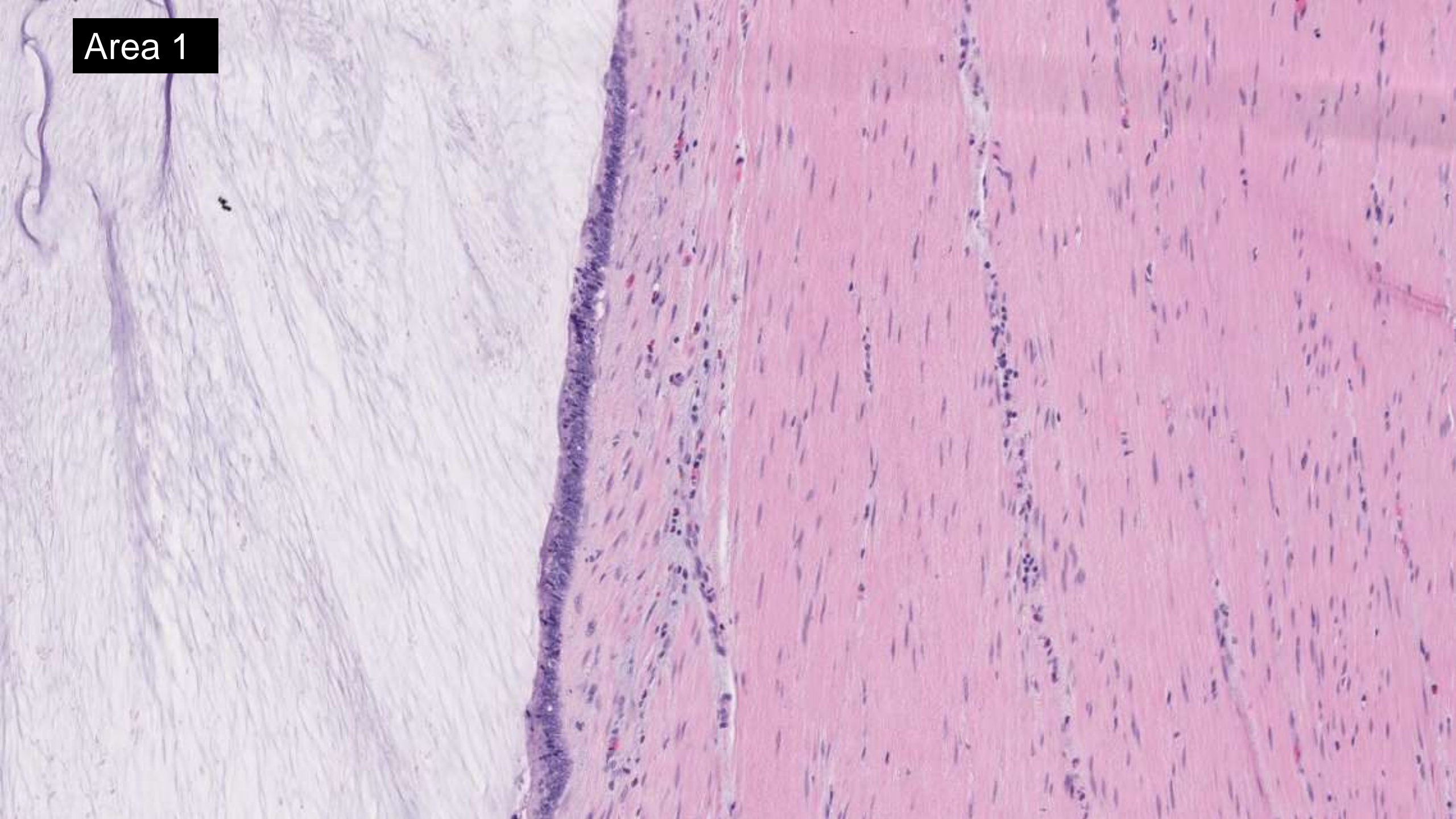
- **68/F with appendectomy for suspected appendicitis**
- **Serosal surface was extensively covered with mucoid material**
- **Lumen was dilated and filled with mucin. Multiple small cystic spaces with mucin in the wall throughout the length**



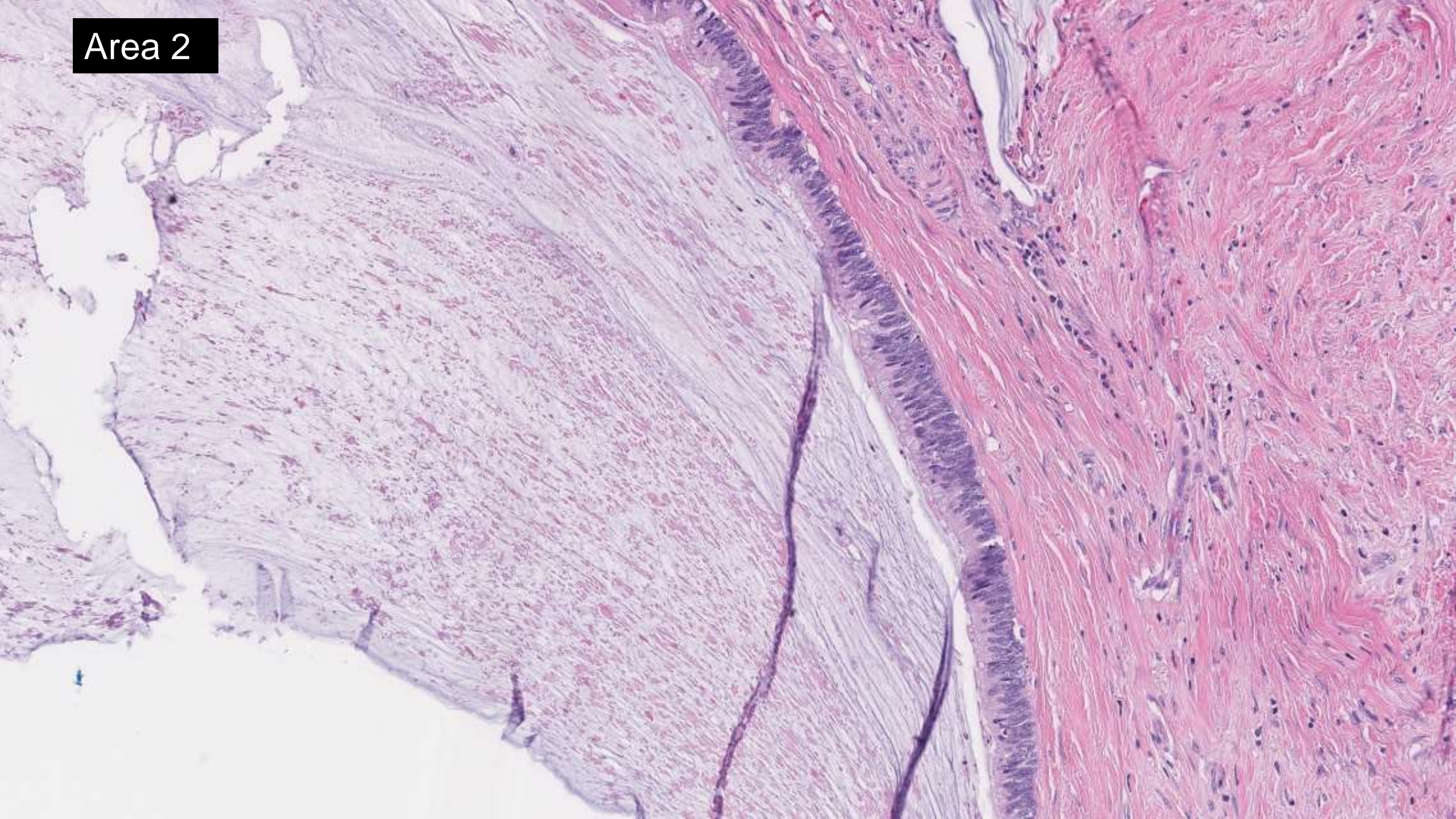
Area 1



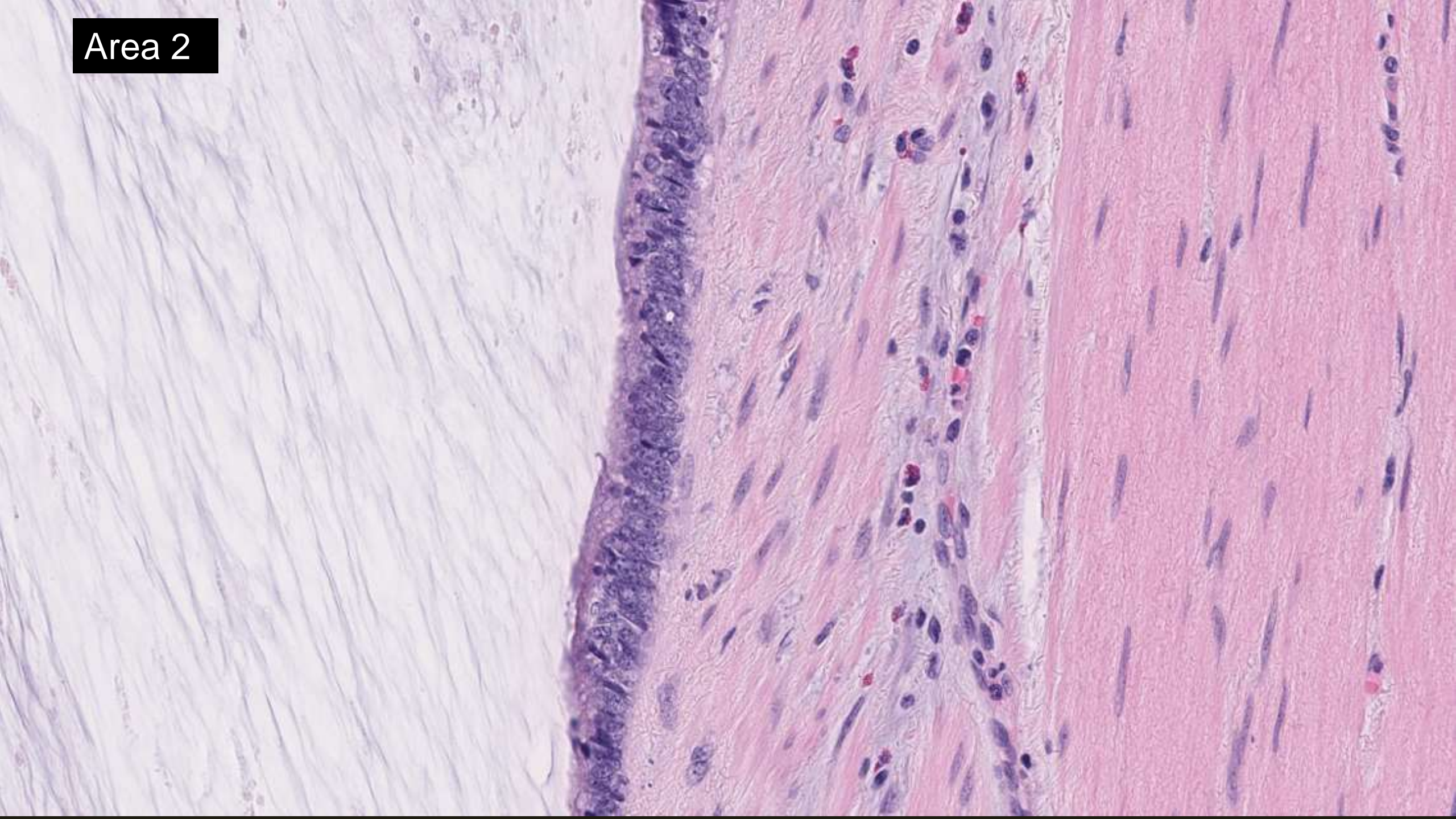
Area 1



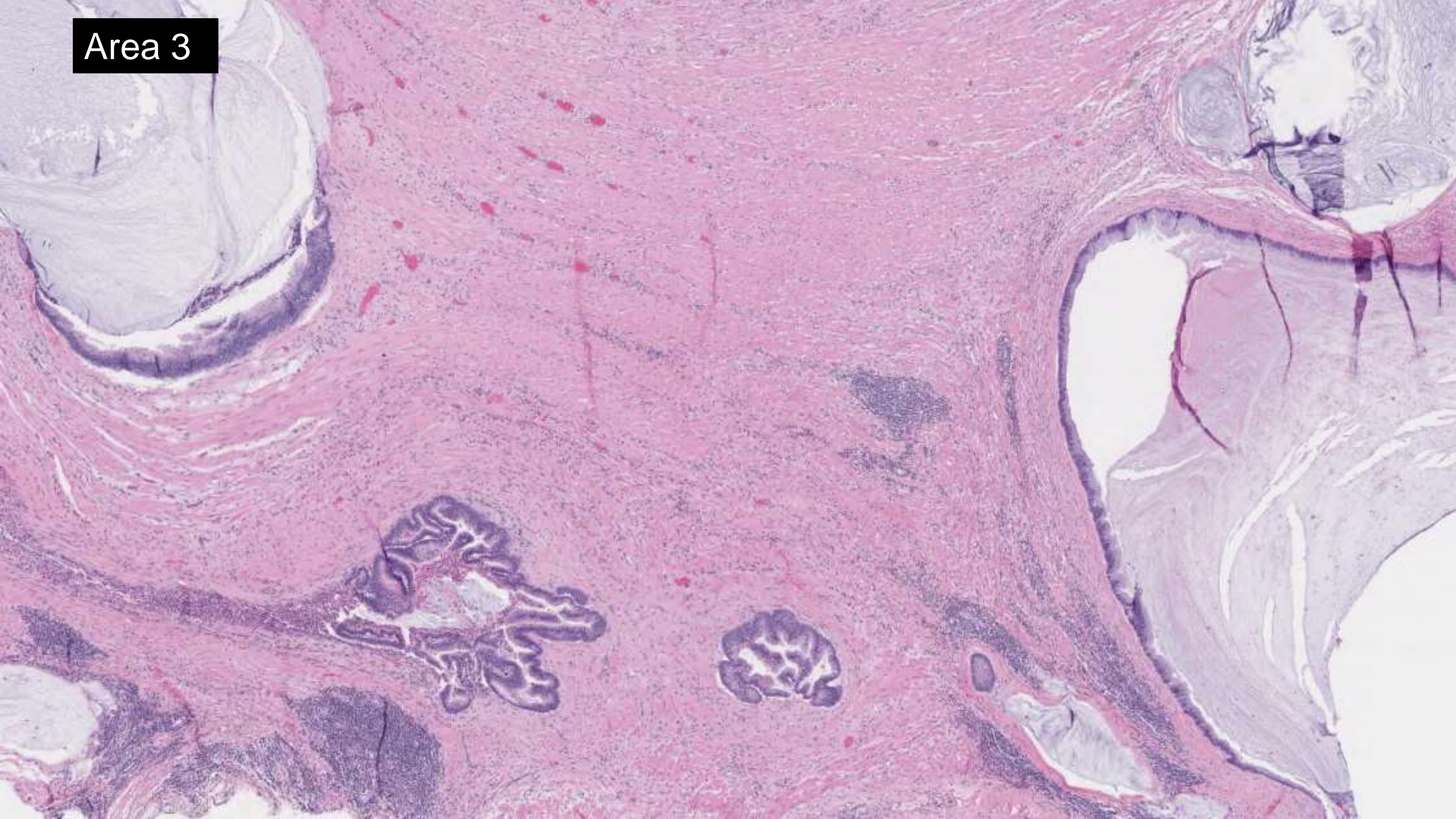
Area 2



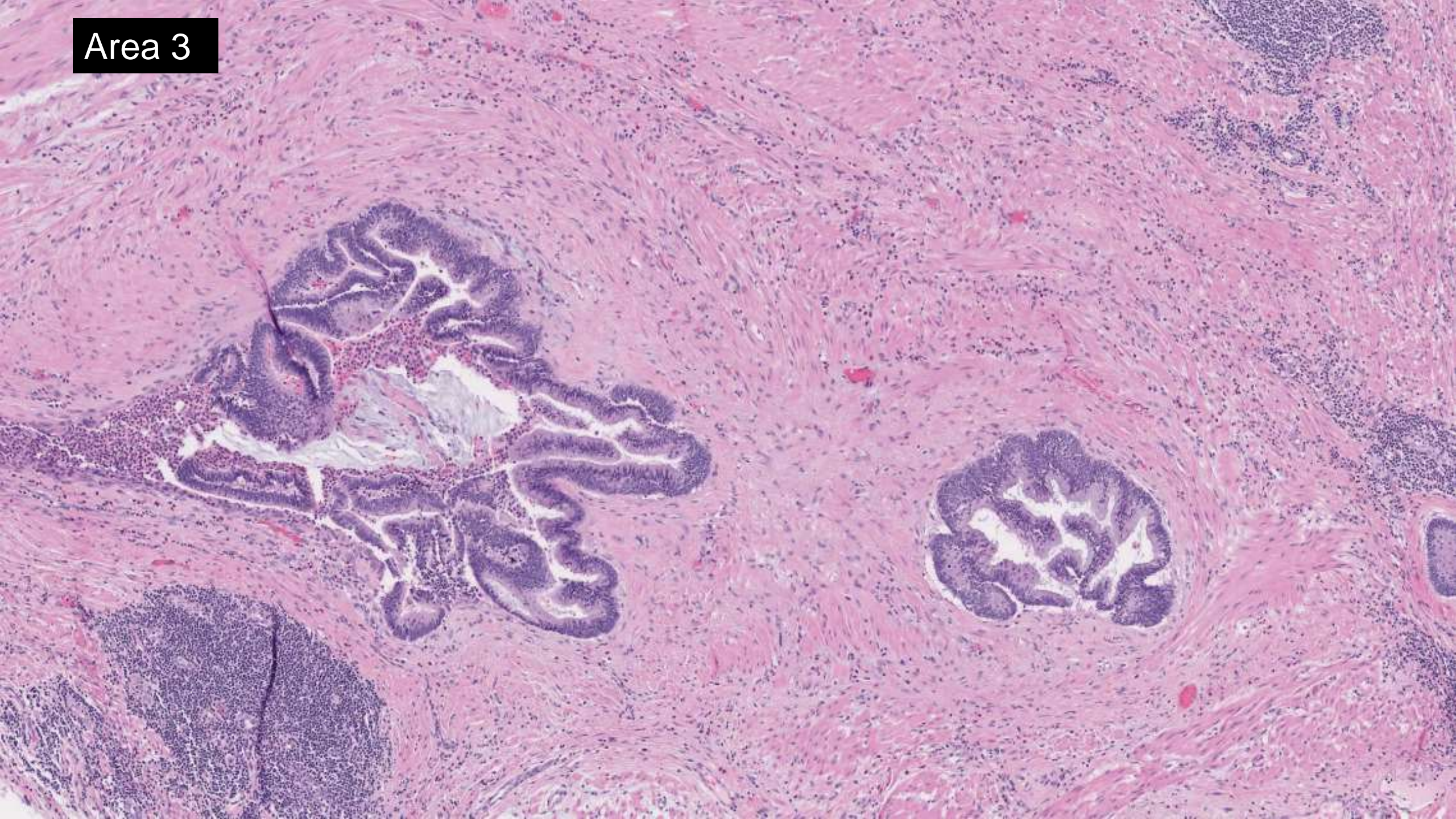
Area 2



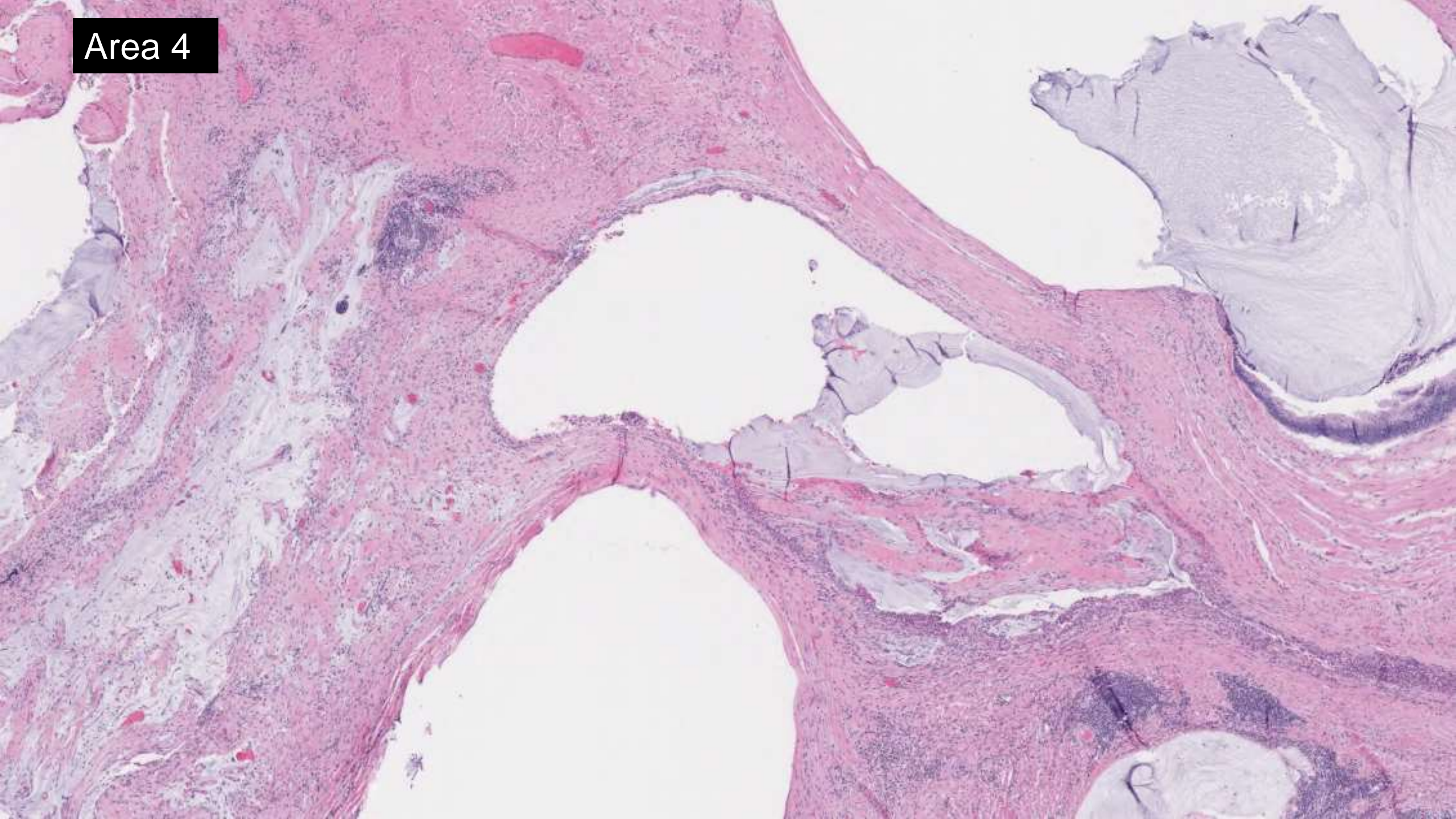
Area 3



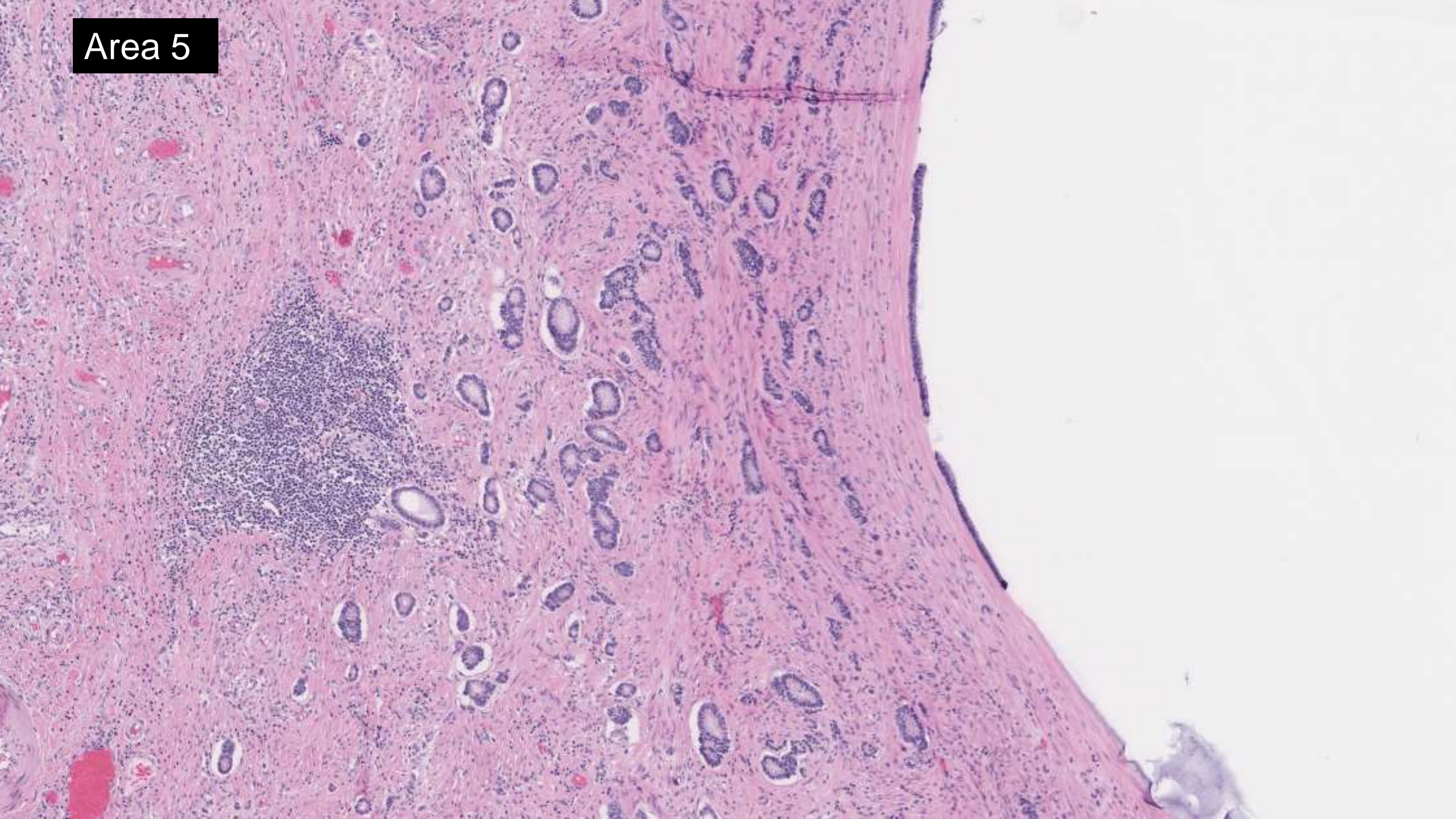
Area 3



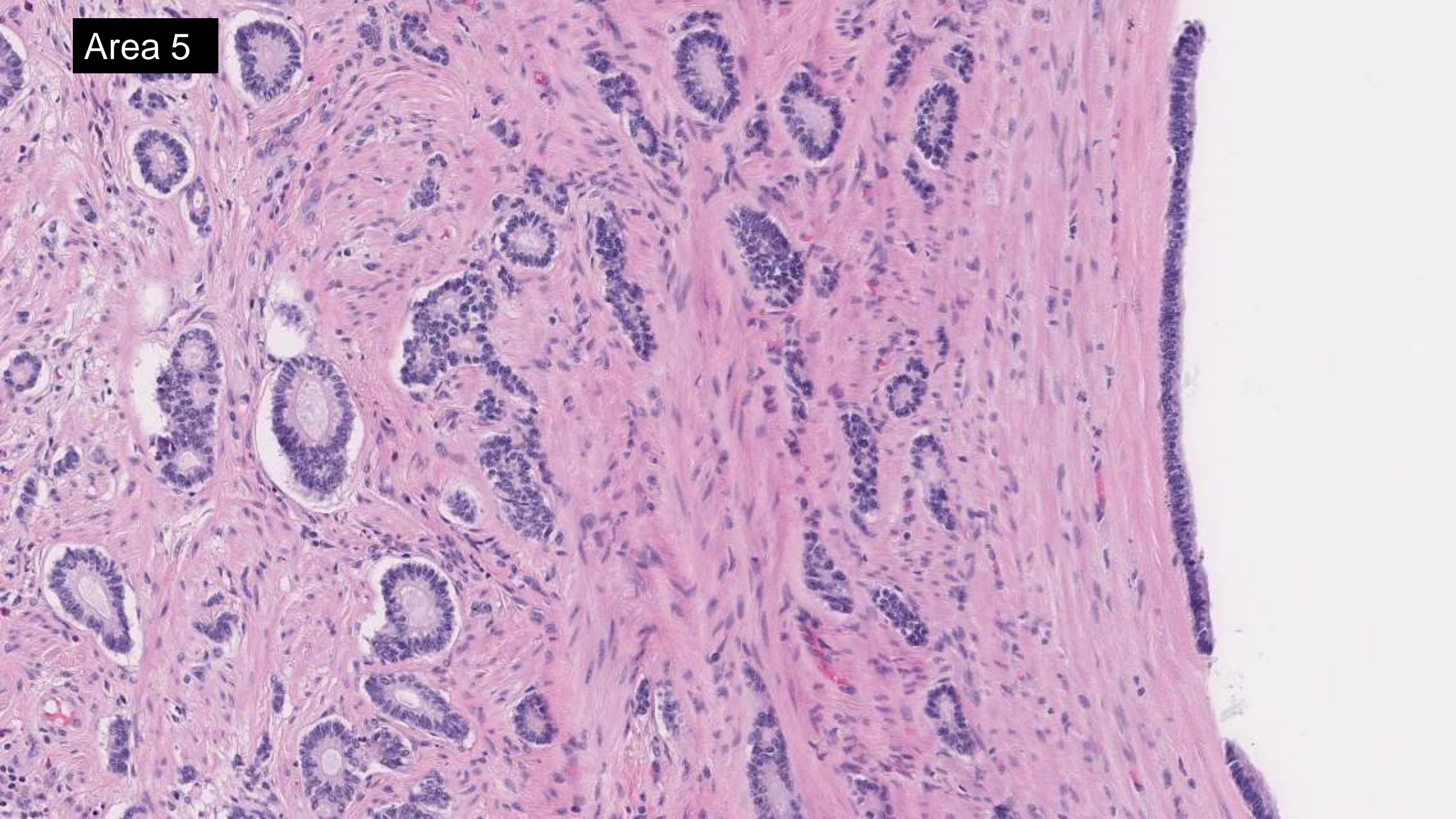
Area 4



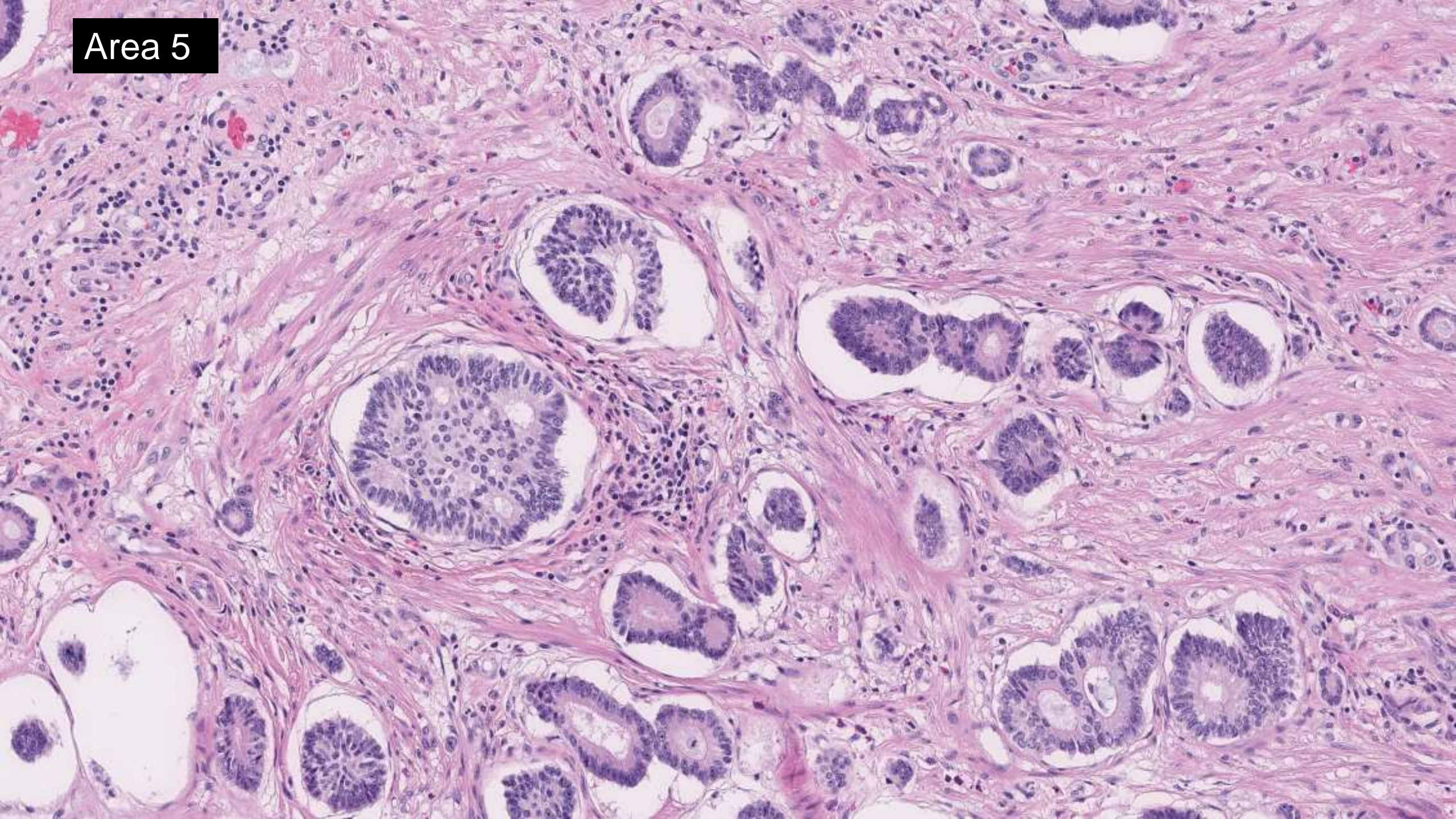
Area 5



Area 5



Area 5



Area 5

