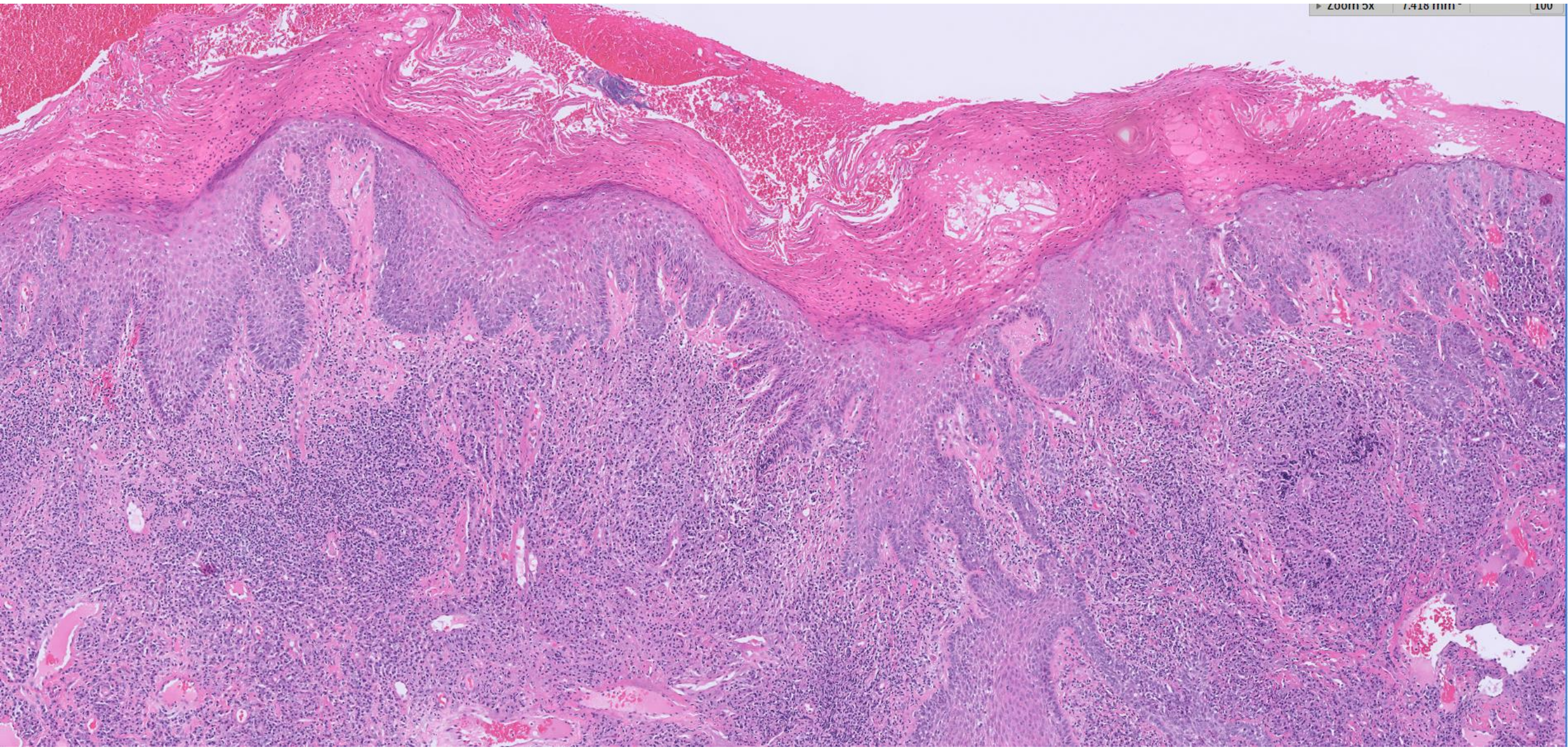


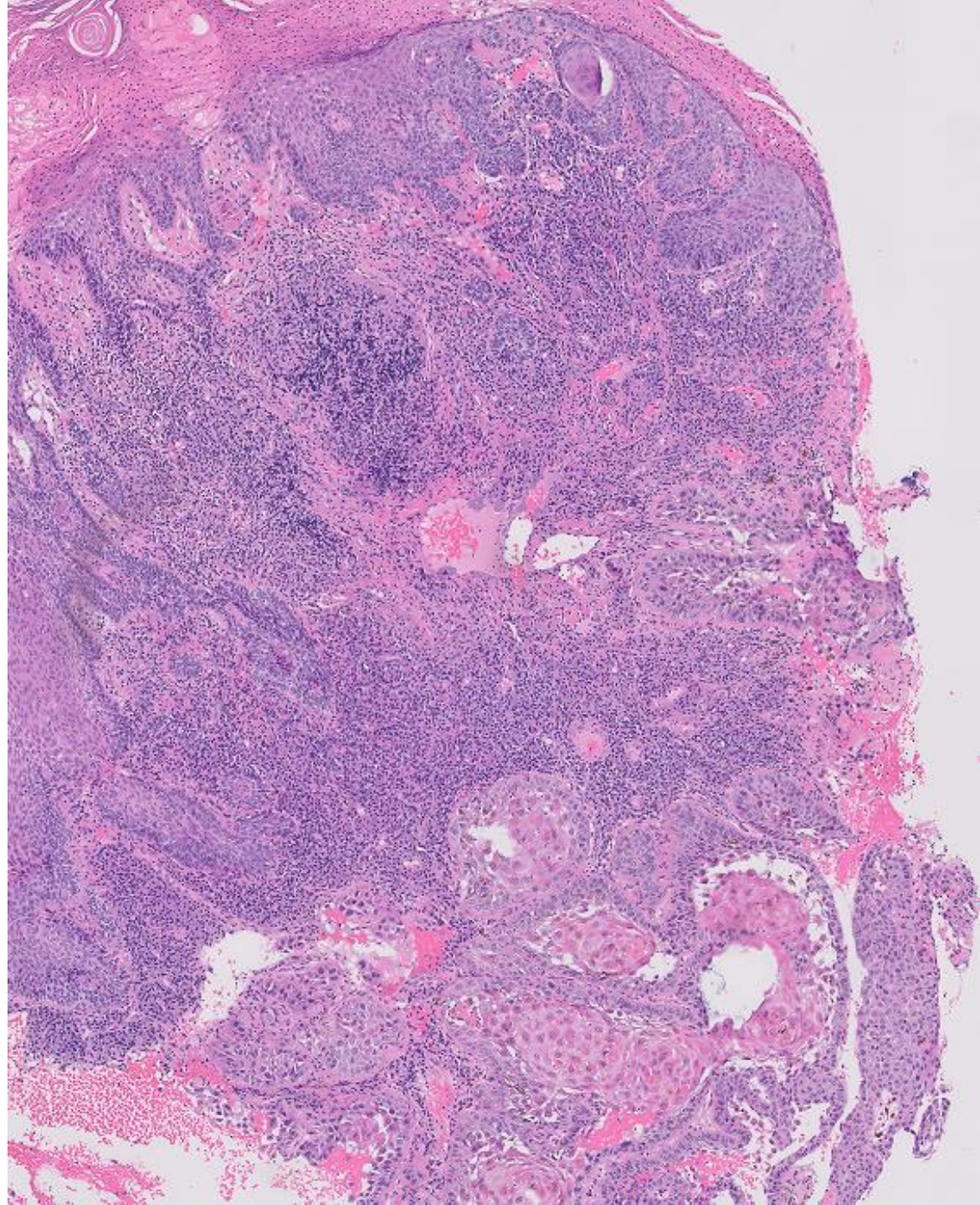
# Southbay April 2024 Webcases

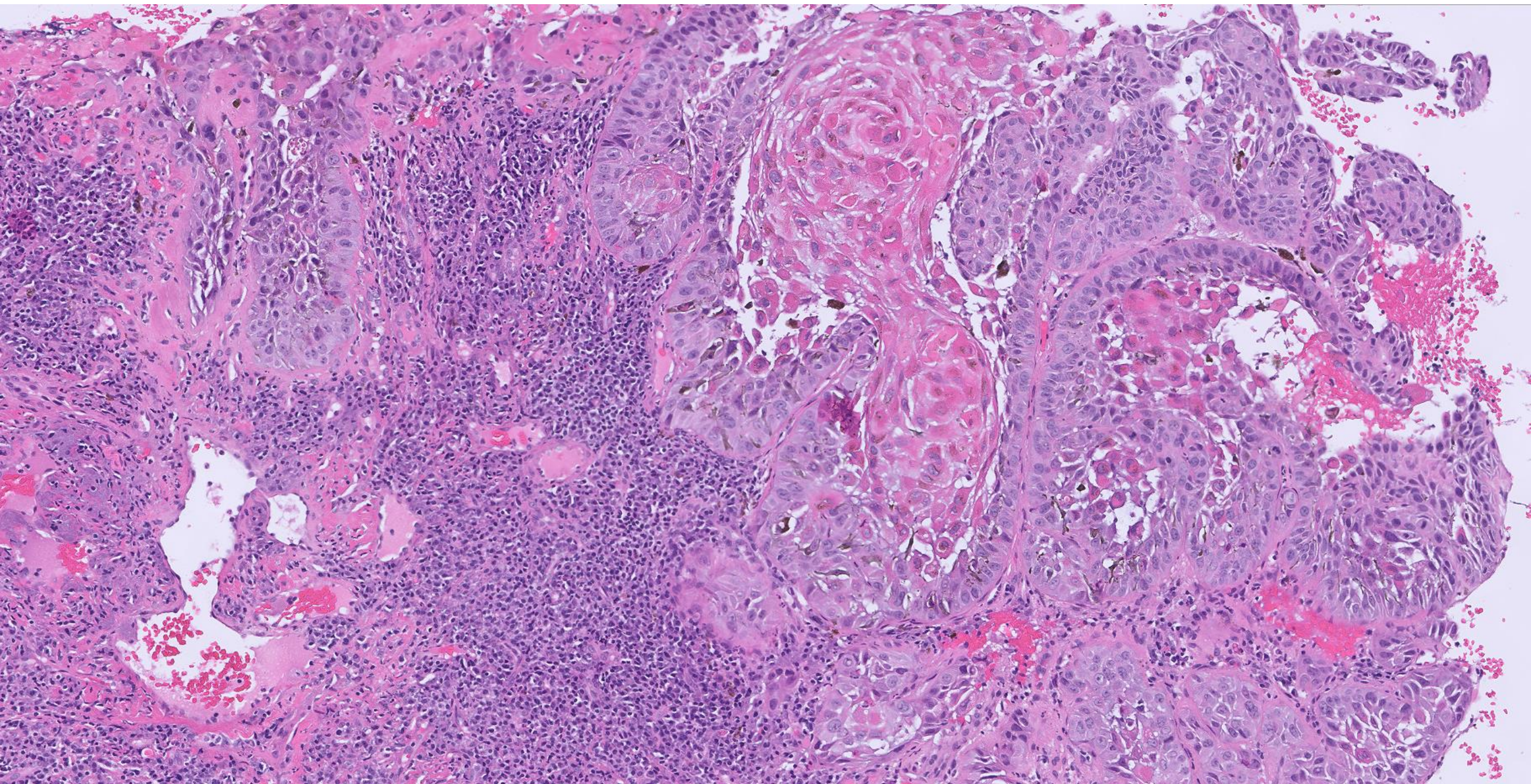
24-0401

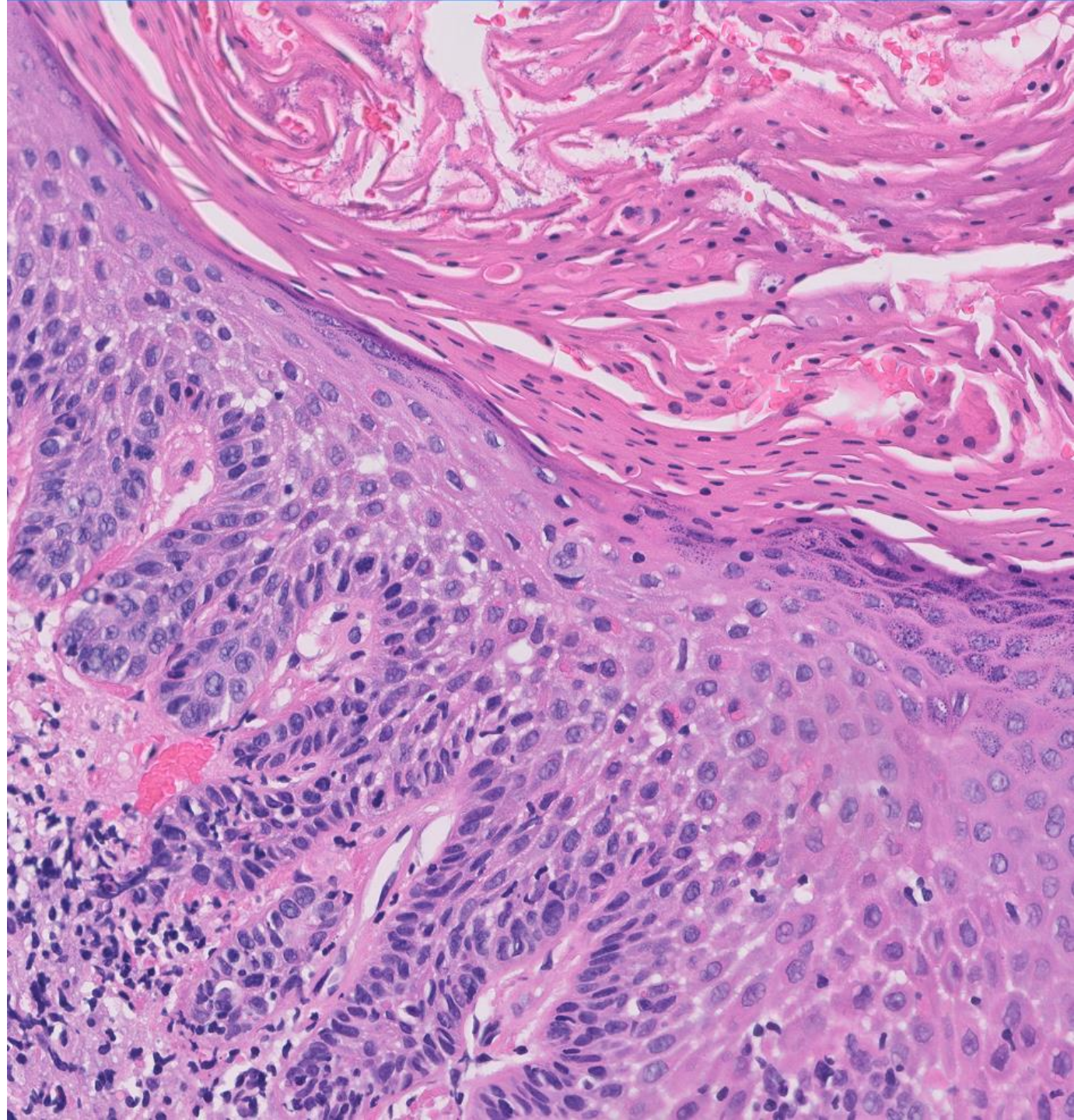
Ashley Monsrud; Stanford

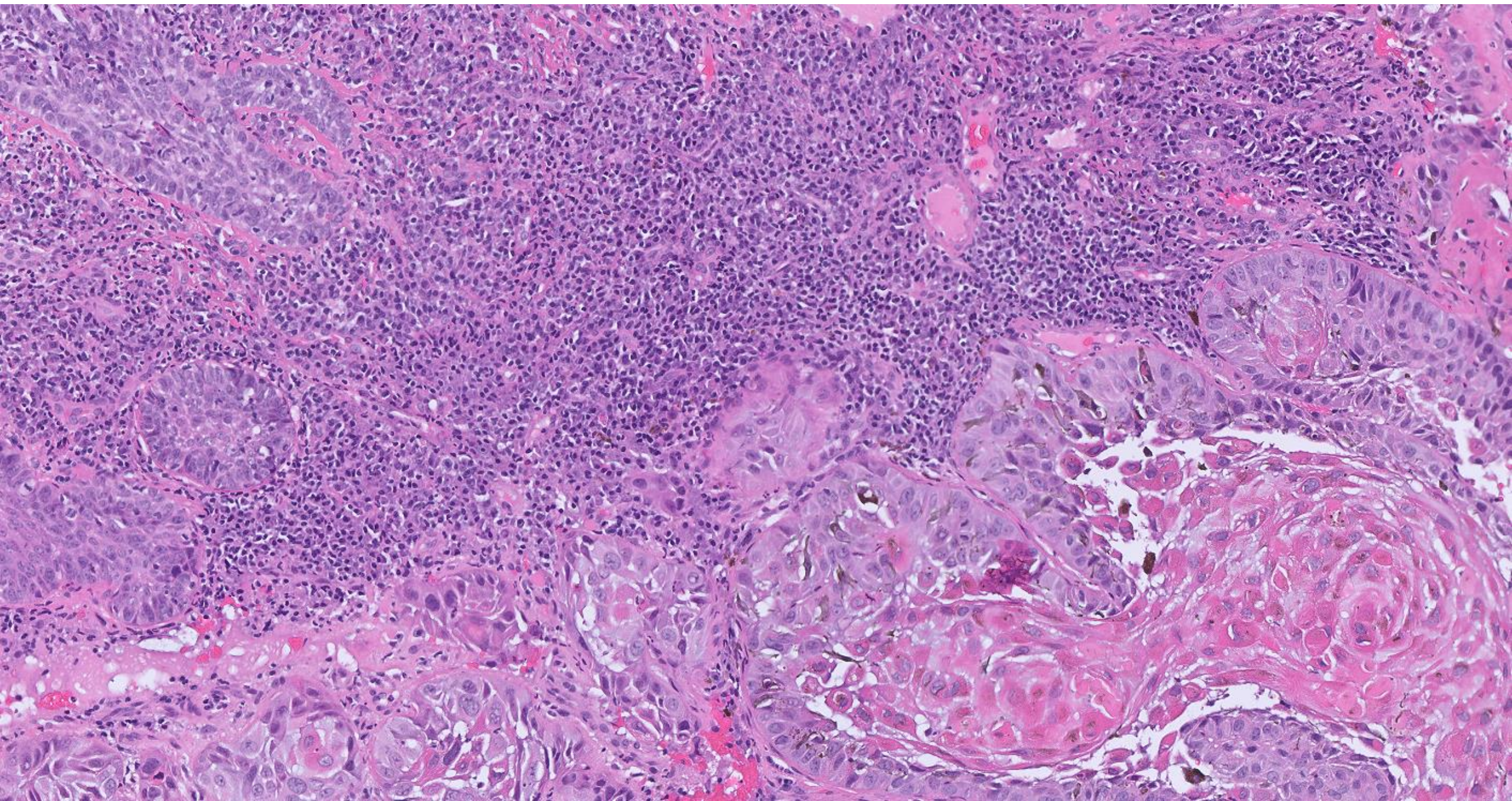
71-year-old female with a 4 cm vulvar mass

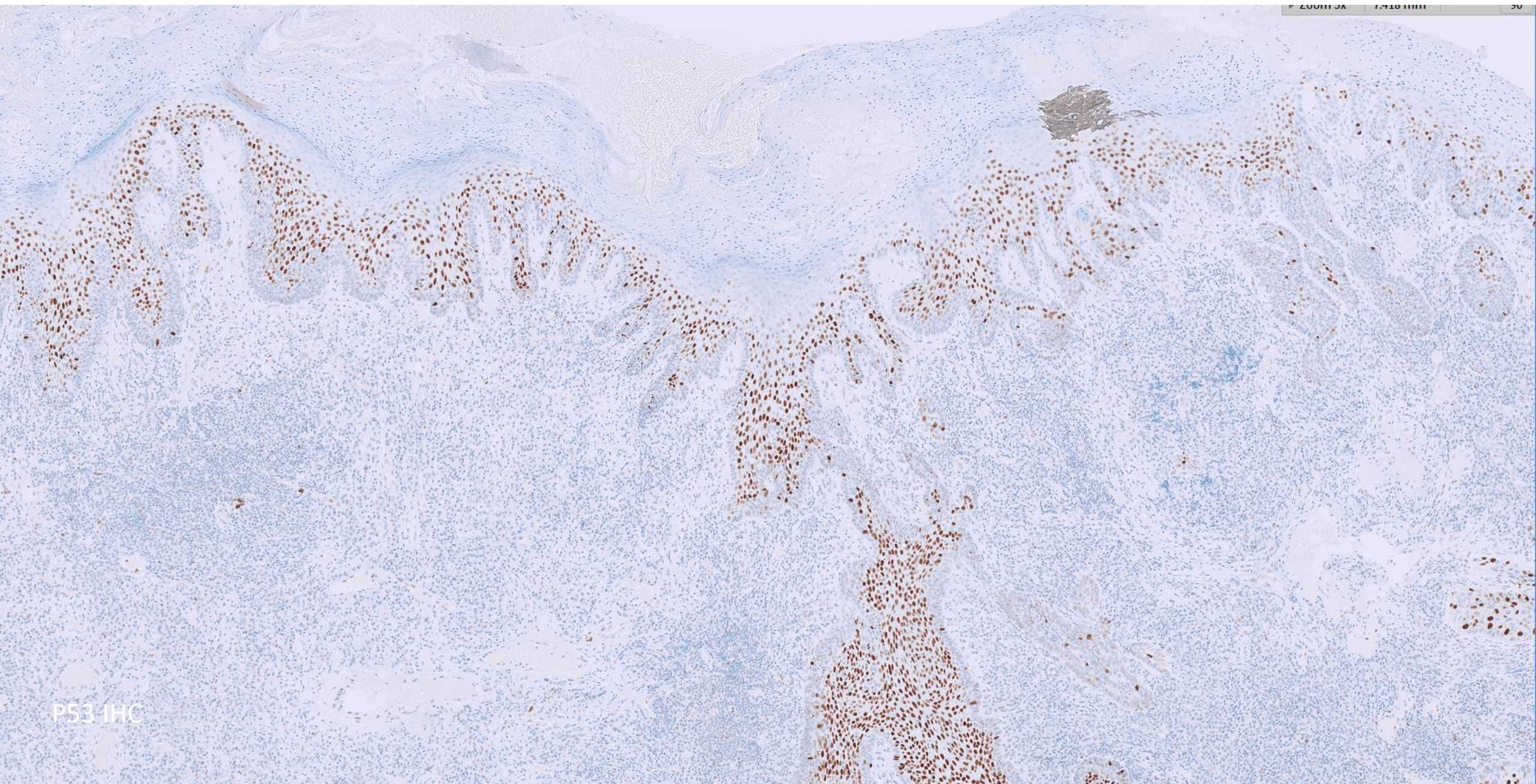












P53 IHC

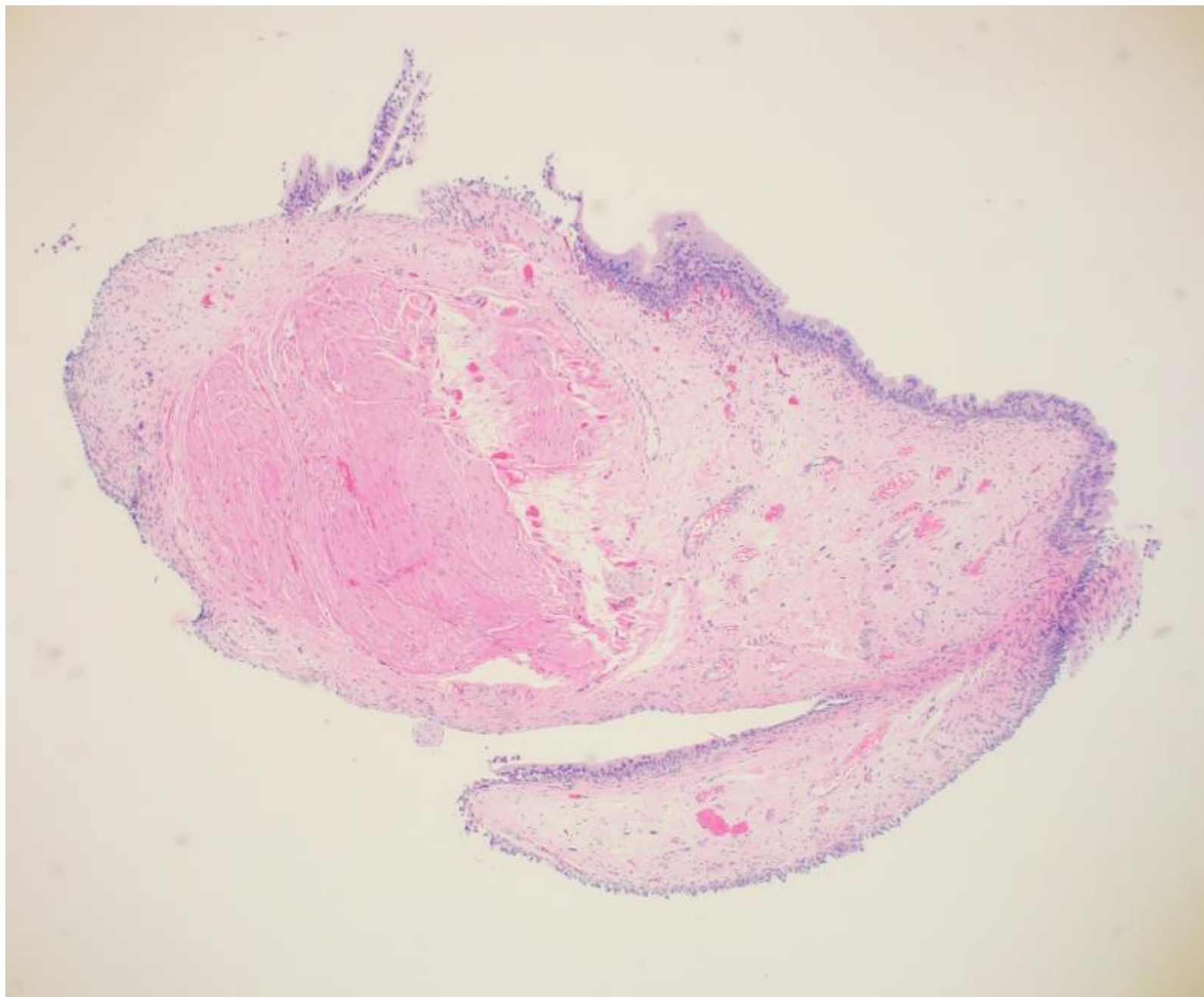
# DIAGNOSIS?

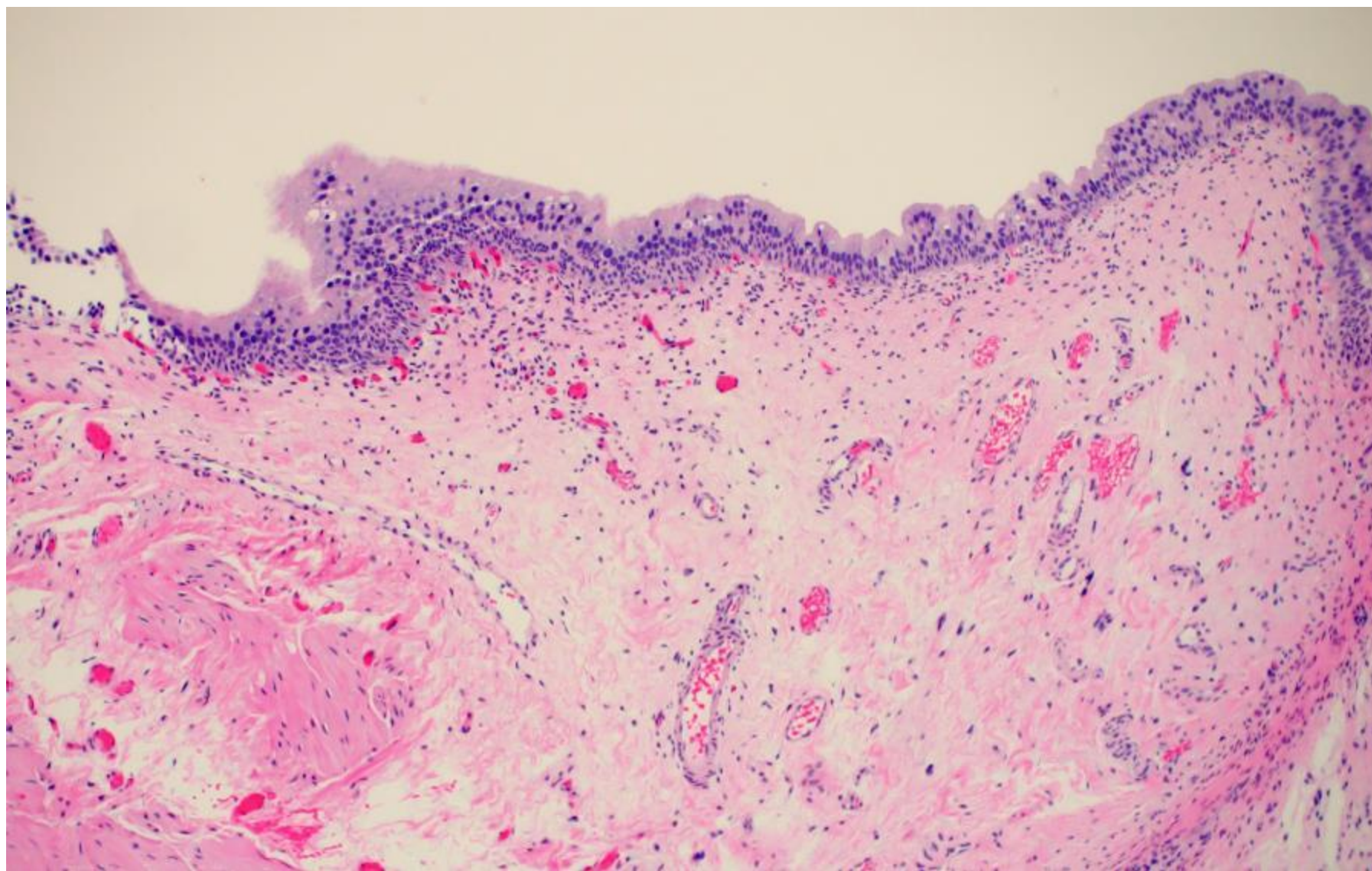


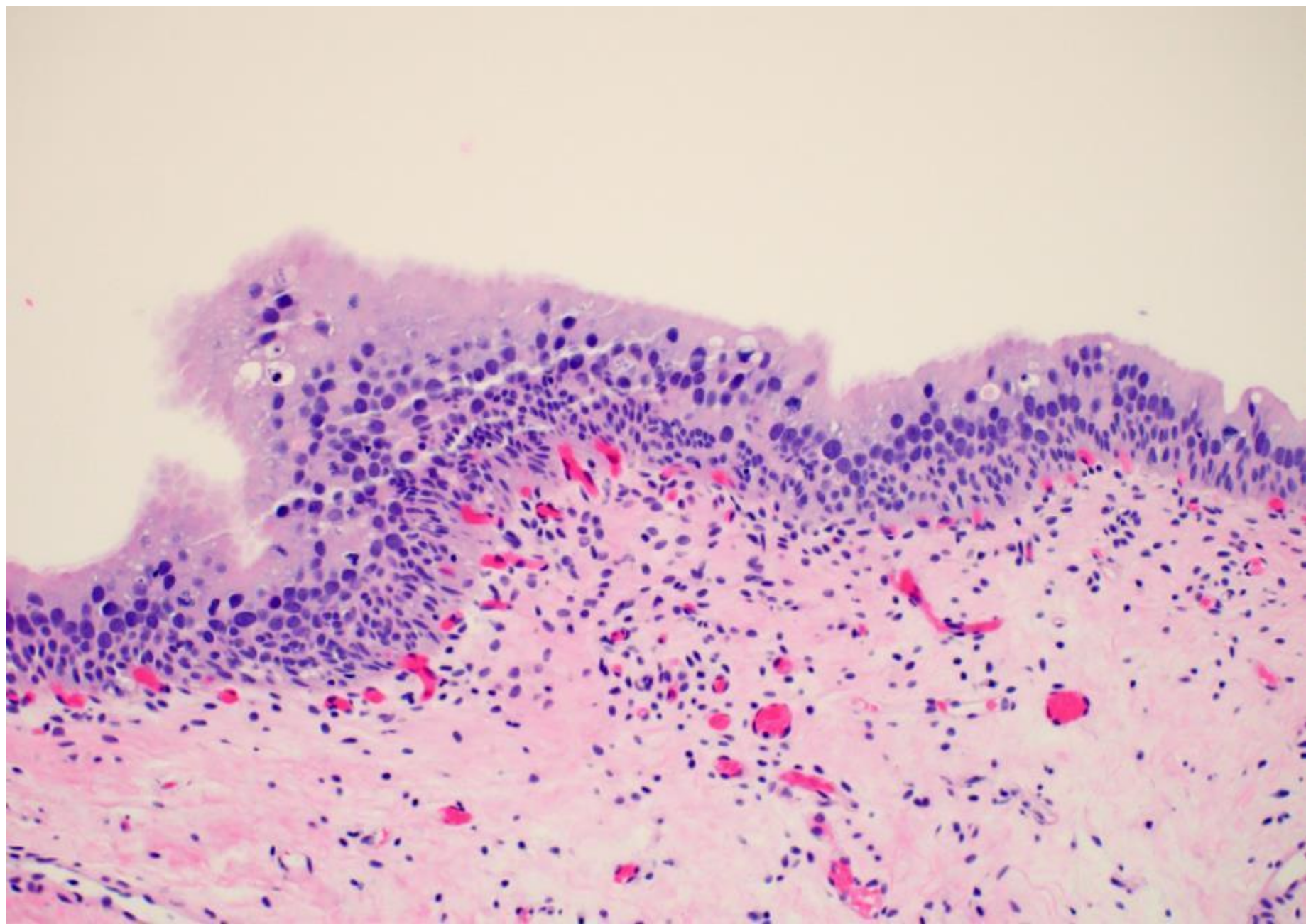
24-0402

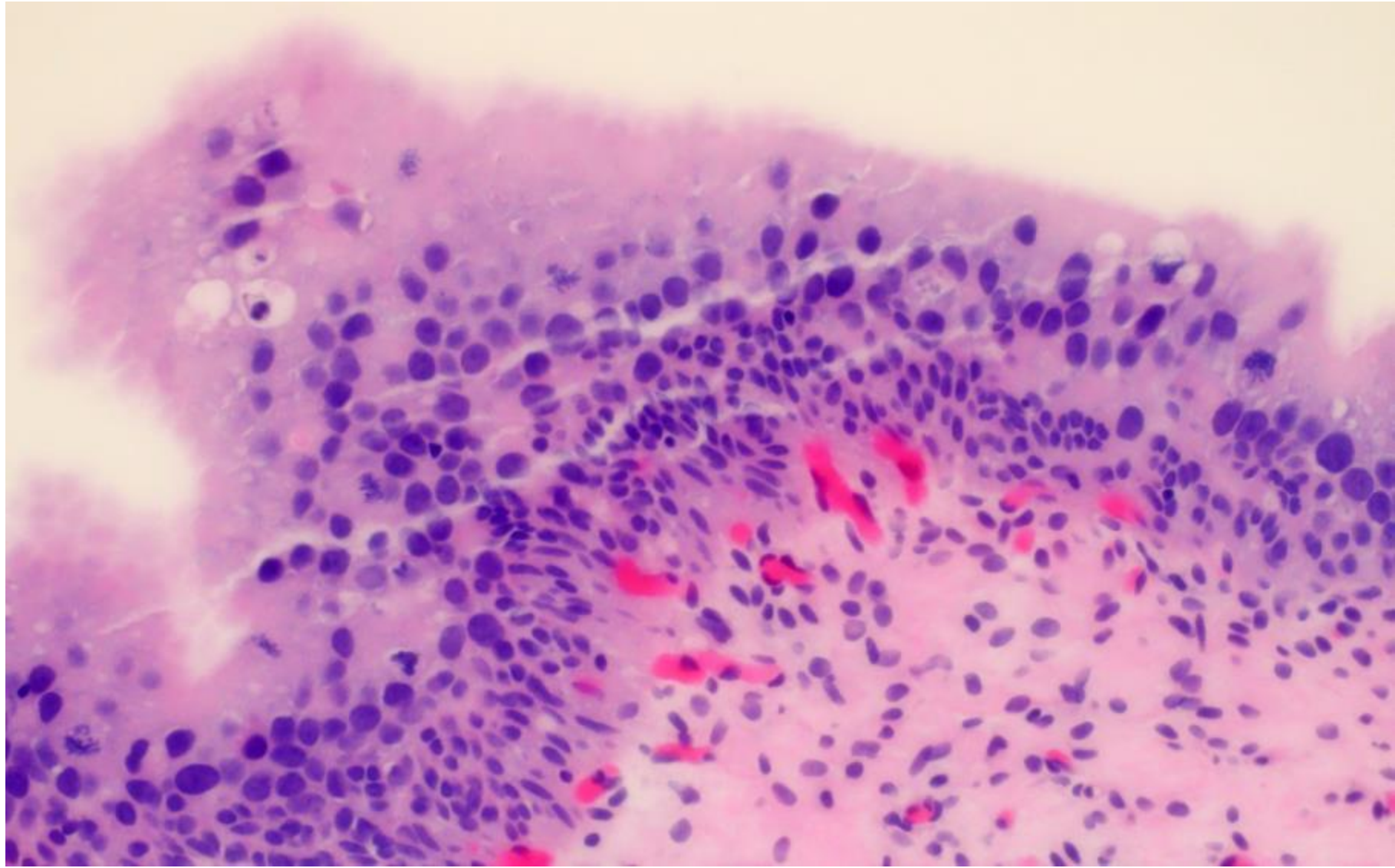
Emily Chan; case from her time at UCSF

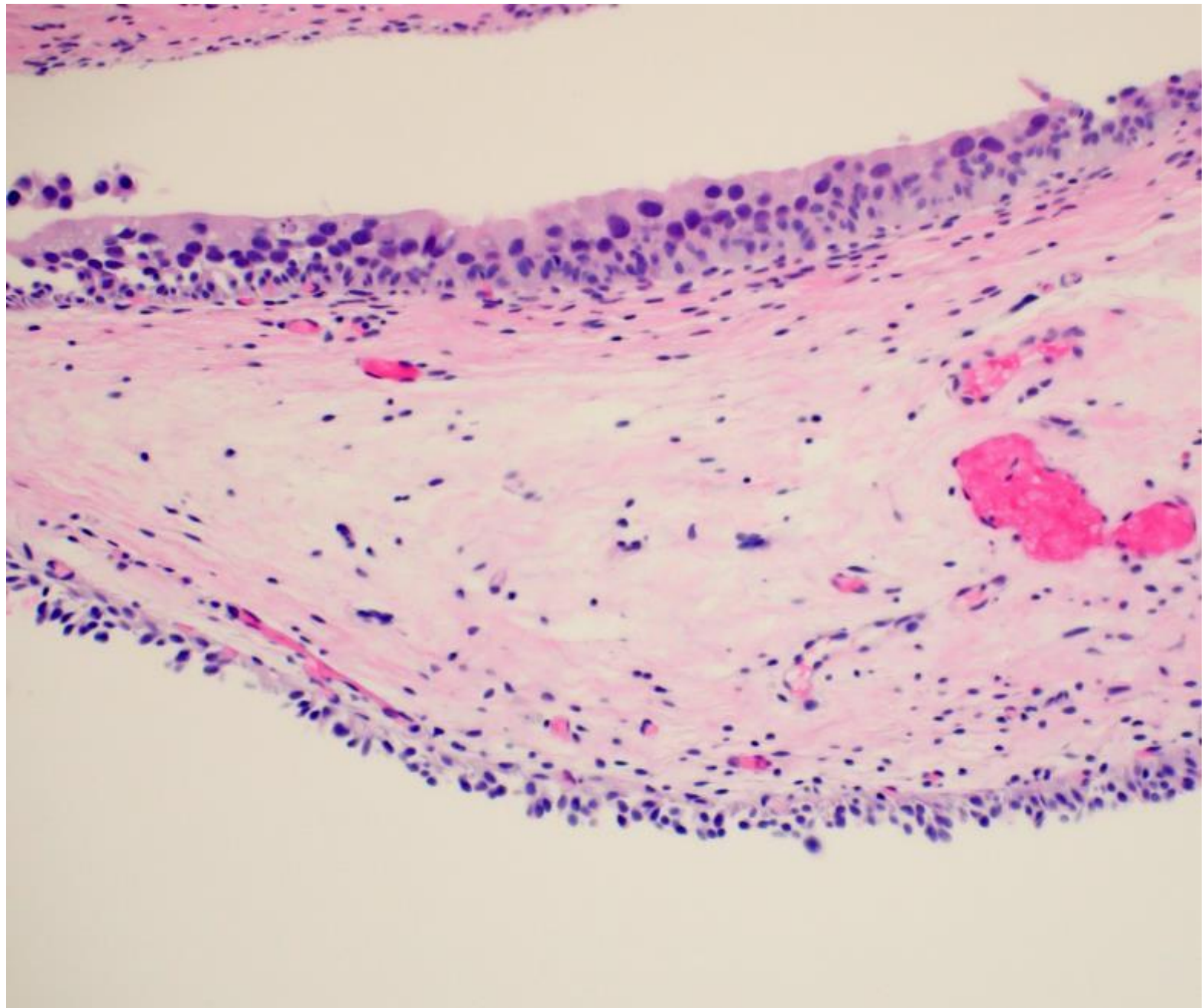
78-year-old man with microscopic hematuria and abnormal urine cytology. Cystoscopy shows no abnormal lesions random bladder biopsies











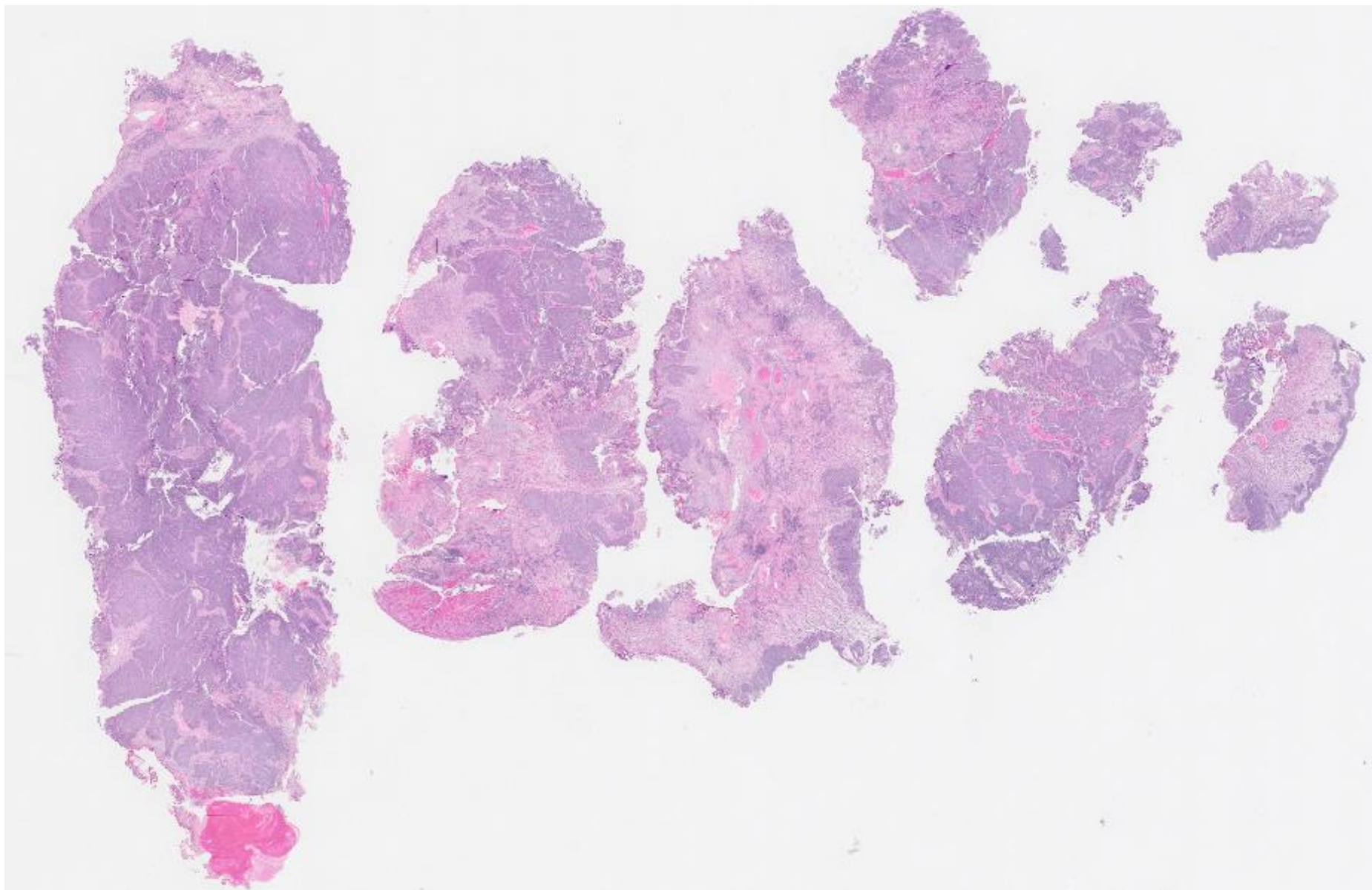
# DIAGNOSIS?

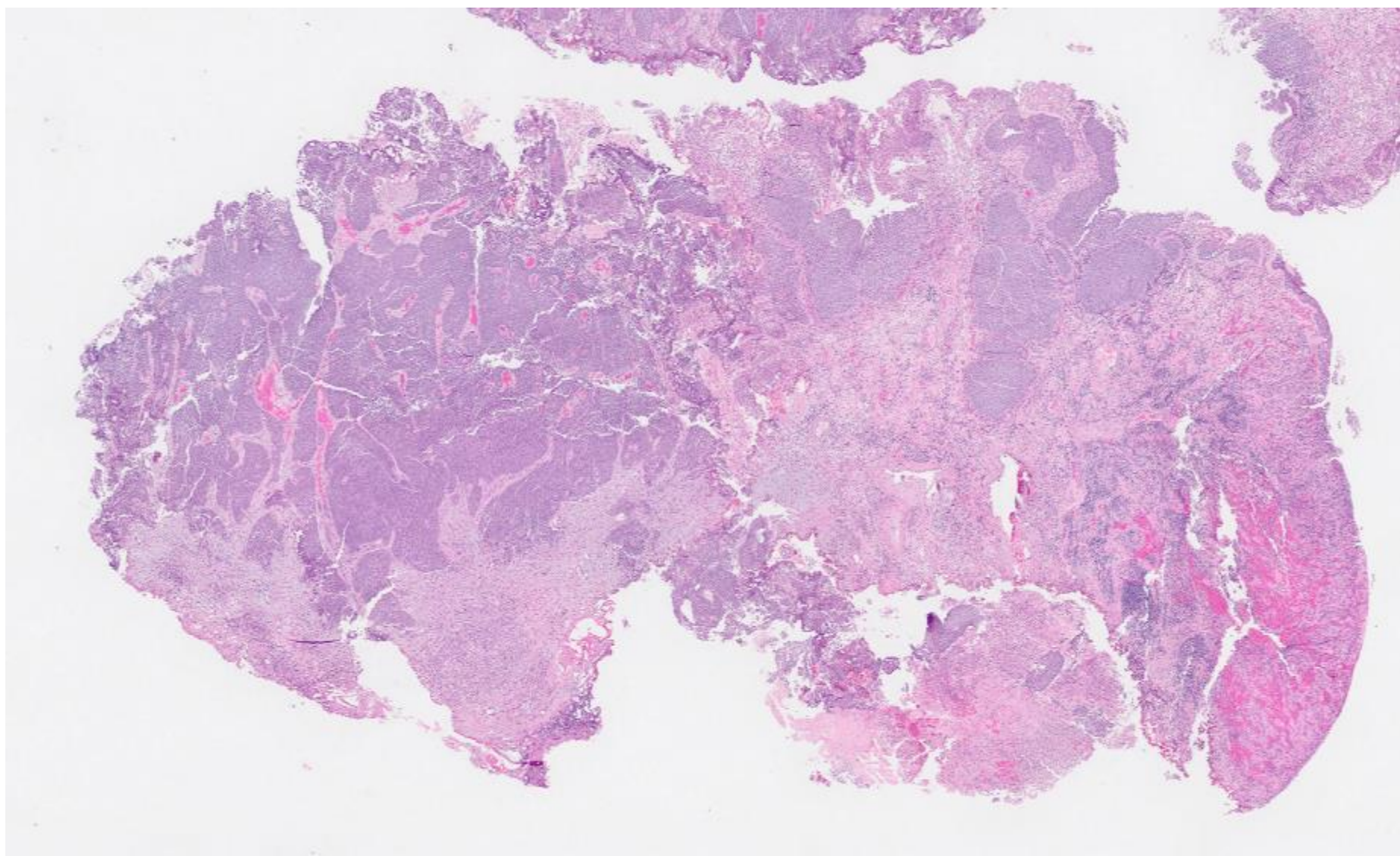


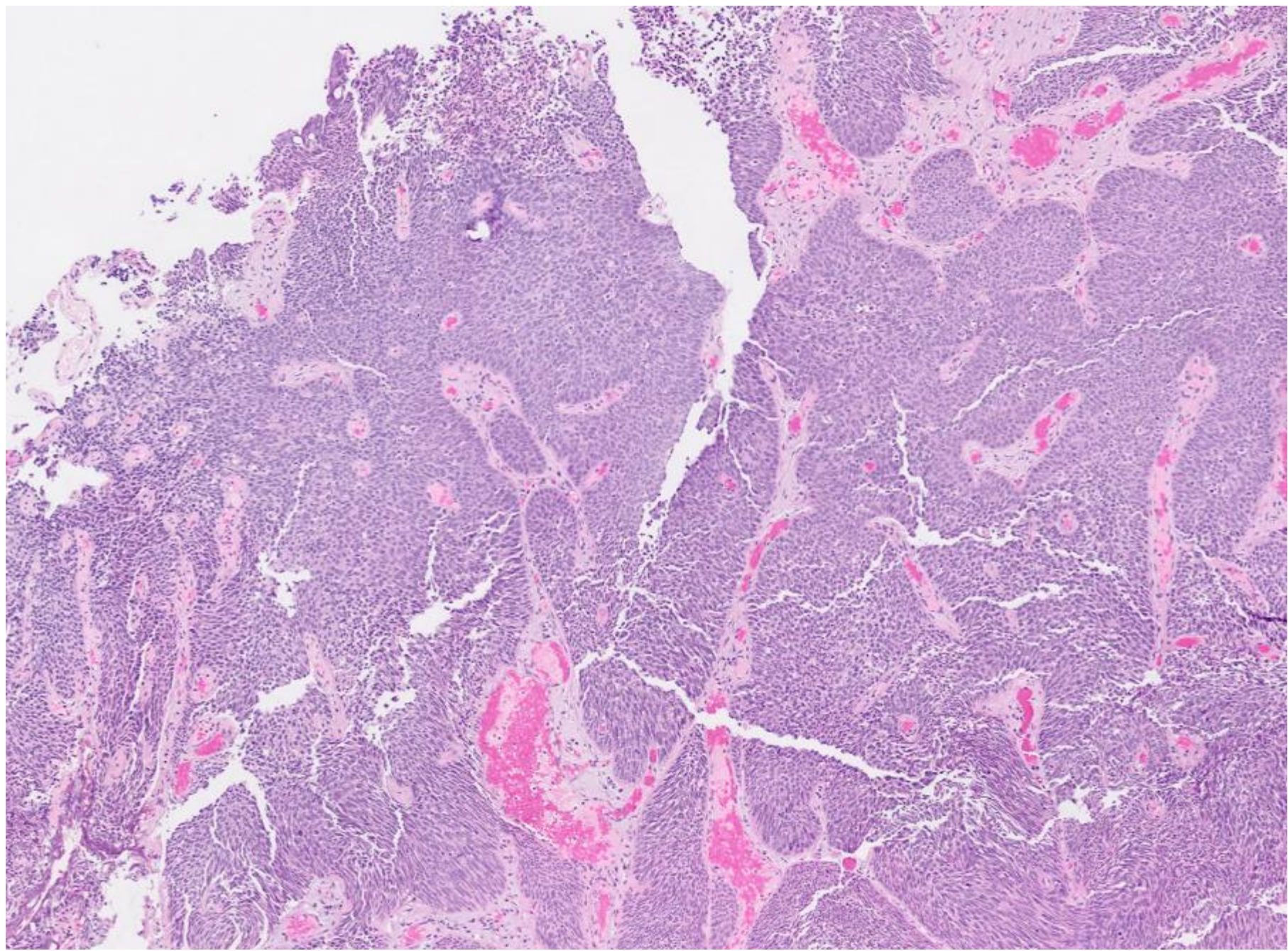
24-0403

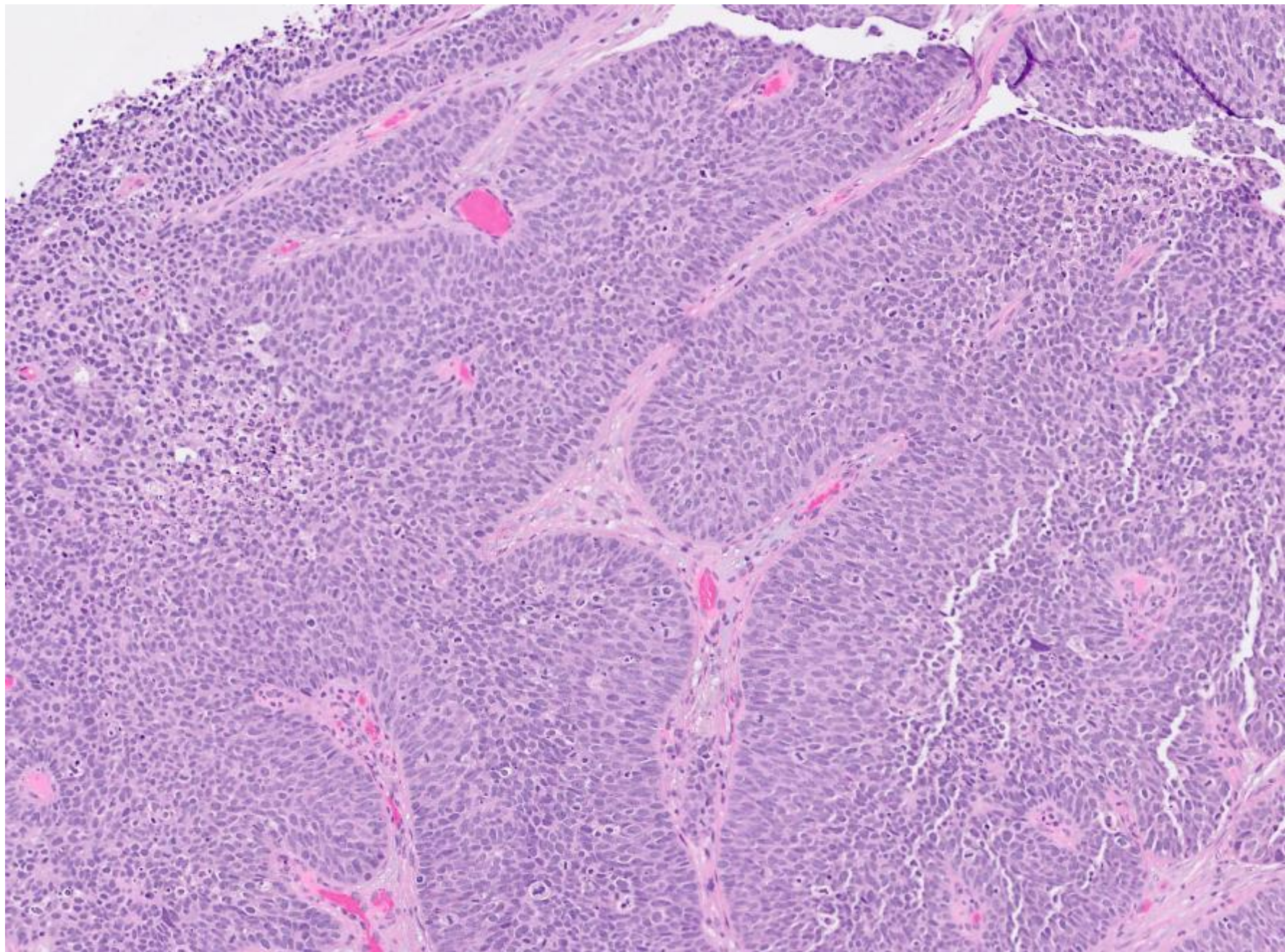
Emily Chan; Stanford

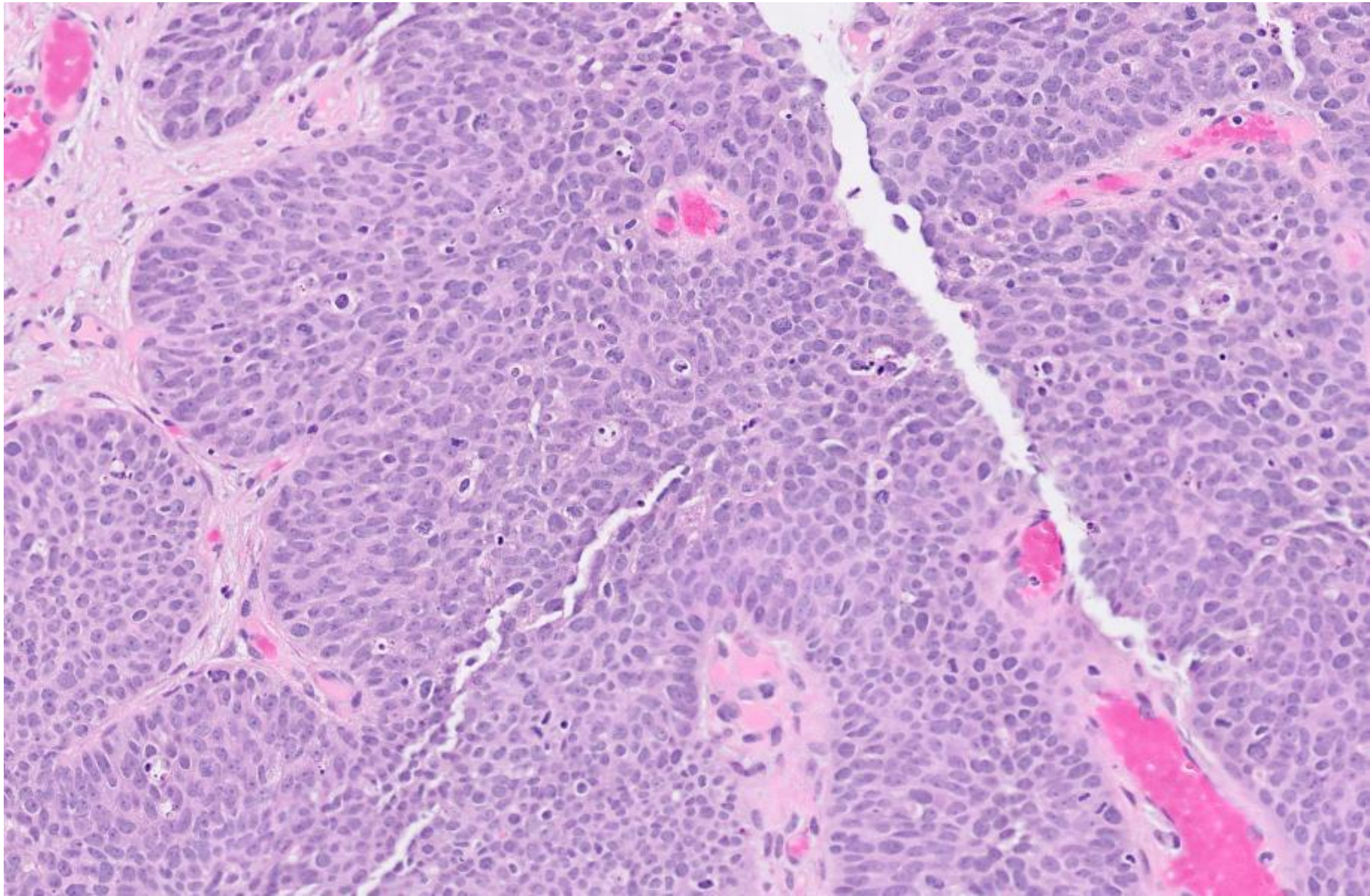
63 year-old woman with bulky urinary bladder posterior wall mass

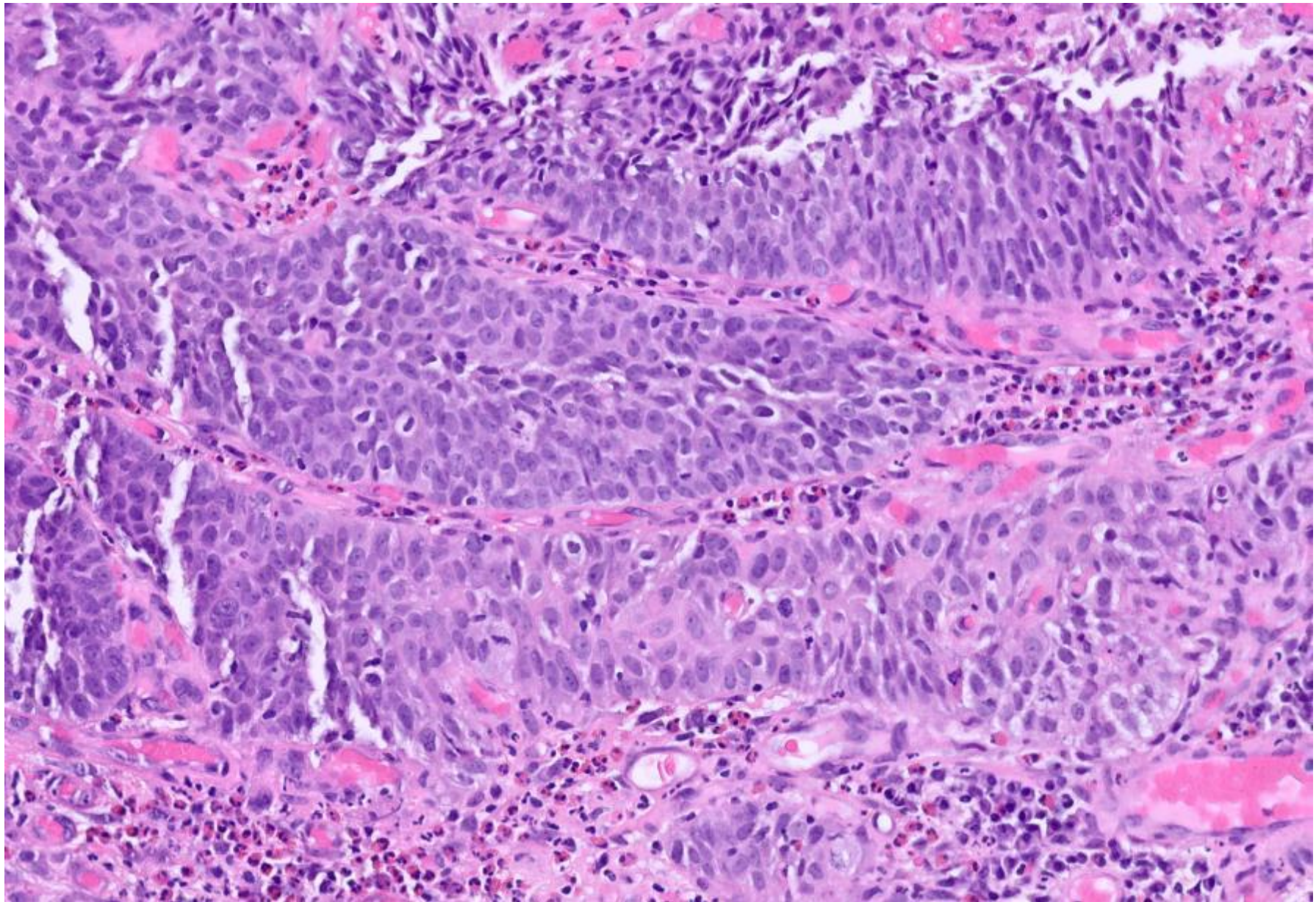












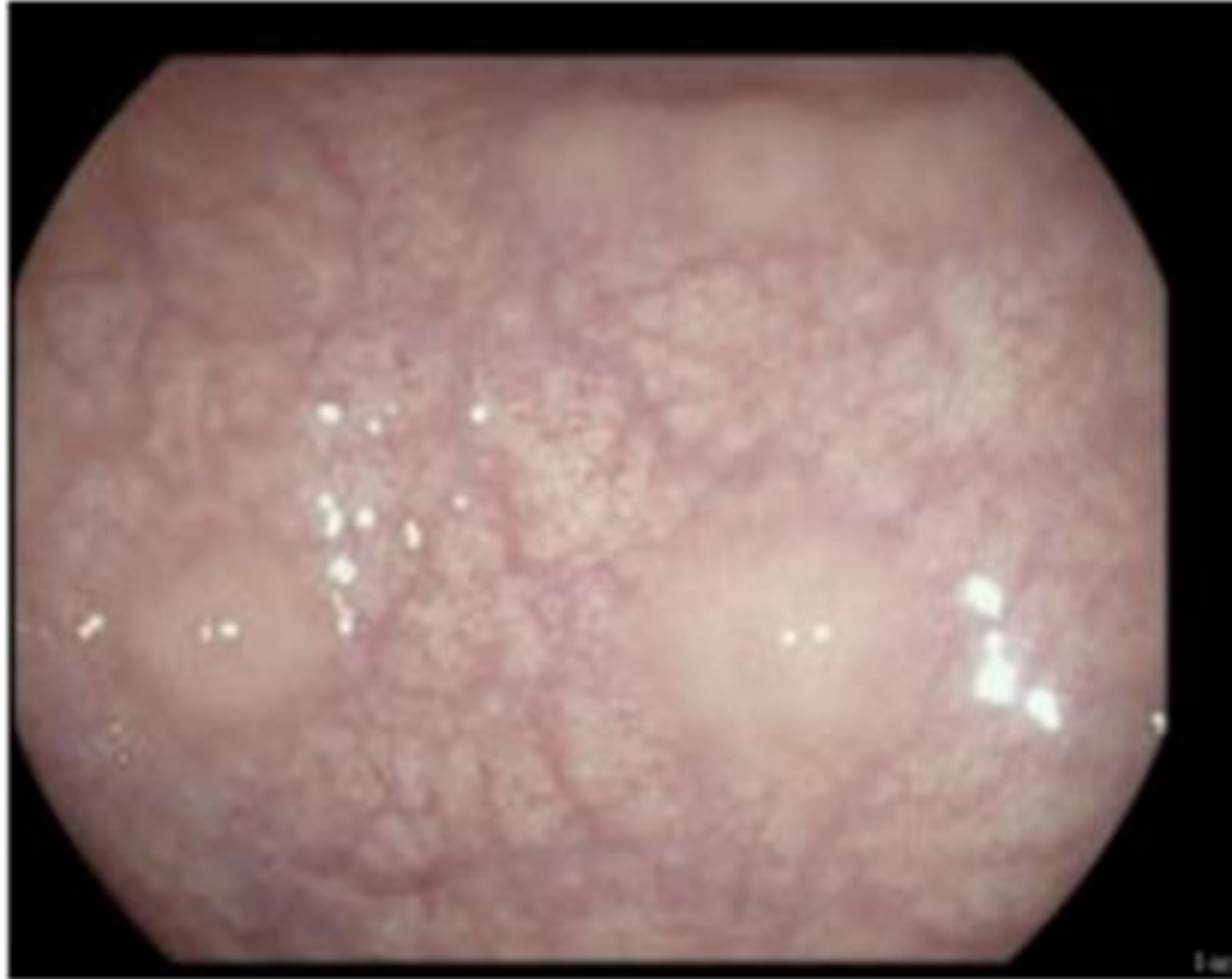
# DIAGNOSIS?



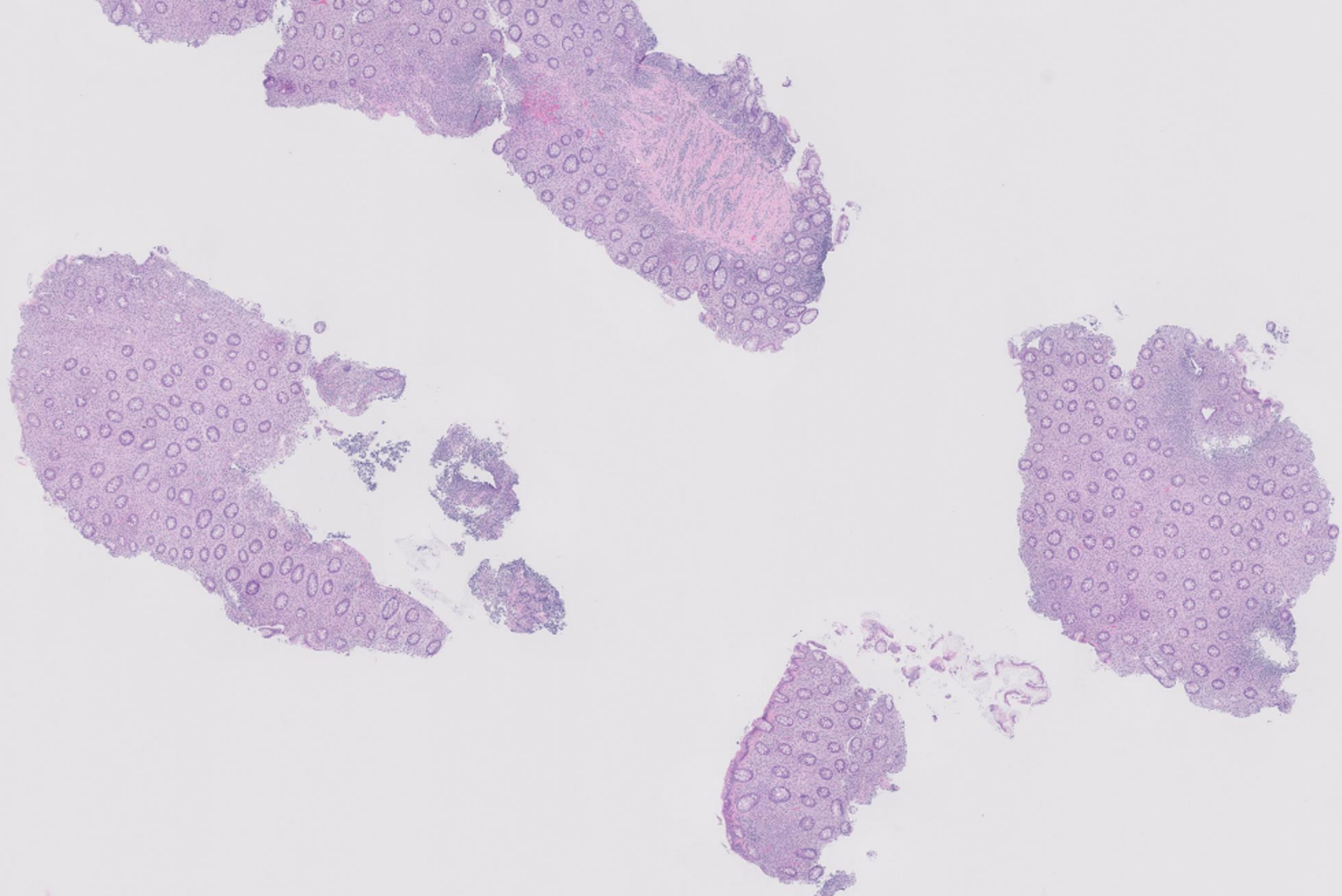
24-0404

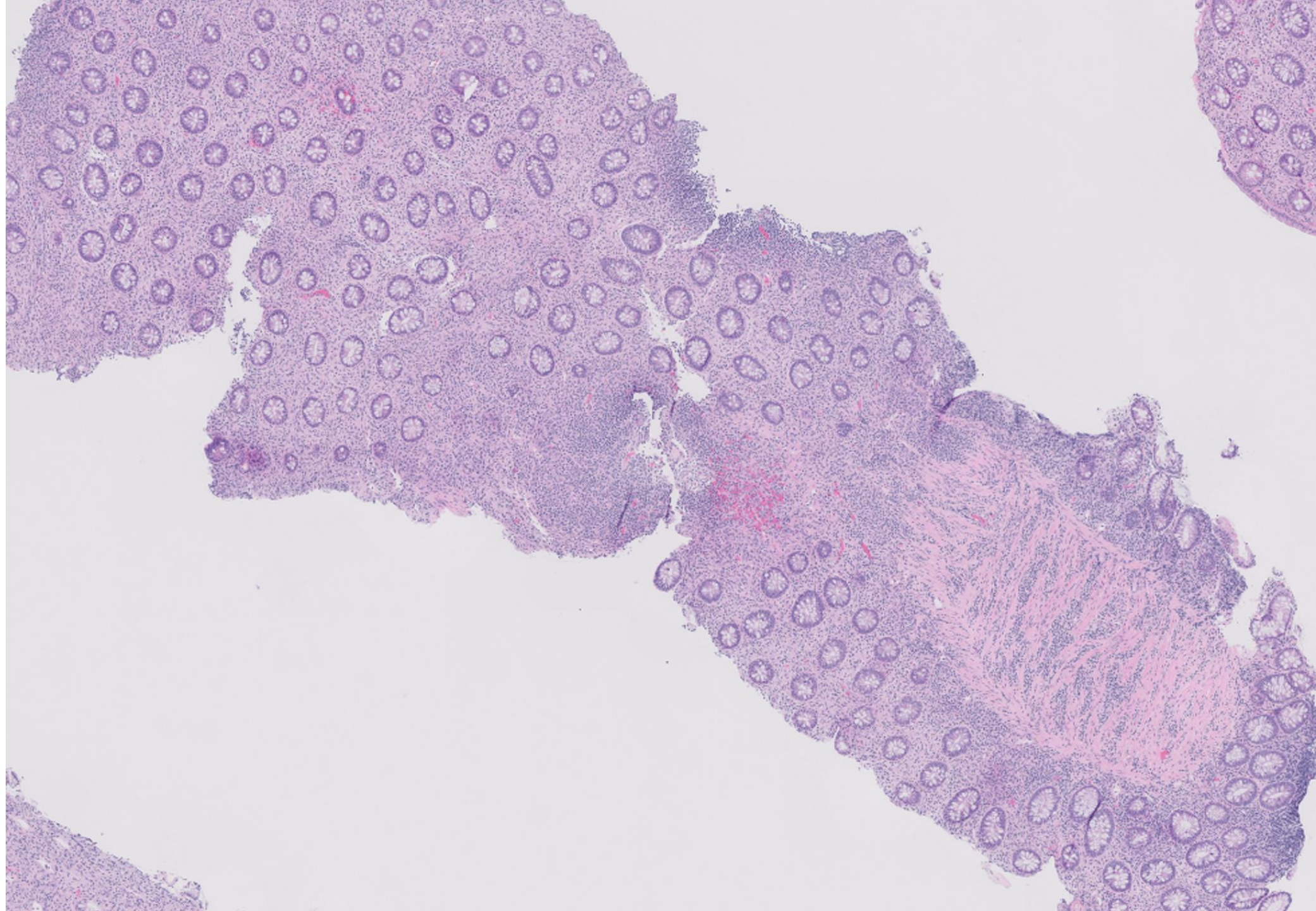
F. Goknur Akarca and Sarah Umetsu; UCSF

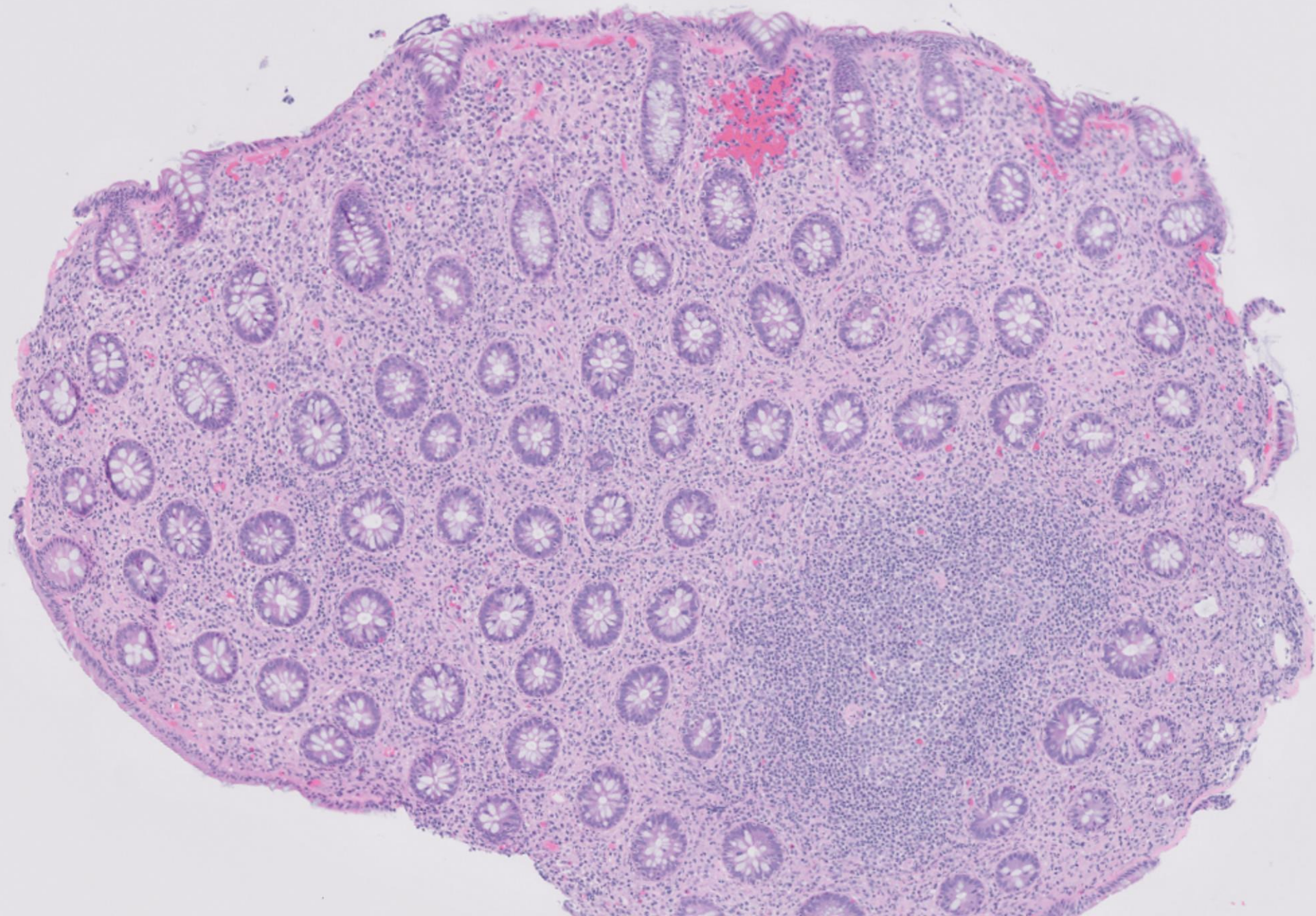
- 43 yo Male with clinically significant diarrhea; family history of Crohn's disease
- Colonoscopy shows multiple well-circumscribed hypopigmented spots in the rectum

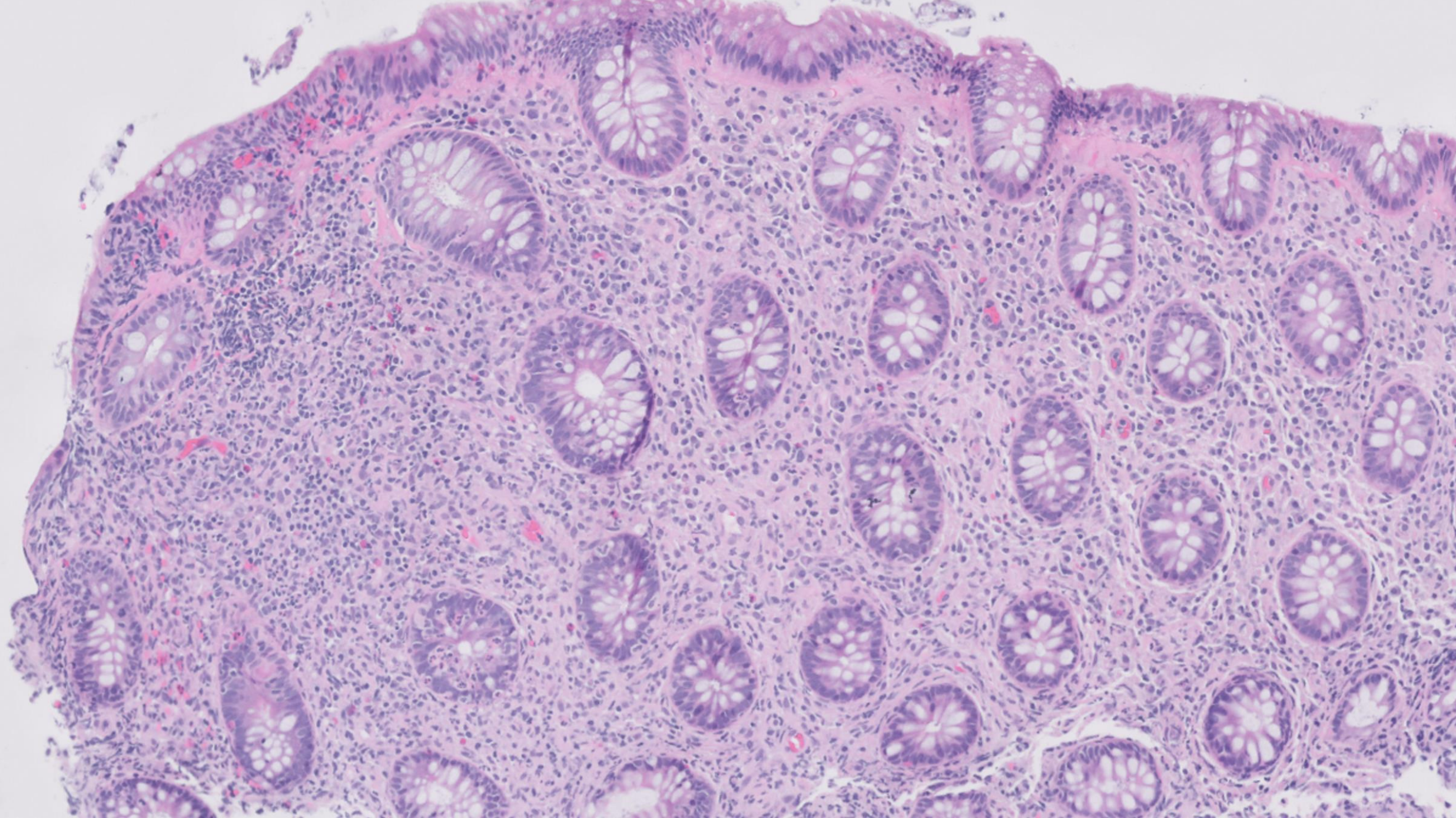


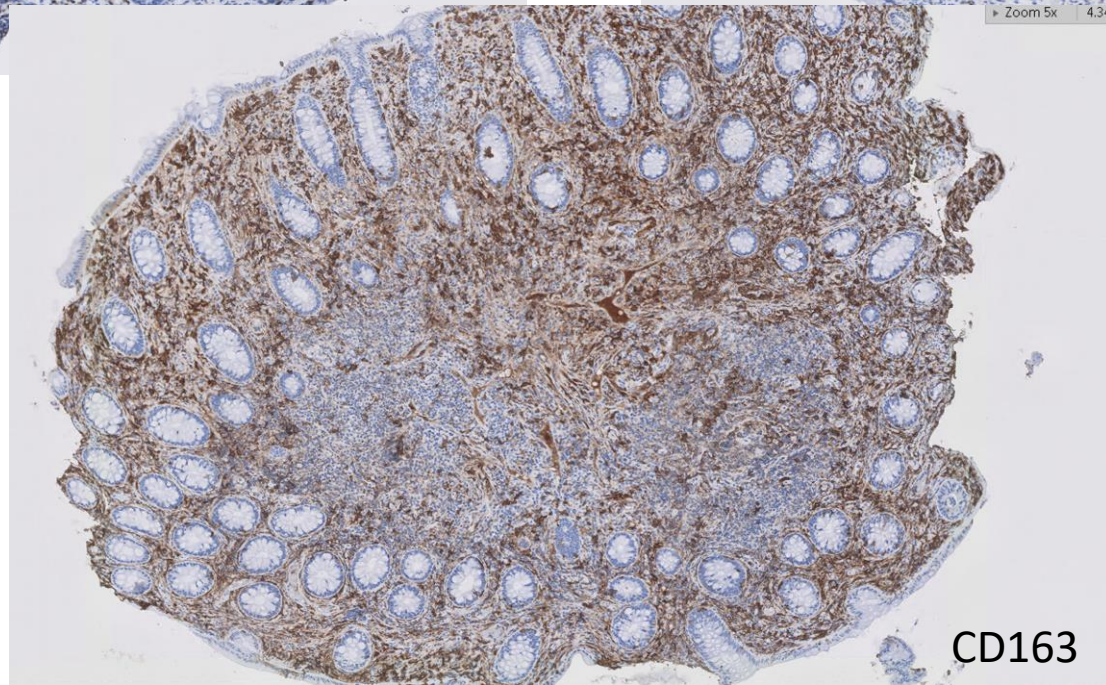
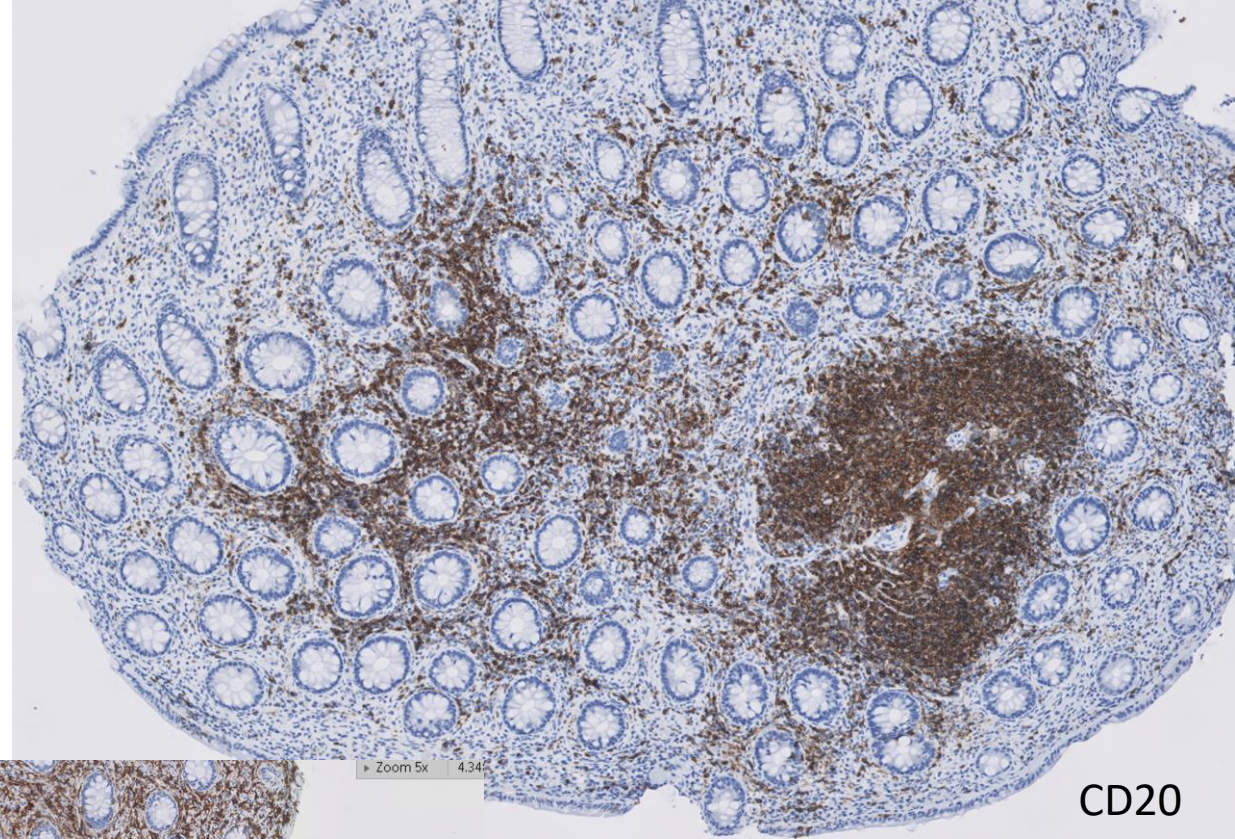
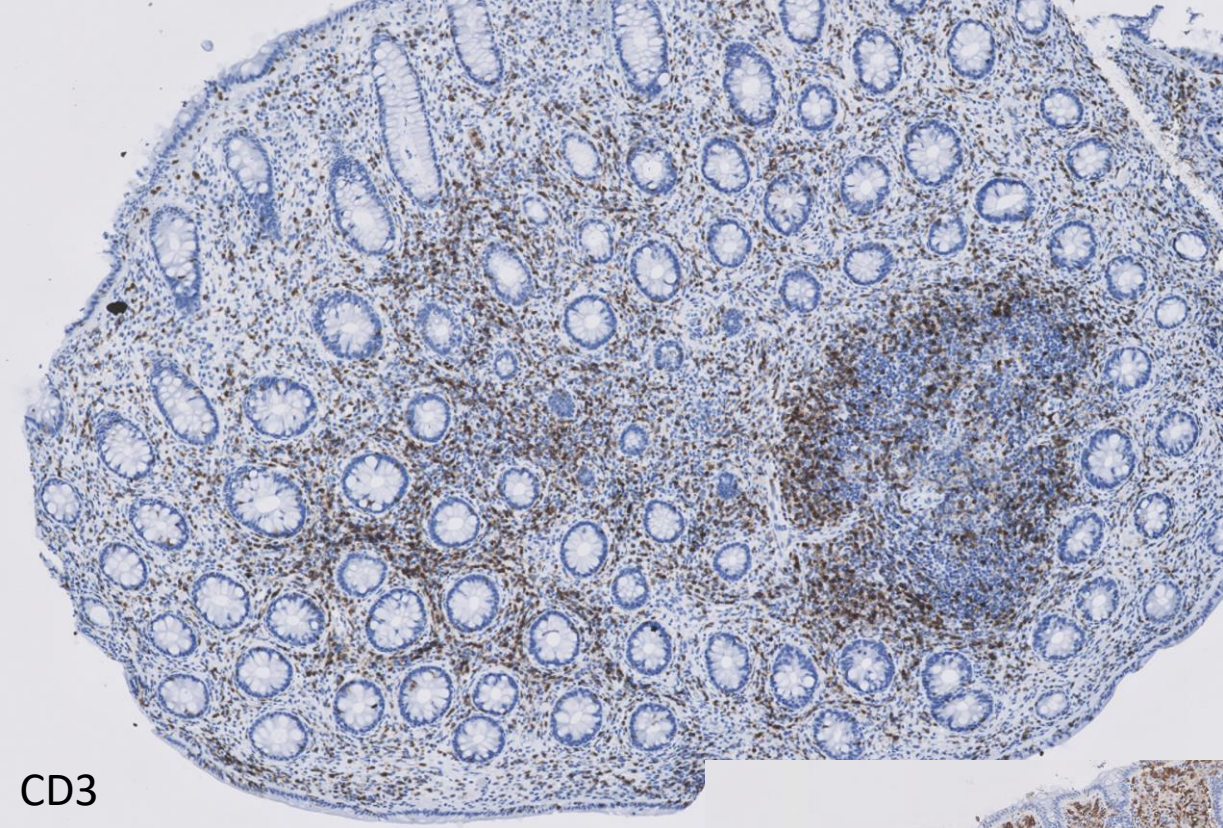
Multiple well-circumscribed, hypopigmented spots  
(possibly suggestive of hyperplastic polyp per gastroenterologist)











# DIAGNOSIS?



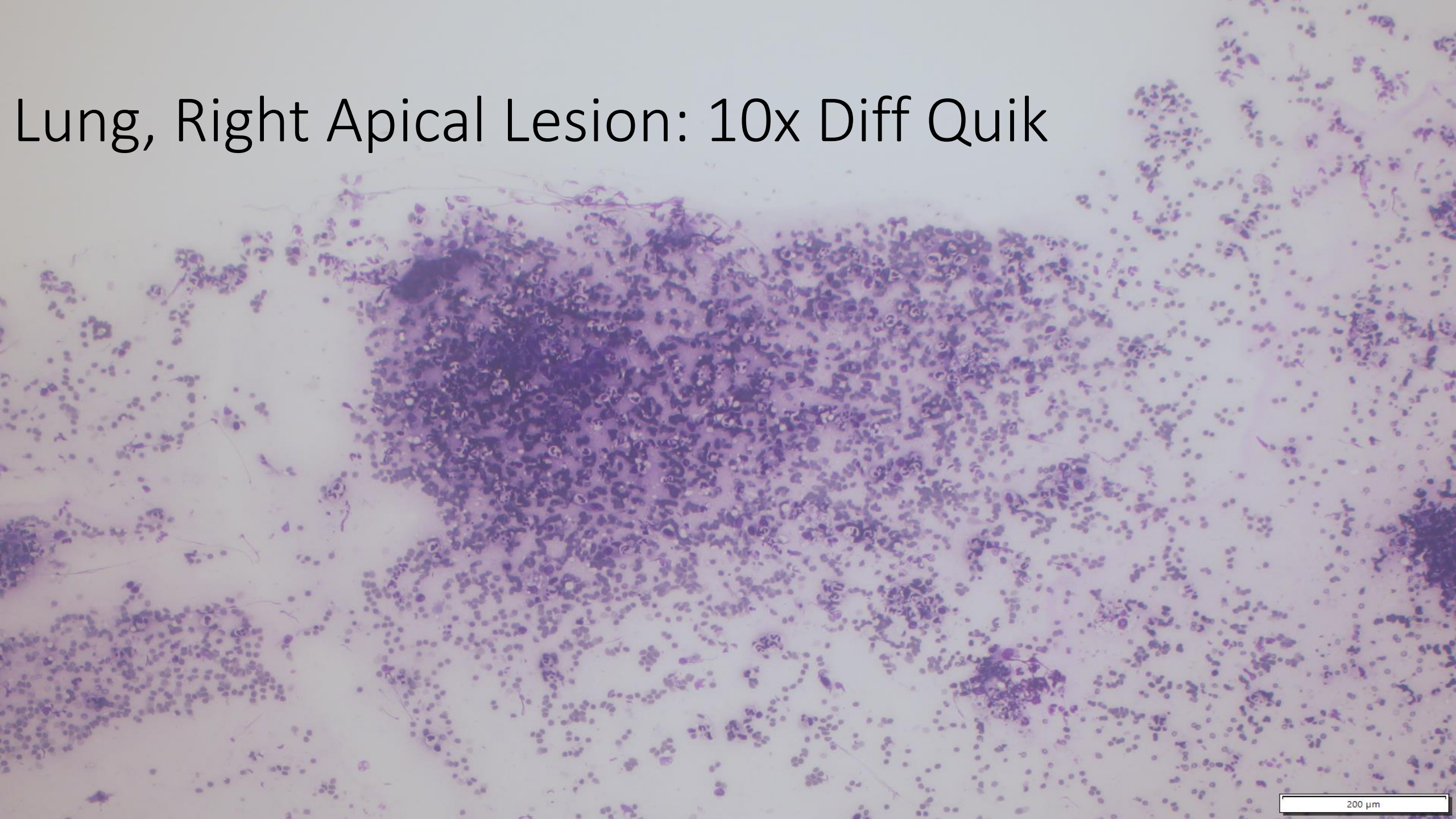24-0405

Iain Miller, MD, Patrick Mullane, MD, Kristin Jensen, MD; Stanford

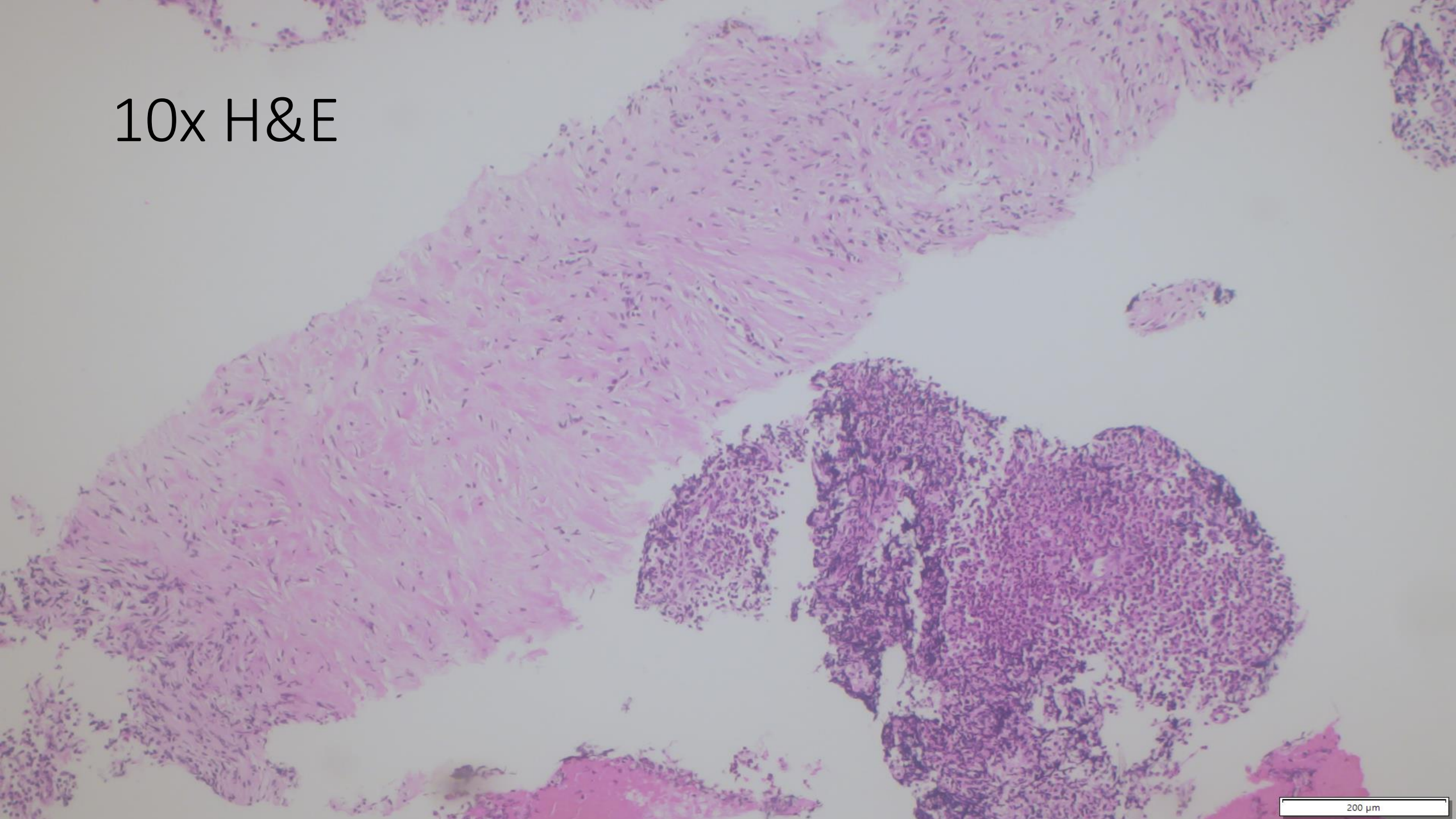
60-ish year-old male with history of prostate cancer (Gleason 4+3) status-post radiation (2019) and Lupron therapy, dilated cardiomyopathy, and pulmonary hypertension status-post heart transplant (3/2023). Patient with SARS-CoV-2 in 11/2023 and presents now with cough, fatigue, and chills.

PET/CT significant for a 4.4 cm right apical lung mass concerning prostate cancer metastasis to the lung. Patient using CPAP at night for comfort for last 6-7 years.

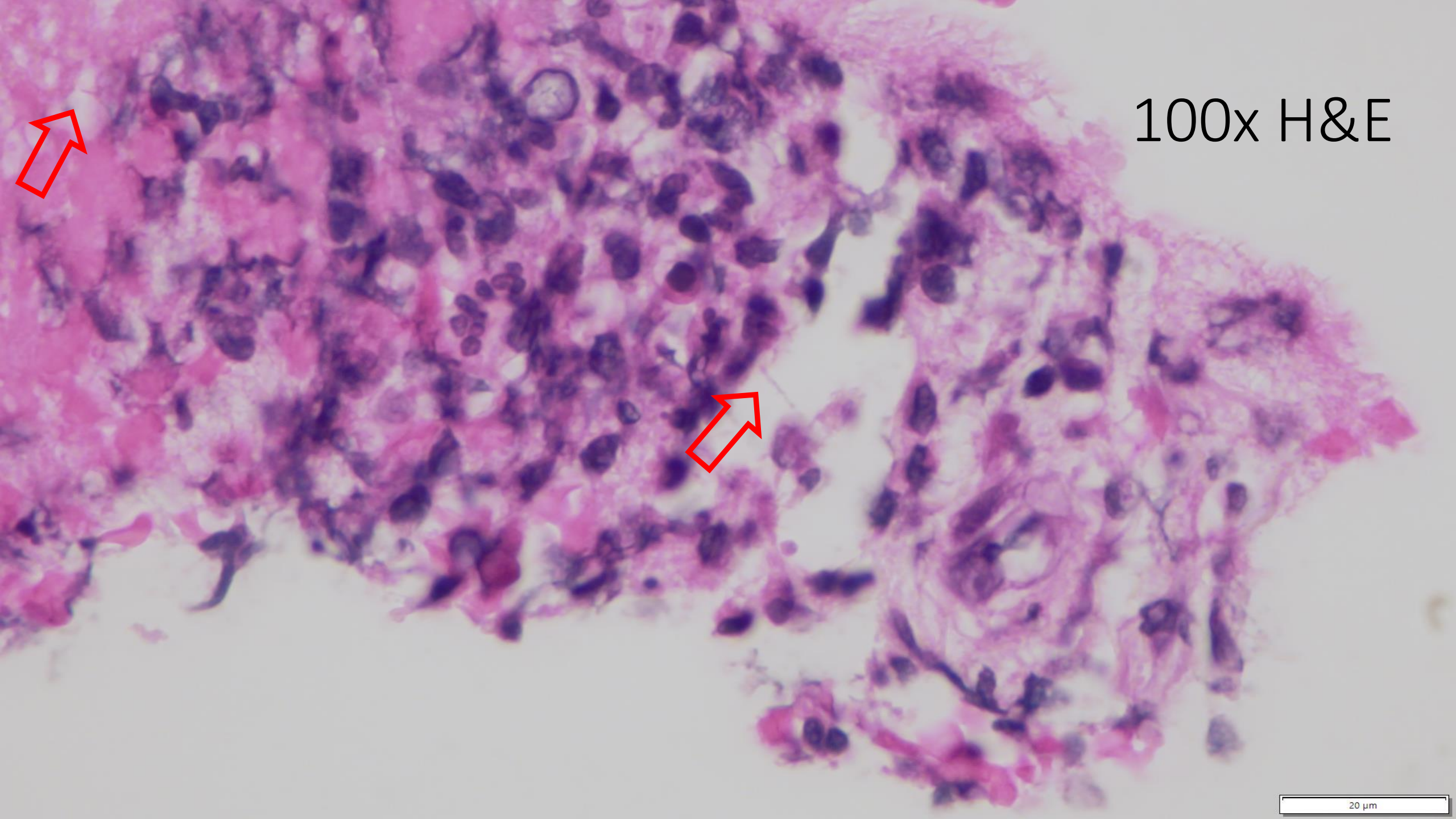
# Lung, Right Apical Lesion: 10x Diff Quik



10x H&E



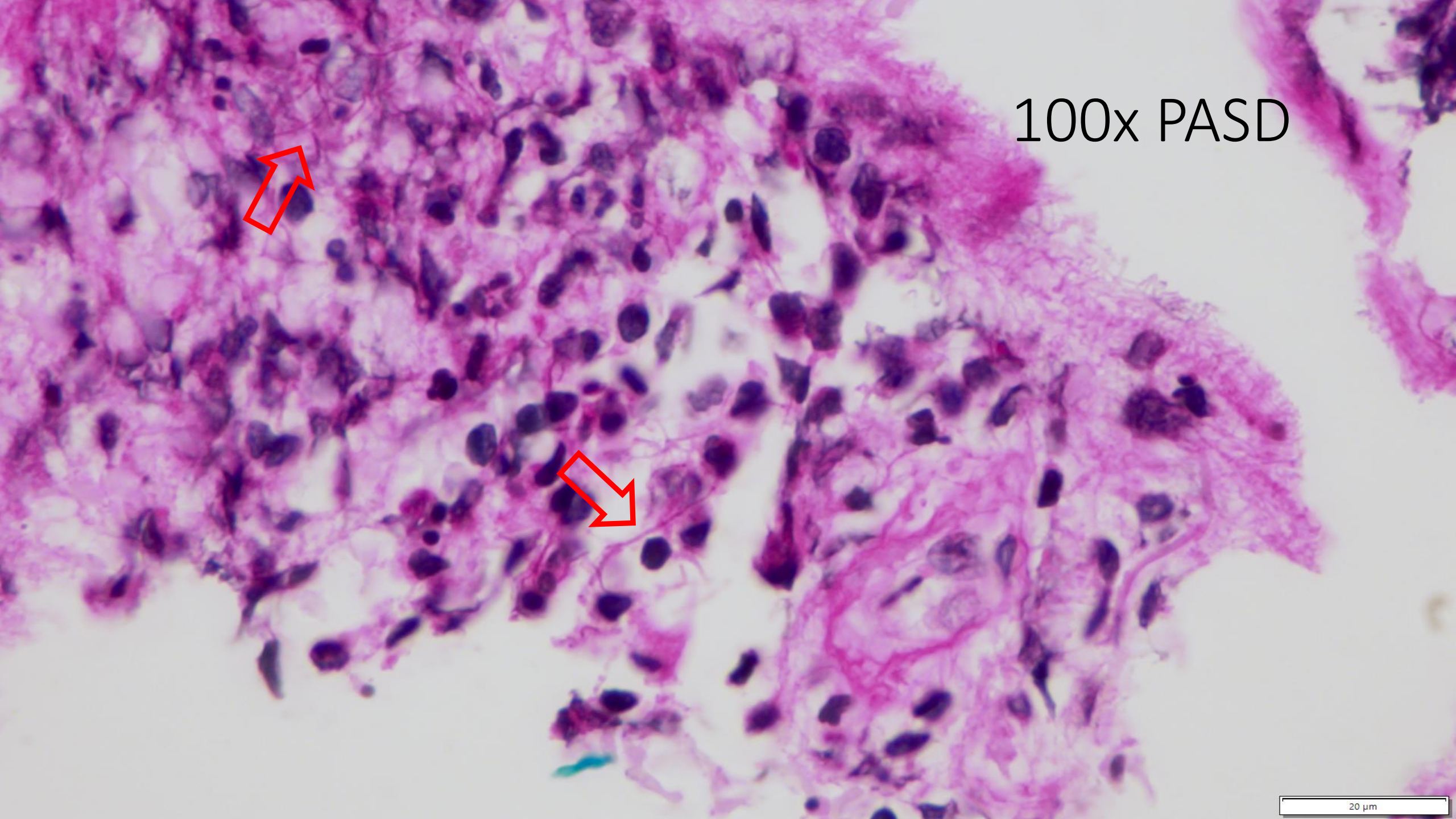
100x H&E



100x GMS



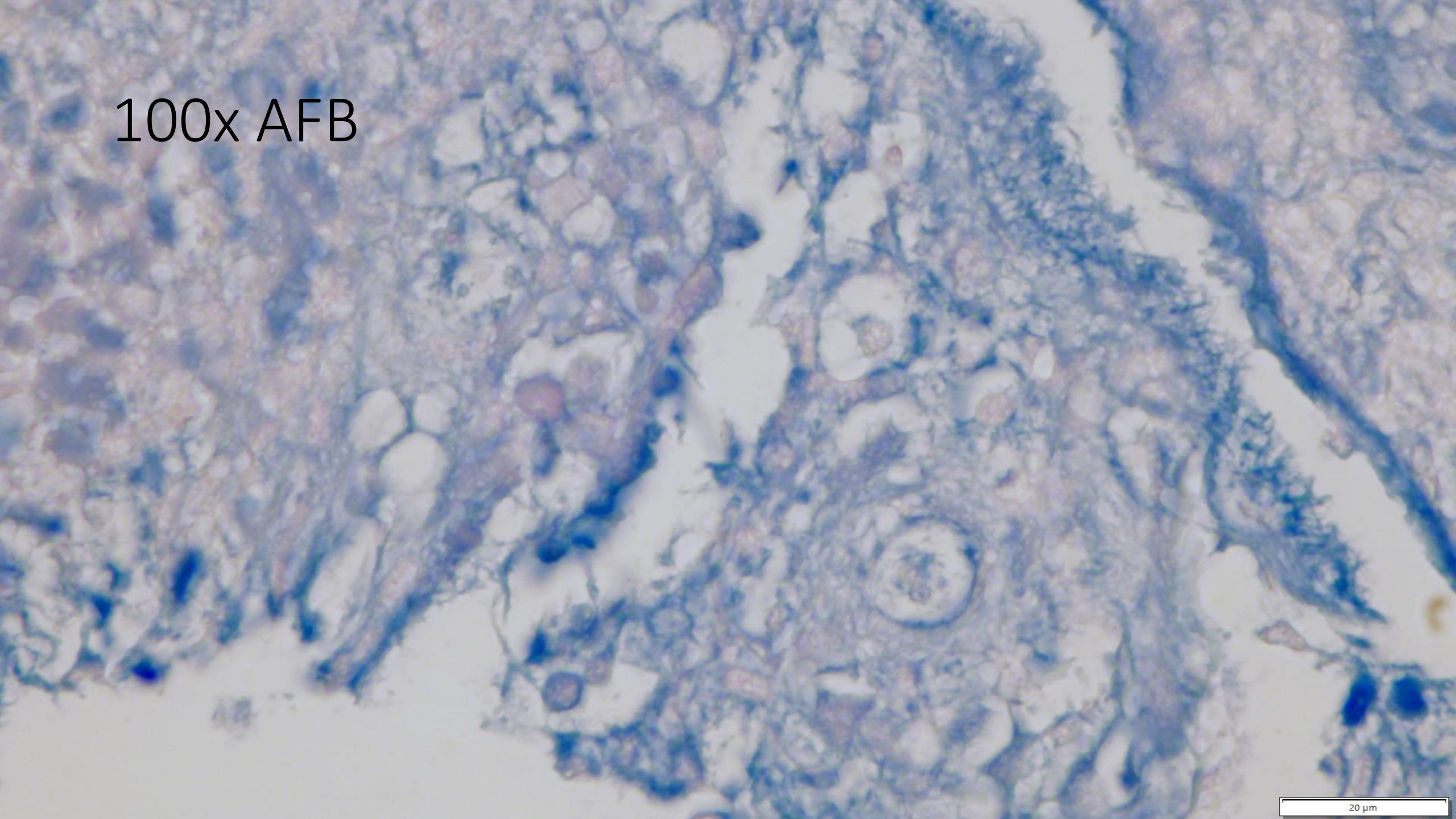
100x PASD



100x Gram



100x AFB



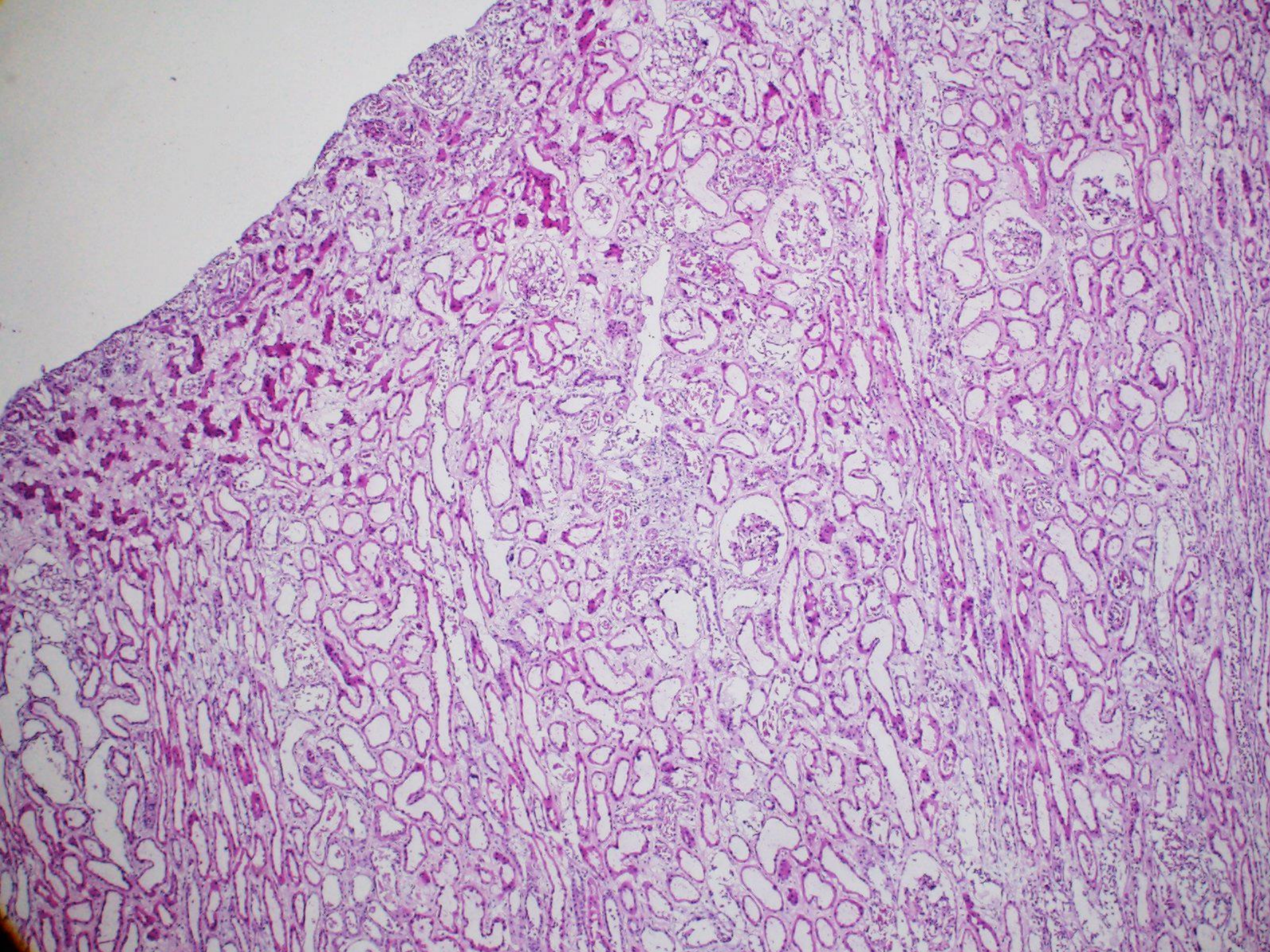
# DIAGNOSIS?

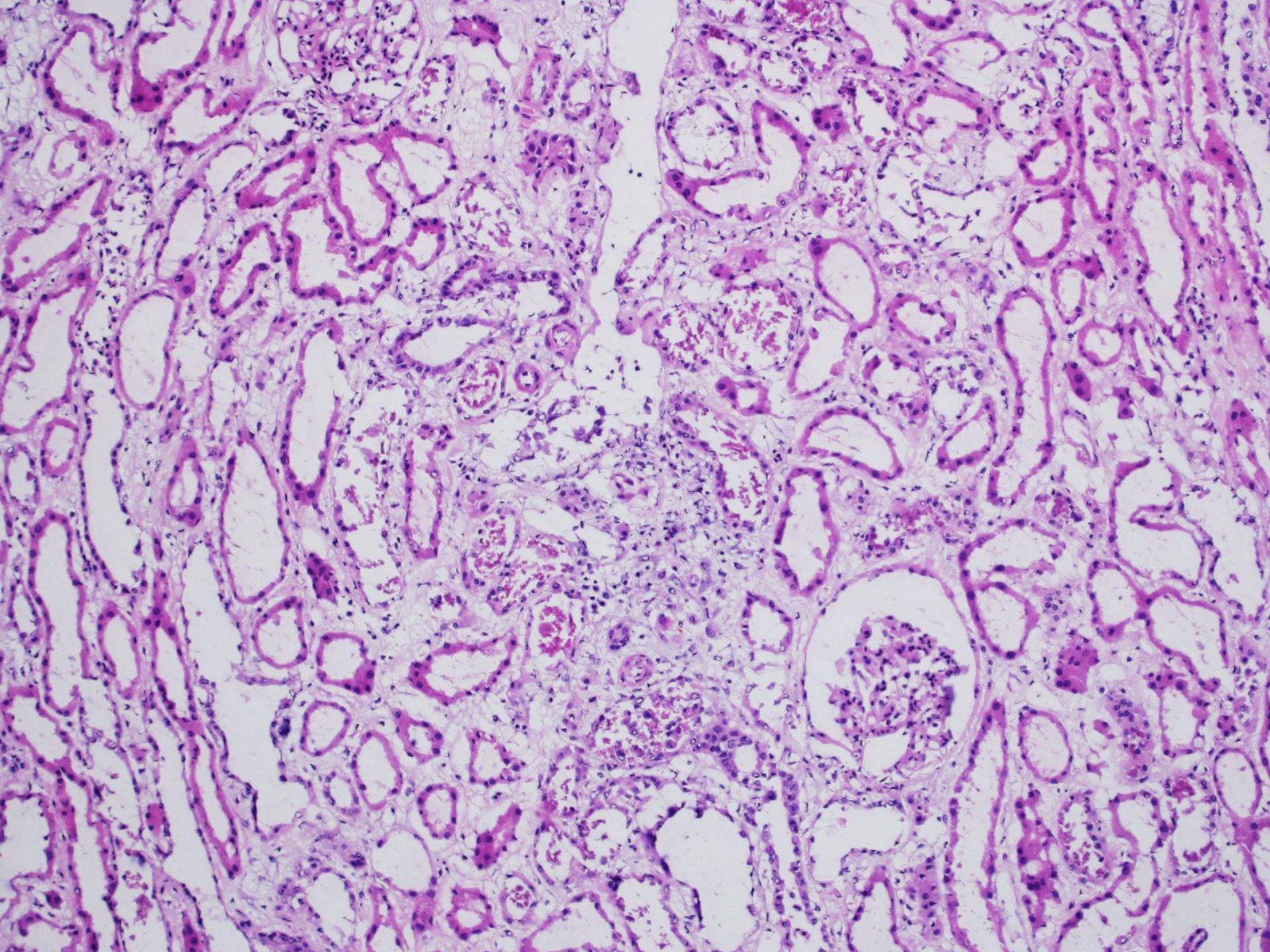


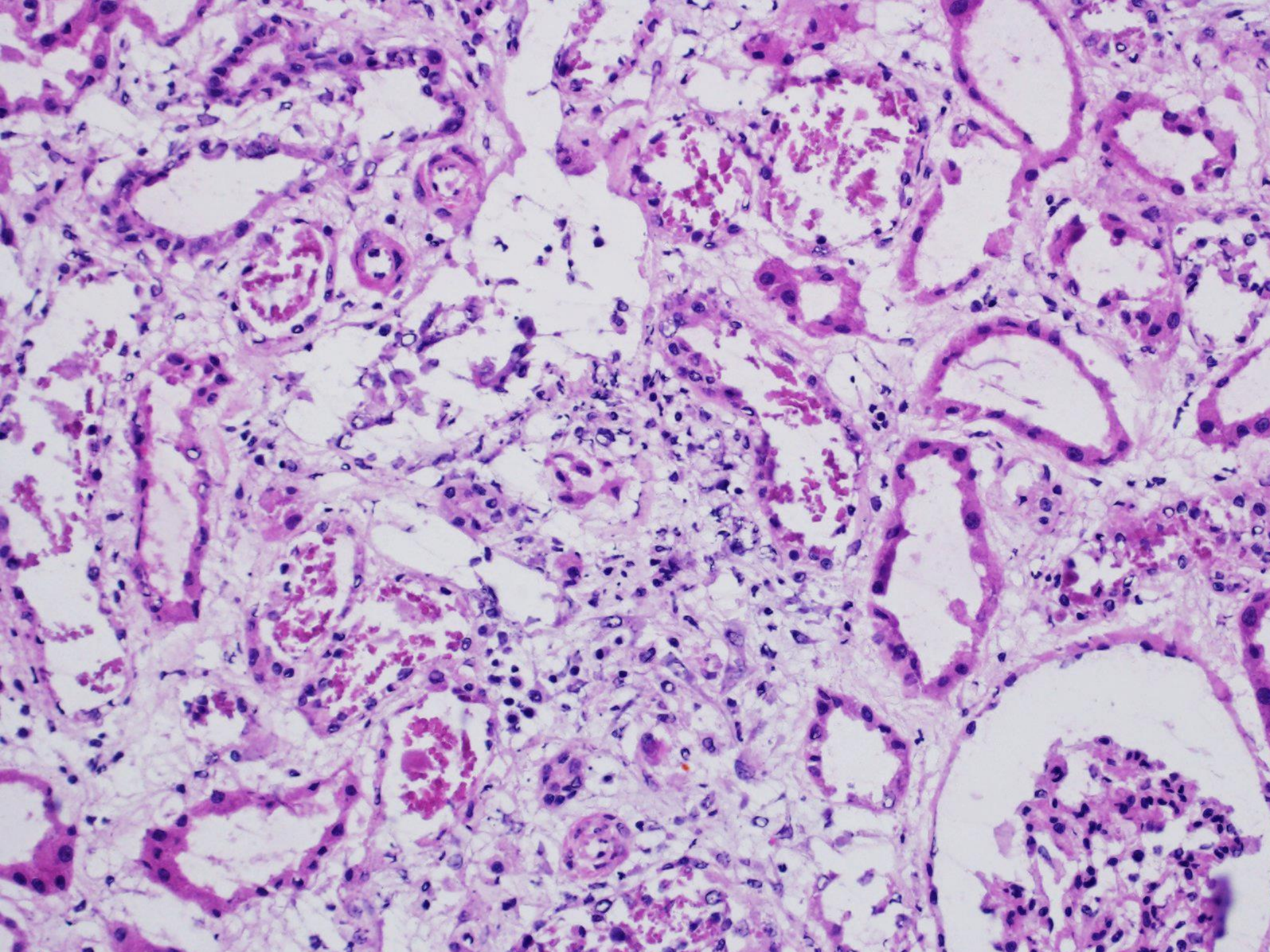
24-0406

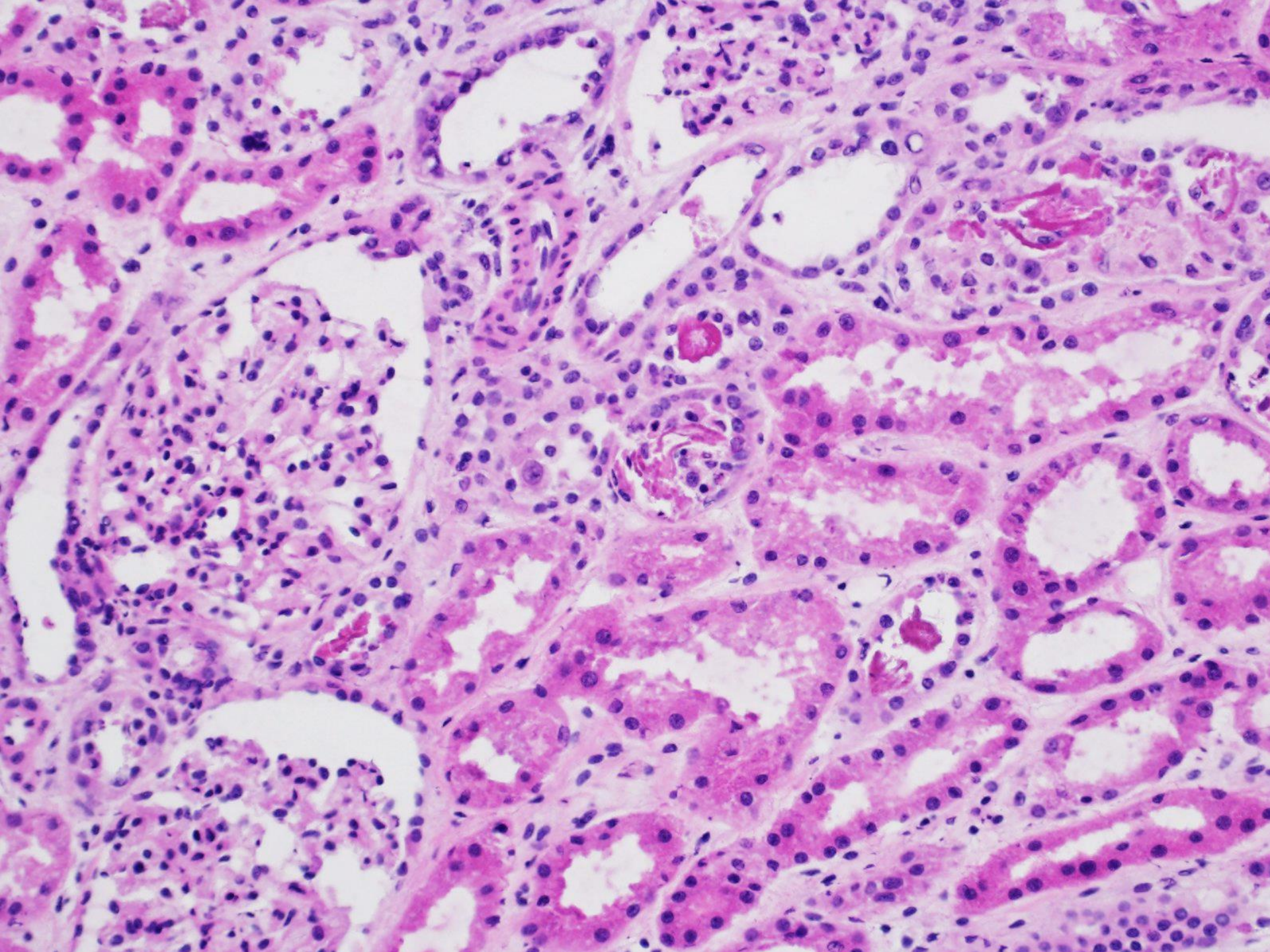
**Megan Troxell; Stanford**

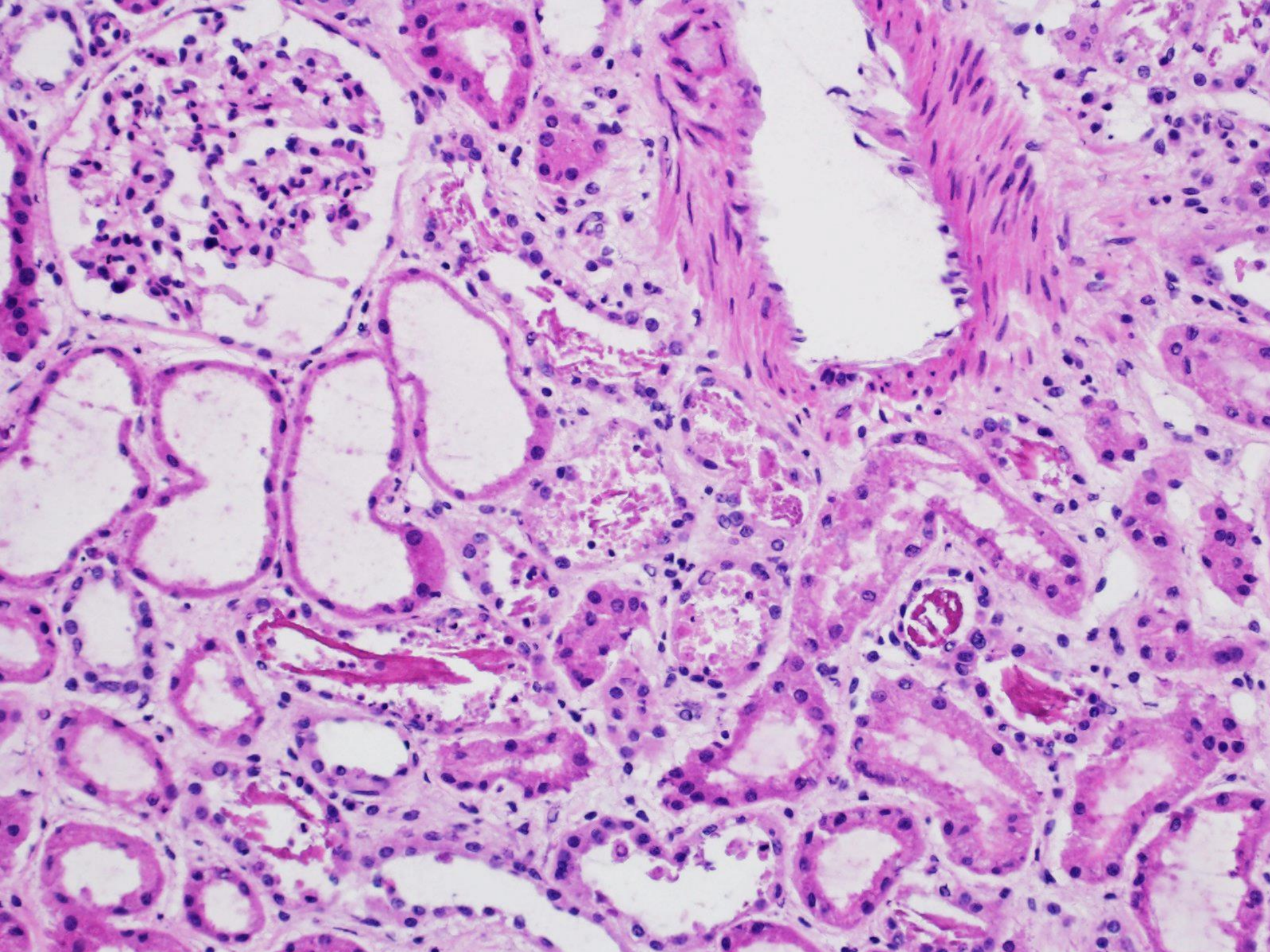
- Donor kidney frozen section (absolutely no history provided)











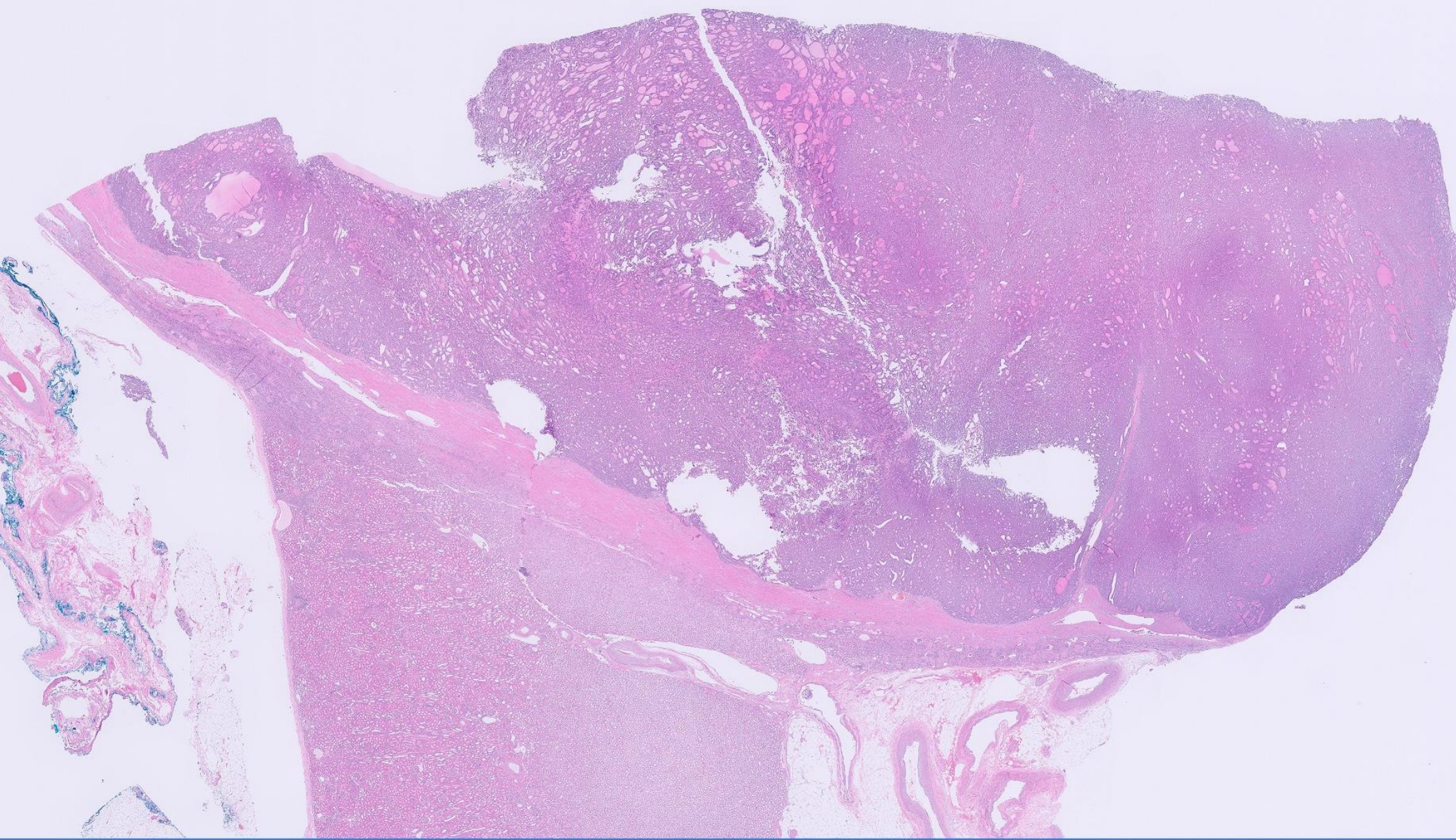
# DIAGNOSIS?



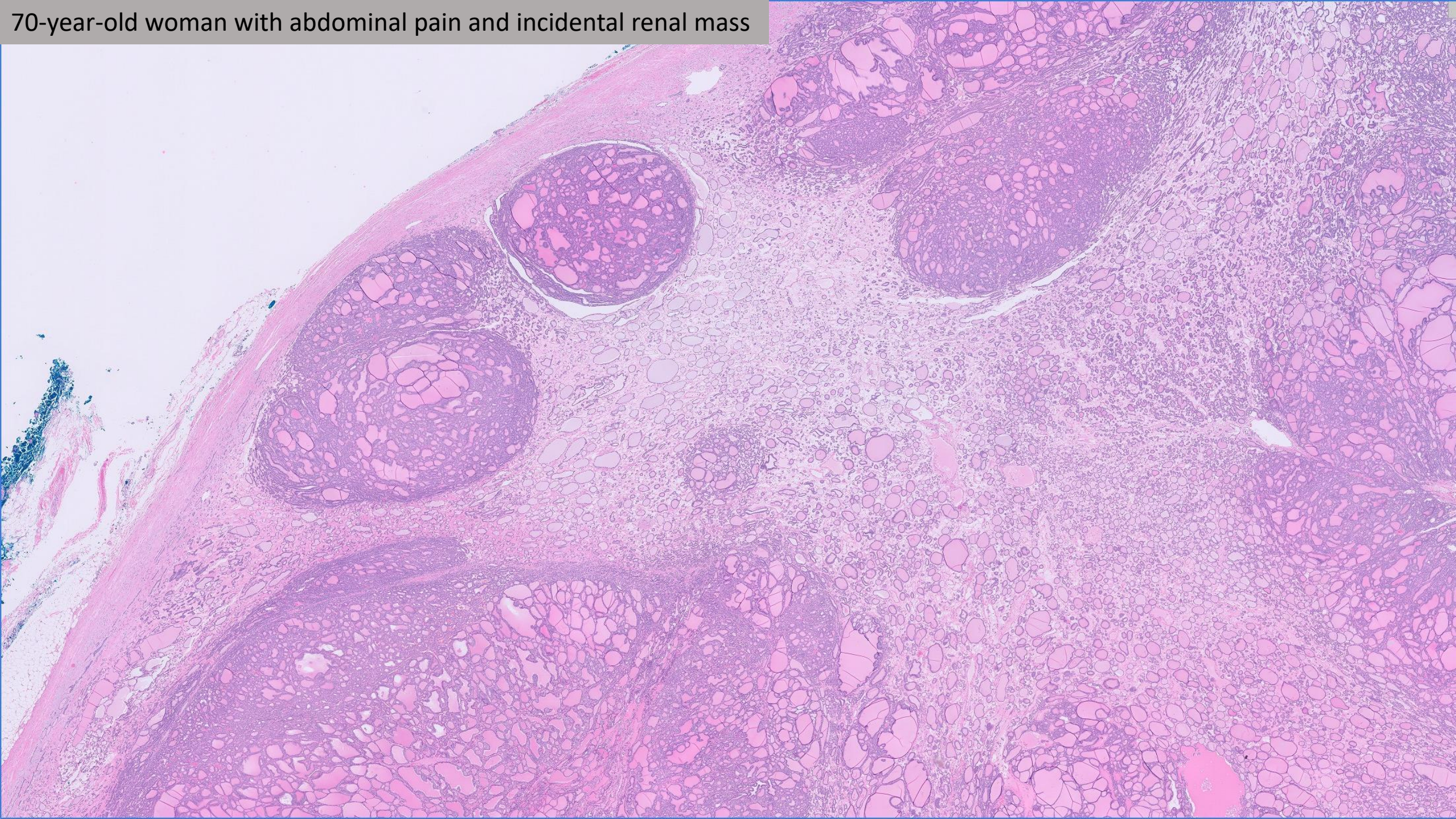
24-0407

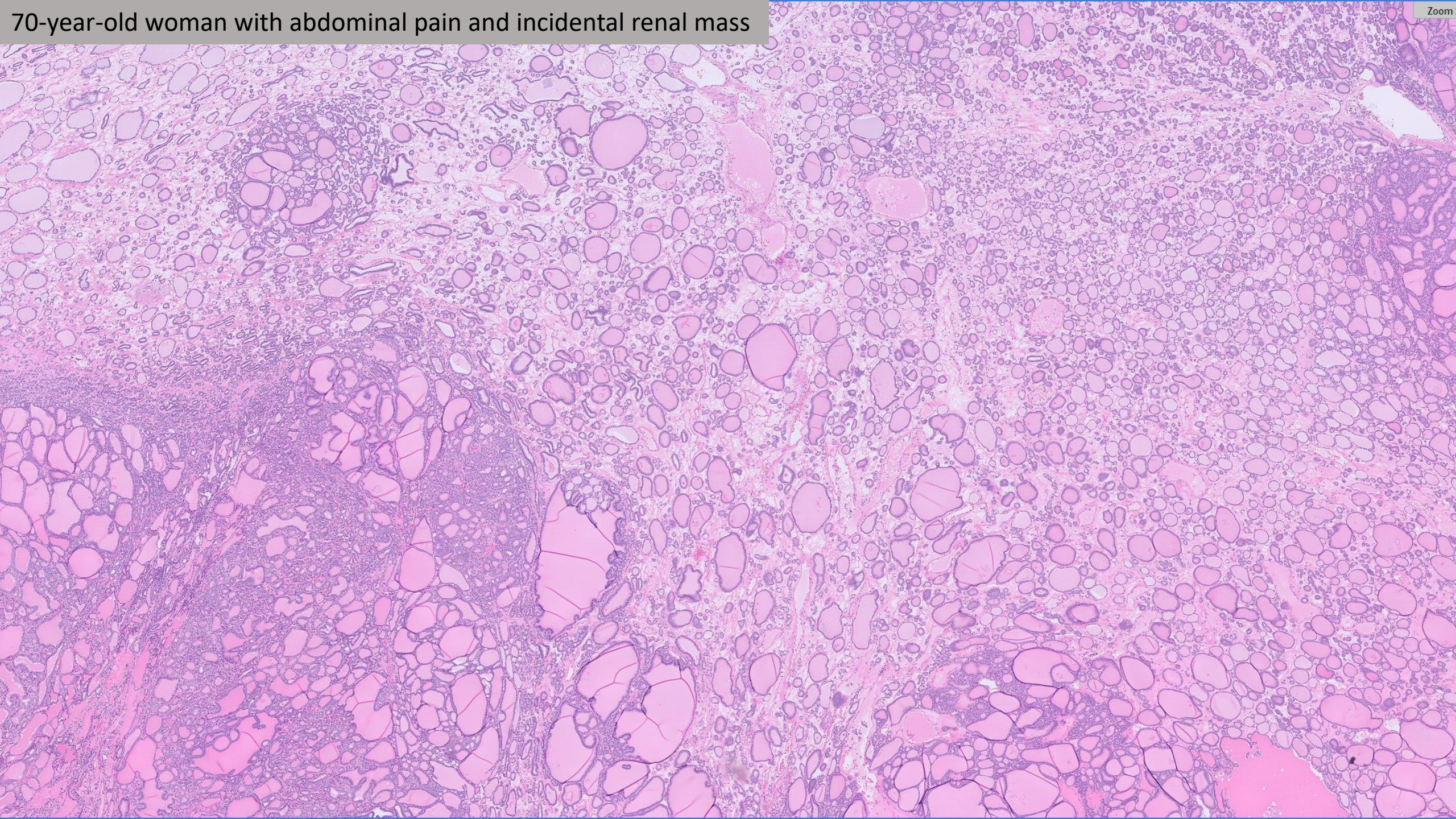
Tyler Jankowski and Ankur Sangoi; Stanford

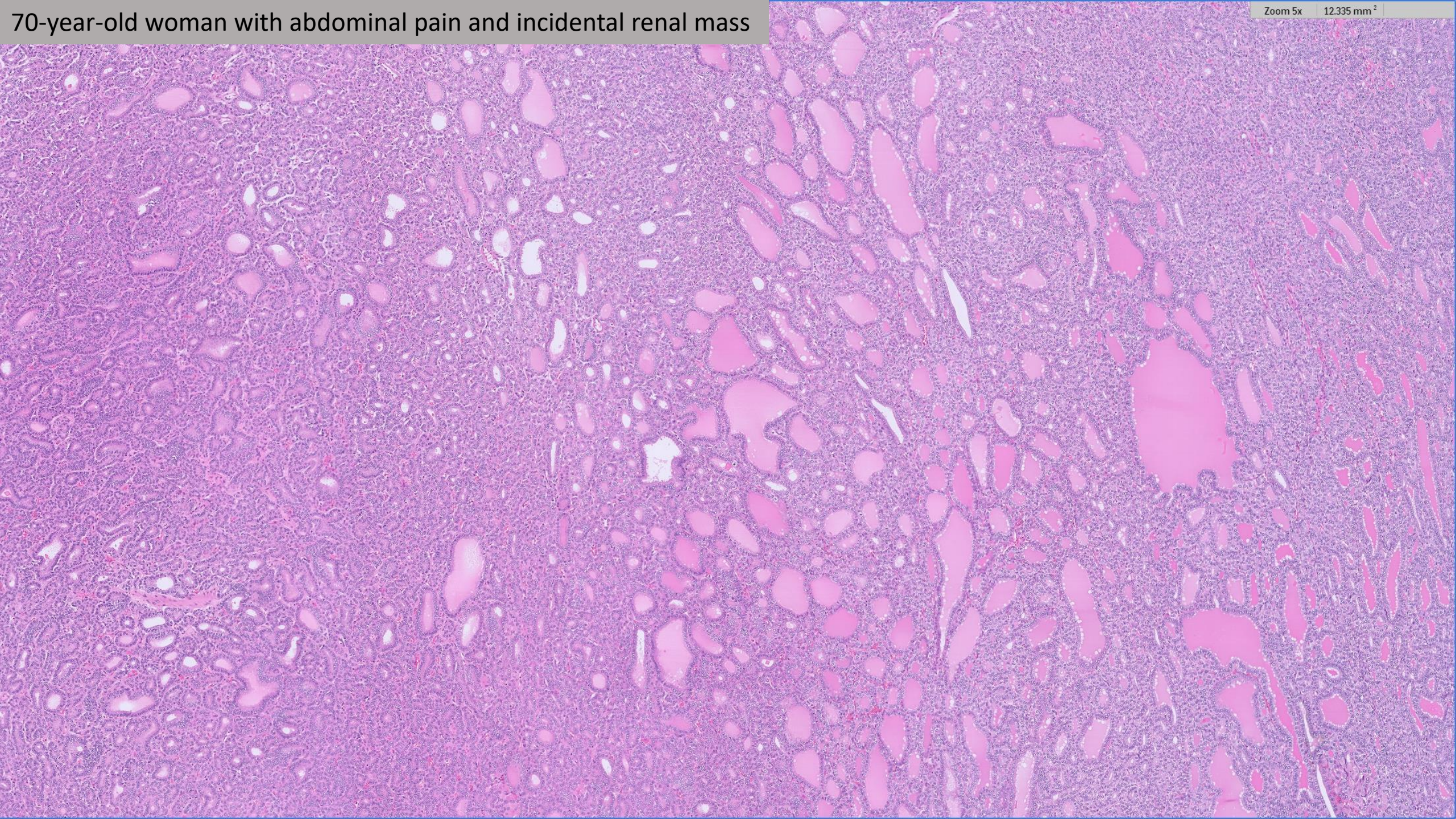
70-year-old woman with abdominal pain and incidental renal mass.

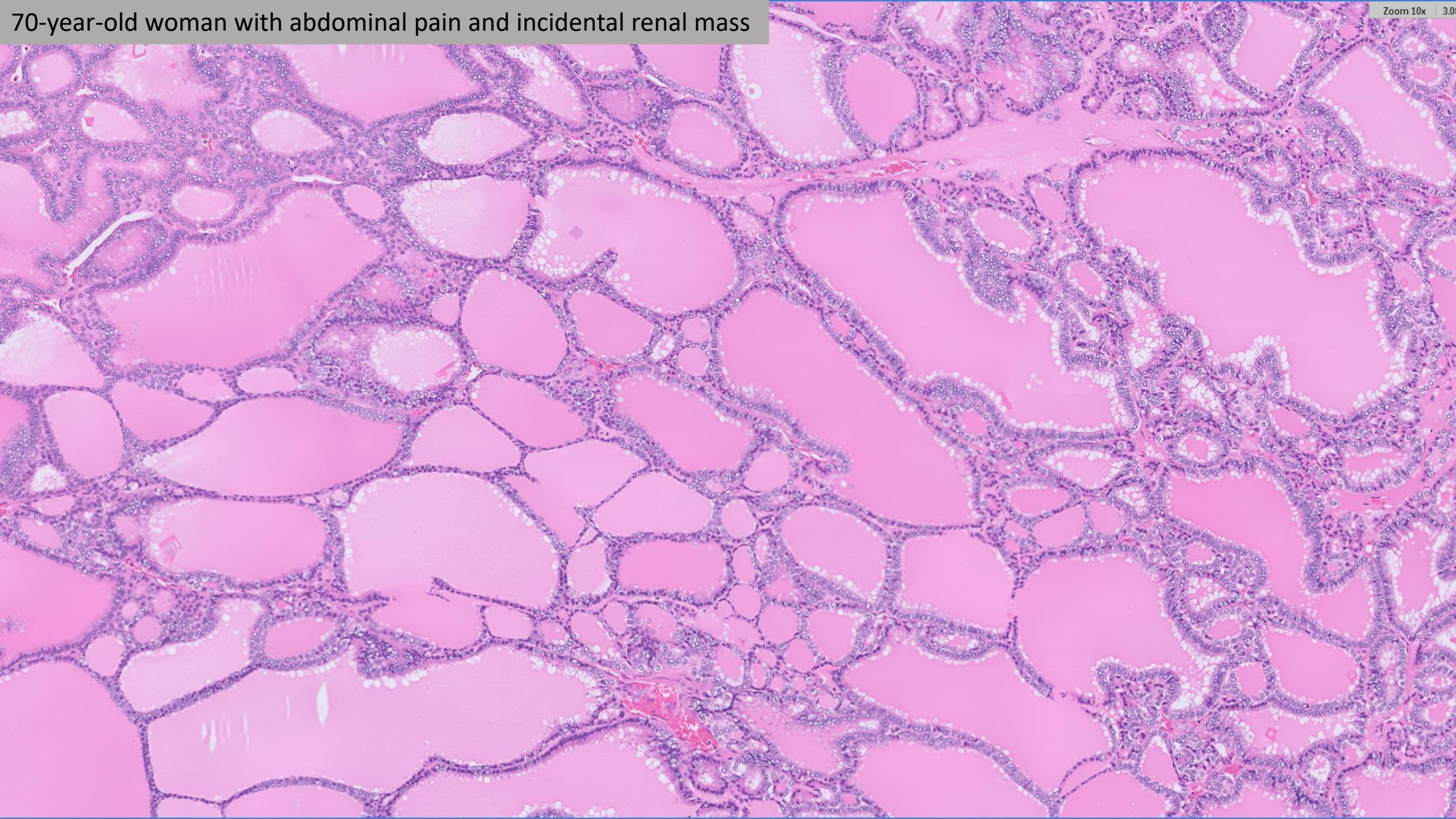


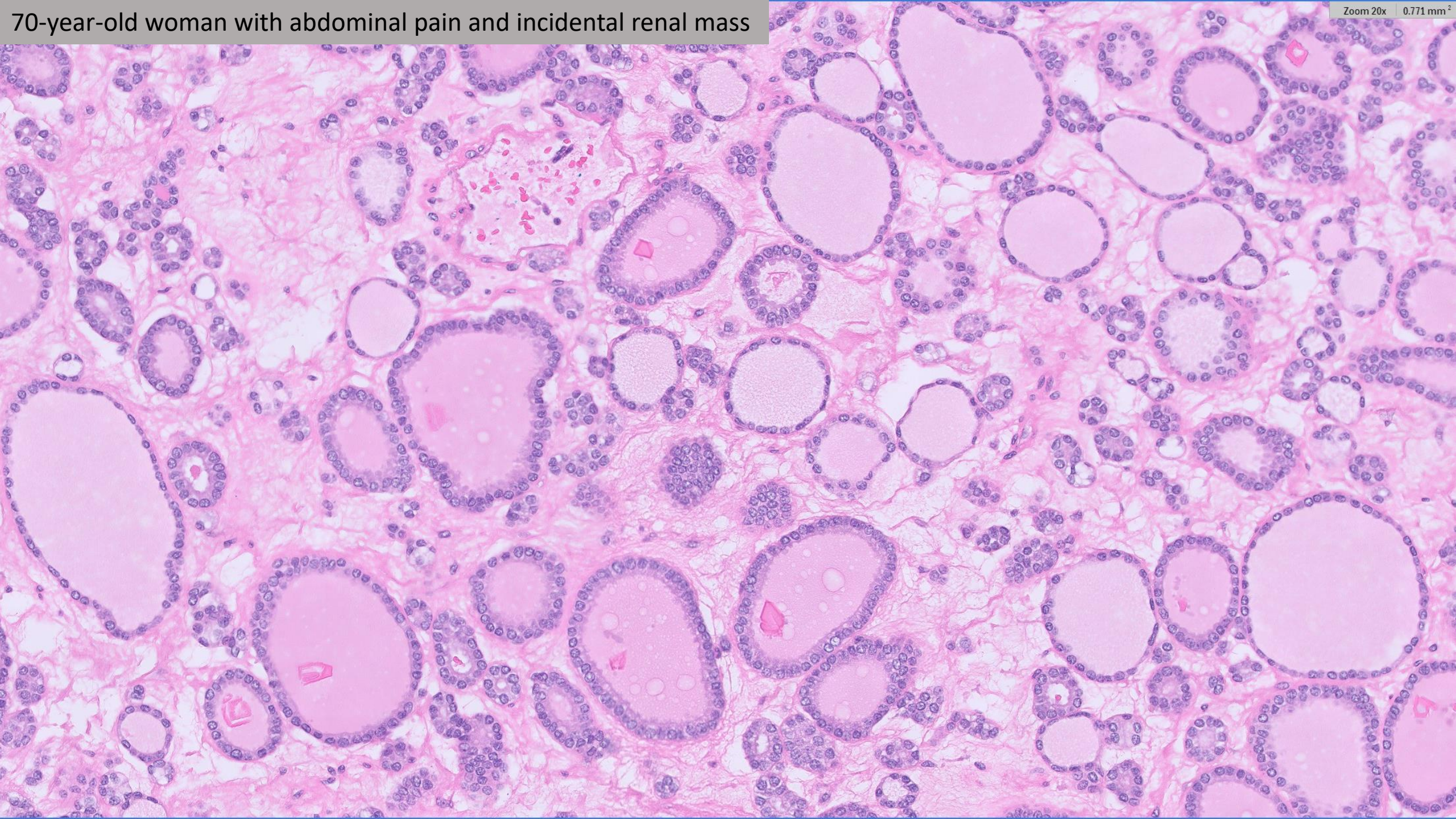
70-year-old woman with abdominal pain and incidental renal mass

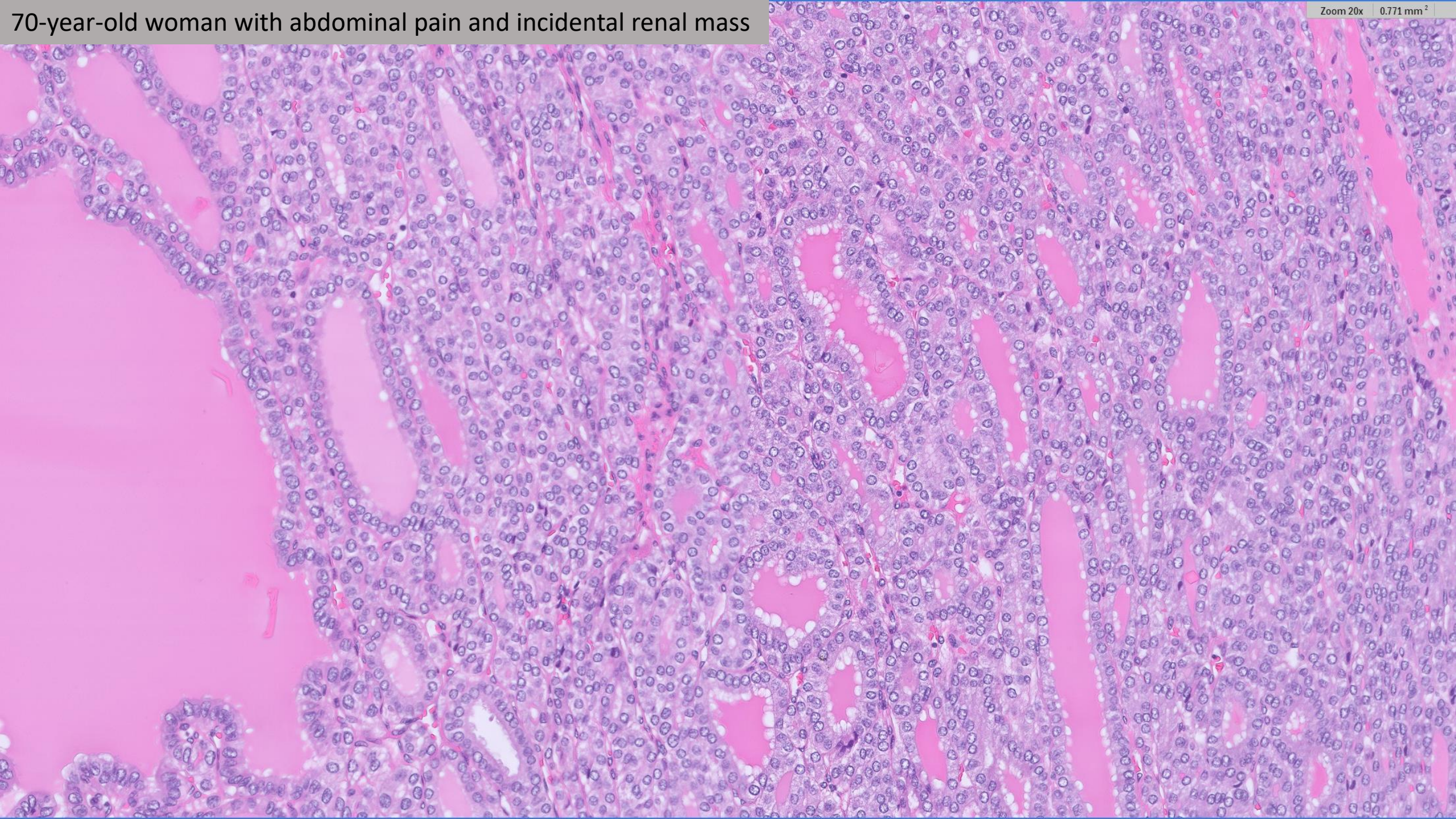


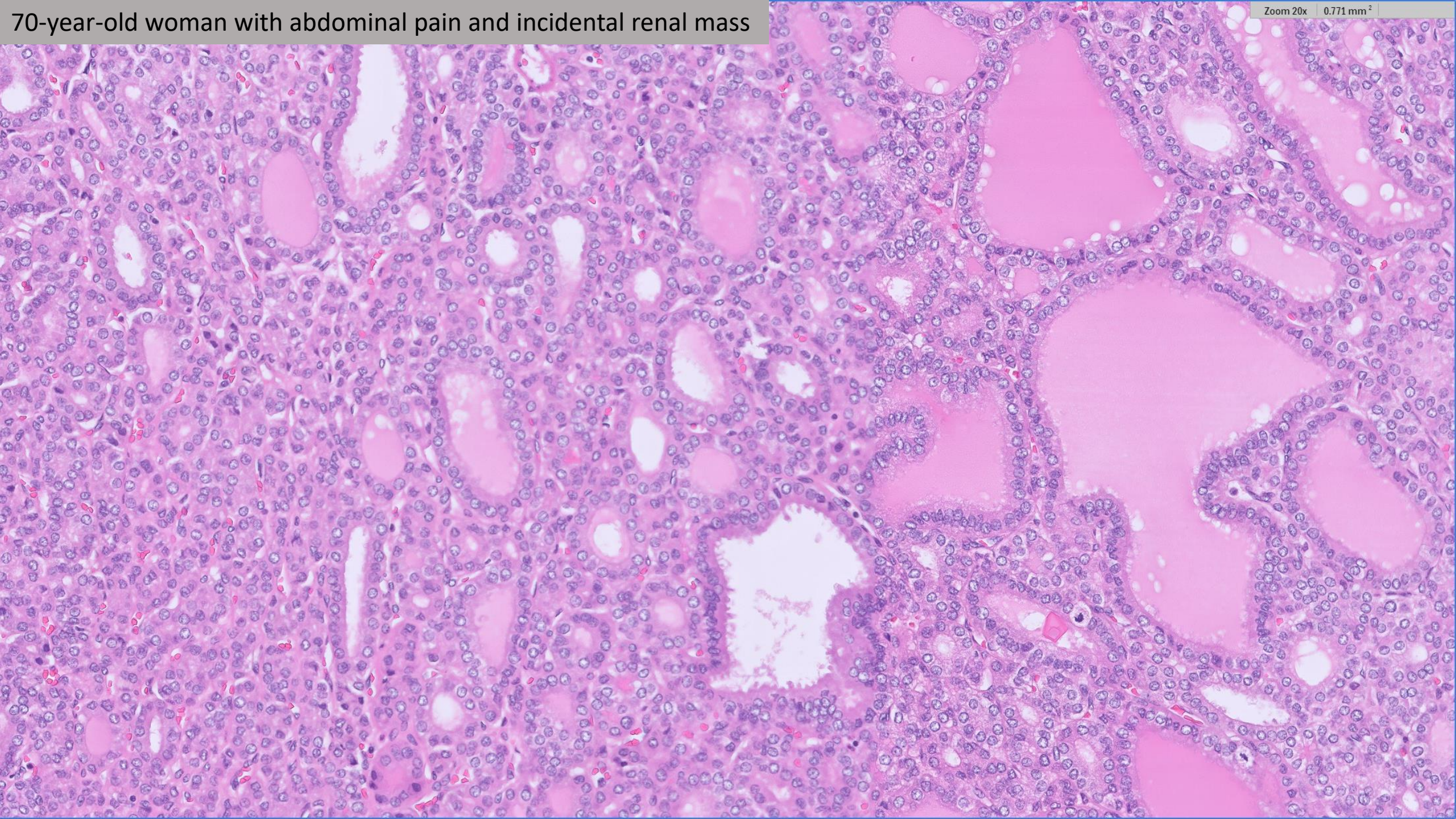




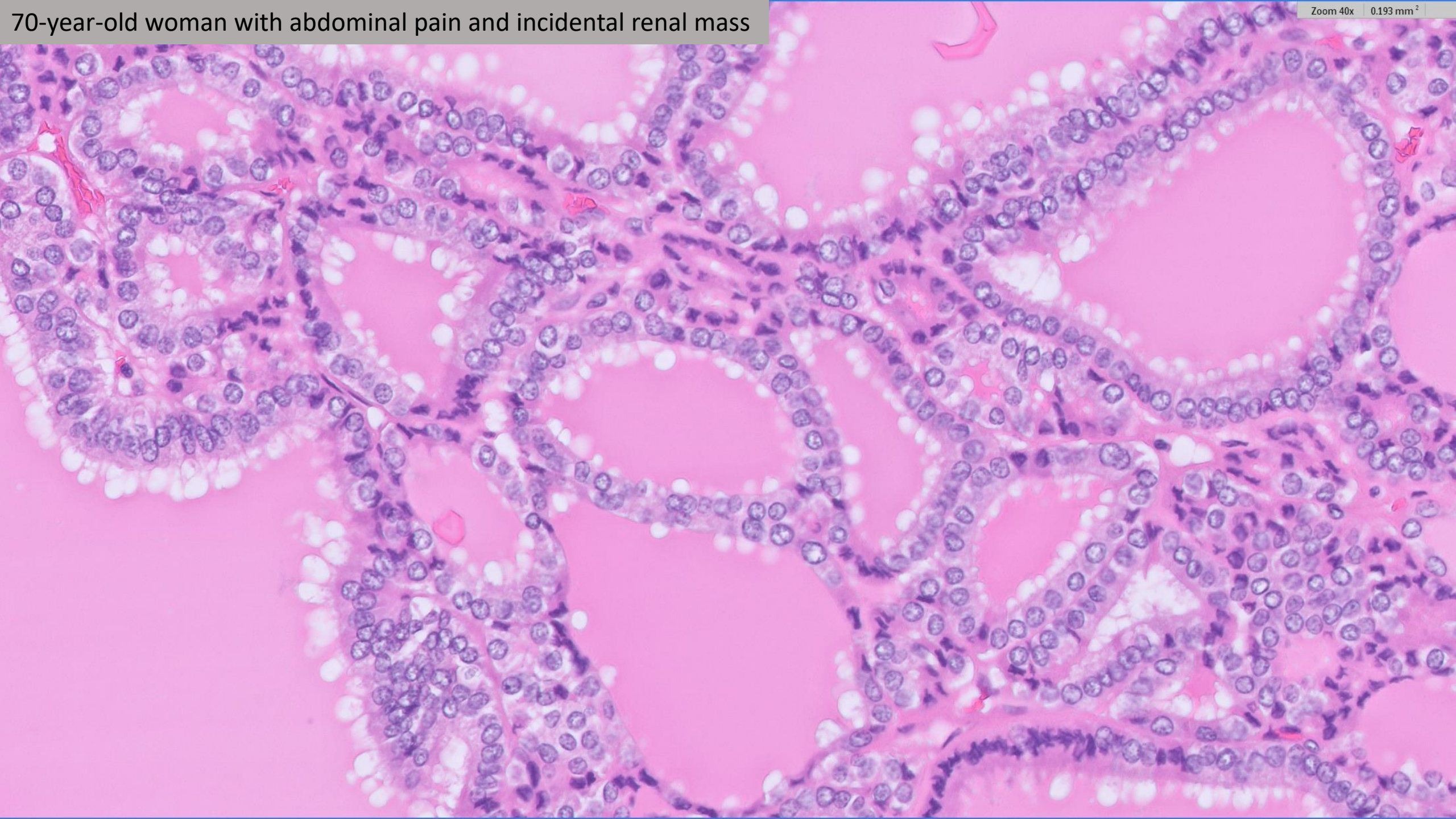


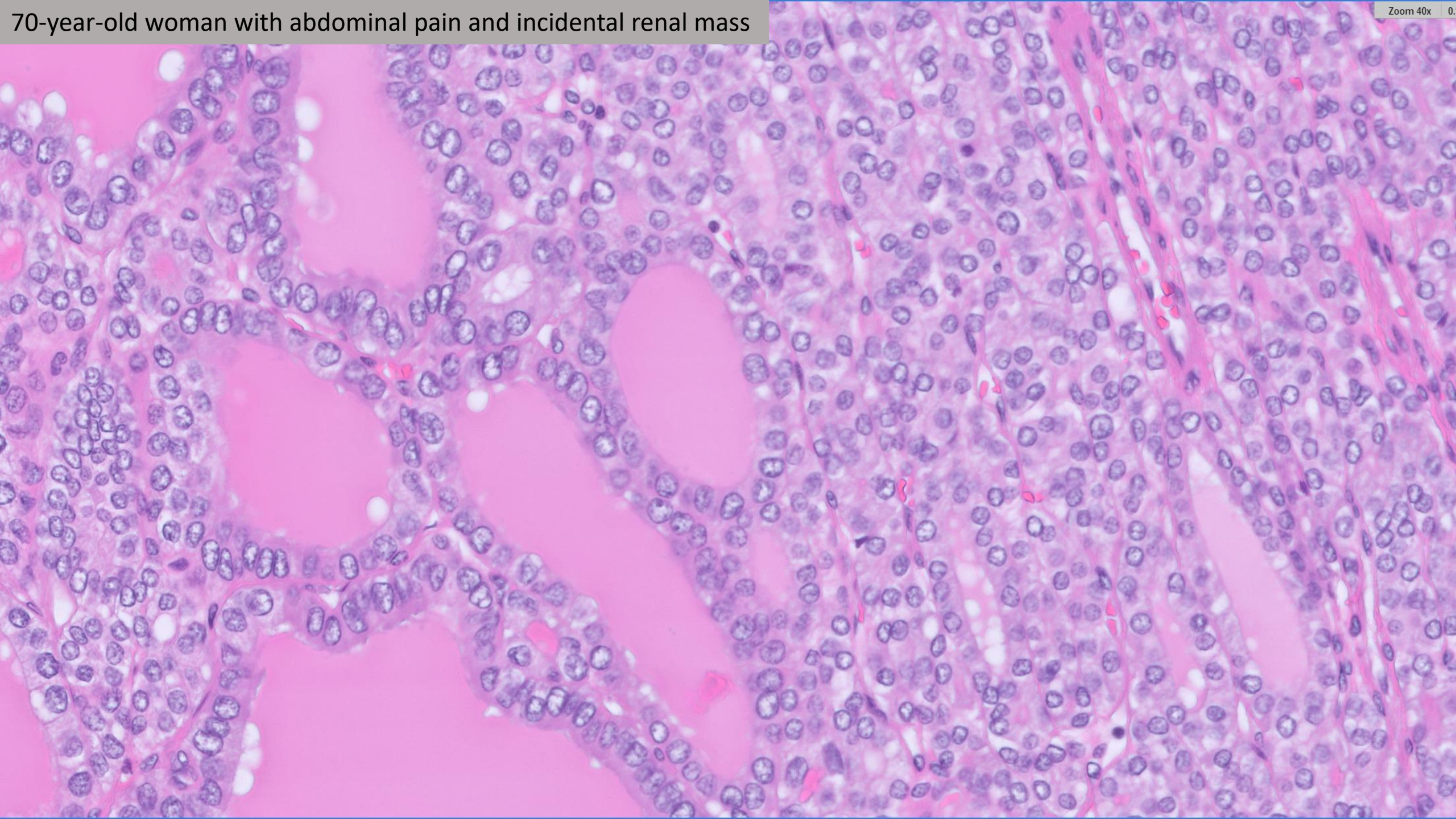






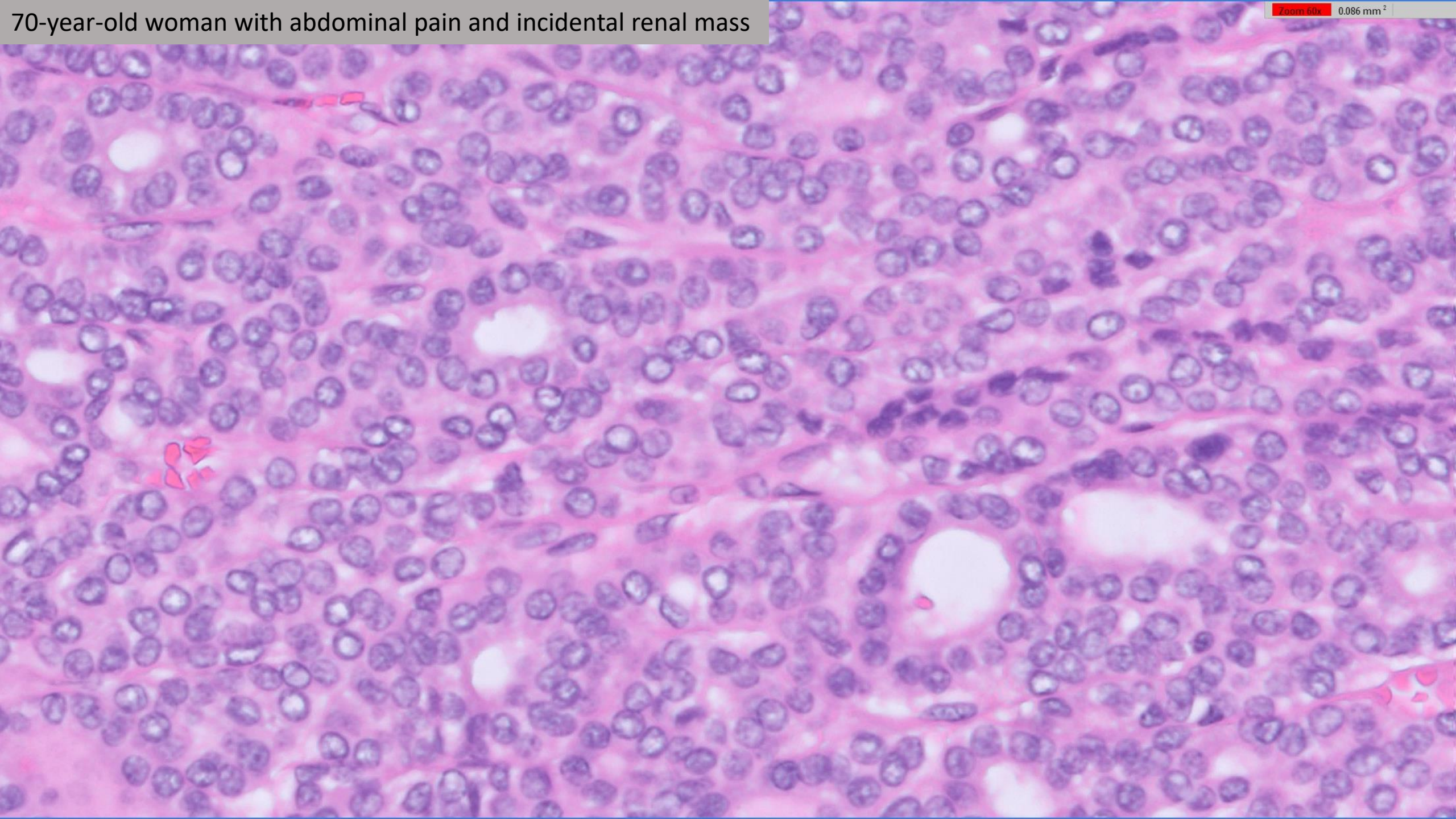
70-year-old woman with abdominal pain and incidental renal mass





70-year-old woman with abdominal pain and incidental renal mass

Zoom 60x 0.086 mm<sup>2</sup>



# DIAGNOSIS?

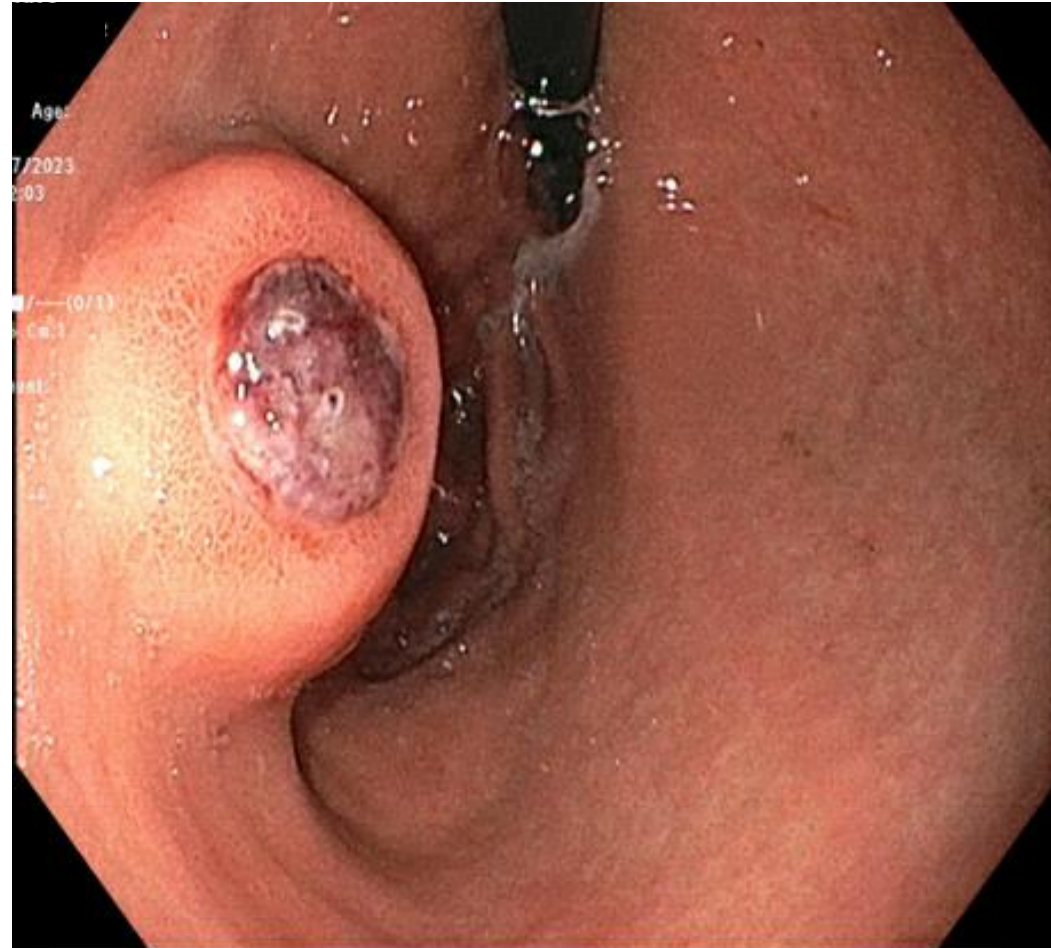


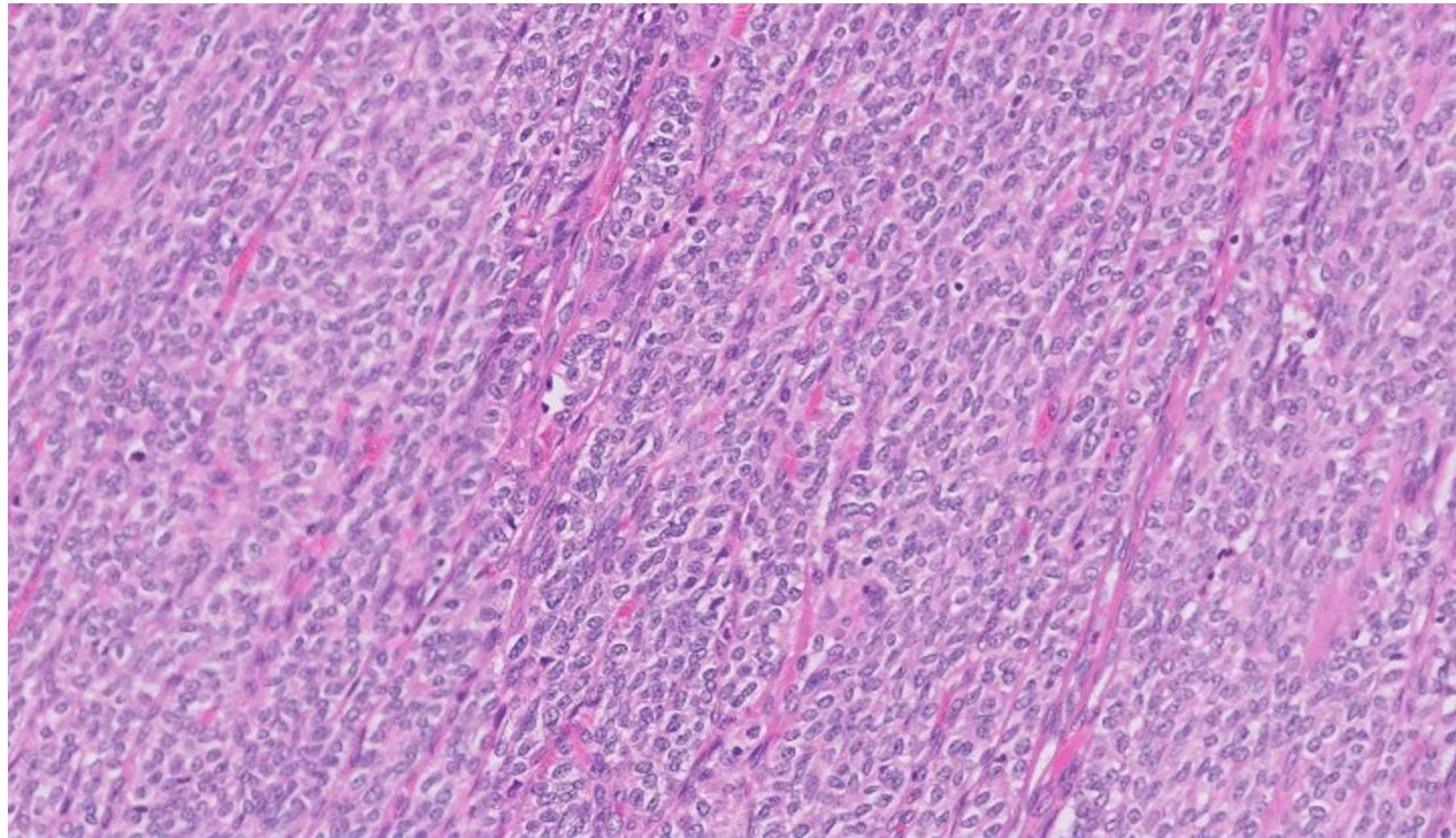
24-0408

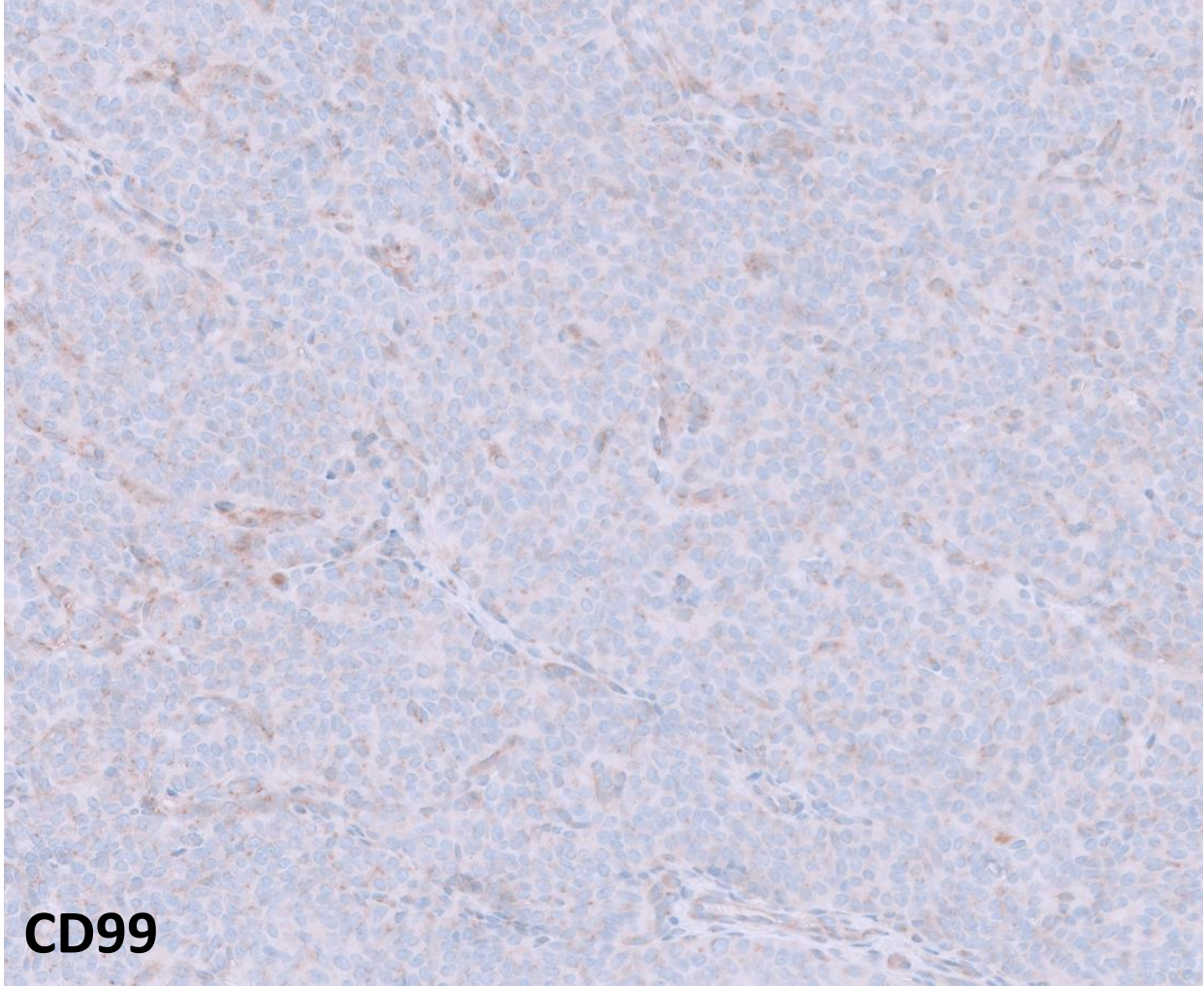
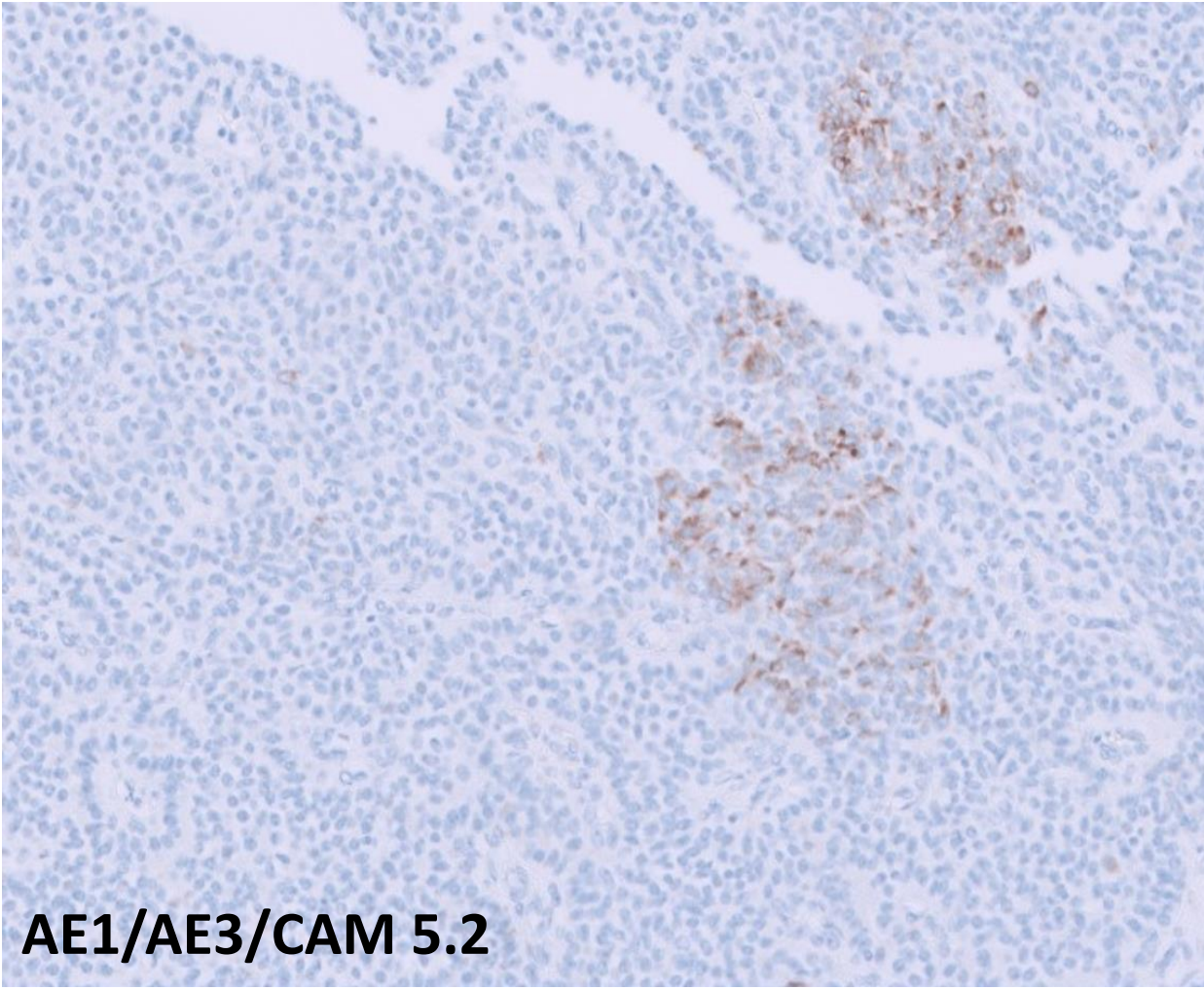
**Oyewale Shiyanbola, Greg Charville and Cindy Wang; Stanford**

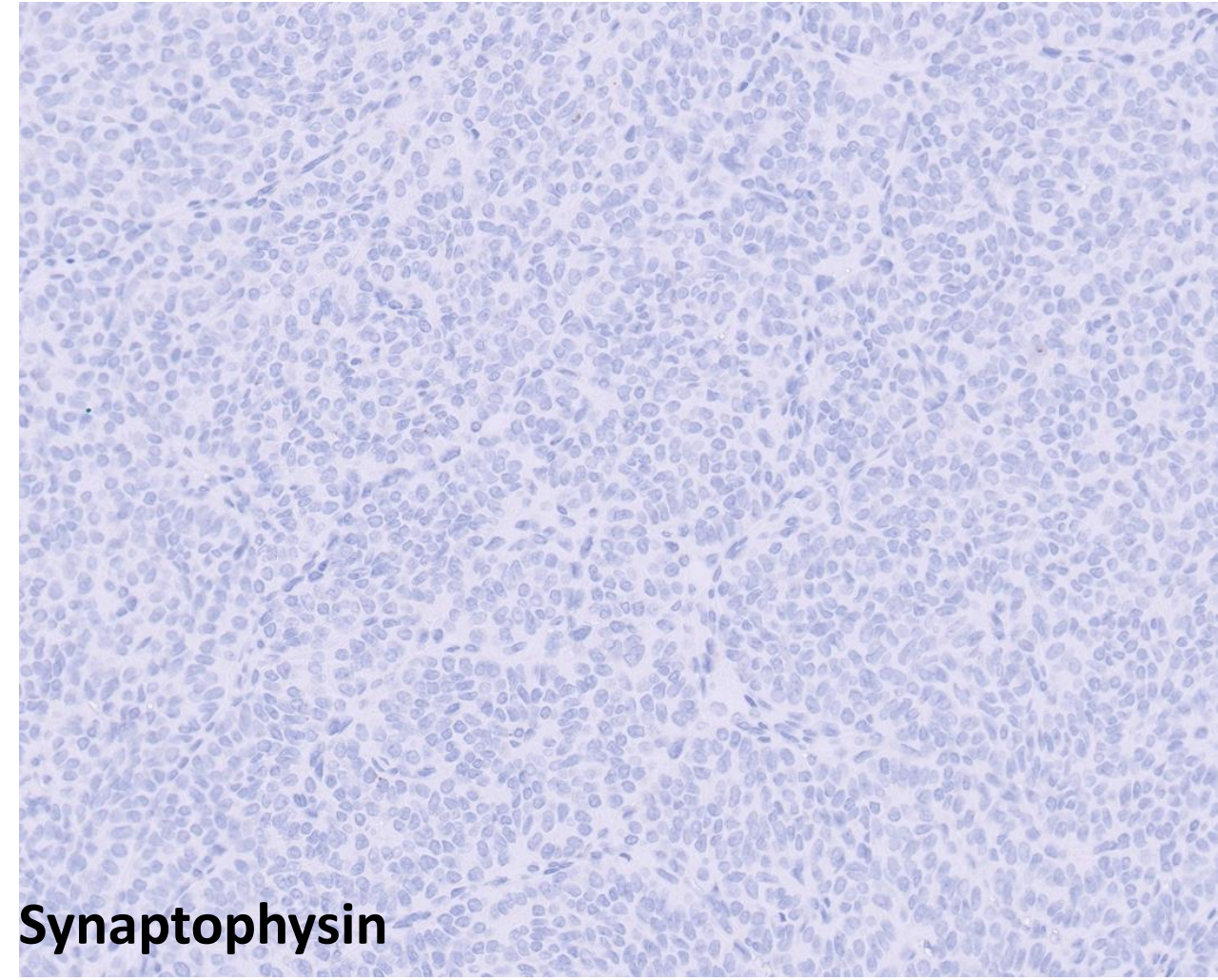
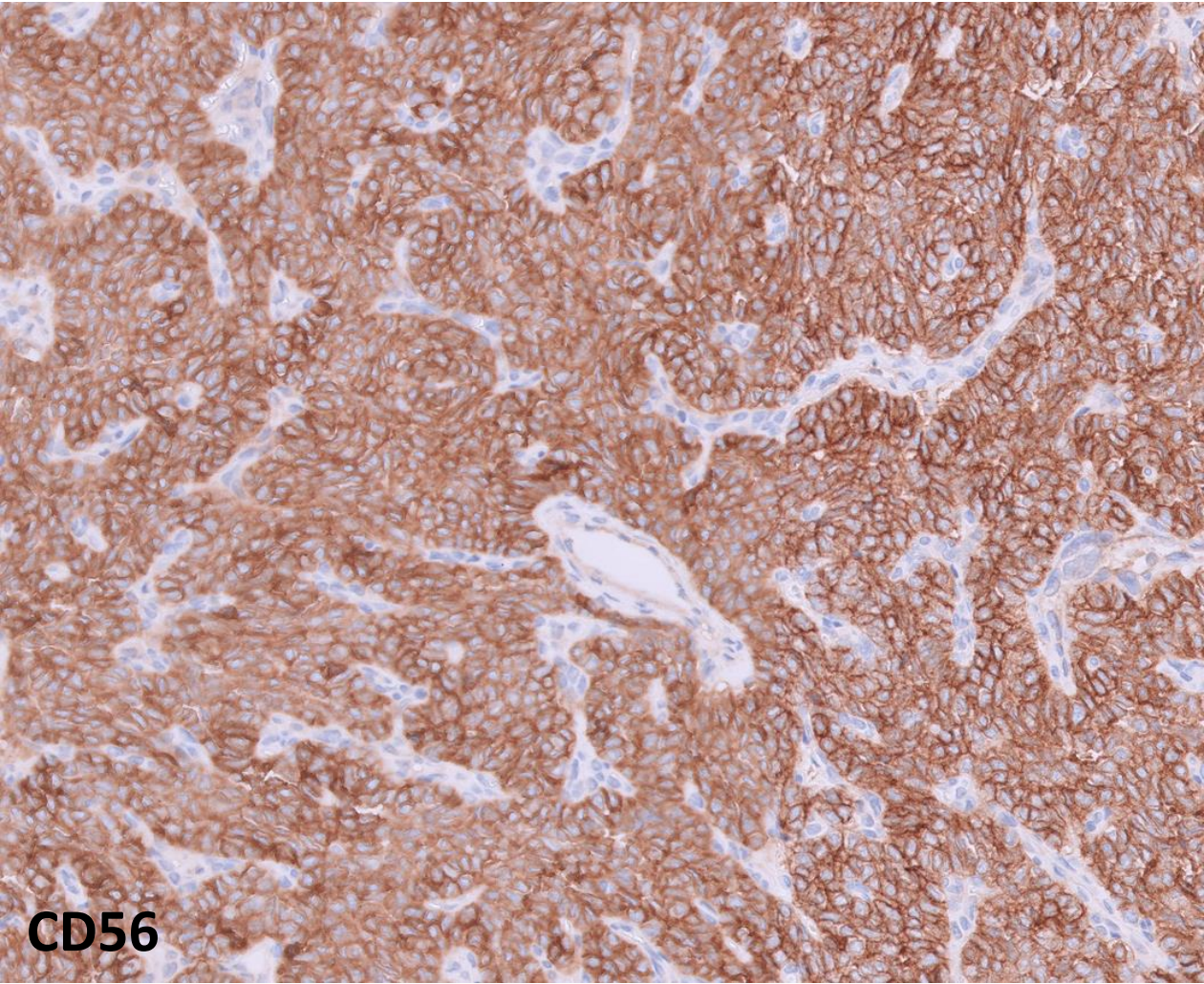
56-year-old male with type 2 diabetes mellitus, presenting to the emergency department for severe fatigue in the setting of recurrent dark stools

# Upper GI Endoscopy









# DIAGNOSIS?

