

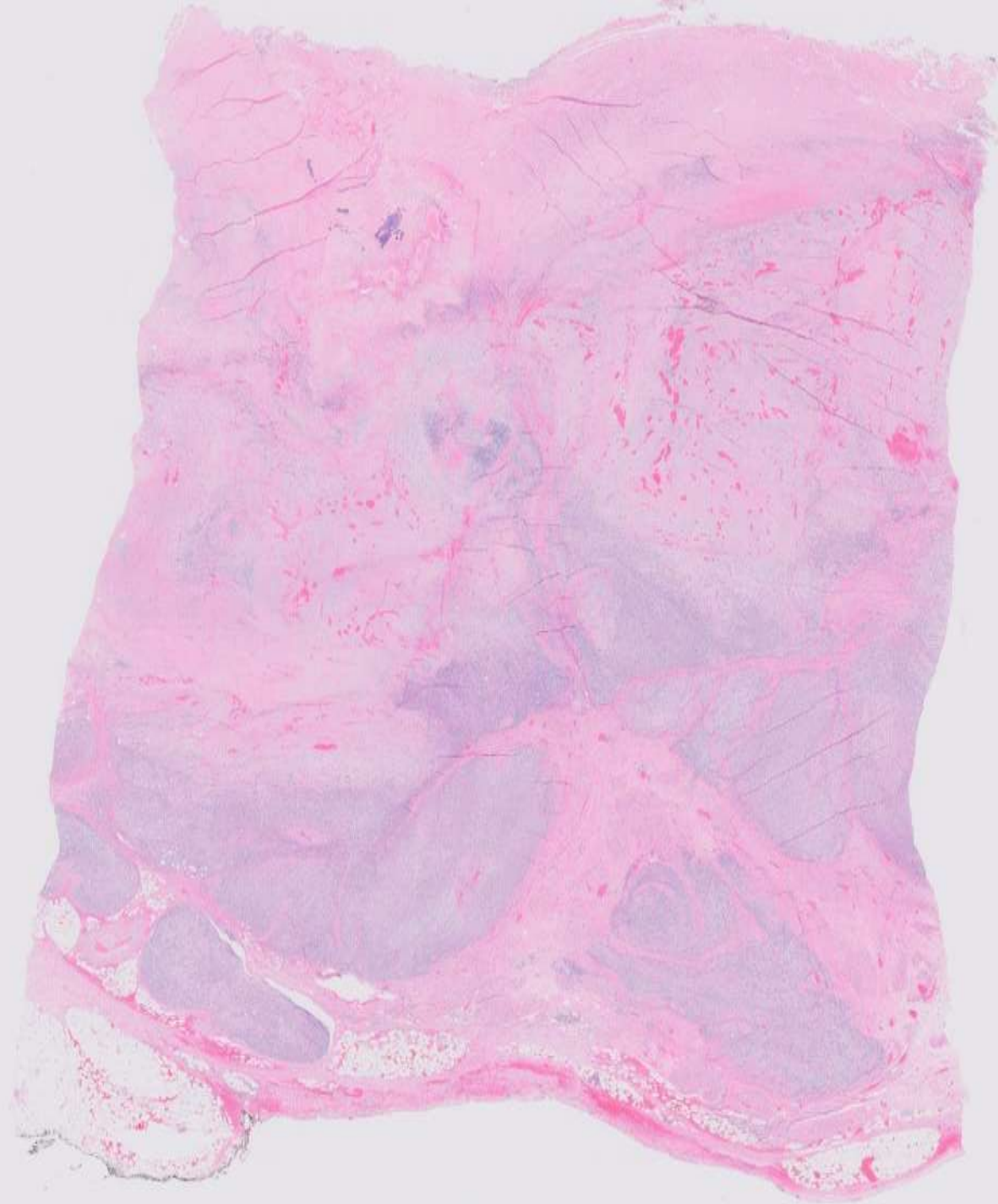EVALUATION QR CODE!
Hold smartphone camera on code



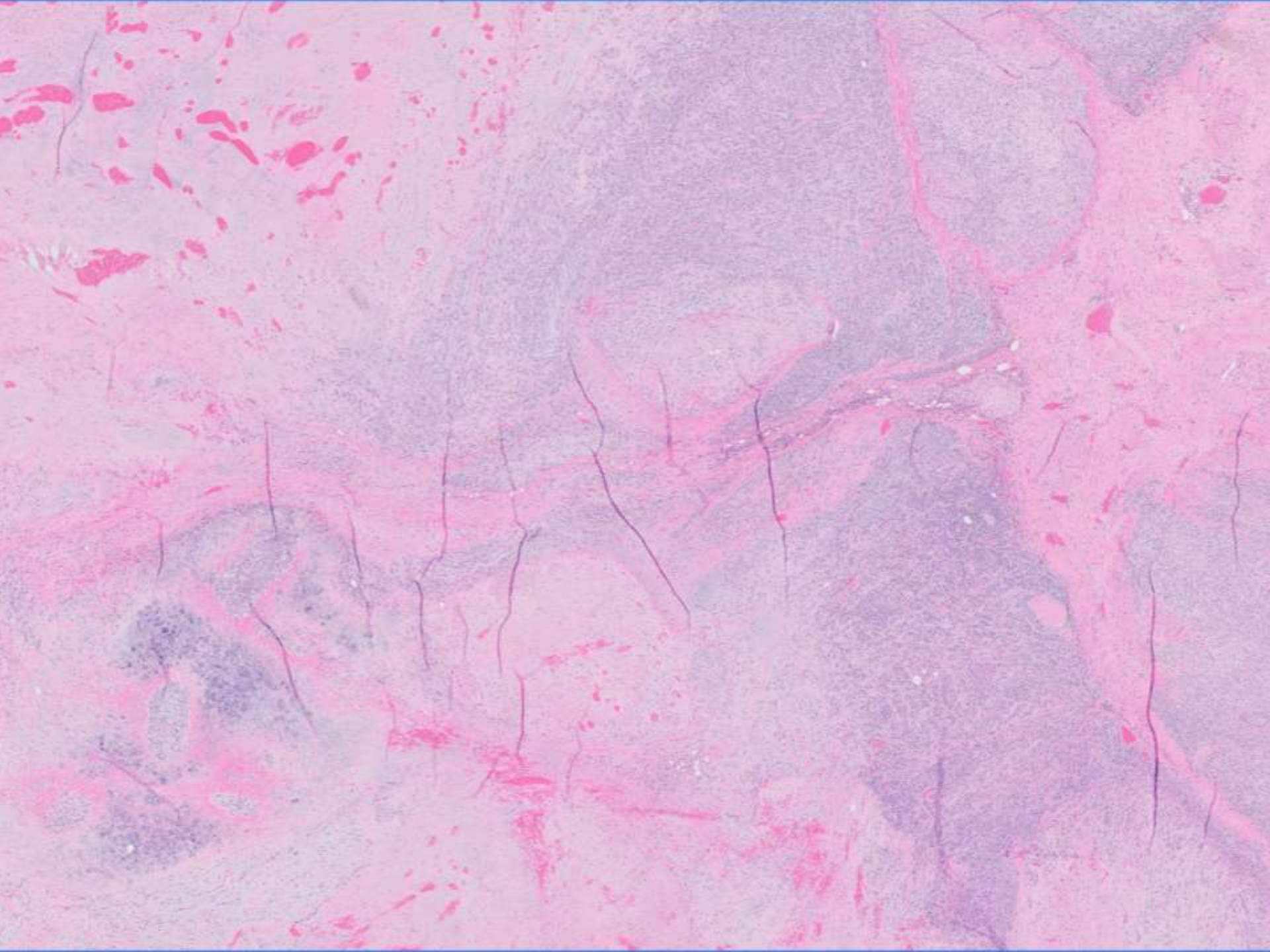
23-0401

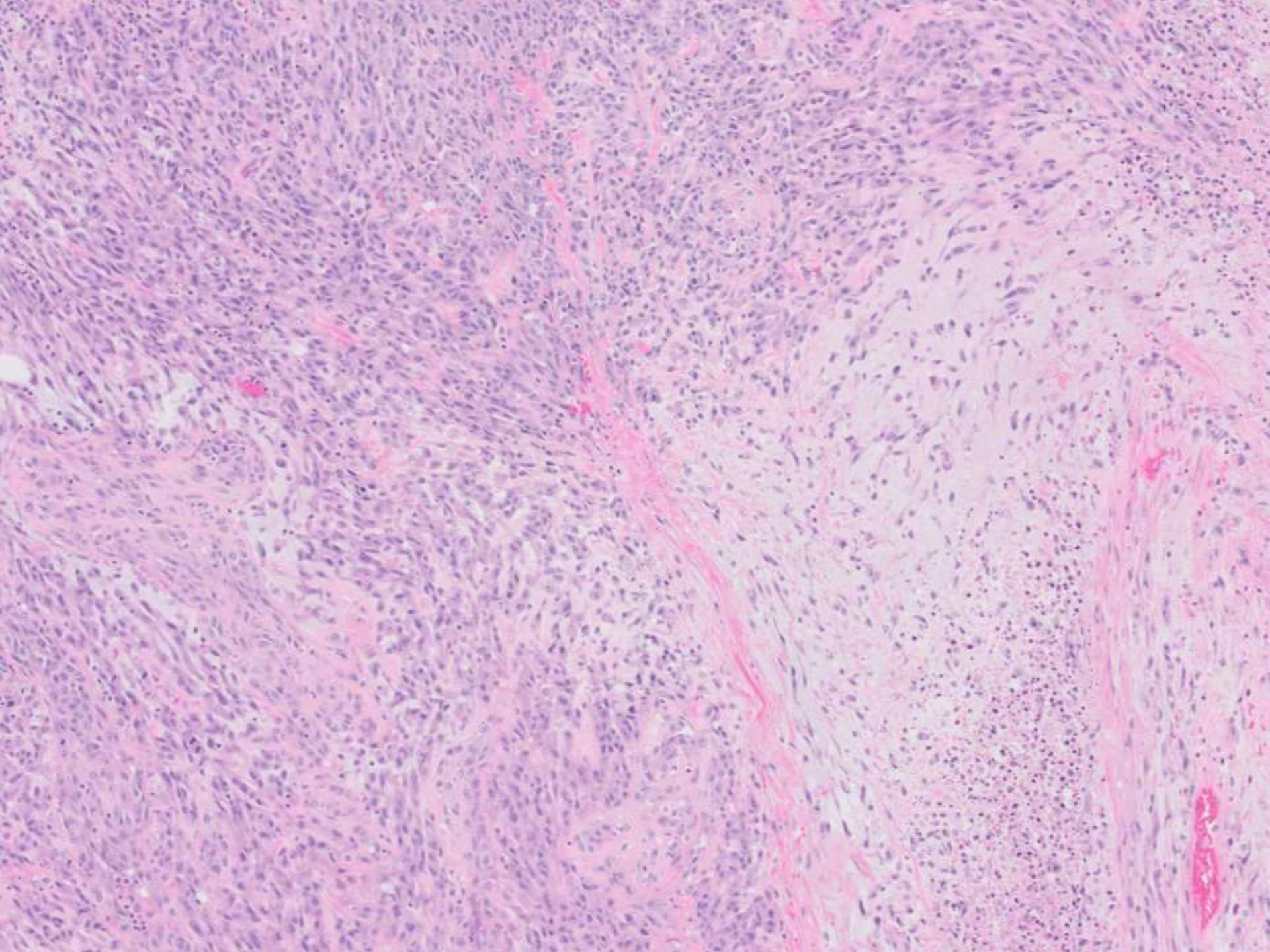
Ingold Huang/Emily Chan; UCSF

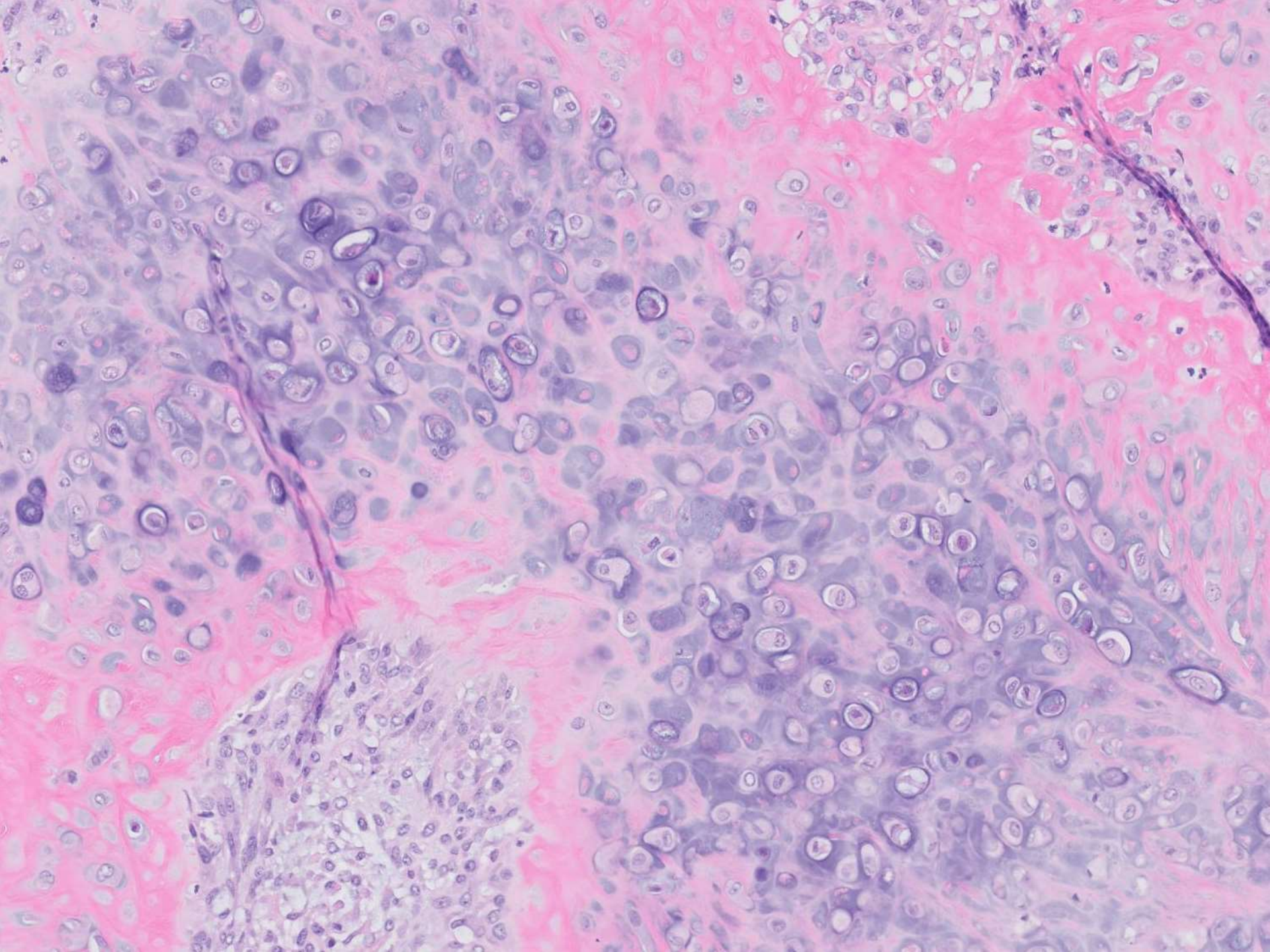
80ish M with remote h/o prostatic adenocarcinoma
treated with radiation and androgen deprivation therapy.
Now undergoes radical cystoprostatectomy for 12cm
urinary bladder mass.

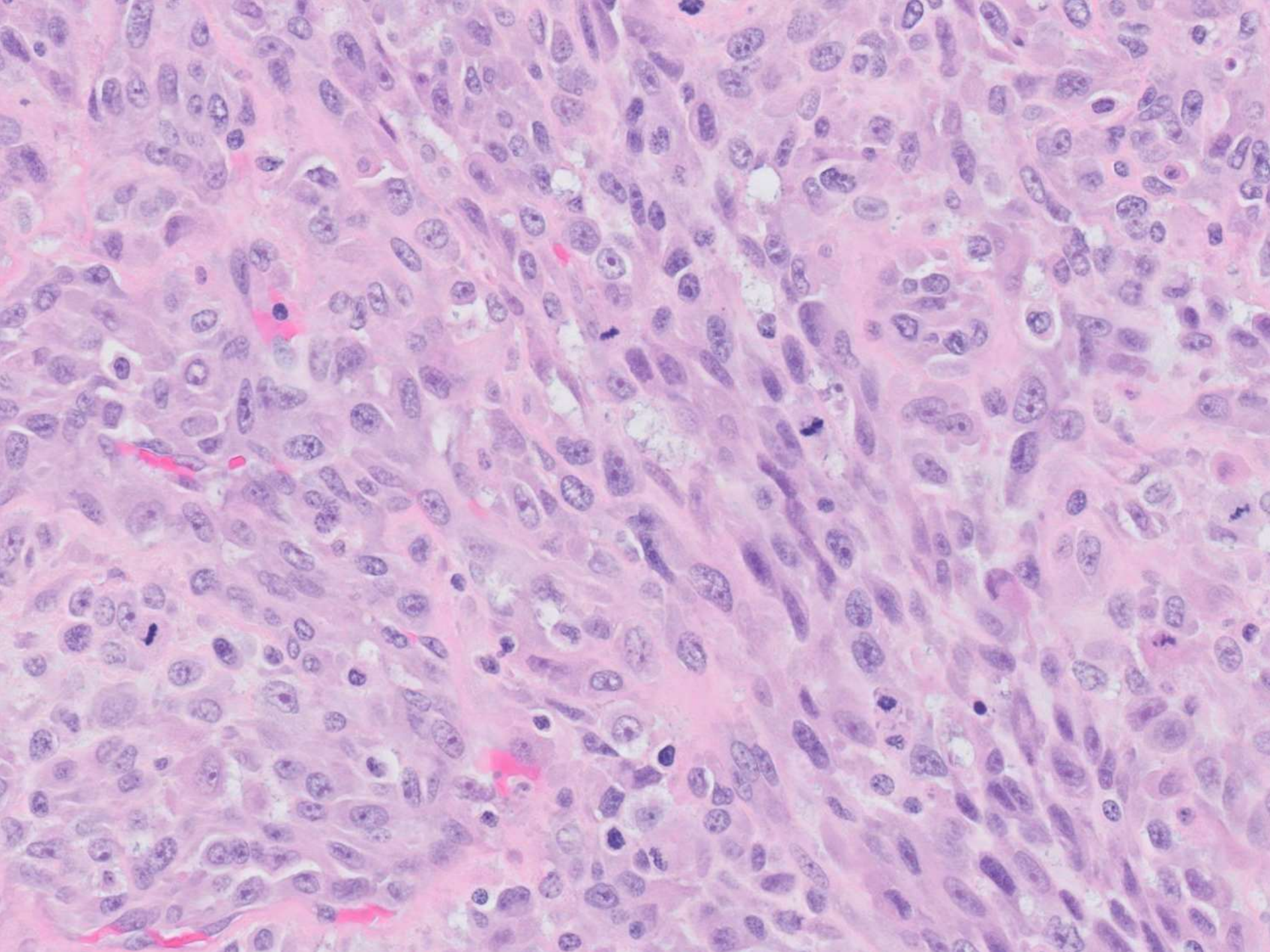


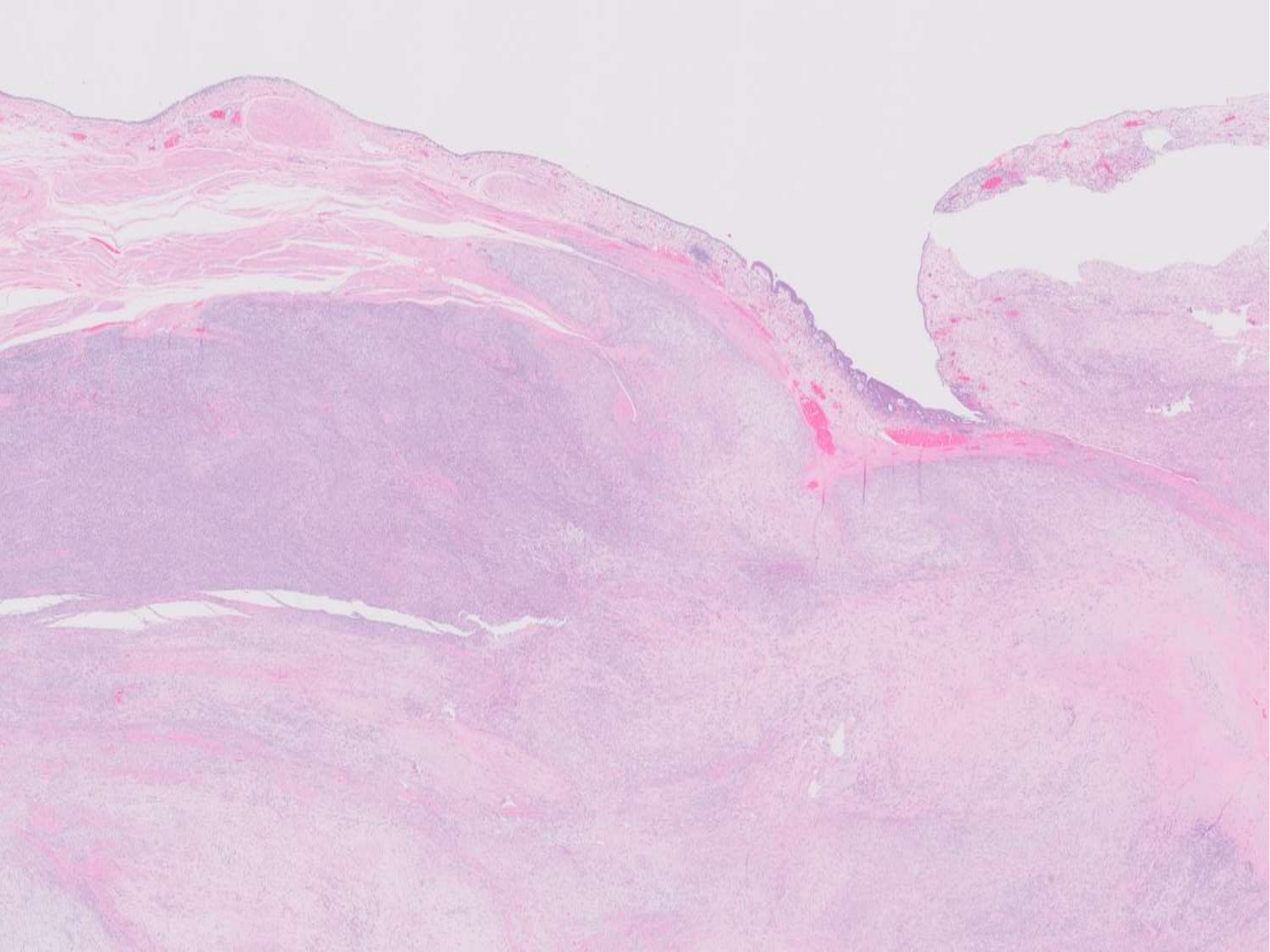
Urinary bladder,
full-thickness
cross section

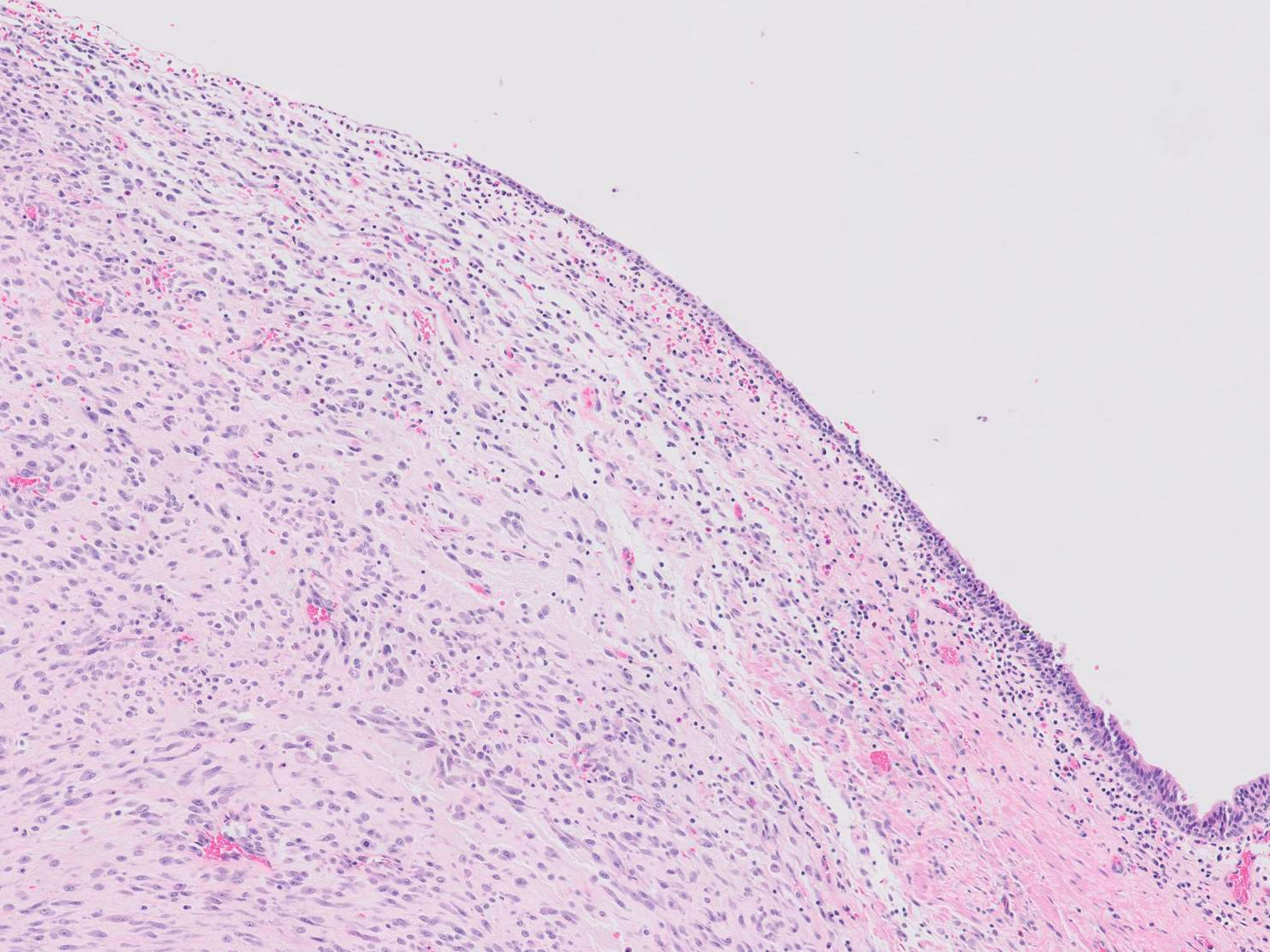


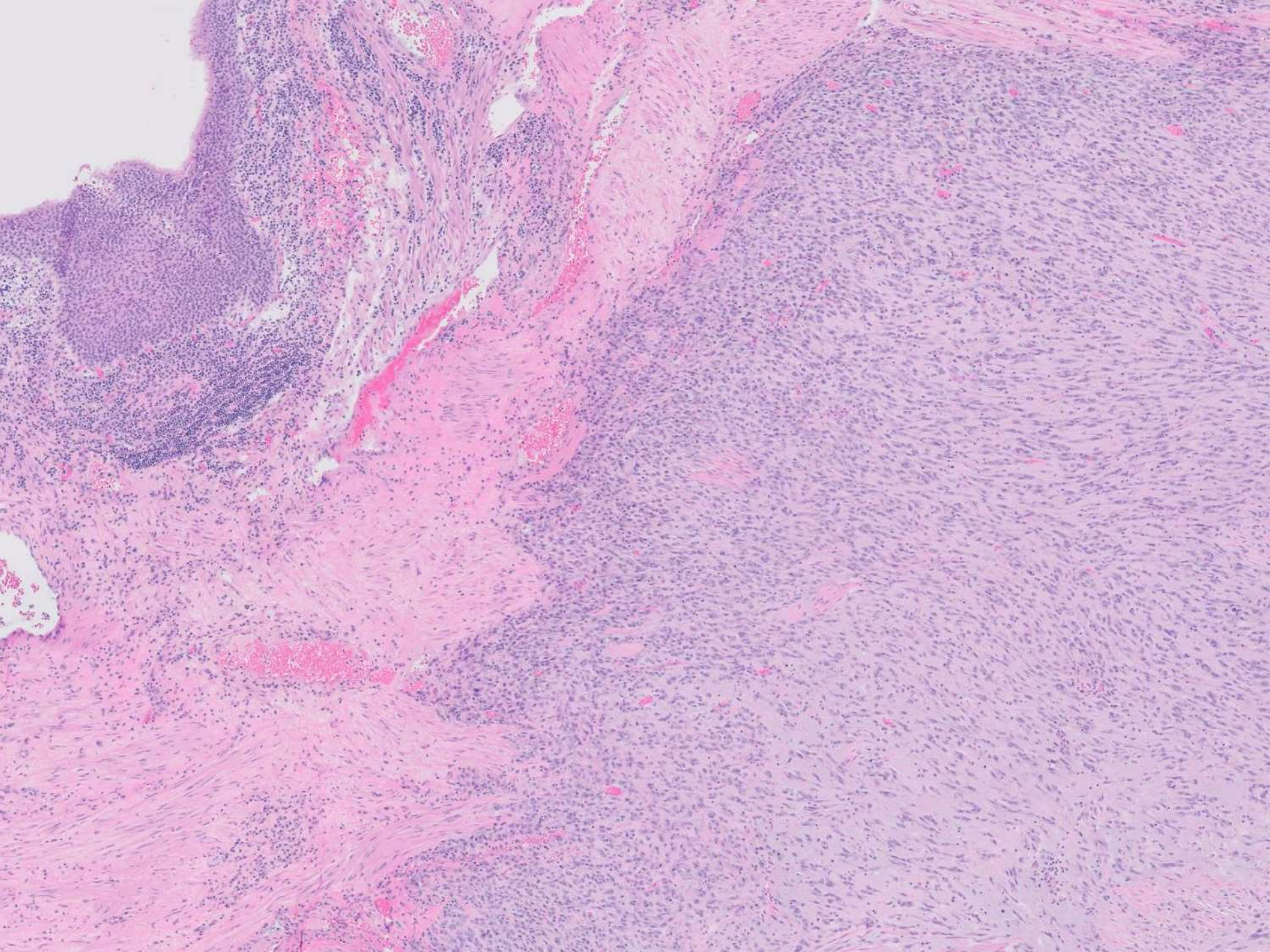












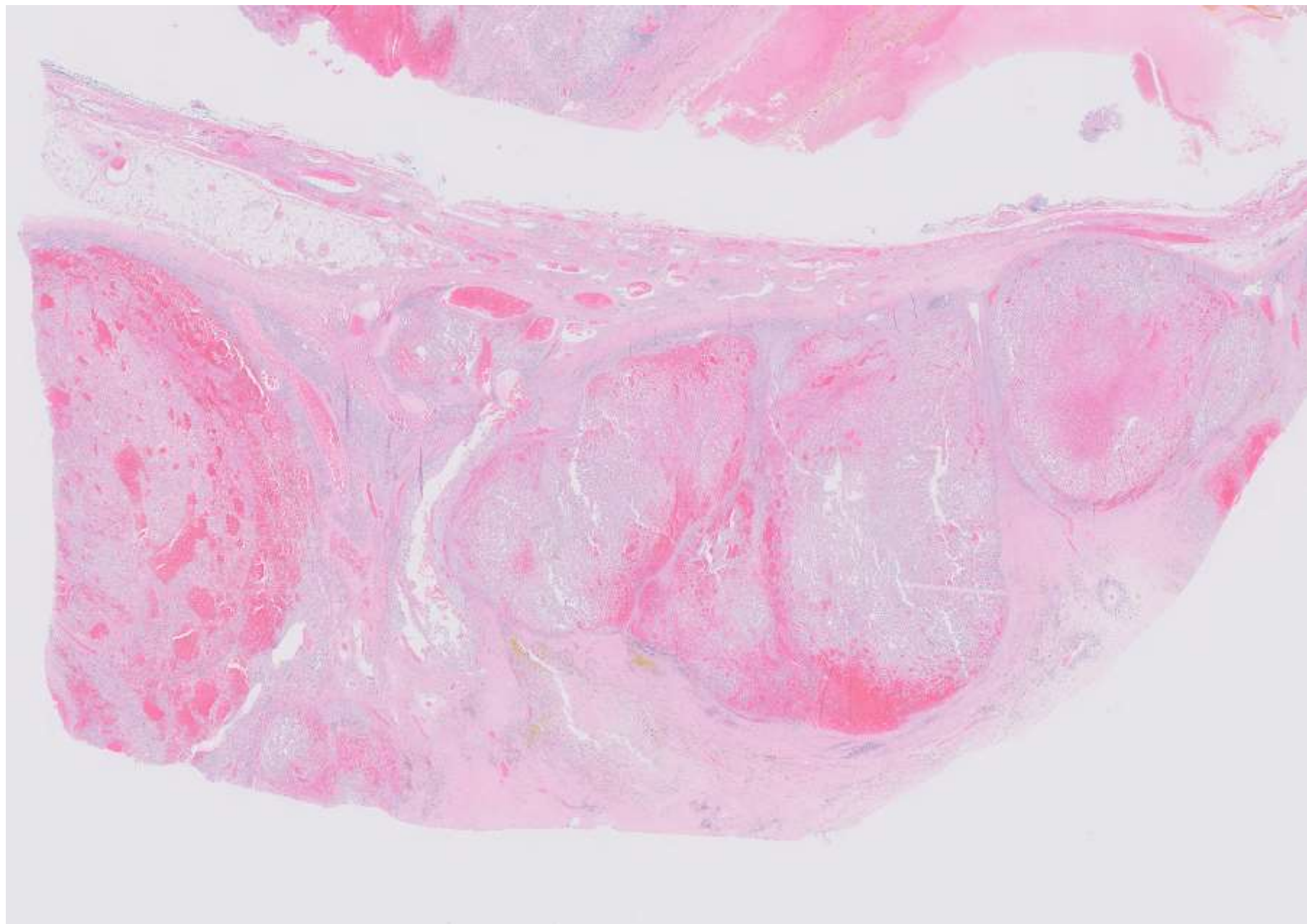
DIAGNOSIS?

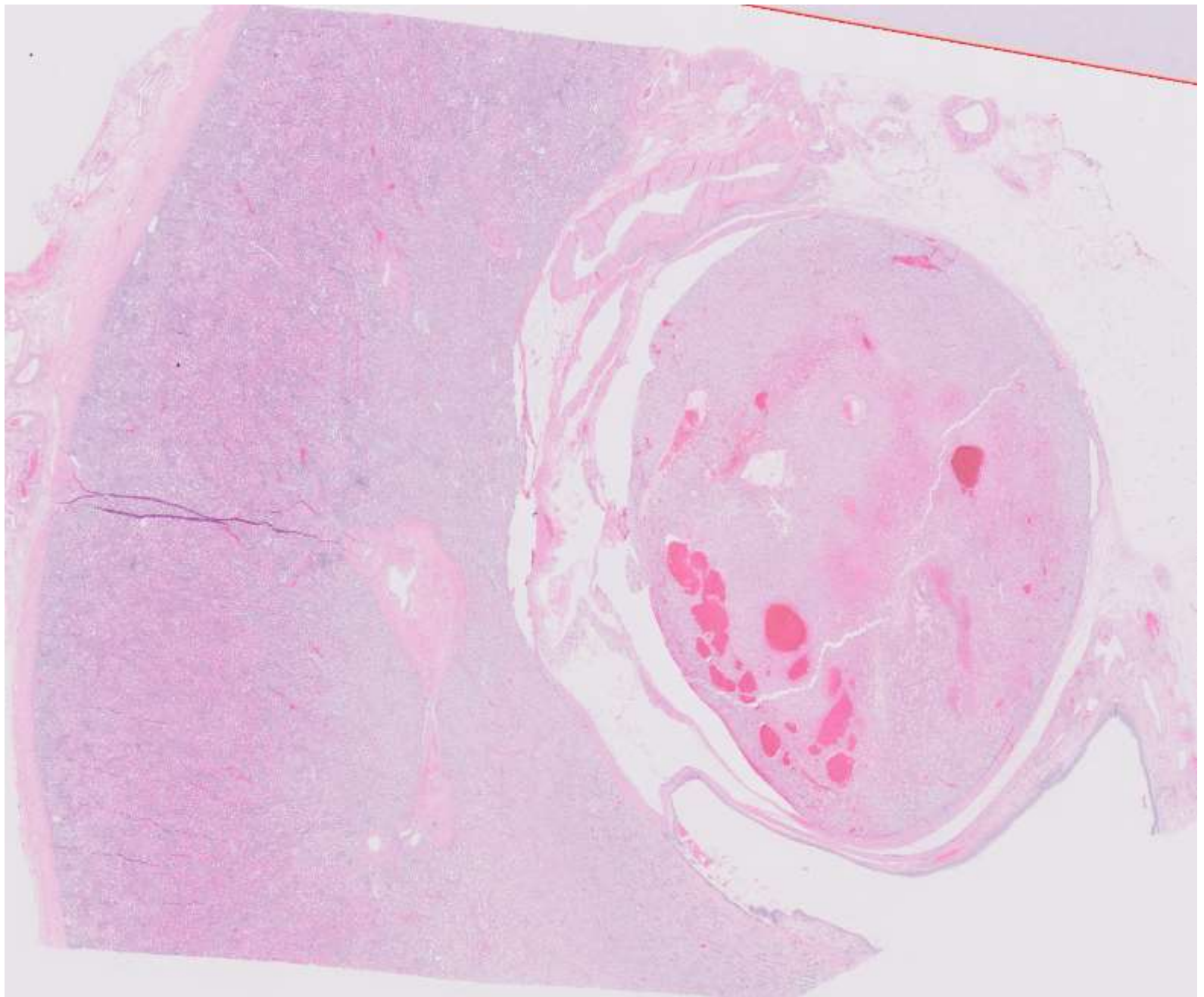


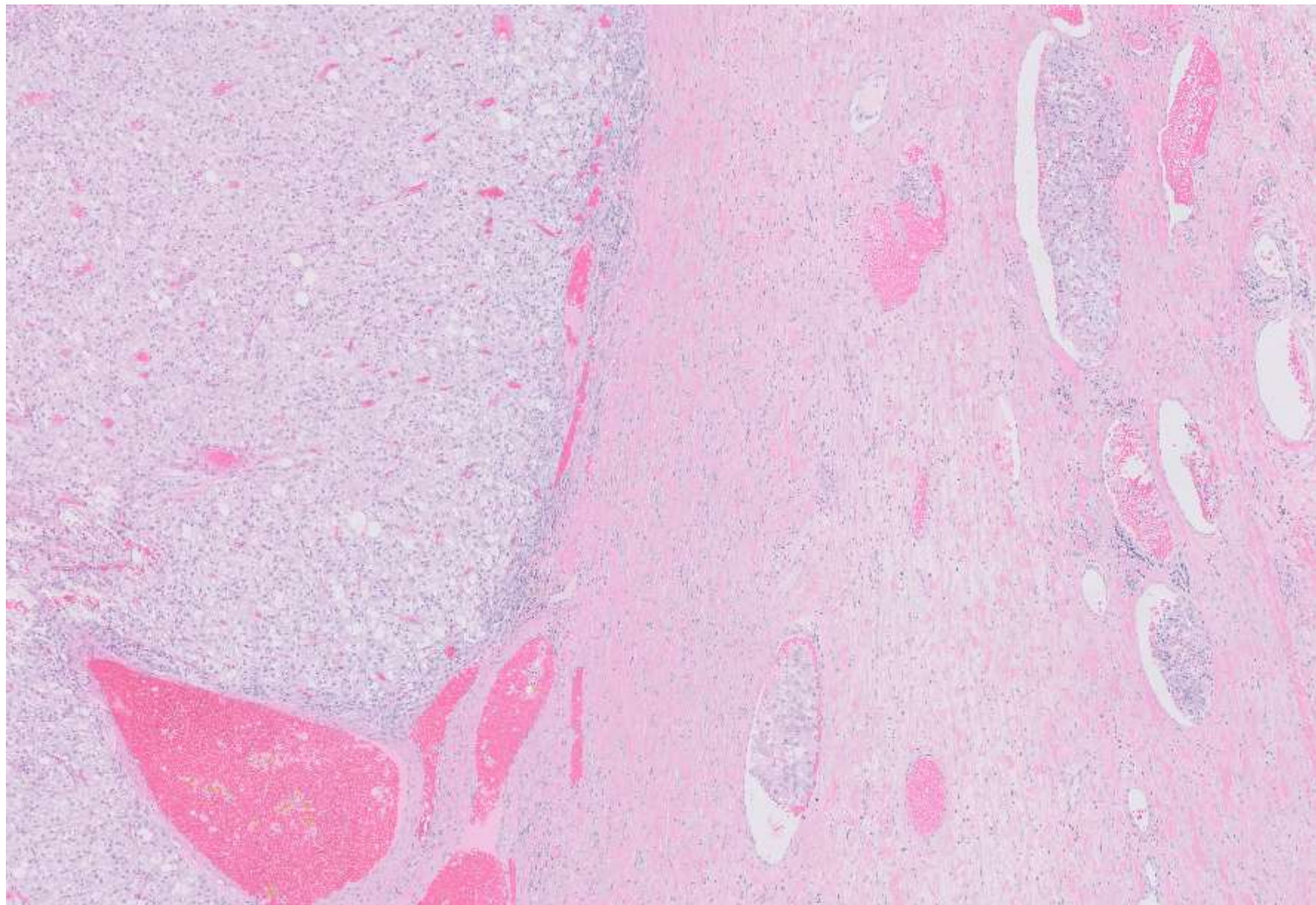
23-0402

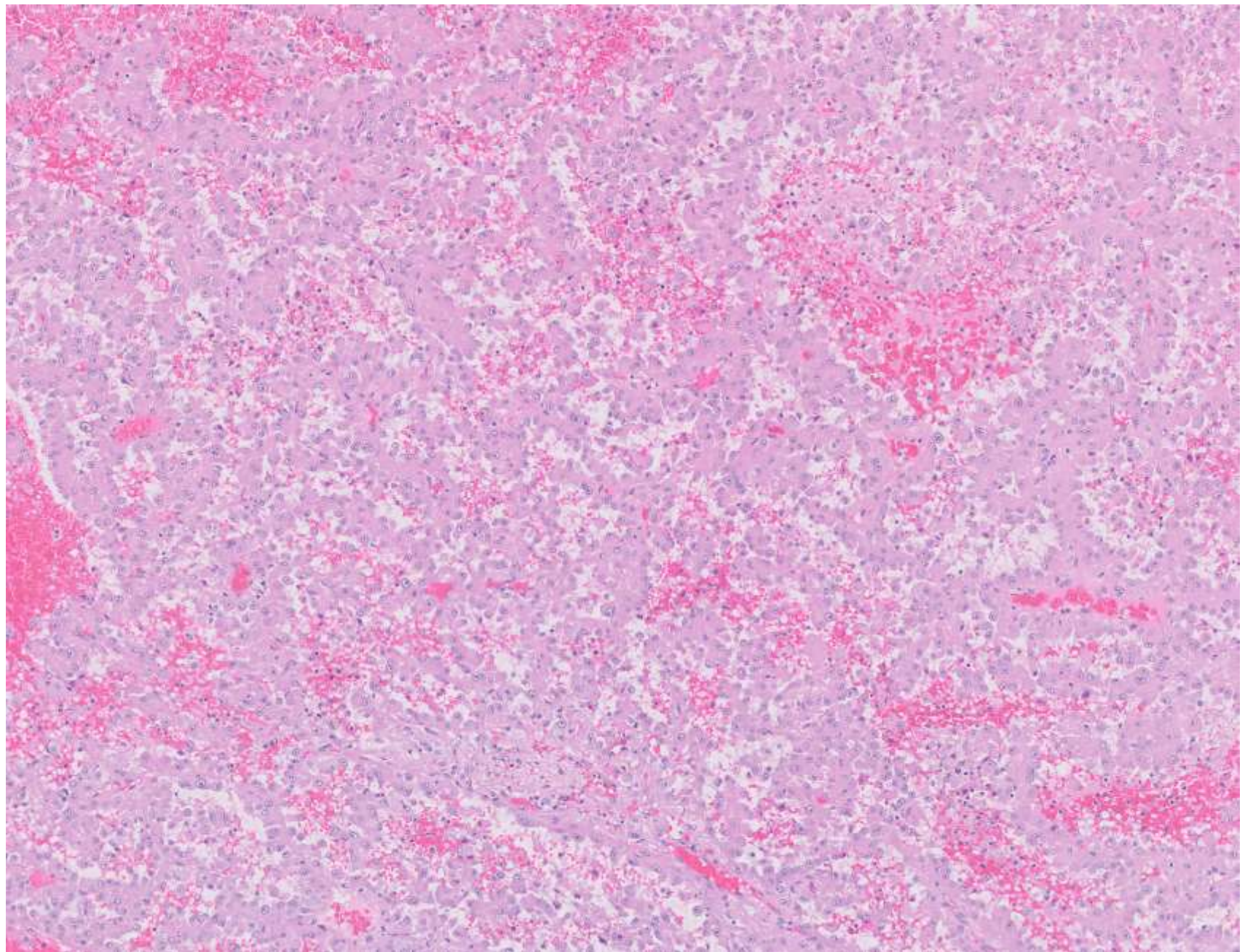
Andrew Xiao/Emily Chan; UCSF

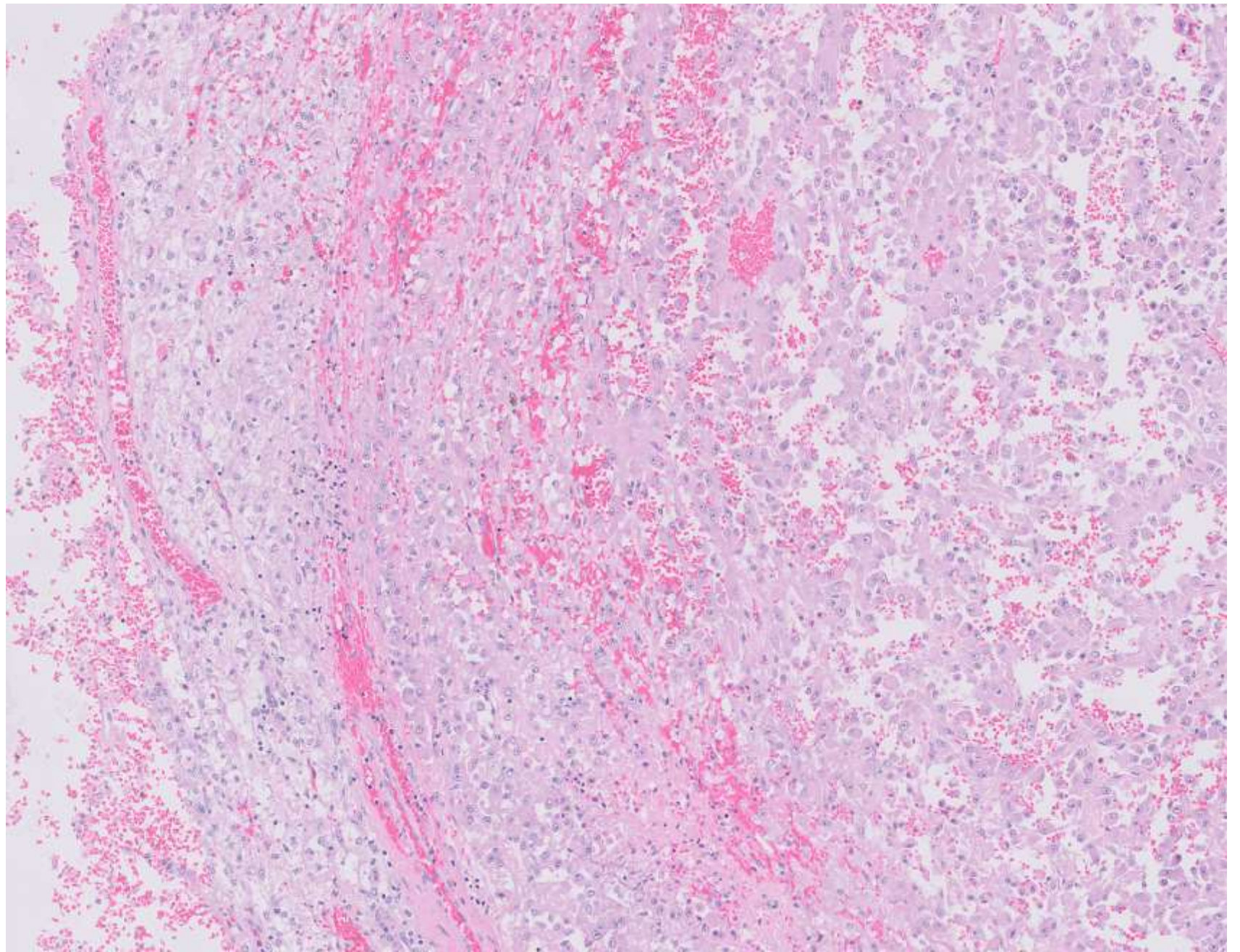
50ish F with 12.5cm left inferior pole renal mass.

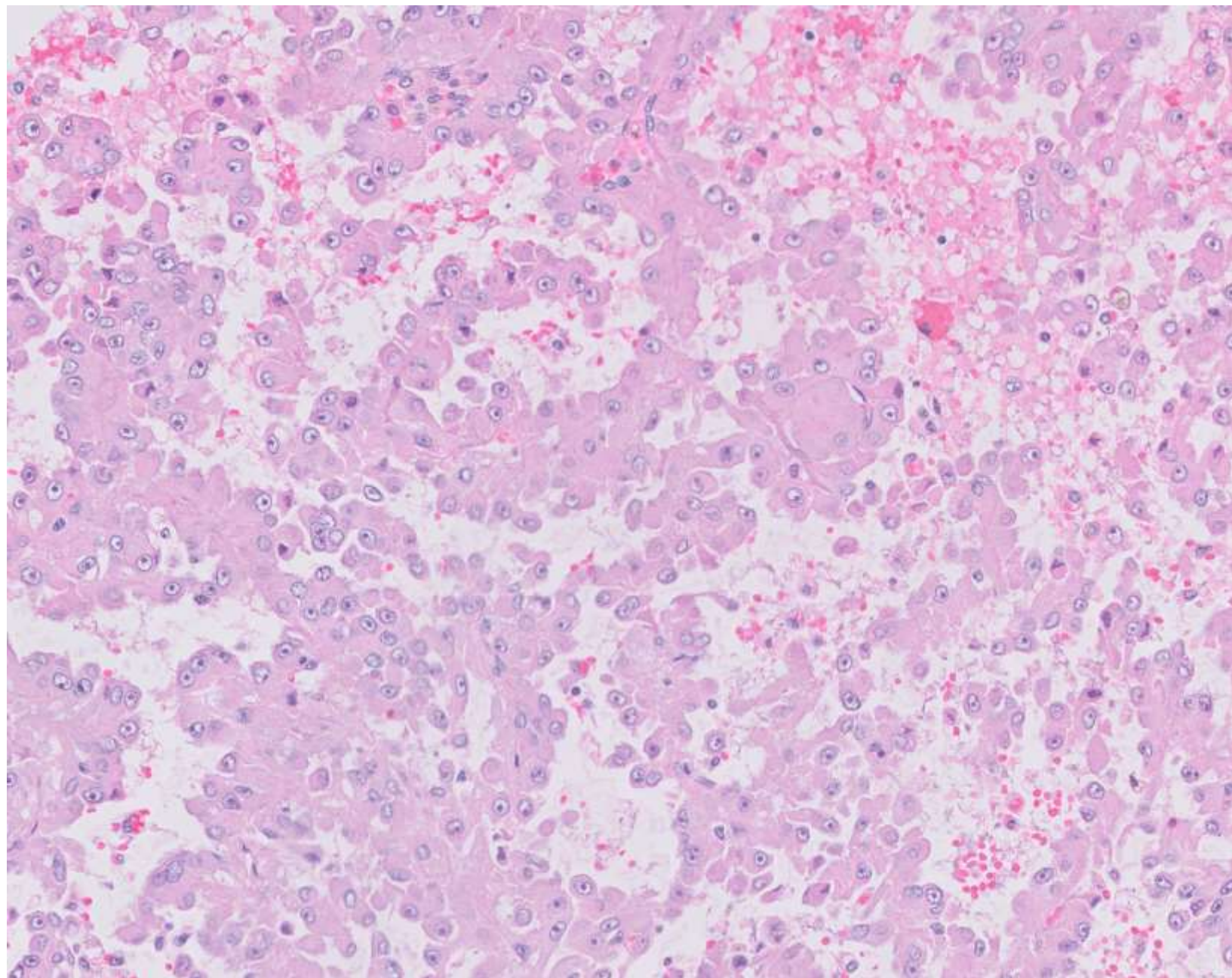


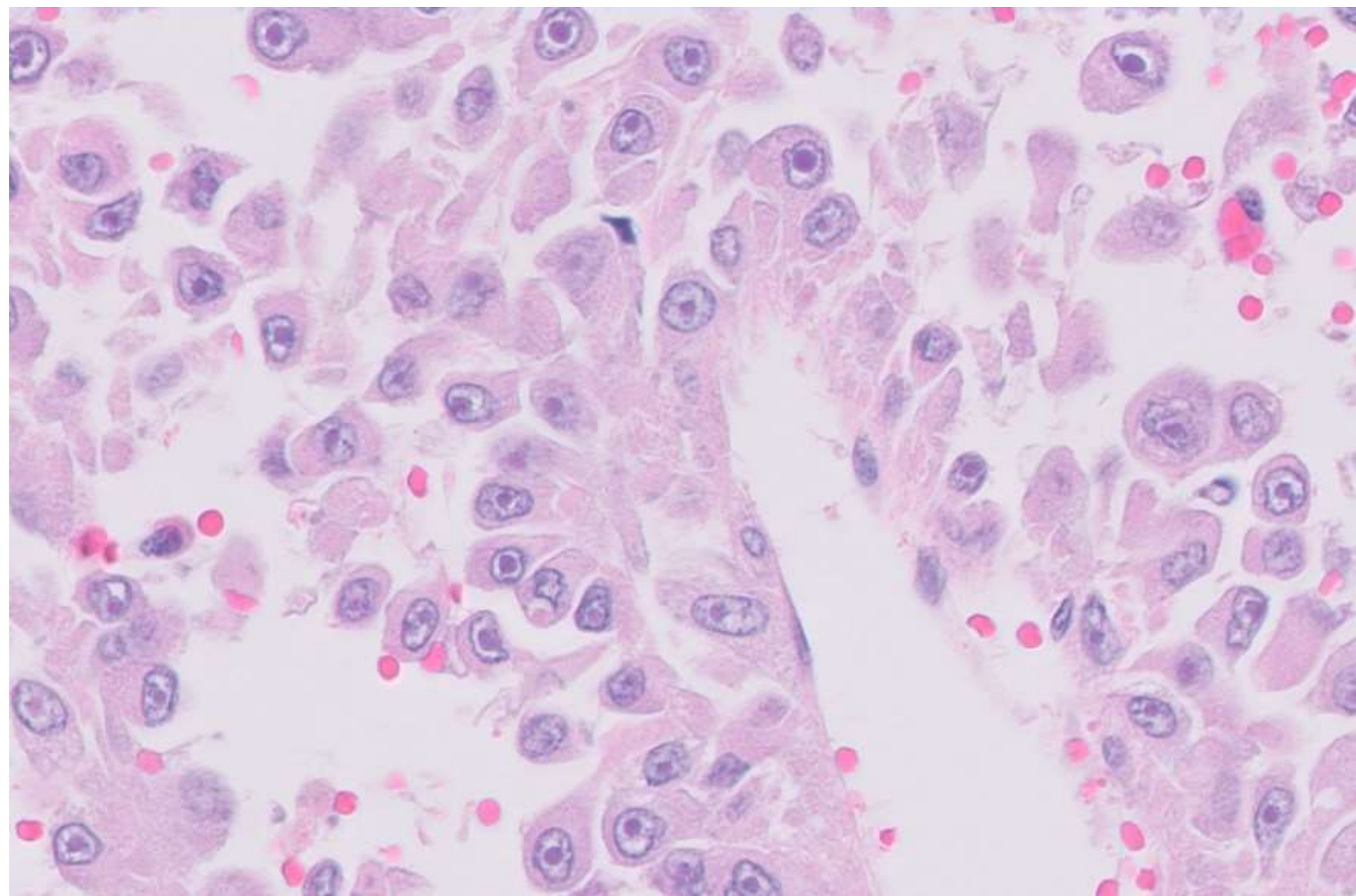


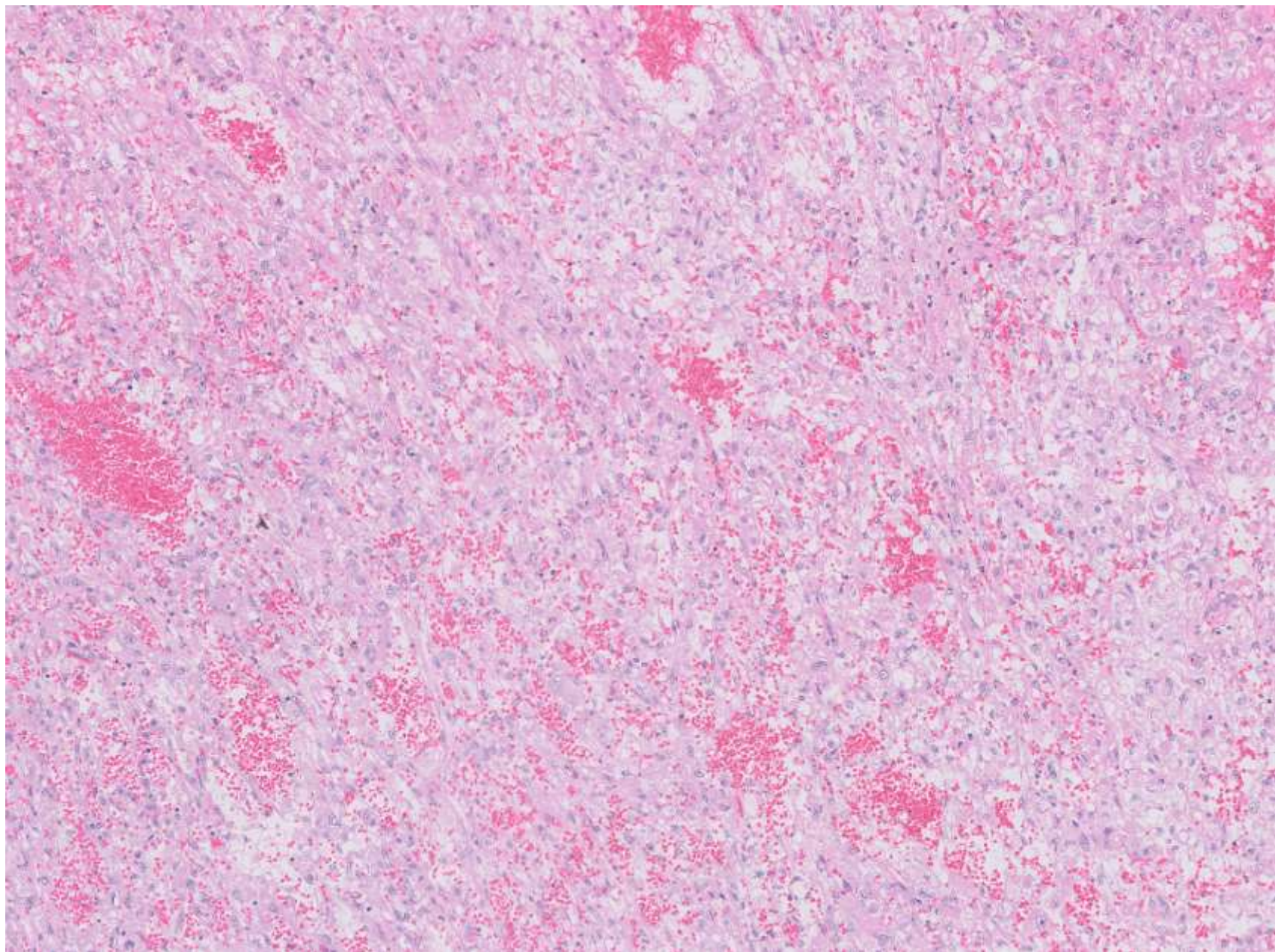


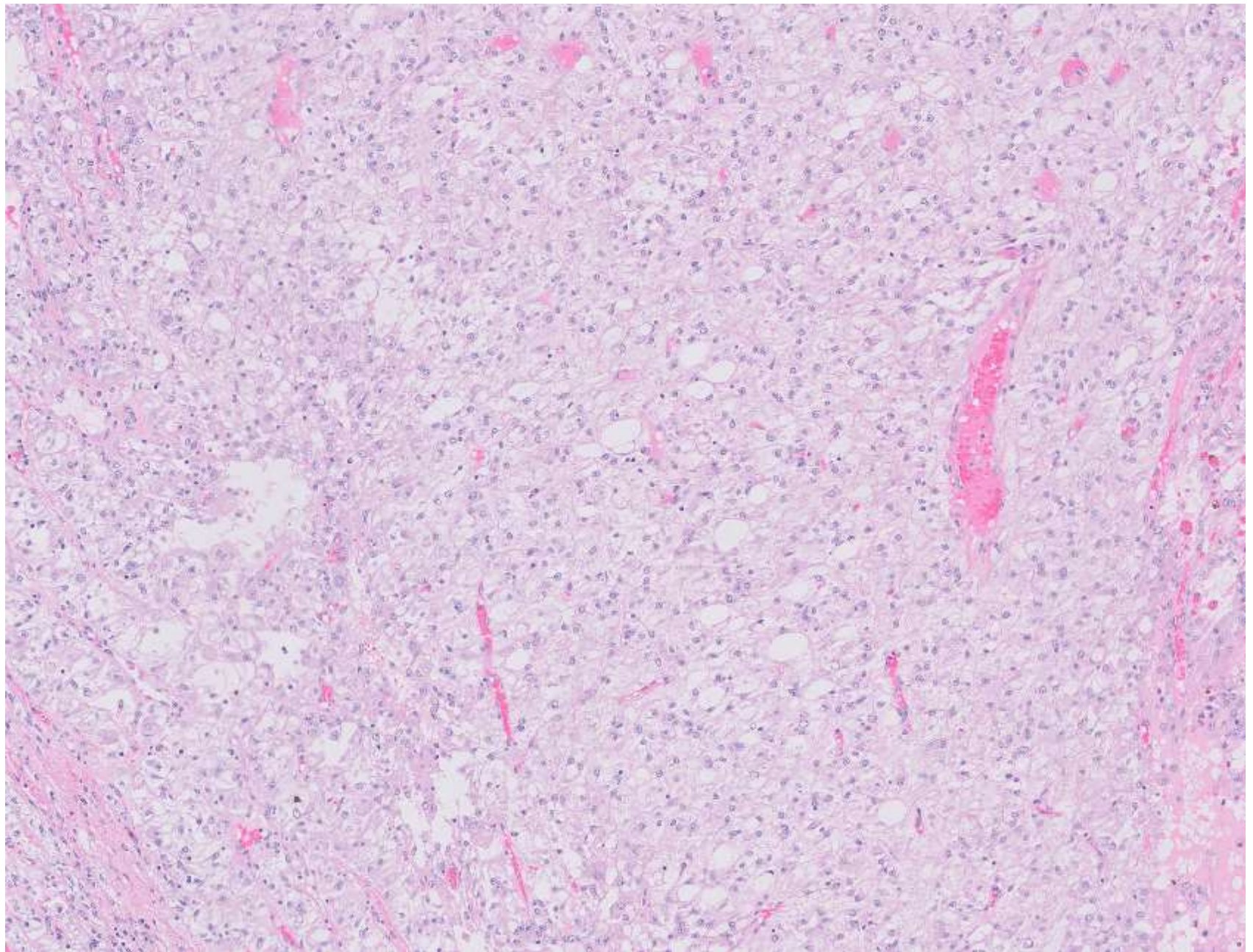


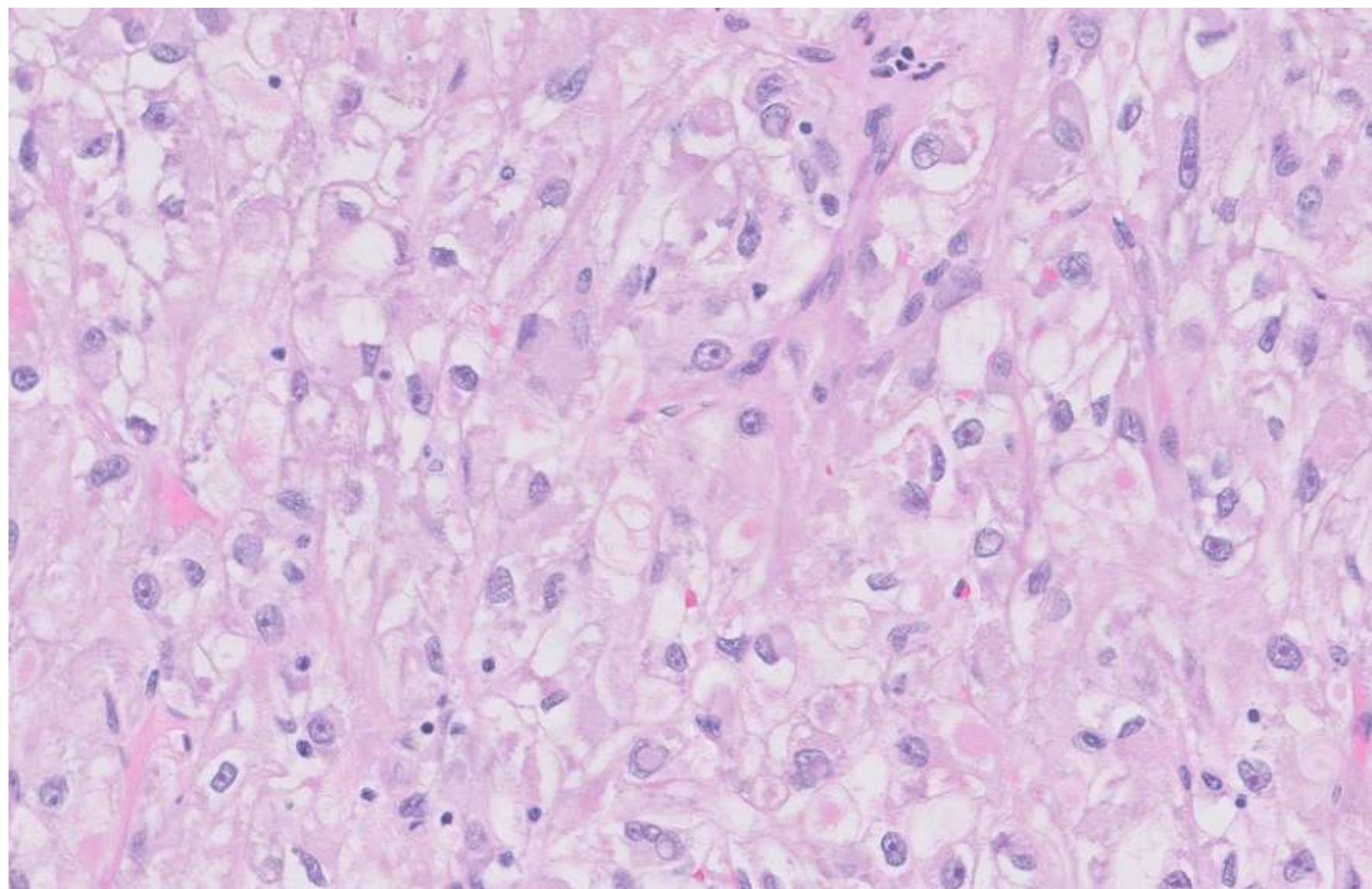












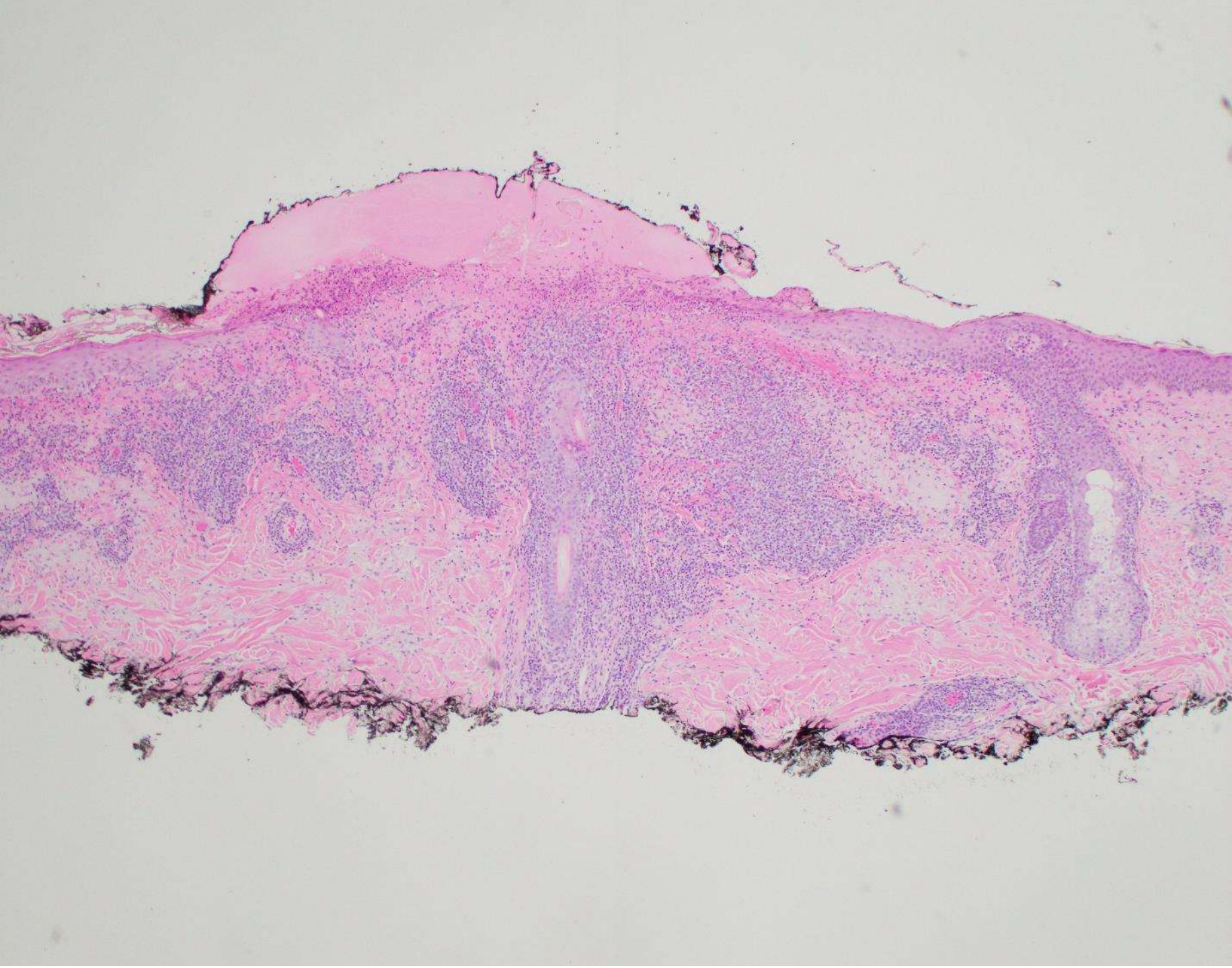
DIAGNOSIS?

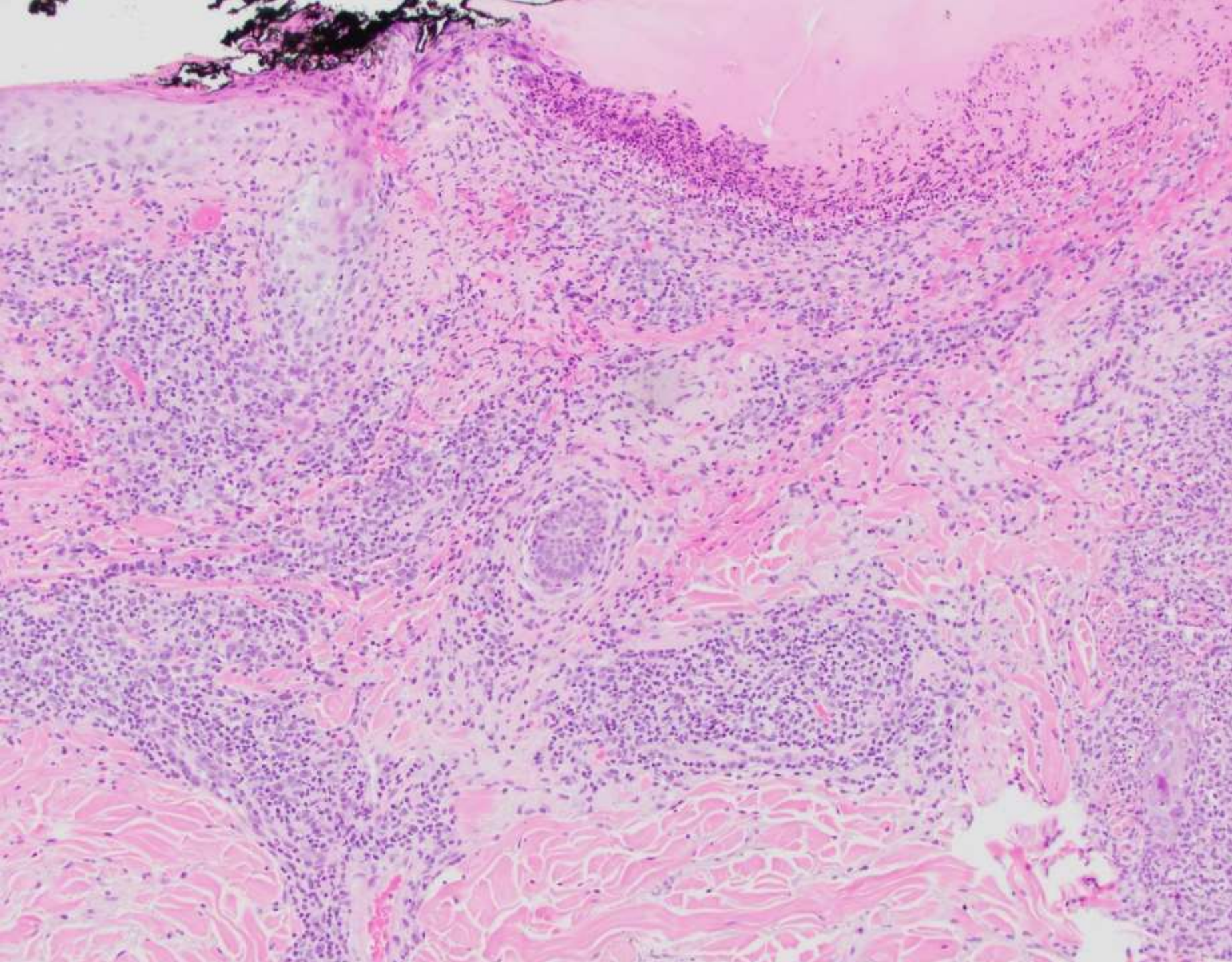


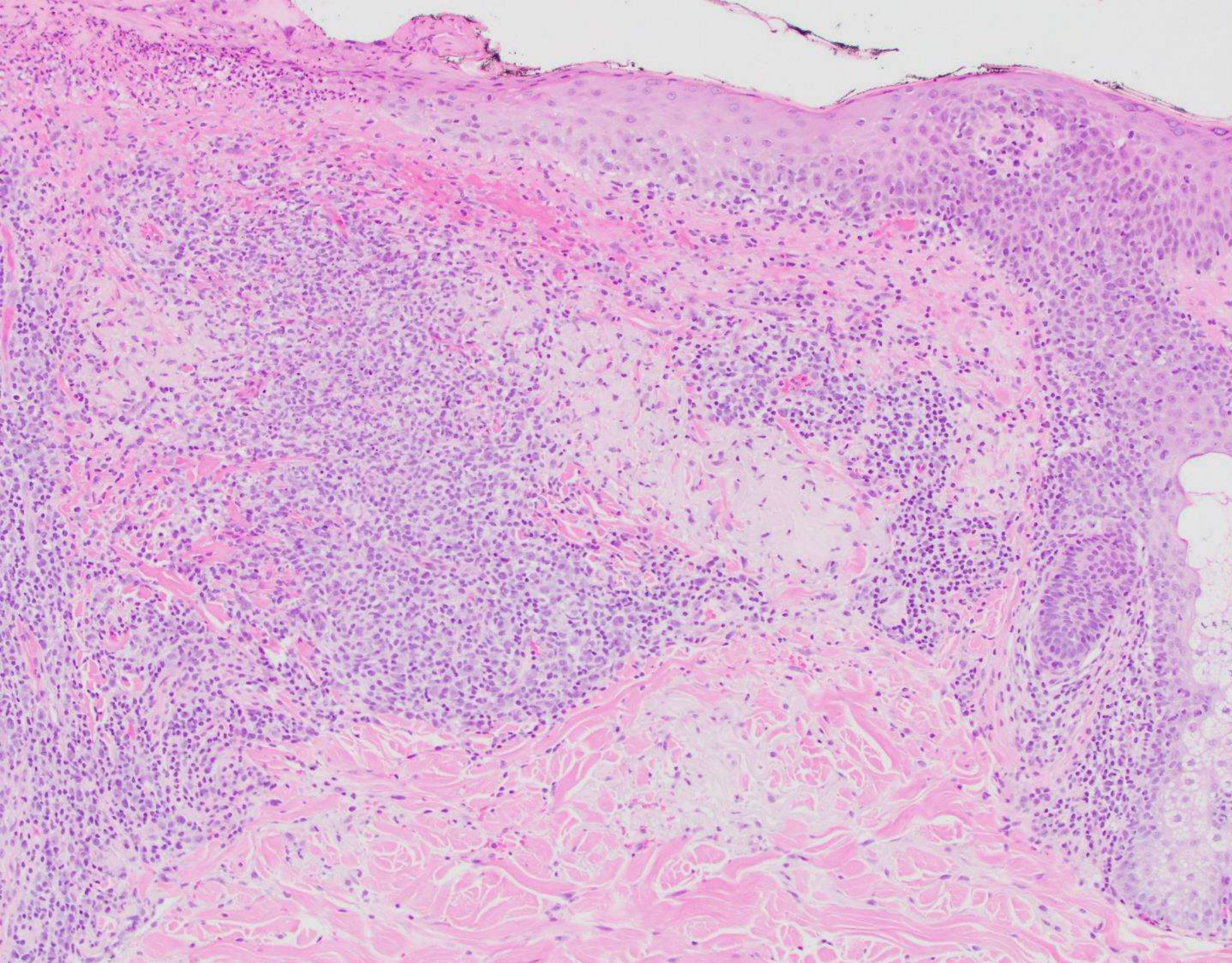
23-0403

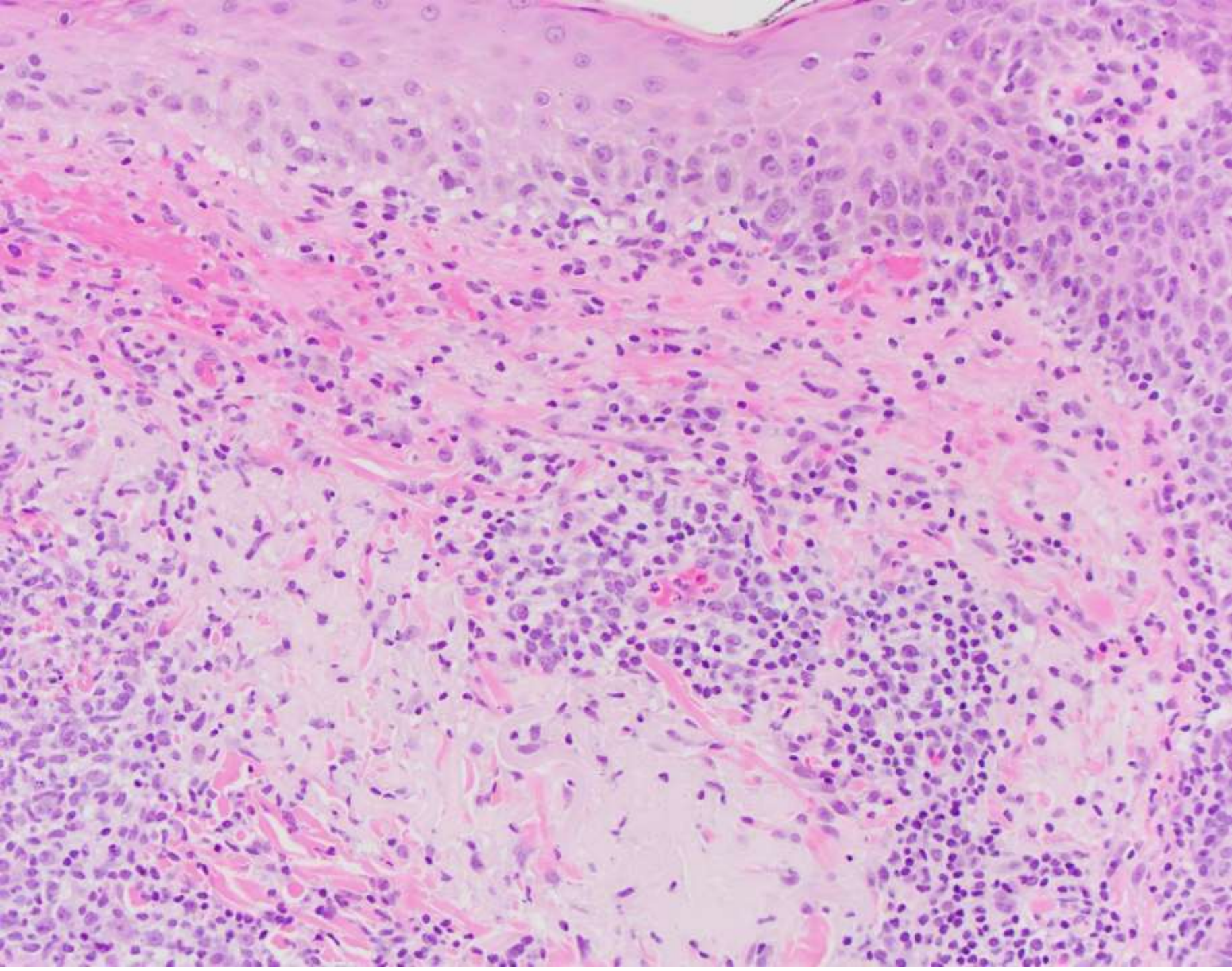
Hubert Lau; VA Palo Alto

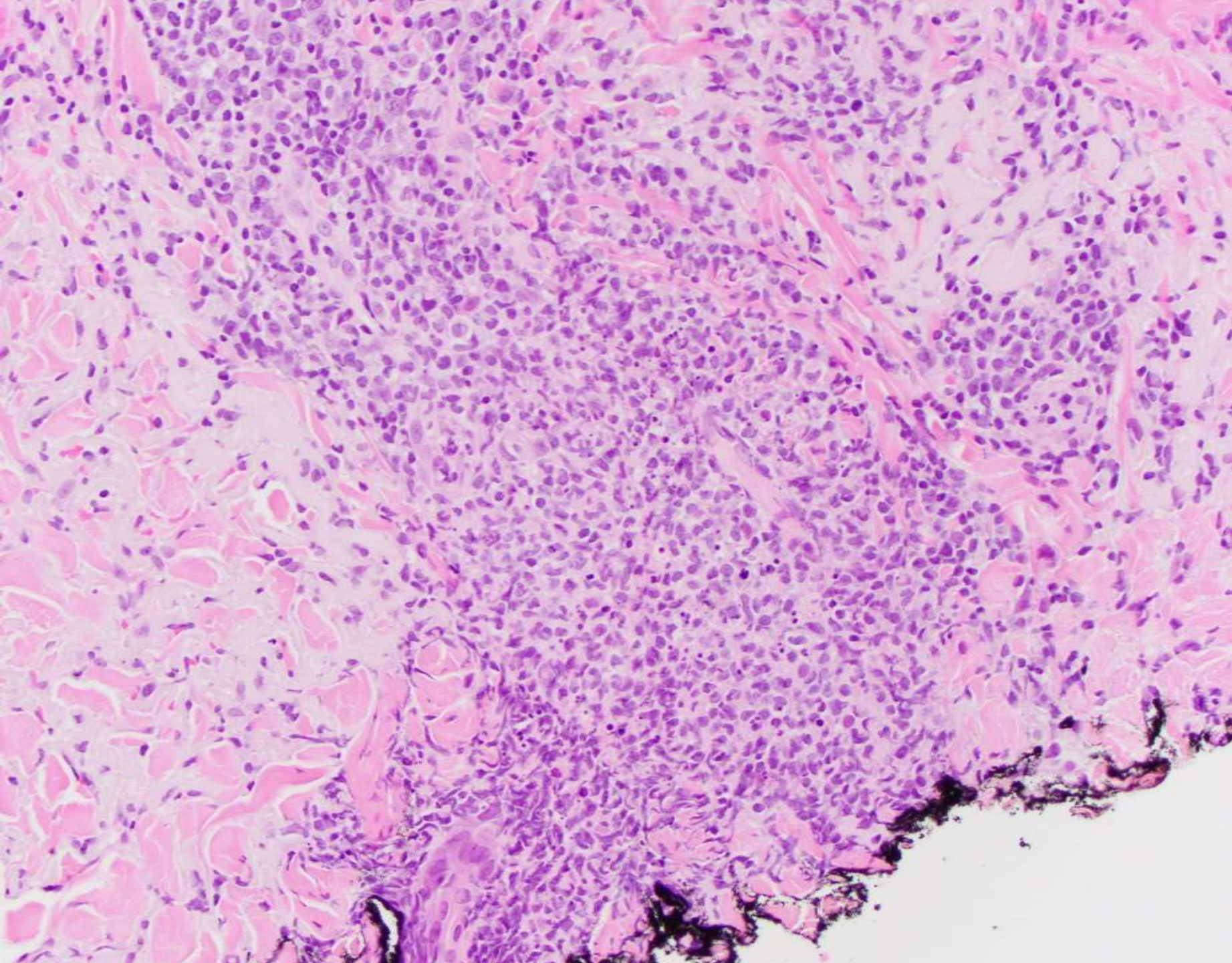
80ish M with h/o melanoma and several non-melanoma skin cancers presents with 3cm pink plaque with overlying scale and hemorrhagic crust in postauricular area for 2-3 months. The lesion is tender and growing. Clinical DDx: SCC, less likely AK, trauma.

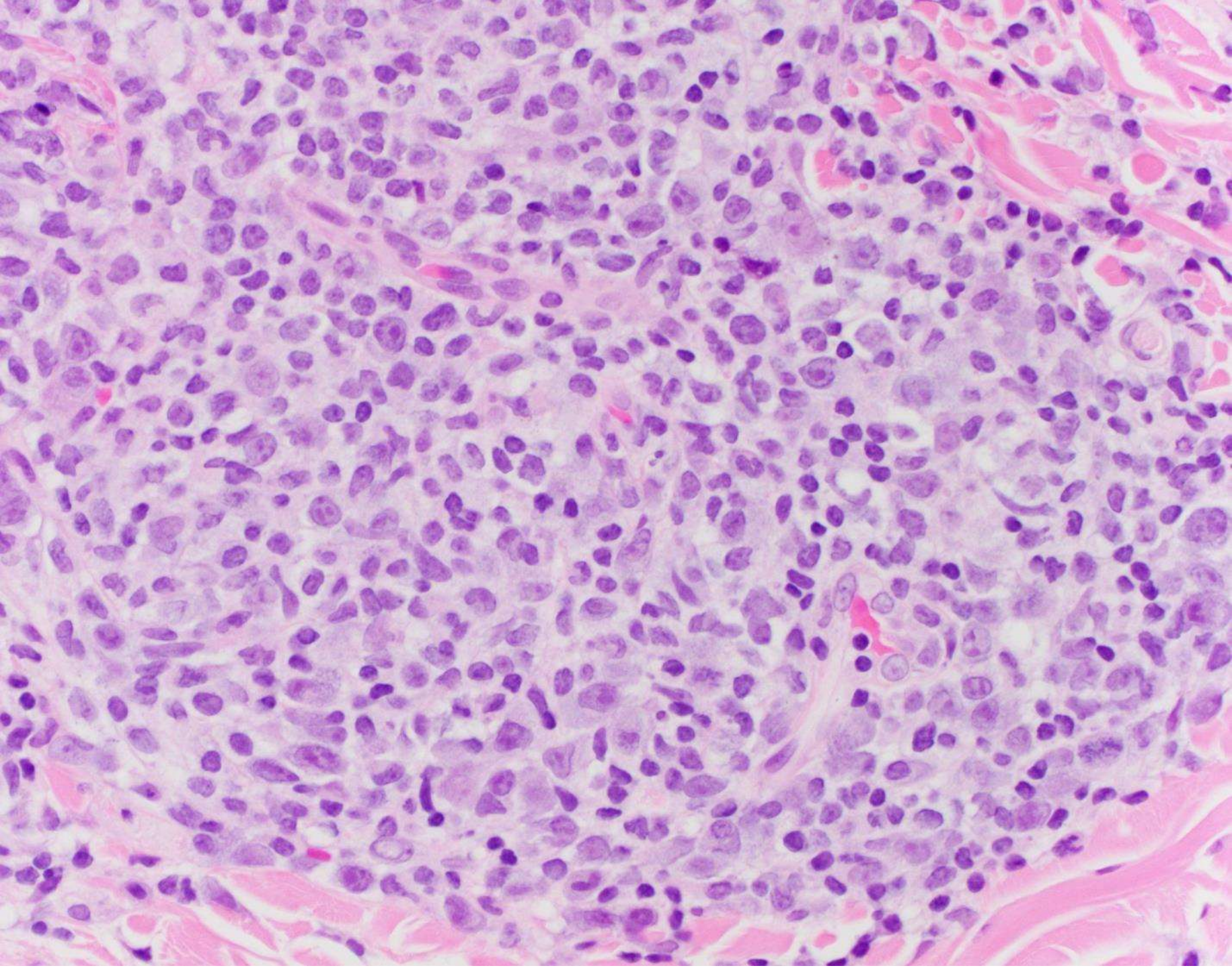




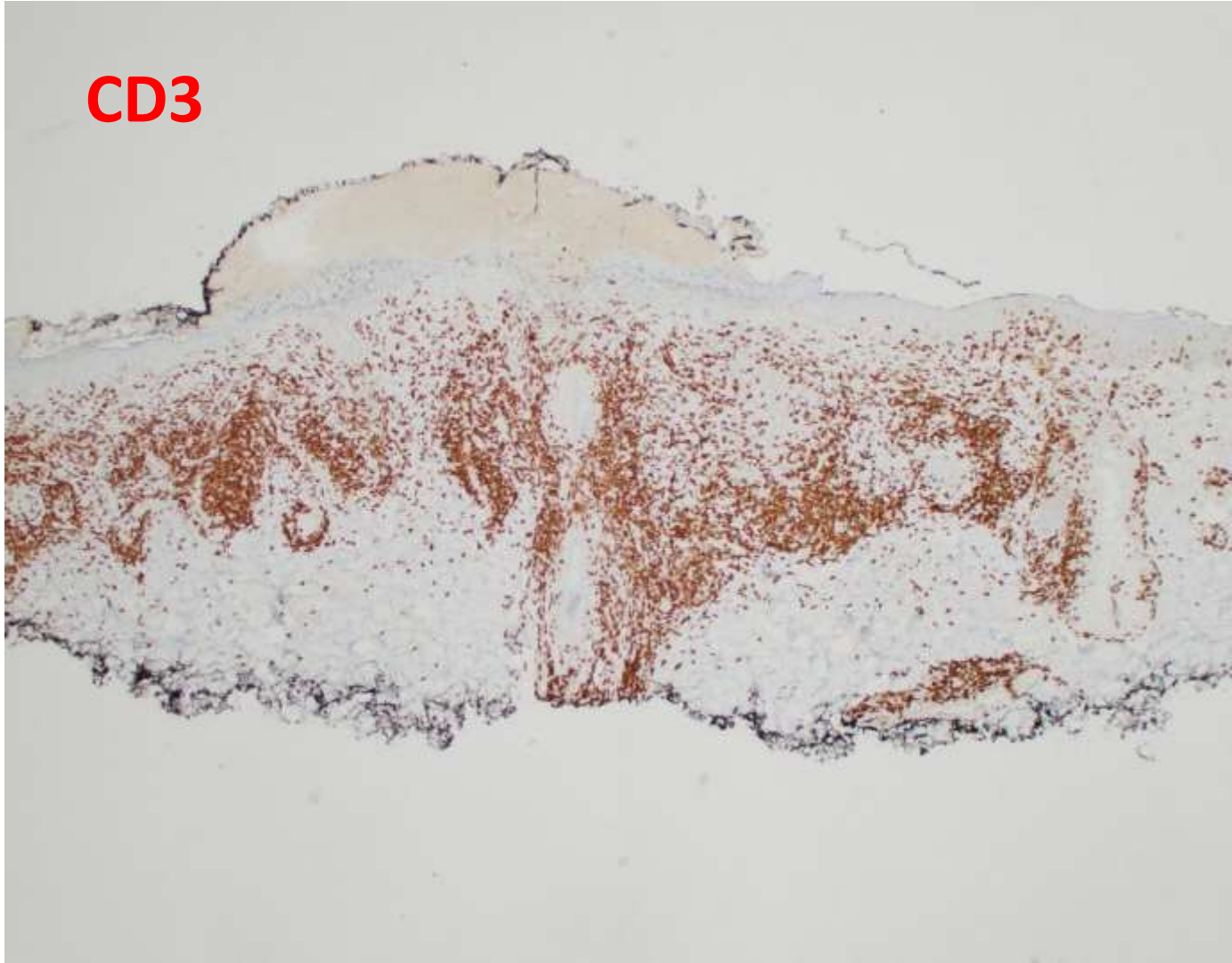

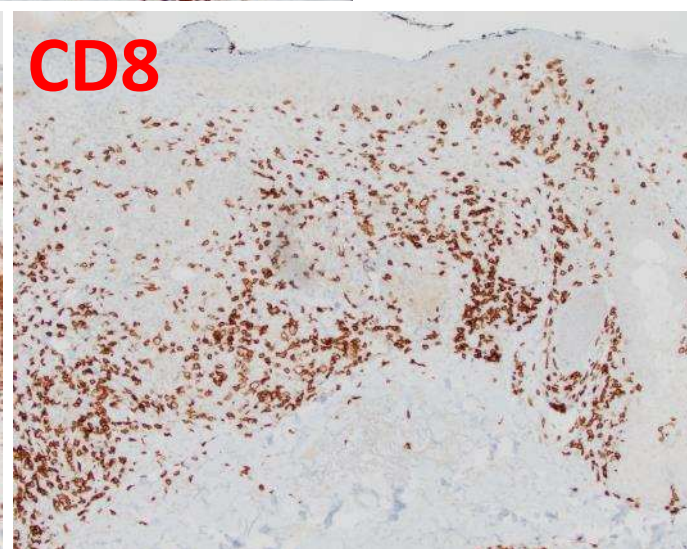
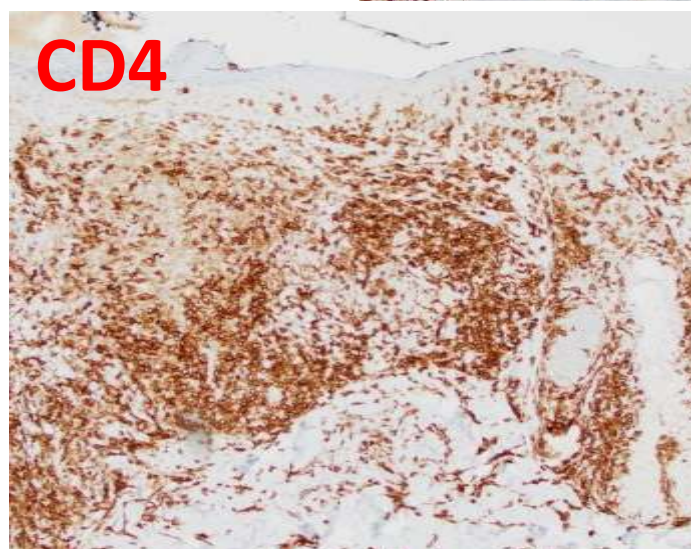
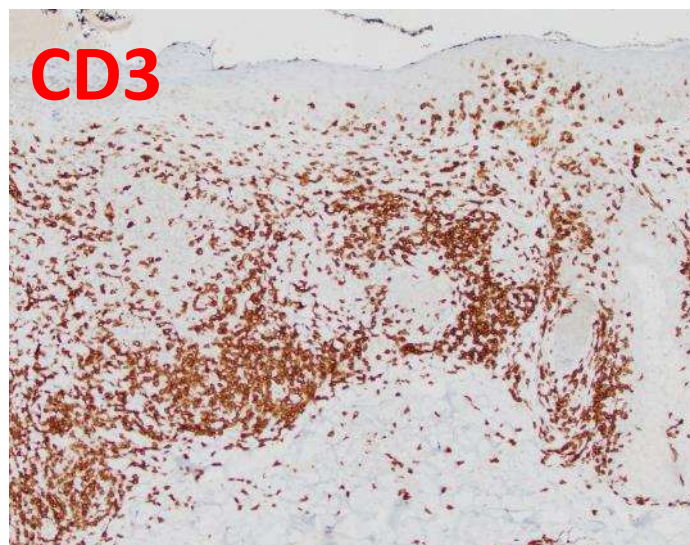




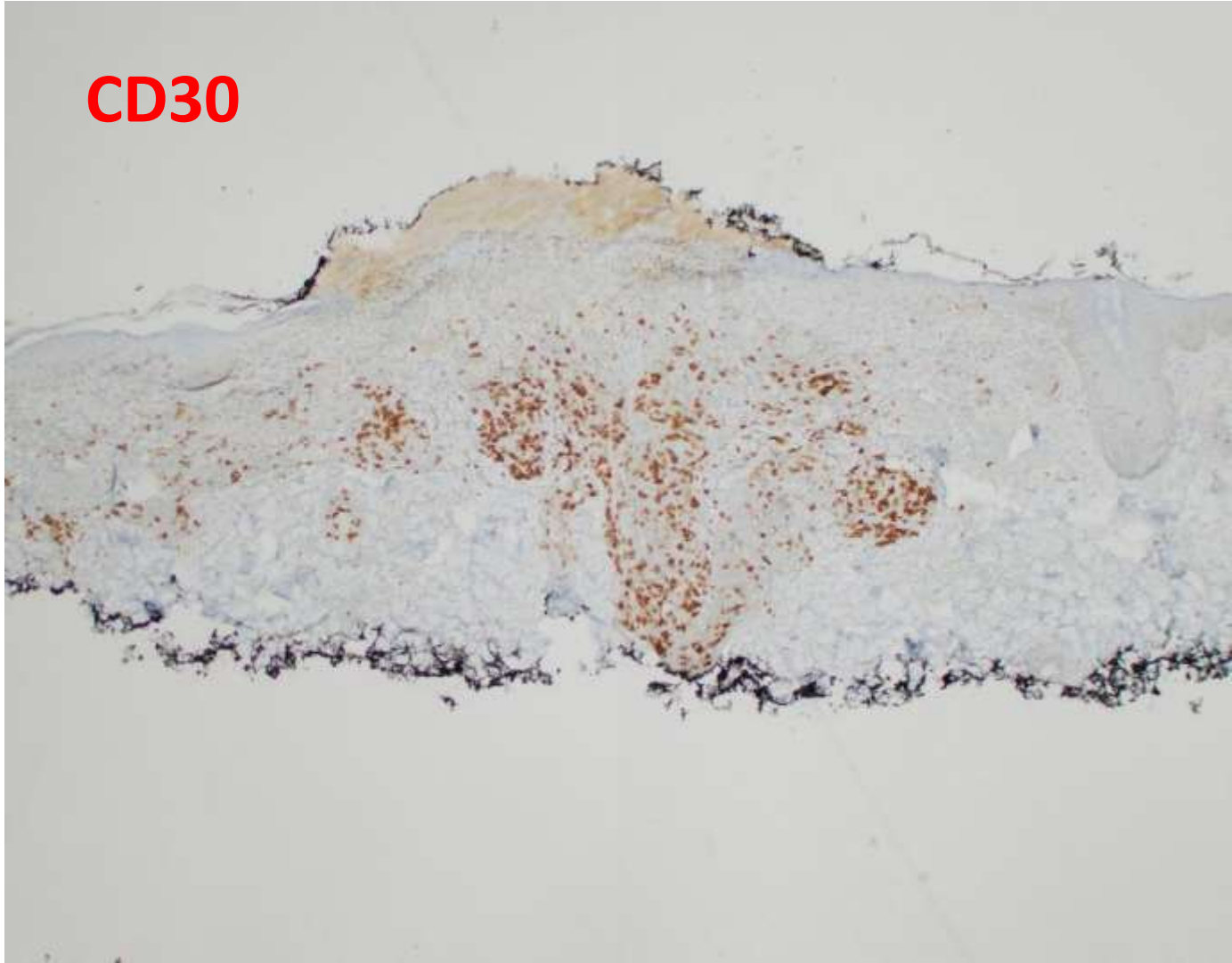


CD3

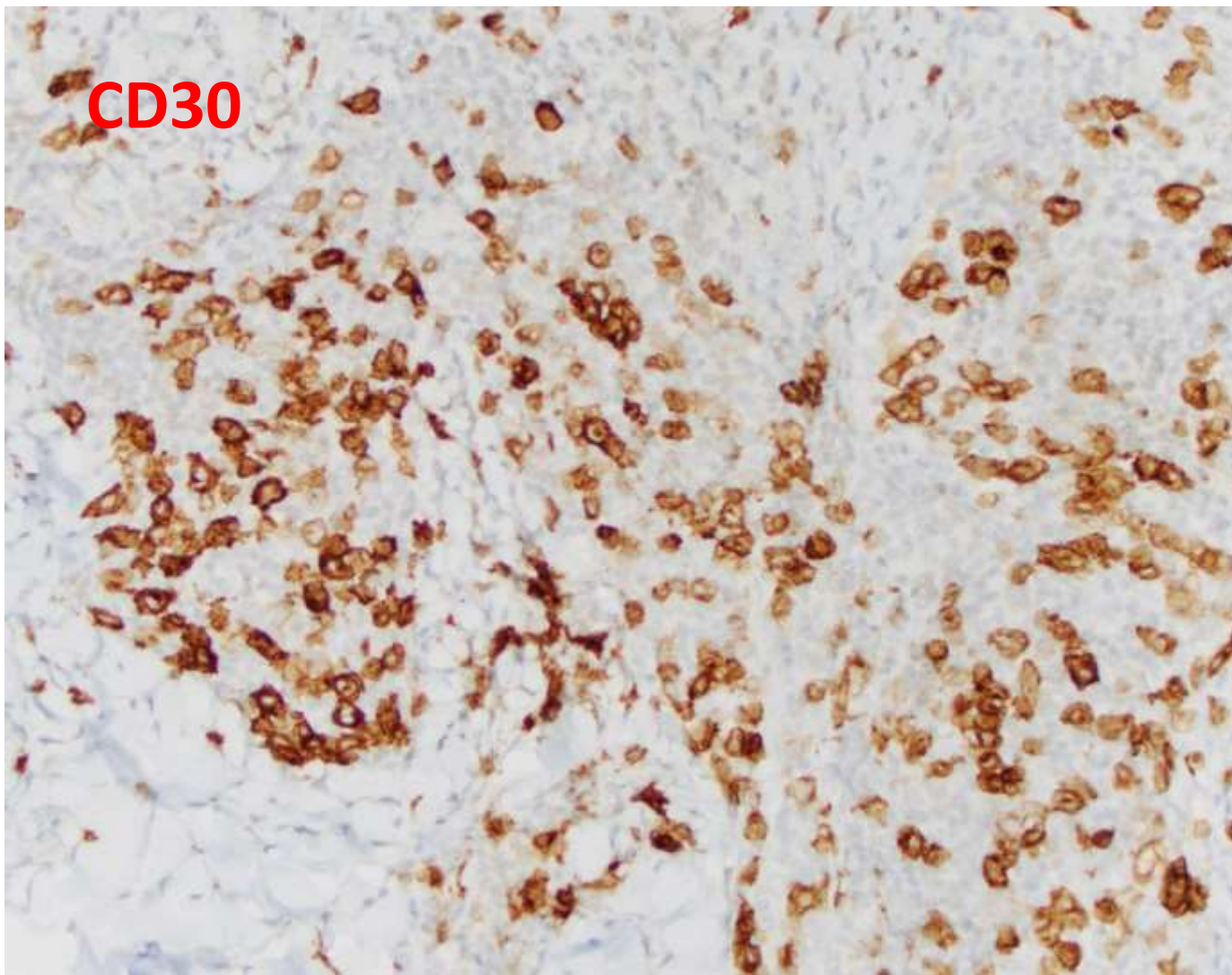




CD30



CD30



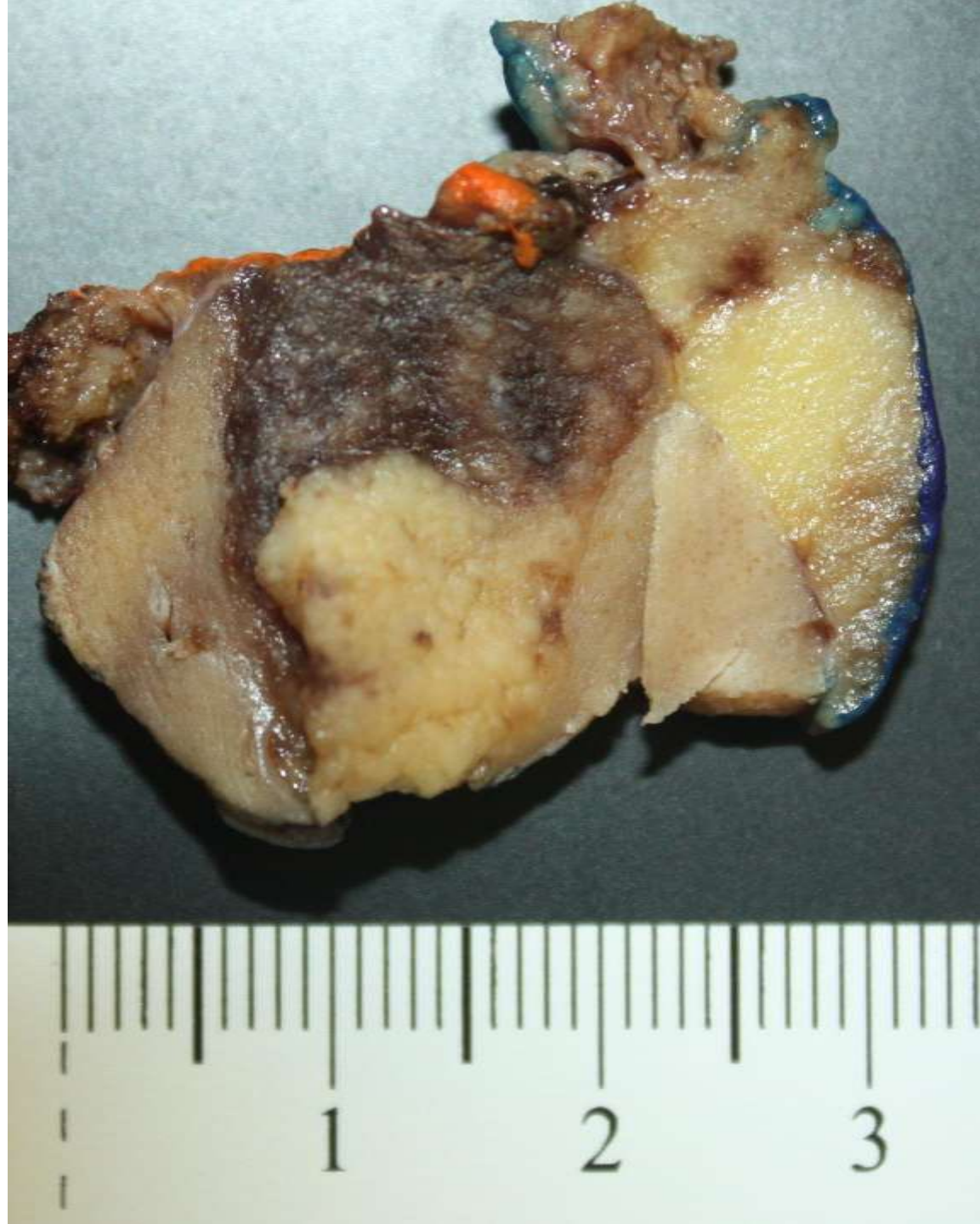DIAGNOSIS?

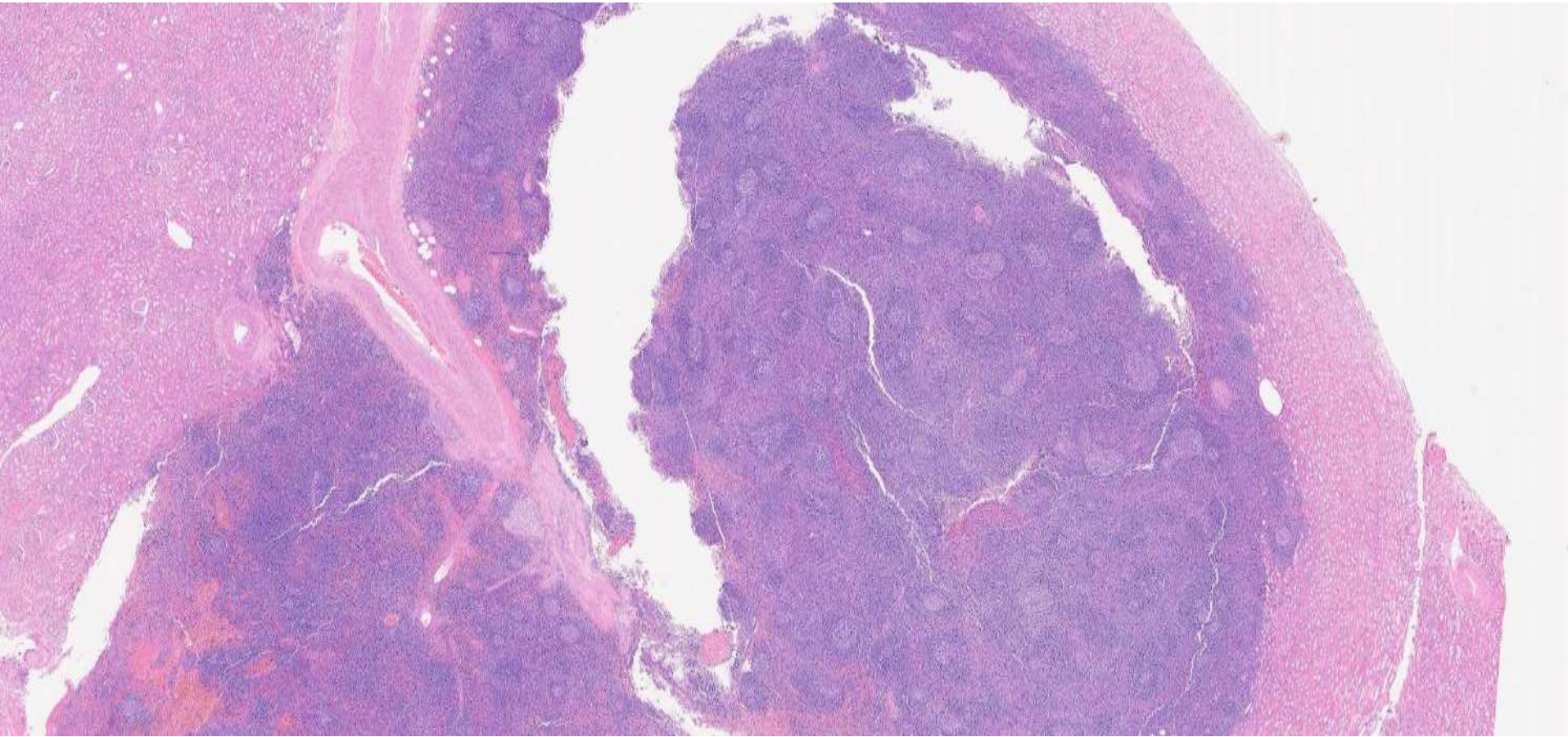


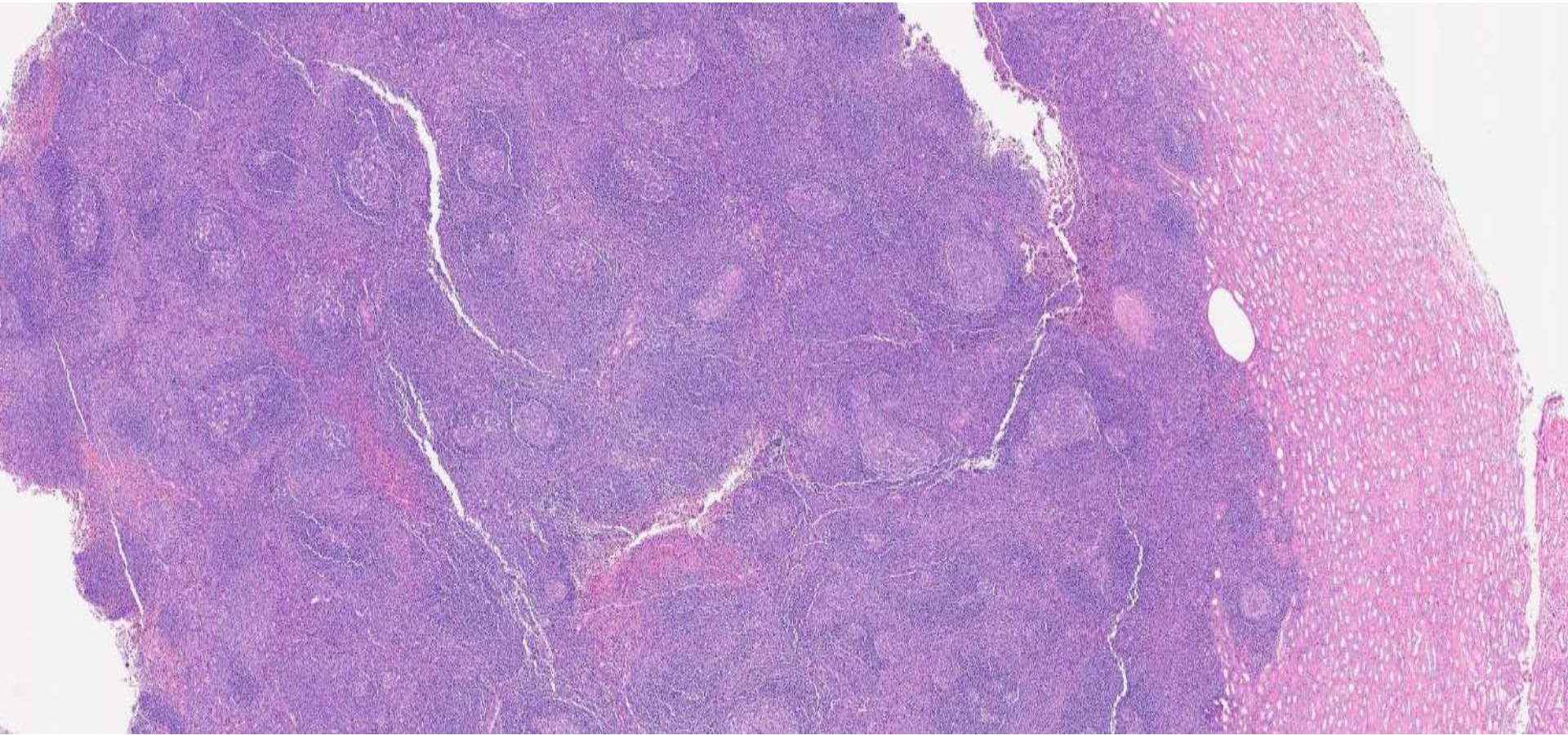
23-0404

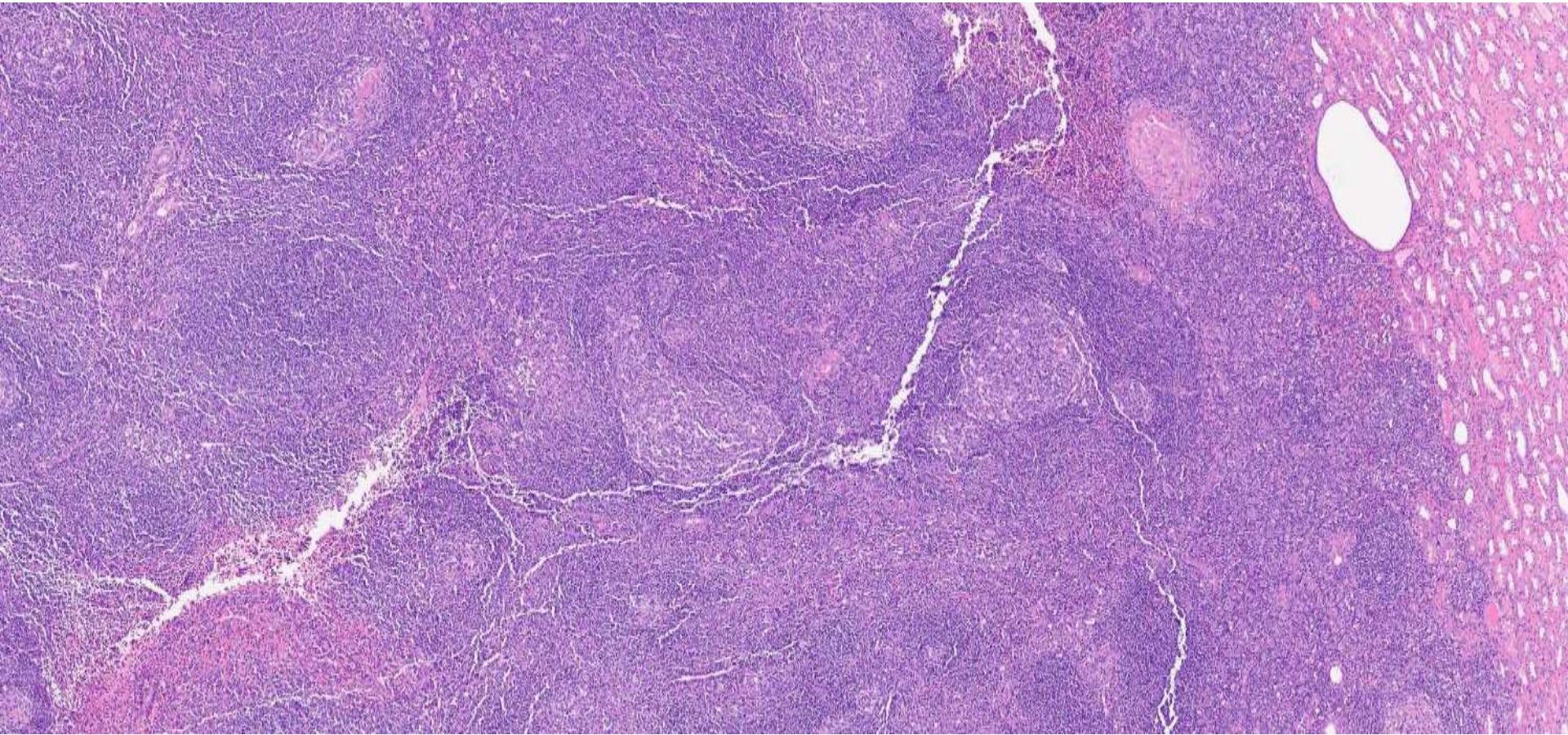
Lucas Massoth; El Camino Hospital

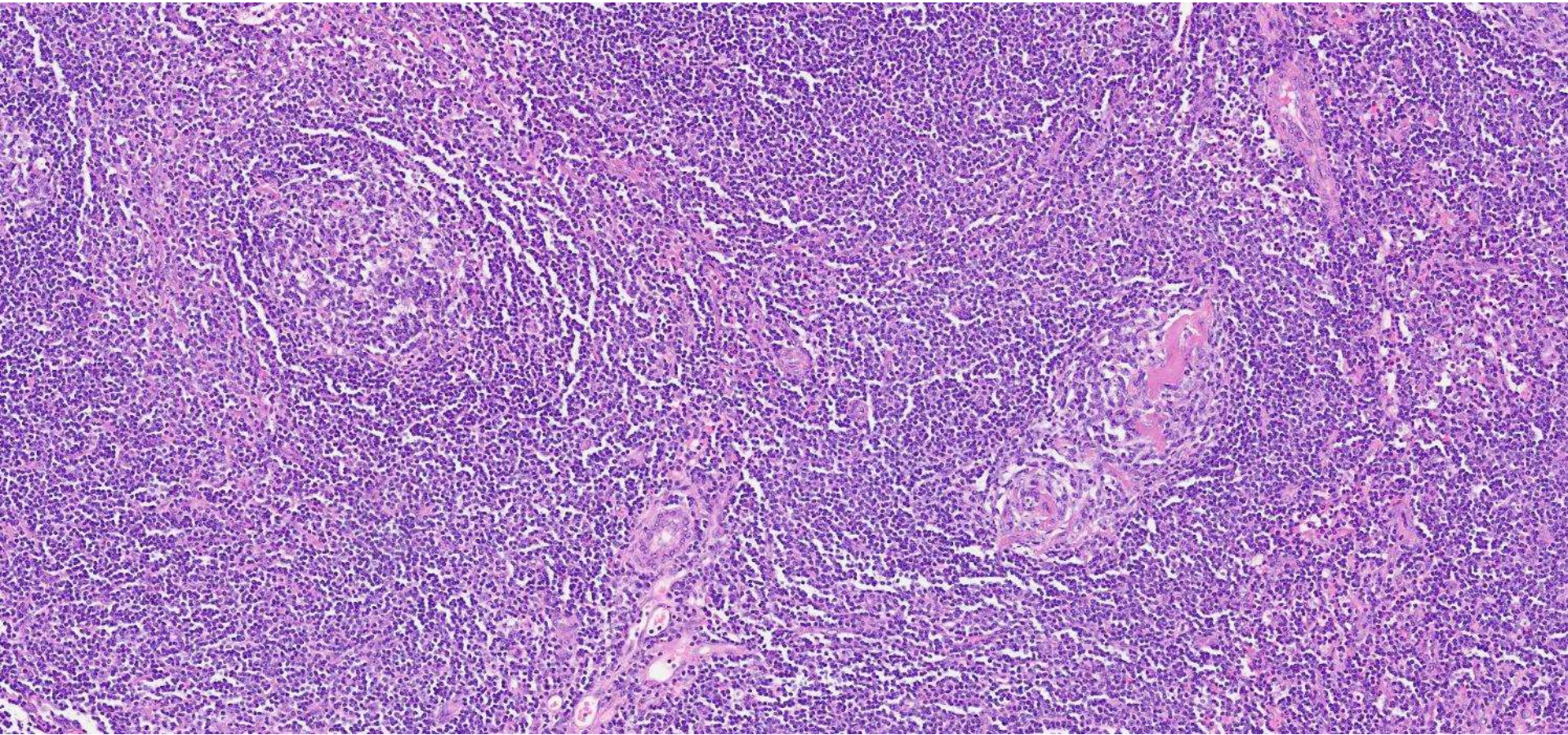
60ish M with 2cm renal mass, partial nephrectomy performed.

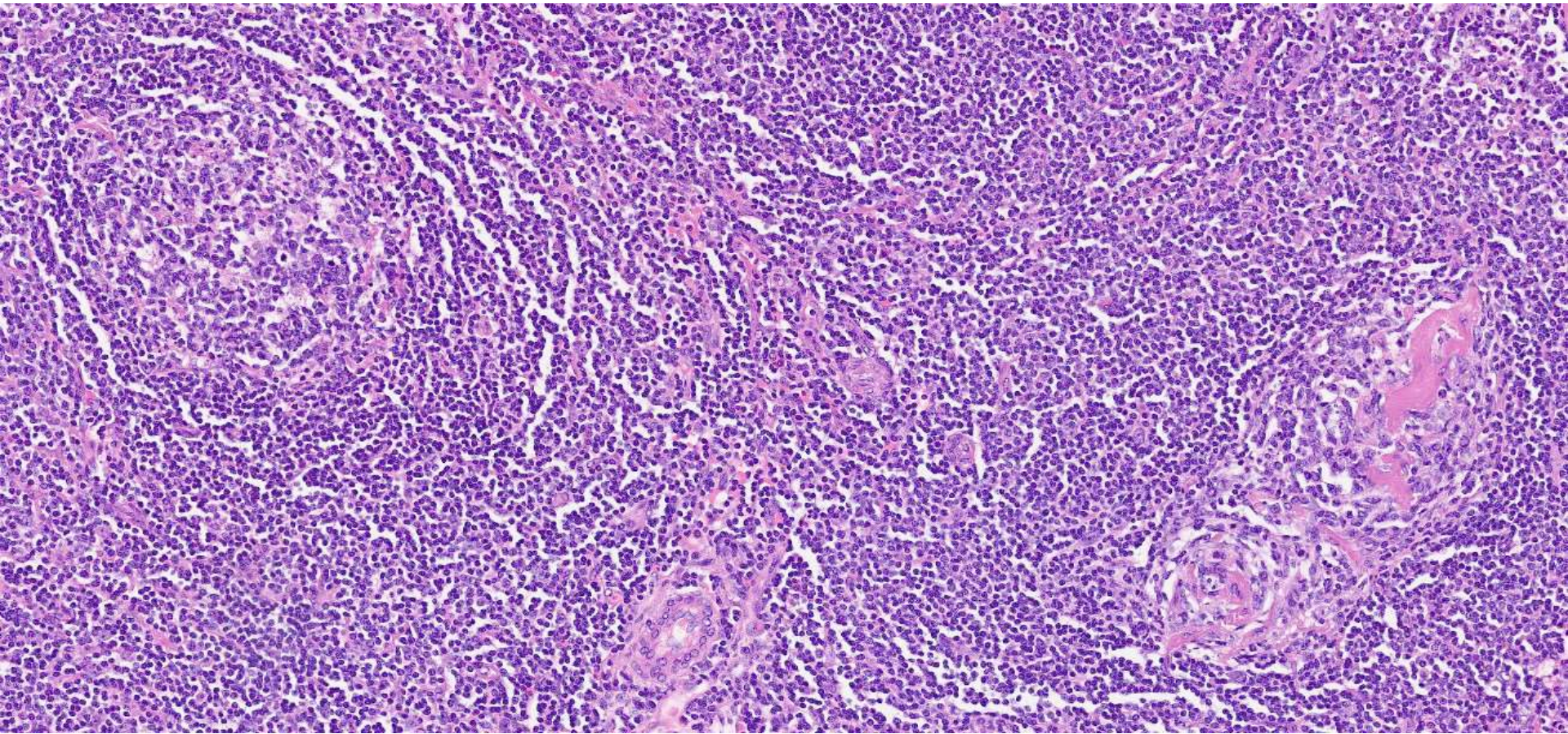


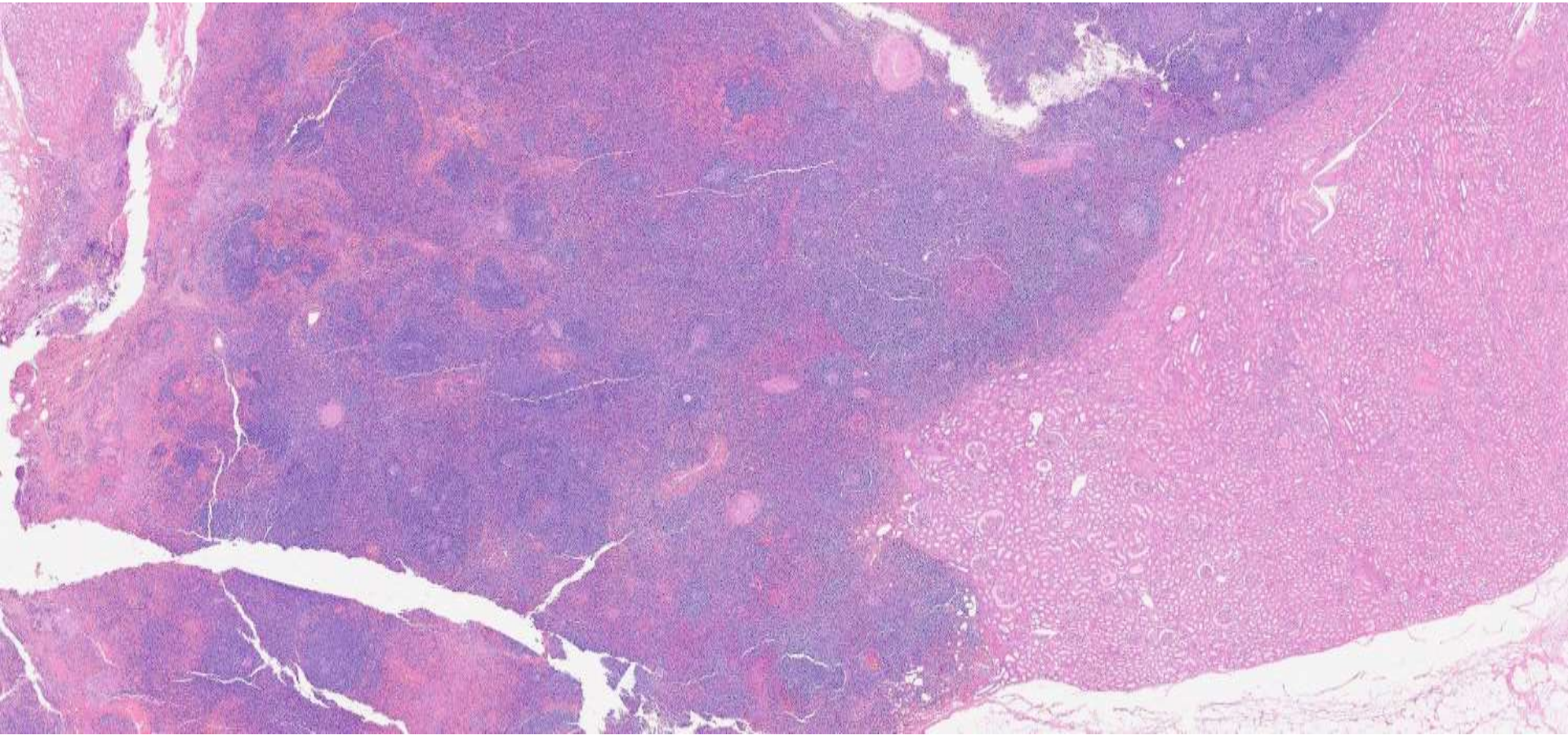


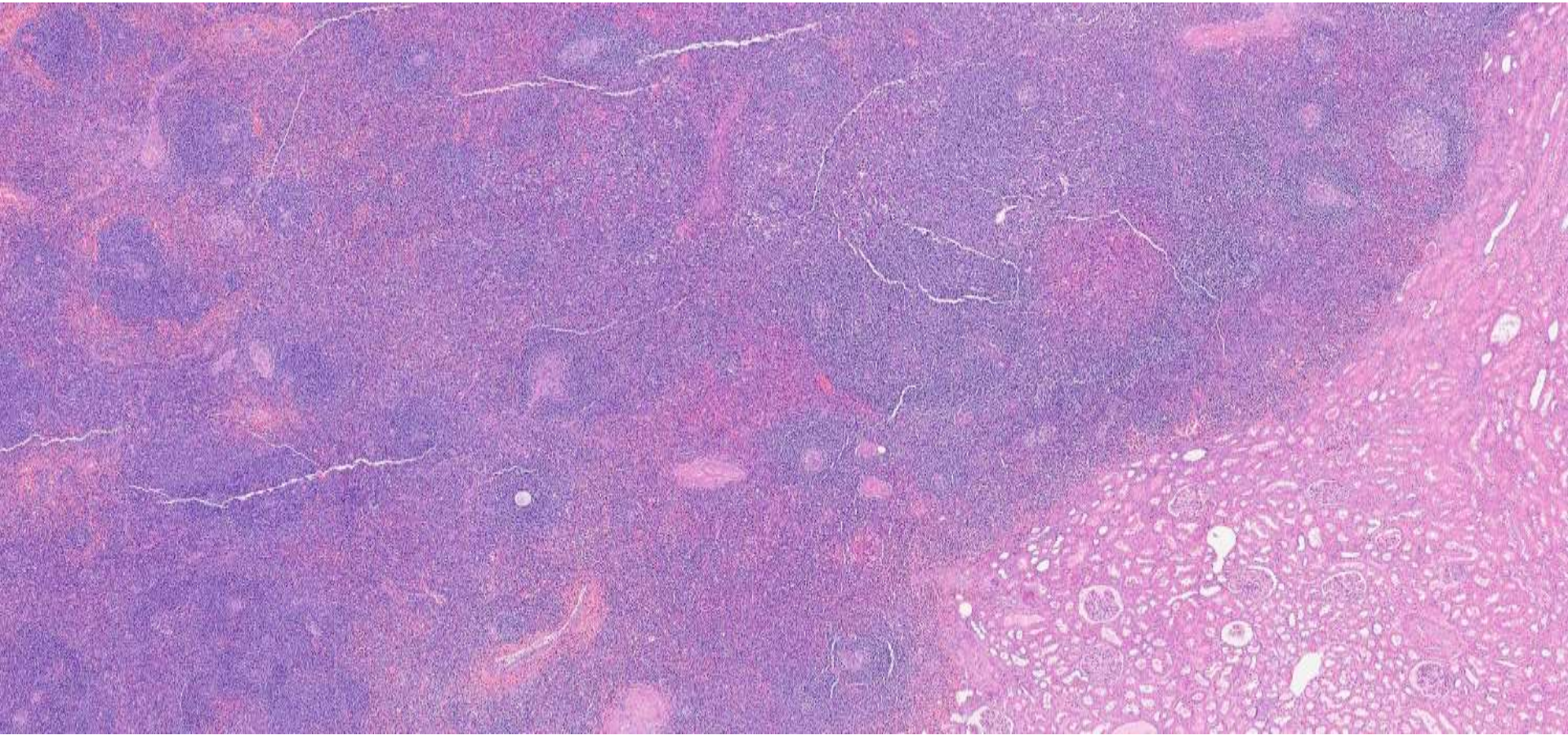


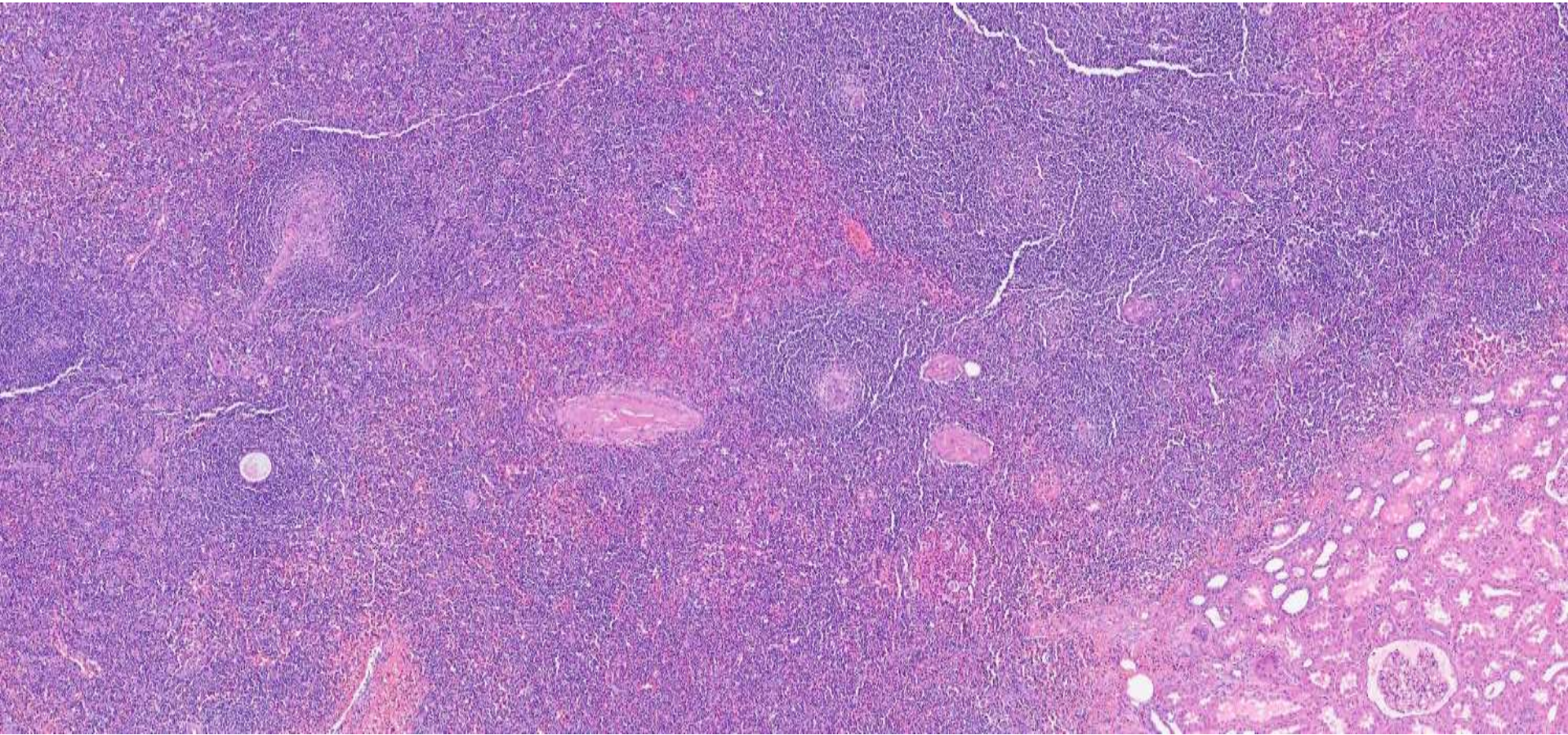


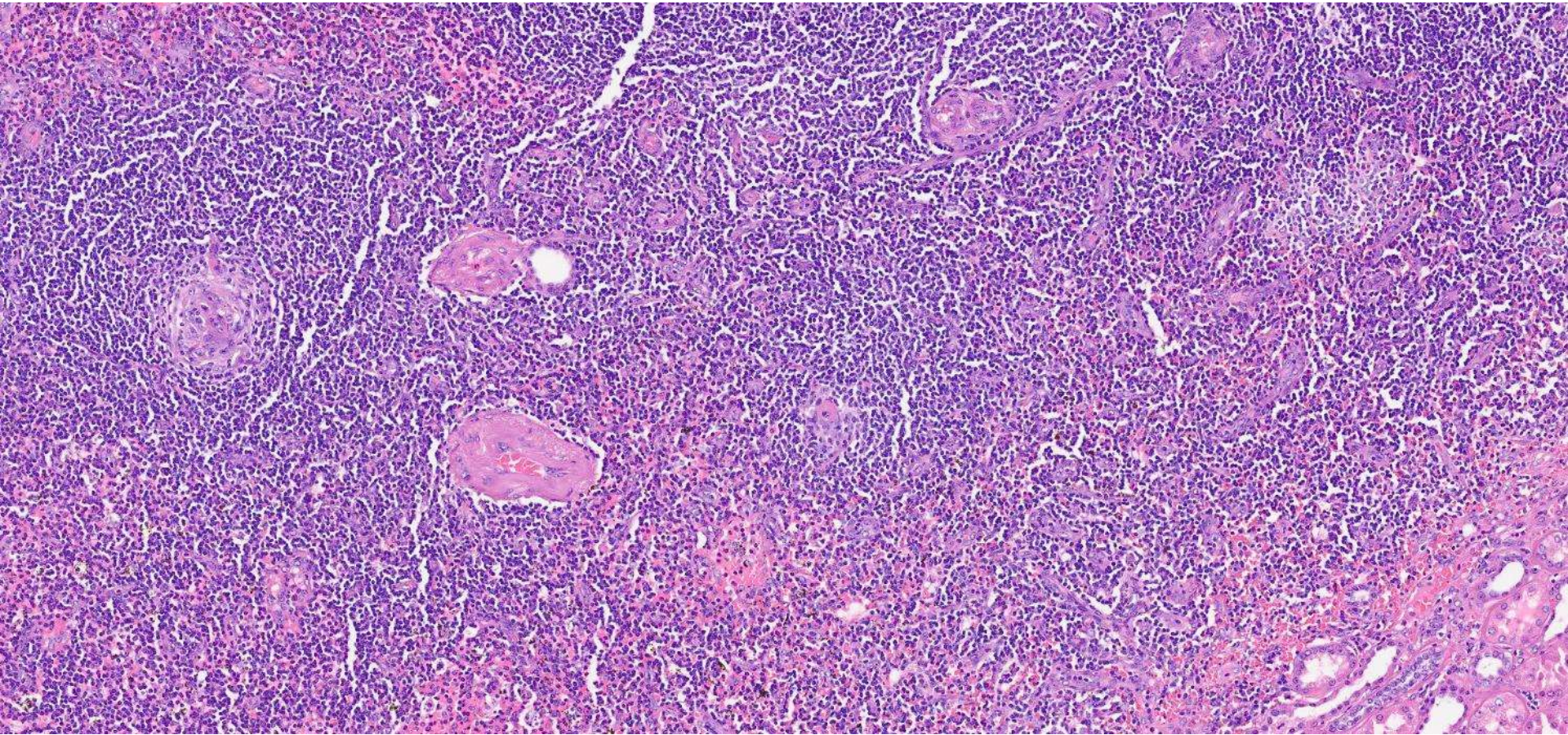


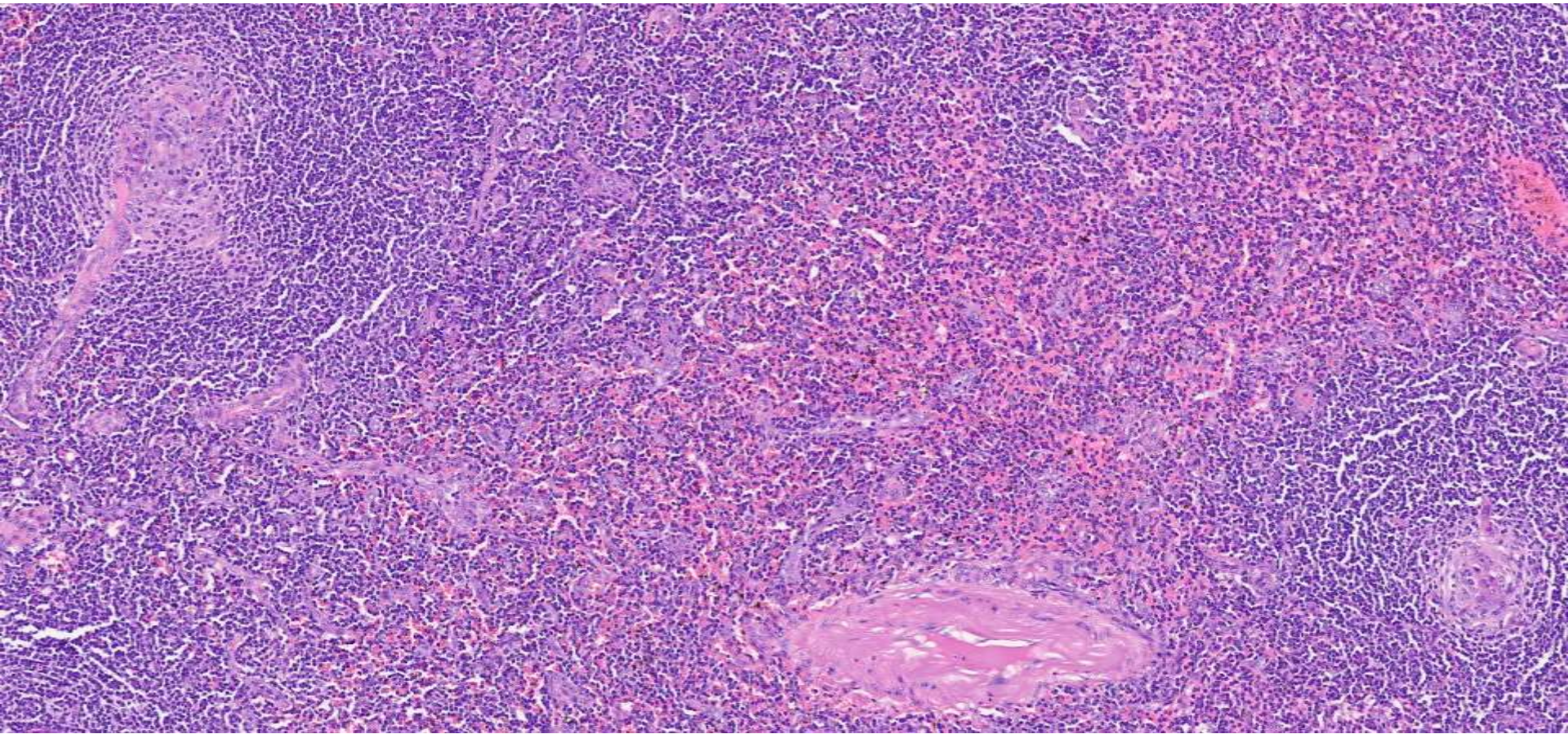


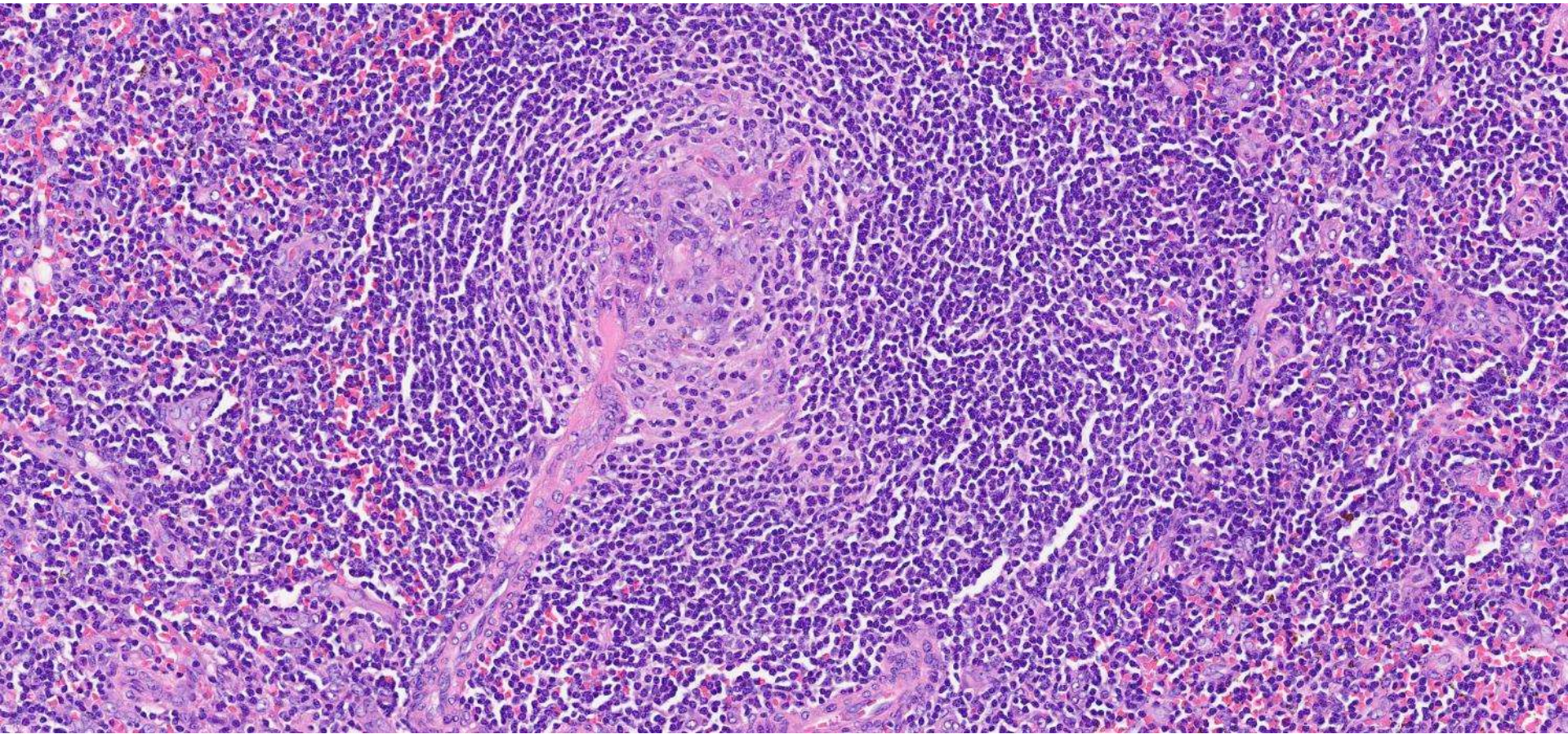


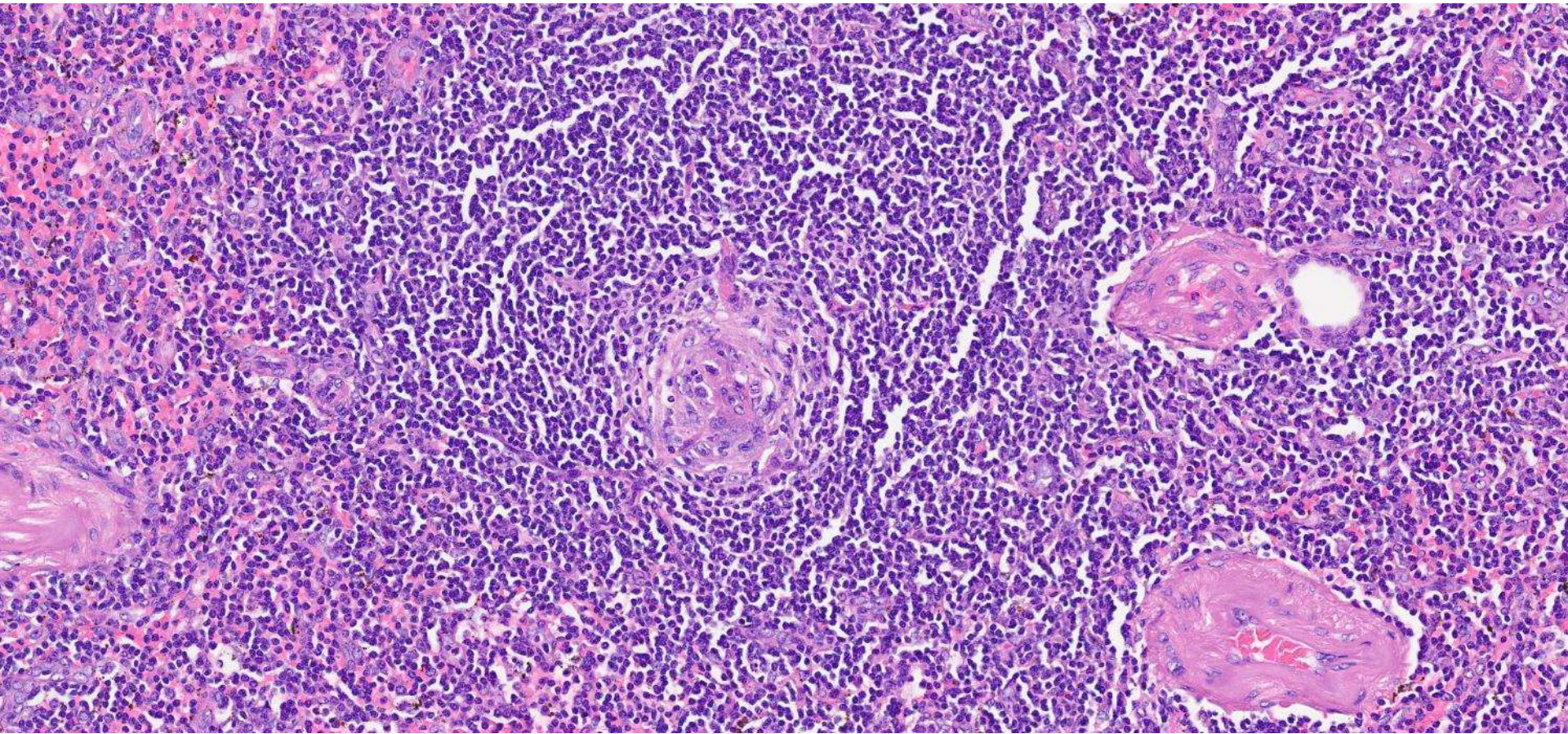












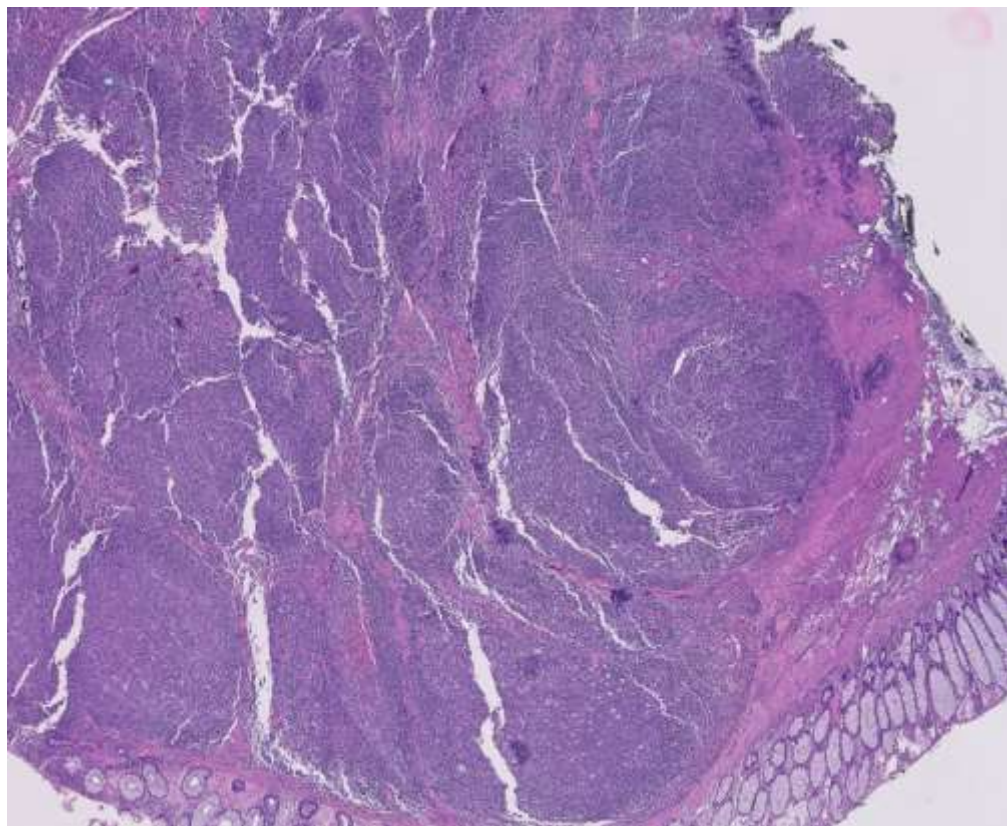
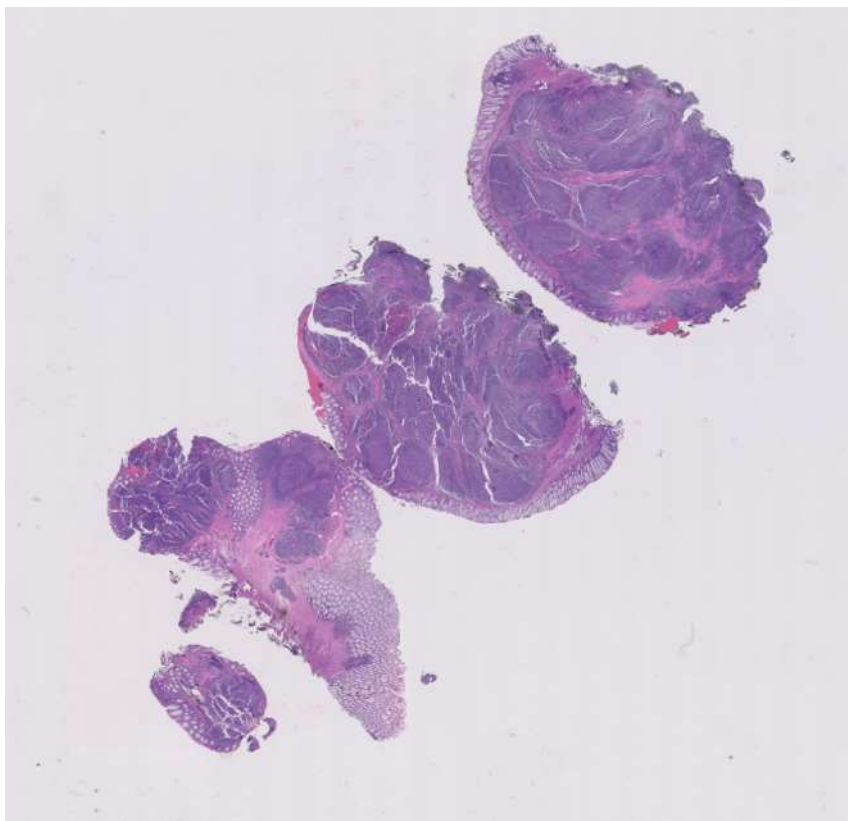
DIAGNOSIS?

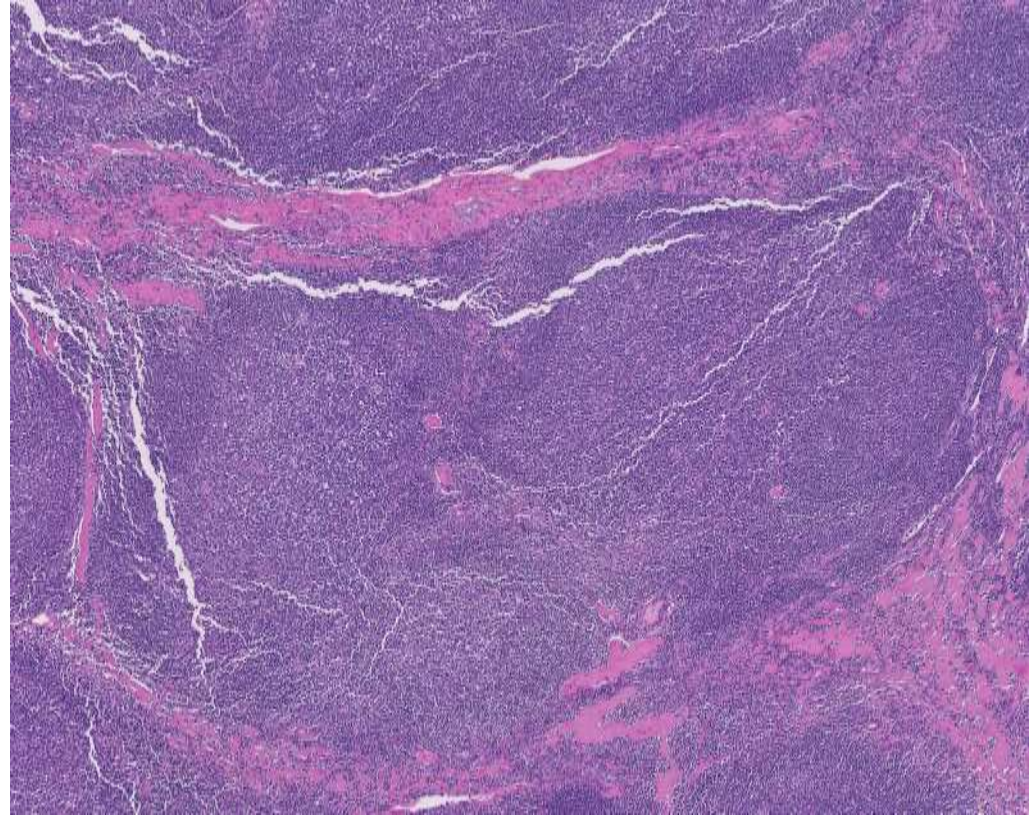
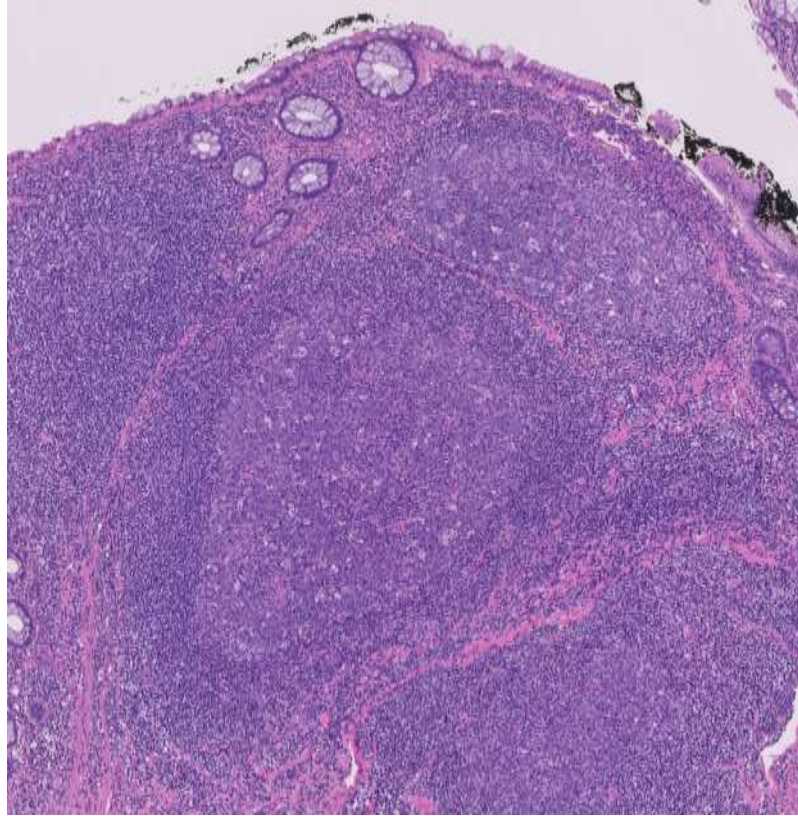


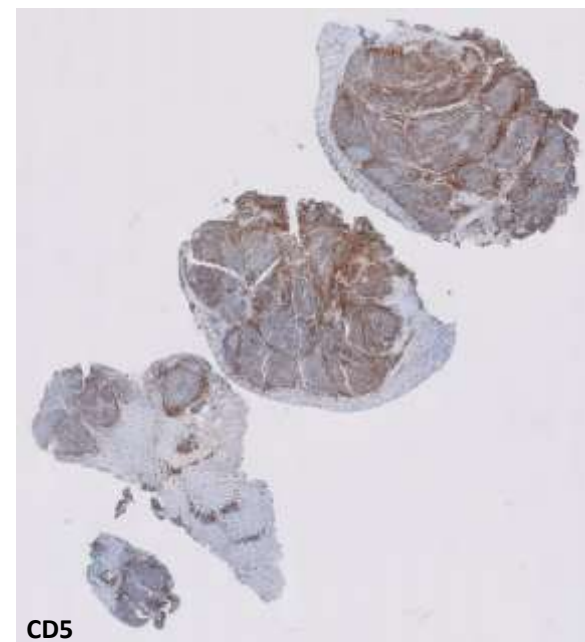
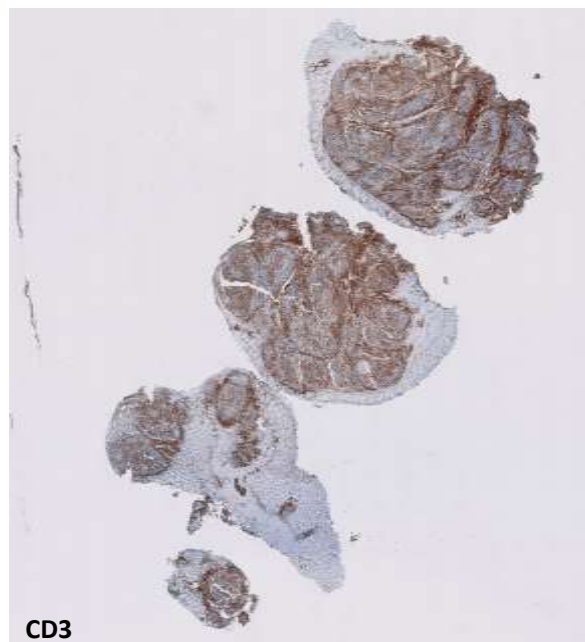
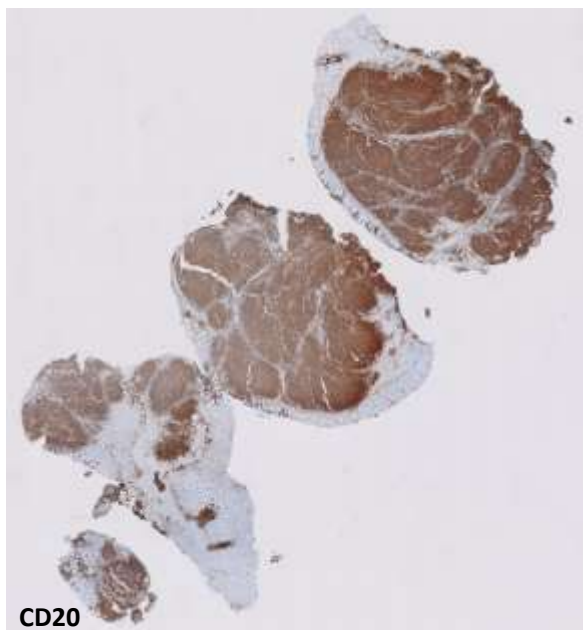
23-0405

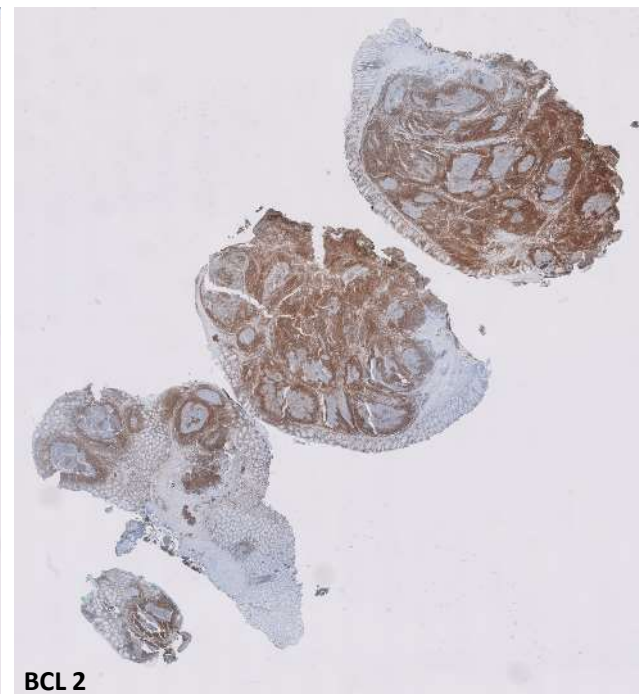
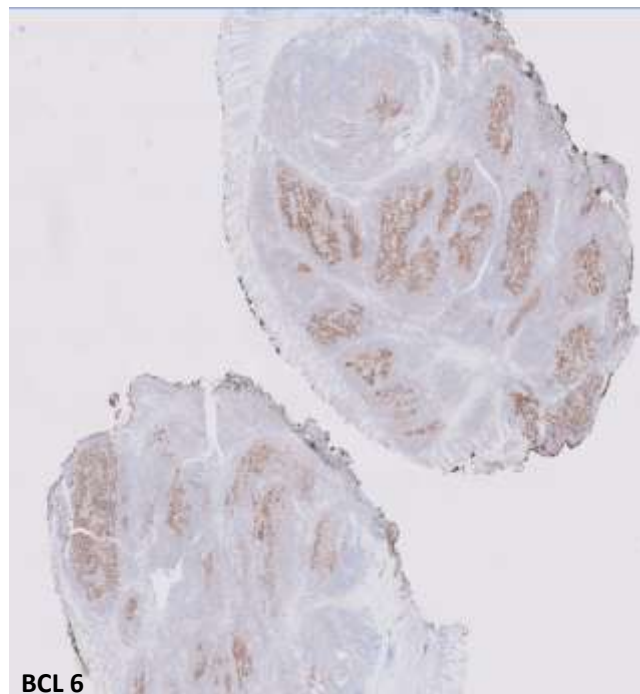
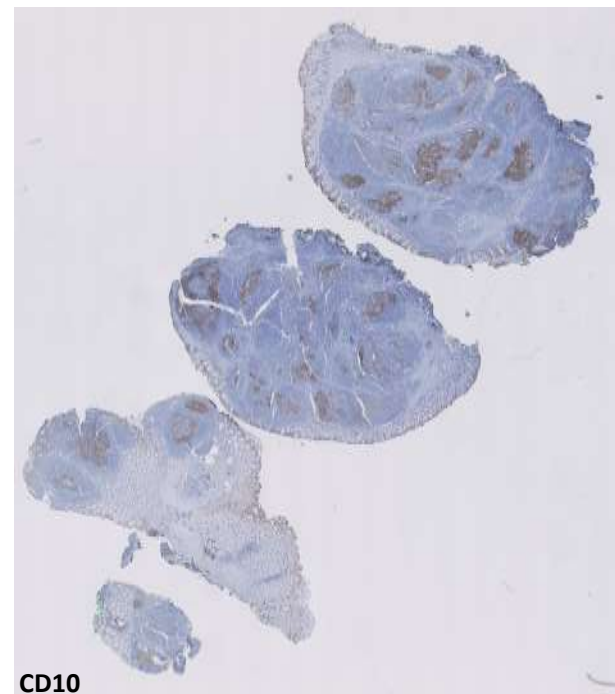
Anjanaa Vijayanarayanan/Sonam Prakash; UCSF

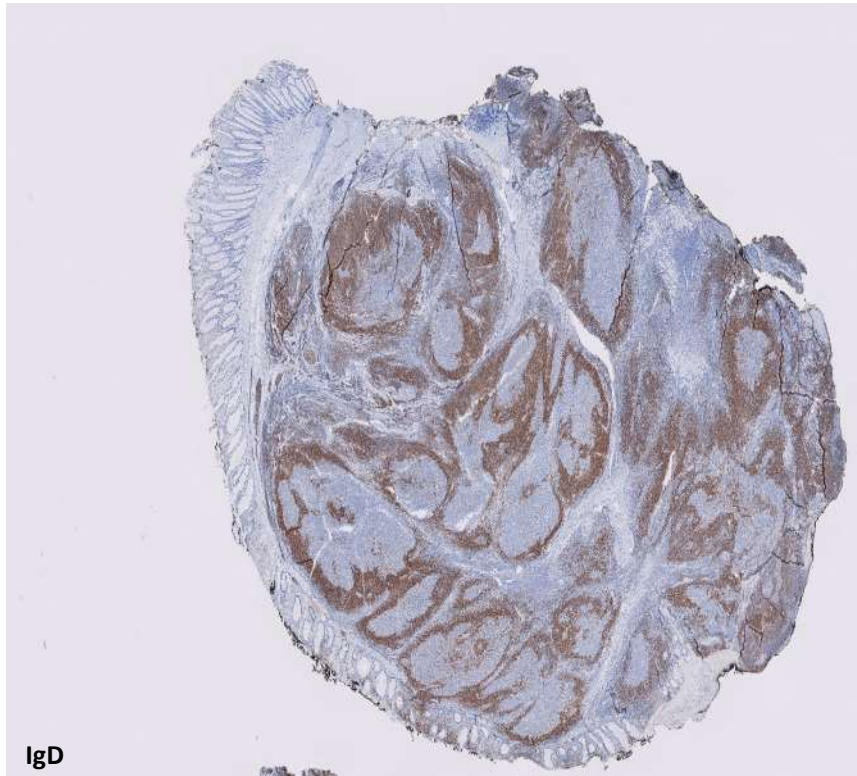
30ish F who presented with rectal and abdominal pain. Rectal biopsy performed.



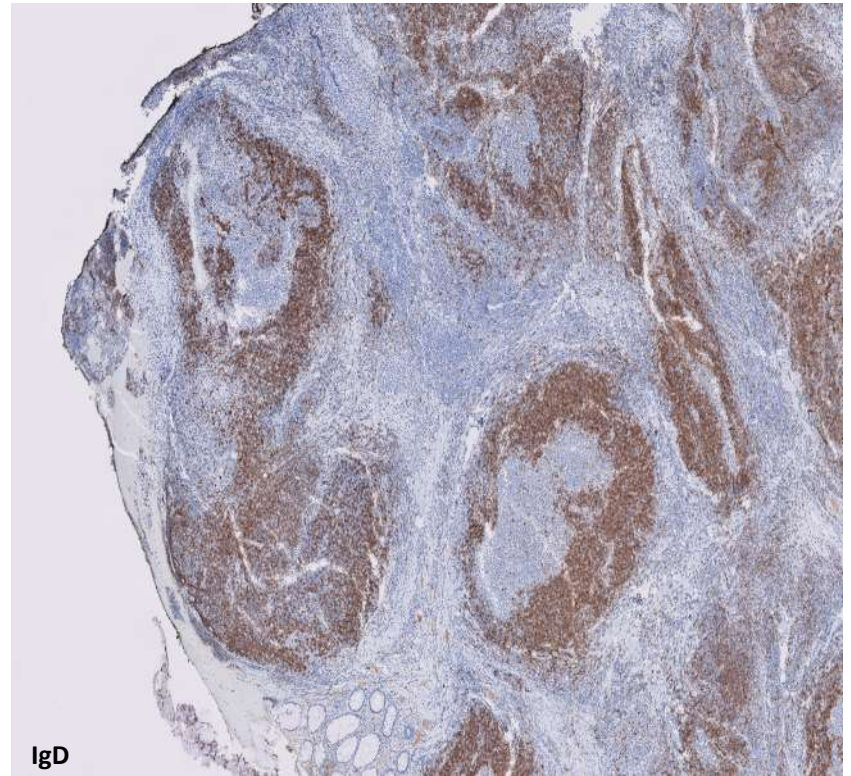




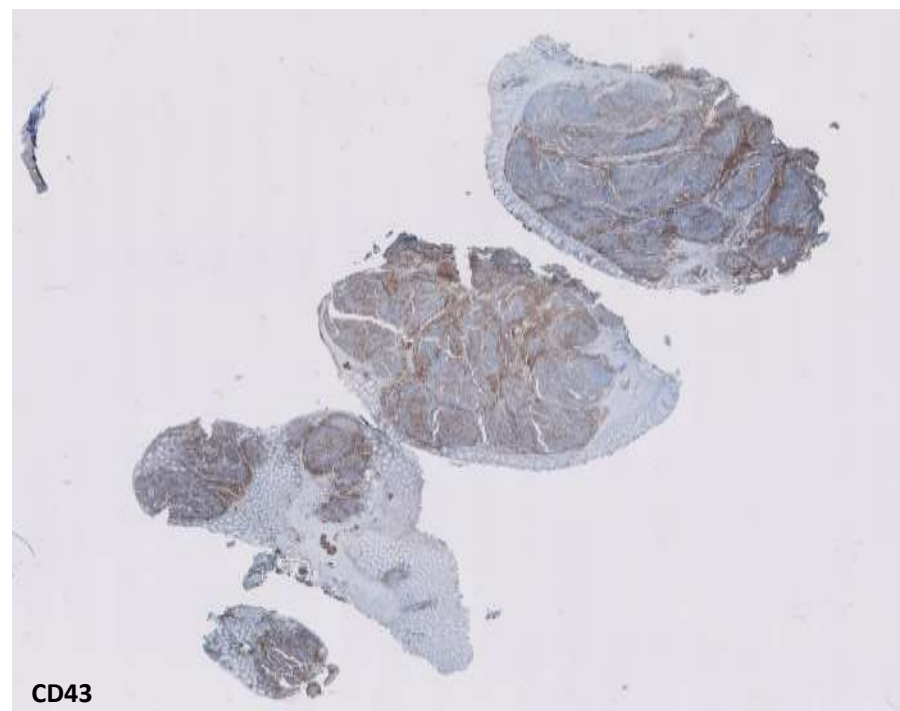
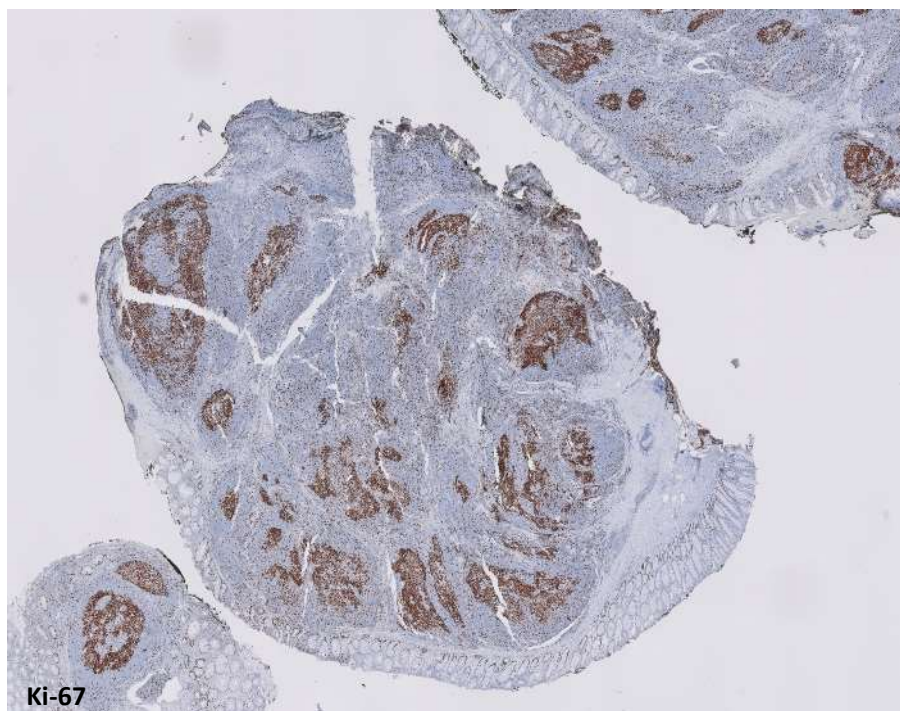




IgD



IgD



DIAGNOSIS?



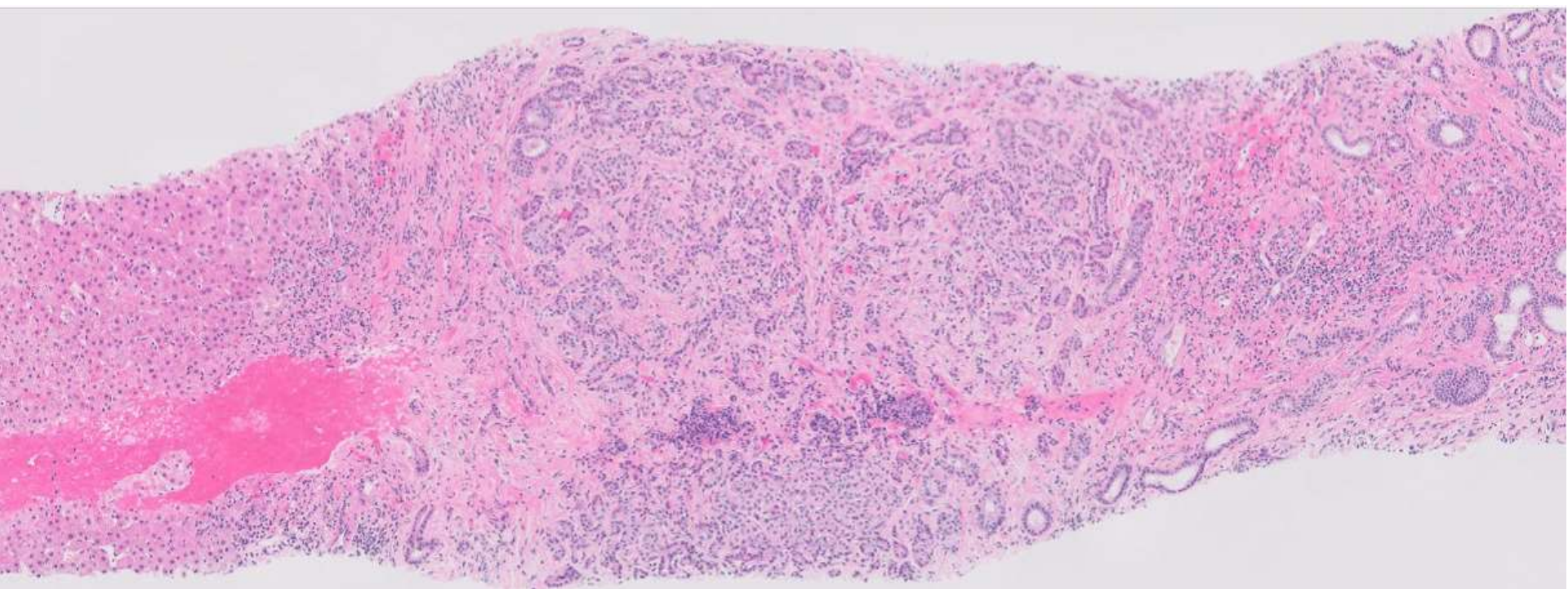
23-0406

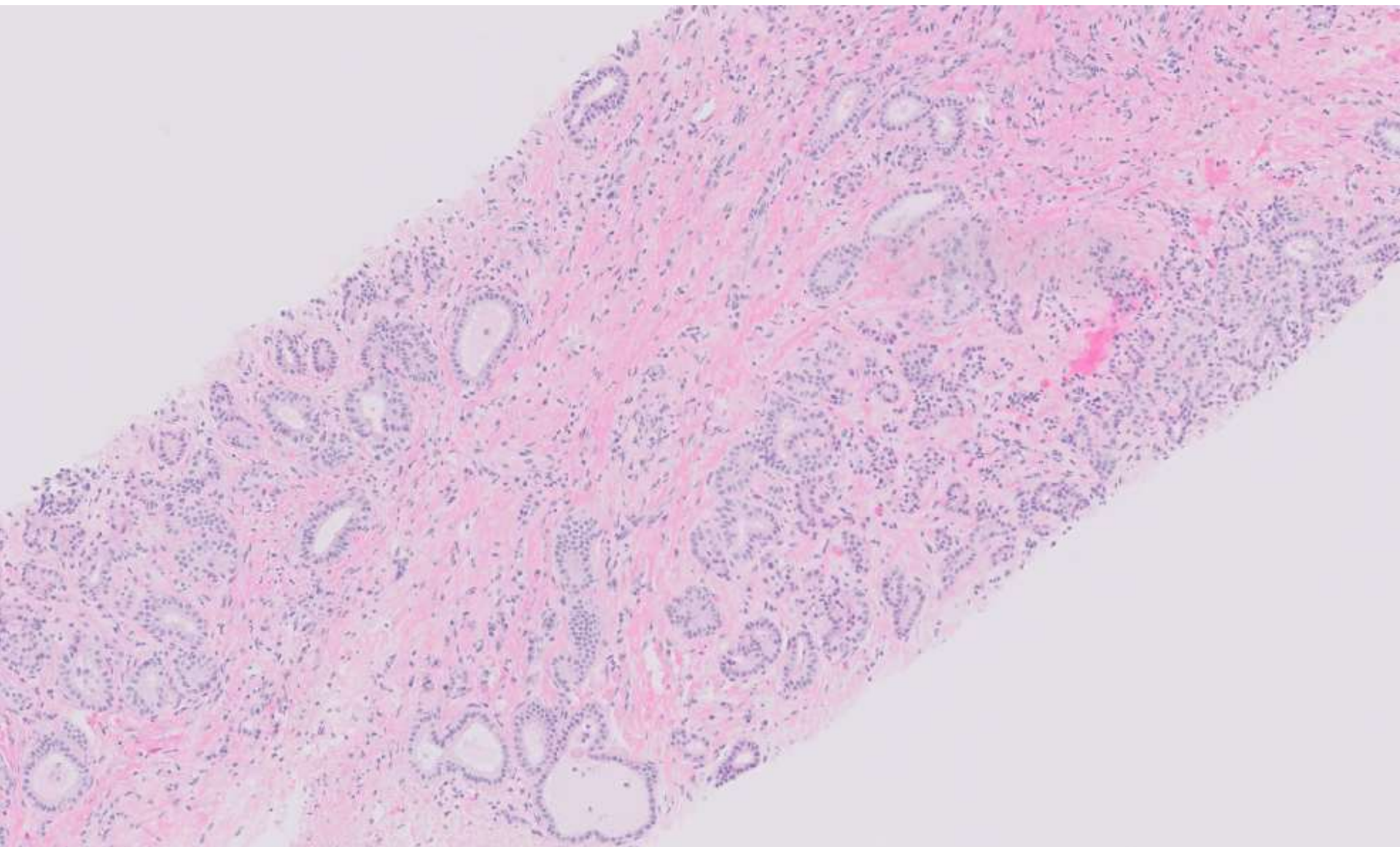
Sanjay Kakar; UCSF

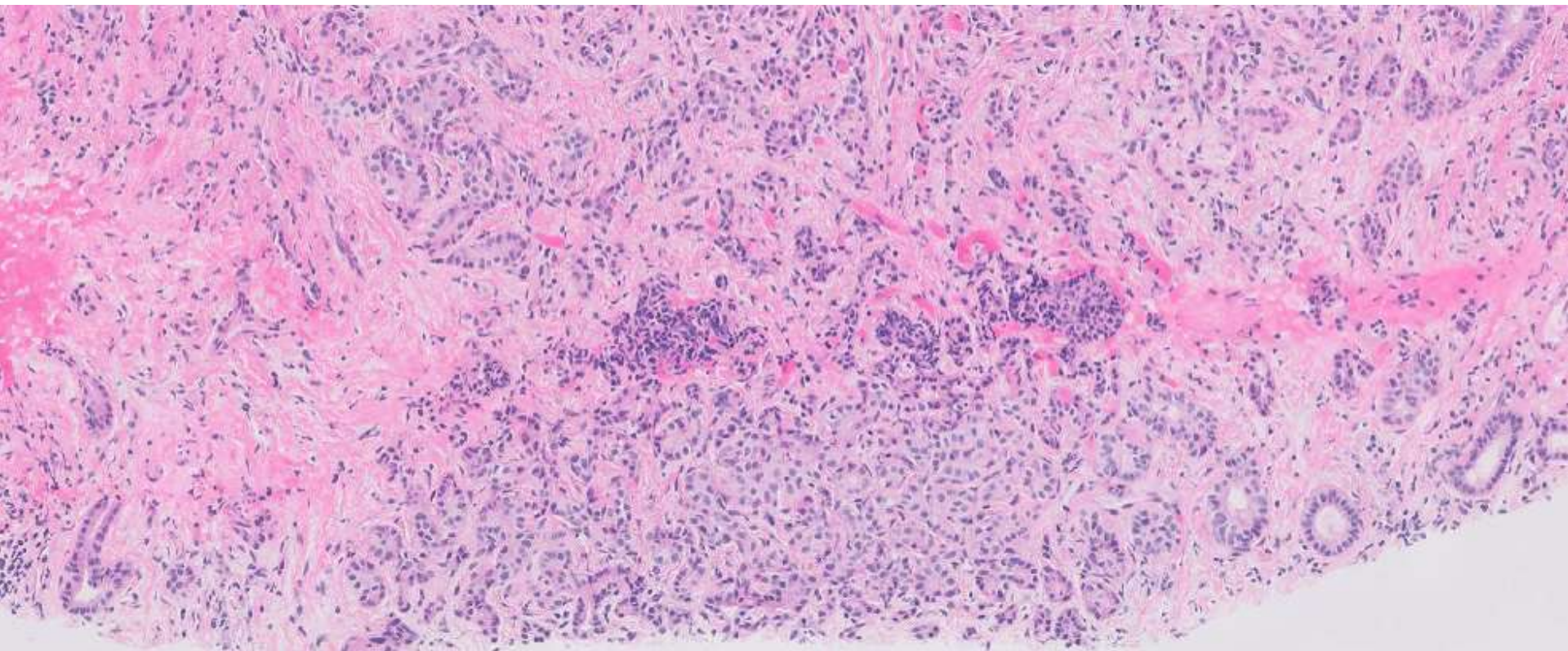
>60F with NASH cirrhosis and 3cm liver mass, biopsied.

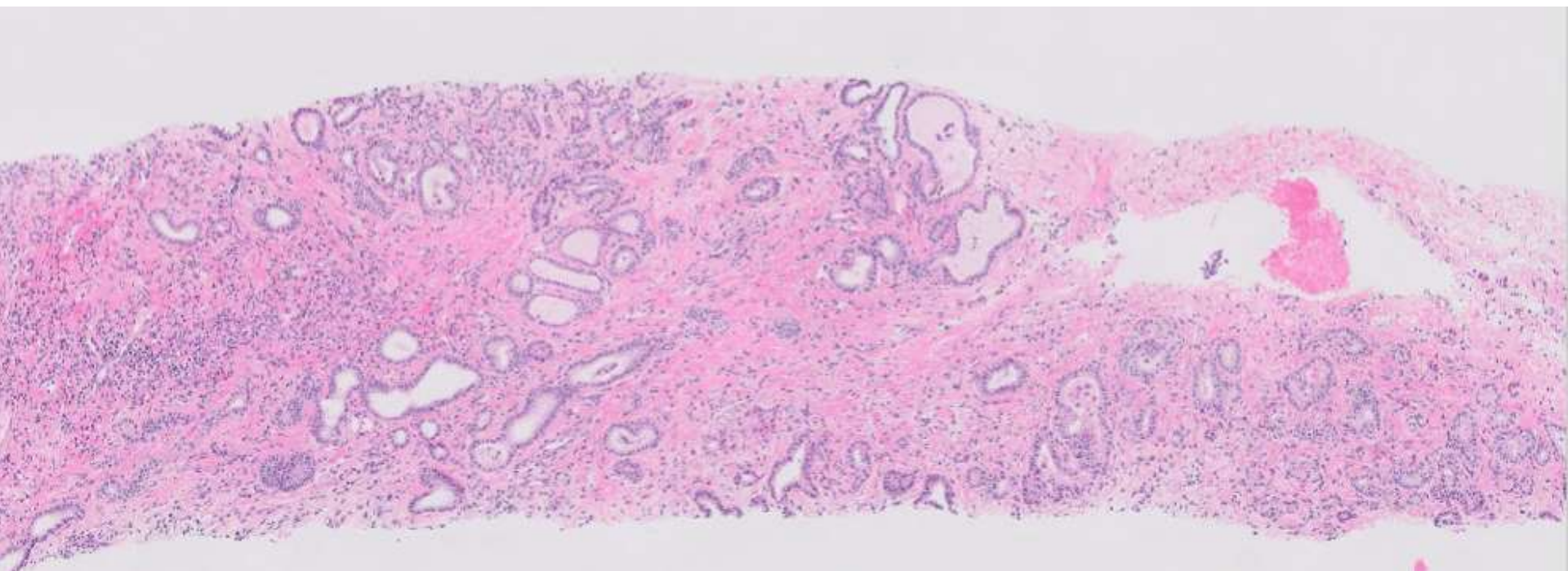
History

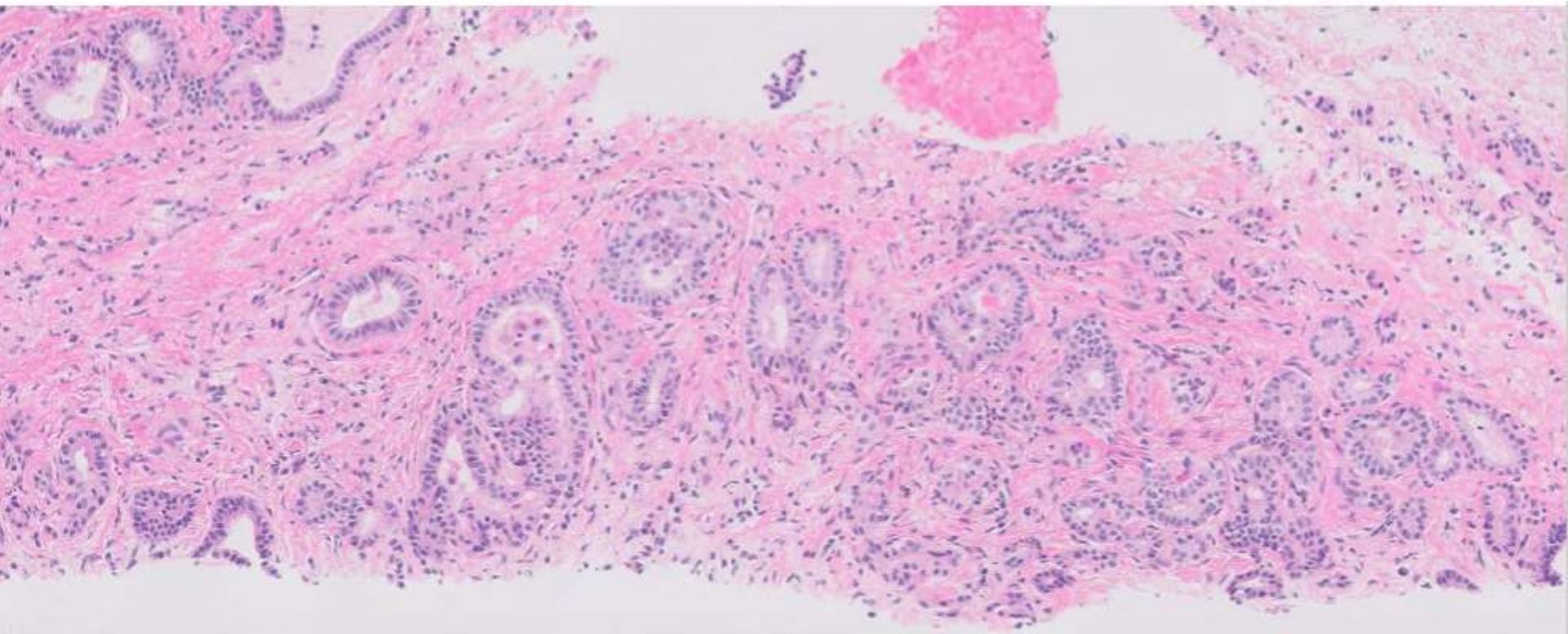
- >60 year old woman with NASH cirrhosis
- 3 cm mass, imaging indeterminate, findings not typical of HCC

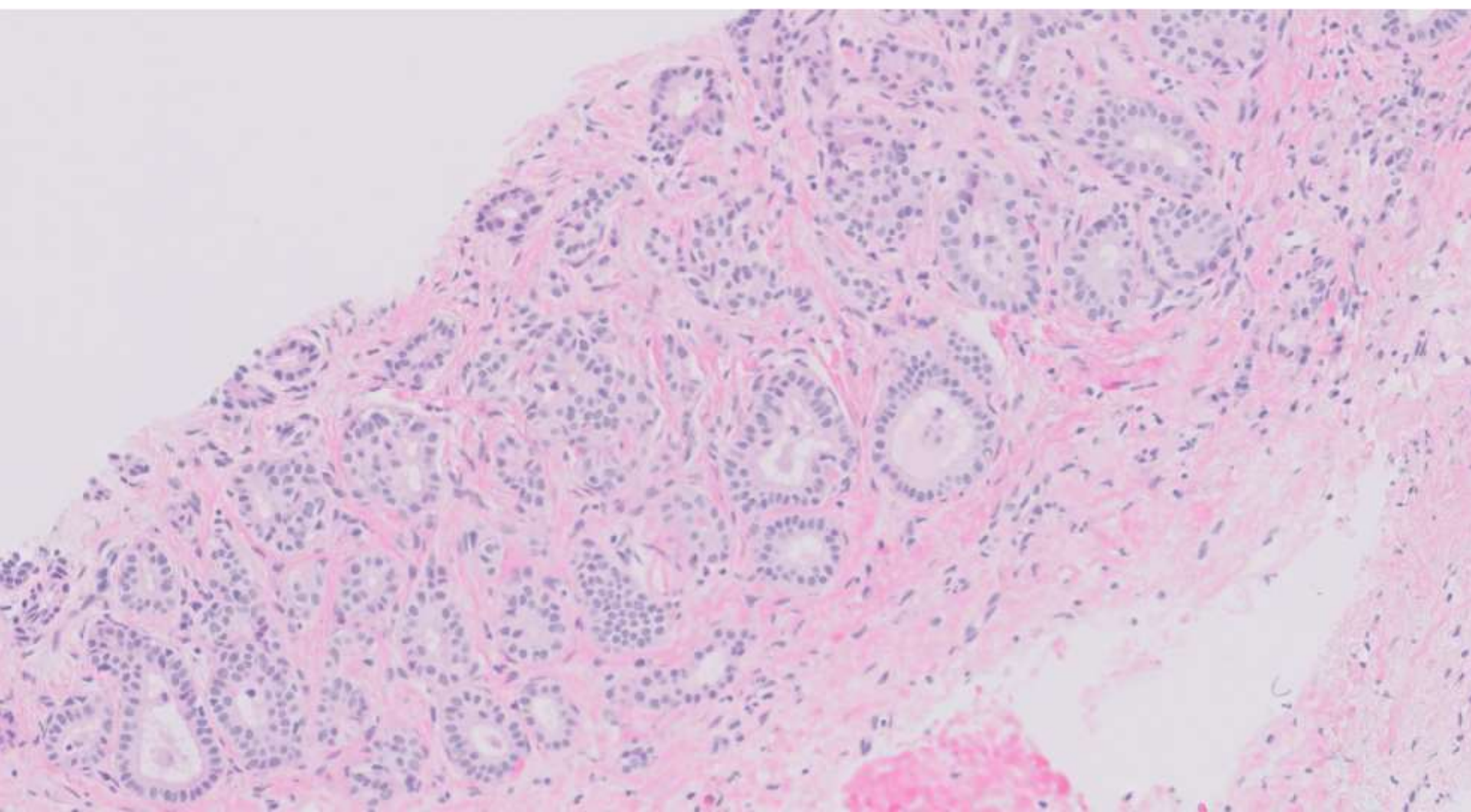


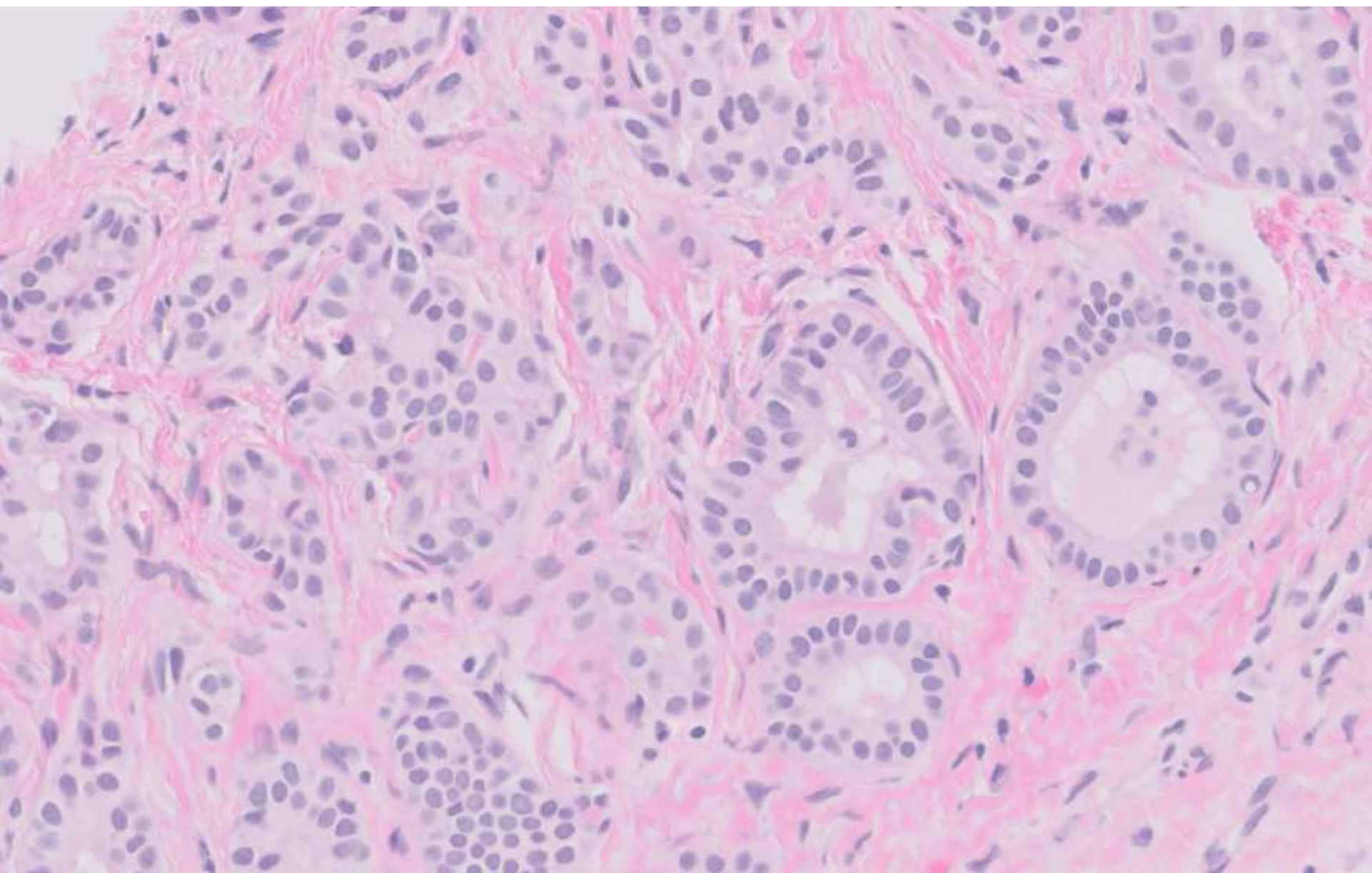




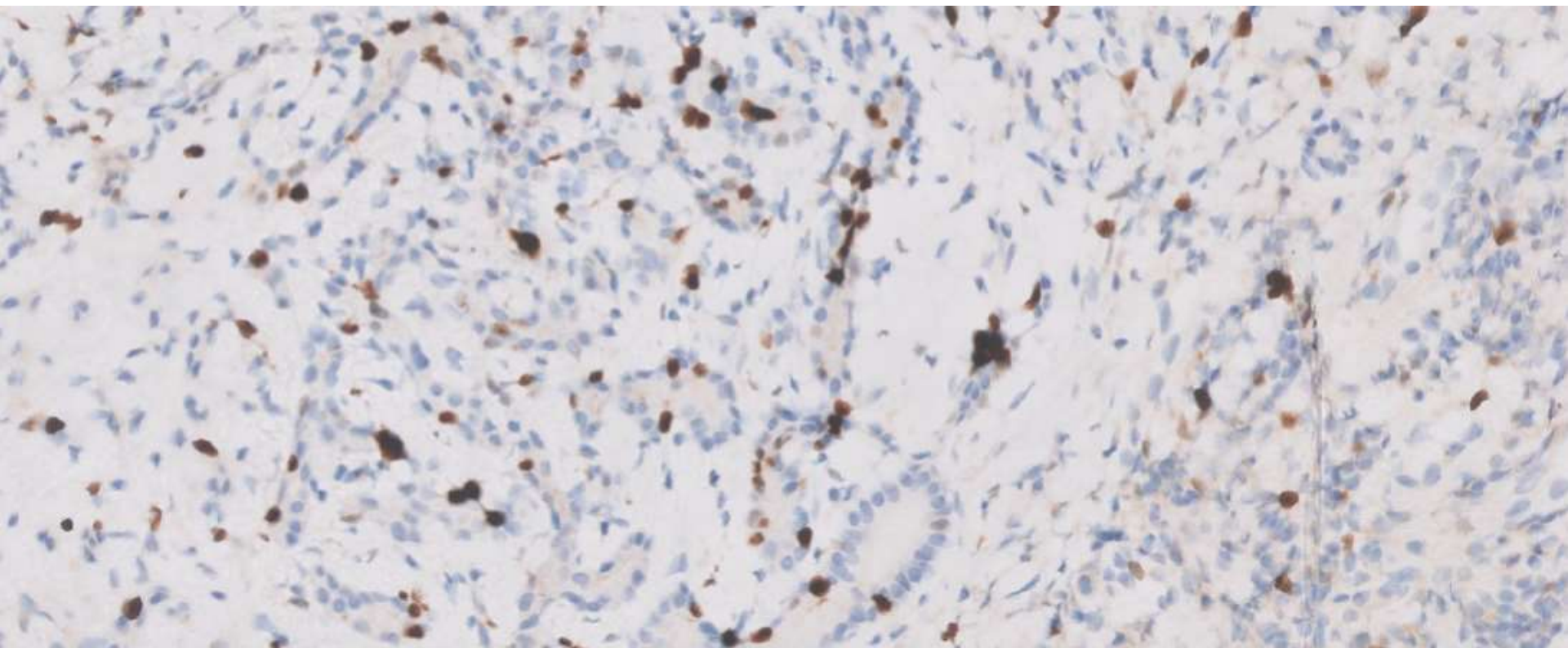




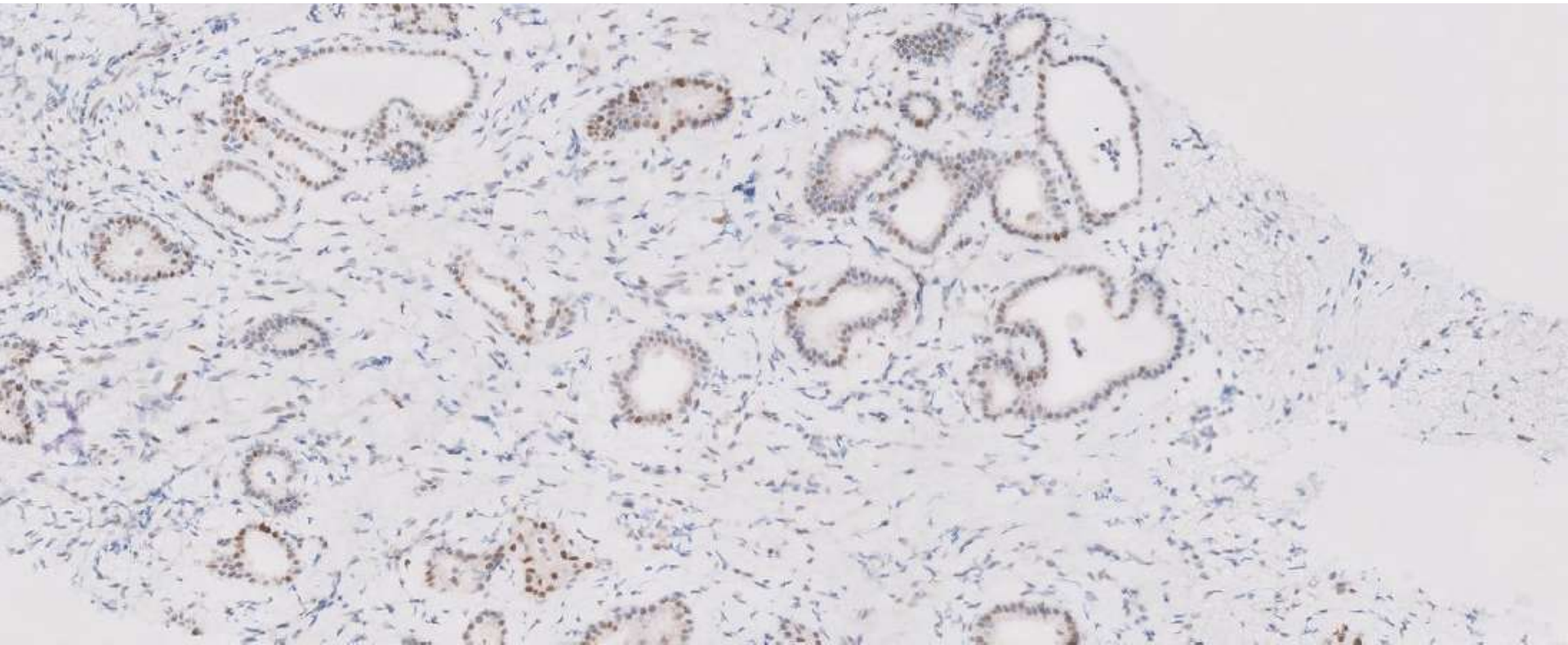




Ki-67



p53



DIAGNOSIS?

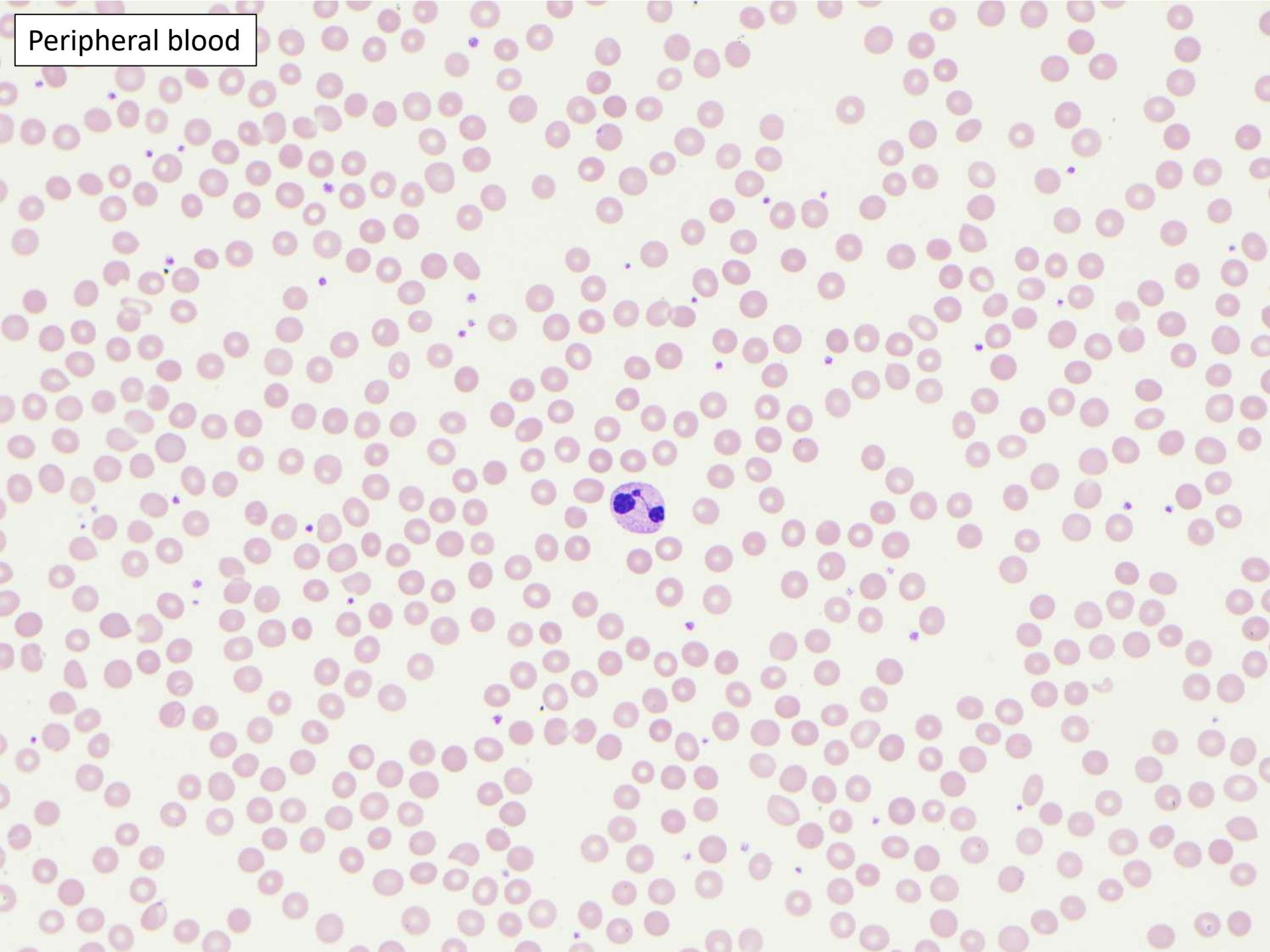

23-0407

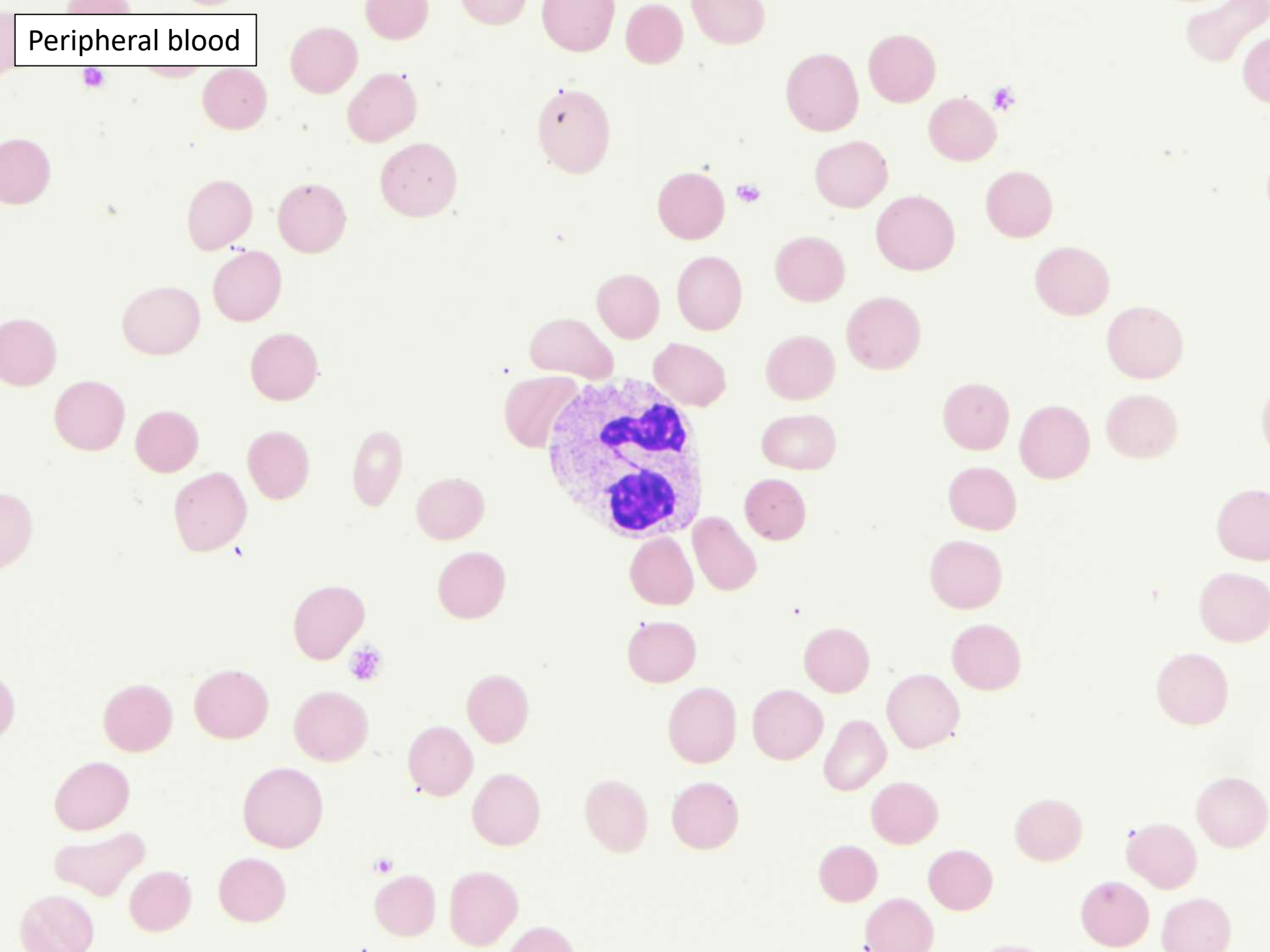
Ingold Huang/Linlin Wang; UCSF

Female infant with neutropenia. Bone marrow biopsy submitted.

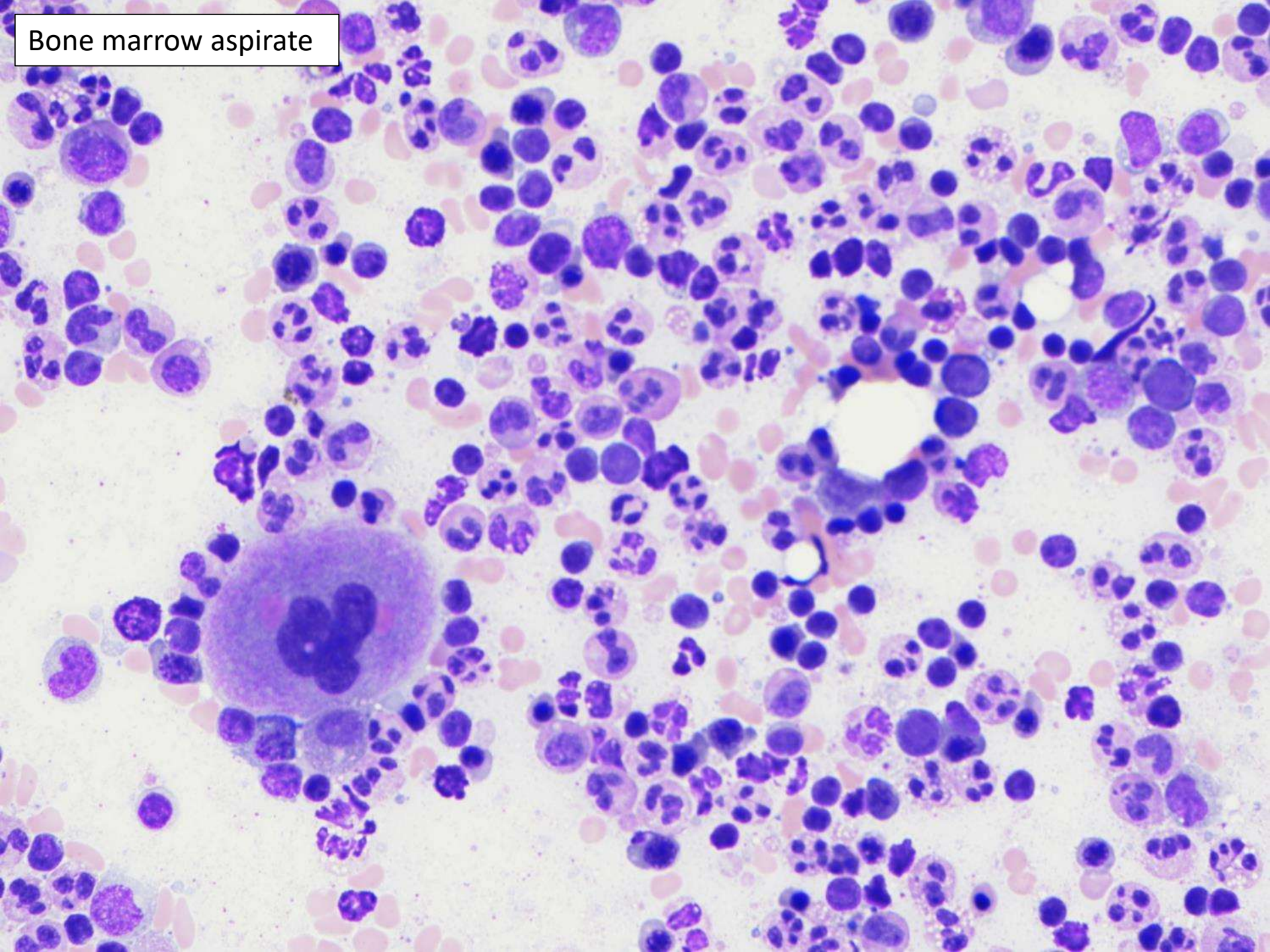
Peripheral blood



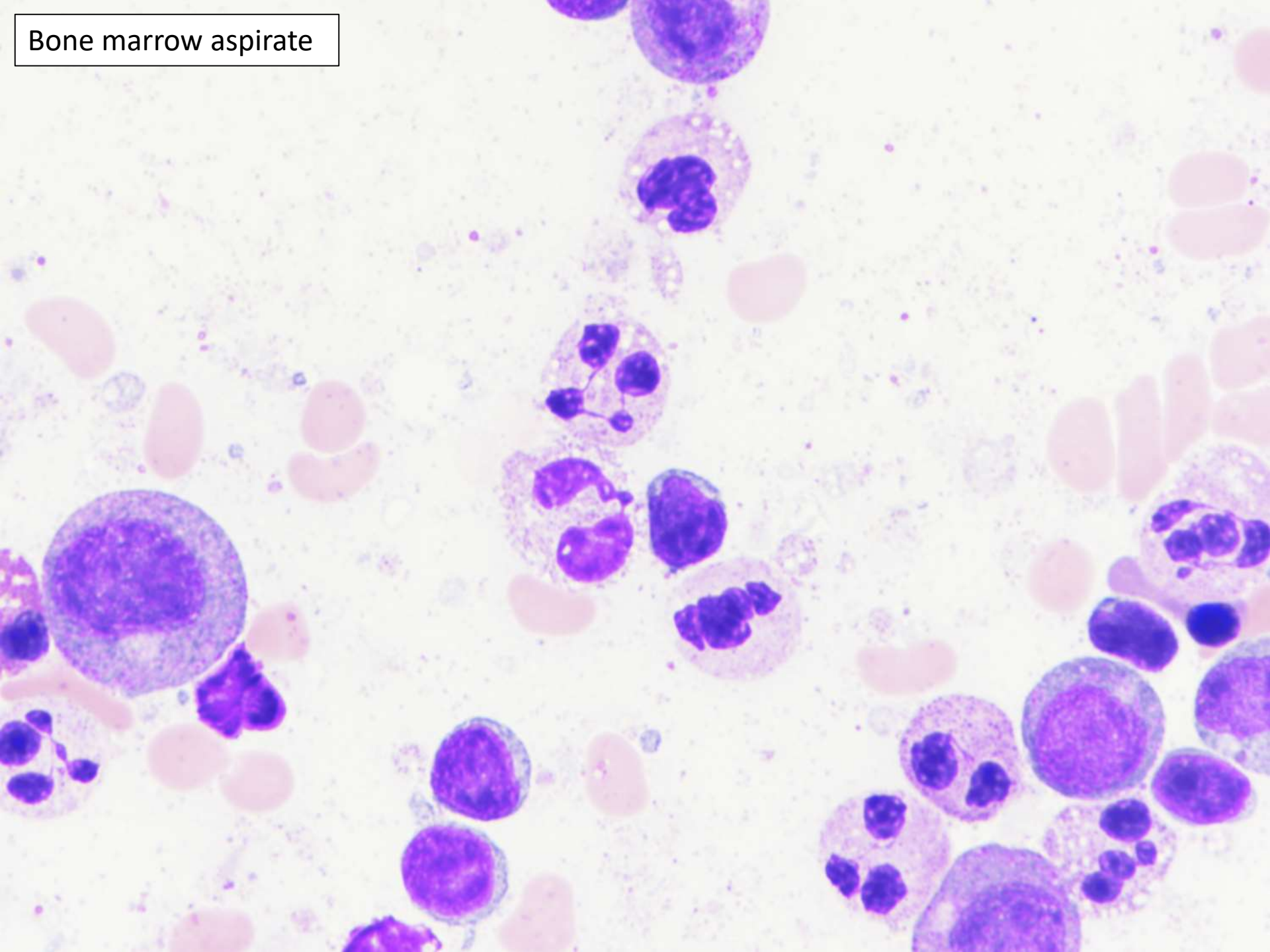
Peripheral blood



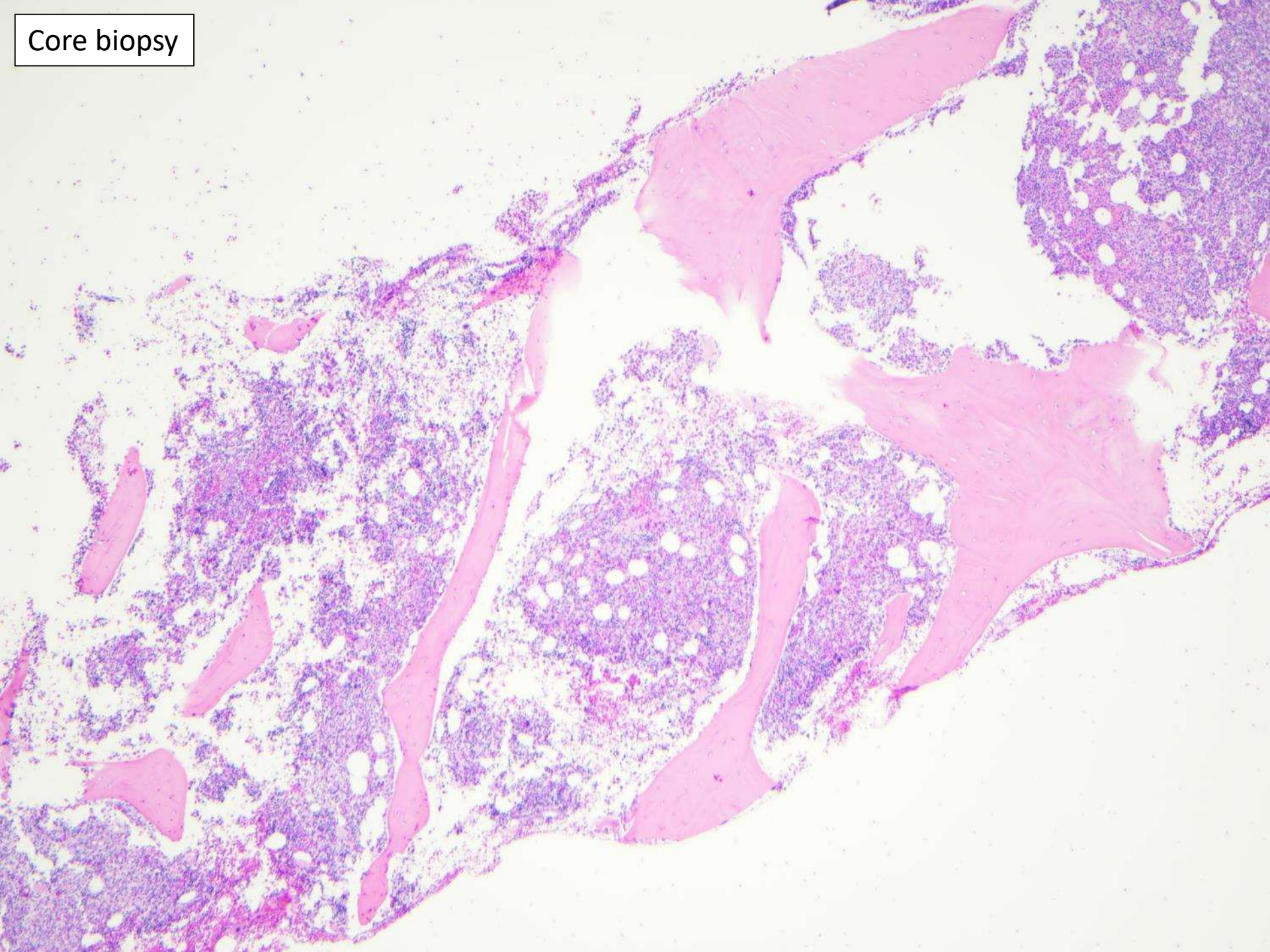
Bone marrow aspirate



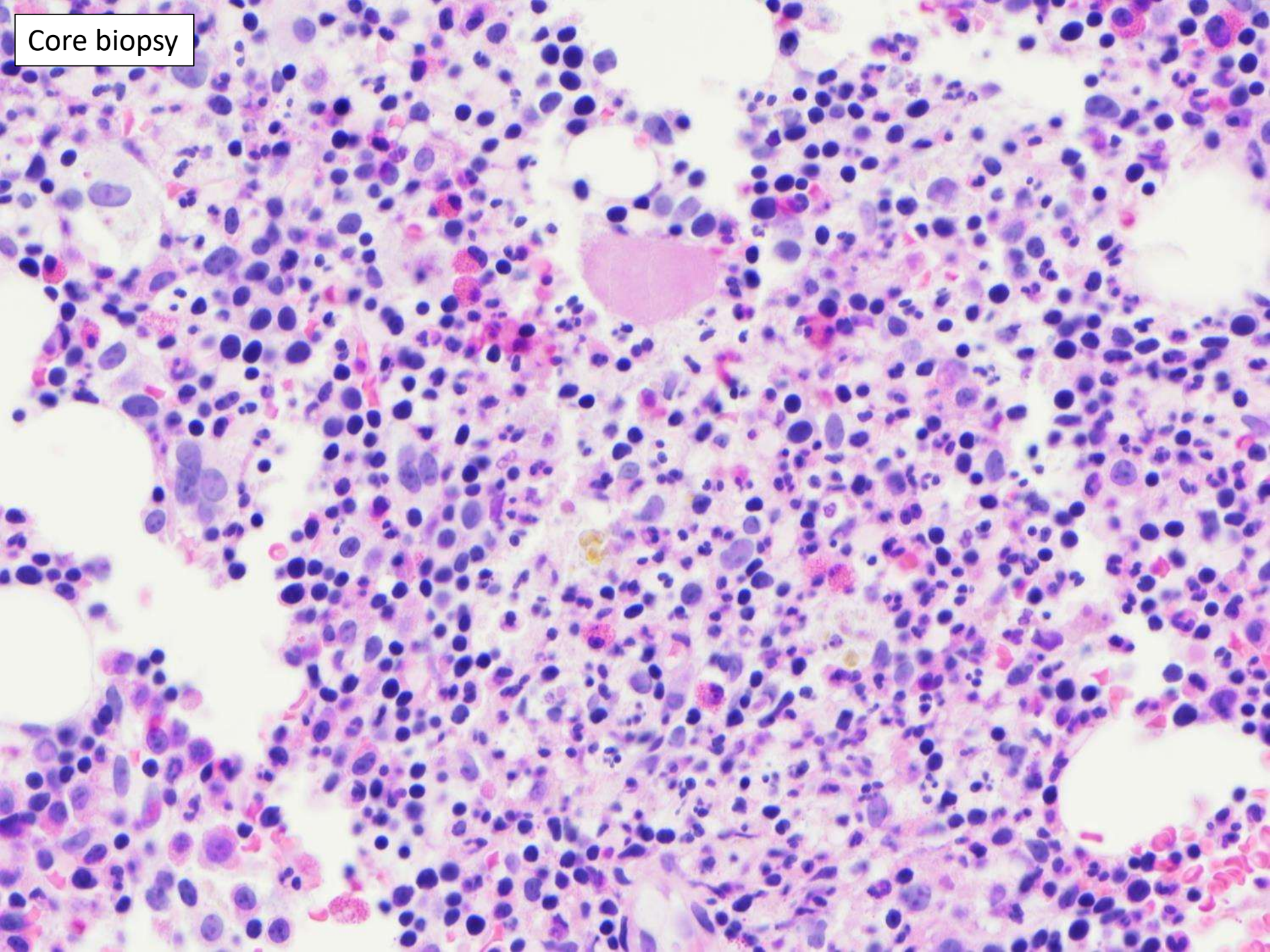
Bone marrow aspirate



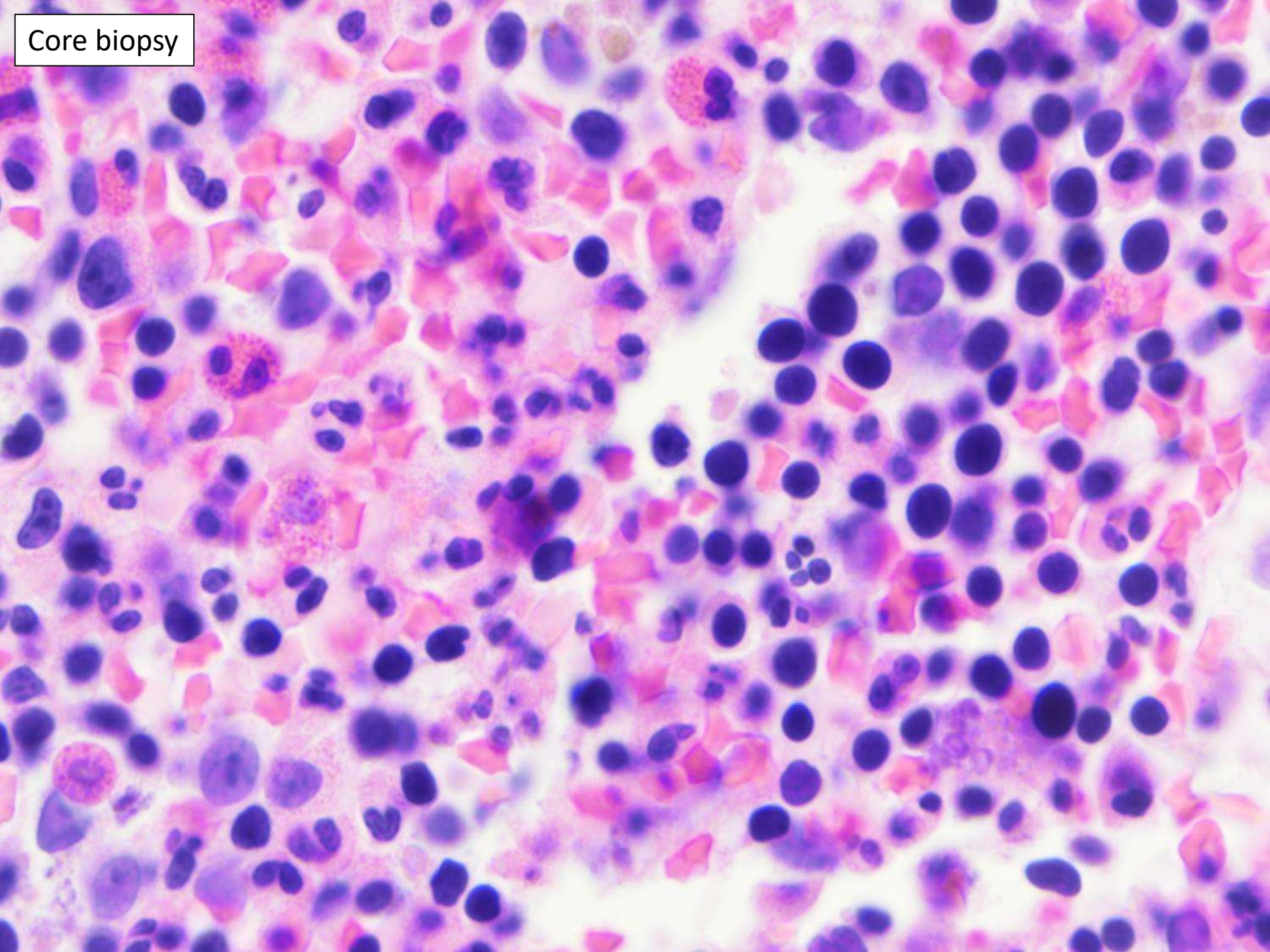
Core biopsy



Core biopsy



Core biopsy



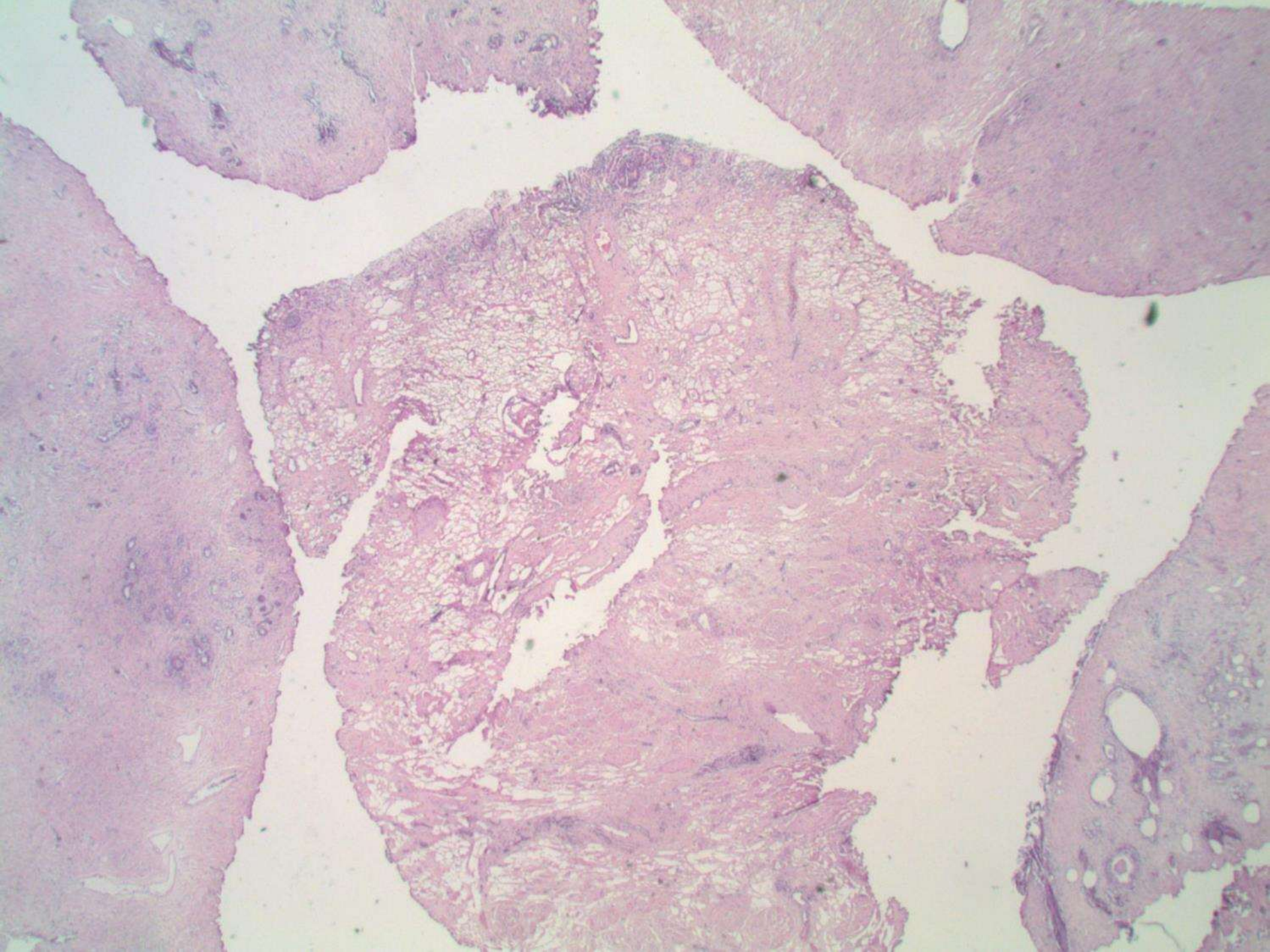
DIAGNOSIS?

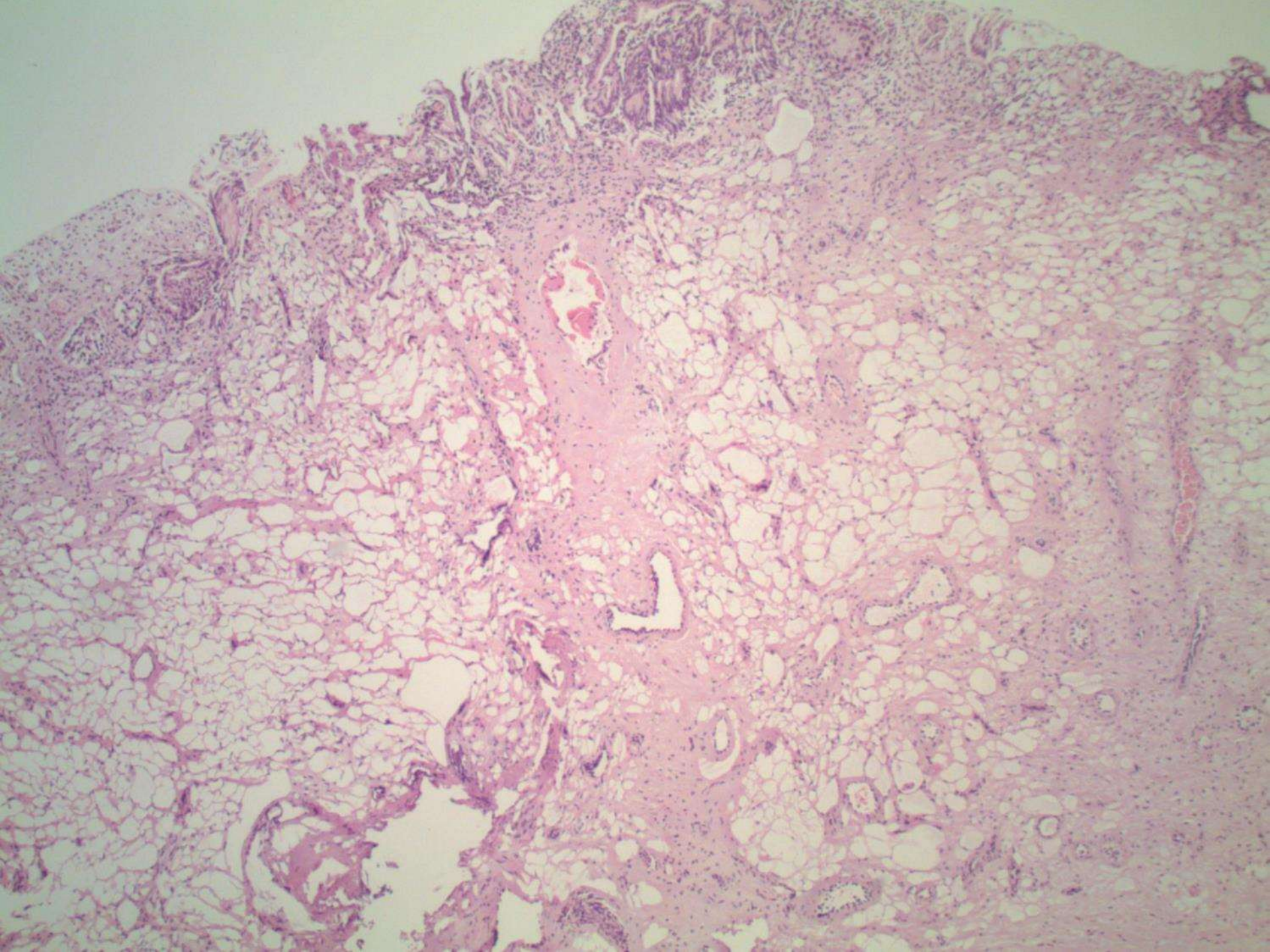


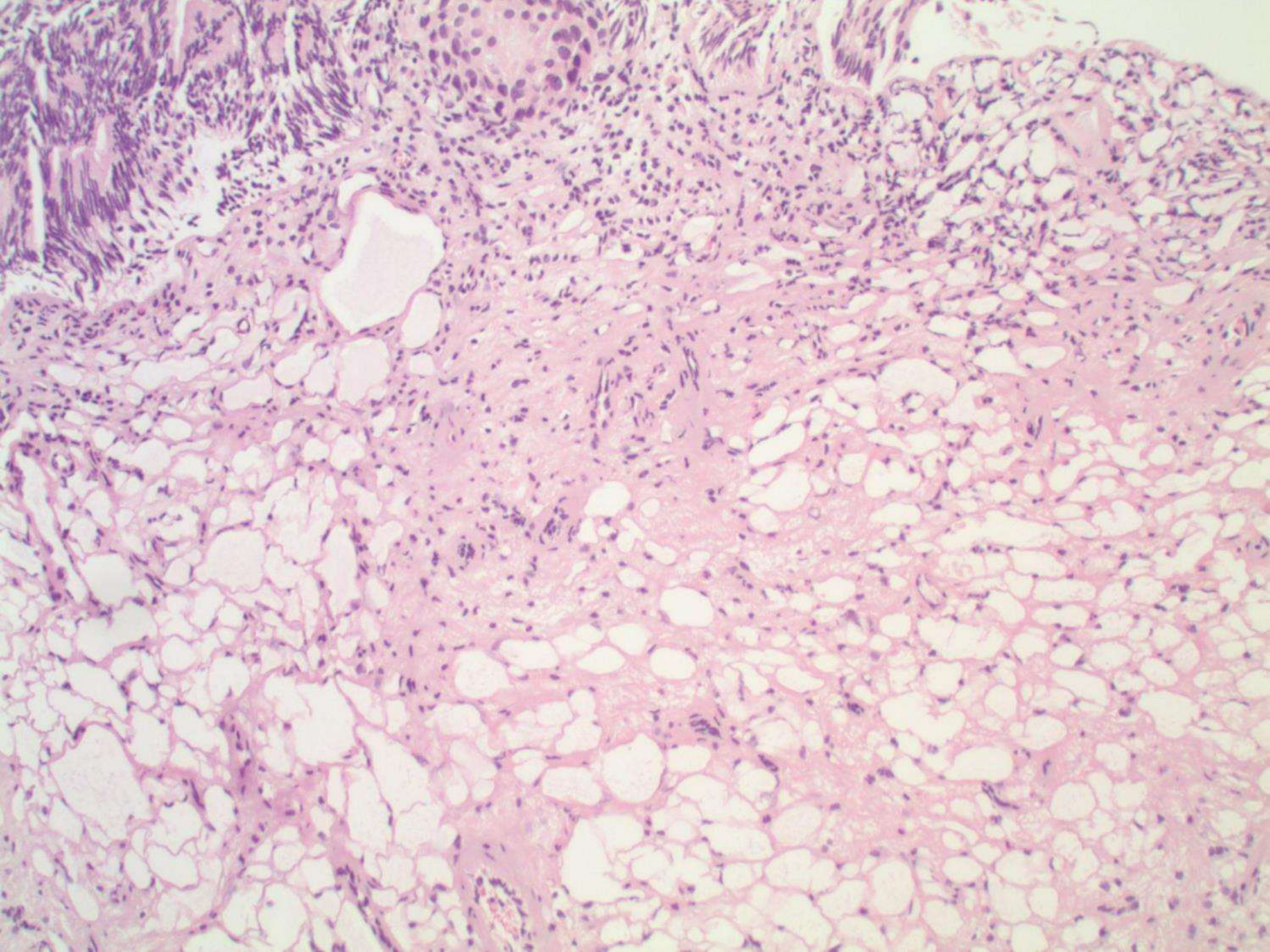
23-0408

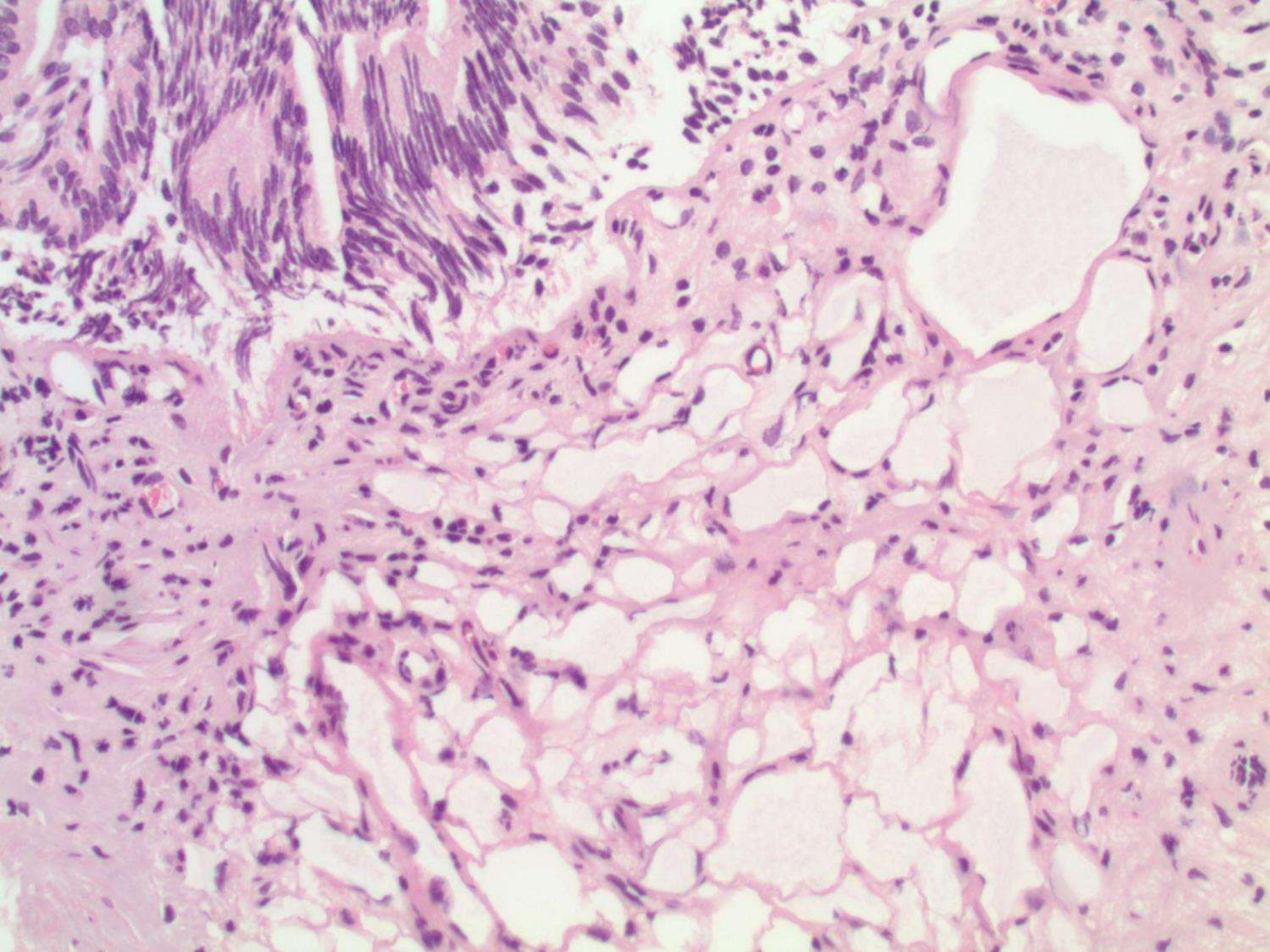
Ankur Sangoi; El Camino Hospital

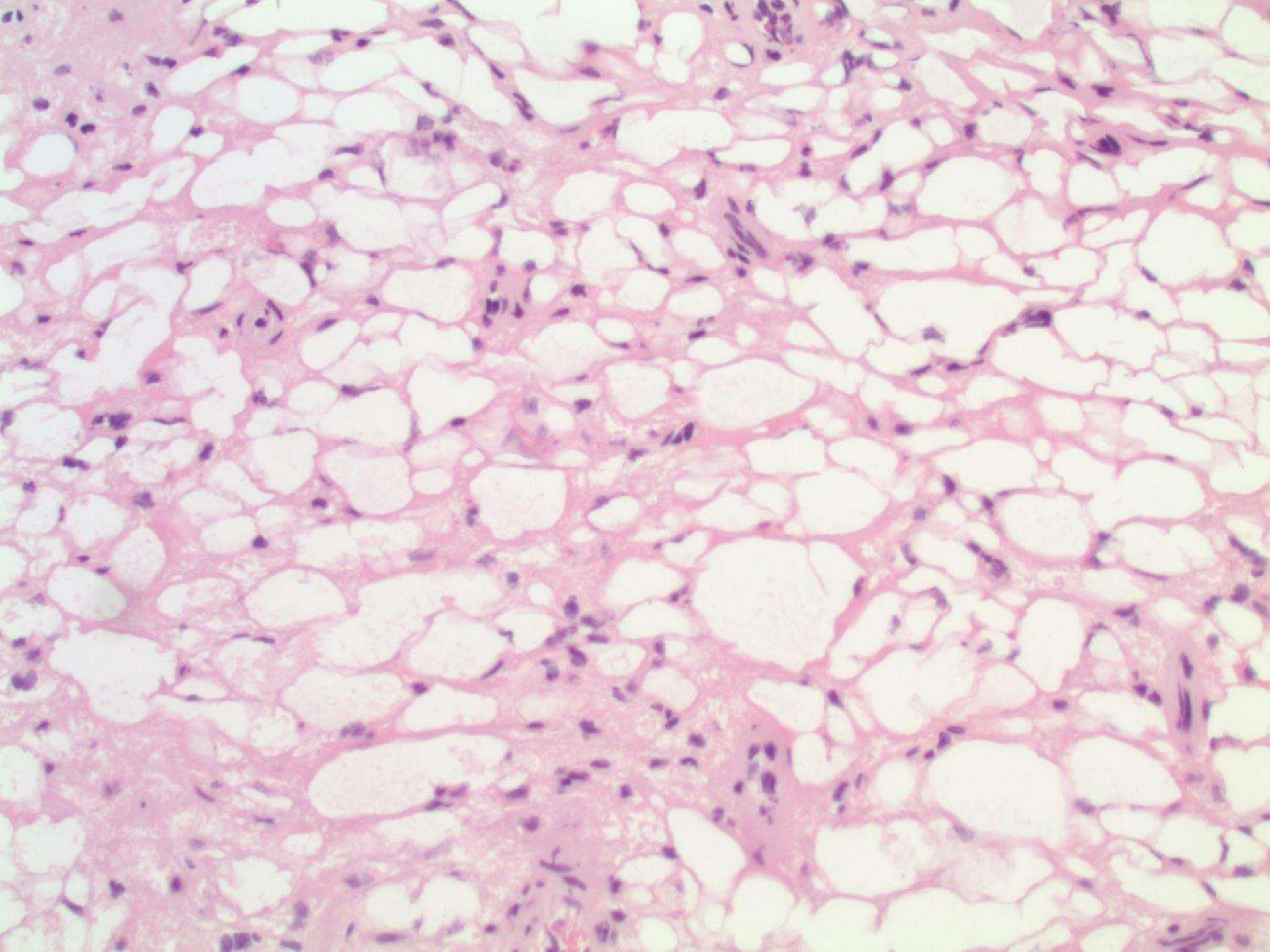
Adult M presents with BPH, undergoes TURP.

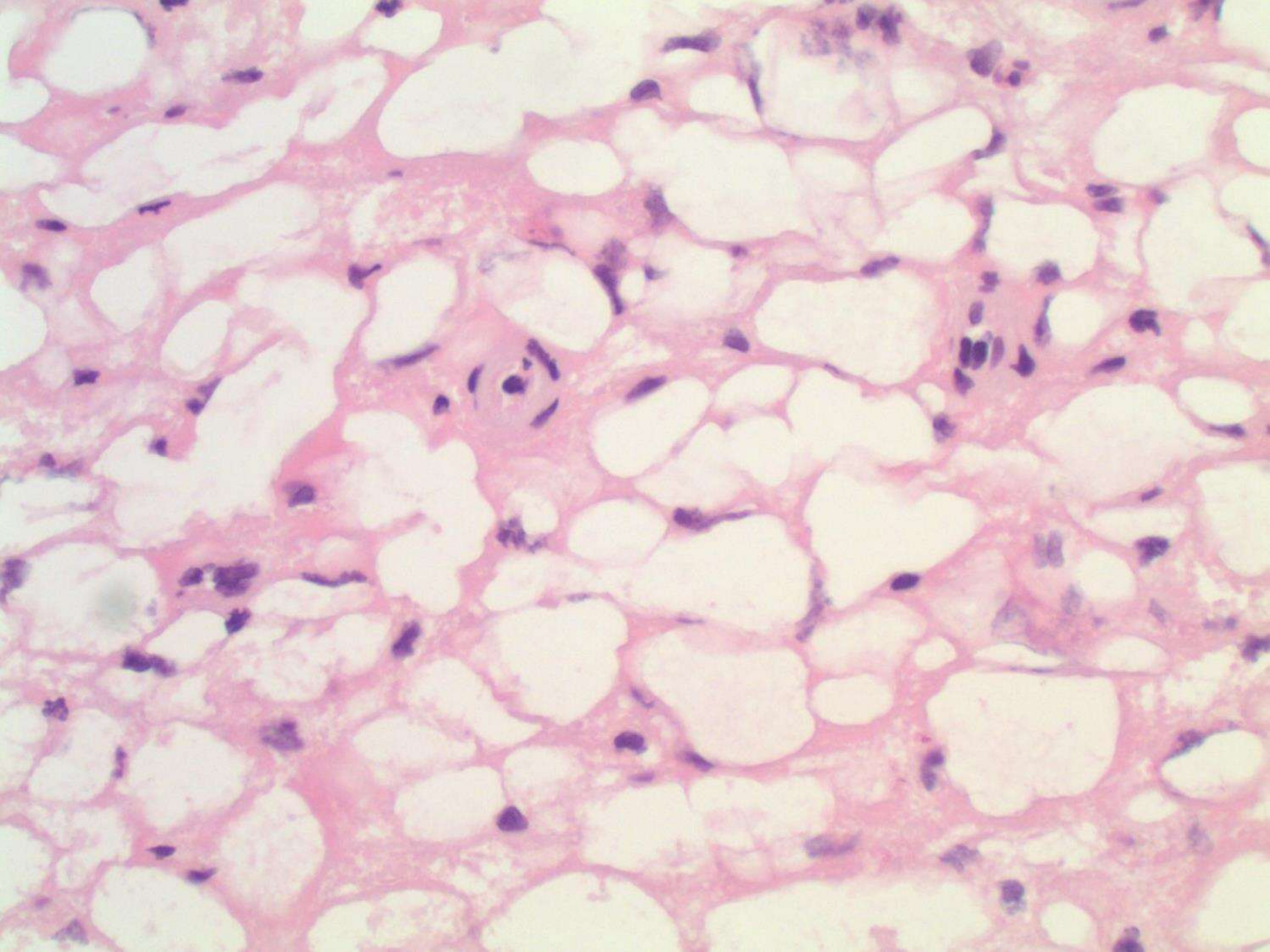


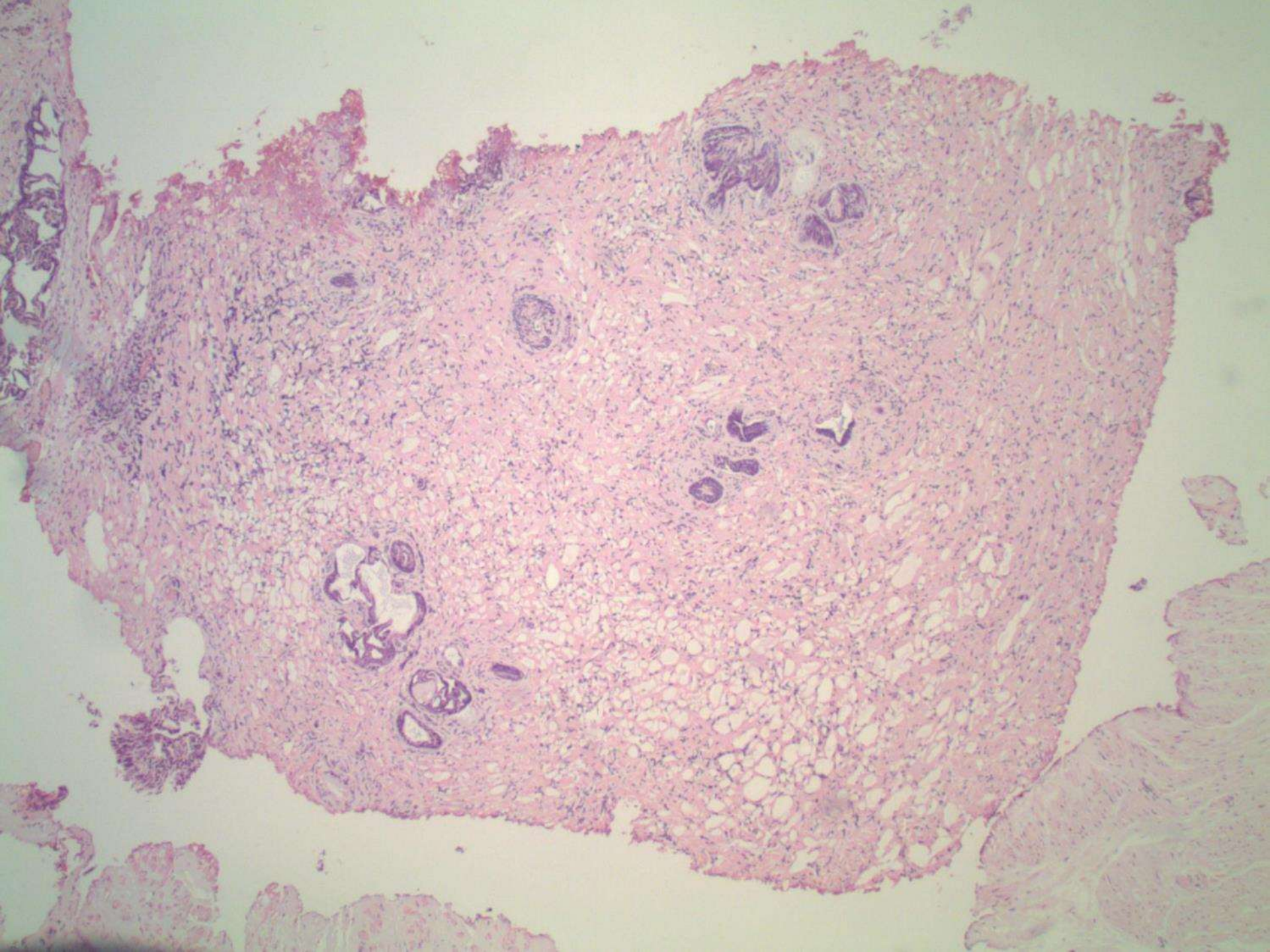


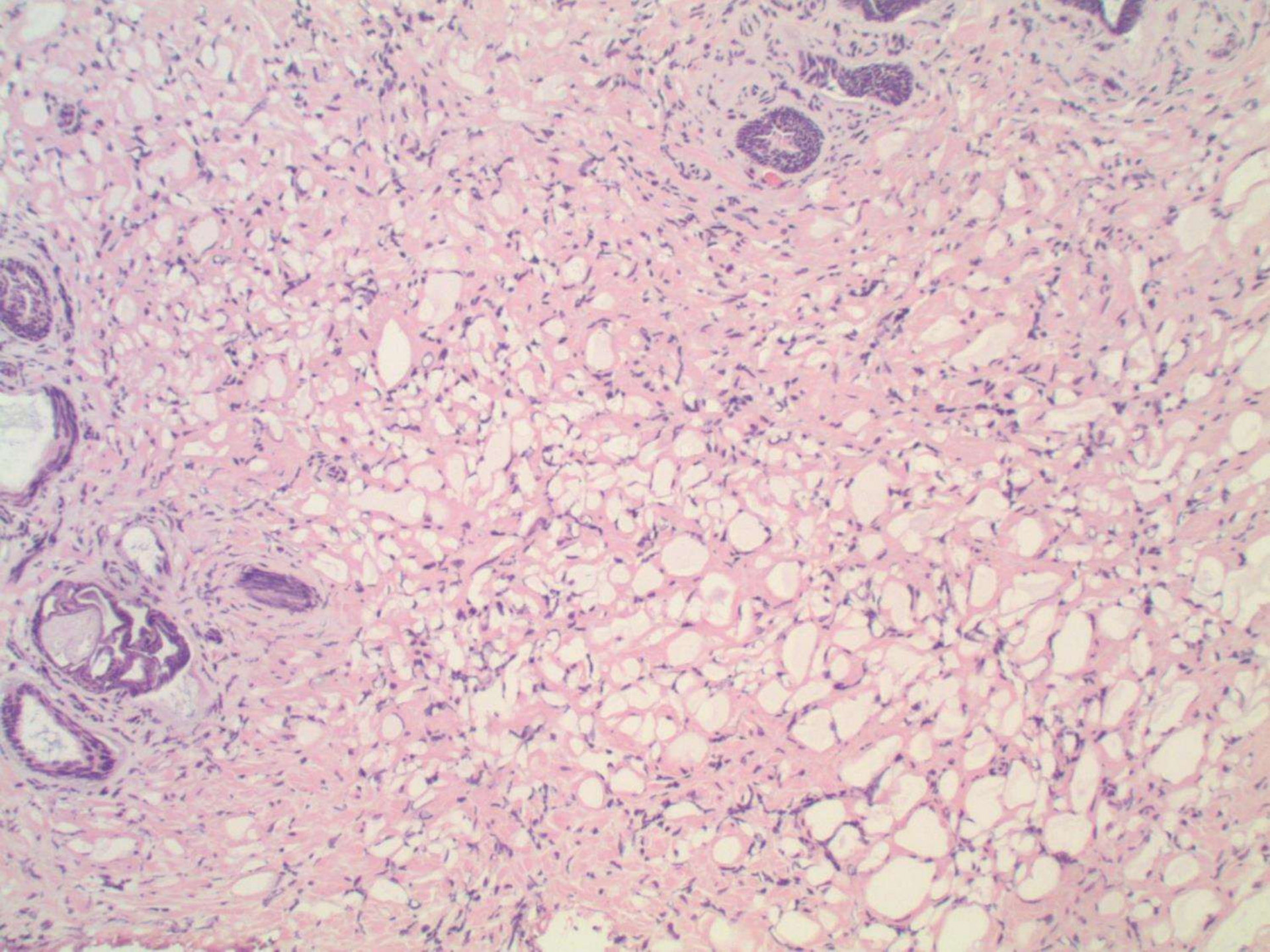


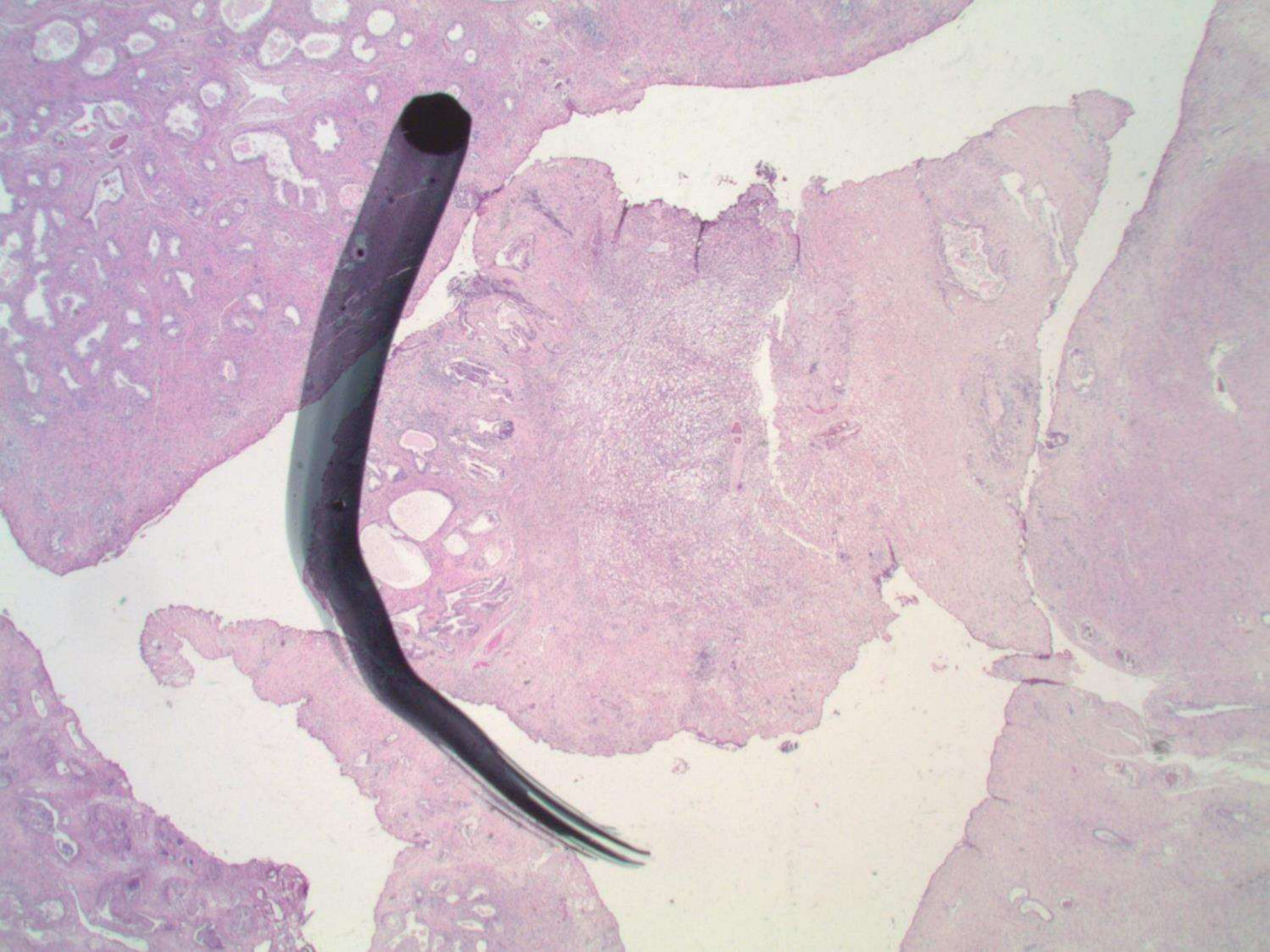

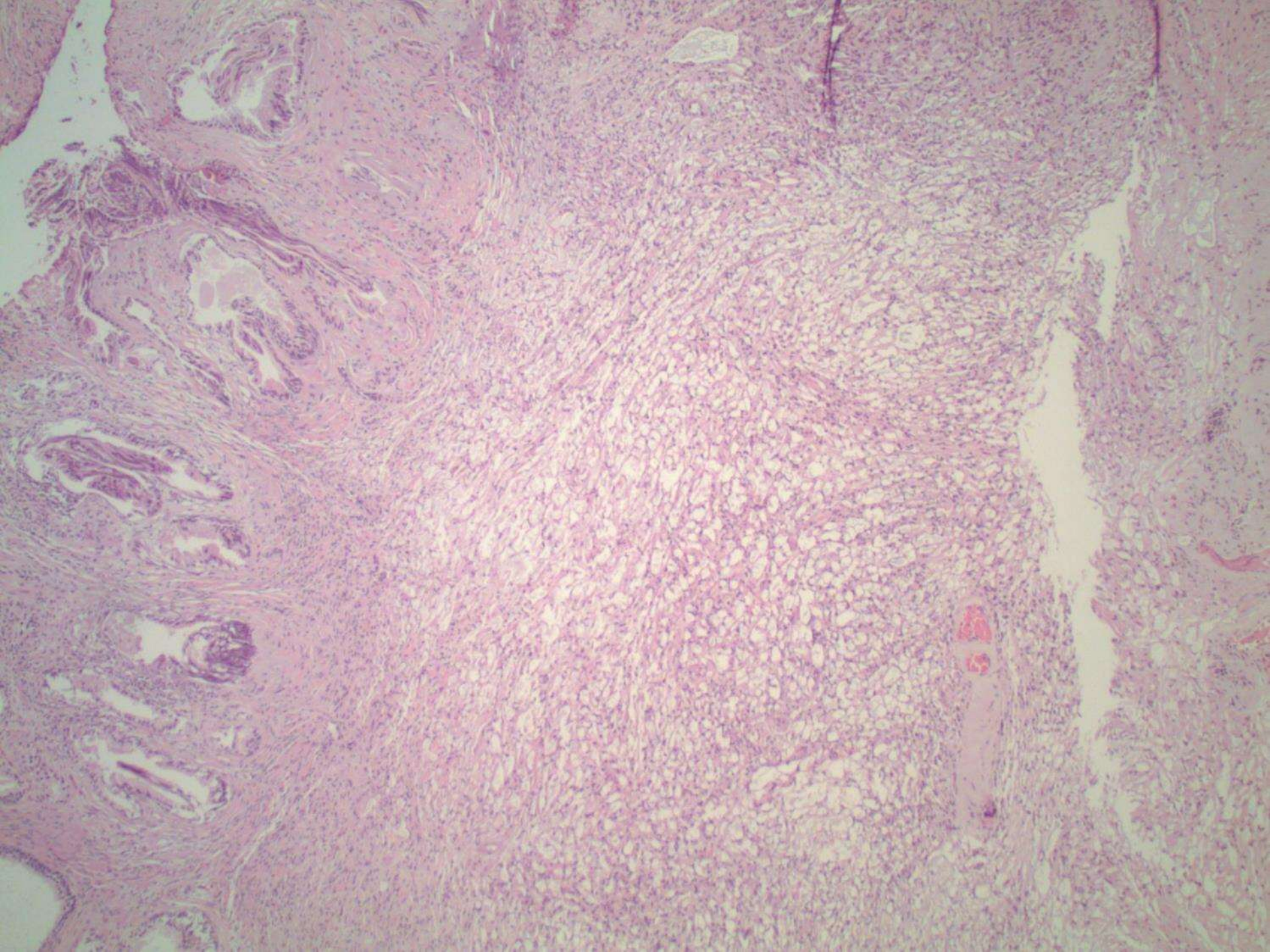


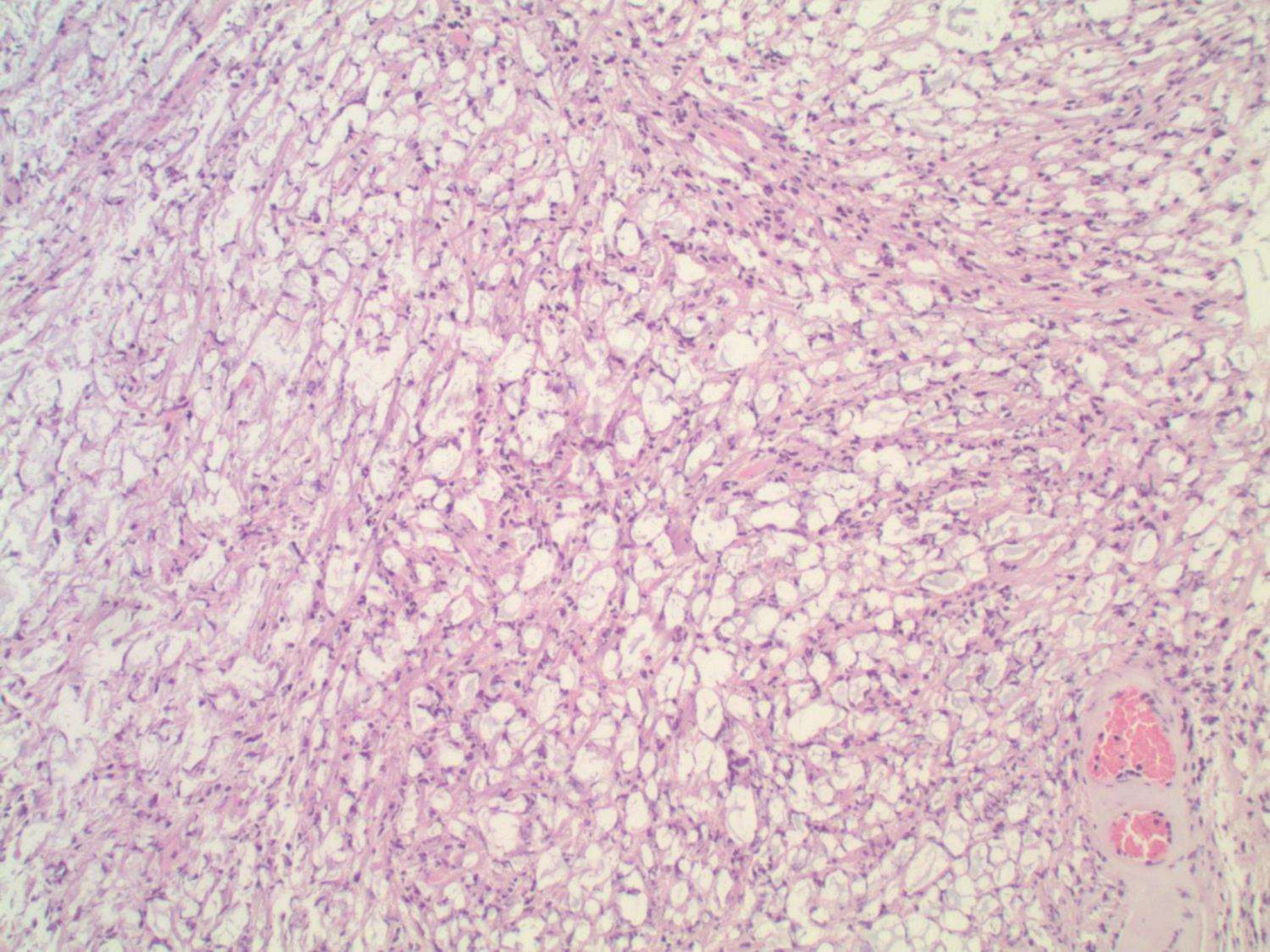


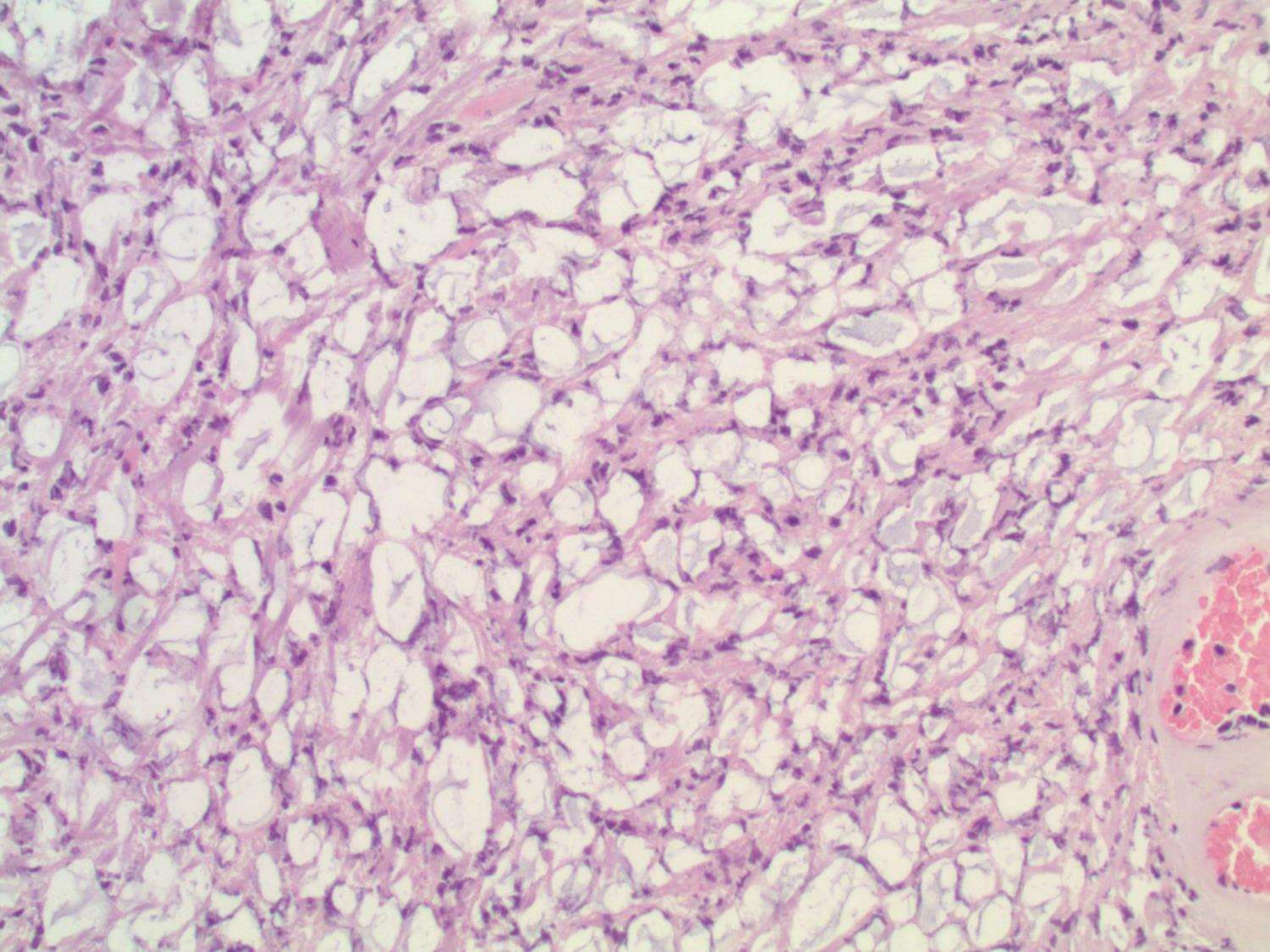


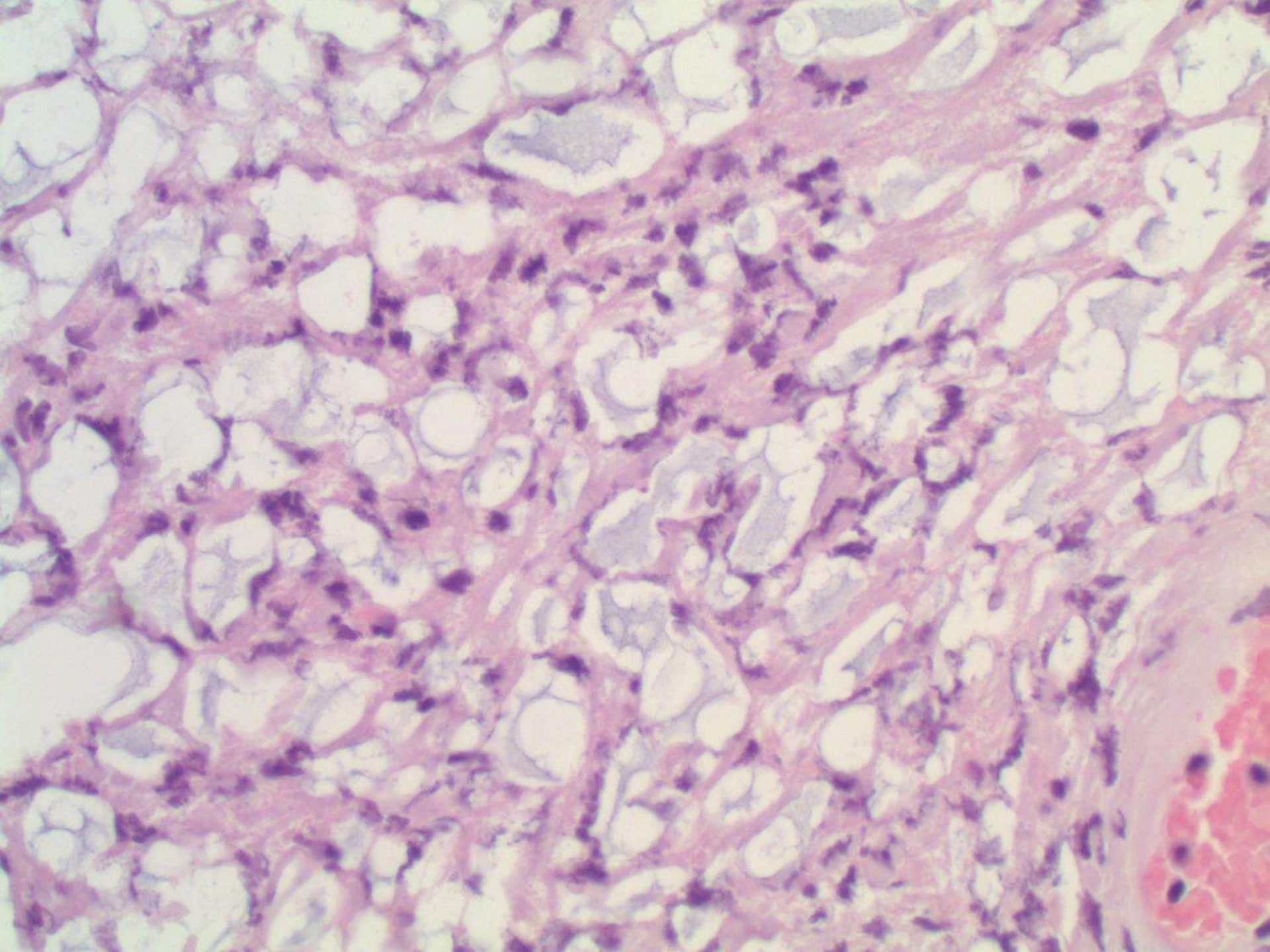












DIAGNOSIS?



EVALUATION QR CODE!
Hold smartphone camera on code

