

# Disclosures

## October 3, 2022

The planners and faculty listed below have no relevant financial relationship(s) to disclose with ineligible companies whose primary business is producing, marketing, selling, re-selling, or distributing healthcare products used by or on patients.

### **Presenters/Faculty:**

Emily Chan, MD  
Harris Goodman, MD  
Cindy Wang, MD  
Brent Tan, MD  
Jiajie (George) Lu, MD  
**Serena Tan, MD**  
Andrew Xiao, MD  
**Chris Schwartz, MD**  
Steve Long, MD  
Dave Bingham, MD

### **Activity Planners/Moderator:**

Kristin Jensen, MD  
Megan Troxell, MD  
Ankur Sangoi, MD

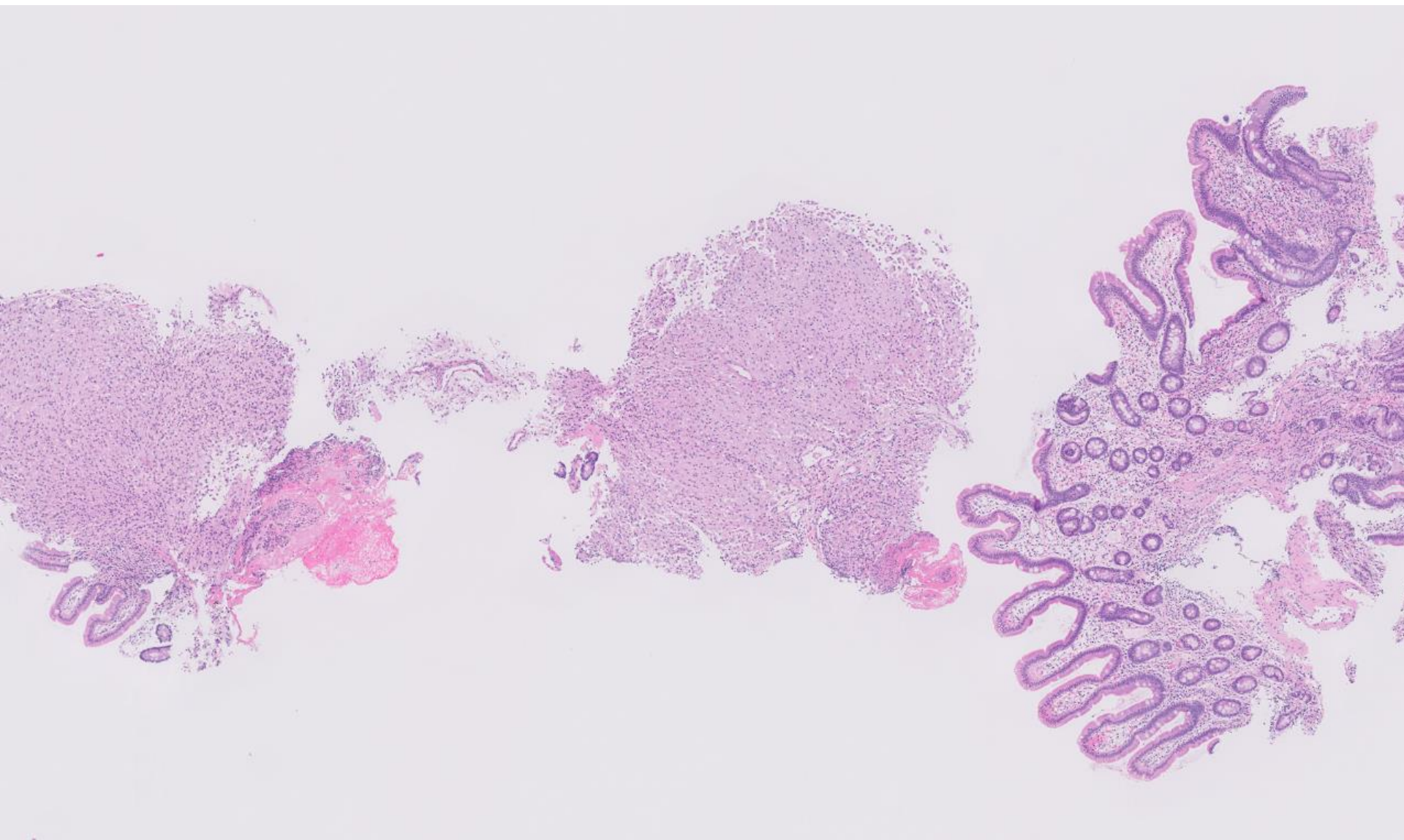
QR code for post-meeting evaluation form

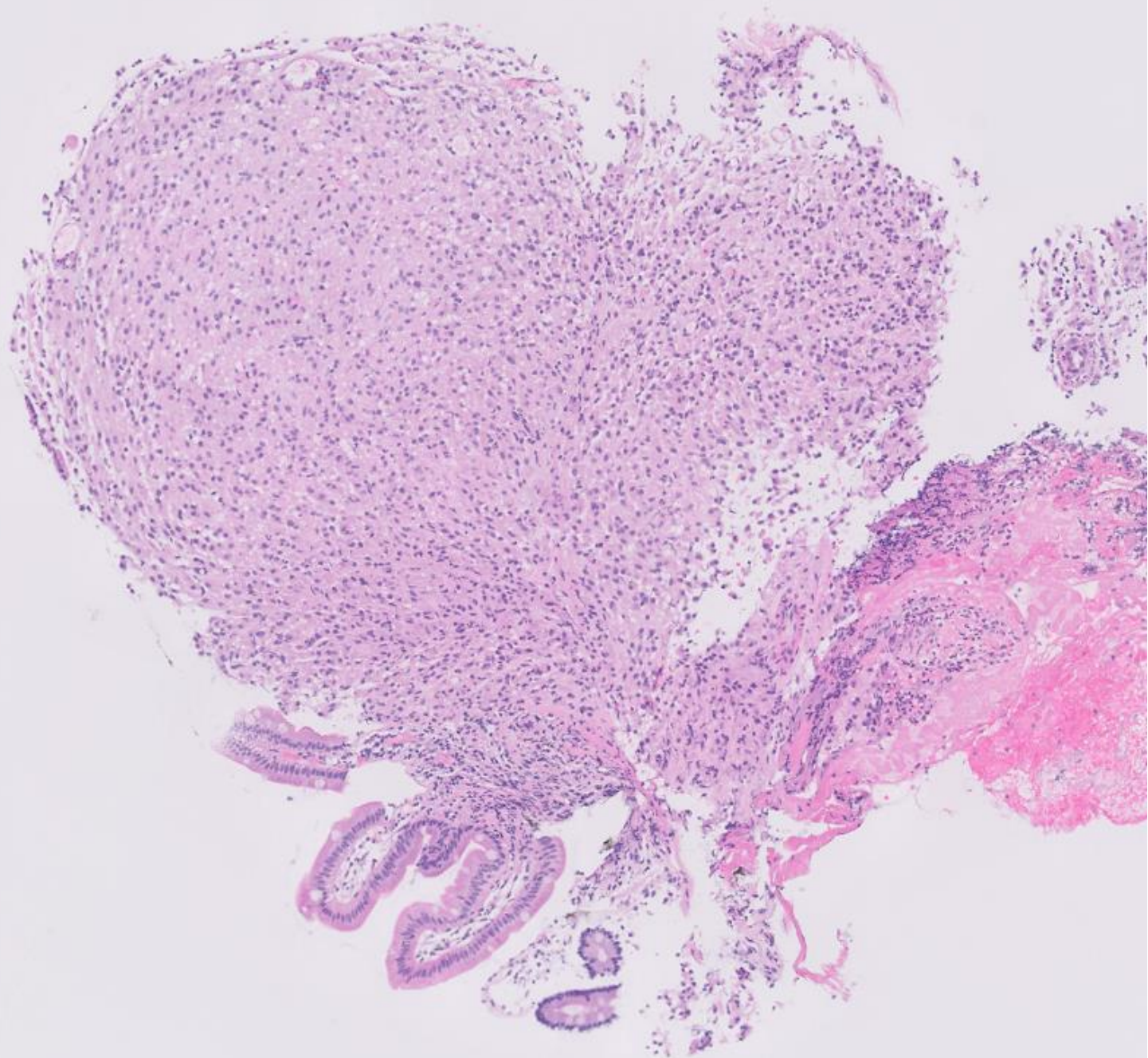


22-1001

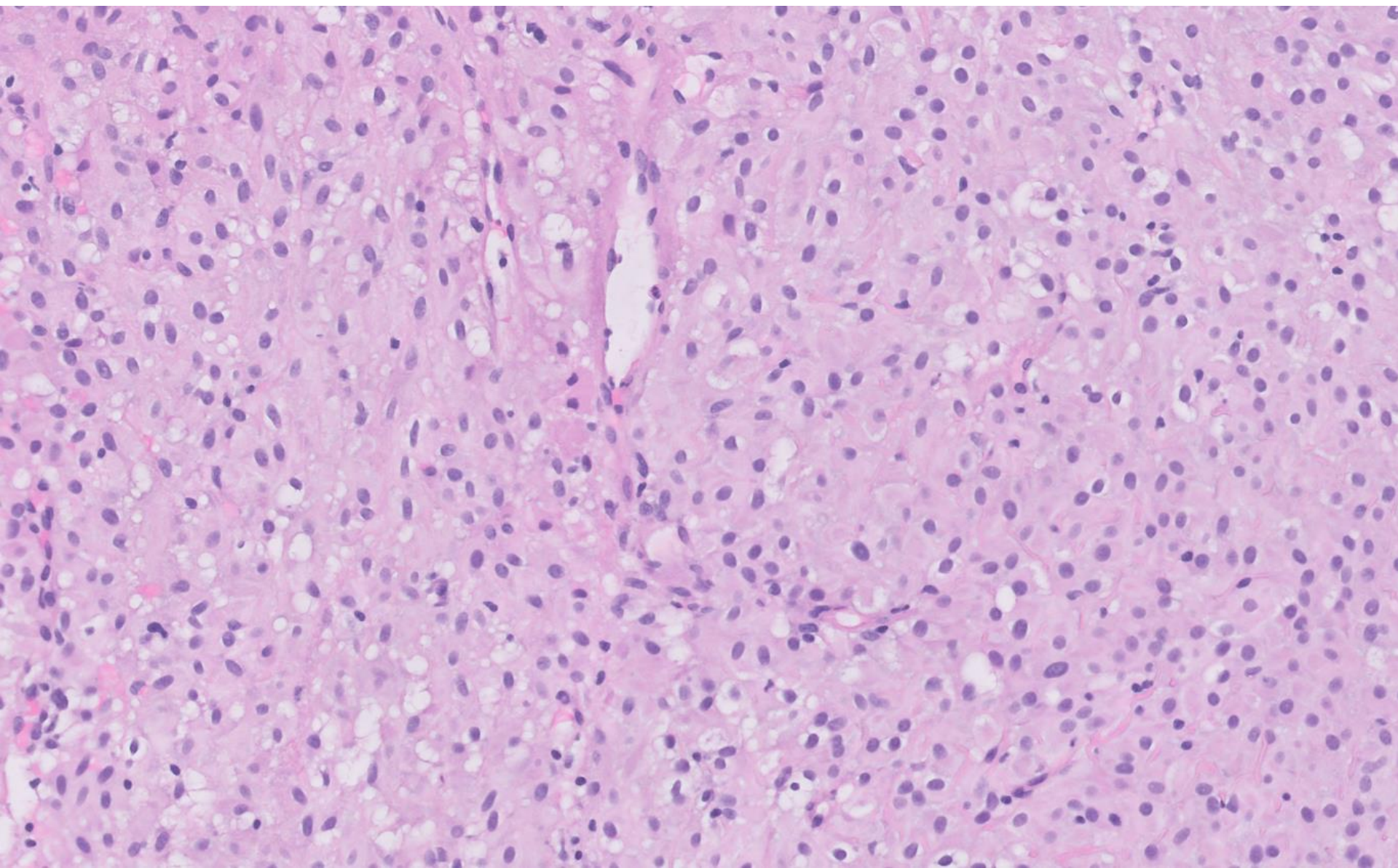
**Cindy Wang; Stanford**

Adult with jejunal lesion, resected.









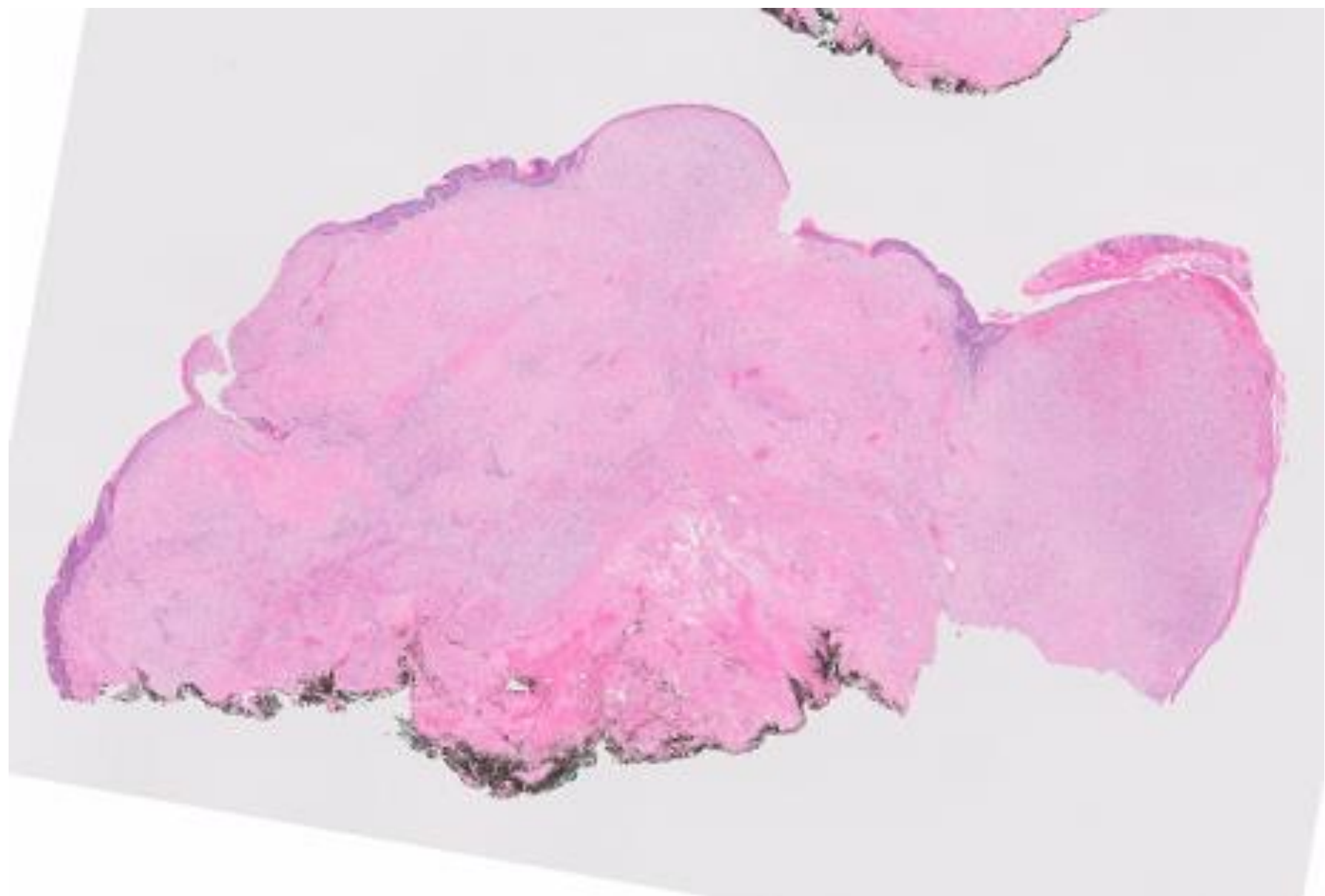
# DIAGNOSIS?



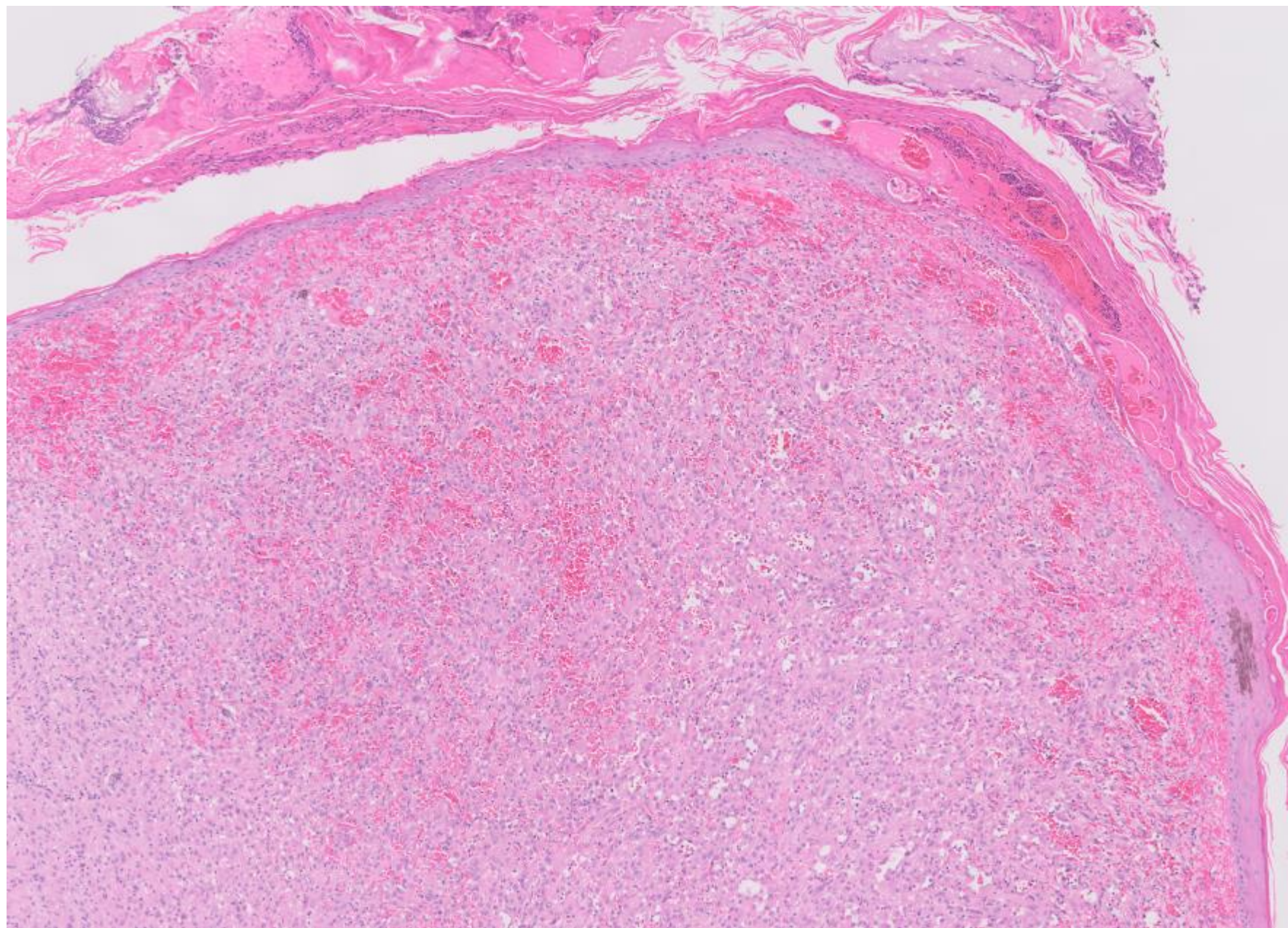
22-1002

**Emily Chan; UCSF**

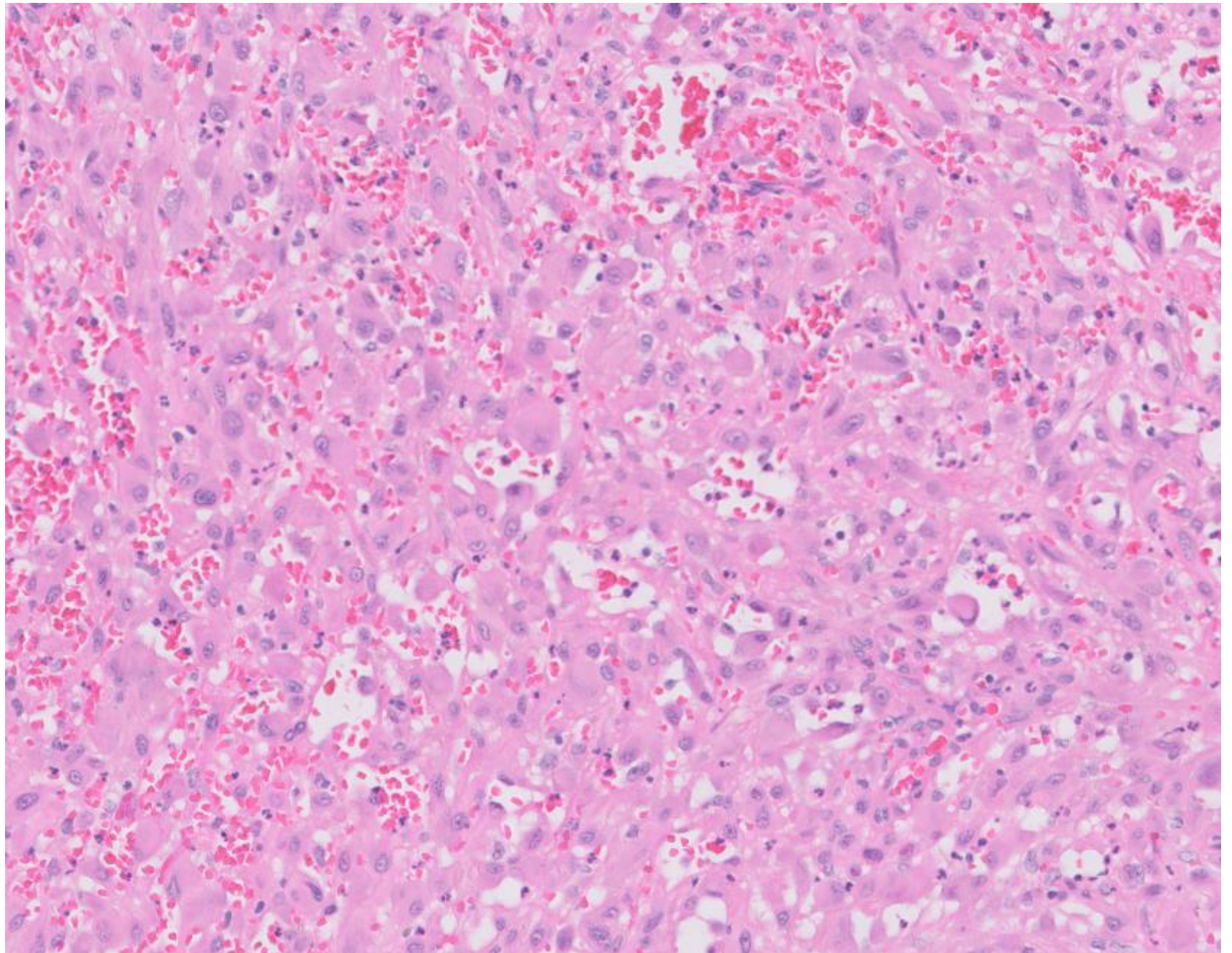
20ish M with multiple penile lesions, excisional biopsy performed.



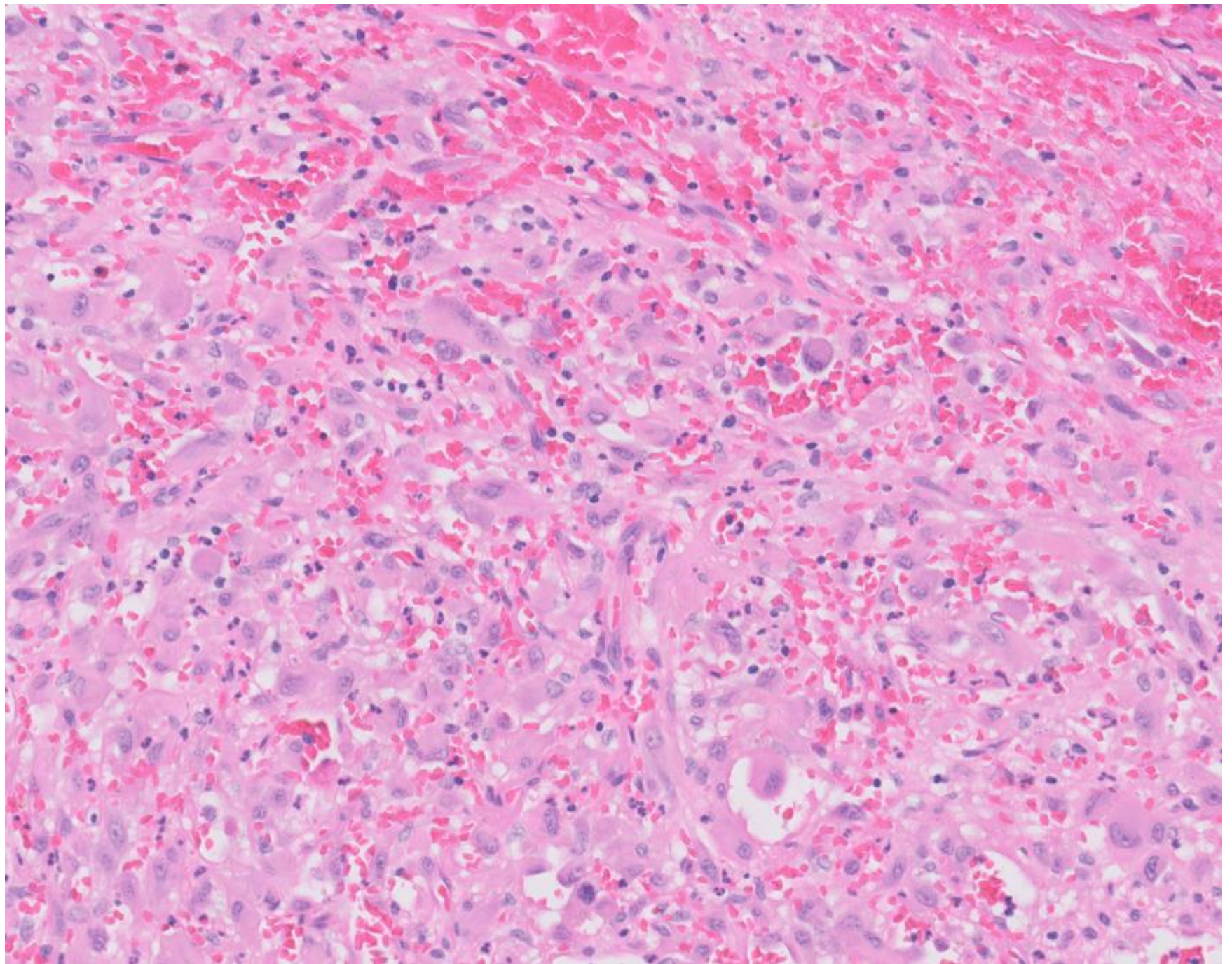




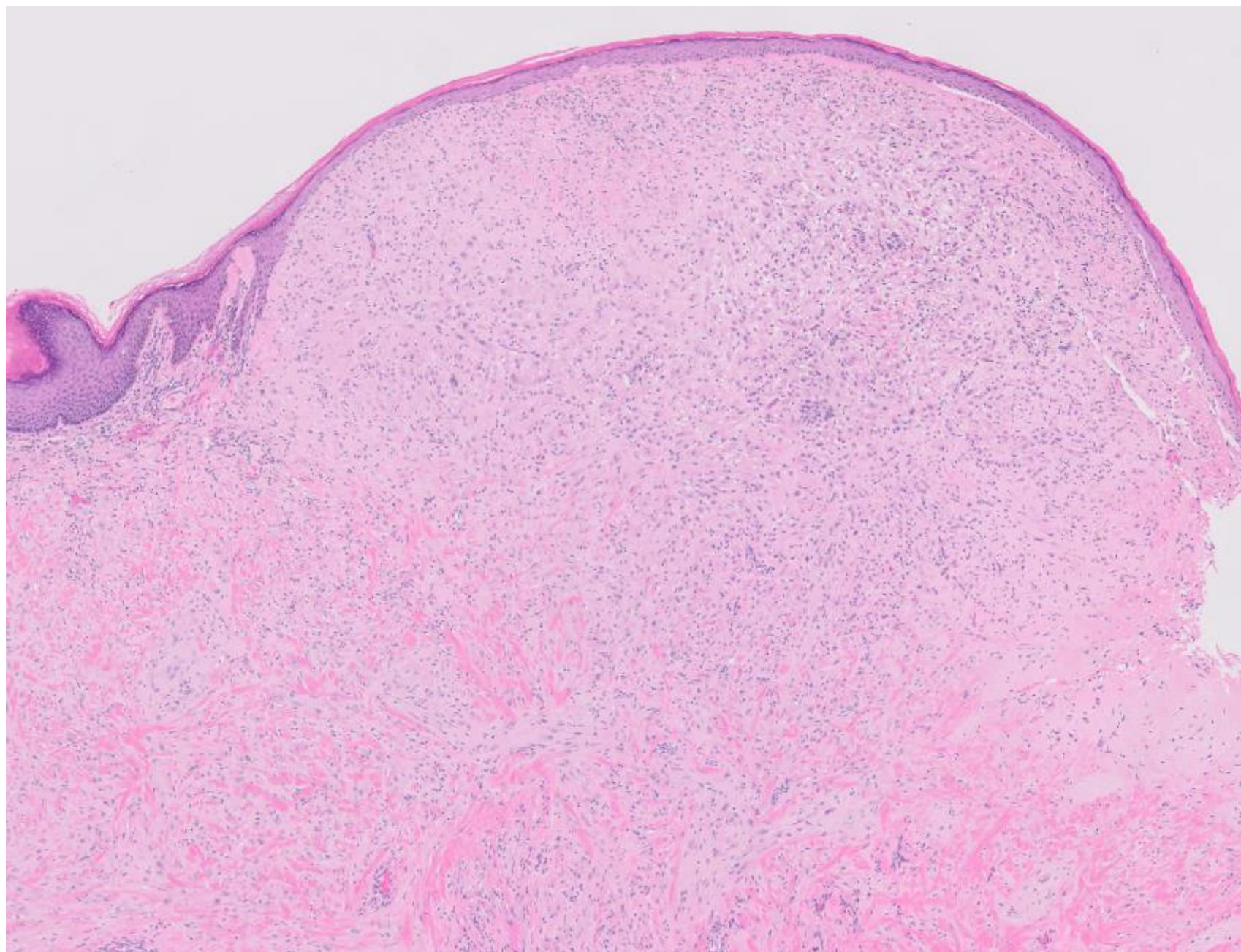




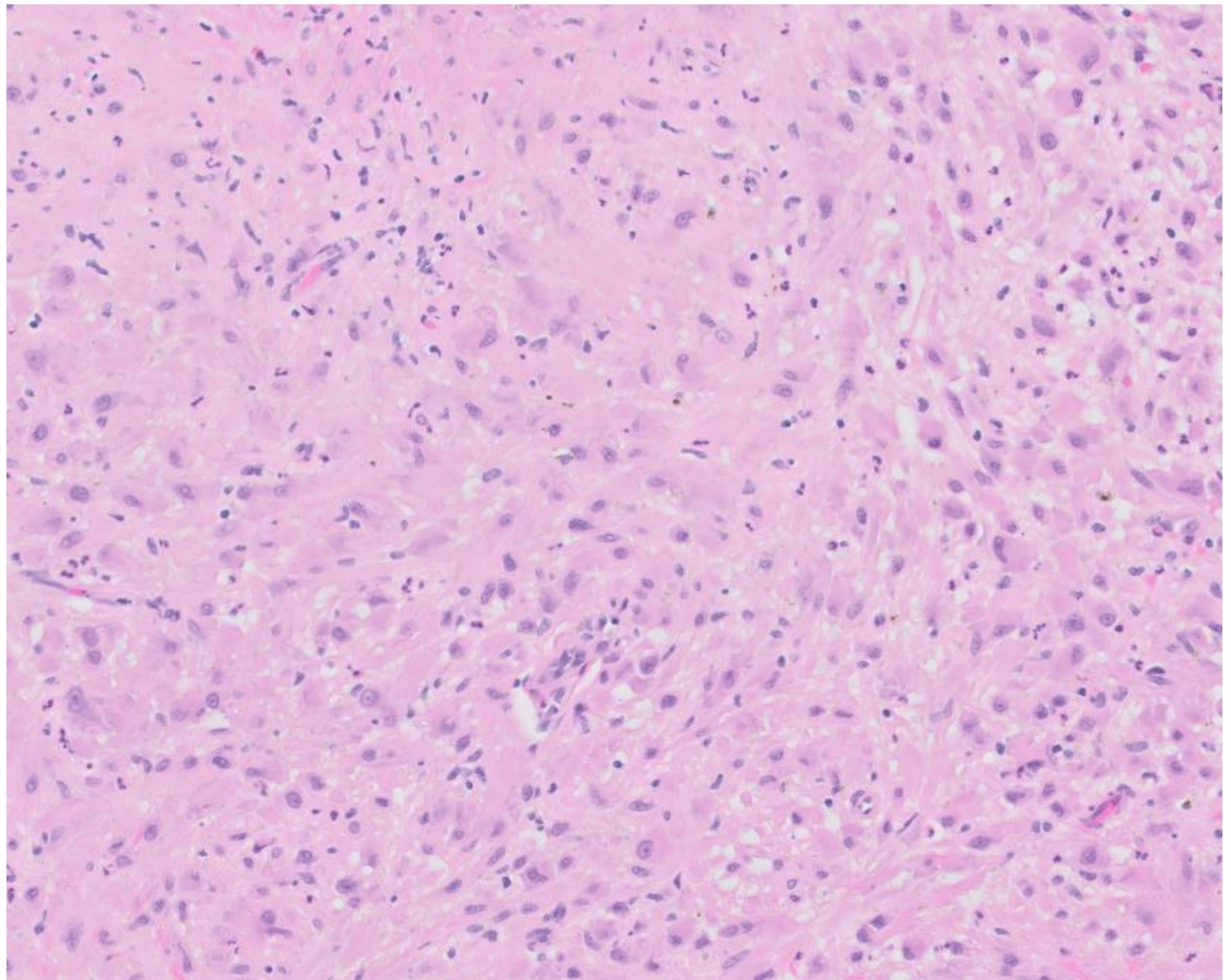


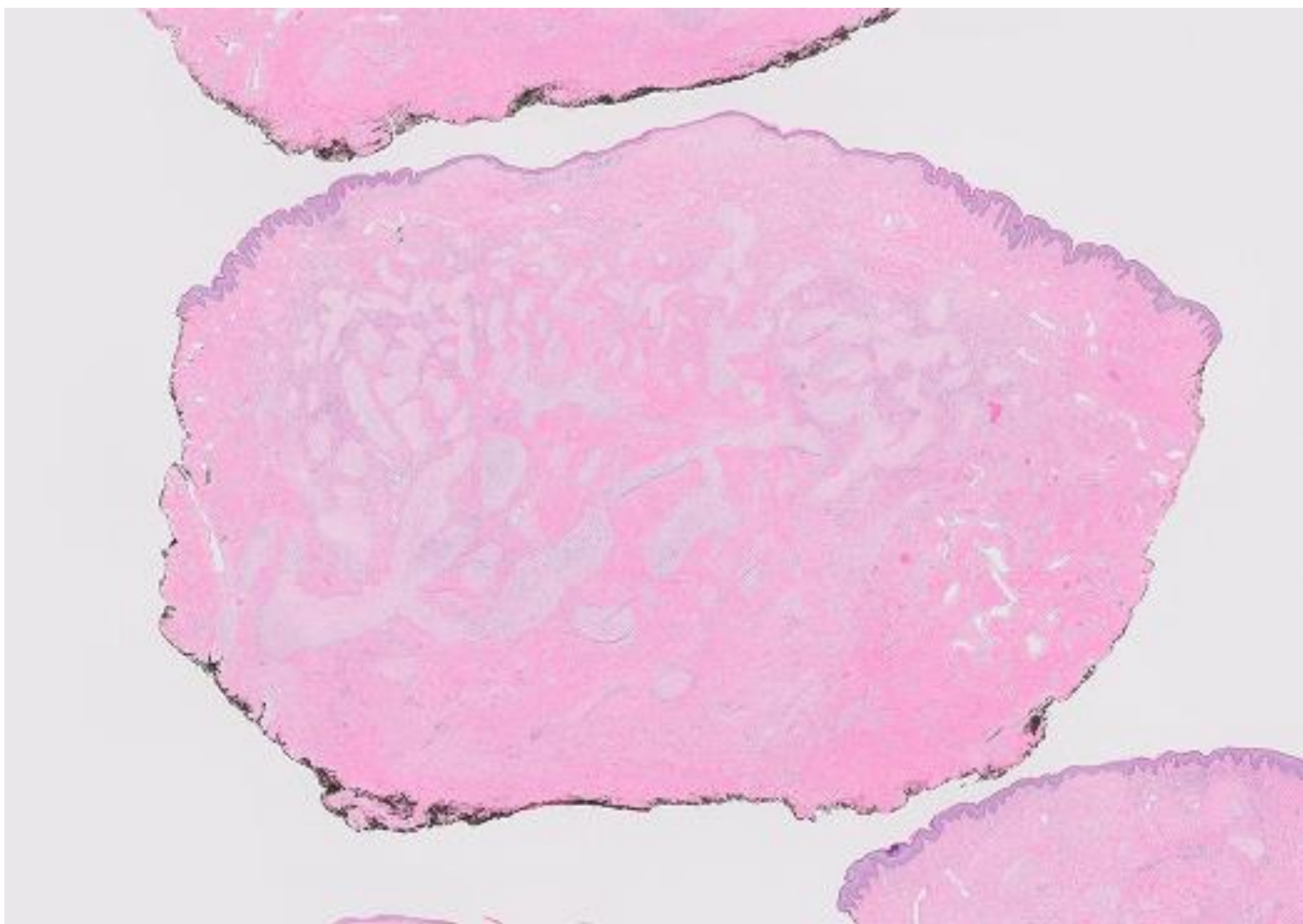




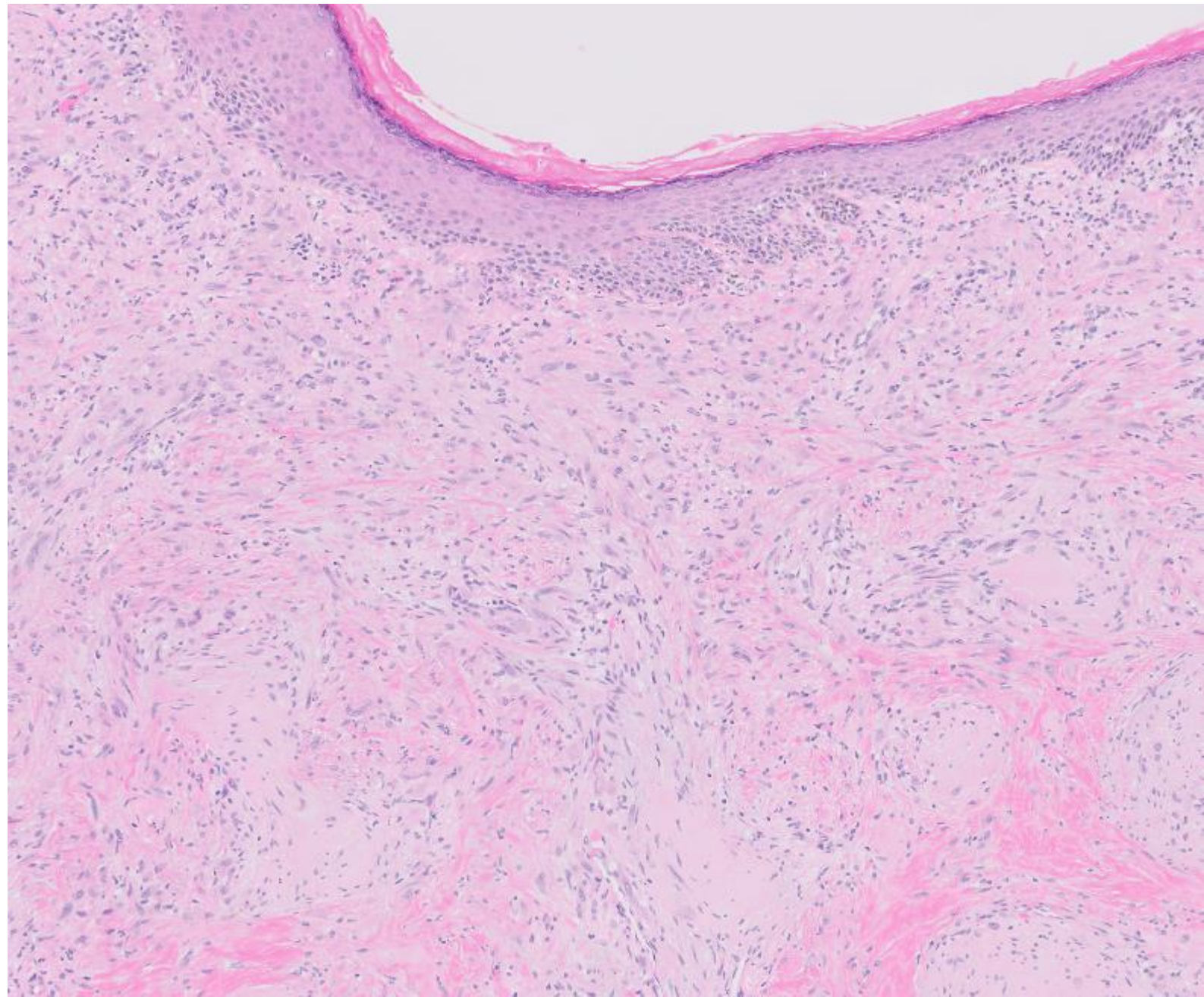




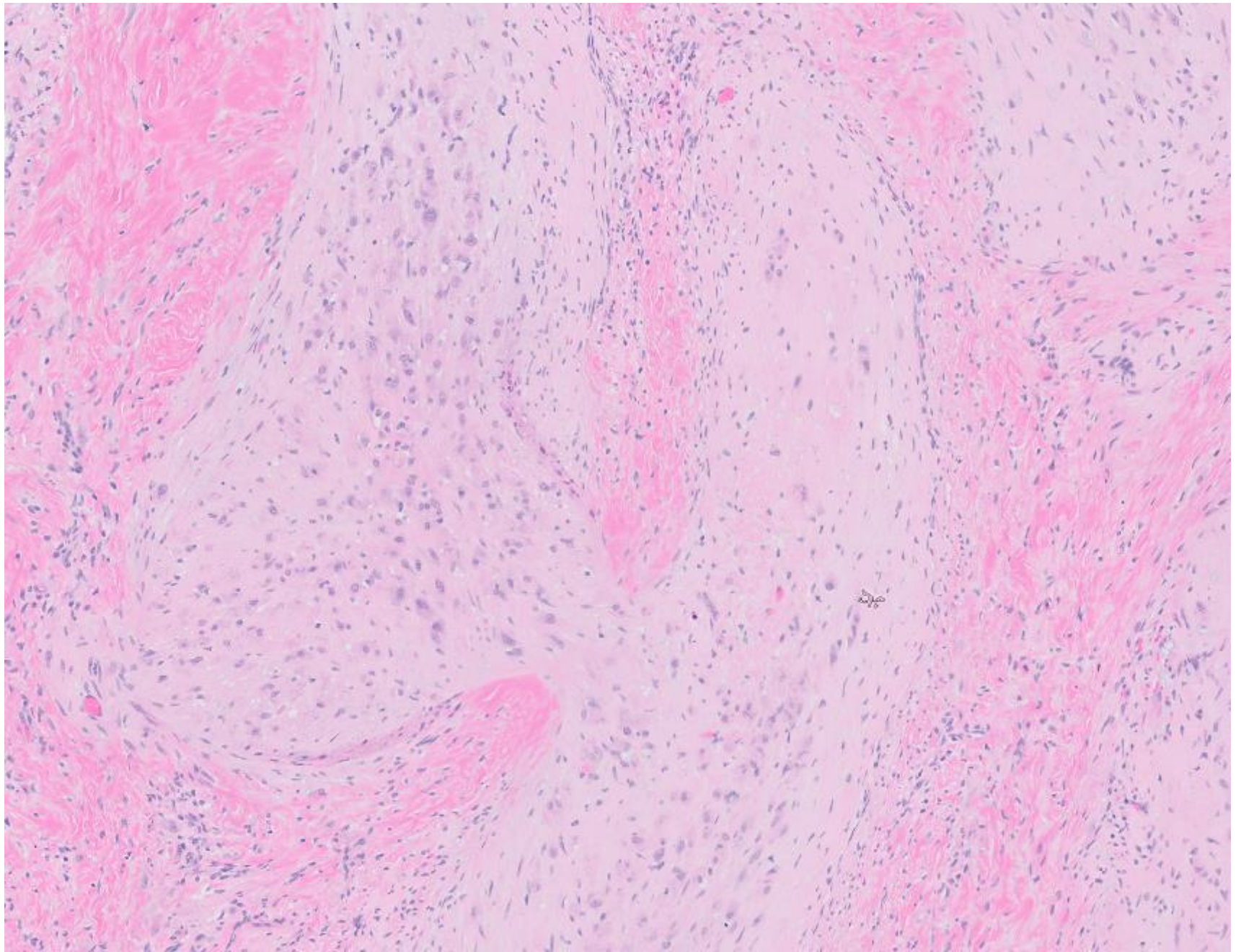




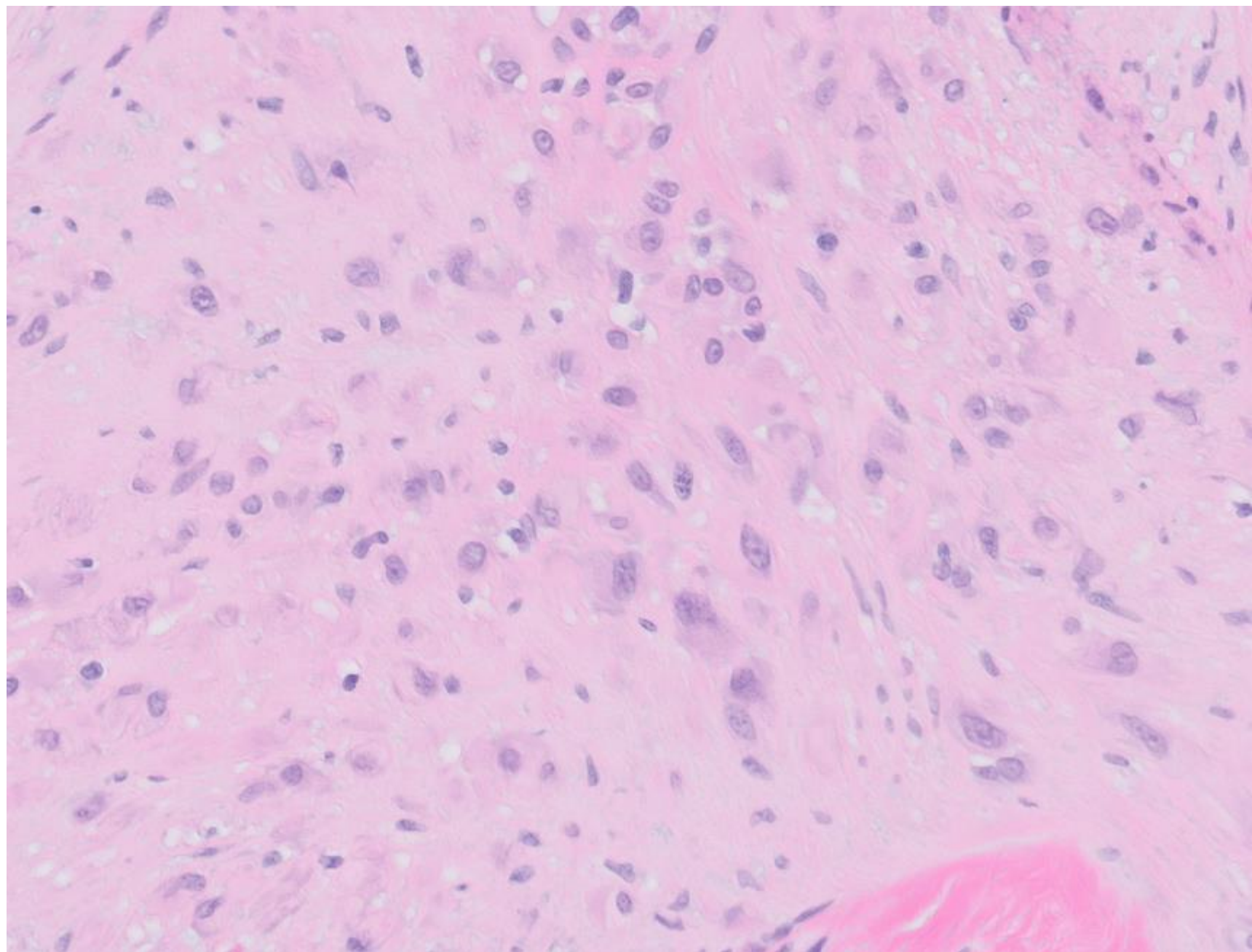




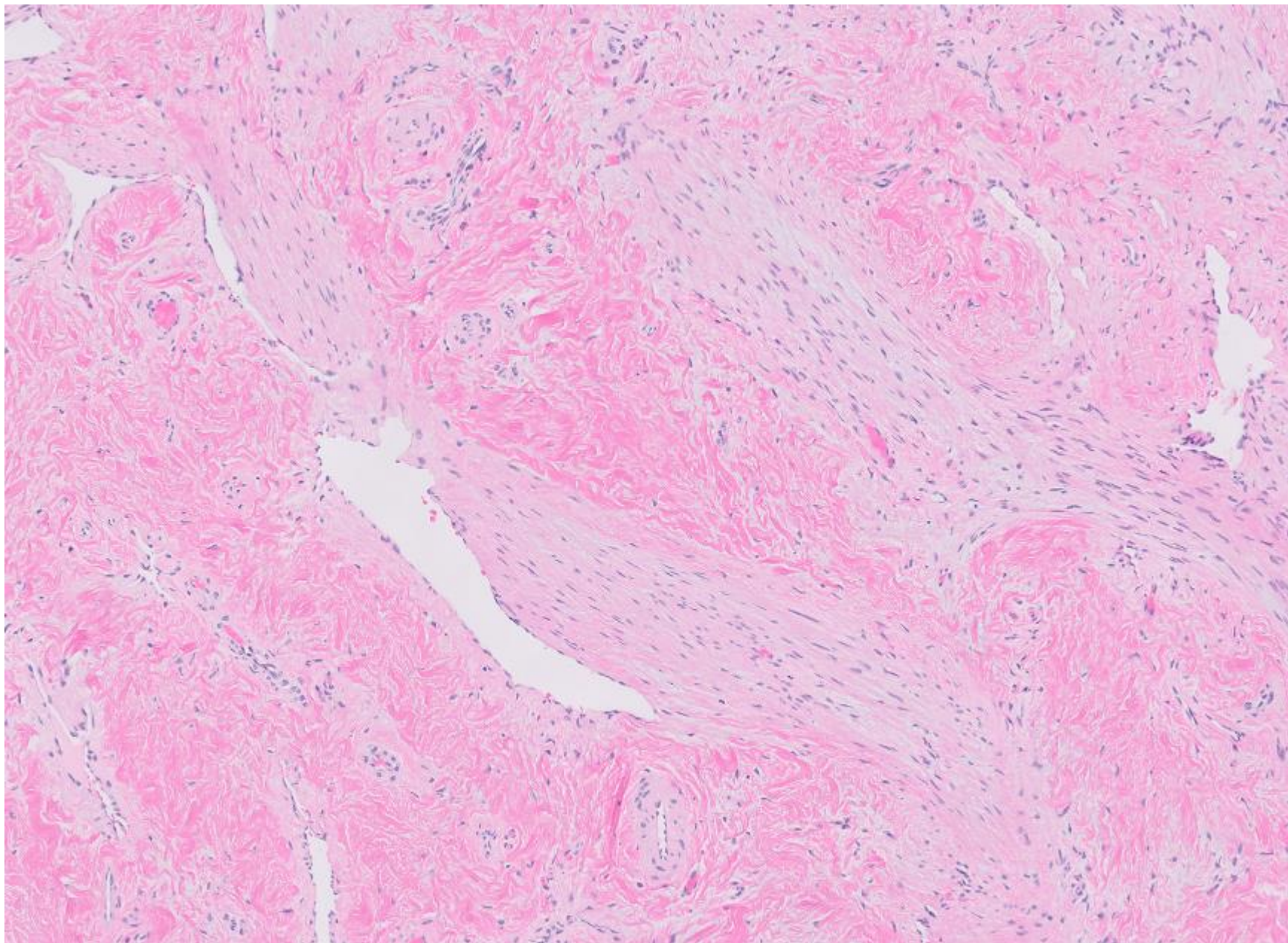






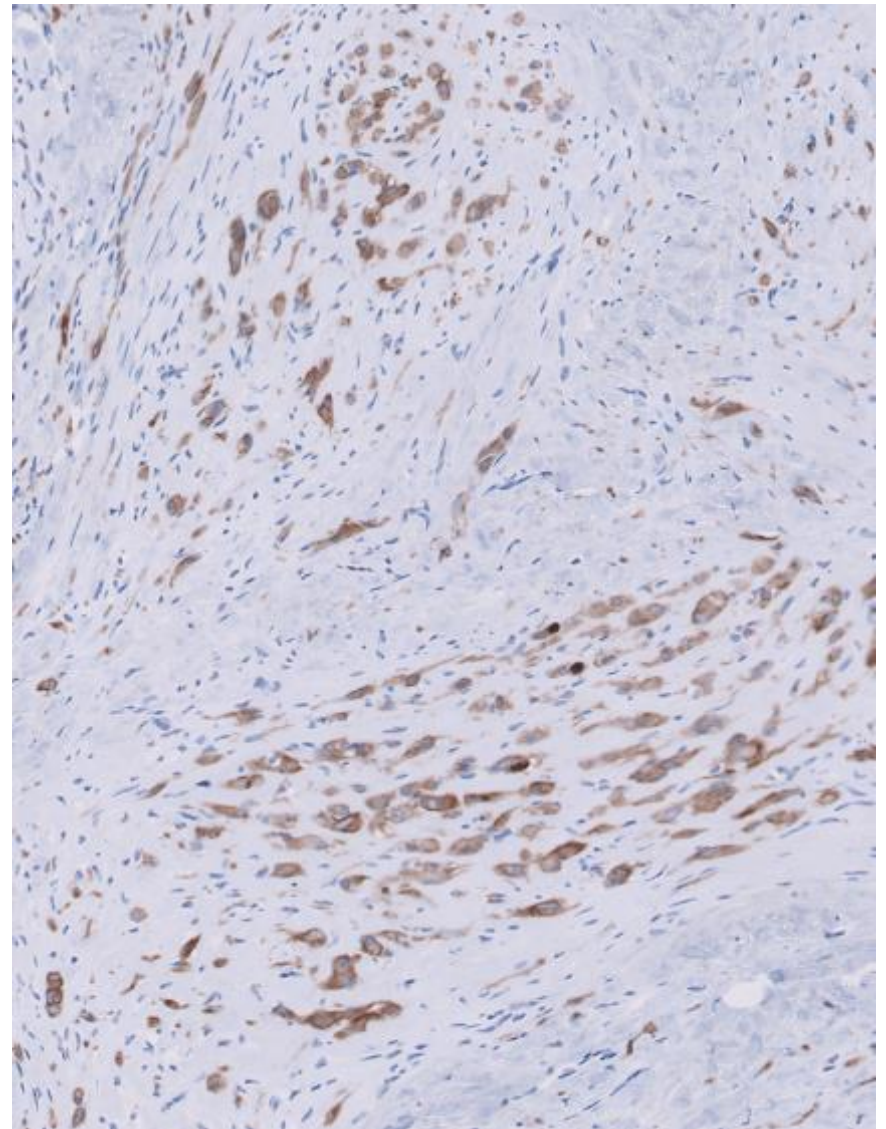
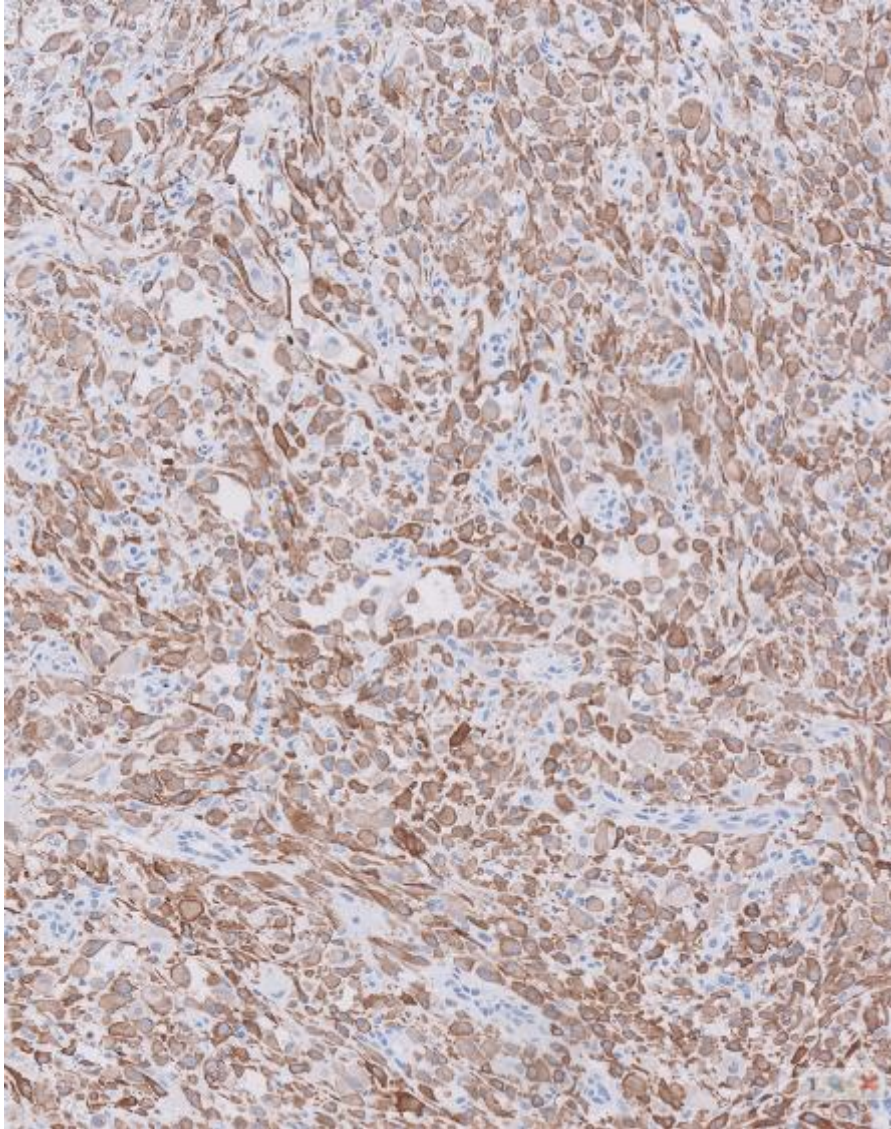






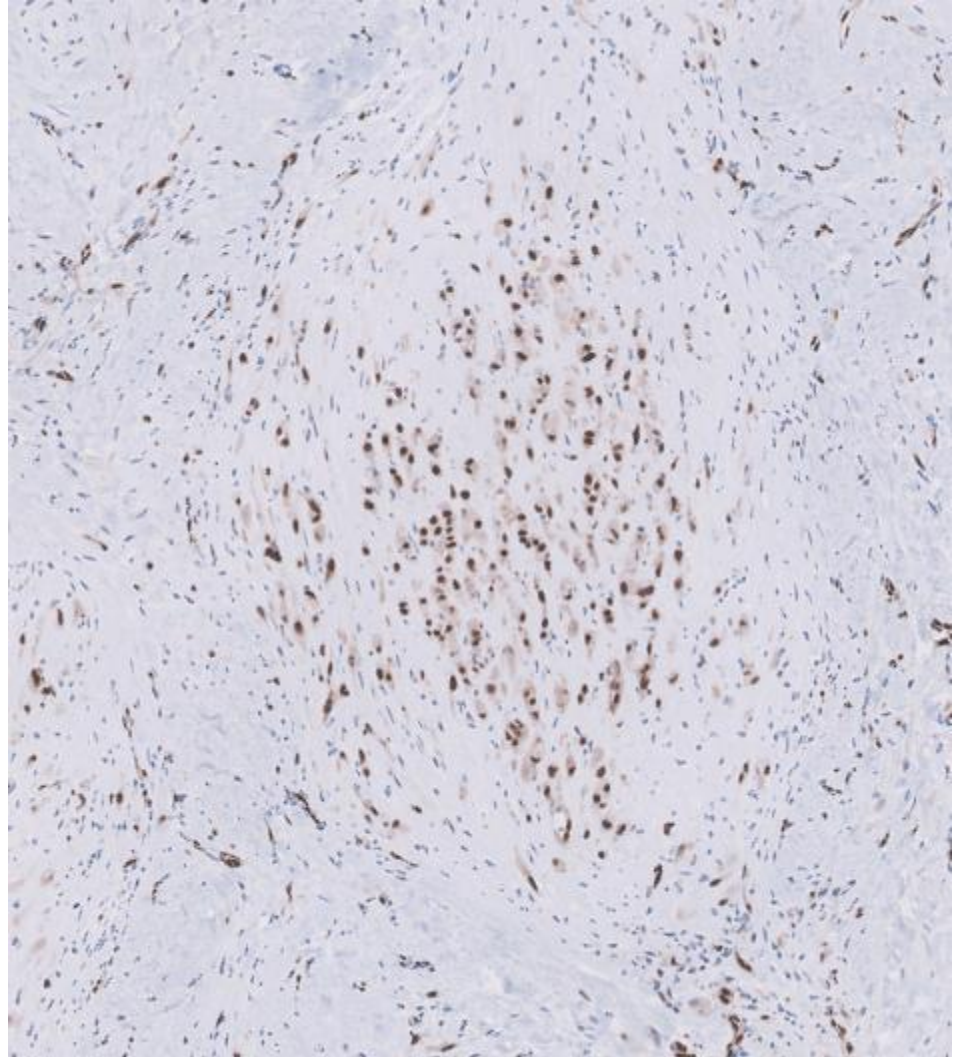
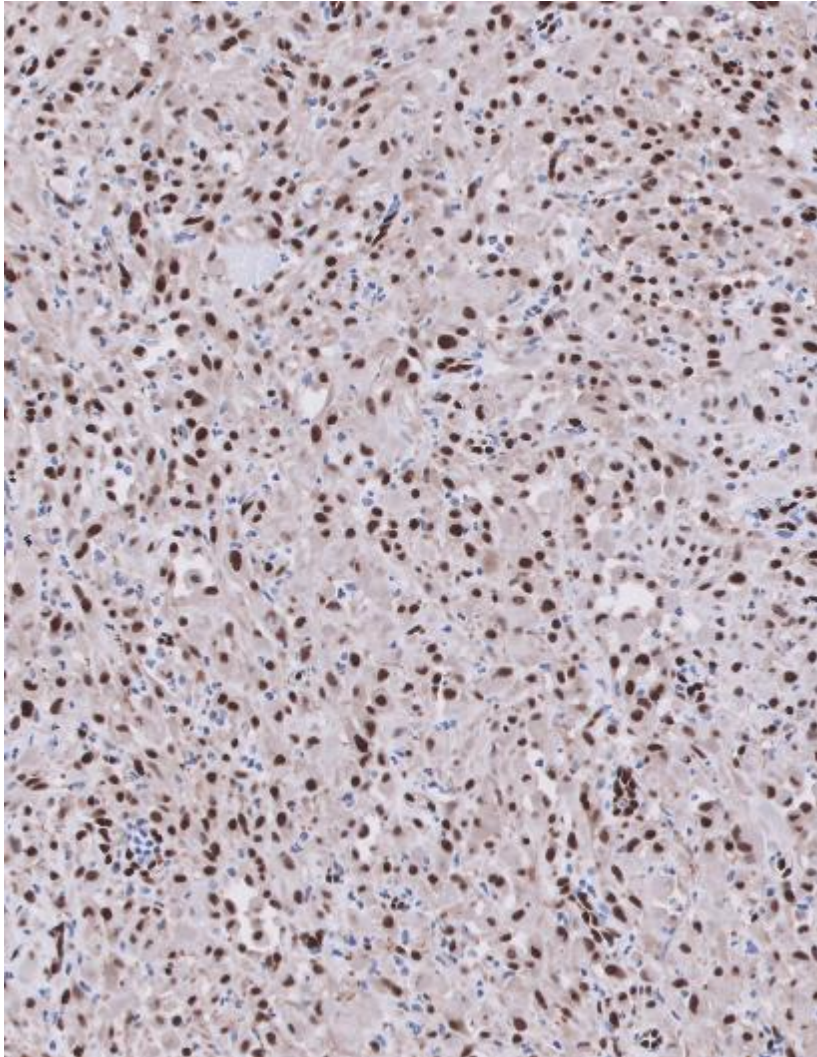


# Pankeratin





# Erg





22-1003

**Brent Tan; Stanford**

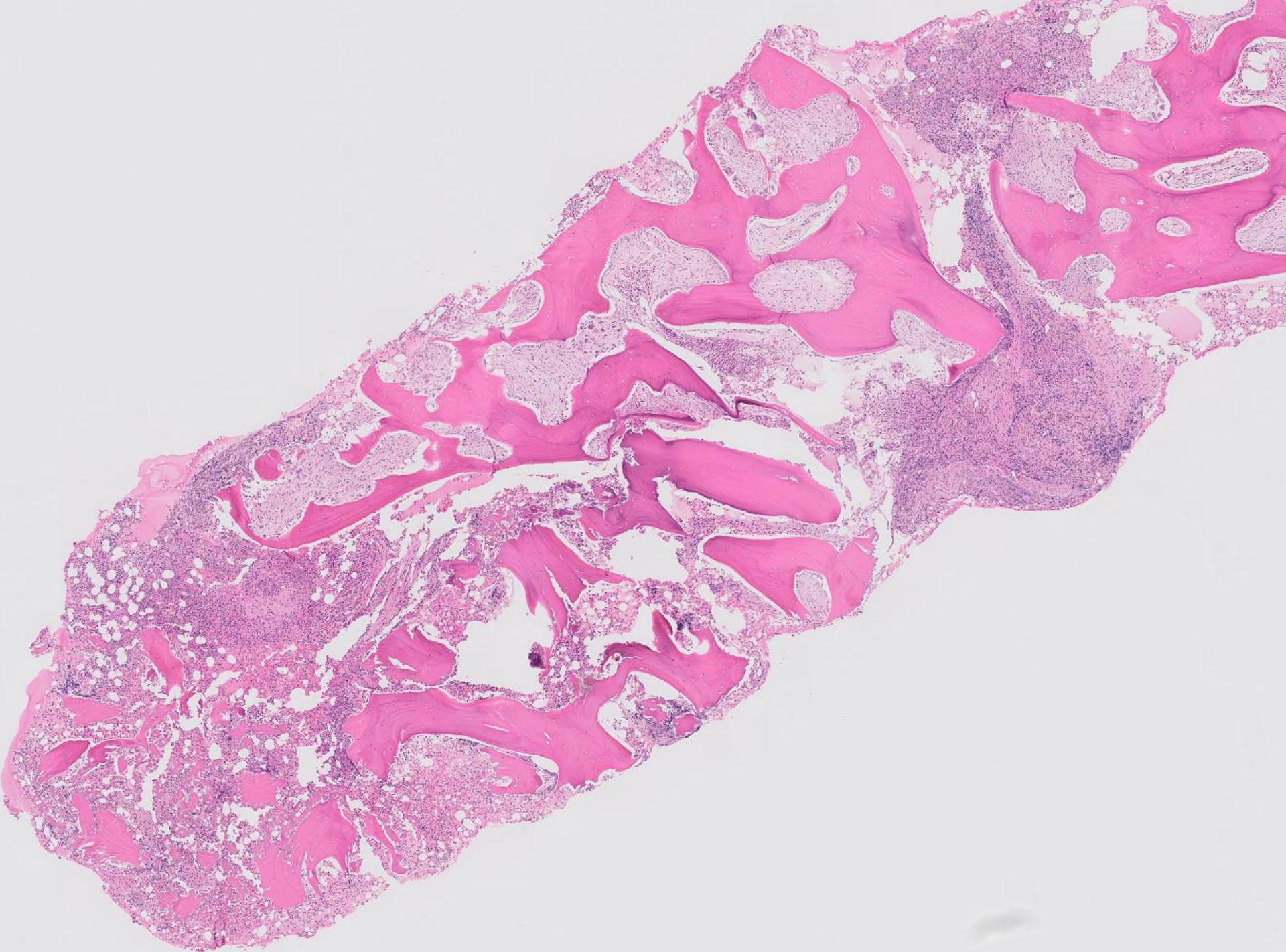
40ish M with pathologic left femur fracture, multiple lytic bone lesions throughout skeleton. Prior hip biopsy showed a giant cell rich lesion.  
Bone marrow biopsy performed.

# Clinical history

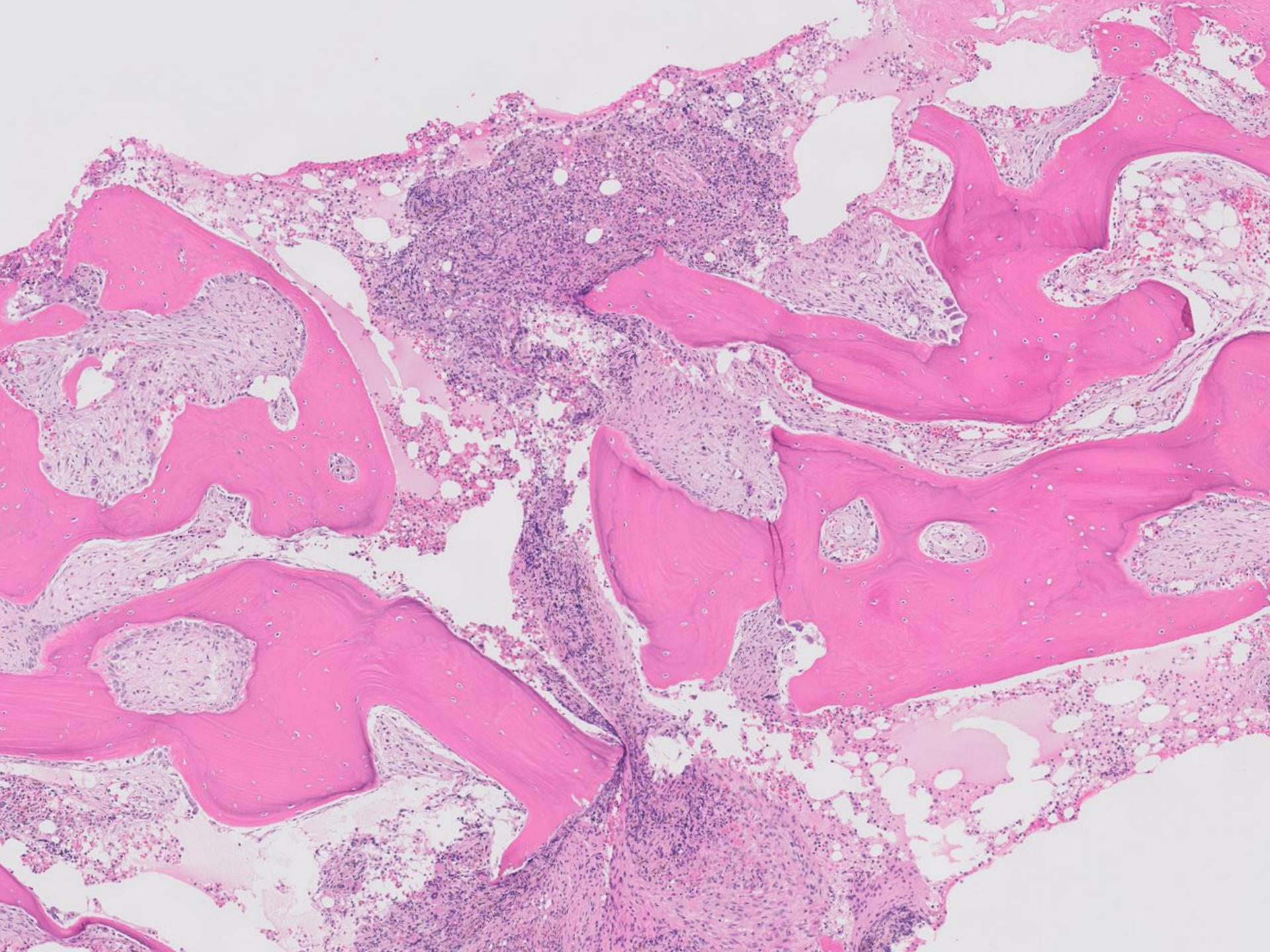
A 40ish man with a history of end-stage renal disease presented with hip pain and was found on imaging to have a pathologic left femur fracture and multiple lytic bone lesions throughout skeleton.

A prior hip biopsy showed a giant cell rich lesion.

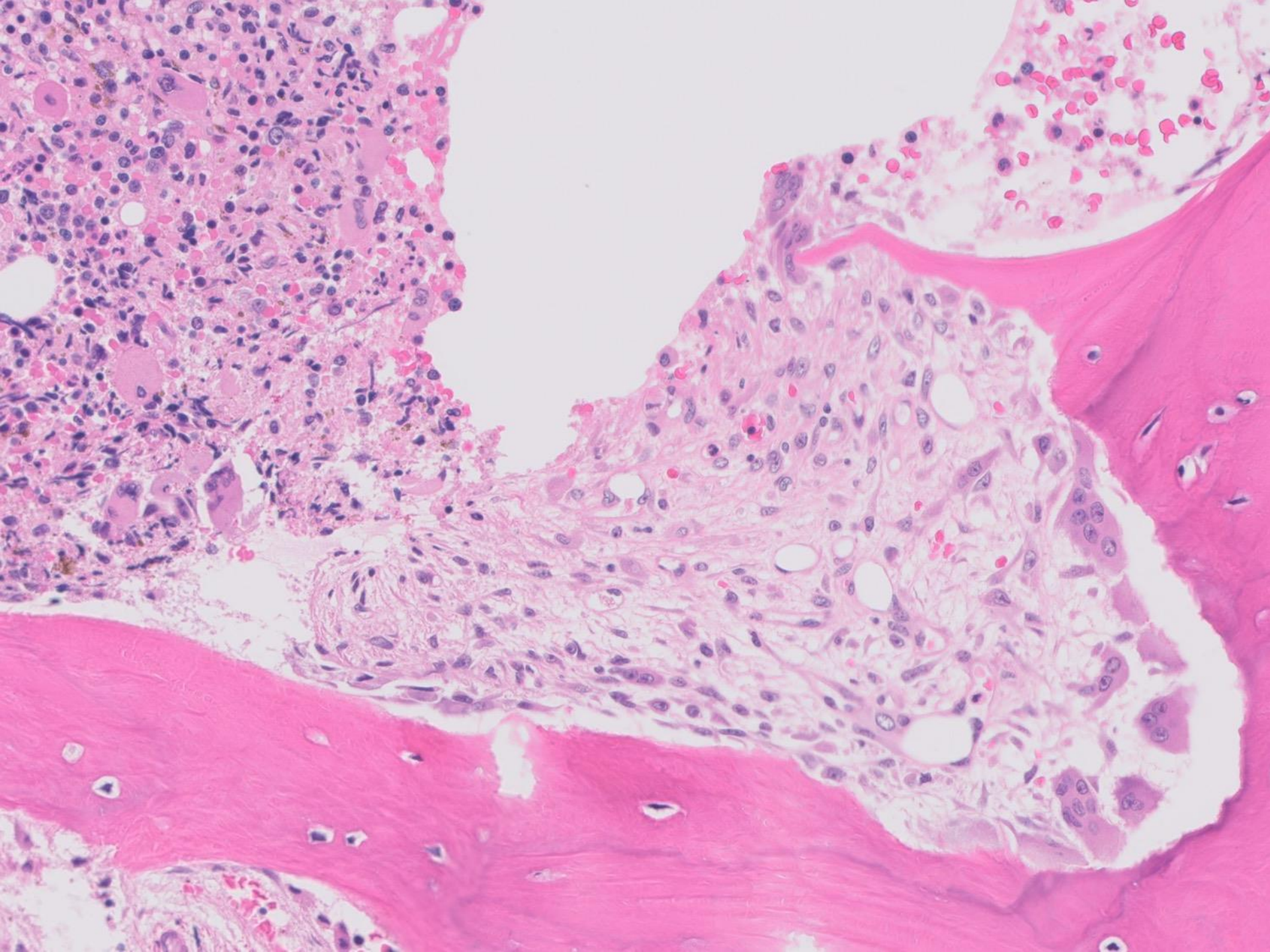
A bone marrow biopsy was performed.



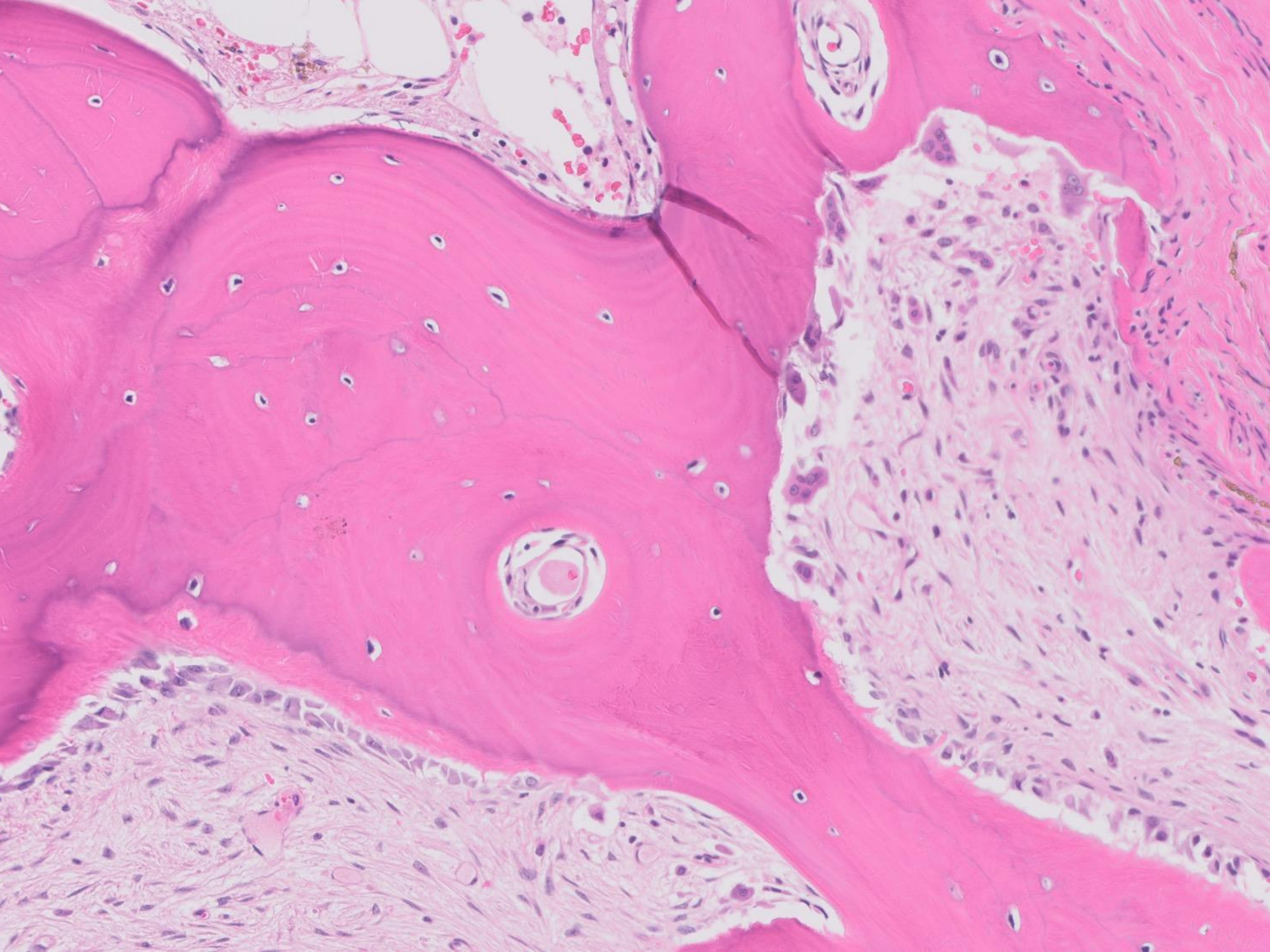




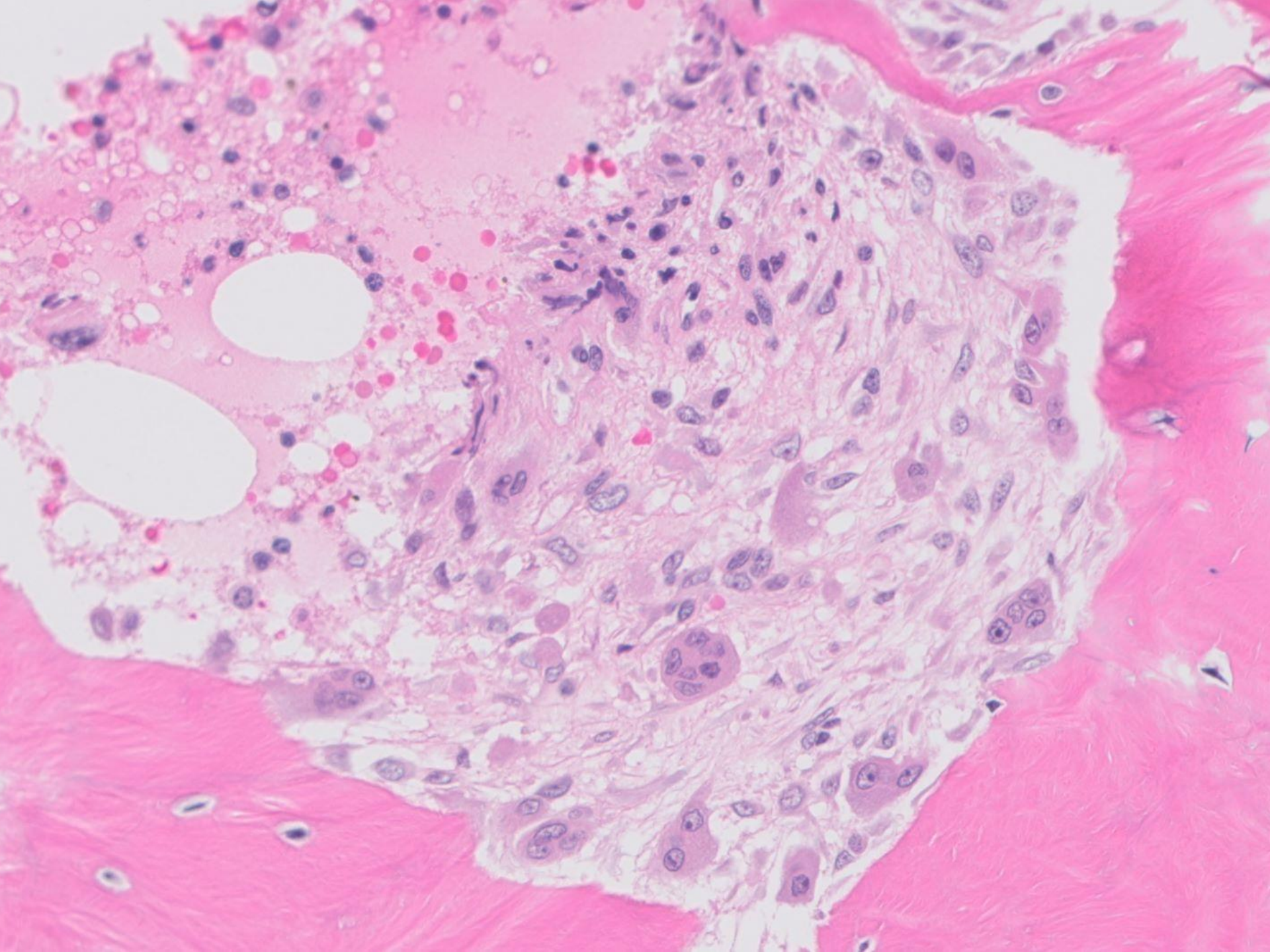






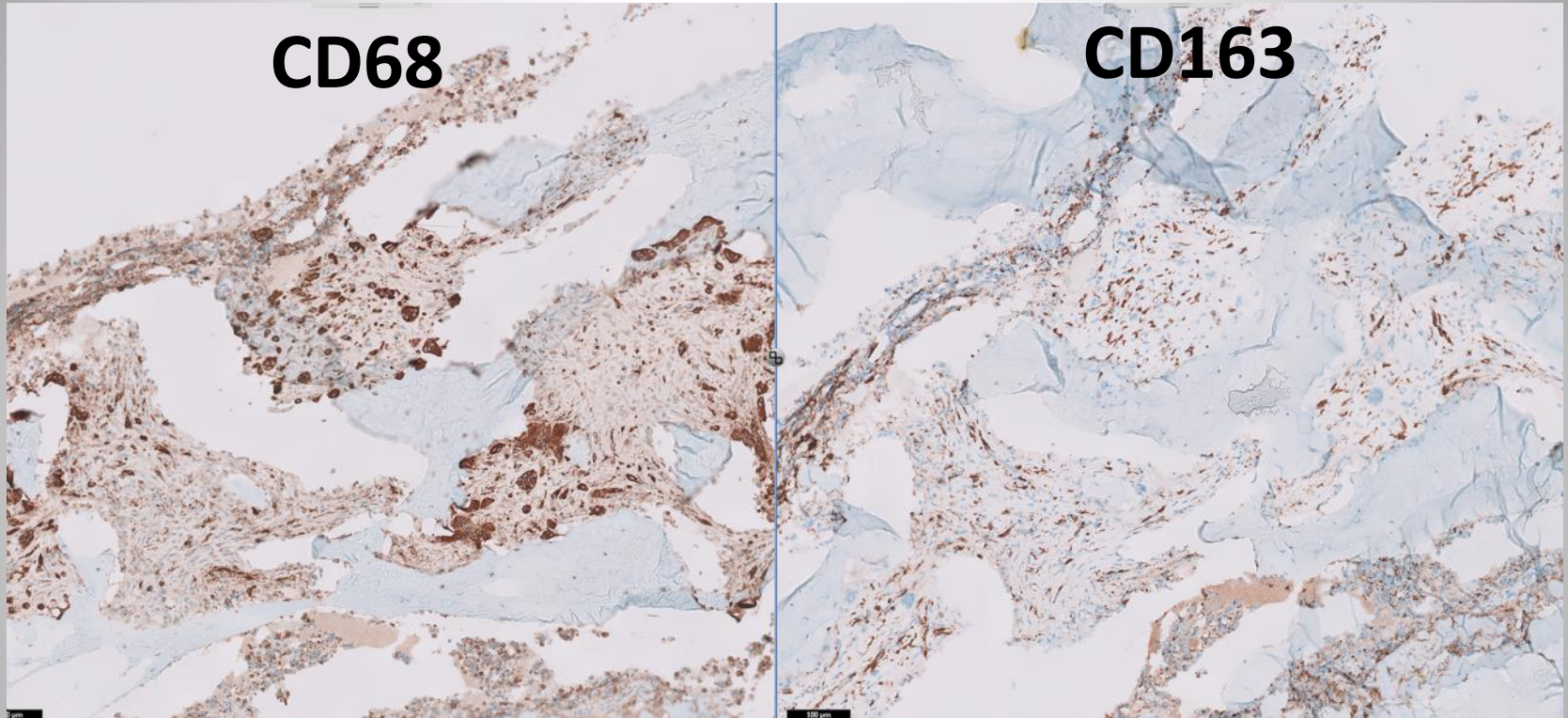








# Immunostains

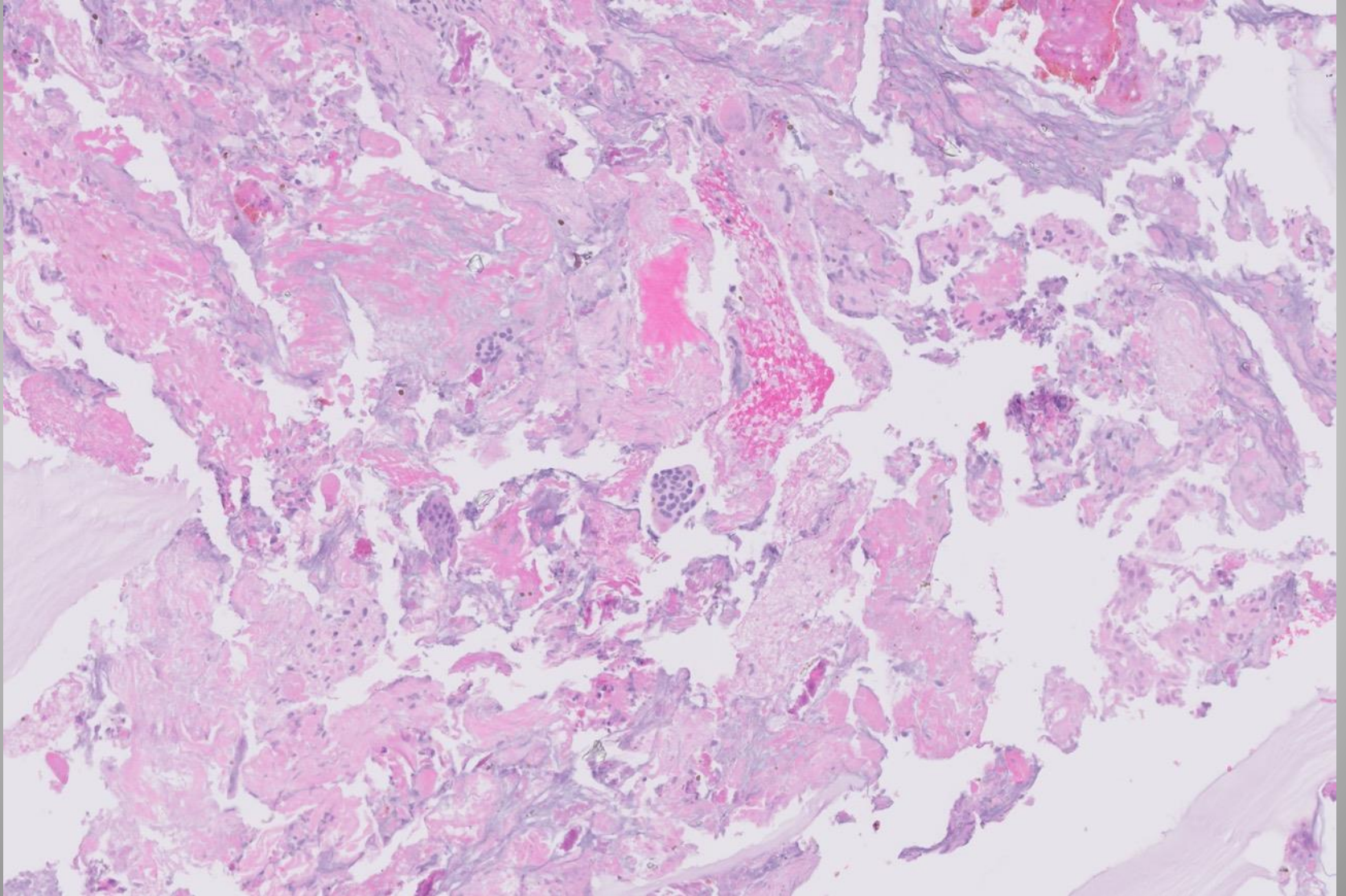


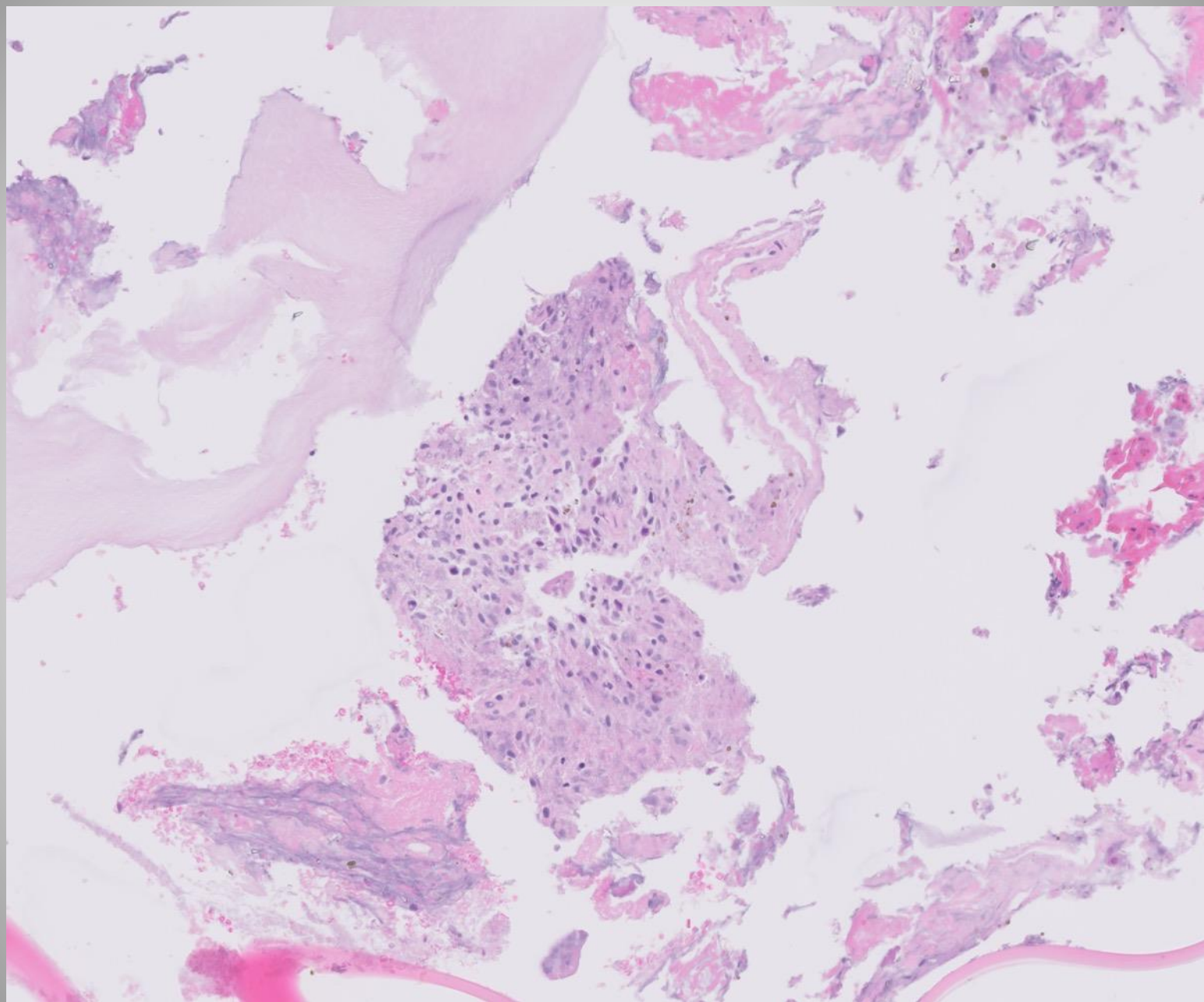
Stains for CD138, ISH kappa/lambda showed polytypic plasma cells within the hematopoietic areas

Stains for BRAF V600E, S100, cytokeratin, langerin, and melanA were negative



# Hip biopsy

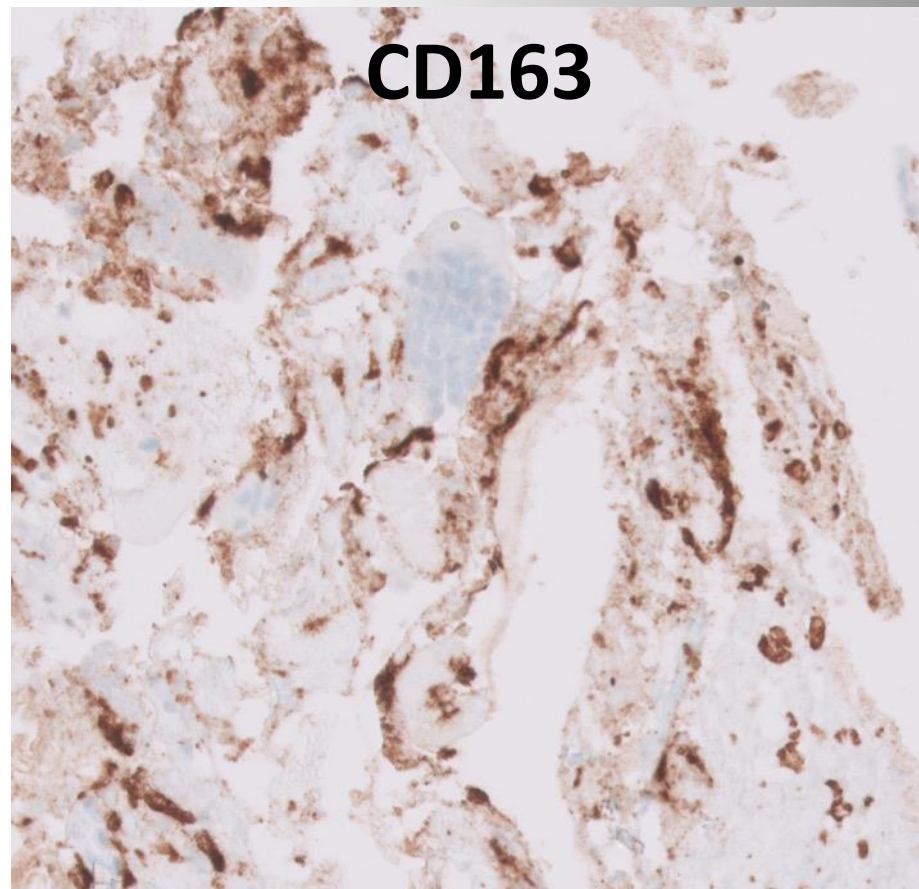
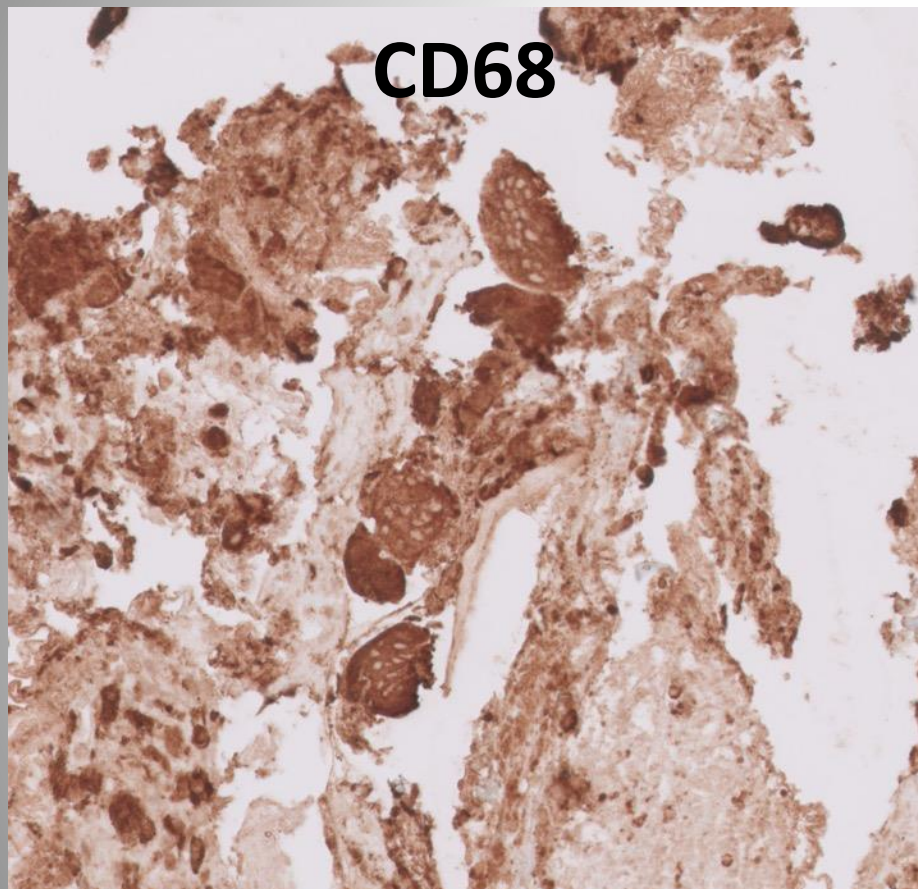






**CD68**

**CD163**



## Laboratory studies

- Creatinine 7.6 mg/dL (0.67 – 1.17 mg/dL)
- Alkaline phosphatase 703 U/L (40-130 U/L)
- Parathyroid hormone 2135 pg/mL (15-65 pg/mL)
- Phosphorus 4.1 mg/dL (2.5 – 4.5 mg/dL)

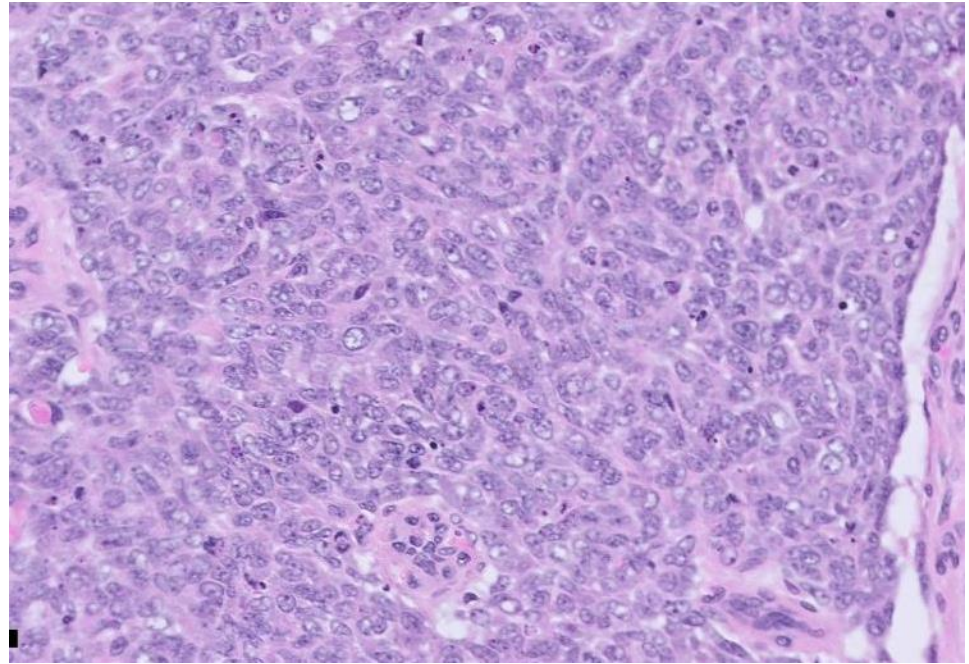
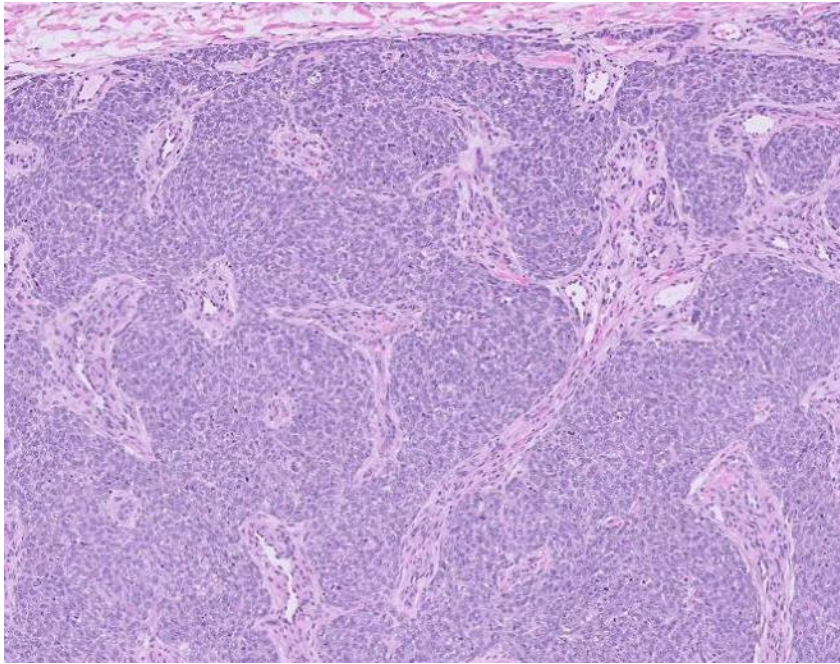


# 22-1004

**Jiajie “George” Lu/Serena Tan; Stanford**

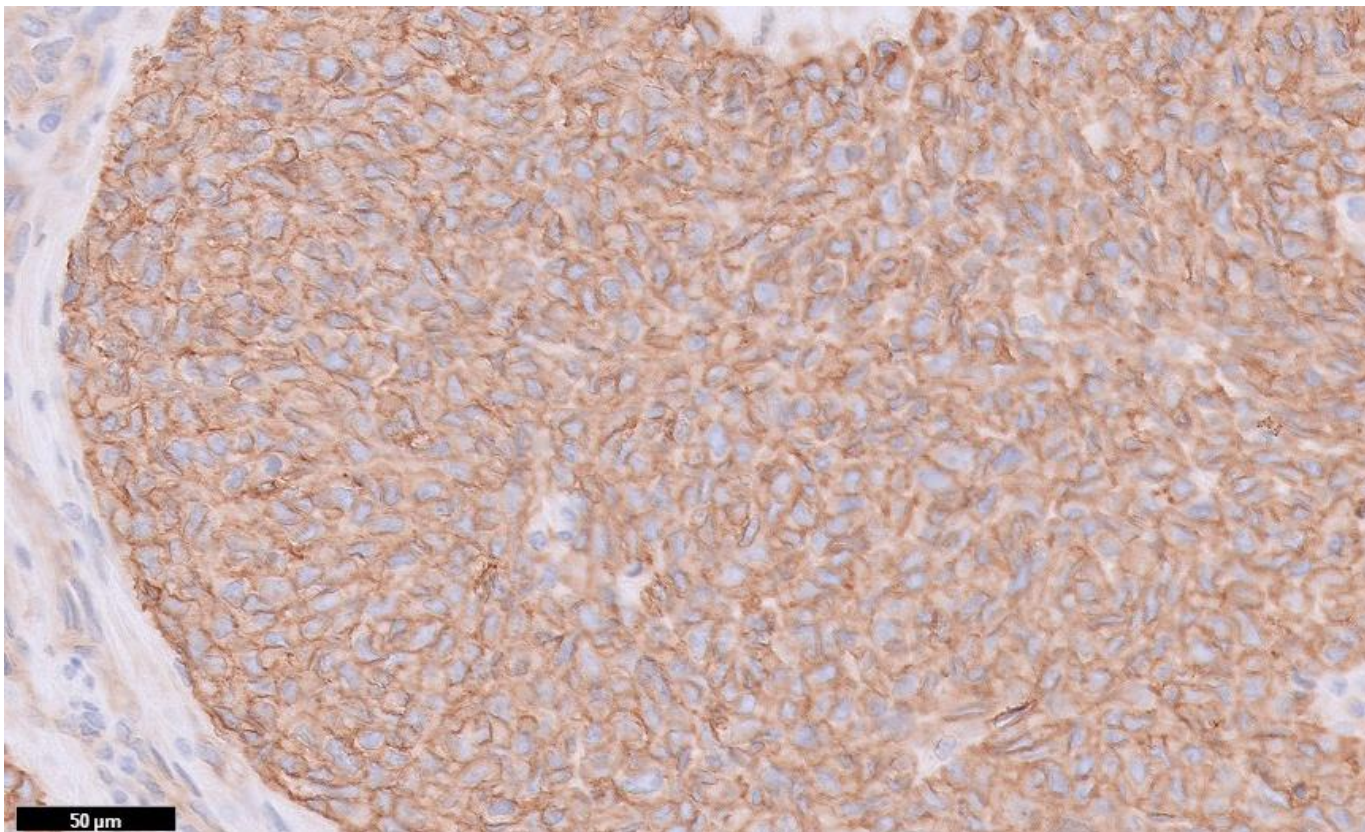
Young infant with presents with scalp mass. Case received in consultation for concern for carcinoma, following a thorough immunohistochemical and cytogenetics/FISH workup.

H&E

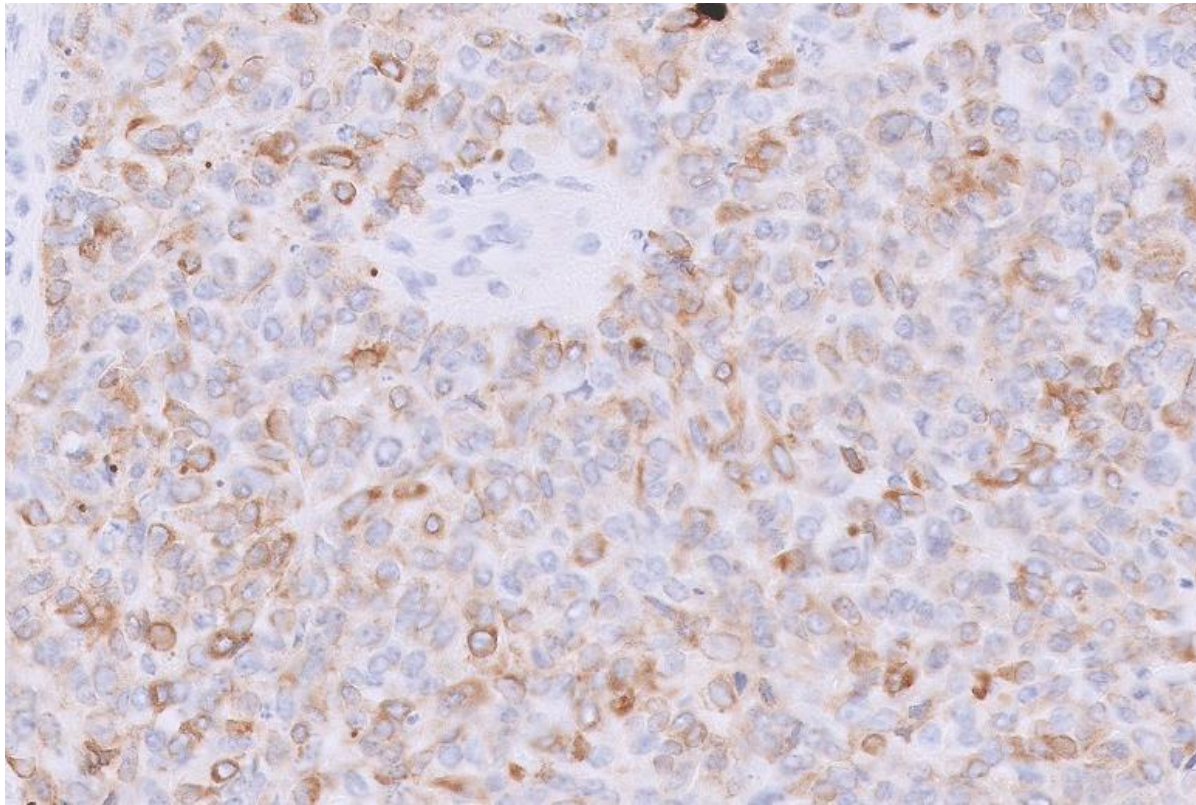




CD99

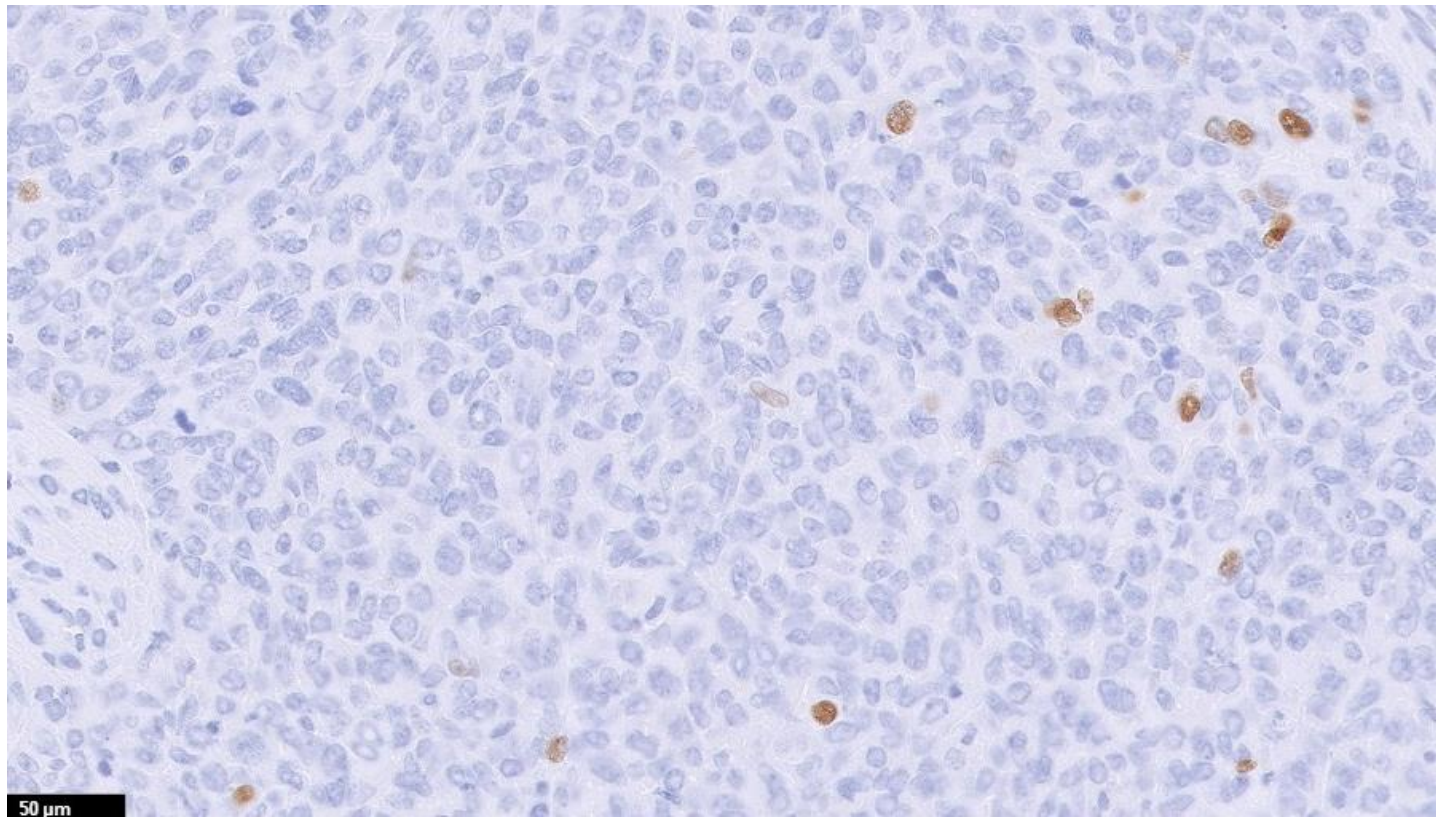


CK AE1/AE3





# NKX2.2



# Additional Immunohistochemistry

IHC	Result
Desmin	Weak/focal positive
EMA	Weak/focal positive
S100	Weak/focal positive
Calretinin	Weak/focal positive
WT1	Weak/focal positive
TLE1	Weak/focal positive
BCOR	Weak/focal positive
Myogenin	Negative
SMA	Negative
CD45	Negative
Synaptophysin	Negative
Chromogranin	Negative

IHC	Result
PHOX2b	Negative
TdT	Negative
SATB2	Negative
Calponin	Negative
CD34	Negative
NUT	Negative
INSMI	Negative
SOX10	Negative
GFAP	Negative
Claudin-4	Negative
p40	Negative
INI1	Retained



# FISH Results

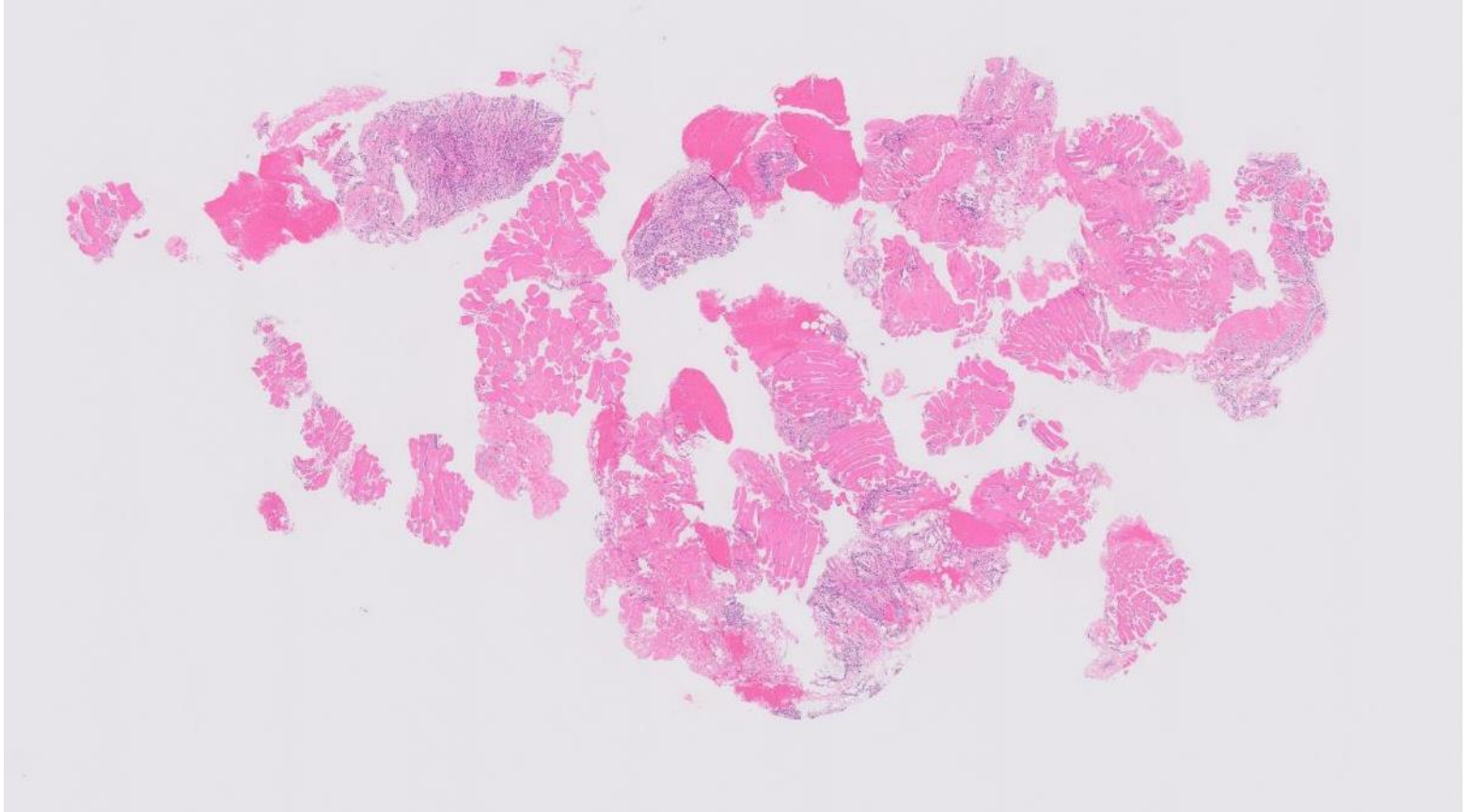
- Negative for rearrangements in *BCOR*, *TFE3*, *NTRK1/2/3*, *ETV6*, *YWAE*, *SS18*, *CIC*, *EWSR1*
- Repeat FISH at second facility again failed to demonstrate rearrangement of *EWSR1*

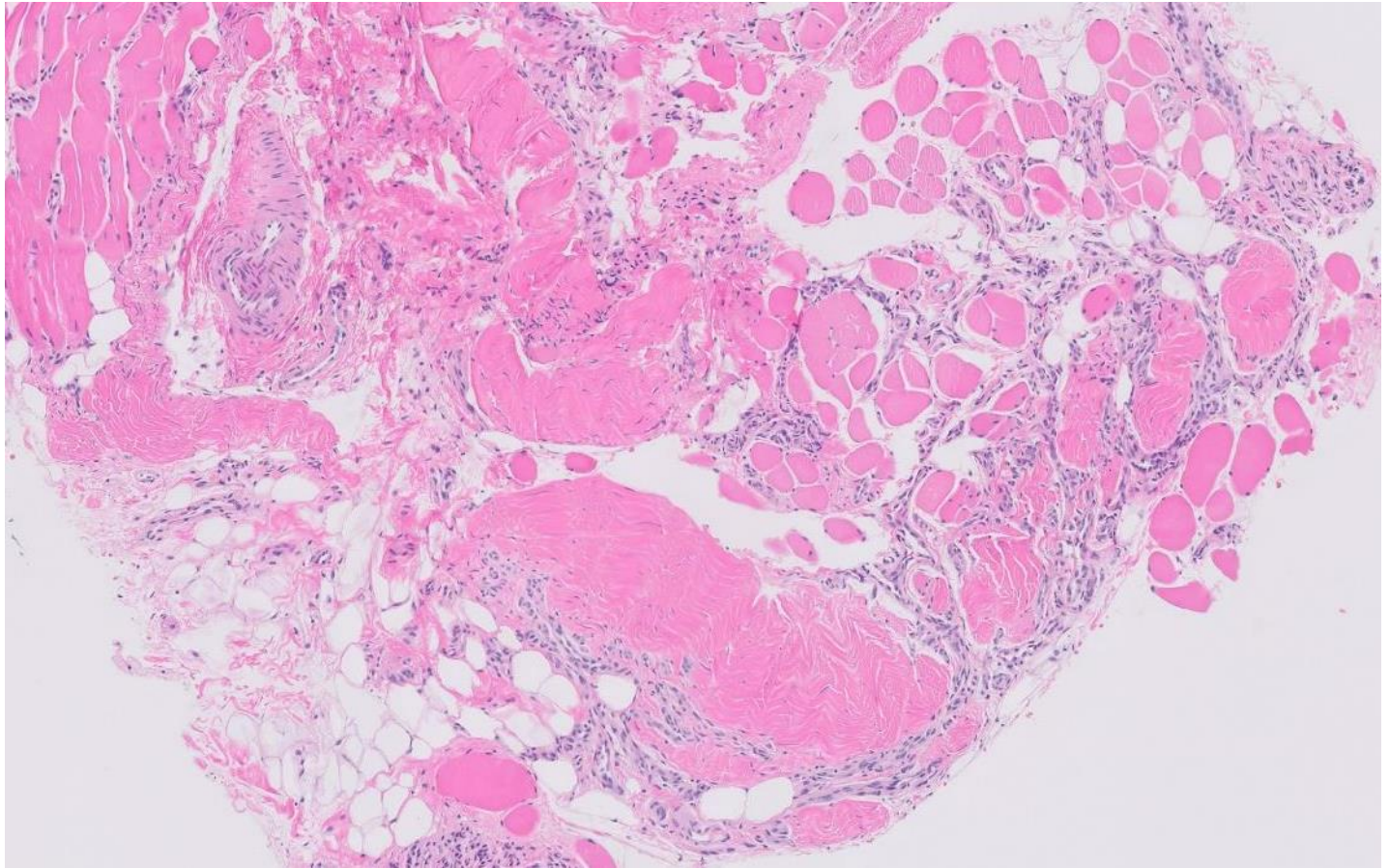
22-1005

**Serena Tan; Stanford**

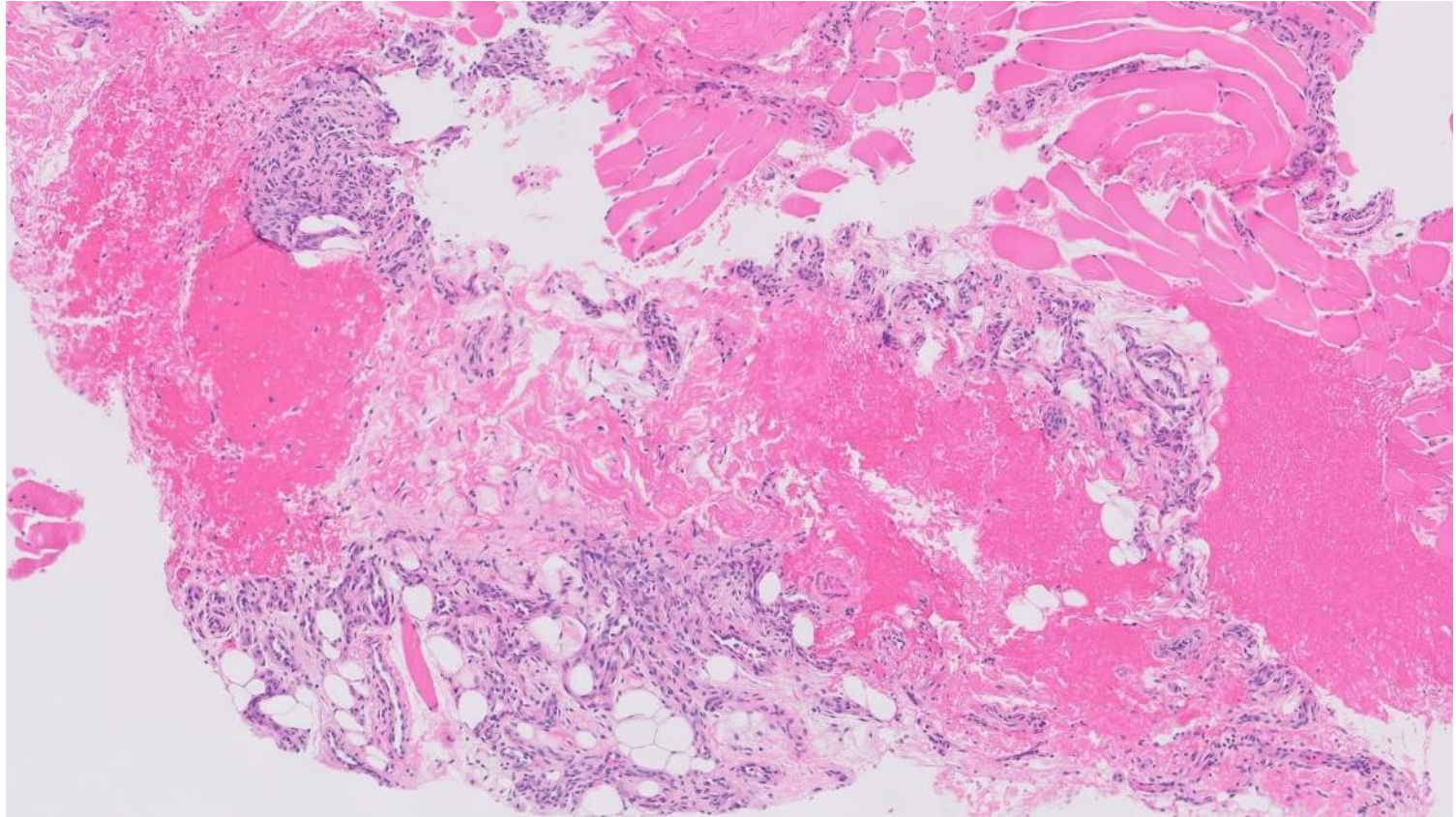
Young infant male with left chest wall mass deep to pectoralis muscle.

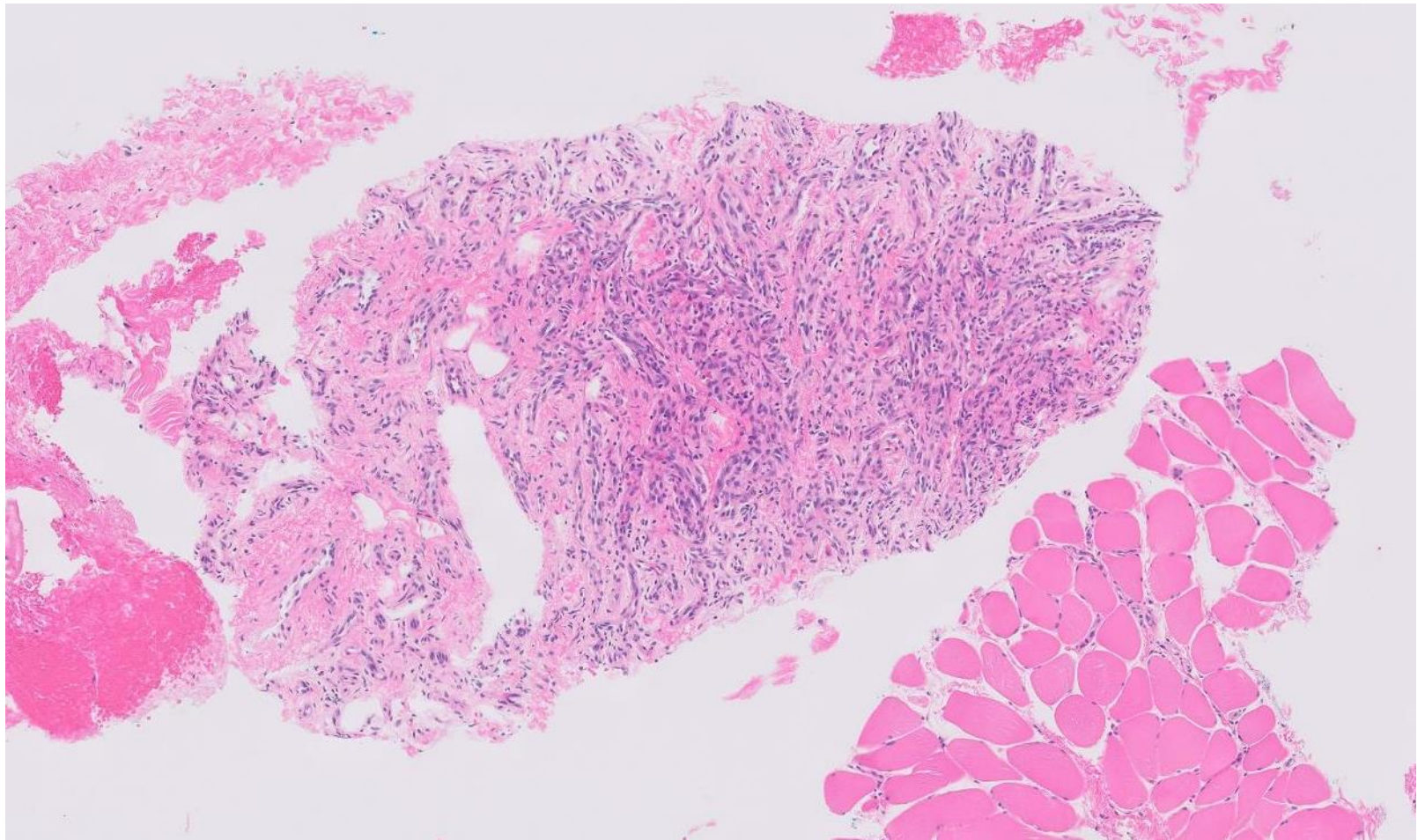




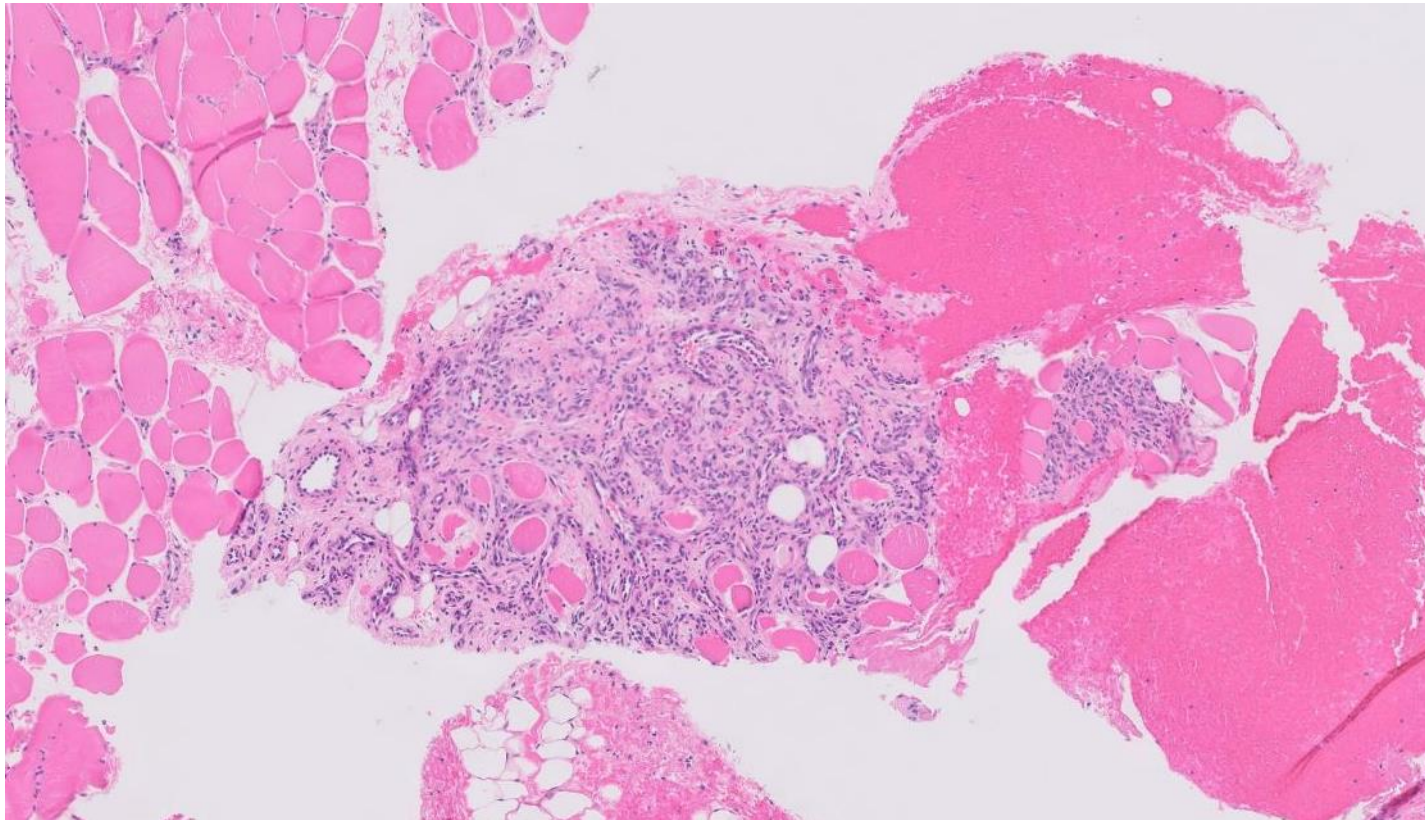


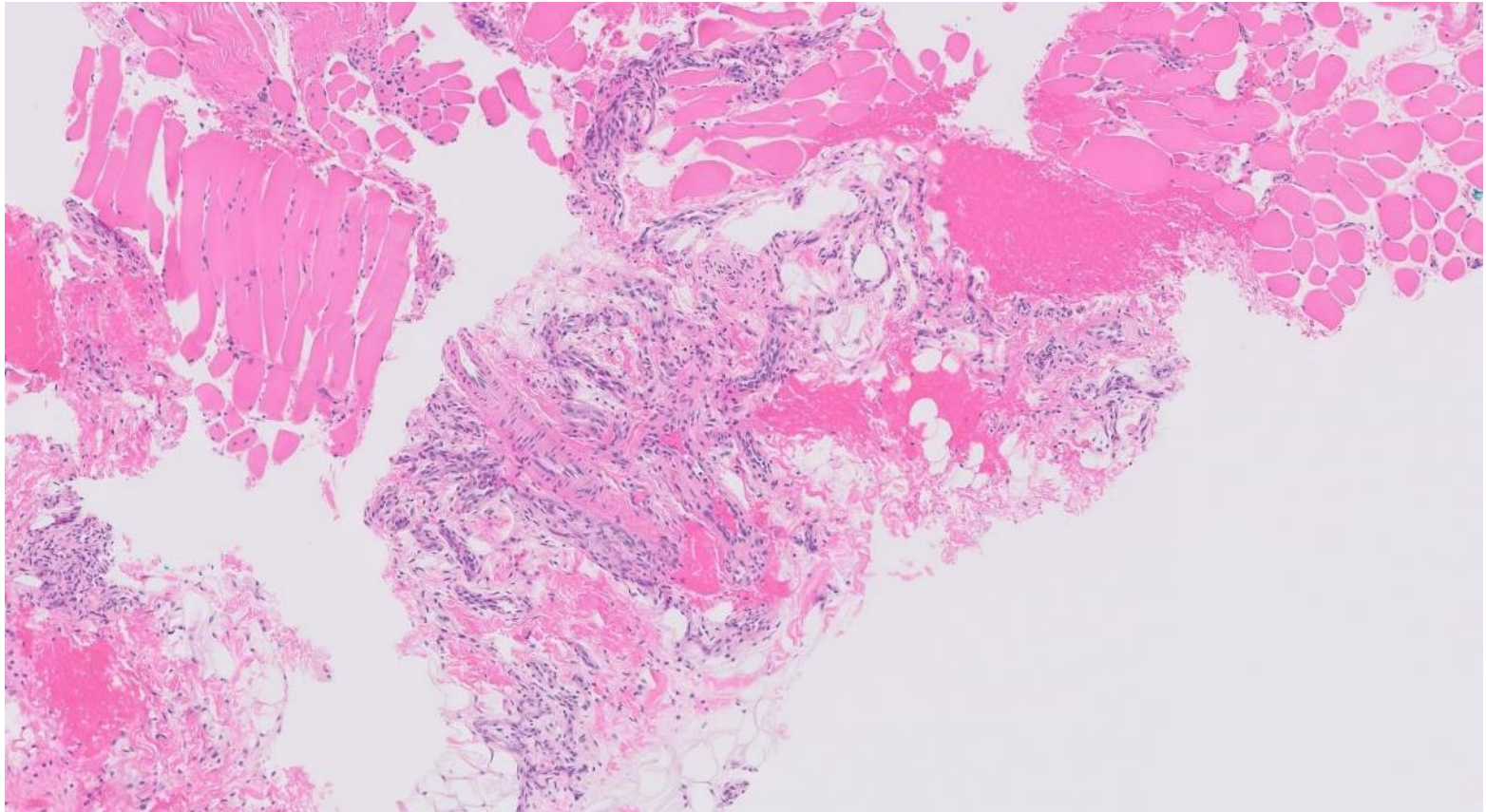




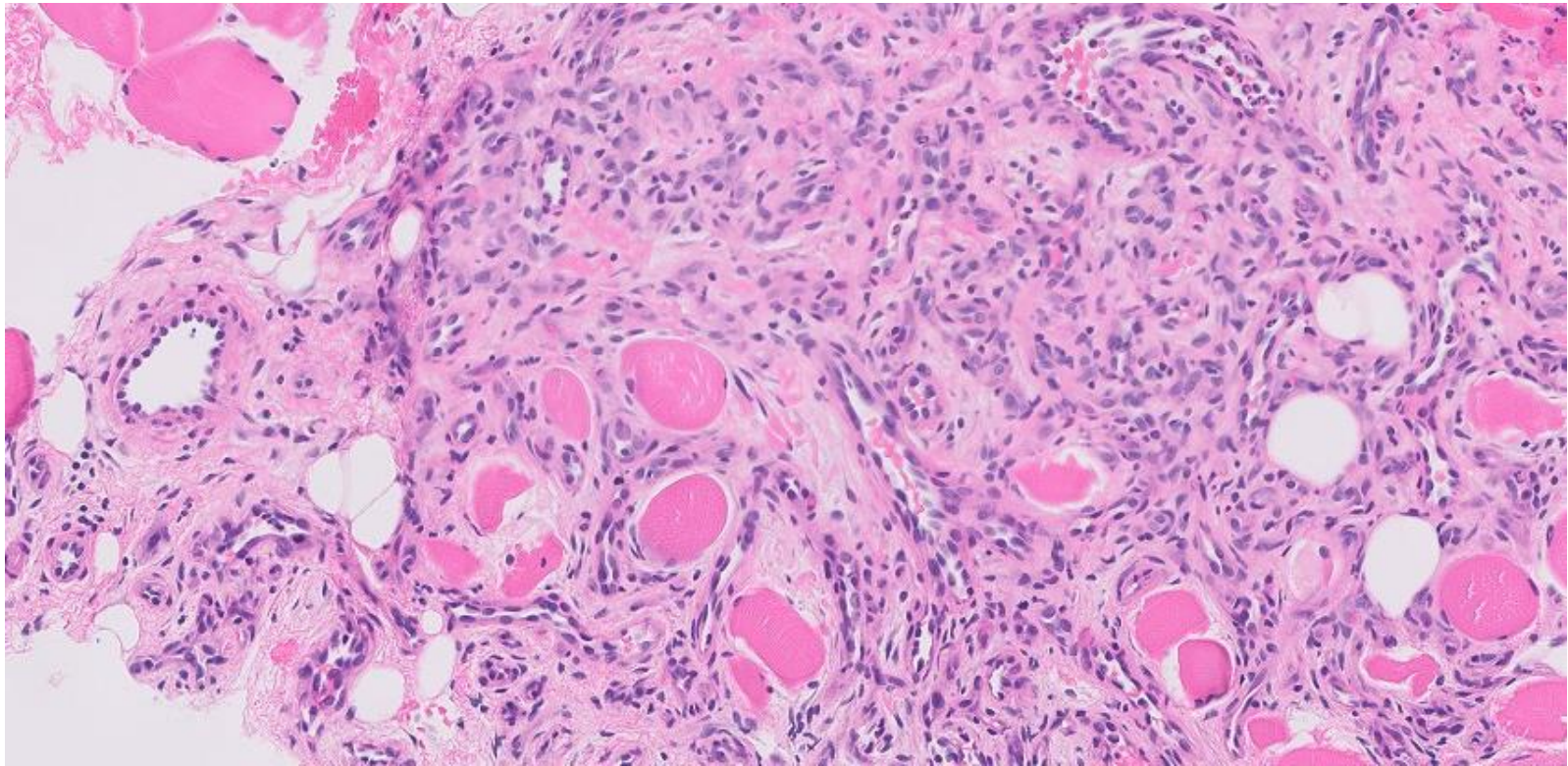


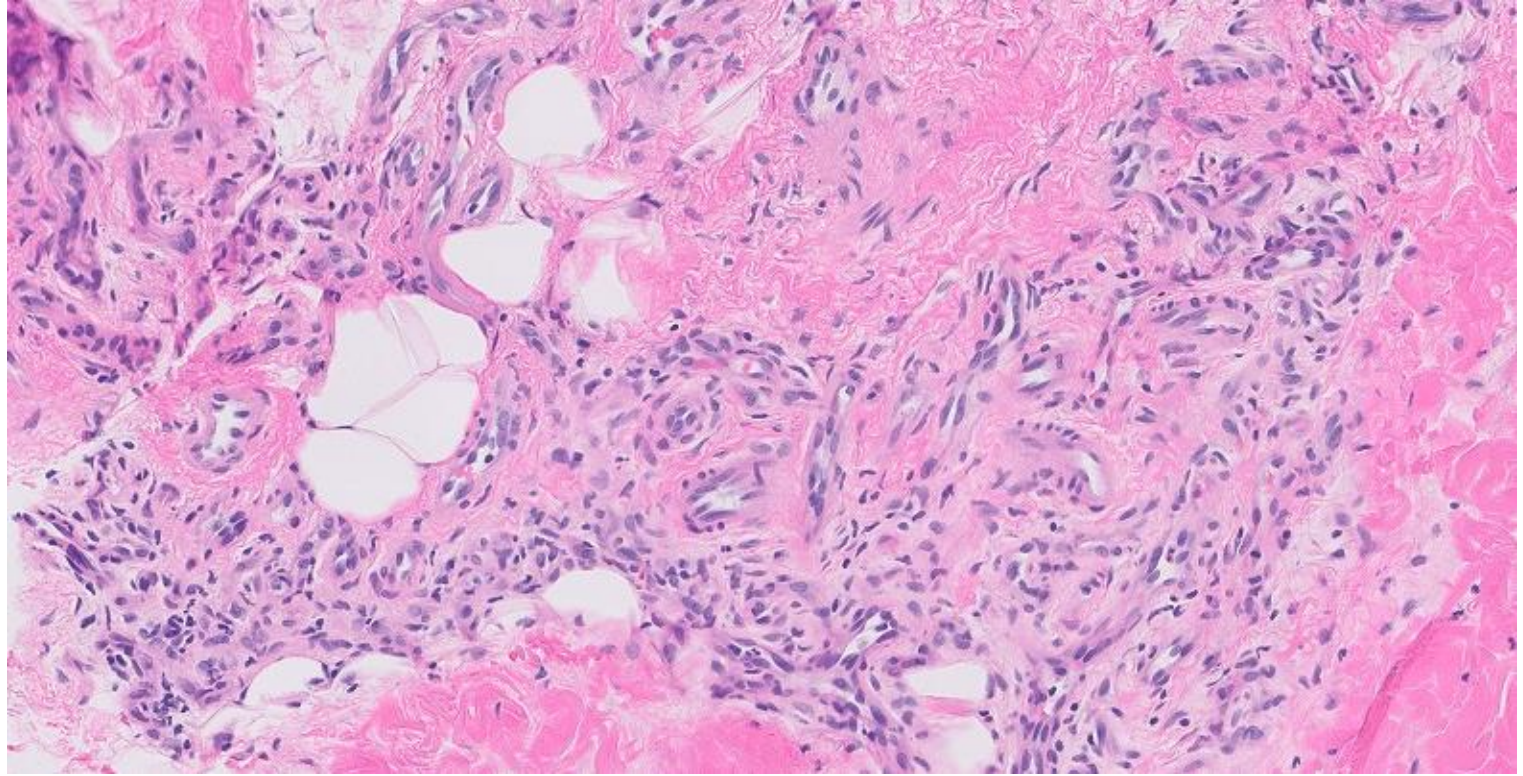














# 22-1006

**Andrew Xiao/Chris Schwartz/Steve Long; UCSF**

20ishF with recently identified palpable right breast mass. Ultrasound demonstrates a 37 x 15 x 33 mm hypoechoic, irregularly shaped solid mass with indistinct margins in the upper inner quadrant of the right breast. She undergoes ultrasound-guided core biopsy.

Zoom 2x 10.672 mm<sup>2</sup>

500  $\mu$ m

This is a low-magnification histological image of a tissue section, likely stained with hematoxylin and eosin (H&E). The image shows a complex arrangement of tissue layers. In the upper right, there are clusters of cells with a pinkish, somewhat fibrous appearance. Below and to the left of these, there are more densely cellular areas with a darker purple hue, indicating the presence of nuclei. The overall structure is irregular, with various sized spaces and regions of different cellular density. A scale bar in the bottom left corner indicates a length of 500 micrometers. The image is presented at a 2x zoom level, covering an area of 10.672 square millimeters.



Zoom 10x 0.667 mm<sup>2</sup>

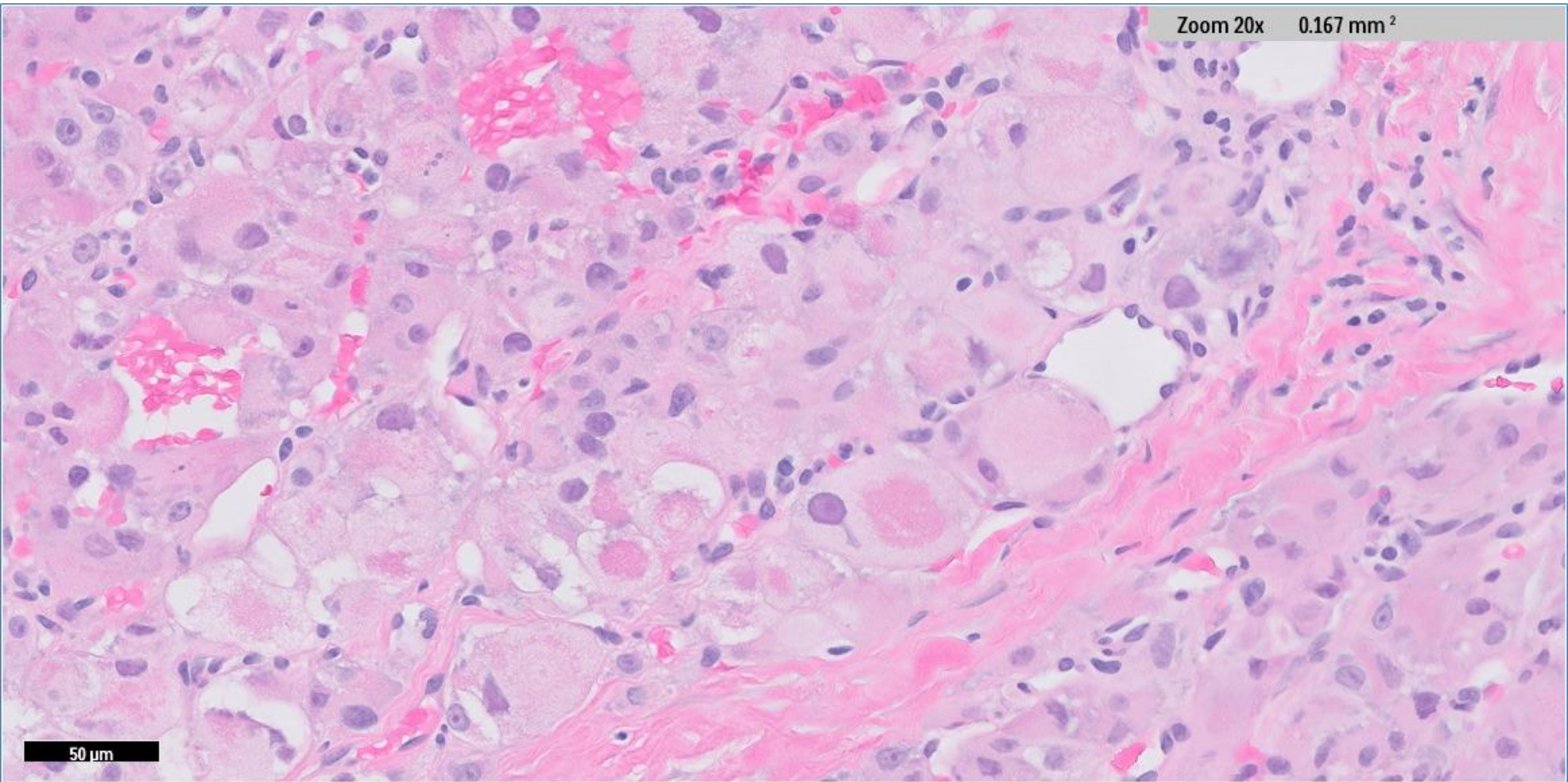
100 μm

A histological section of tissue stained with hematoxylin and eosin (H&E). The image shows a dense population of cells with prominent nuclei (stained purple) and varying amounts of cytoplasm and extracellular matrix (stained pink). There are several large, pale, irregular areas that appear to be cysts or areas of necrosis. The overall architecture is disorganized, suggesting a pathological process. The scale bar in the bottom left indicates 100 μm.



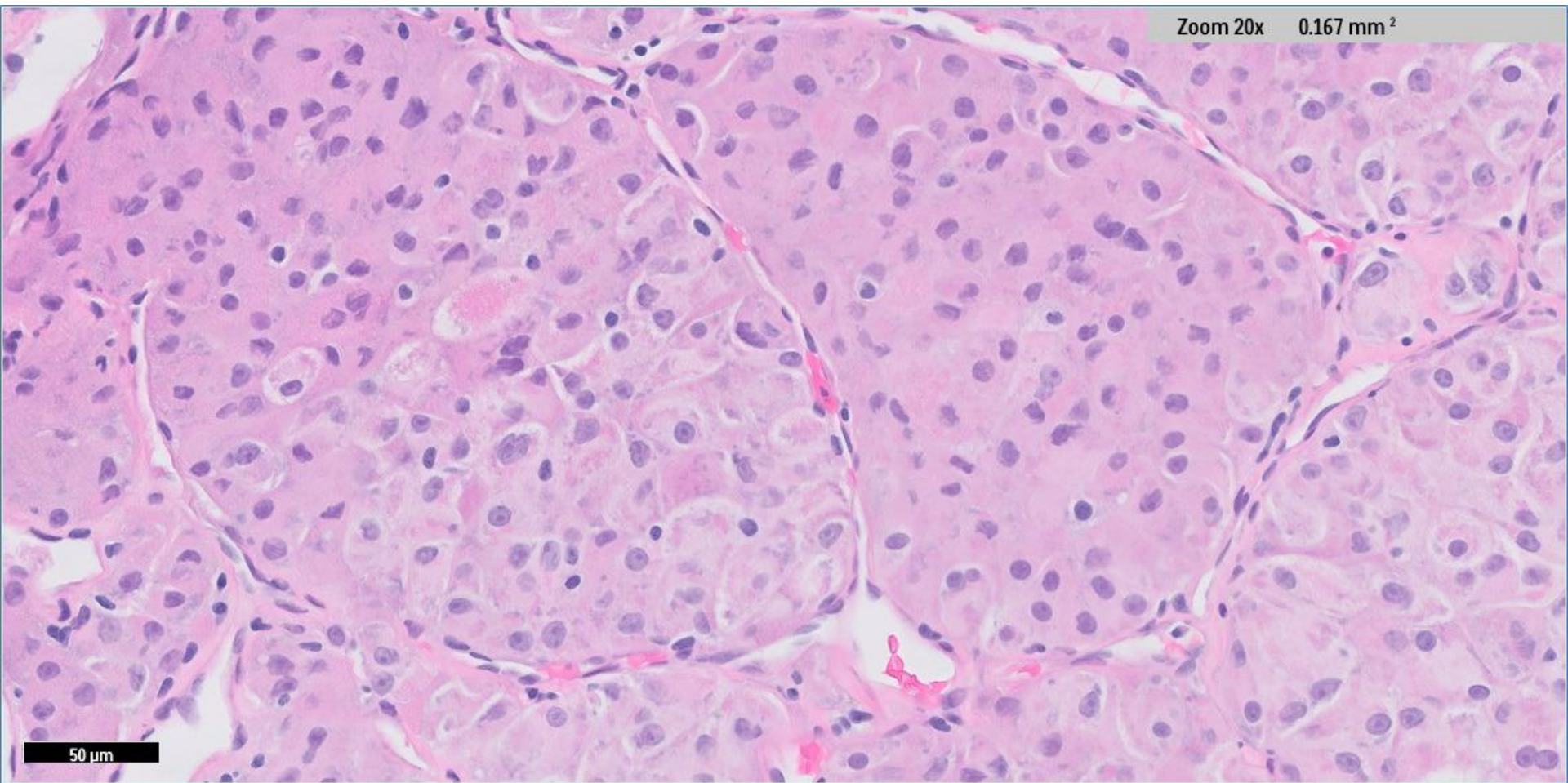
Zoom 20x 0.167 mm<sup>2</sup>

50 μm





Zoom 20x 0.167 mm<sup>2</sup>



50  $\mu$ m

Zoom 40x 0.042 mm<sup>2</sup>

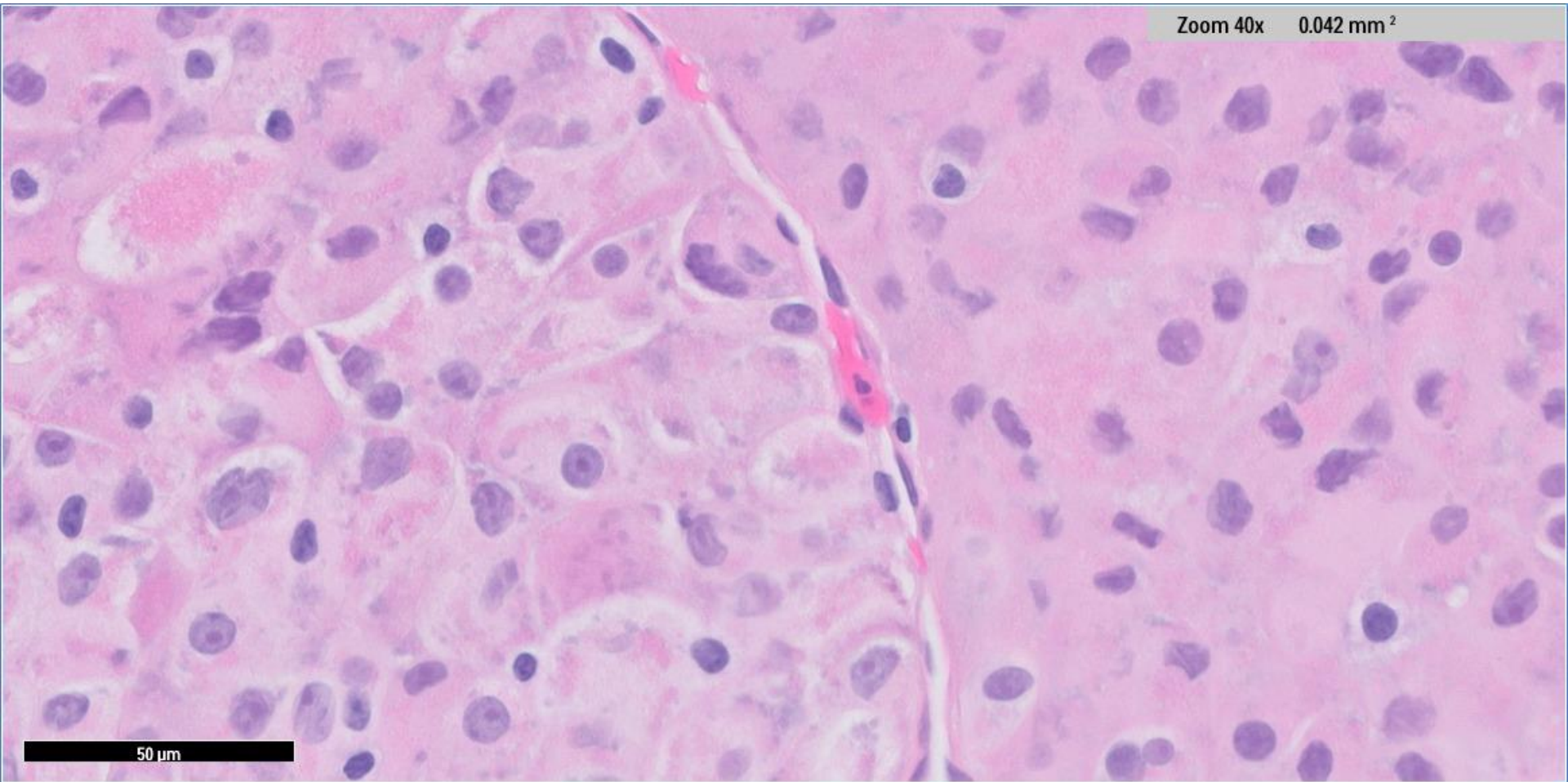
50 μm

A histological micrograph showing a tissue section stained with hematoxylin and eosin (H&E). The image displays a dense population of cells with prominent, dark purple nuclei and pinkish cytoplasm and extracellular matrix. There are several large, pale, circular or oval structures scattered throughout, which could be cysts, vacuoles, or areas of necrosis. The overall architecture appears disorganized, with cells packed closely together. The staining highlights the cellular morphology and the surrounding stromal components.



Zoom 40x 0.042 mm<sup>2</sup>

50 μm



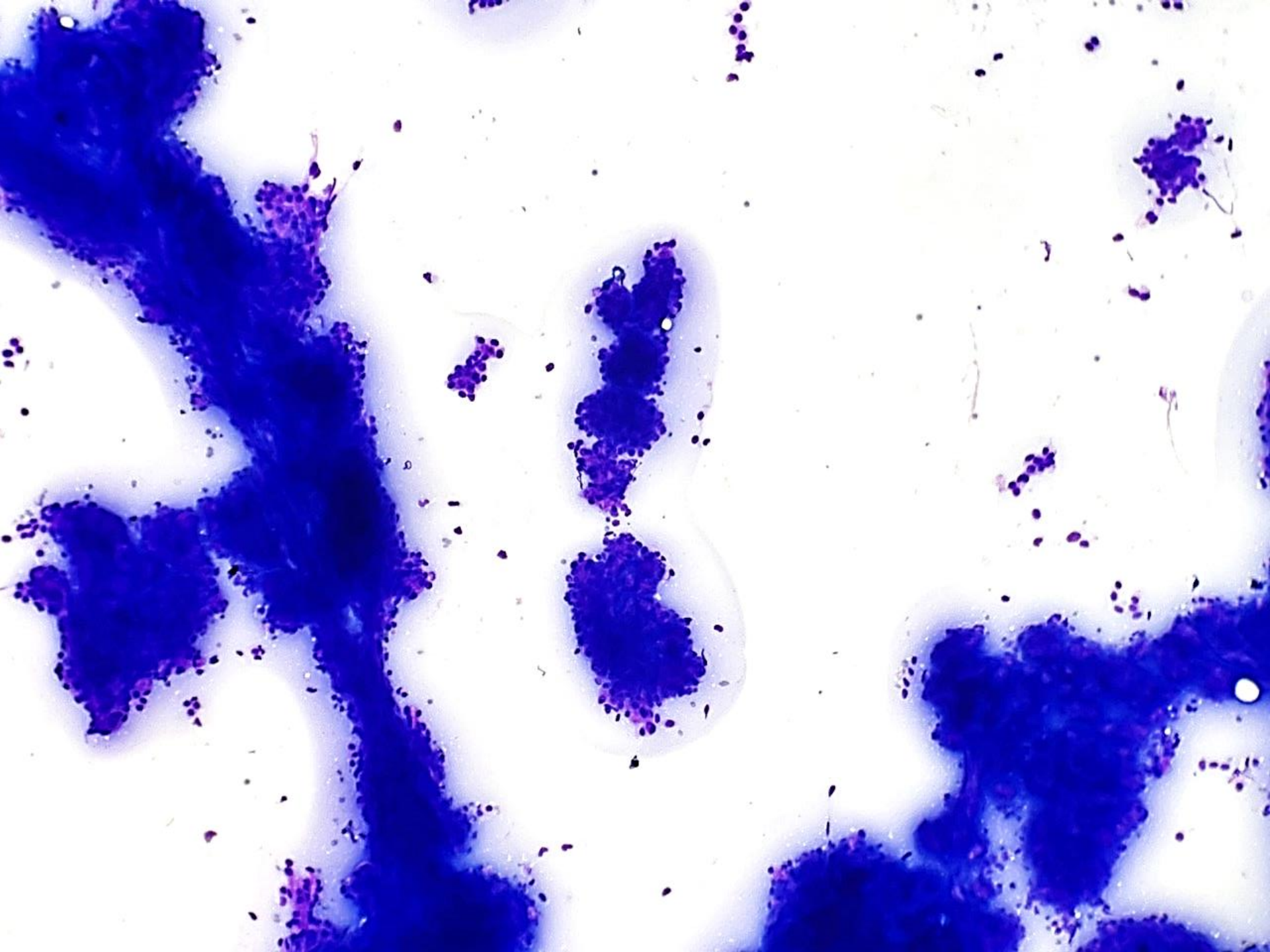
22-1007

**22-1007 Harris Goodman; Alameda Health**

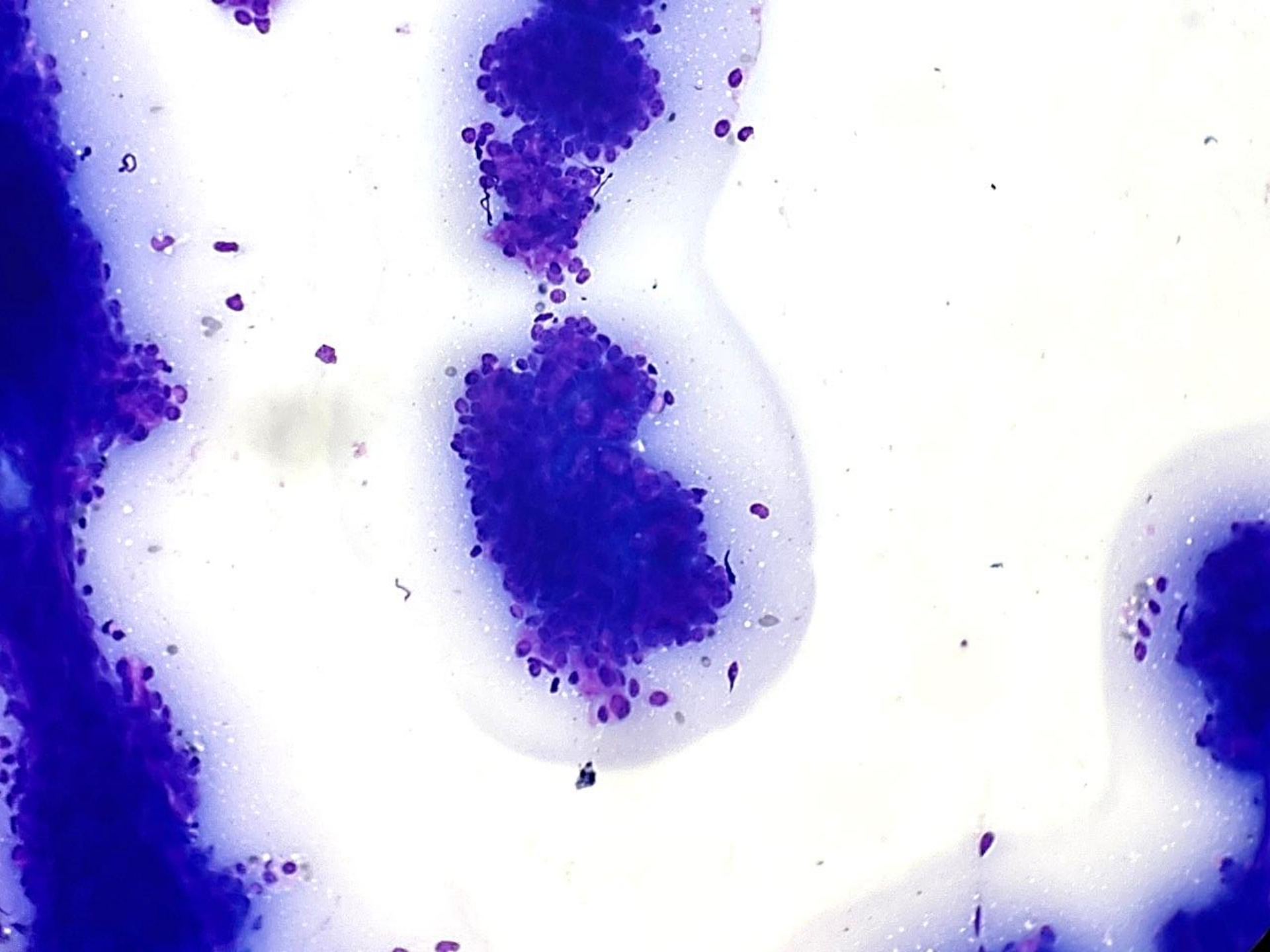
30ish F with right parotid mass, FNA performed.

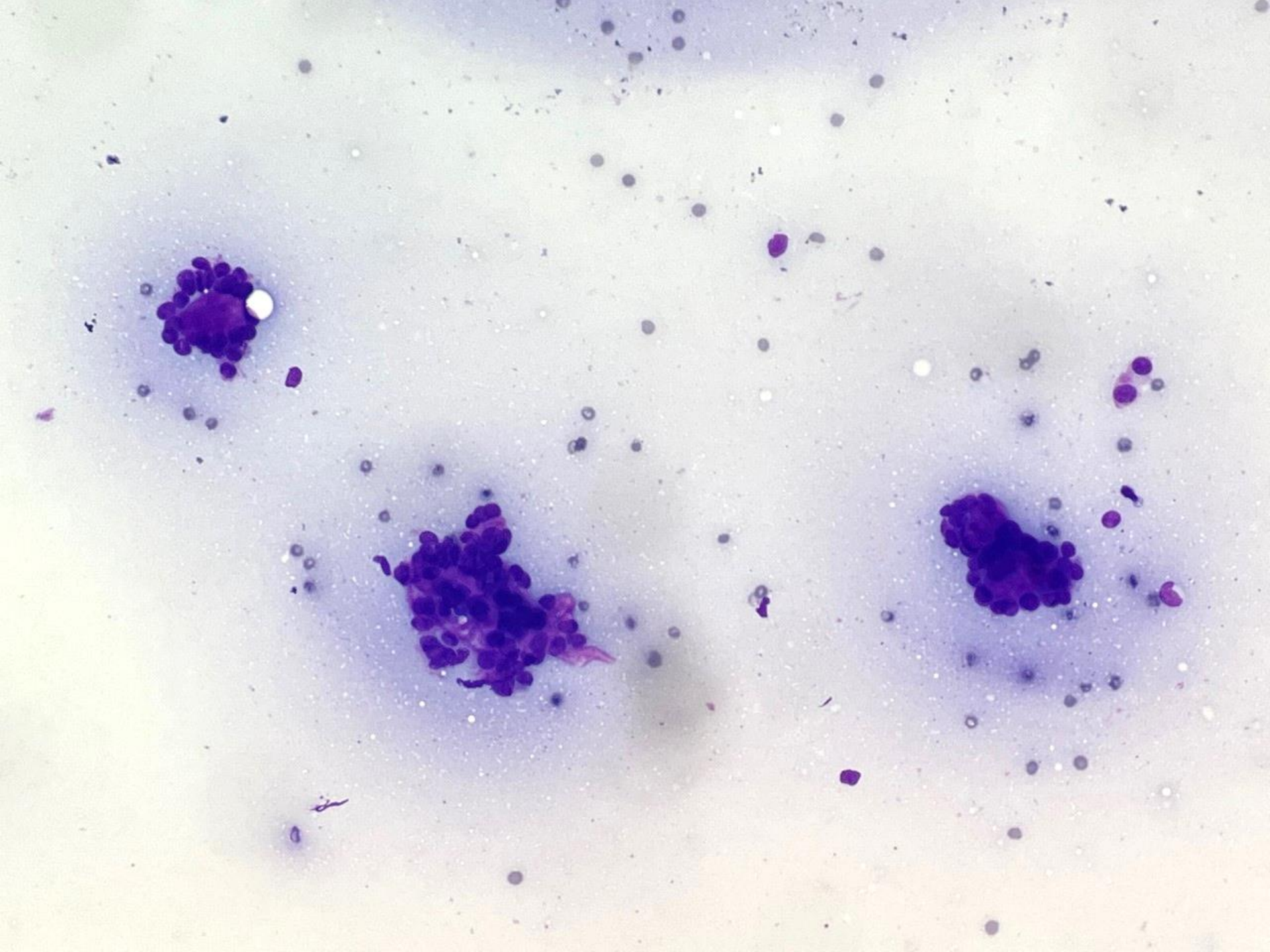




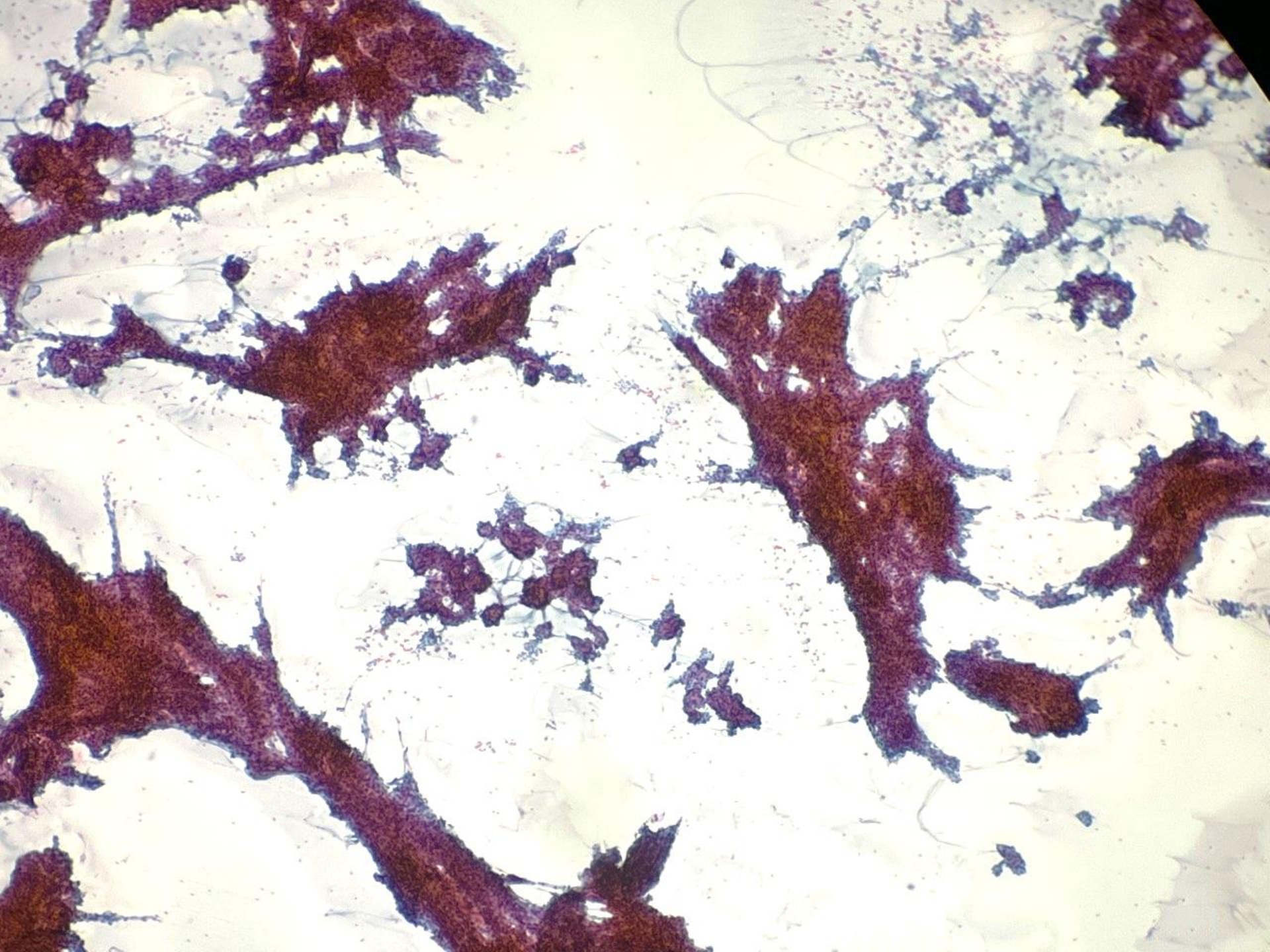




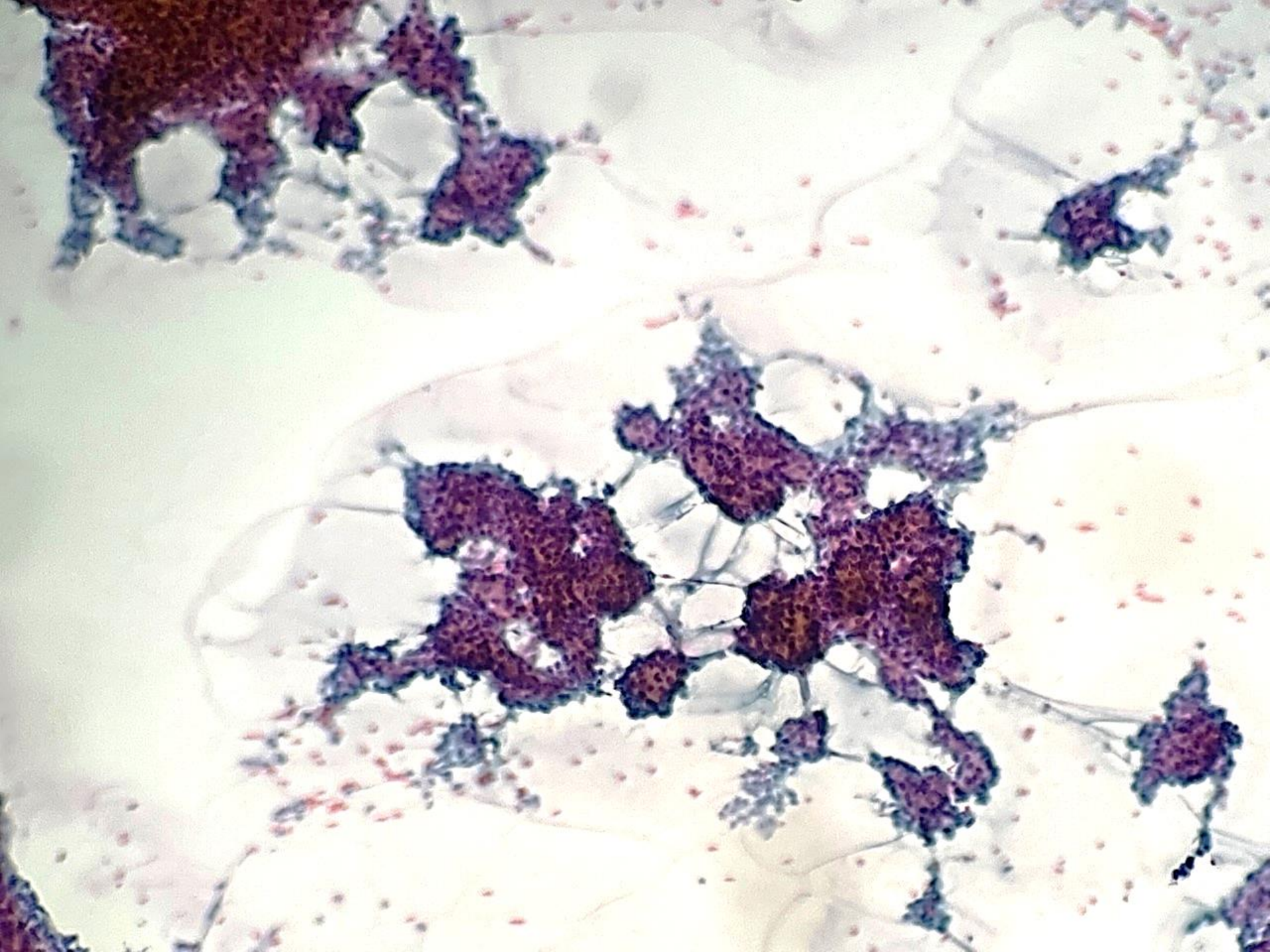




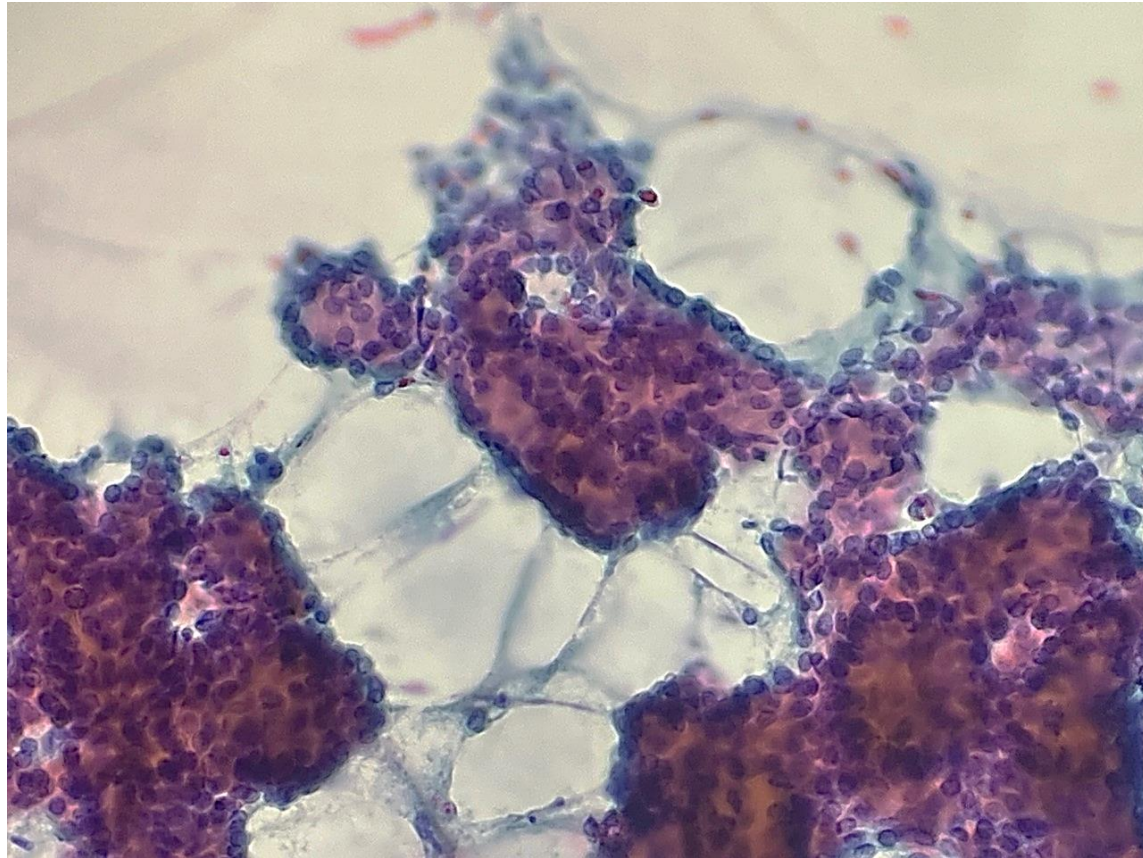










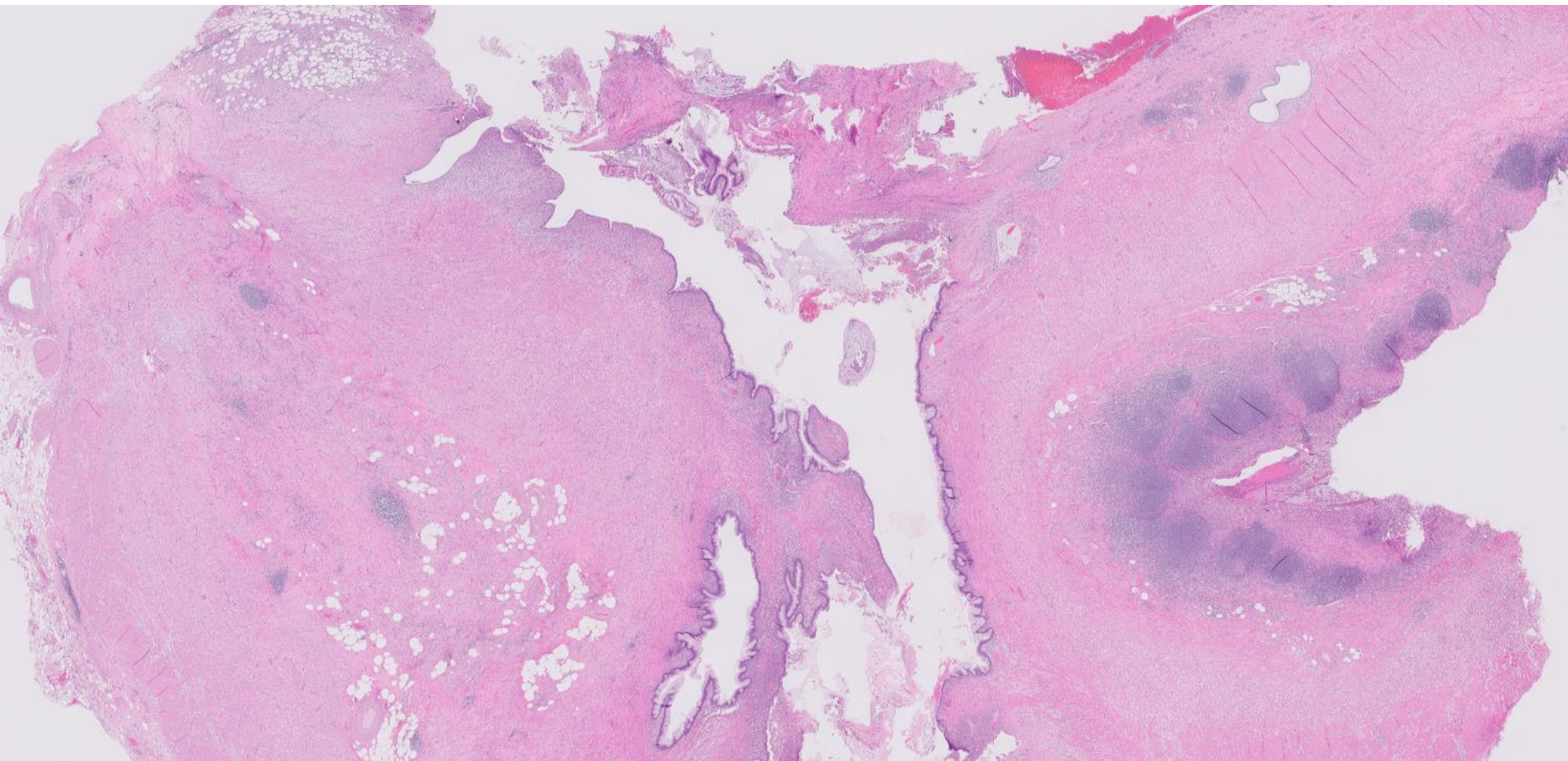


# 22-1008

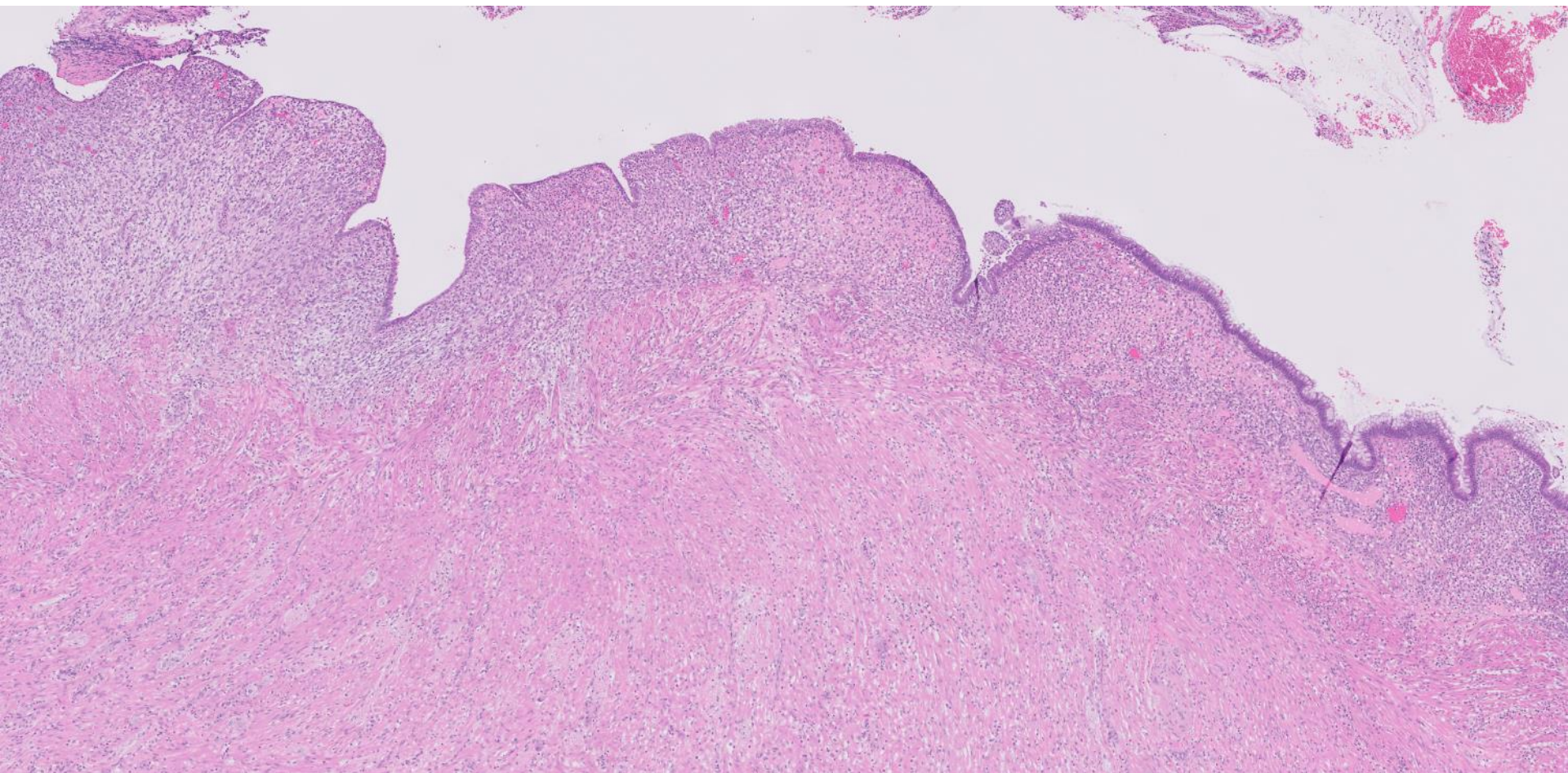
**Dave Bingham; Stanford**

30ish F with 1-day h/o acute abdominal pain. Work-up revealed focal tenderness in the RUQ, WBC 16, and CT showing acute inflamed appendix.

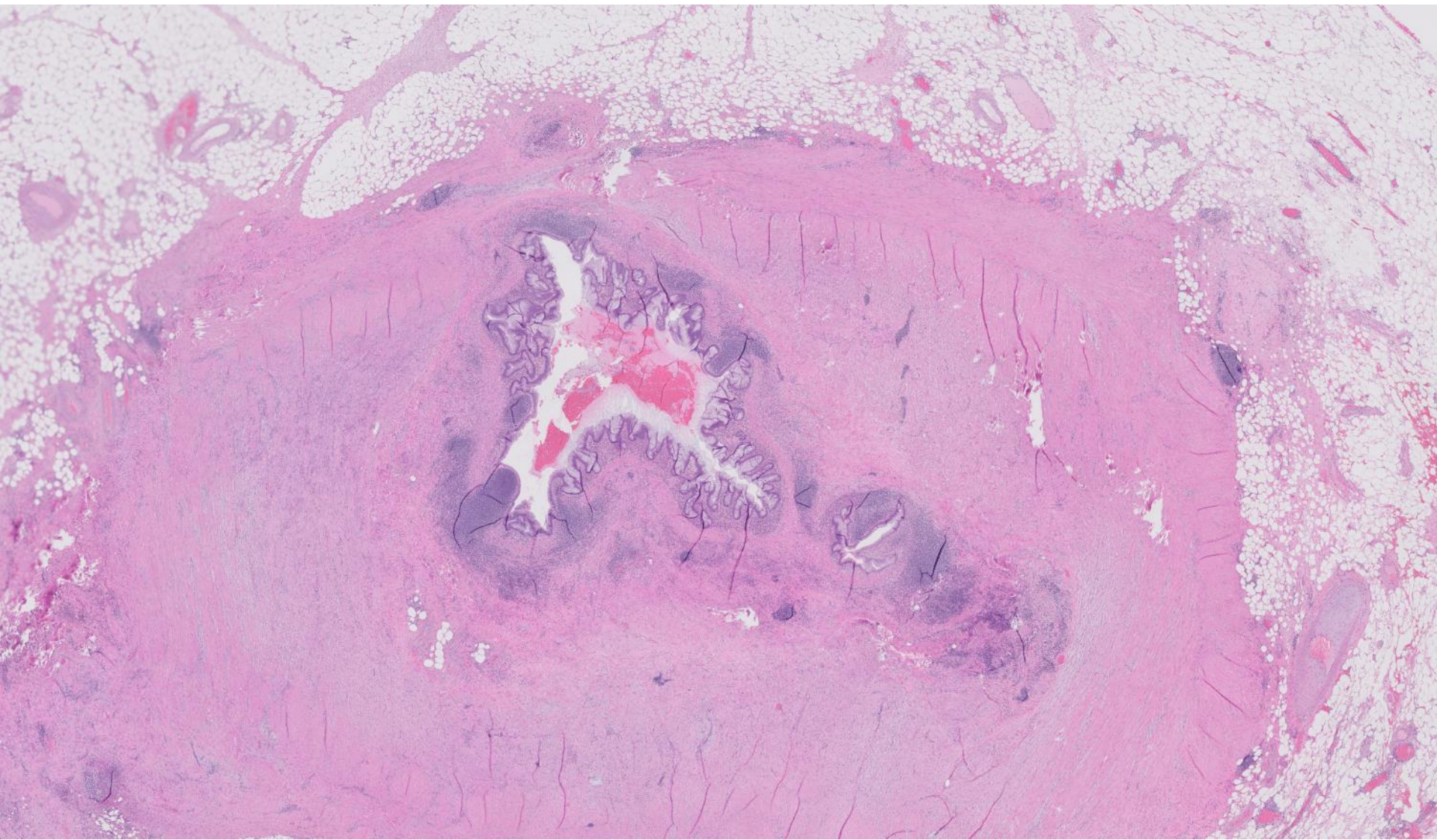



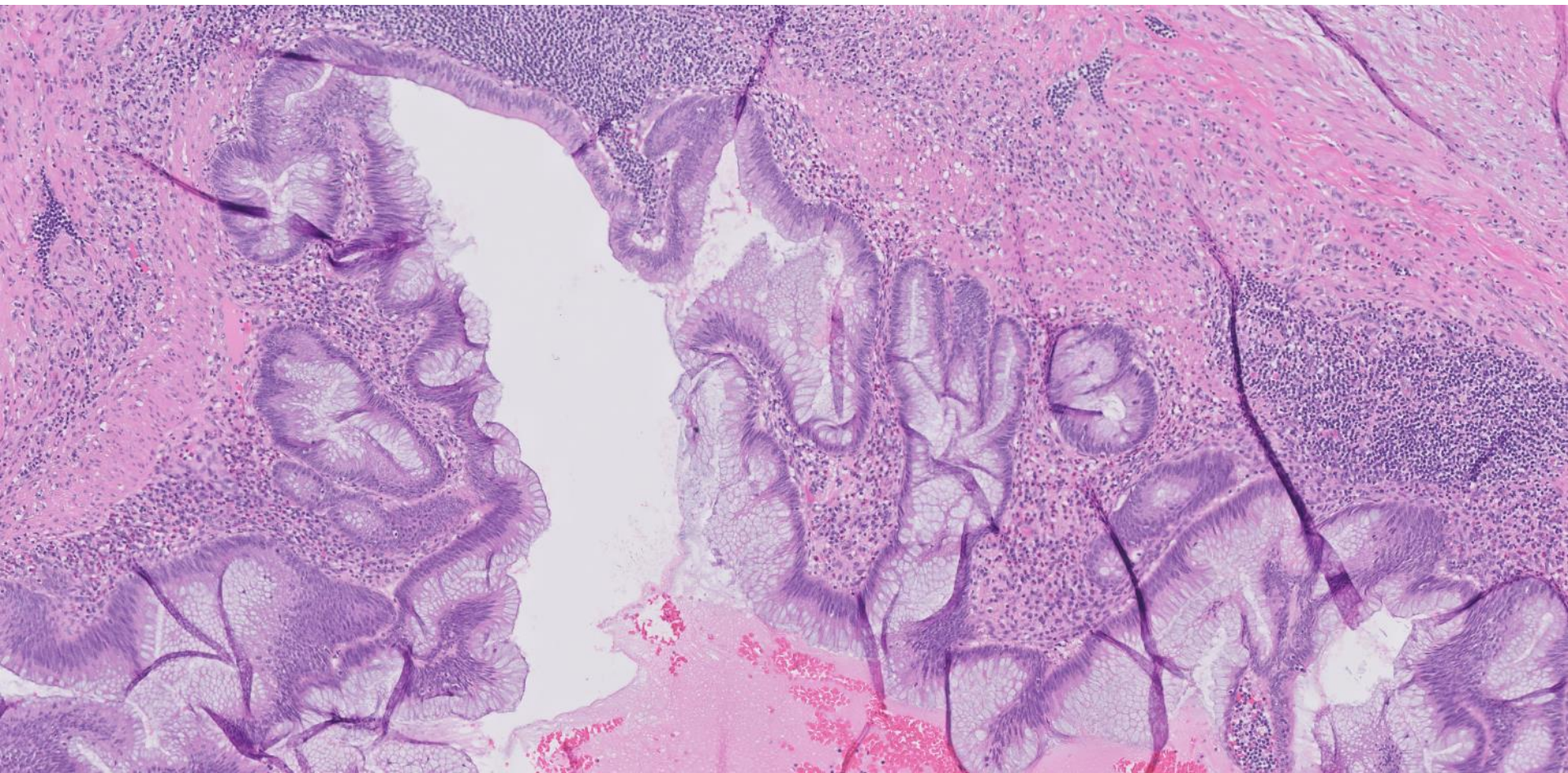




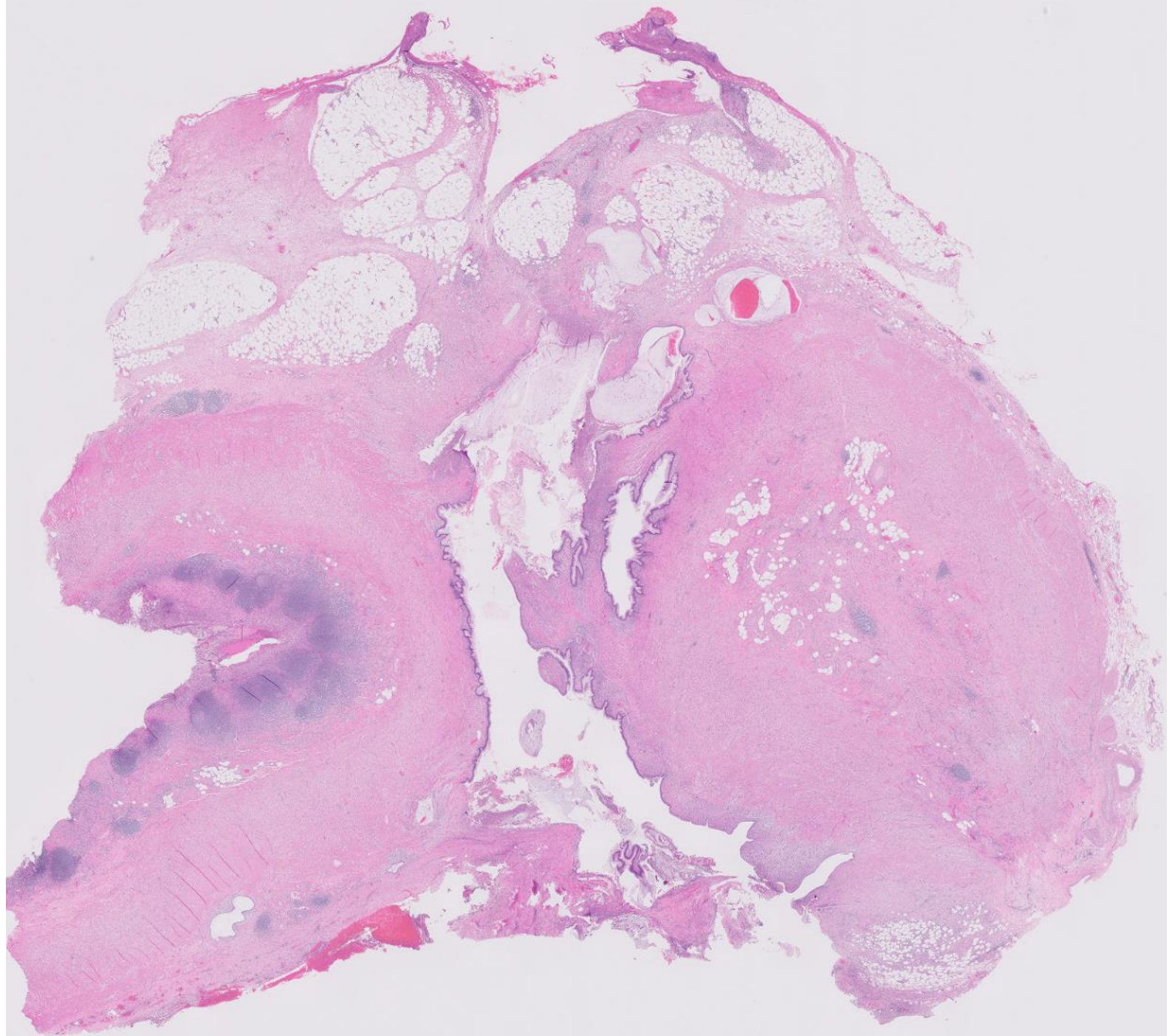




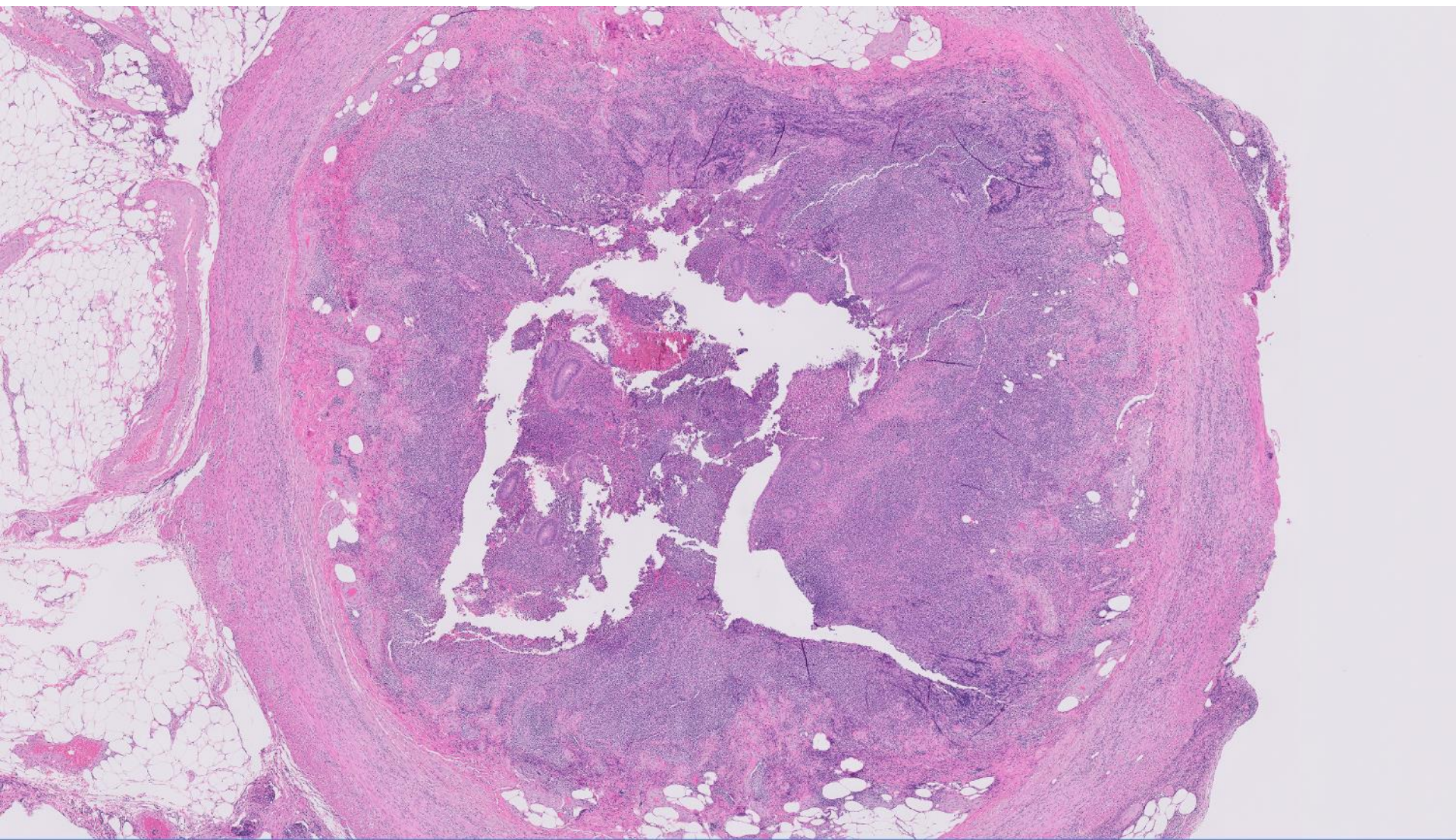




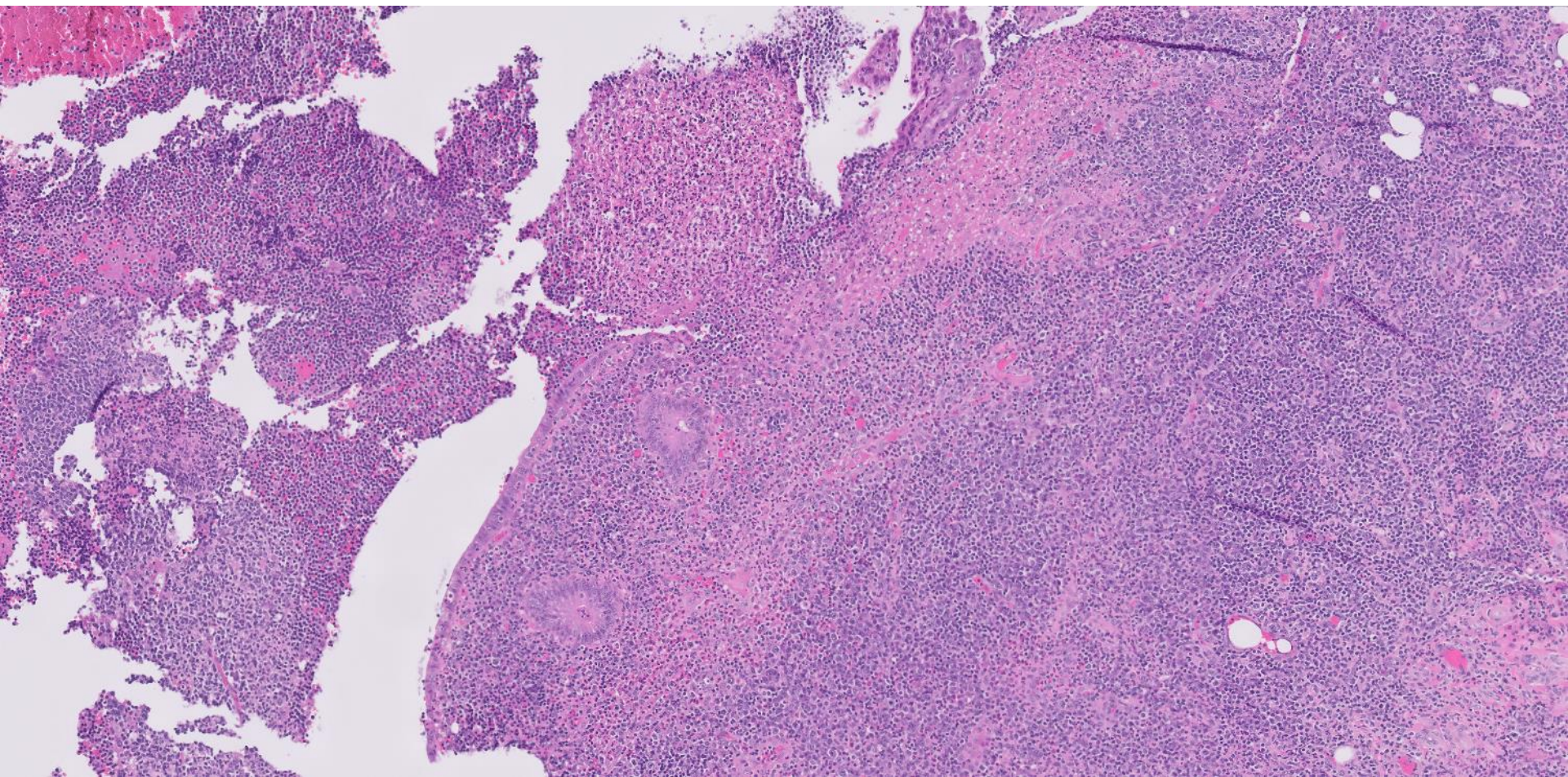




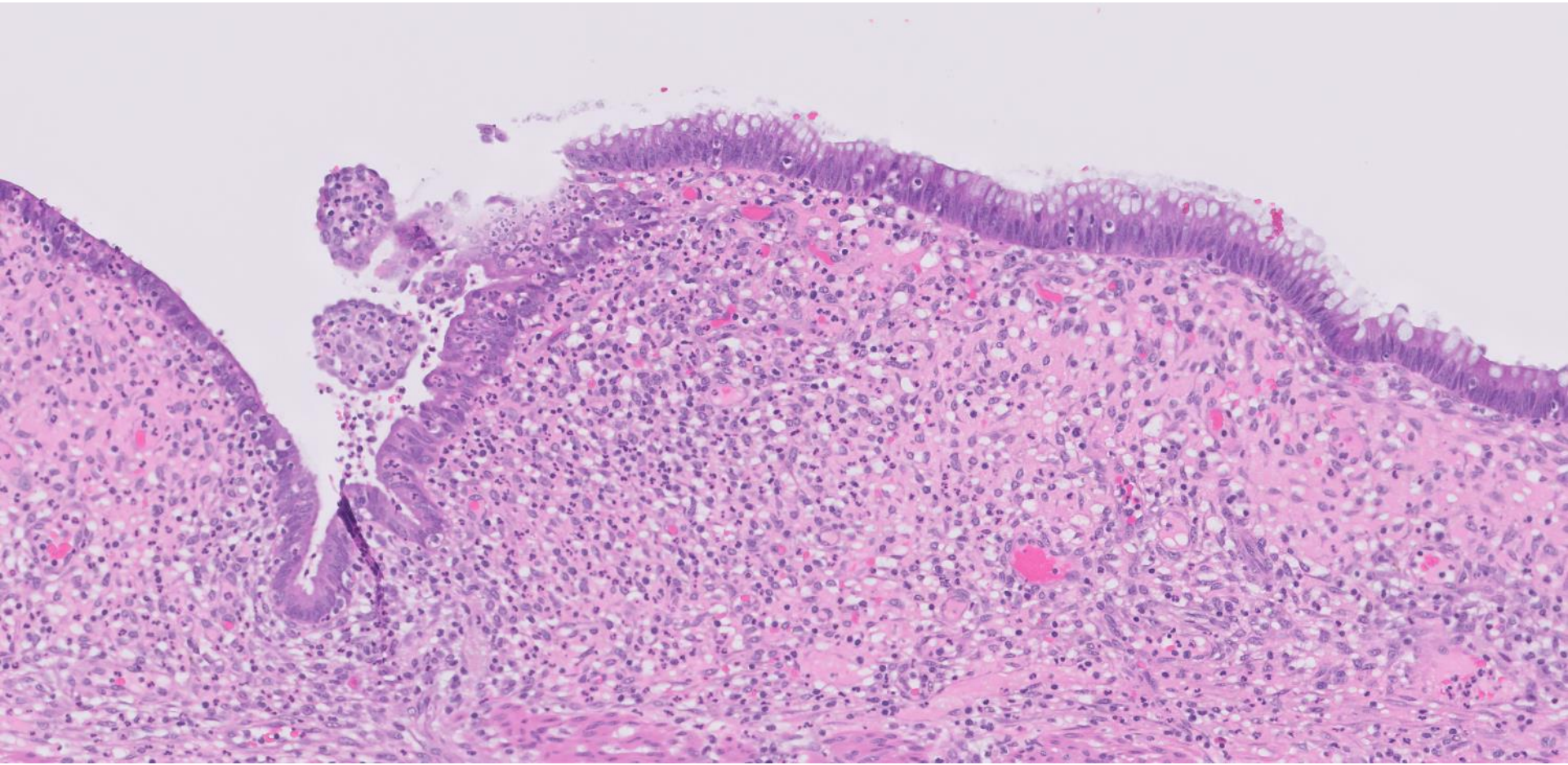














# Disclosures

## October 3, 2022

The planners and faculty listed below have no relevant financial relationship(s) to disclose with ineligible companies whose primary business is producing, marketing, selling, re-selling, or distributing healthcare products used by or on patients.

### **Presenters/Faculty:**

Emily Chan, MD  
Harris Goodman, MD  
Cindy Wang, MD  
Brent Tan, MD  
Jiajie (George) Lu, MD  
Serena Tan, MD  
Andrew Xiao, MD  
Chris Schwartz, MD  
Steve Long, MD  
Dave Bingham, MD

### **Activity Planners/Moderator:**

Kristin Jensen, MD  
Megan Troxell, MD  
Ankur Sangoi, MD

QR code for post-meeting evaluation form

