

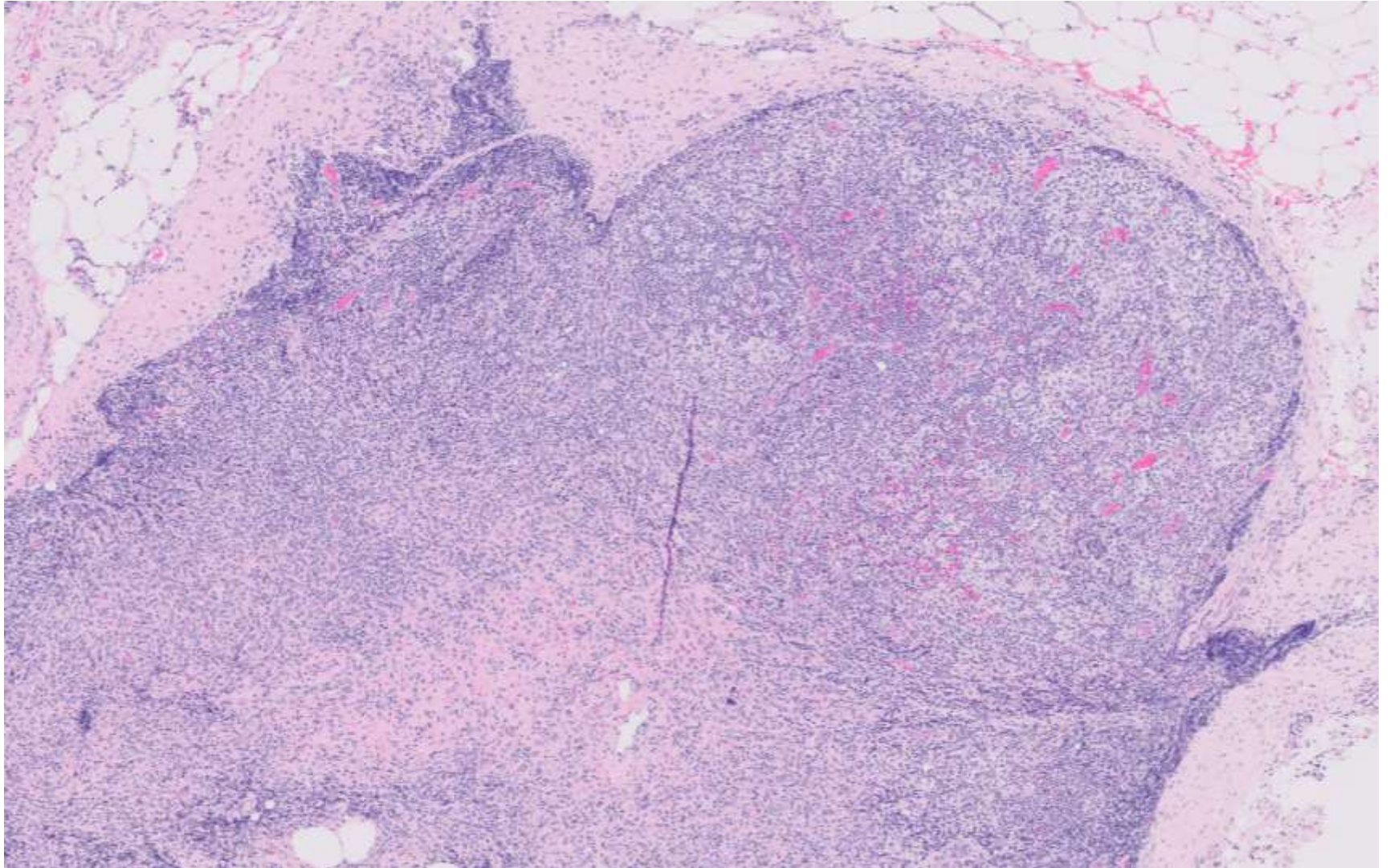
EVALUATION QR CODE!  
Hold smartphone camera on code



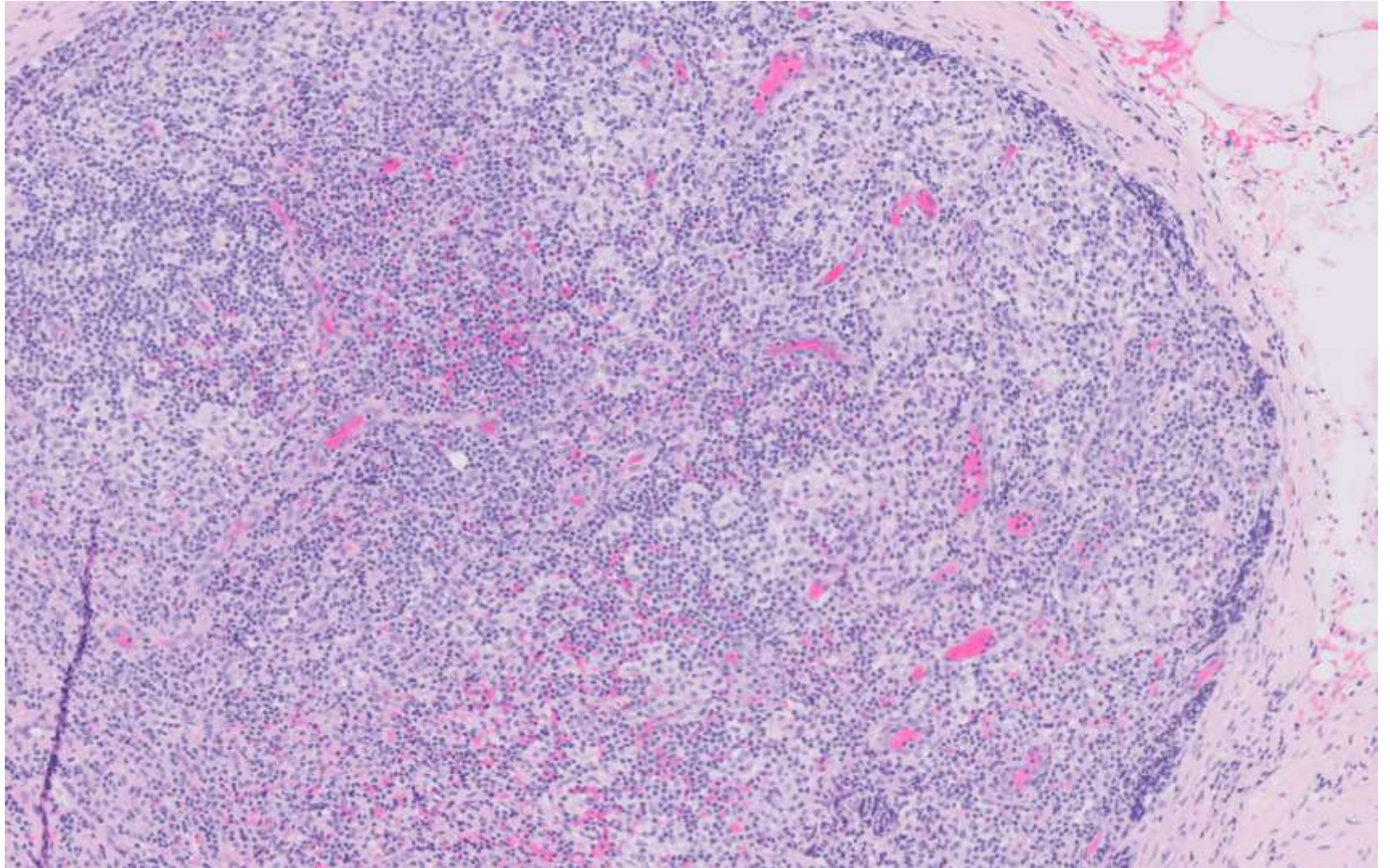
# 22-0801

**Marietya Lauw/George Xu; Stanford**

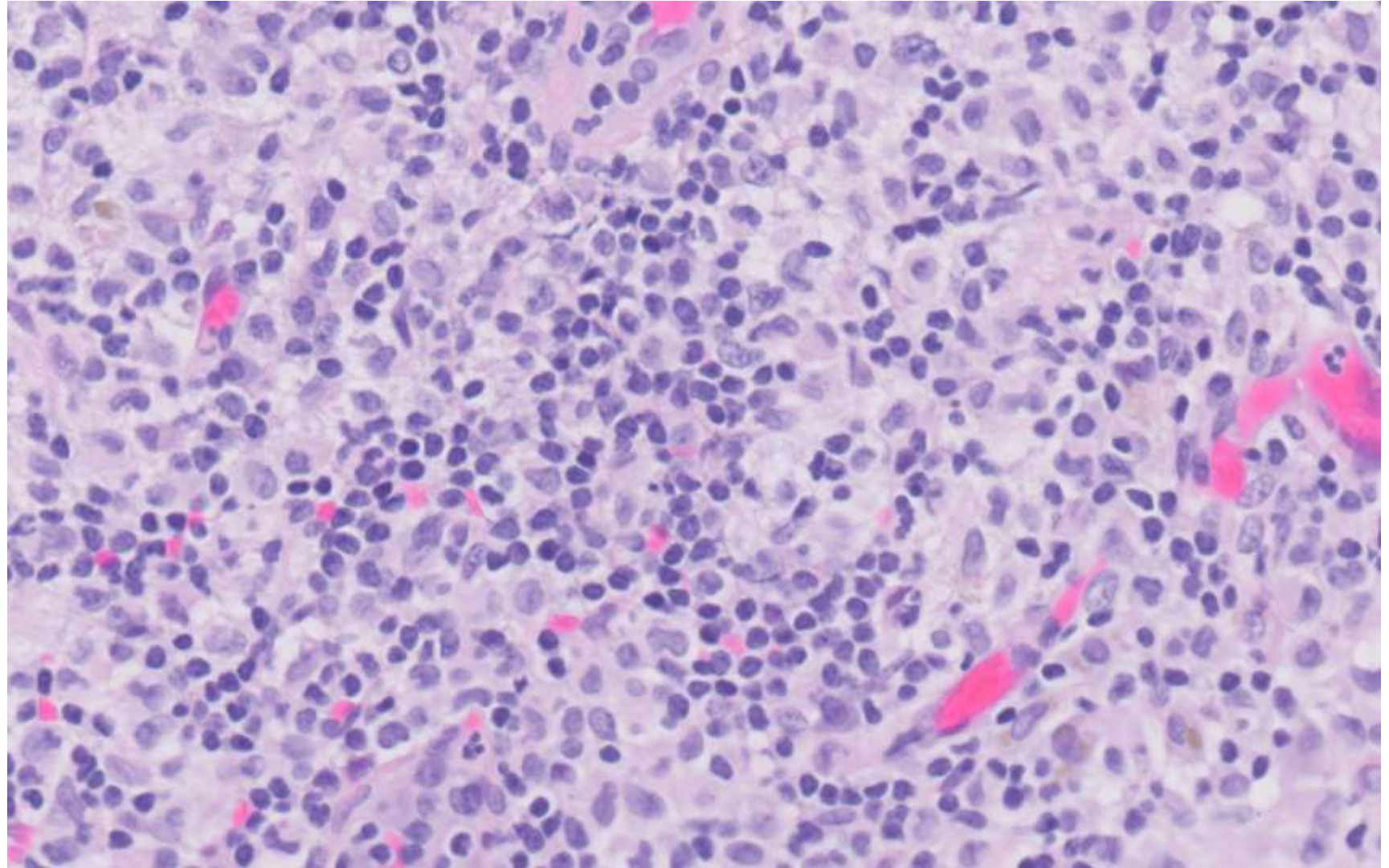
70ish F with inguinal lymphadenopathy. Flow cytometry detected no immunophenotypic abnormalities. Right groin lymph node submitted.





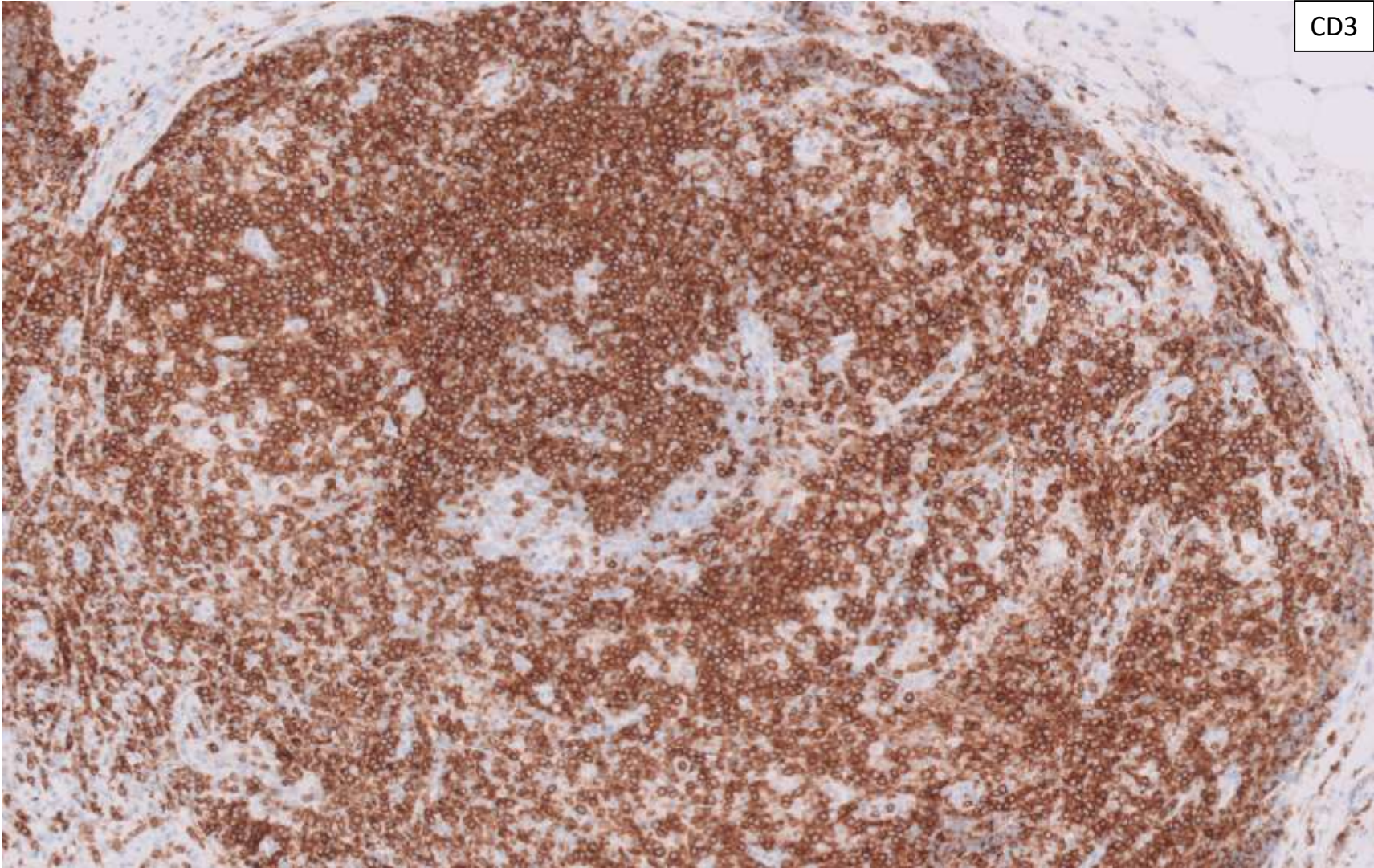





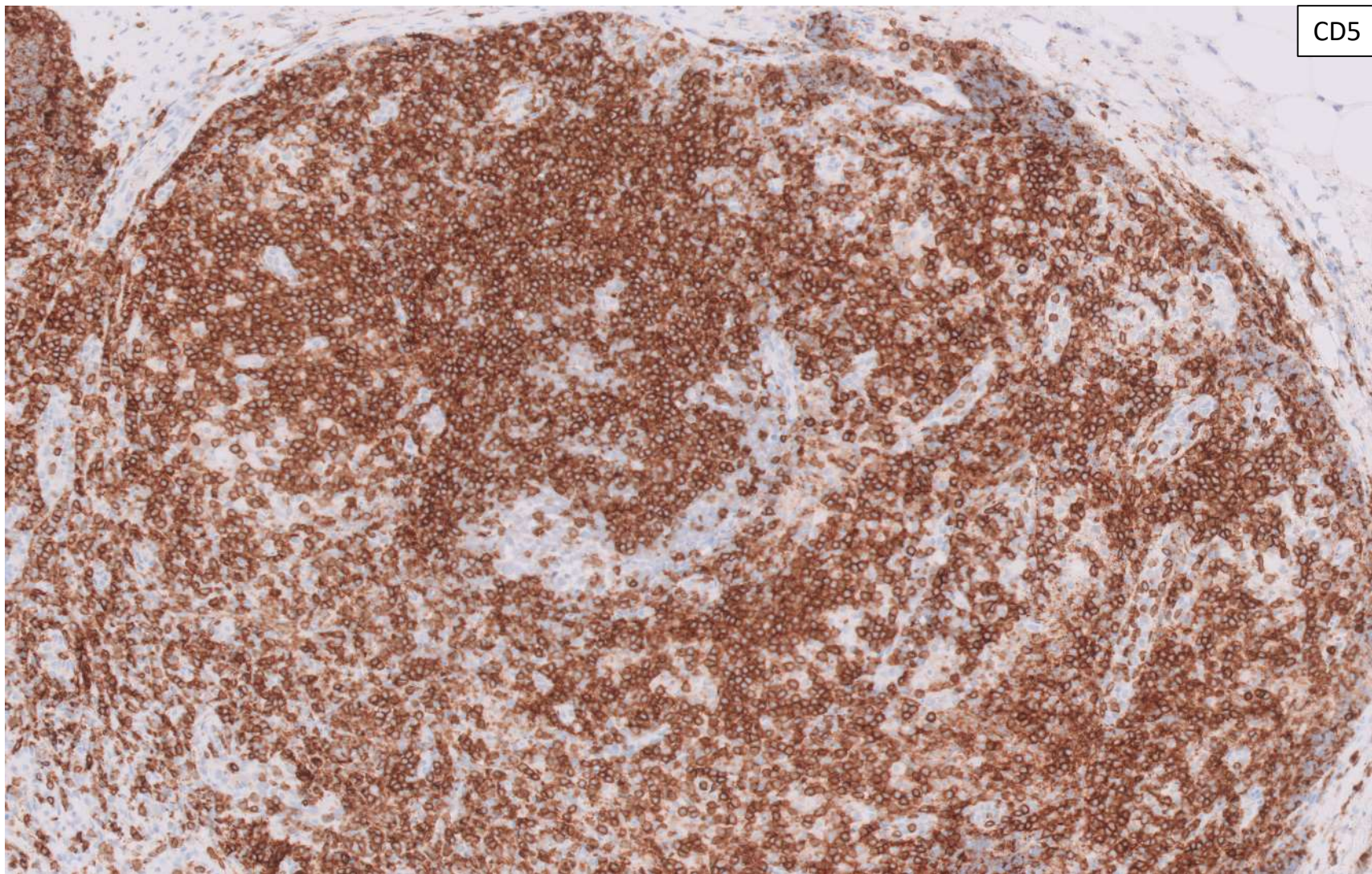


CD3

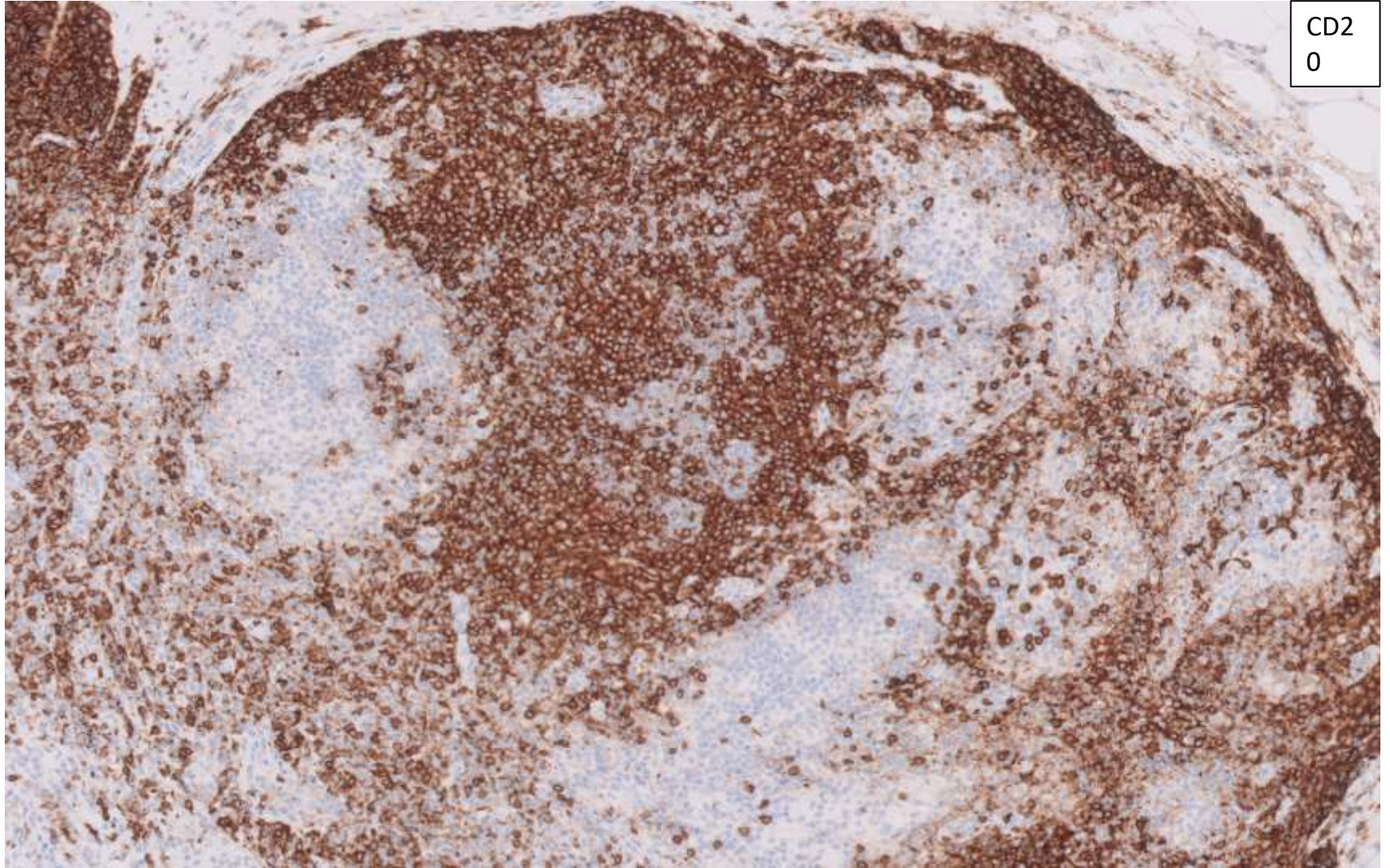




CD5



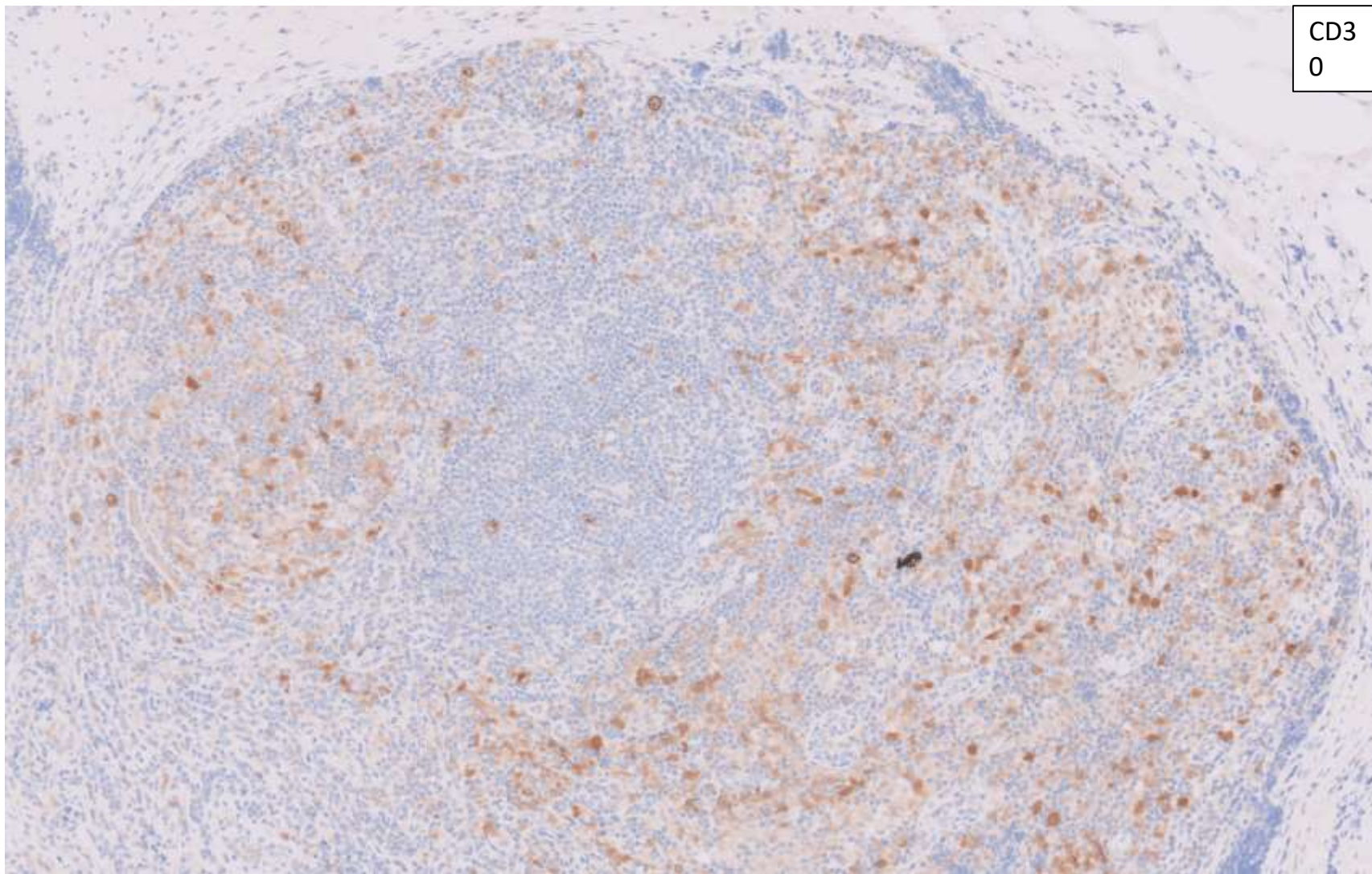




CD20  
0

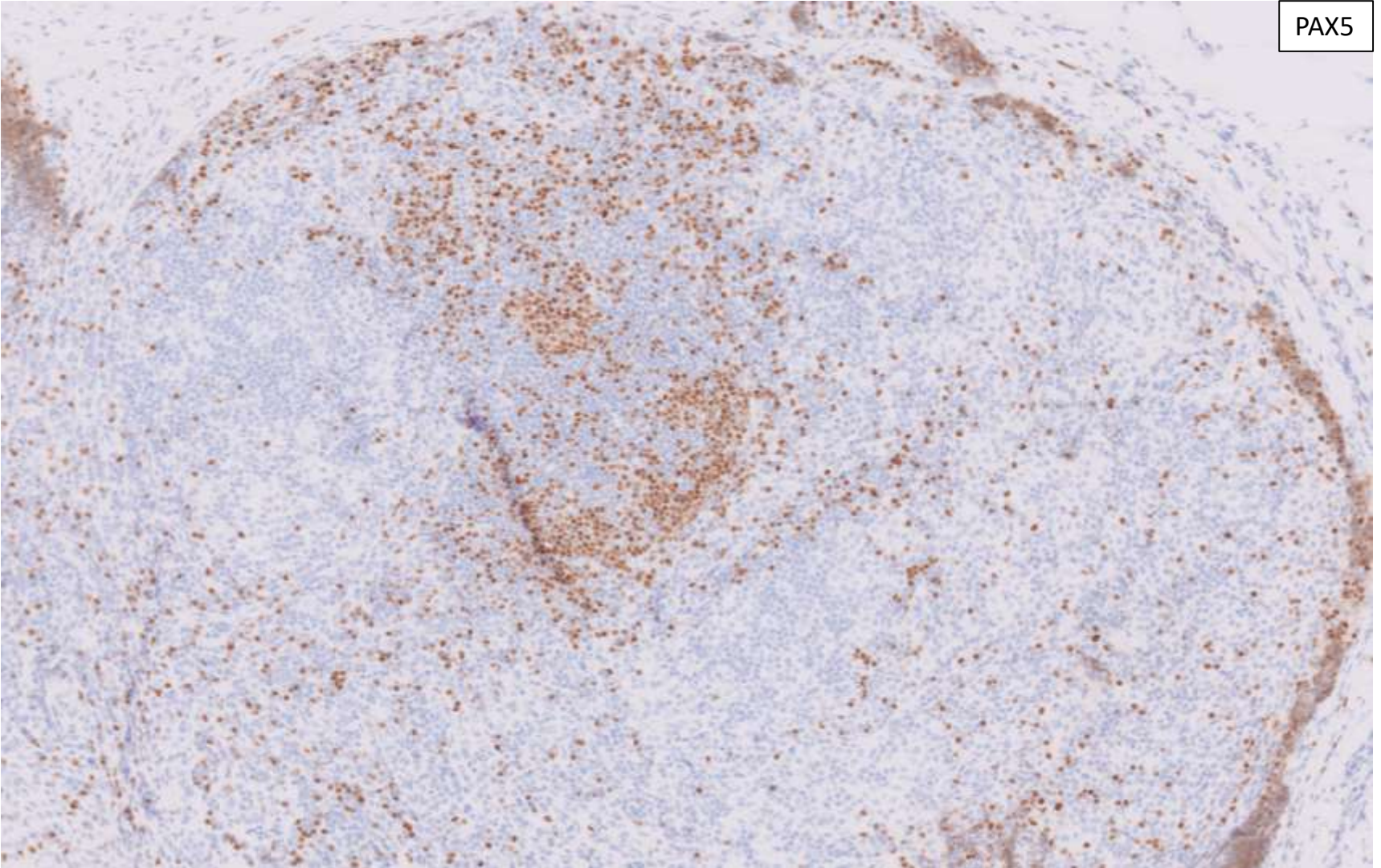


CD3  
0



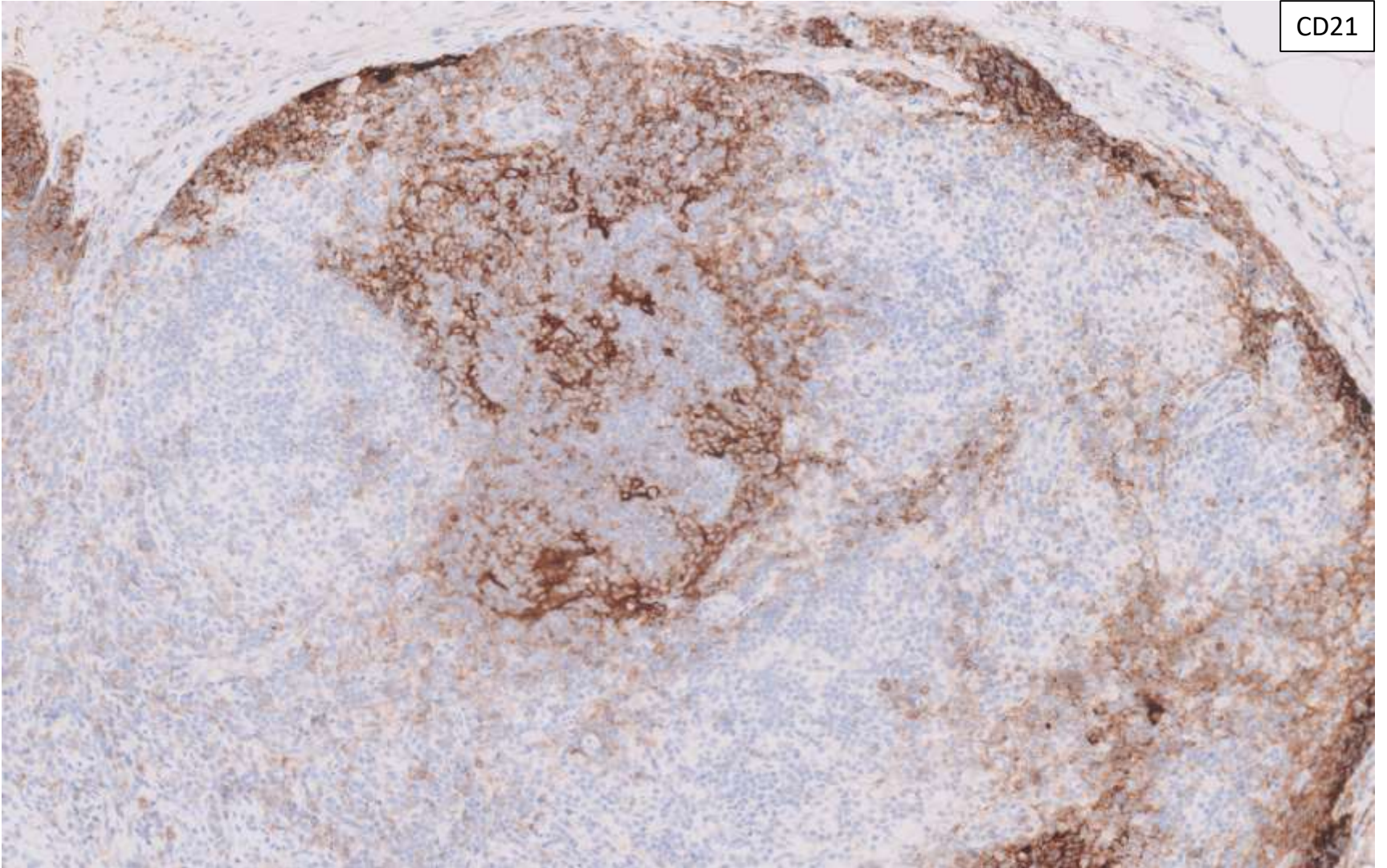


PAX5

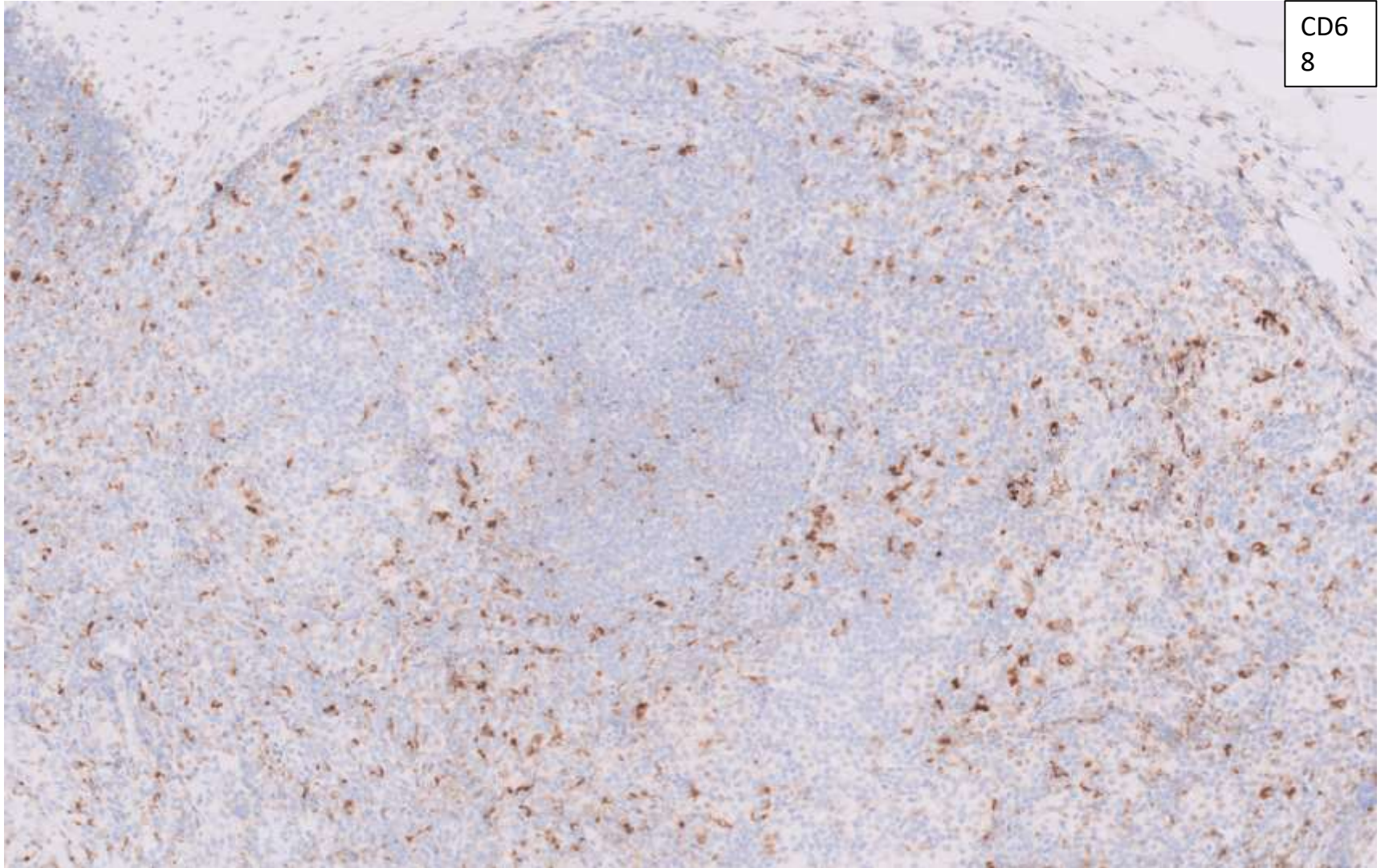




CD21



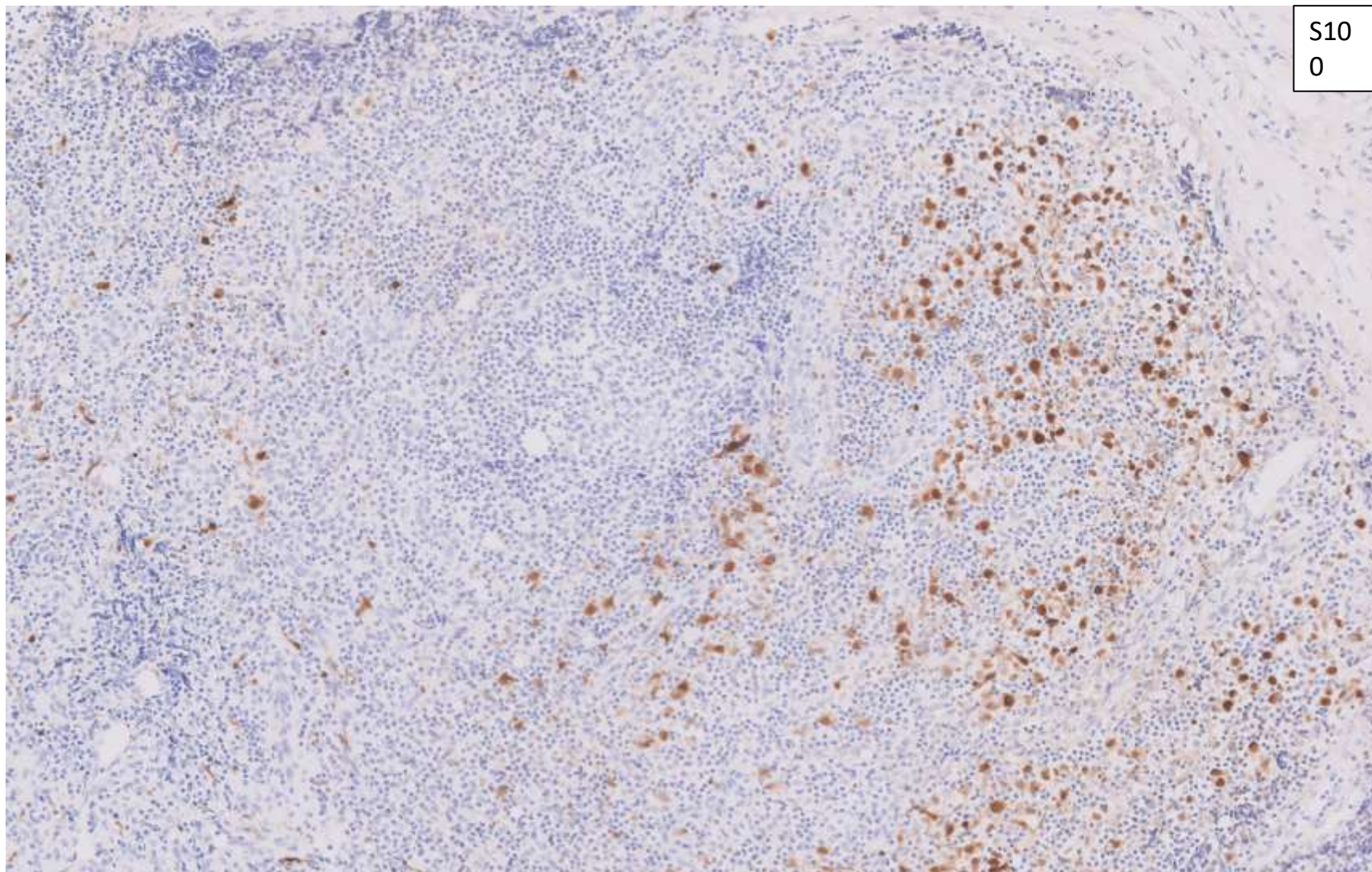




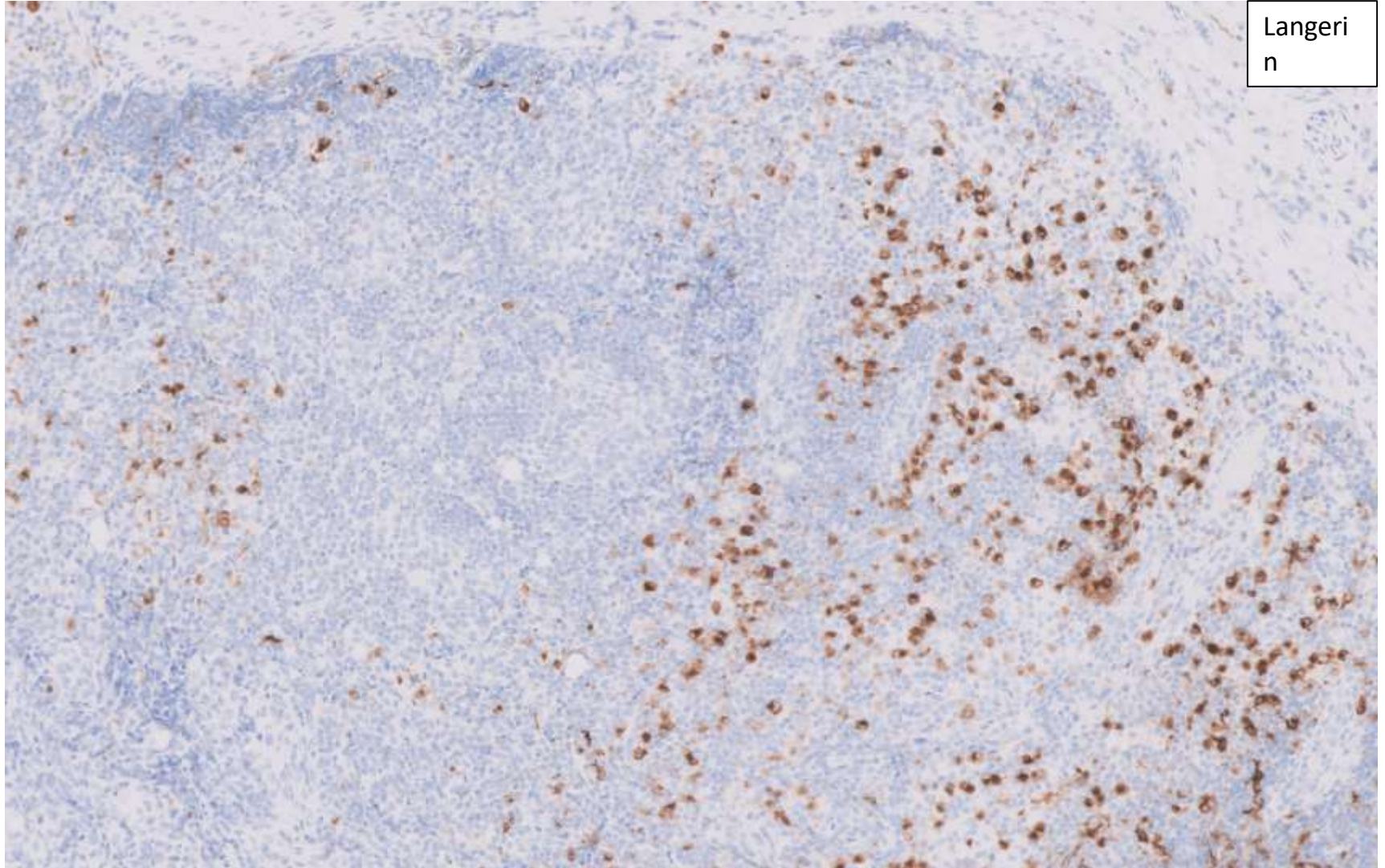
CD68  
8



S10  
0



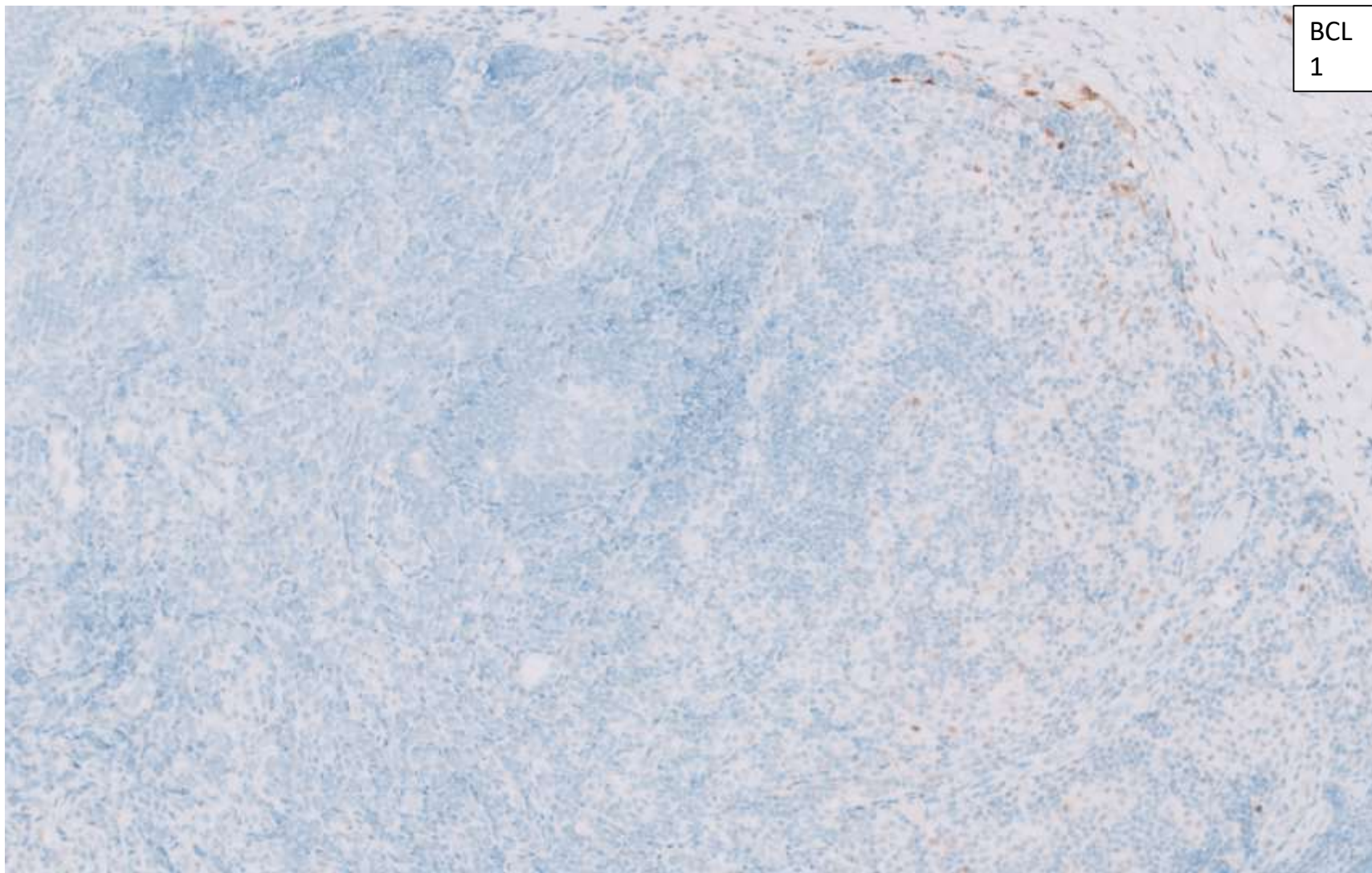




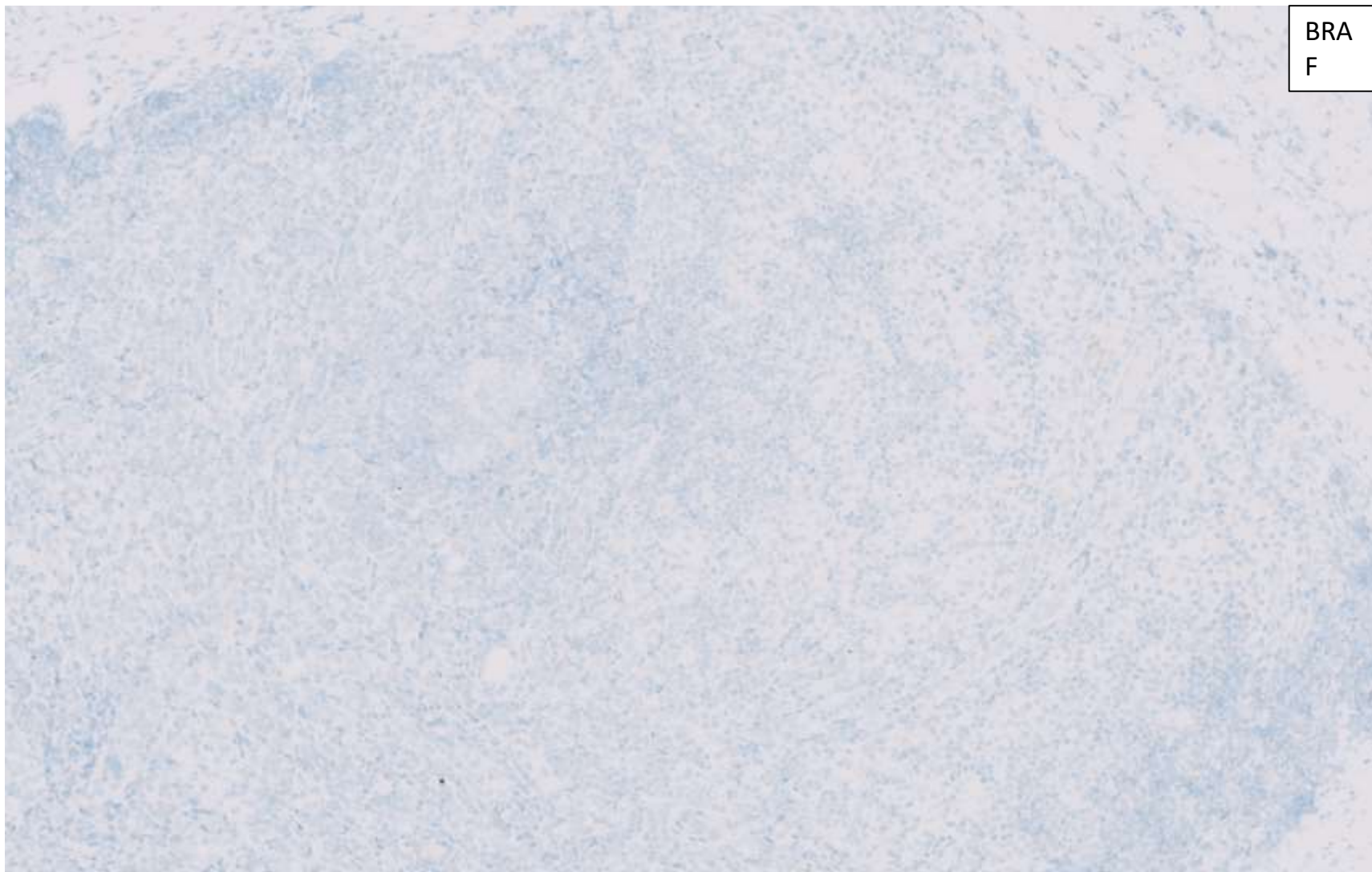
Langeri  
n



BCL  
1



BRA  
F

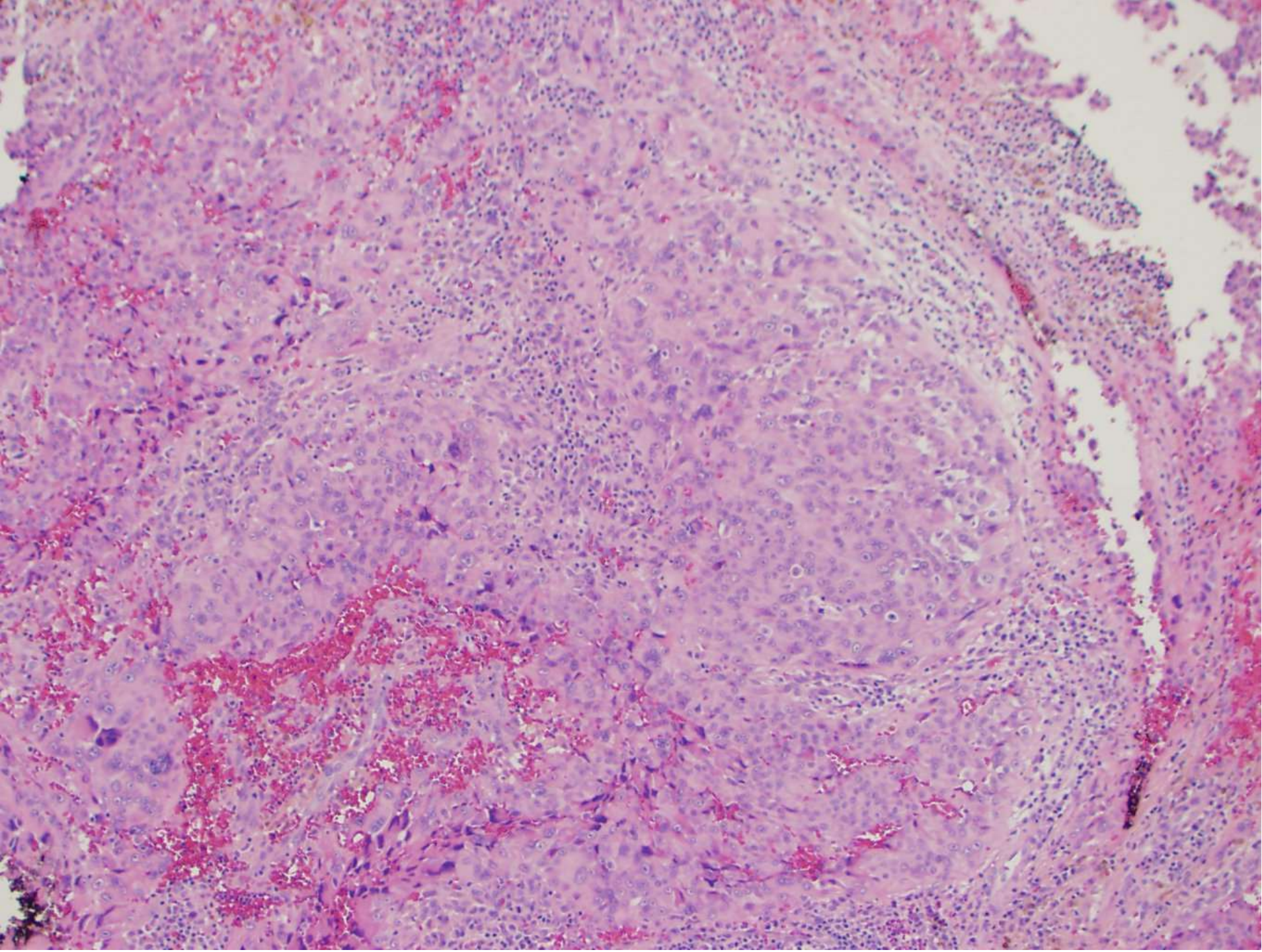




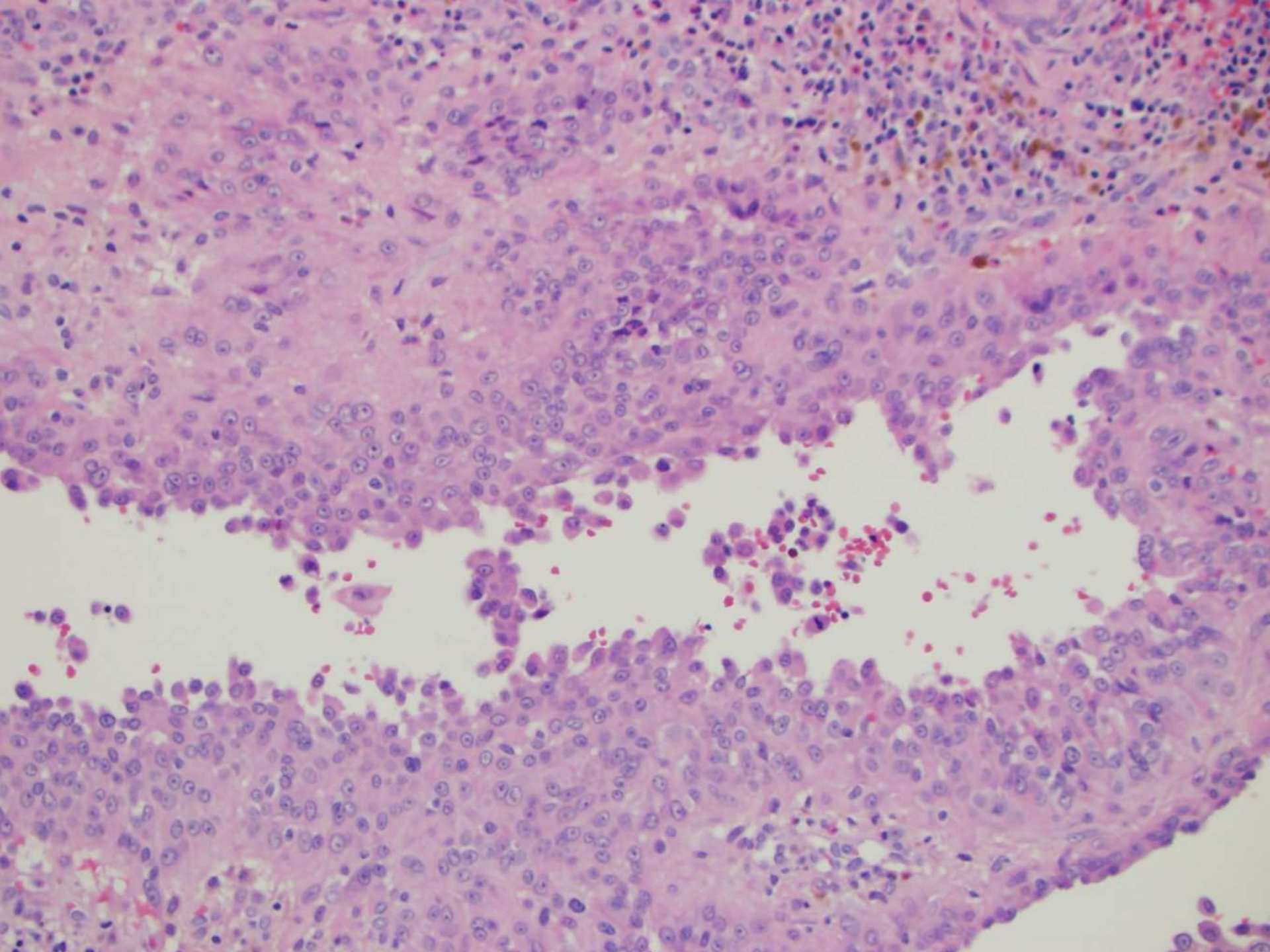
22-0802

**Greg Rumore; Kaiser Diablo**  
20ish F with vulvar cyst/mass.

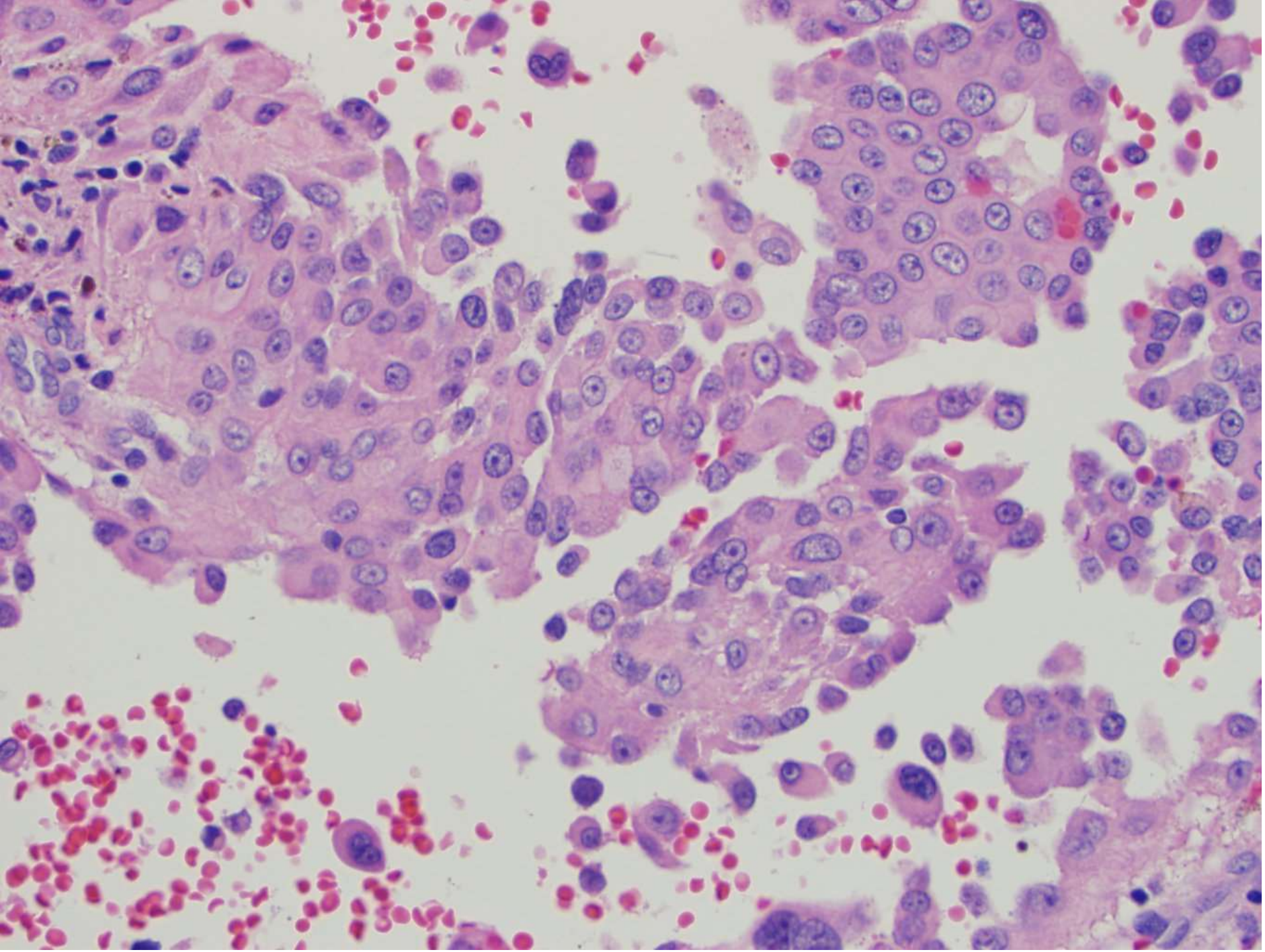




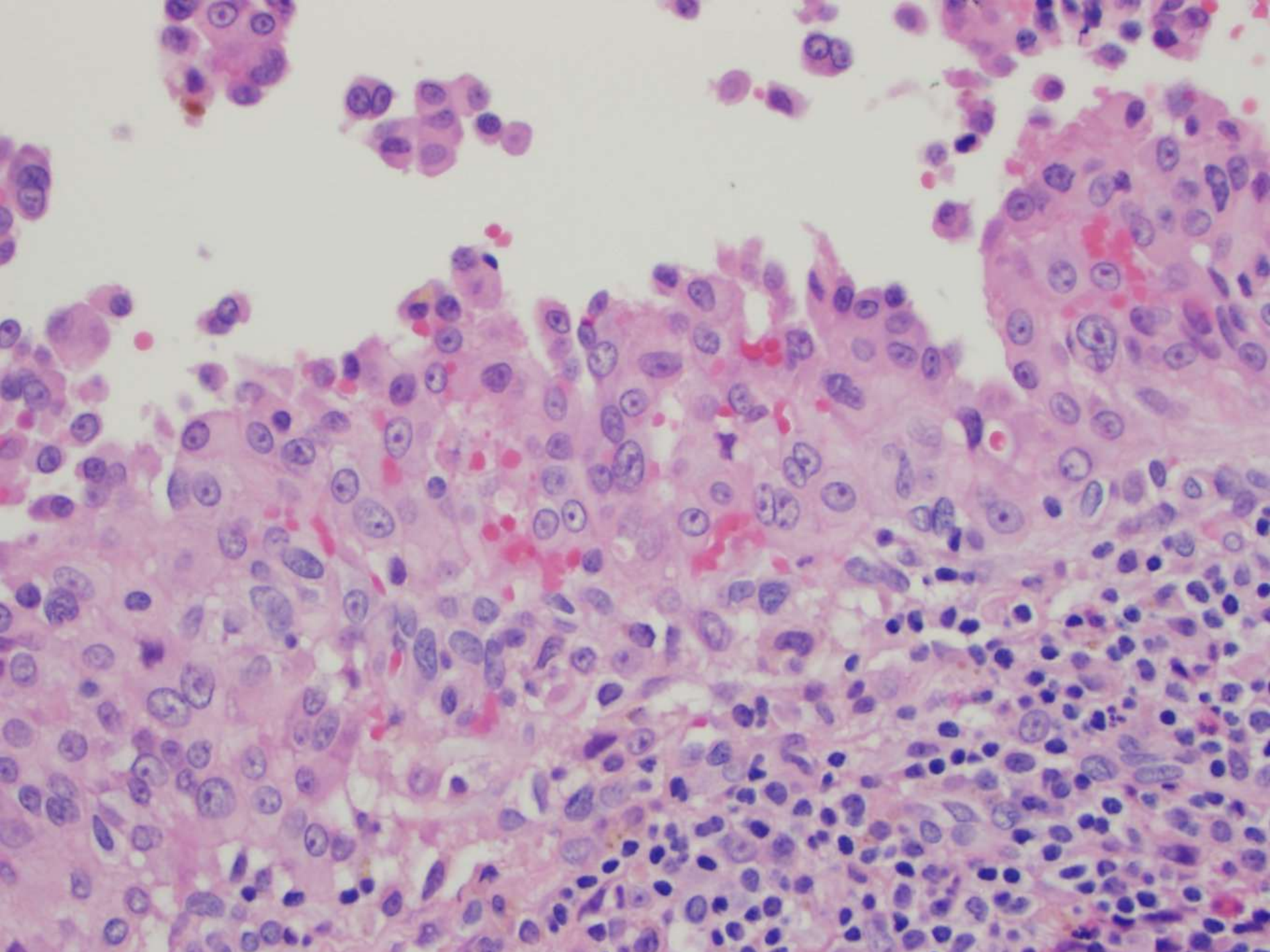




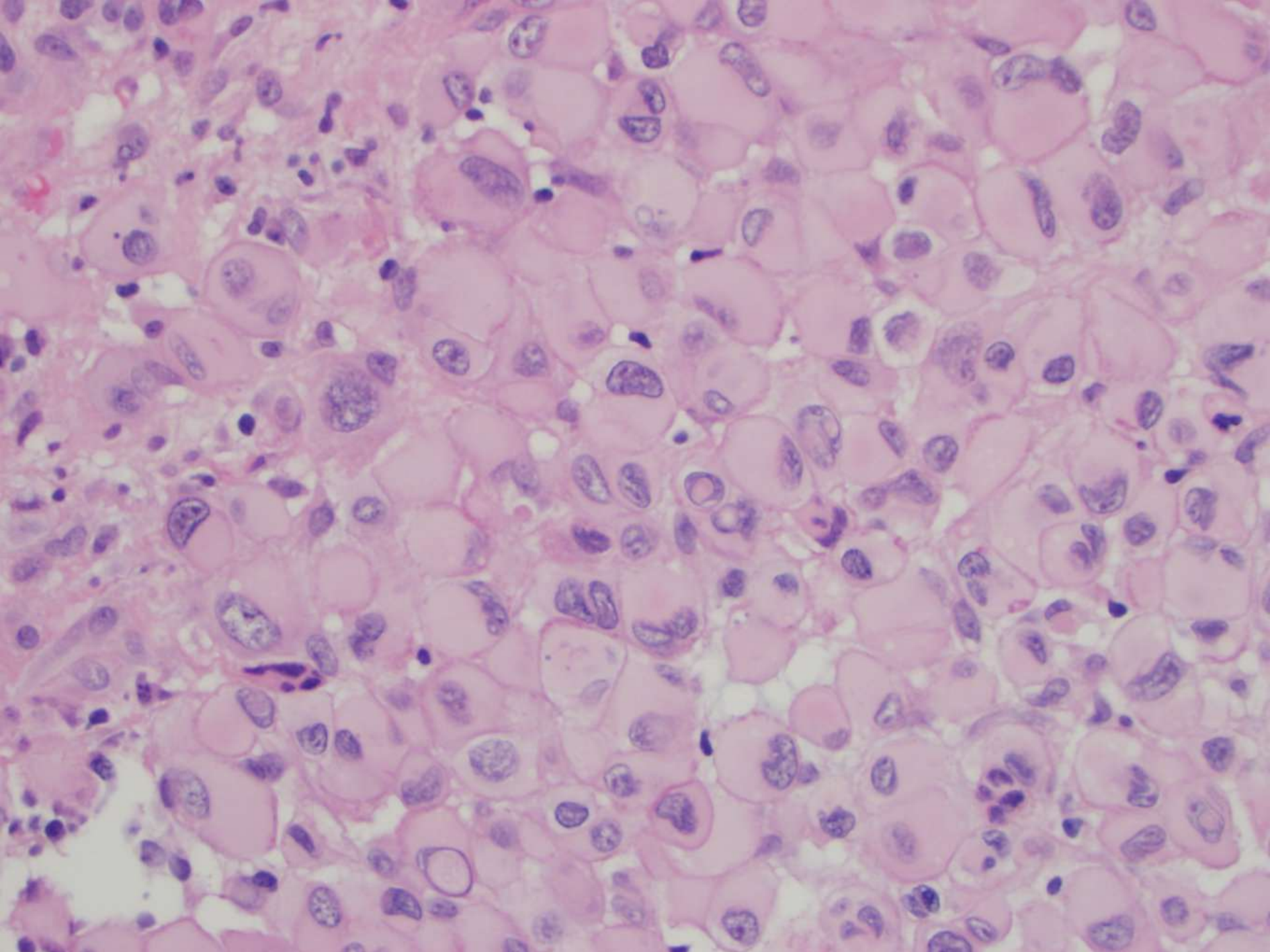




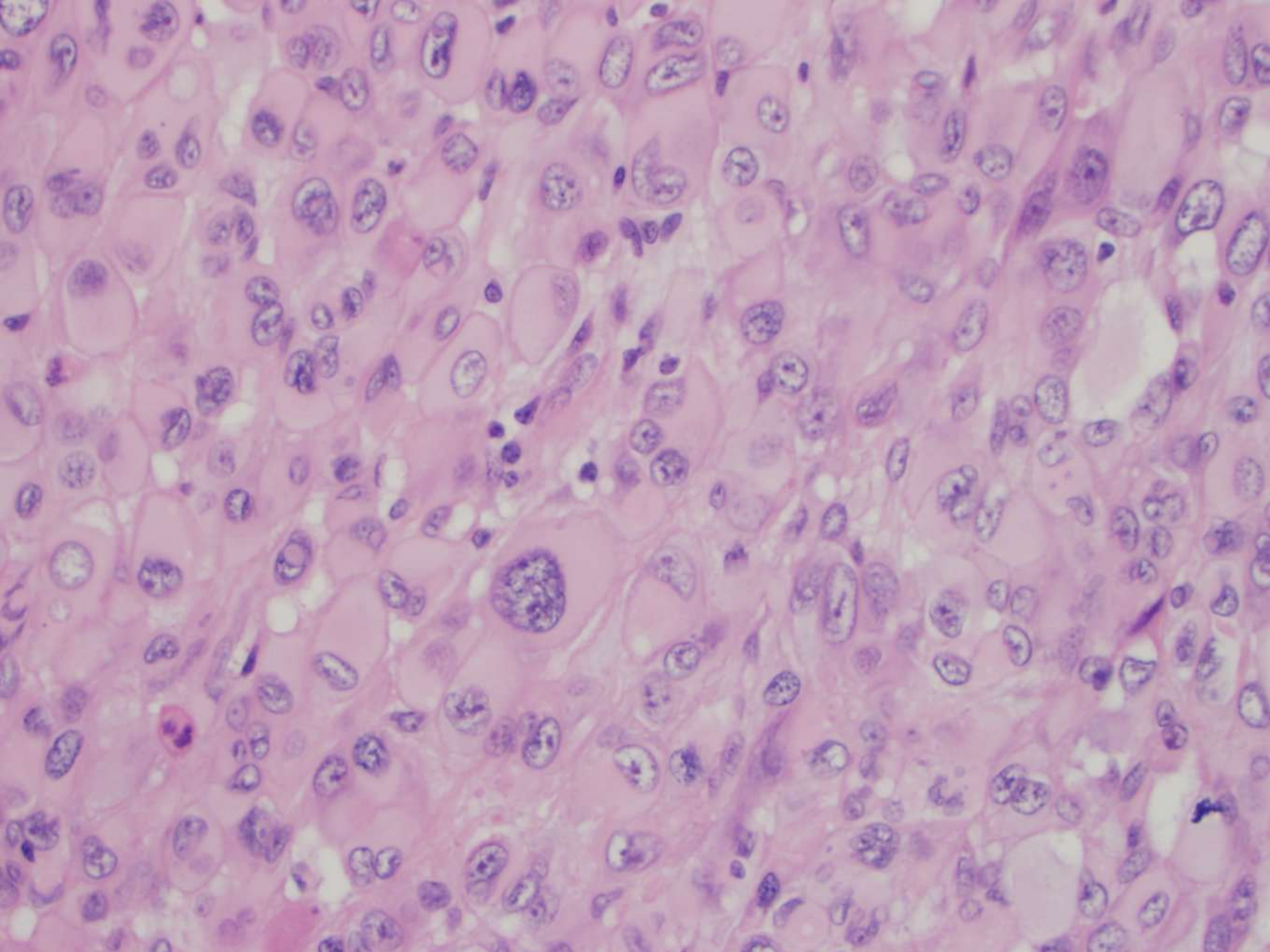


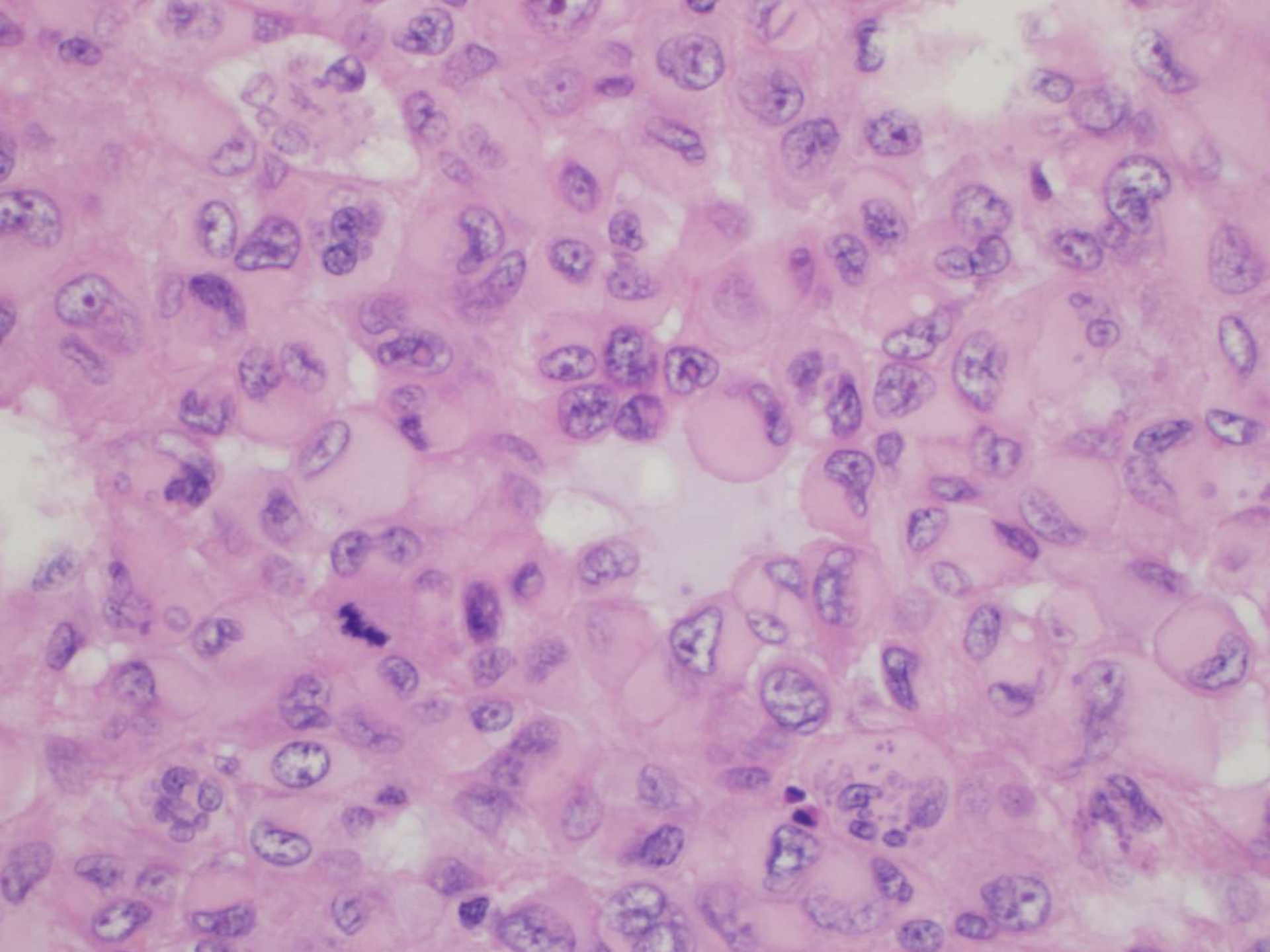














22-0803

**Alexandra Chang-Graham/Joshua Menke; Stanford**

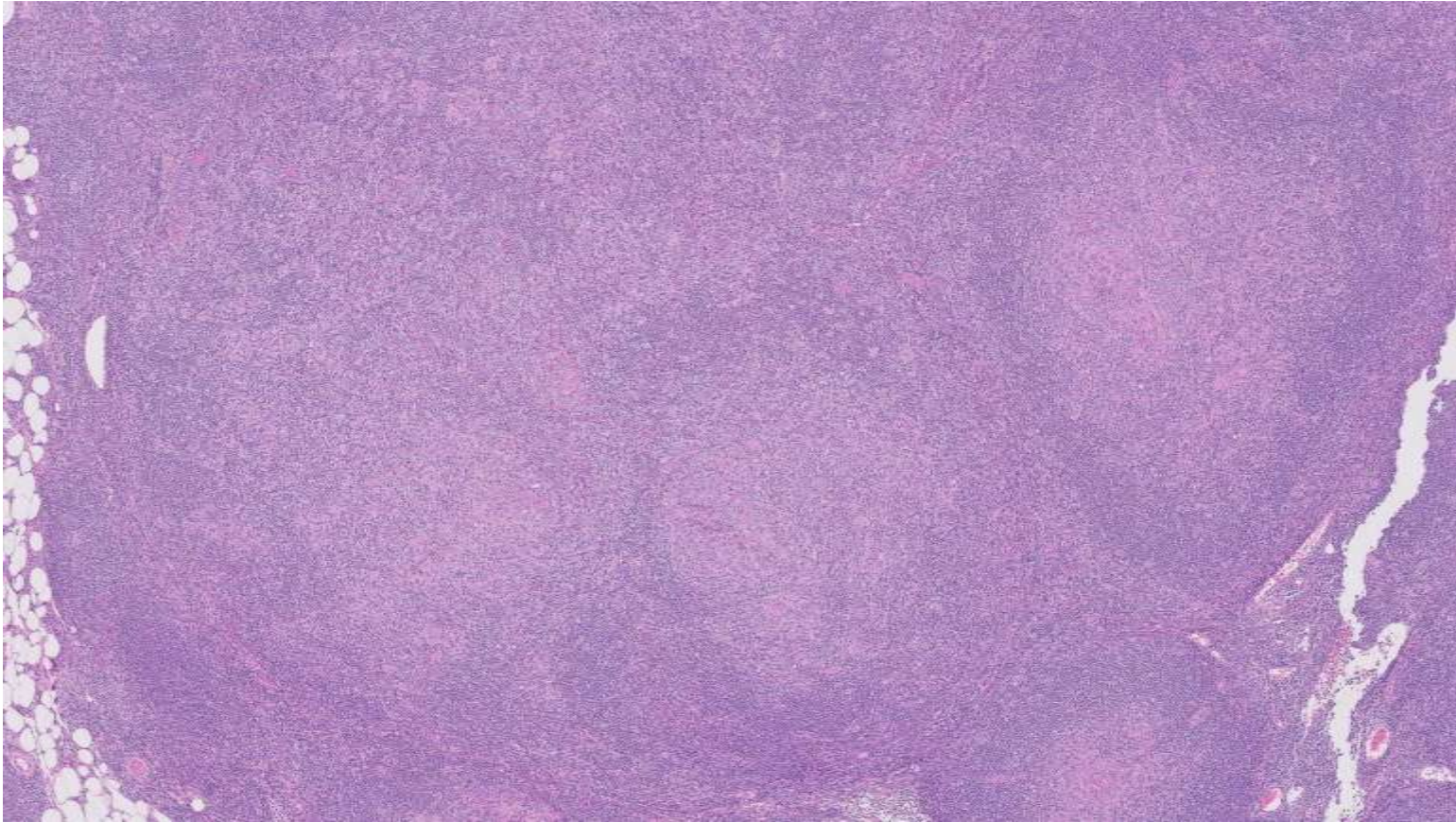
60ish F with h/o “atypical Hodgkin lymphoma” with recurrence two years after standard classic Hodgkin lymphoma therapy (ABVD). Lymph node submitted.

# 60ish F with "atypical Hodgkin lymphoma" and recurrent adenopathy

Alex Chang-Graham, Sebastian Fernandez-Pol, Joshua Menke  
Stanford University  
South Bay

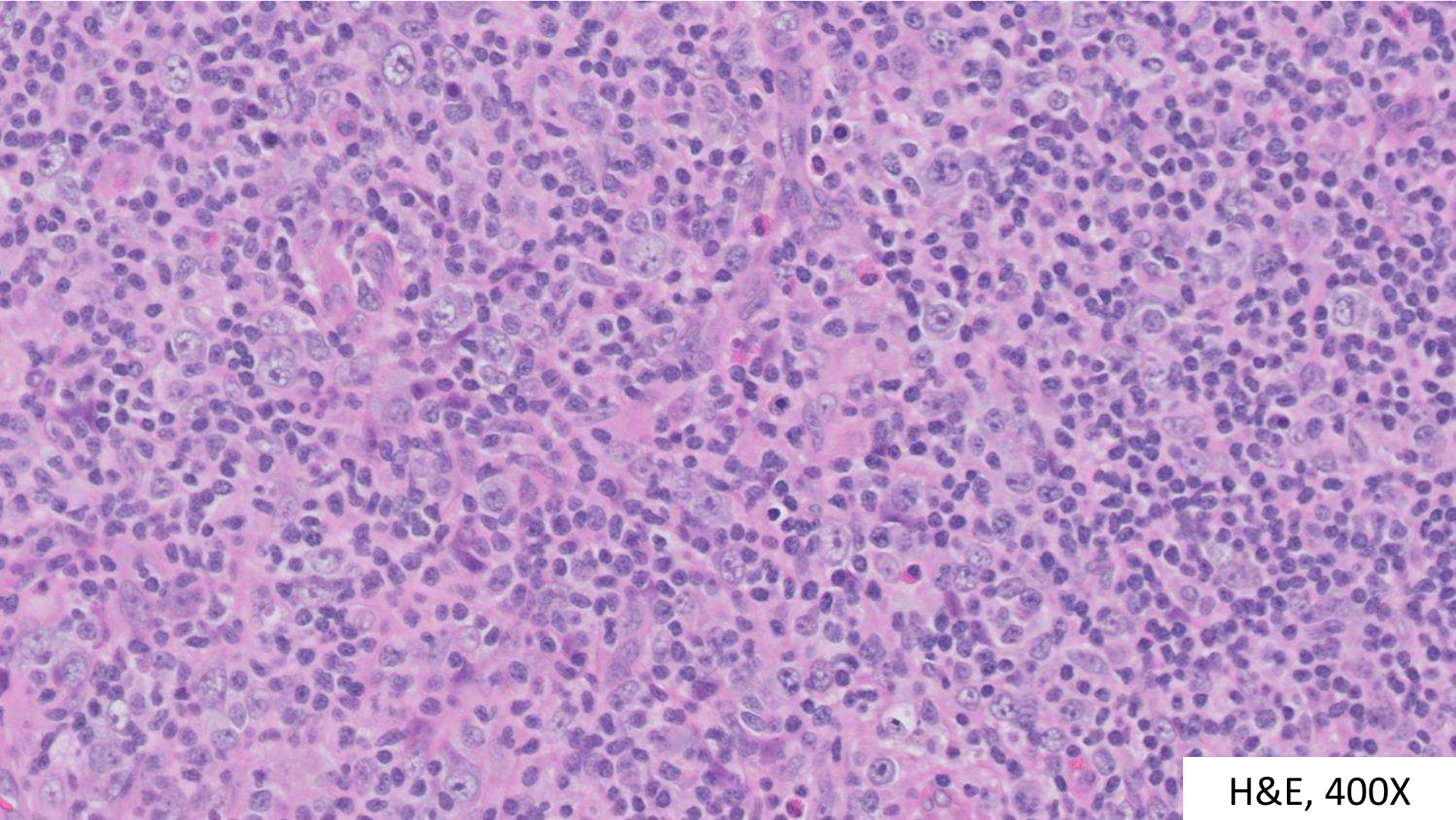


Clinical History: Elderly woman presenting with a history of "atypical Hodgkin lymphoma" s/p 2 cycles of ABVD and 5 cycles of AVD, now with recurrent adenopathy above and below the diaphragm. Right inguinal lymph node excisional biopsy was performed.



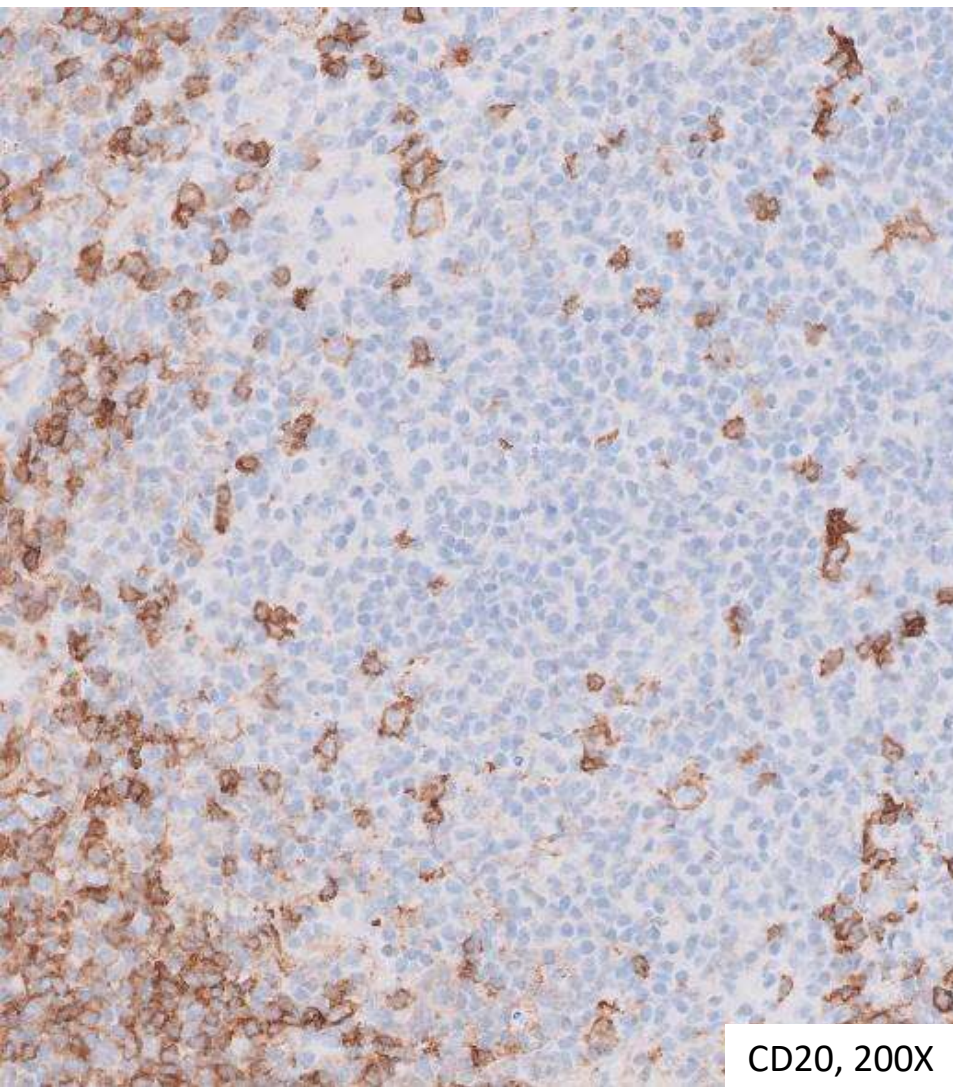
H&E,  
50X



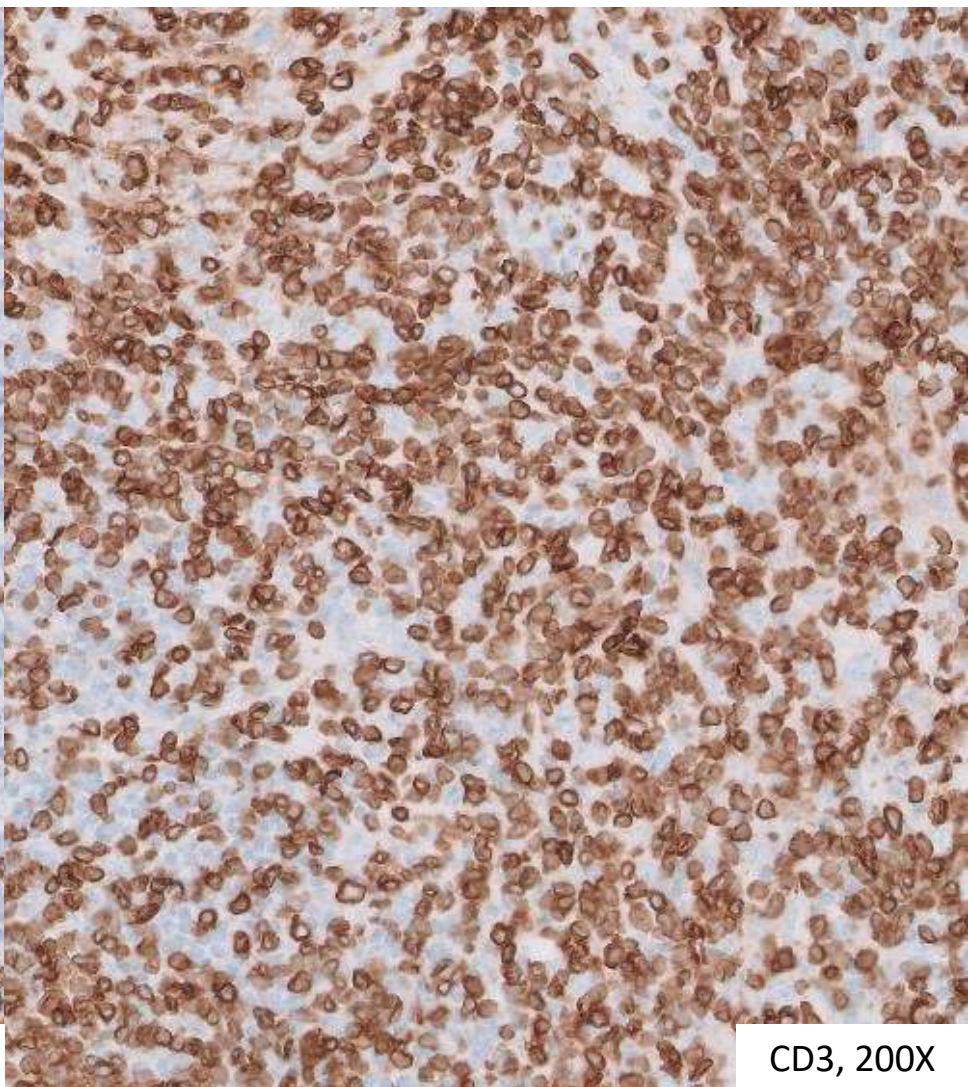


H&E, 400X



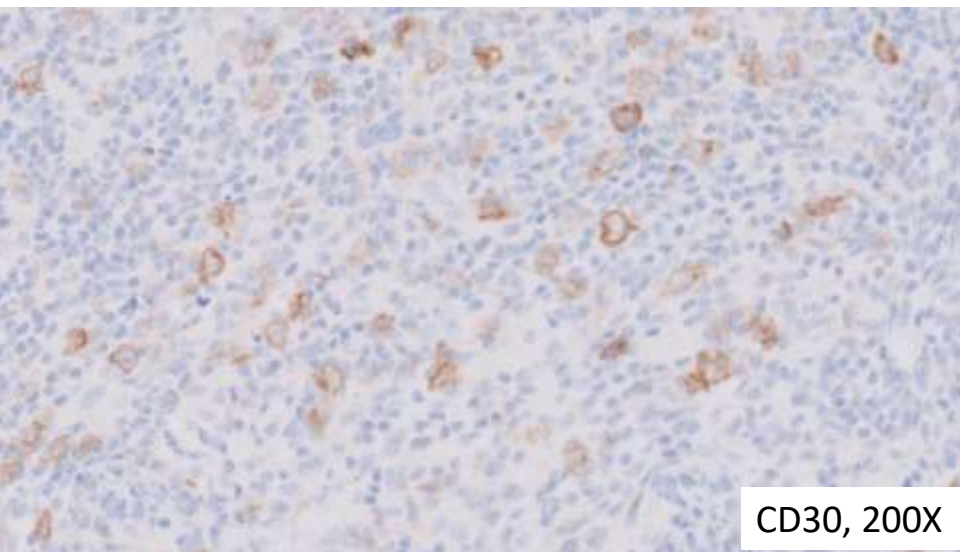


CD20, 200X

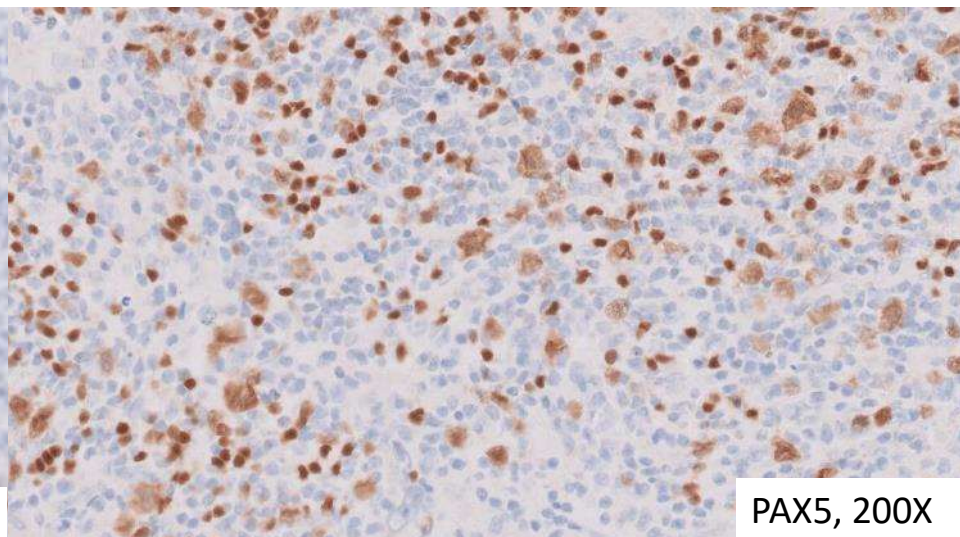


CD3, 200X

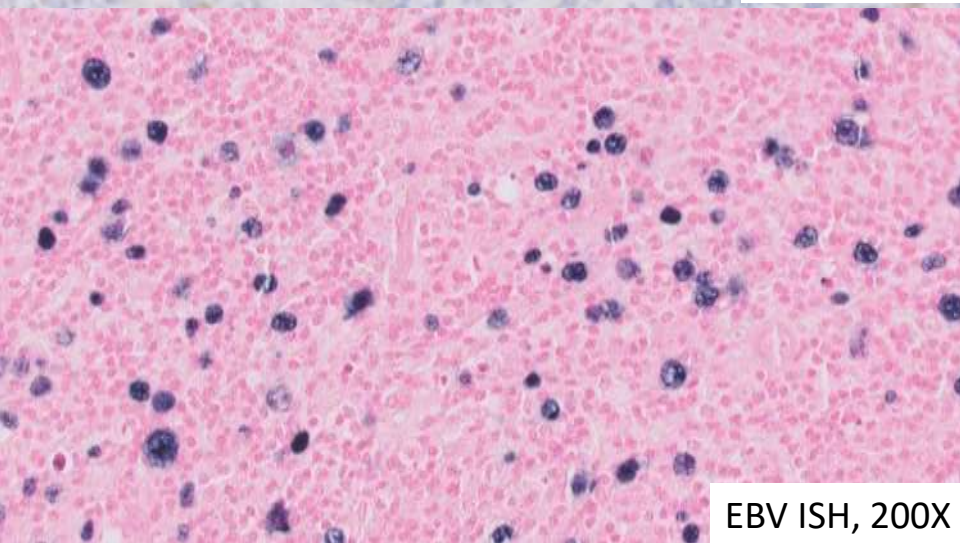




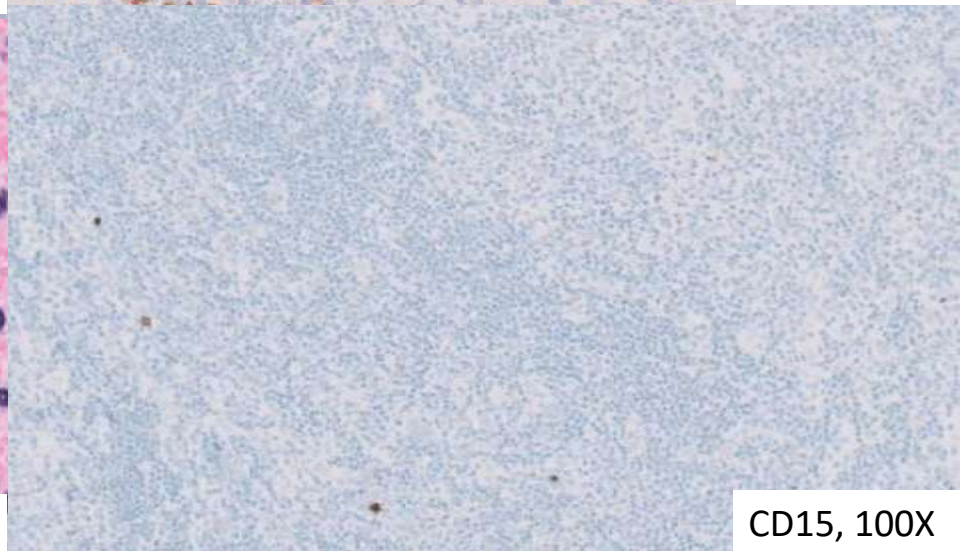
CD30, 200X



PAX5, 200X

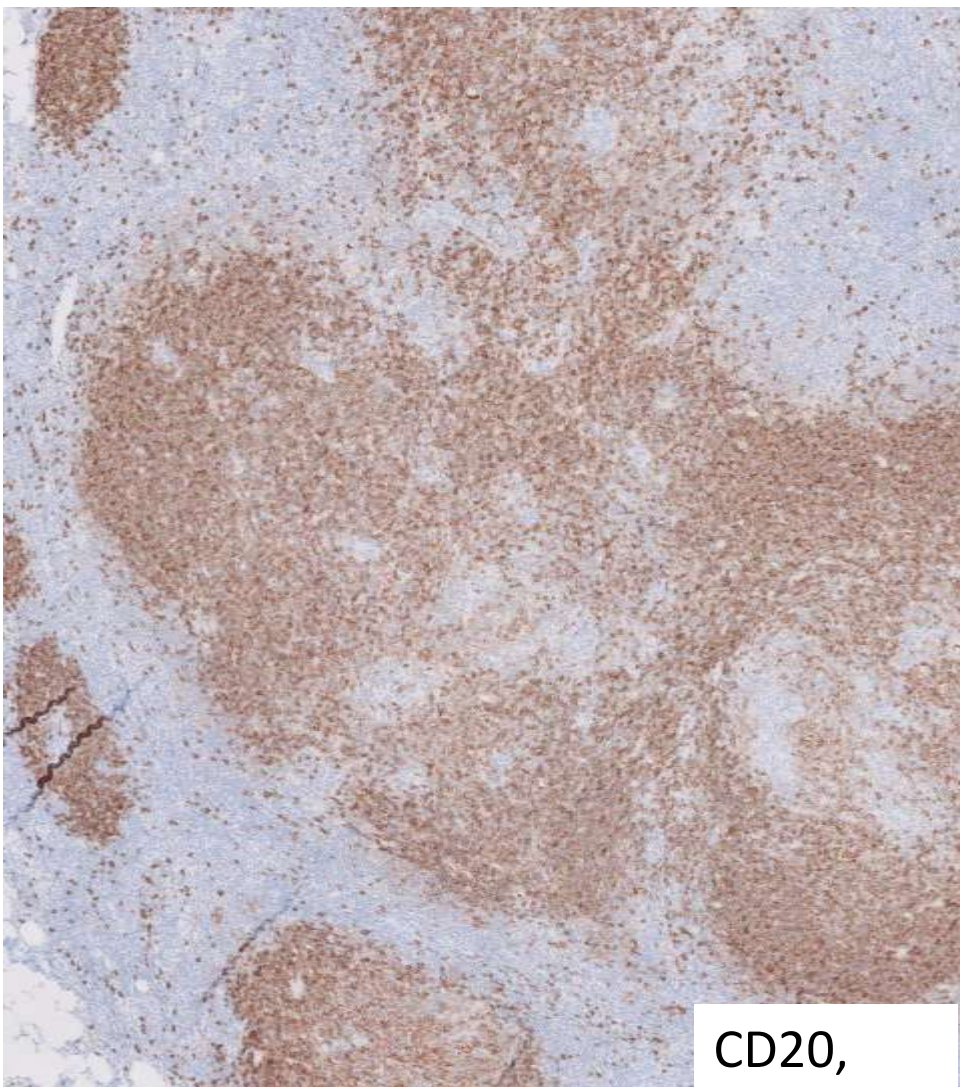


EBV ISH, 200X

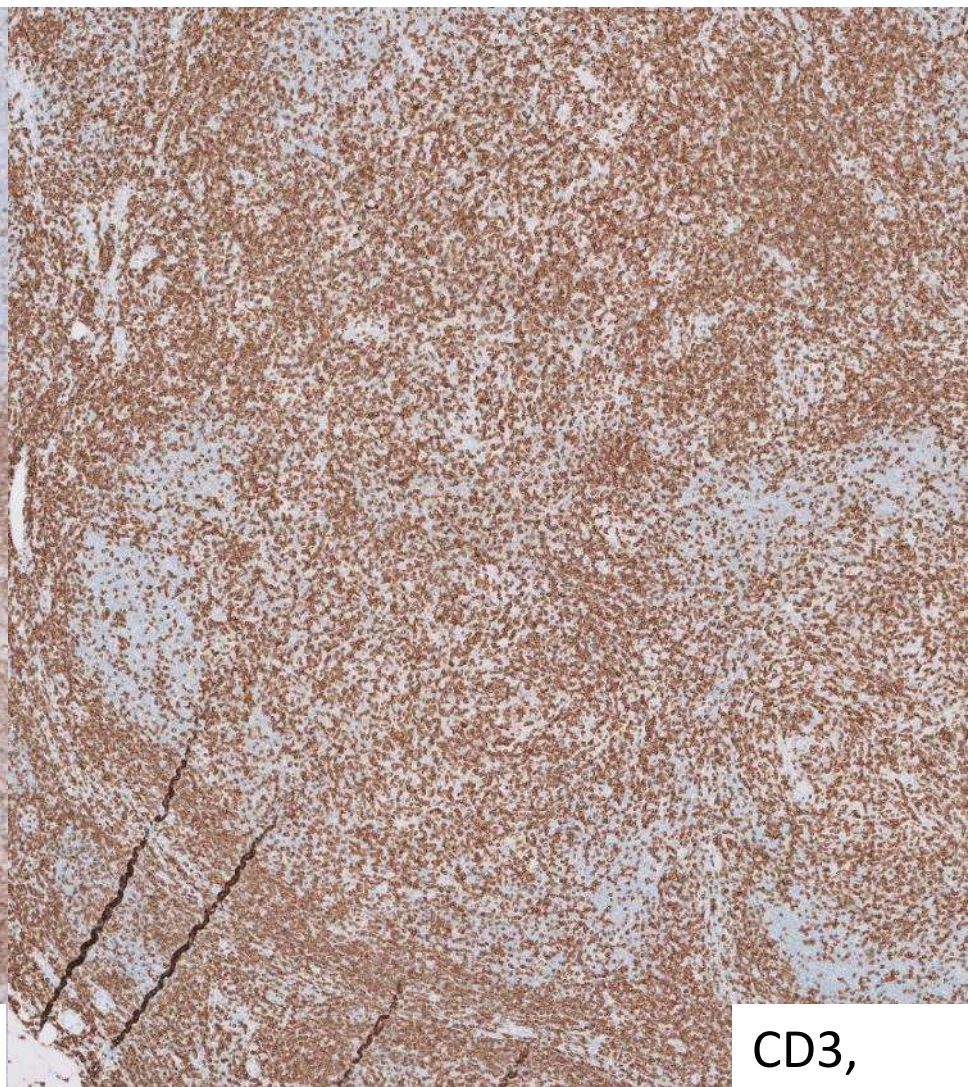


CD15, 100X



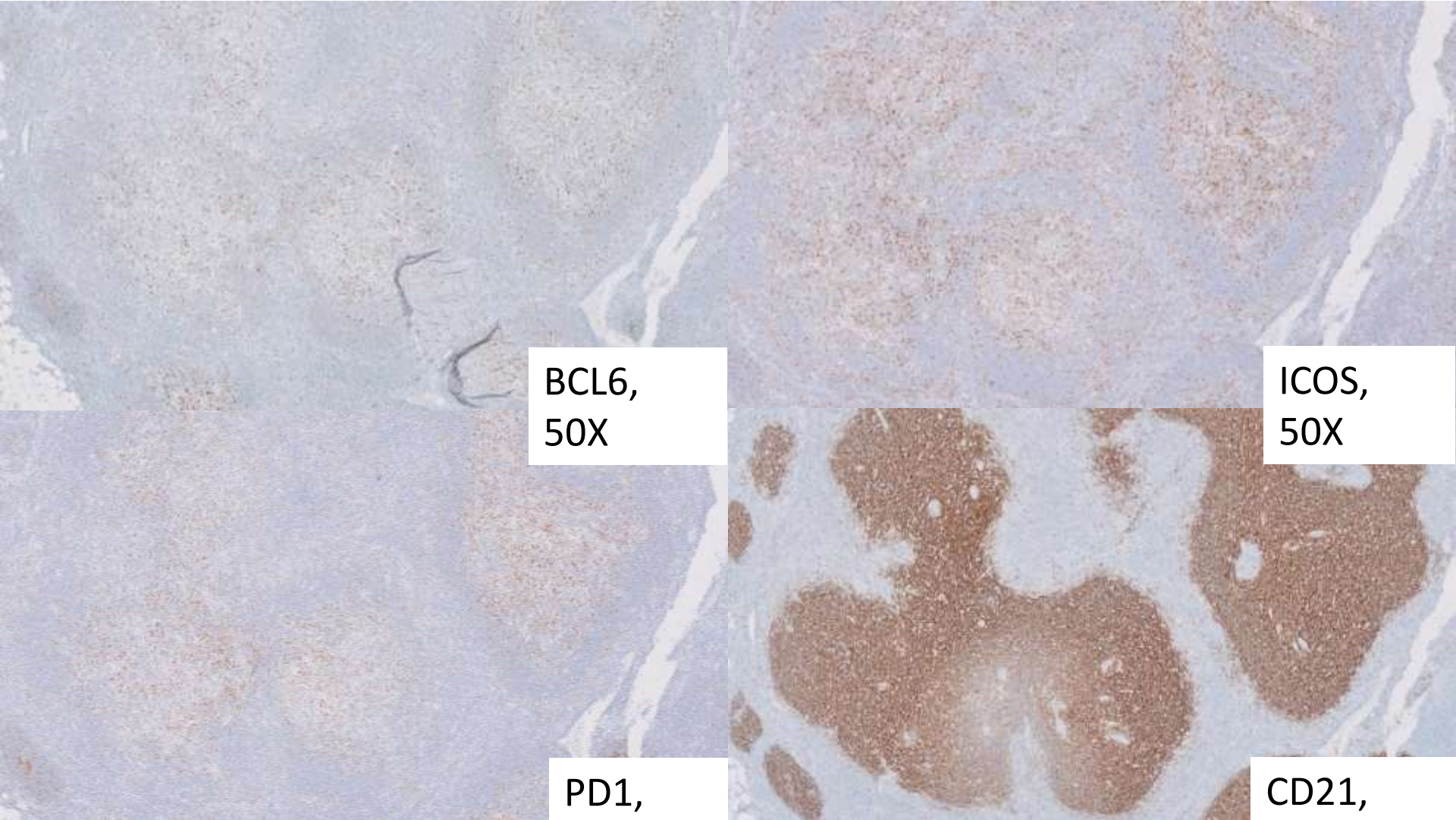


CD20,  
50X



CD3,  
50X





BCL6,  
50X

ICOS,  
50X

PD1,  
50X

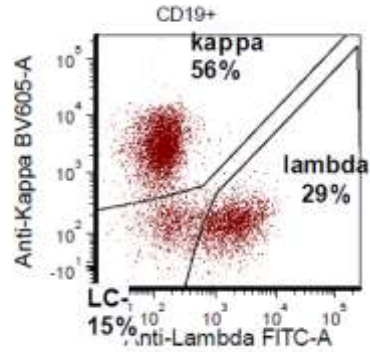
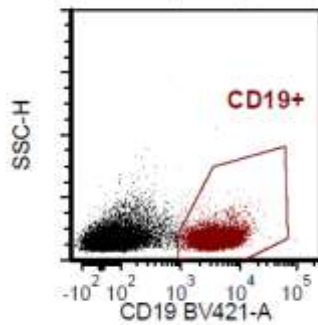
CD21,  
50X



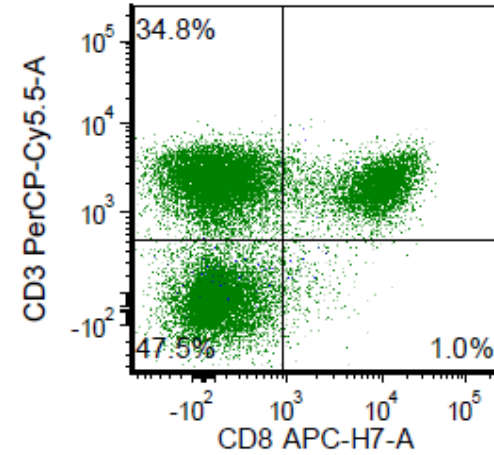
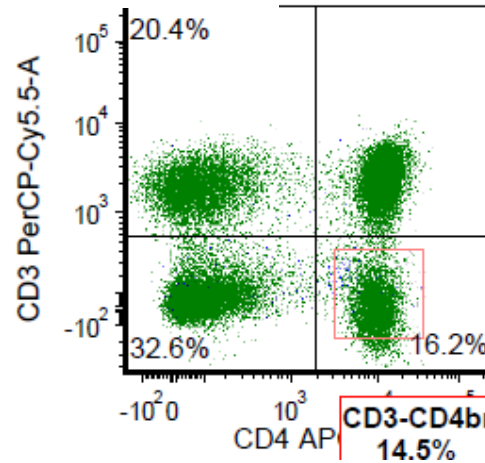
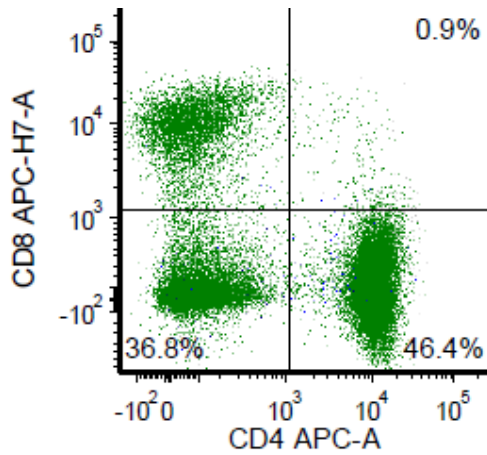
# Flow cytometry

## CD19+ Analysis

debris (7-AAD-)



	% of viable	κ/λ ratio
CD19+	26.4	1.9 : 1
CD10+CD19+	0.2	2.1 : 1
CD5+CD19+	1.4	2.1 : 1
CD20+	26.9	2 : 1
CD22+	26.0	1.9 : 1



# 22-0804

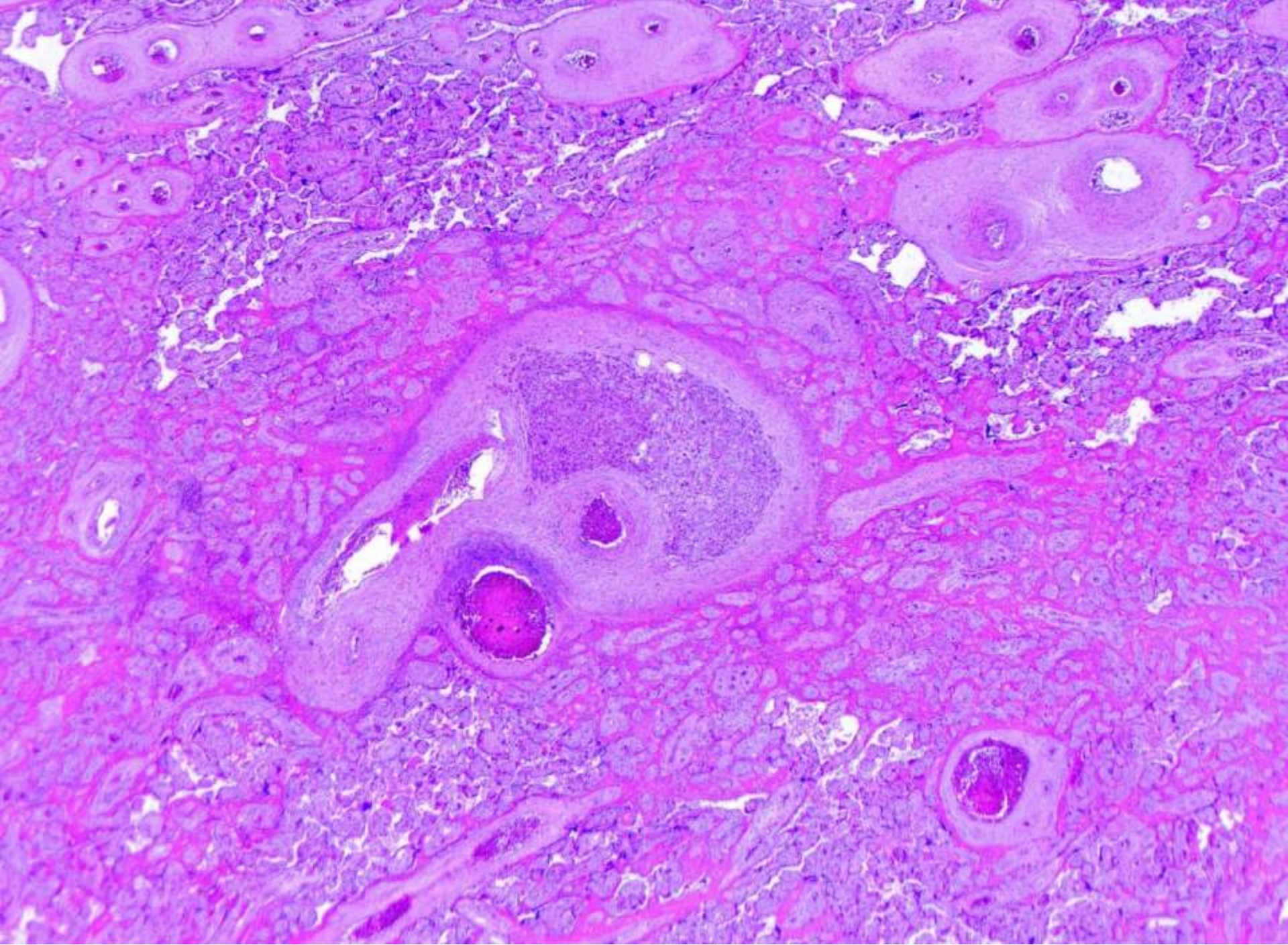
## Direct link to scanned slide:

<https://pathpresenter.net/public/display?token=3221eb31>

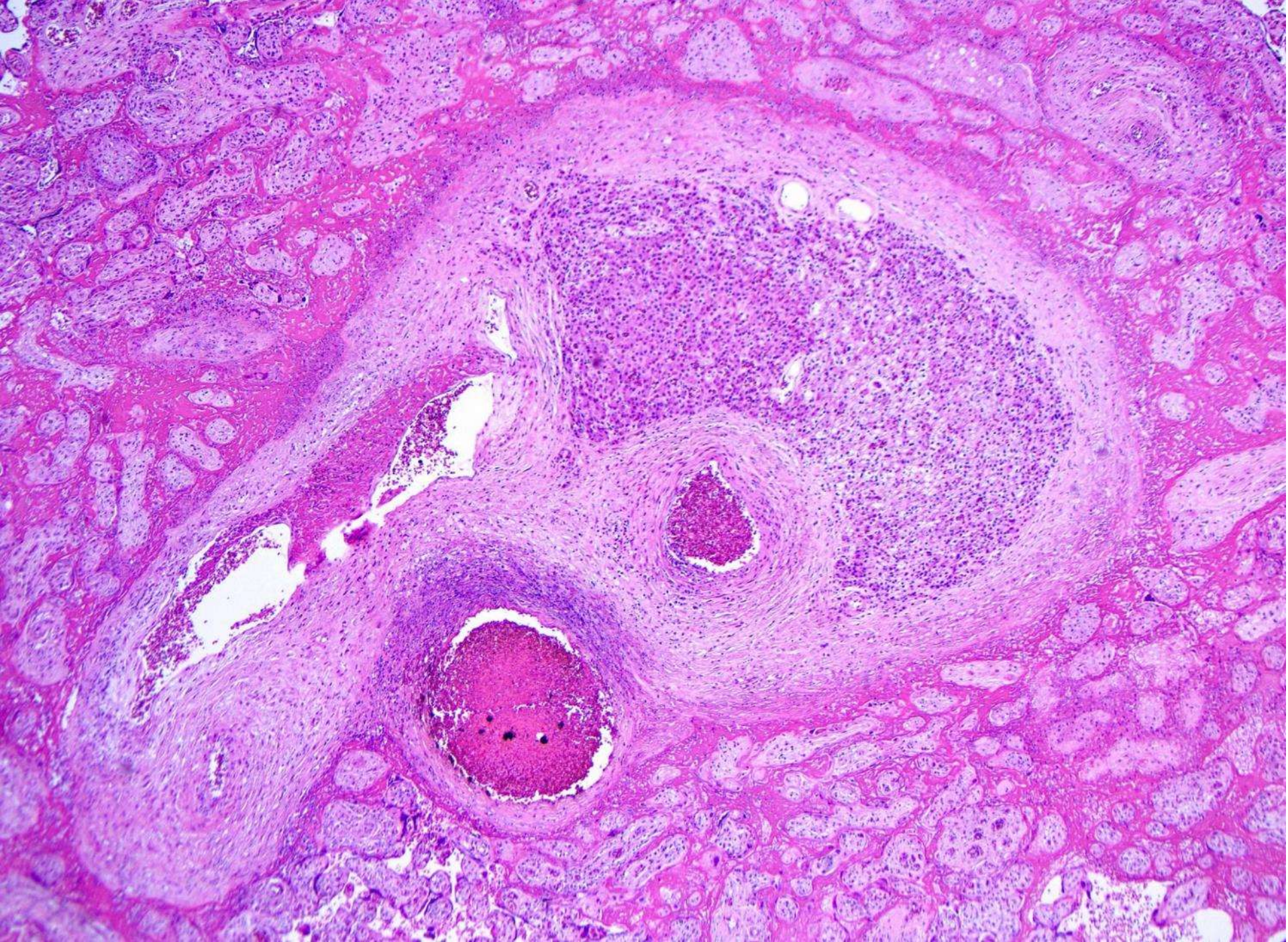
### **Lucas Massoth; El Camino Hospital**

30ish F presents at 39 weeks in labor. Cesarean section performed due to failure to progress and fetal intolerance to labor. Thick meconium was noted at delivery. Section of placental disc.

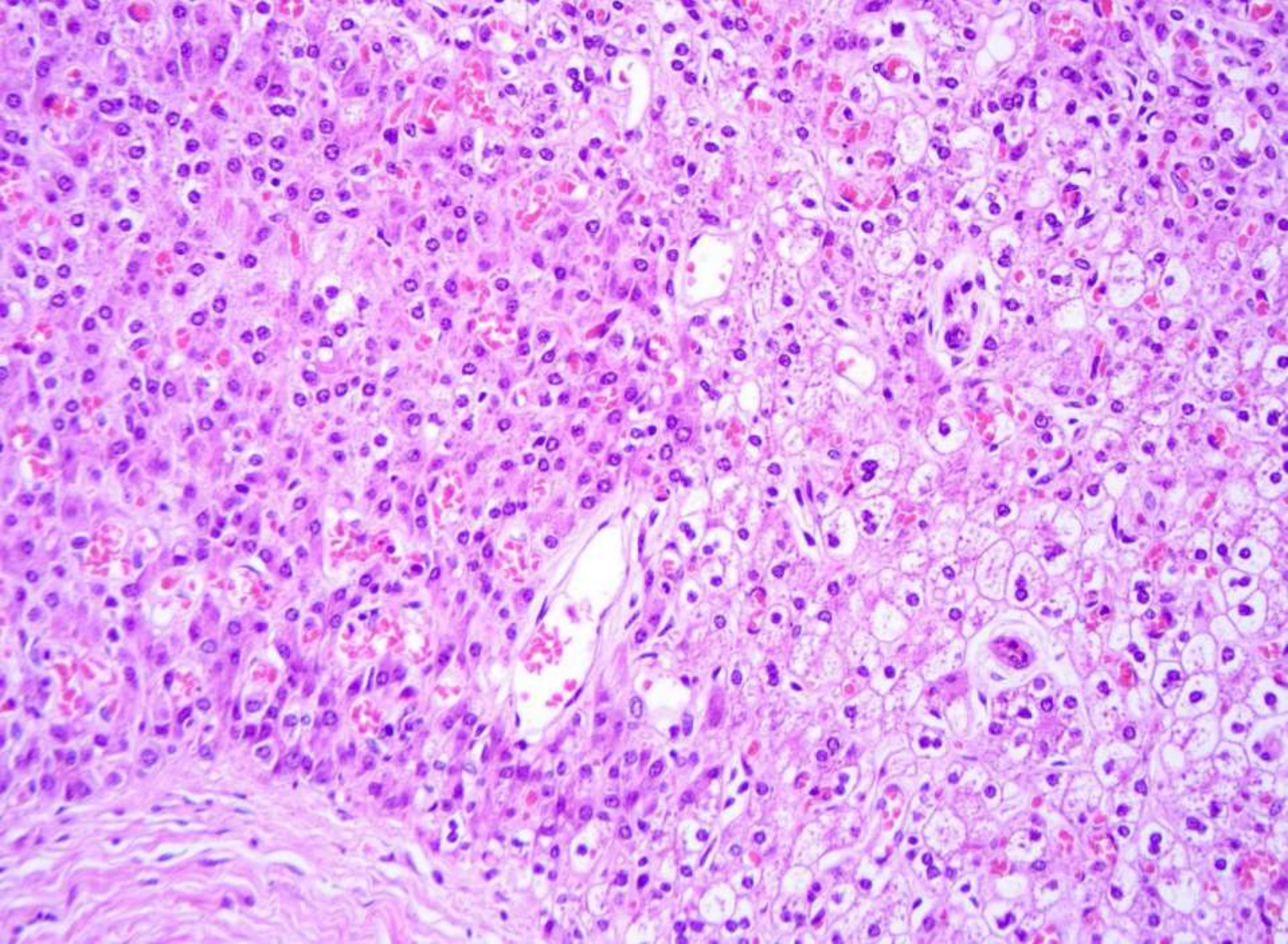














22-0805

**Nivaz Brar/Joshua Menke; Stanford**

70ish F with lymphadenopathy and splenomegaly.  
Bone marrow & lymph node submitted.

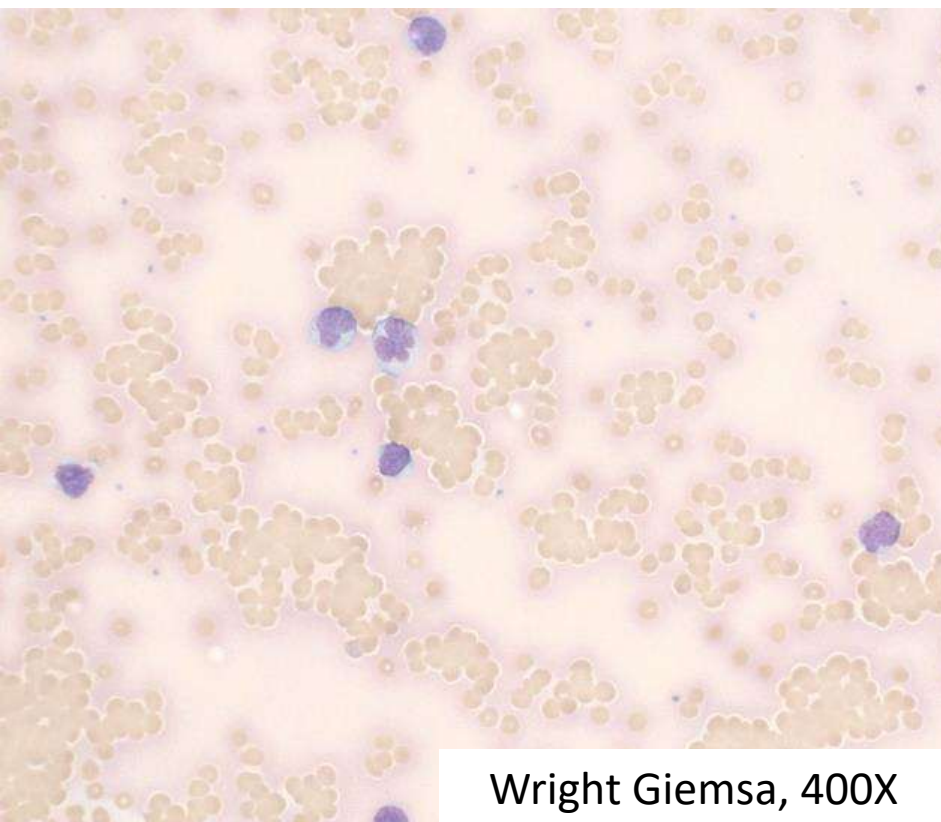


# Clinical history

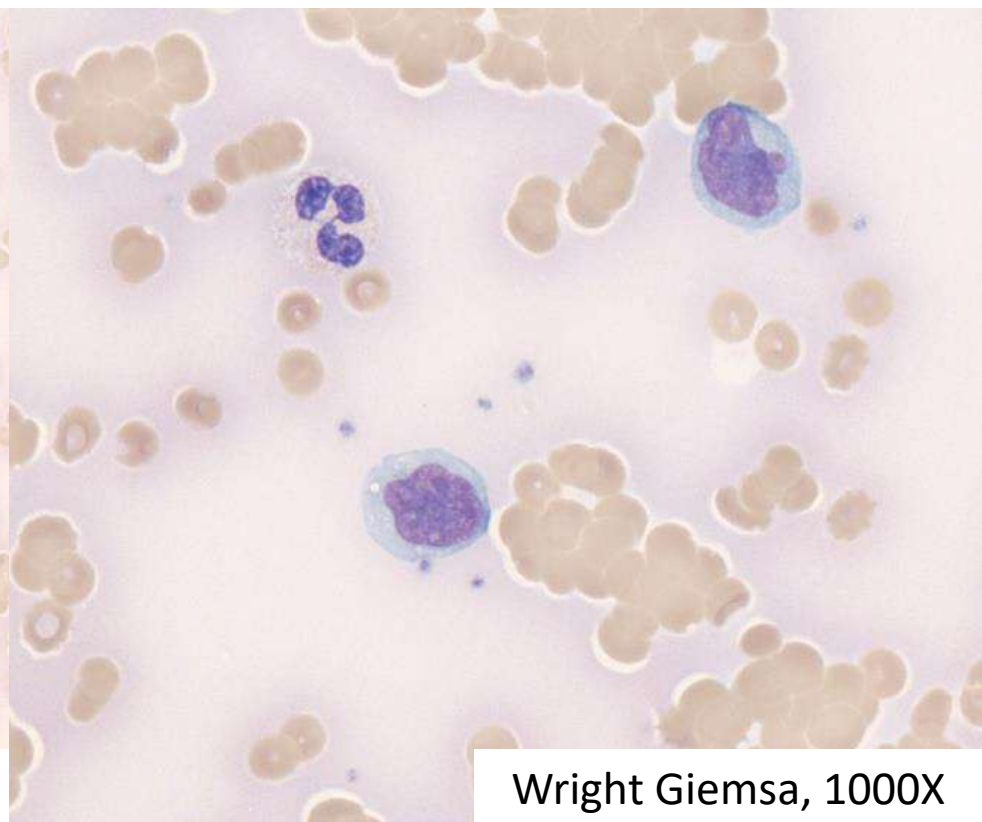
- 70ish F with a reported history of chronic lymphocytic leukemia diagnosed in another country
- Patient has anemia with prominent RBC agglutination, neutropenia, and thrombocytopenia
- PET-CT shows massive splenomegaly (20 cm in vertical axis), mildly enlarged hypermetabolic lymph nodes above and below the diaphragm, and moderate uptake throughout the marrow



Peripheral blood smear shows RBC agglutination and atypical lymphoid cells



Wright Giemsa, 400X



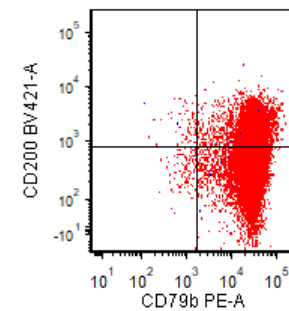
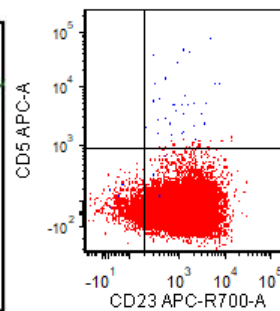
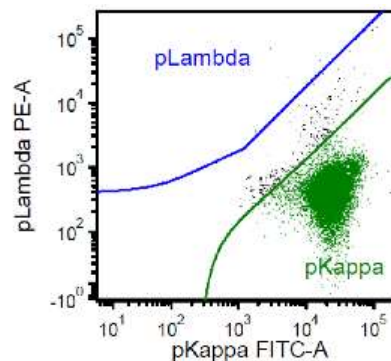
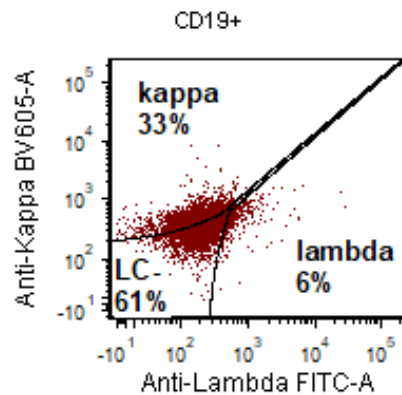
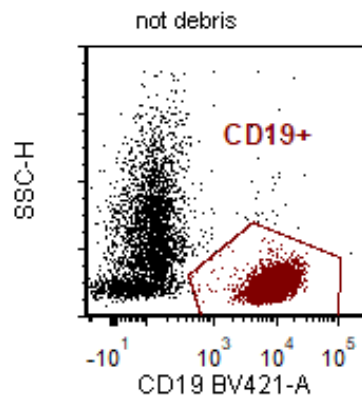
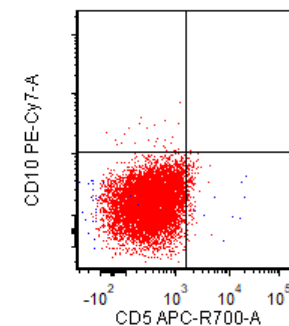
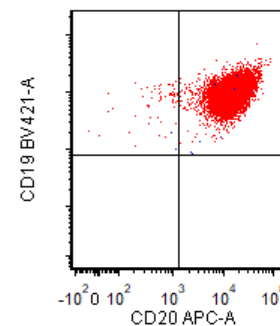
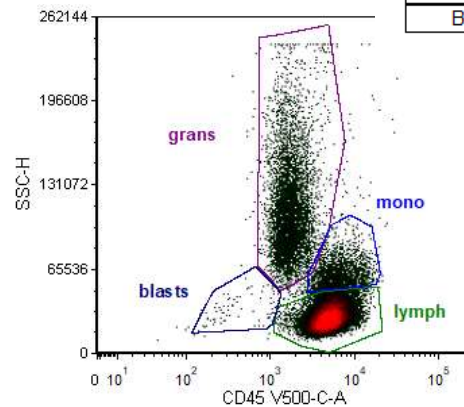
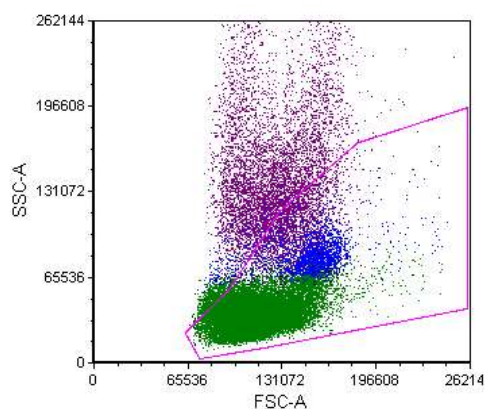
Wright Giemsa, 1000X

# Peripheral blood flow

## Differential:

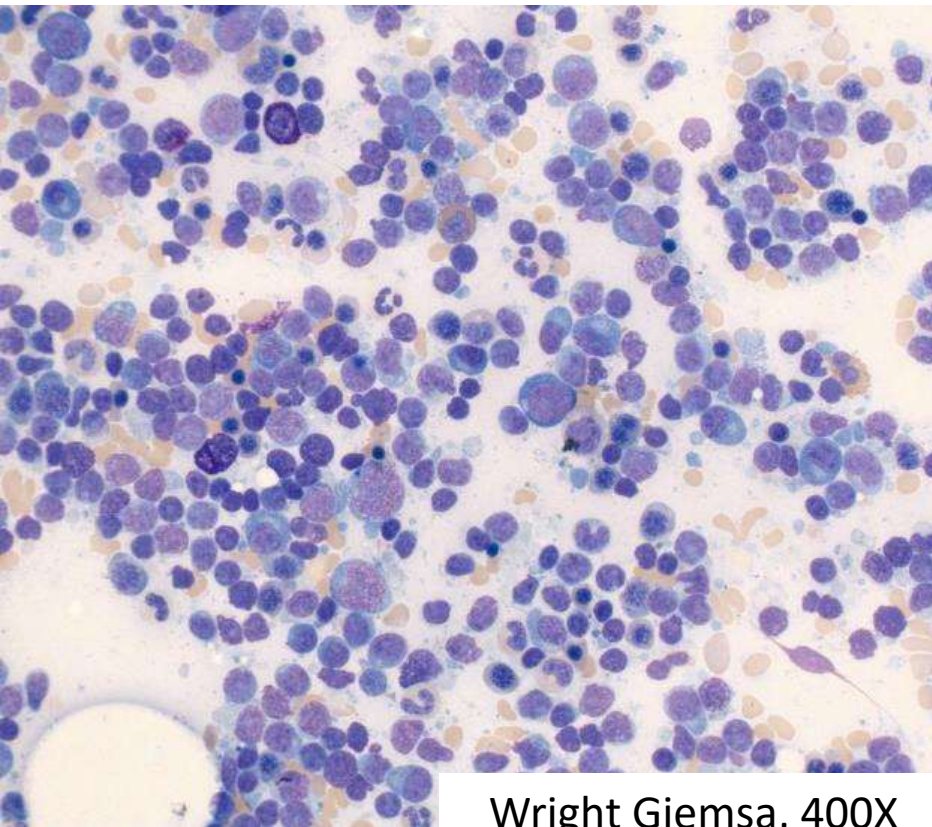
	% not debris	%CD45+
Lymphocytes	75.0	75.1
Granulocytes	17.3	17.3
Monocyte	6.7	6.7
Blasts	0.2	0.1

**Abnl B** 62.04% of CD45+  
61.96% of not debris  
(24453 events)

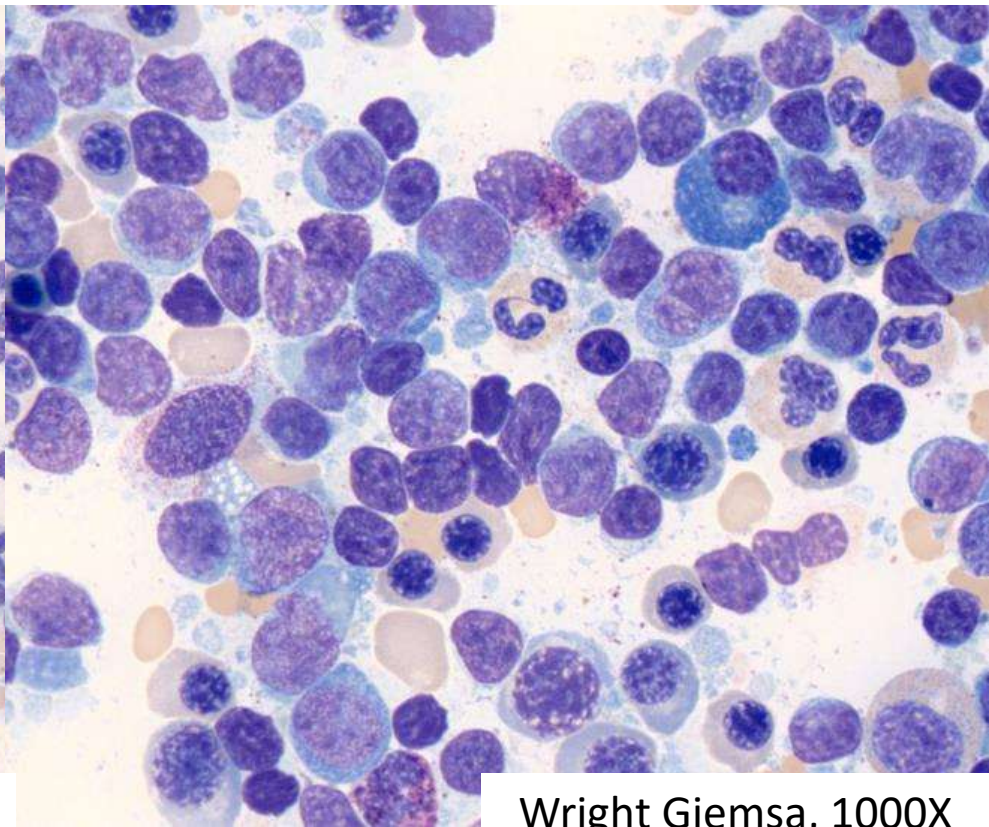




# Bone marrow aspirate

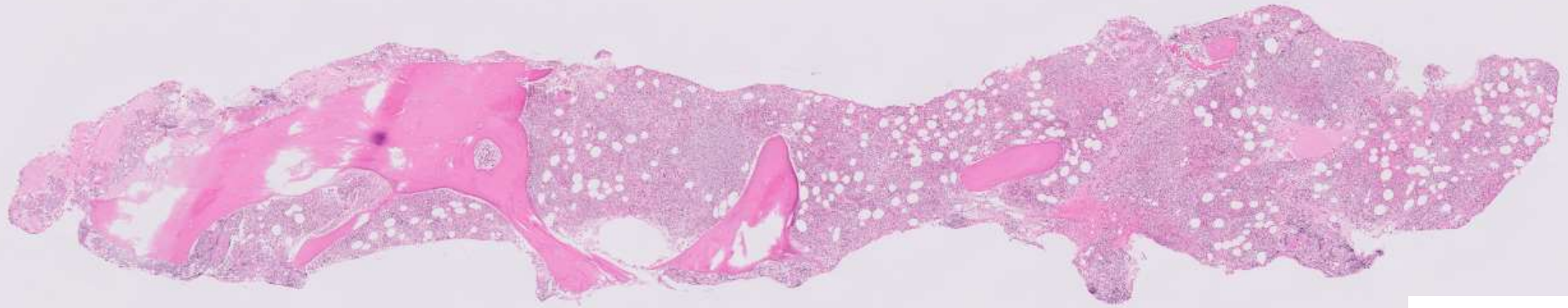
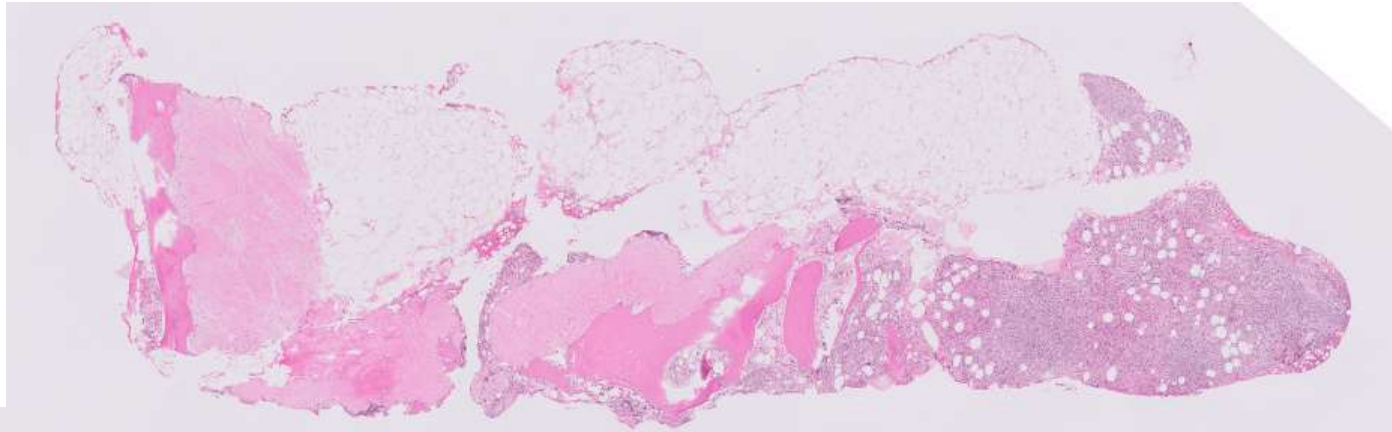


Wright Giemsa, 400X



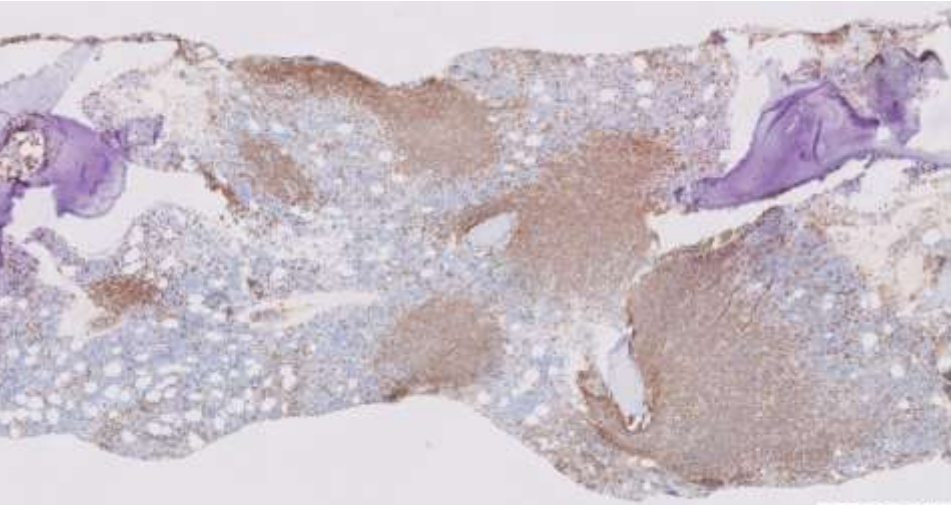
Wright Giemsa, 1000X

# Bone marrow core biopsy

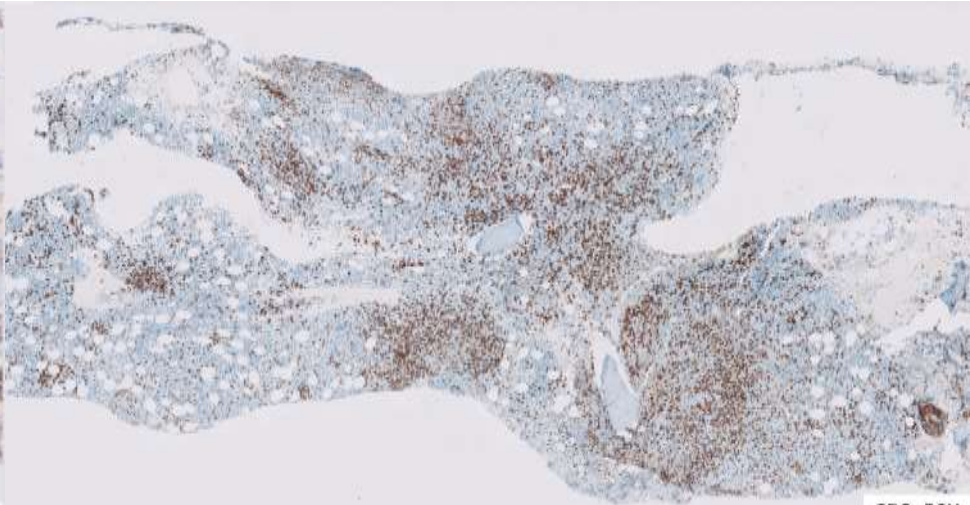


H&E,  
10X

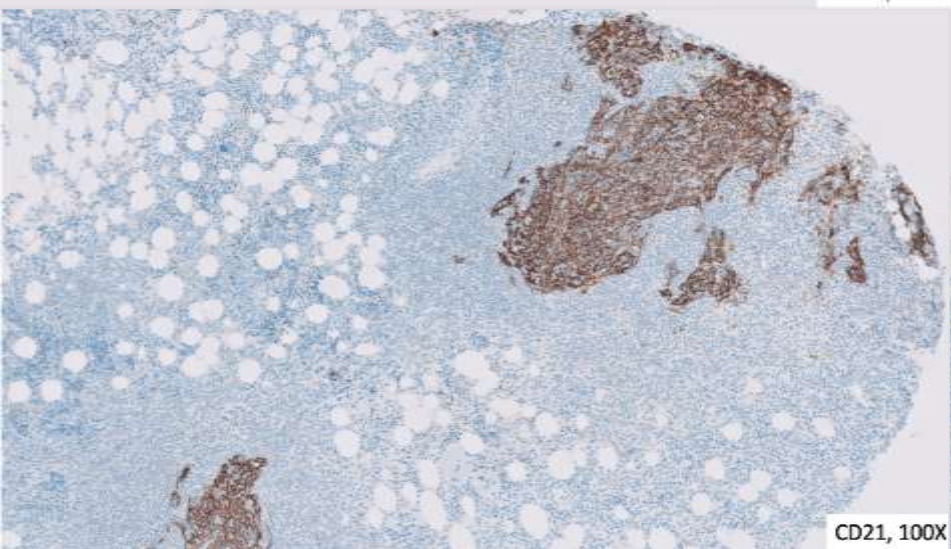




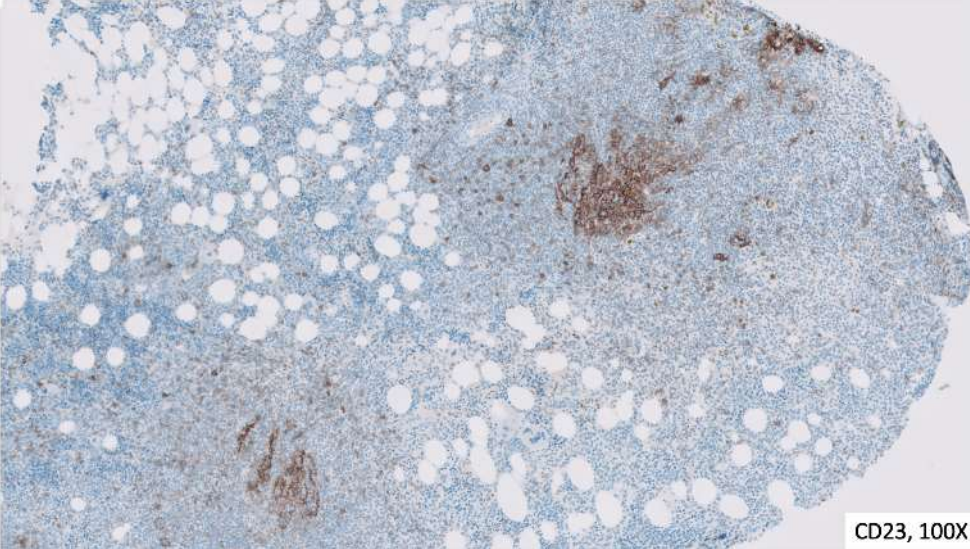
CD20, 50X



CD3, 50X

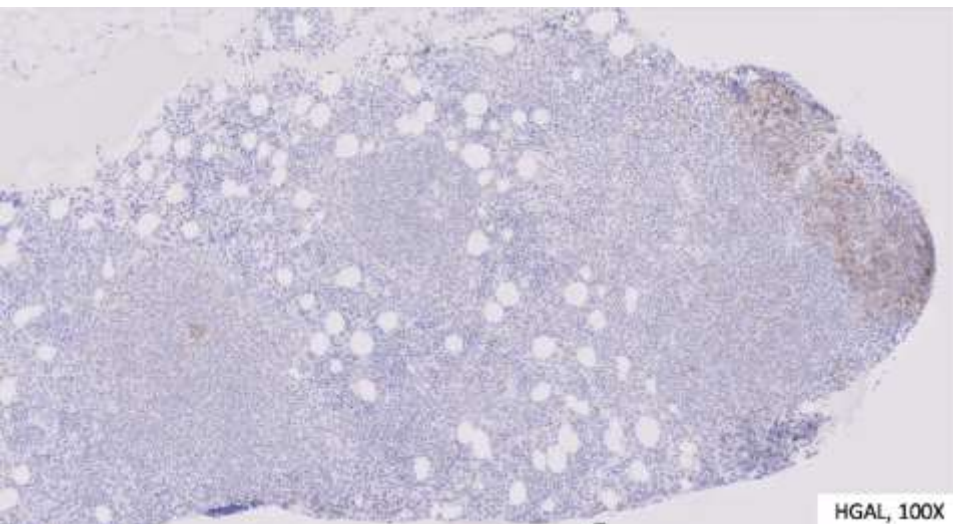


CD21, 100X

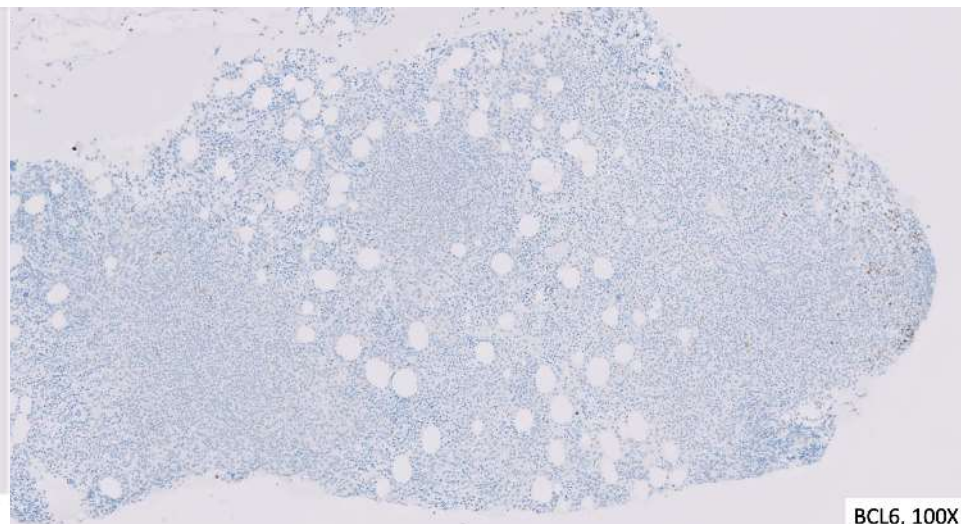


CD23, 100X

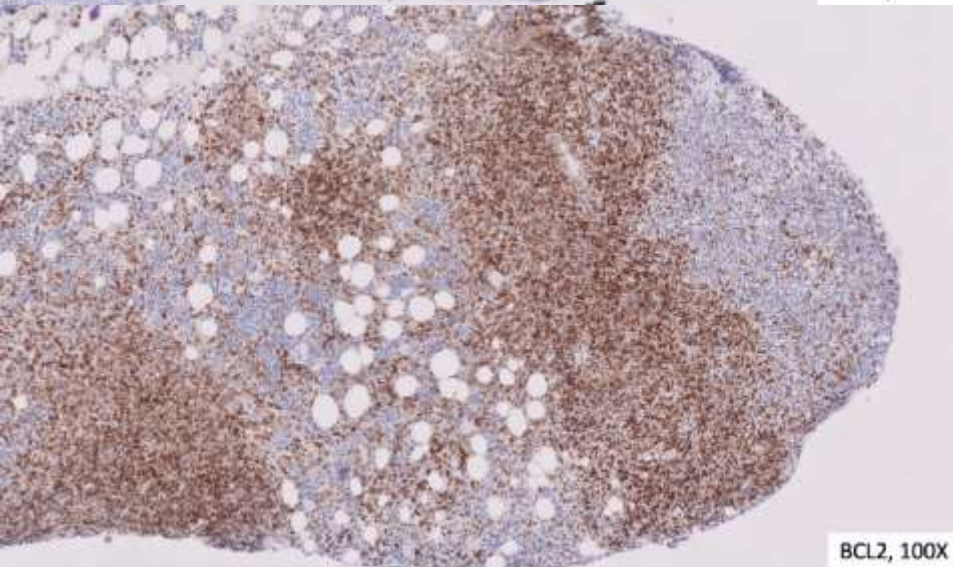




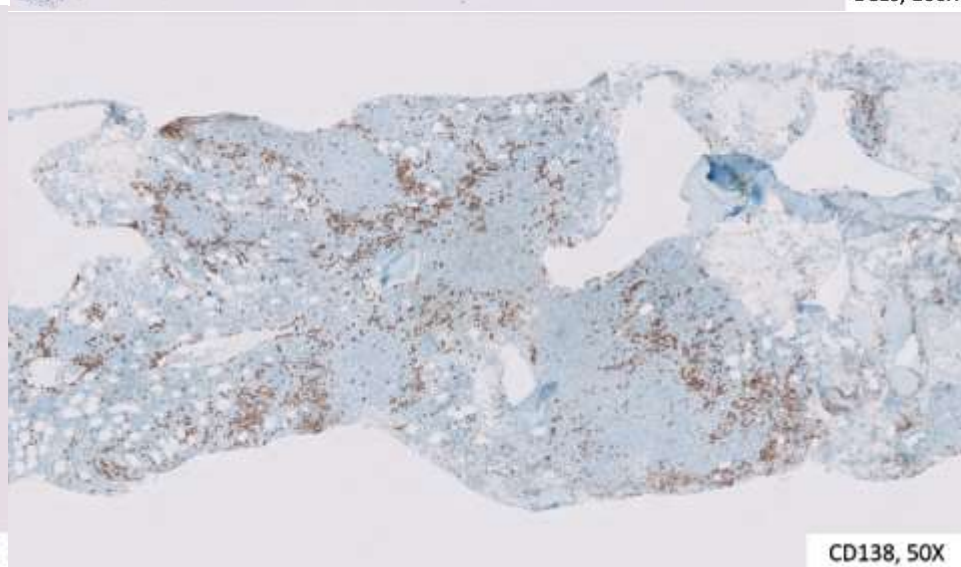
HGAL, 100X



BCL6, 100X

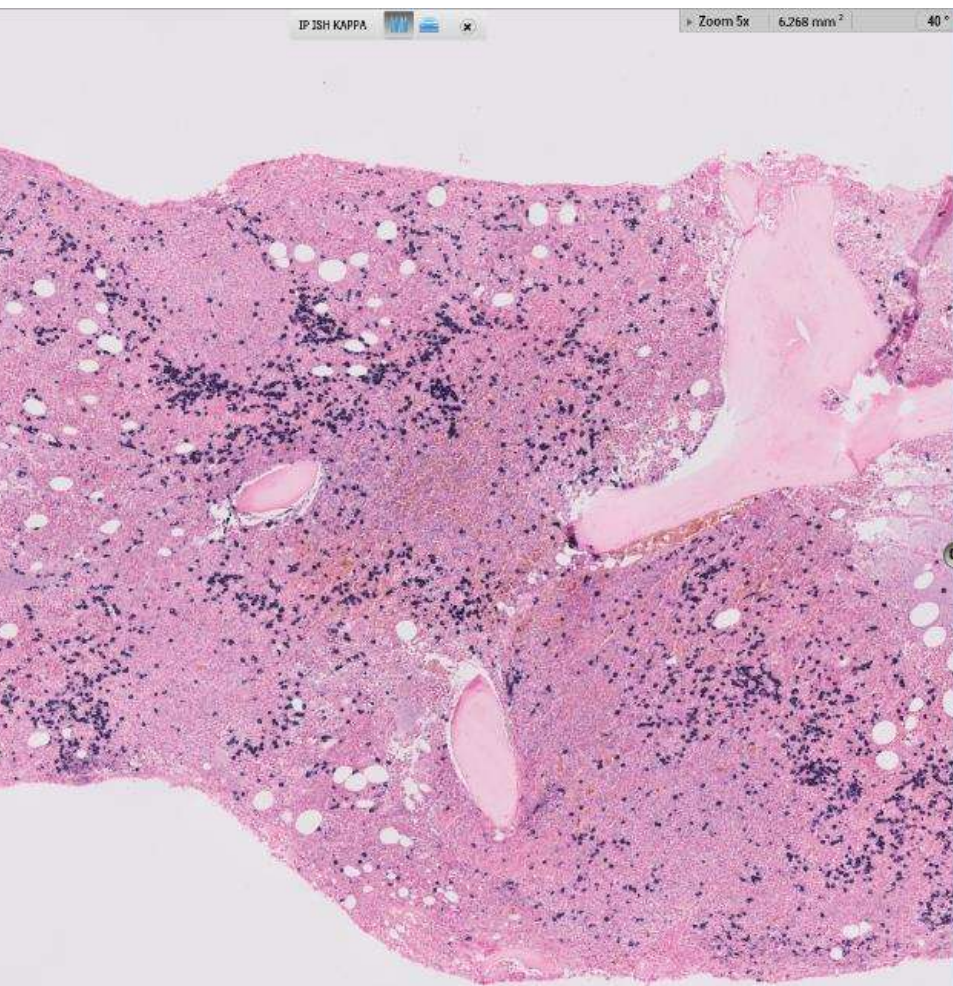


BCL2, 100X



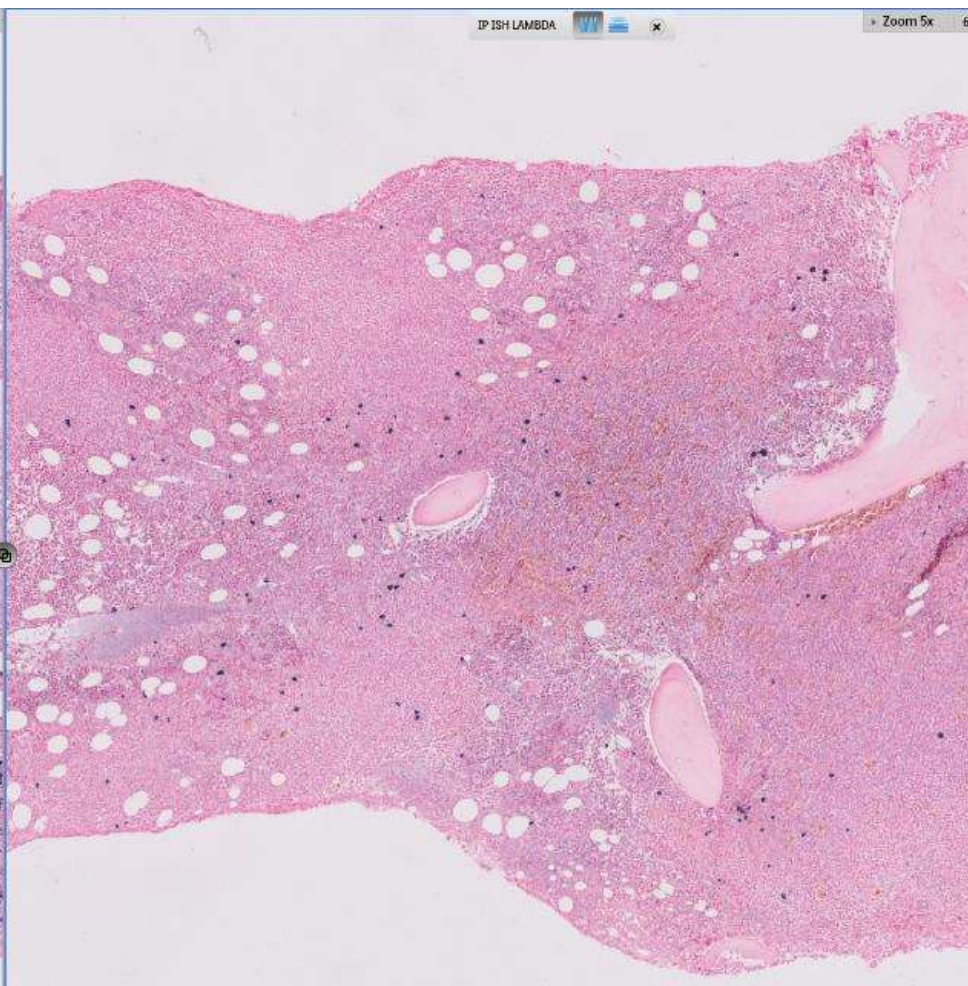
CD138, 50X



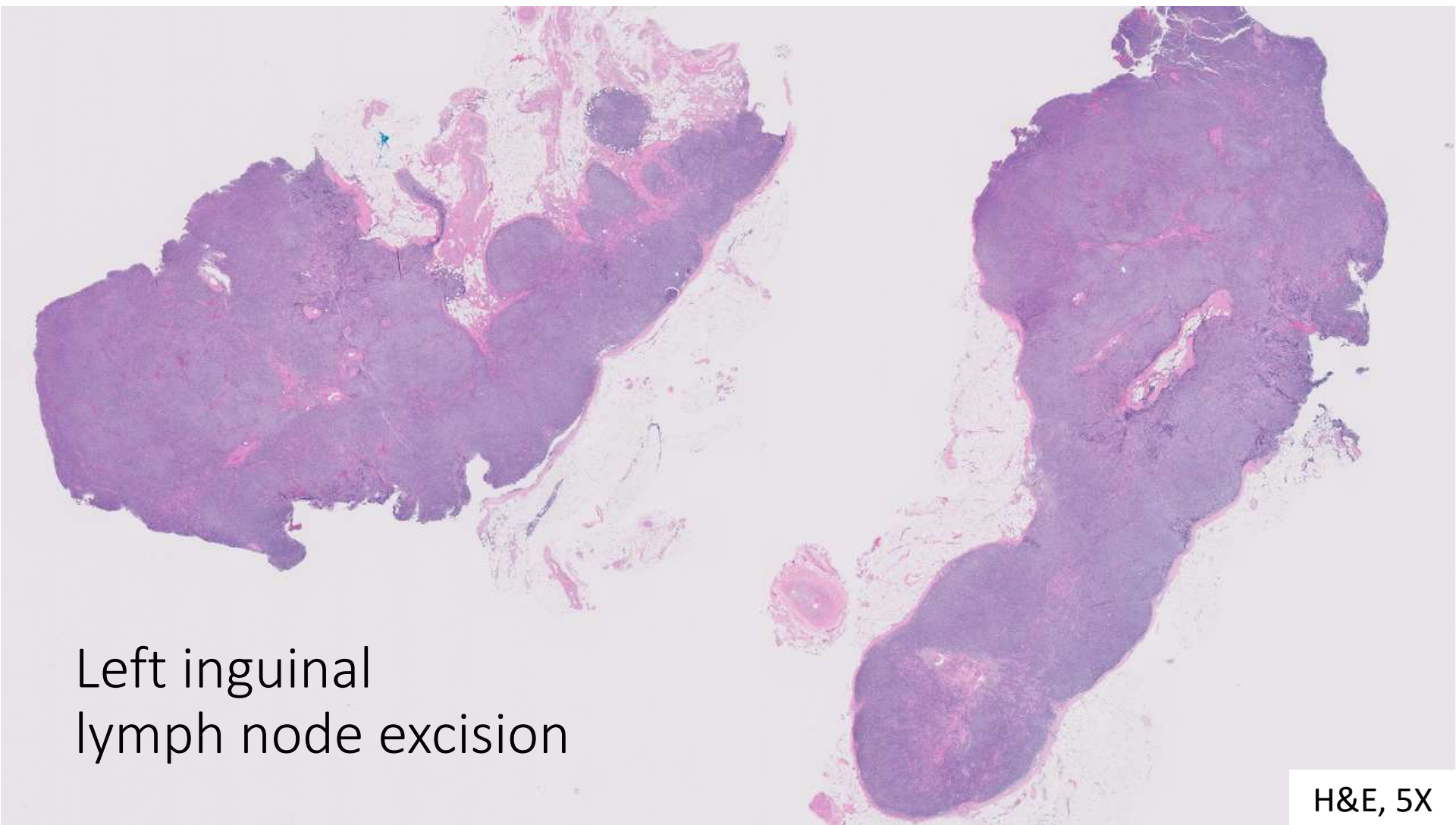


Kappa ISH, 50X

Image regions aligned successfully  
Viewports are linked together



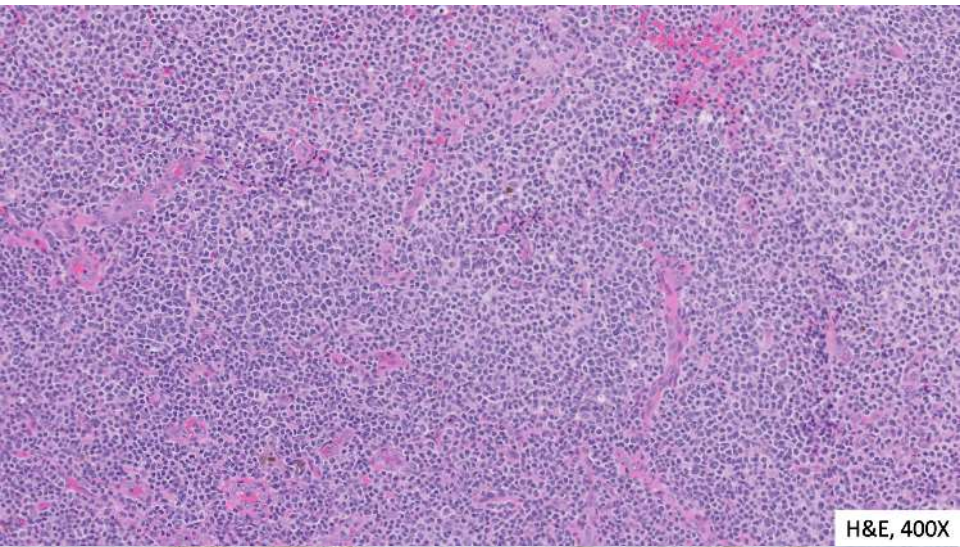
Lambda ISH, 50X



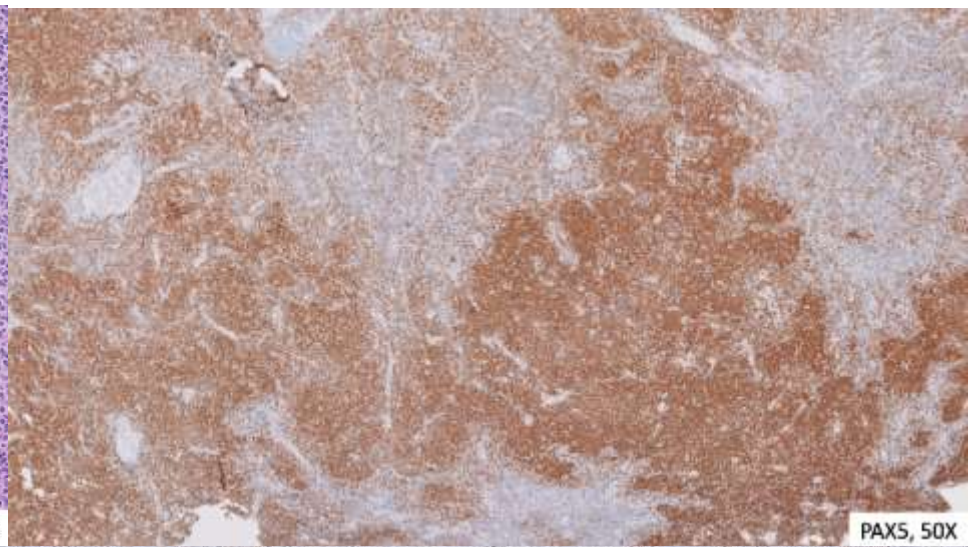
Left inguinal  
lymph node excision

H&E, 5X

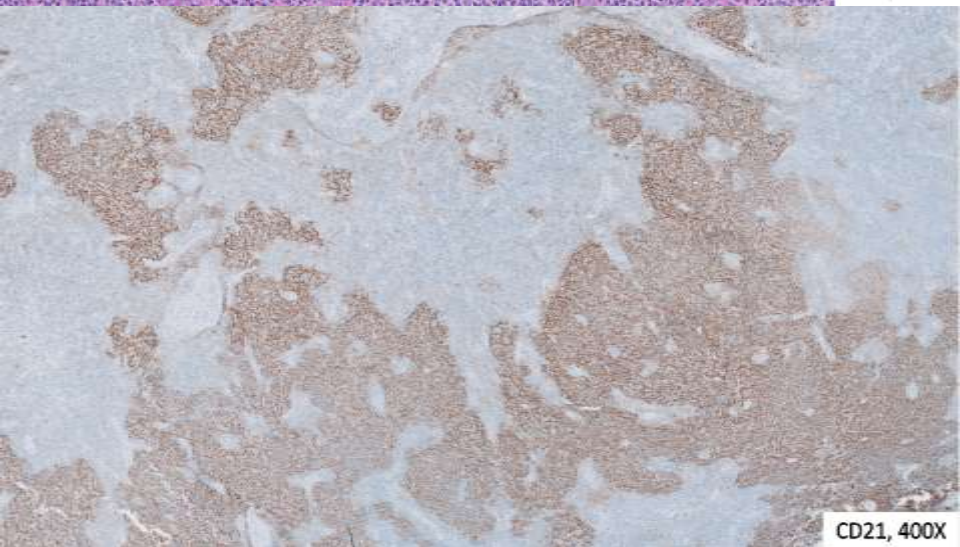



H&E, 400X



PAX5, 50X



CD21, 400X



Ki-67, 400X

# 22-0806

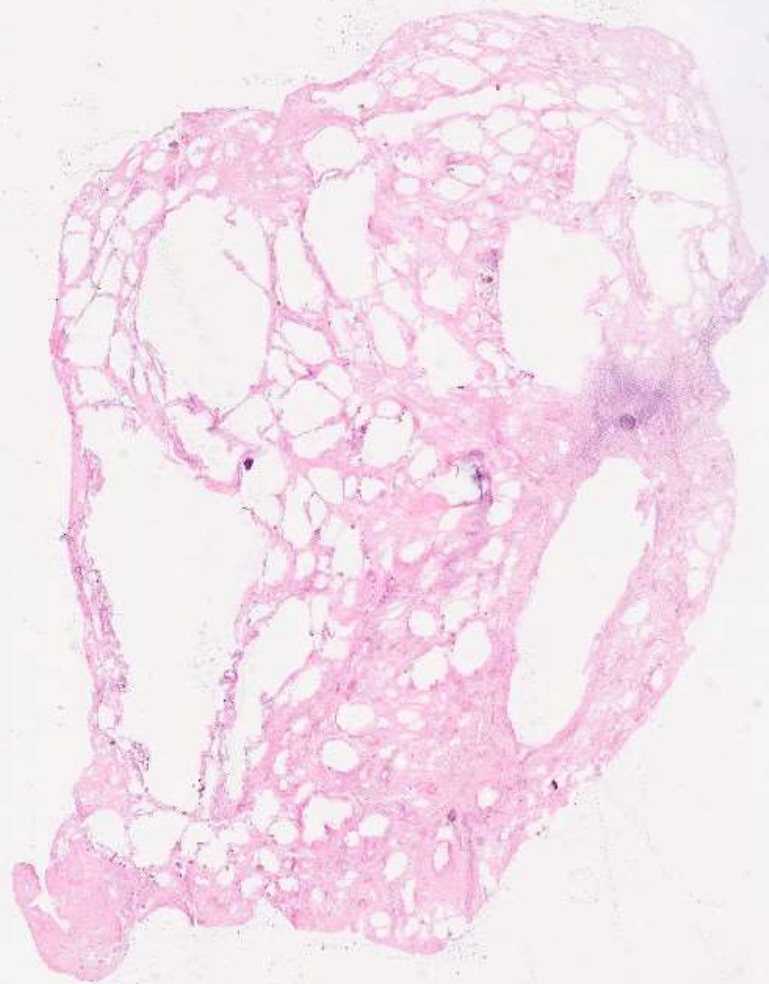
Direct link to scanned slide:

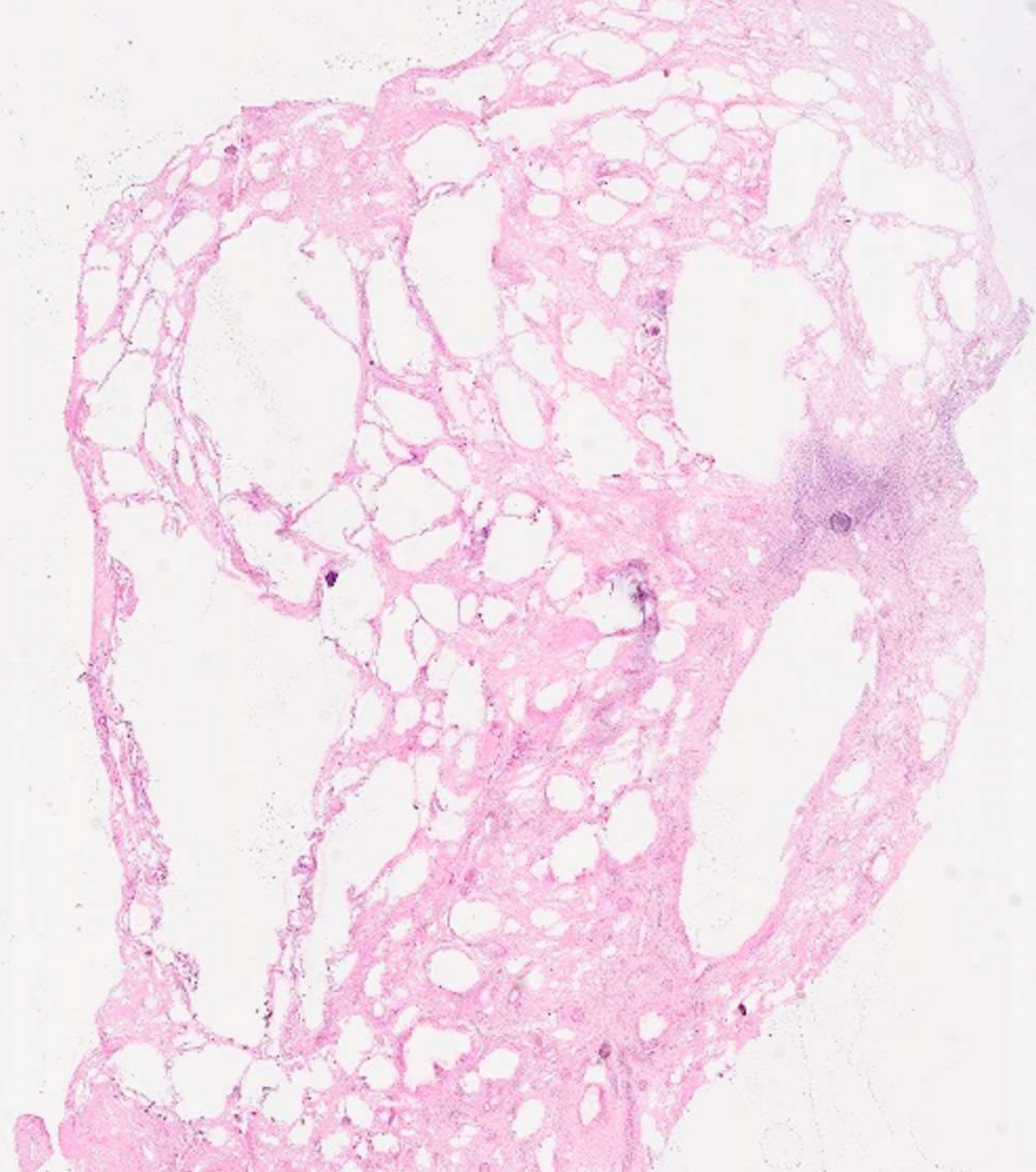
<https://pathpresenter.net/public/display?token=9b813d13>

**Ankur Sangoi; El Camino Hospital**

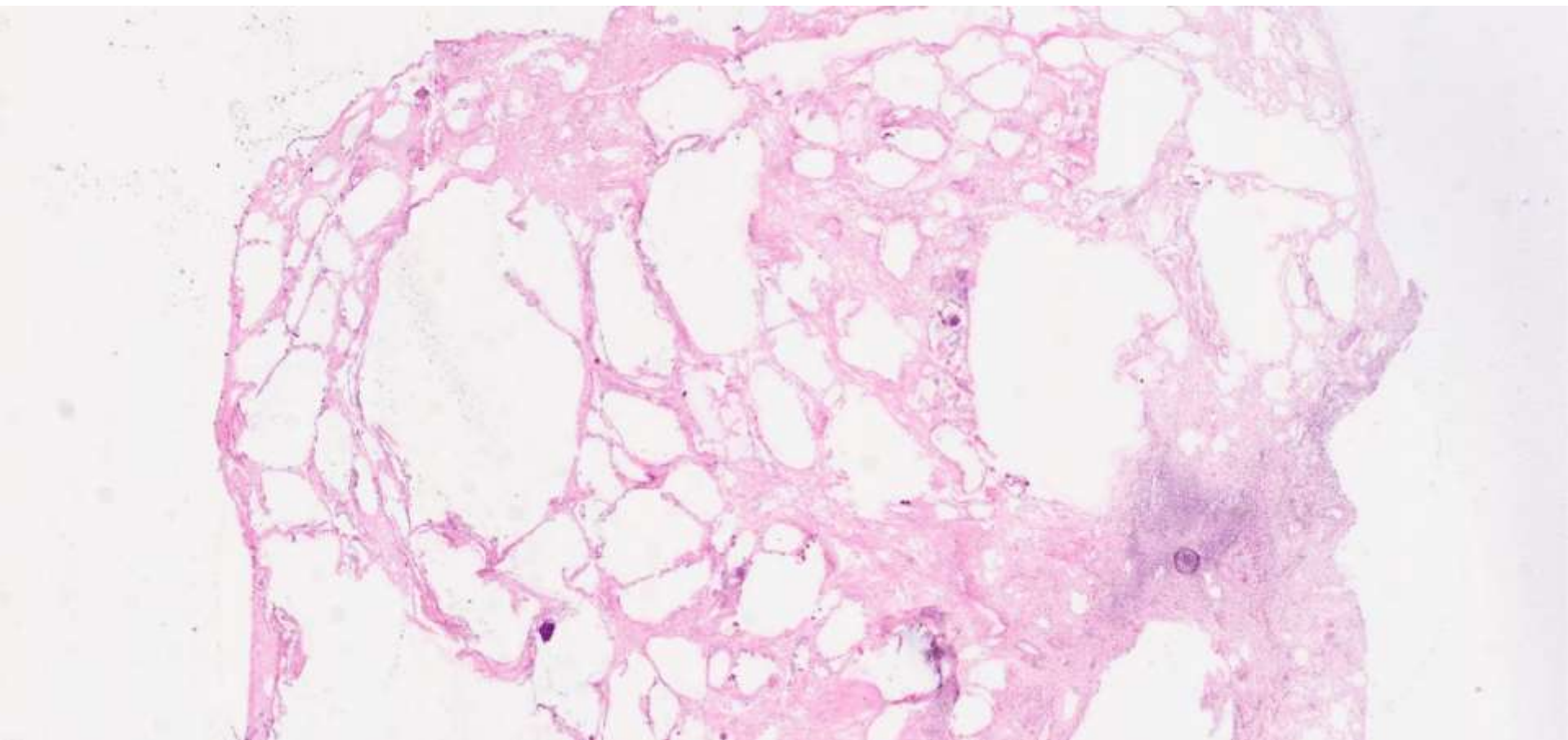
Teenage girl presents with left ovarian cystic mass,  
frozen section of left ovarian cyst submitted.

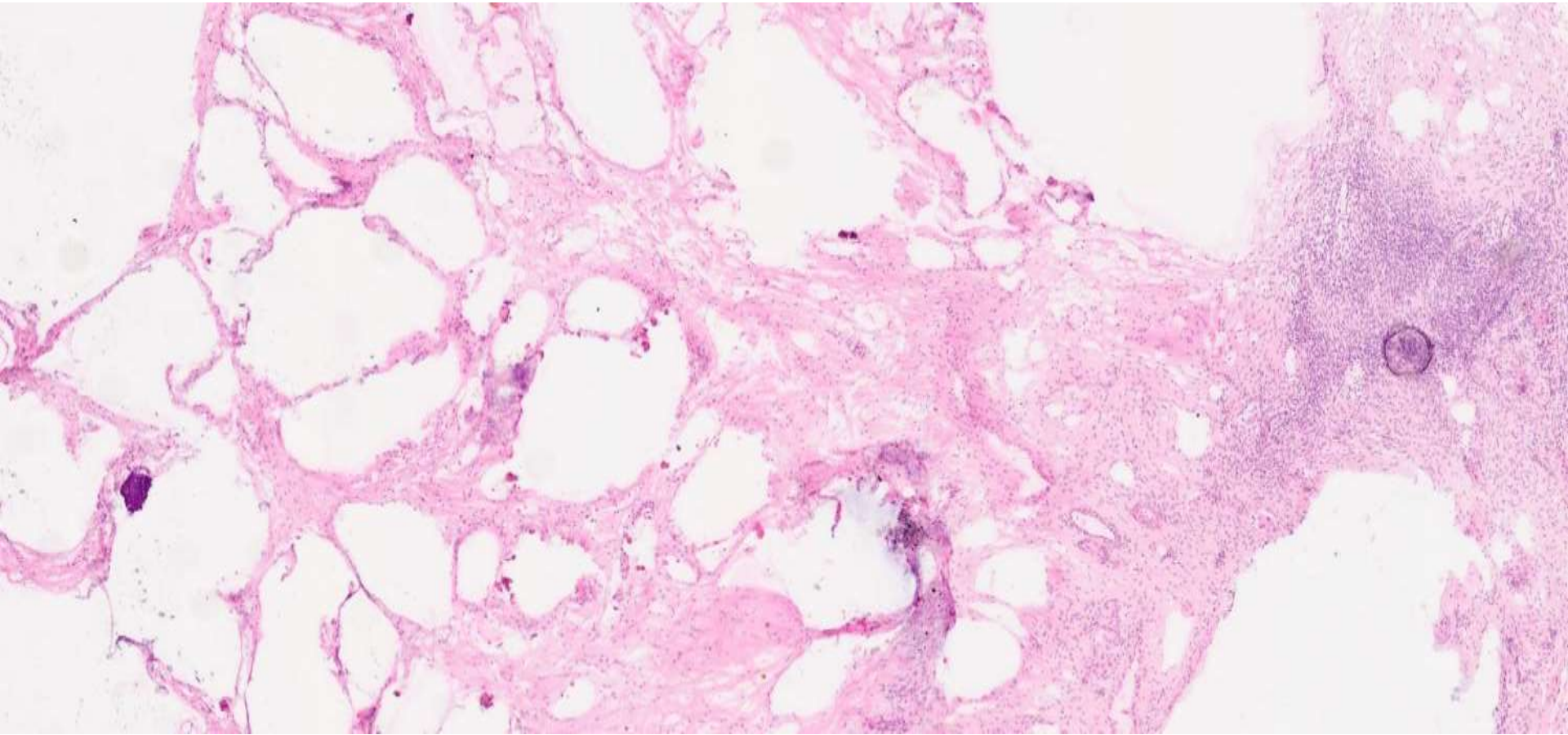




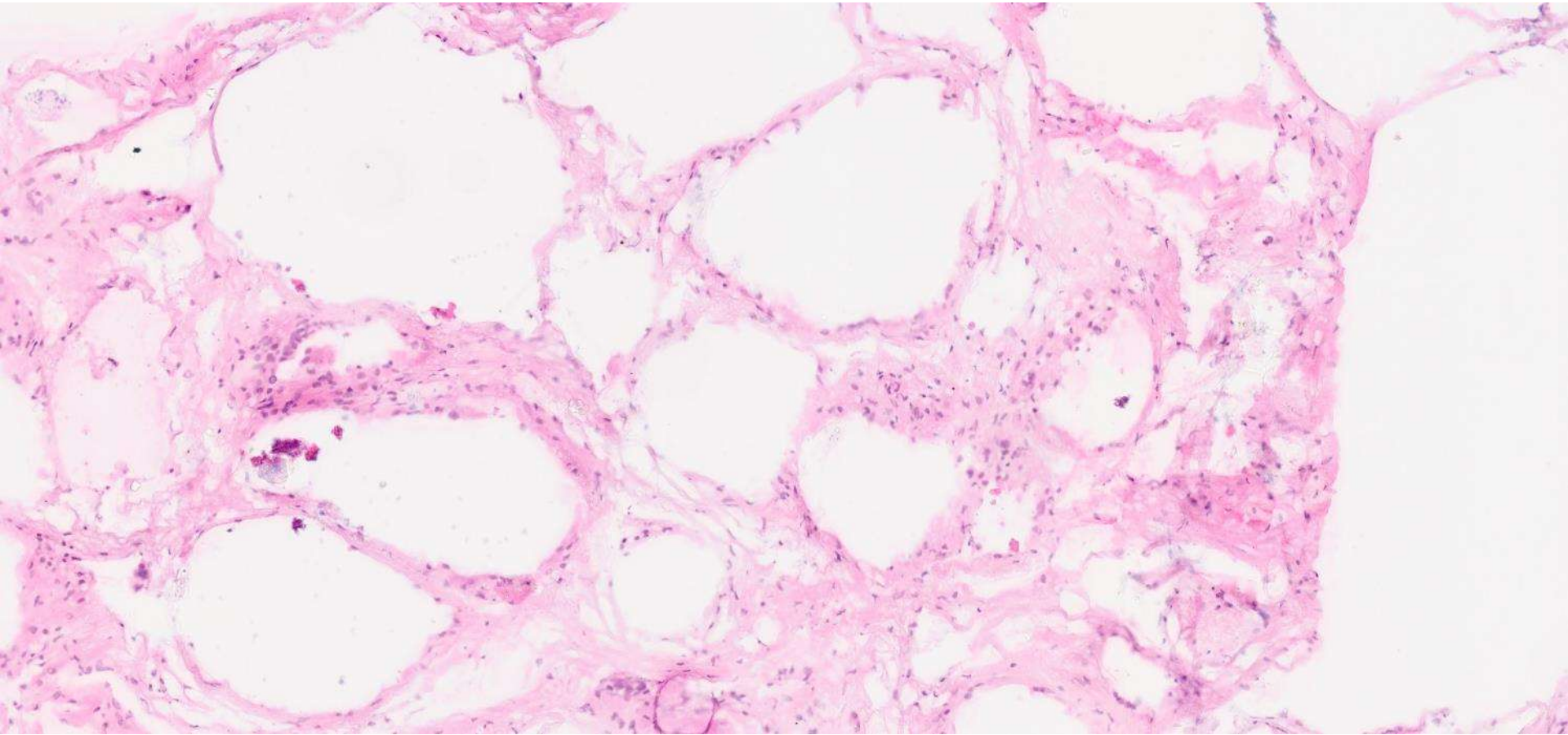


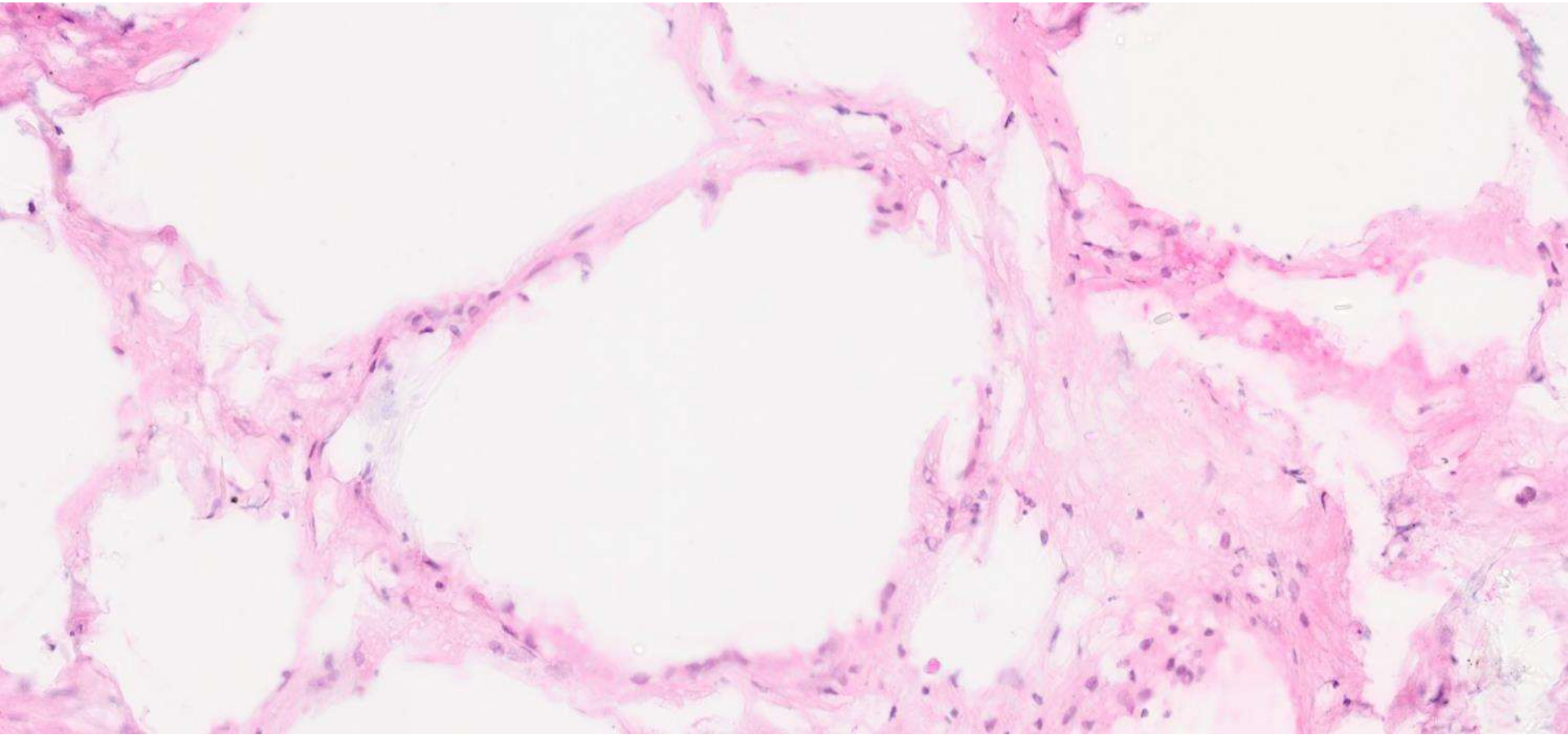




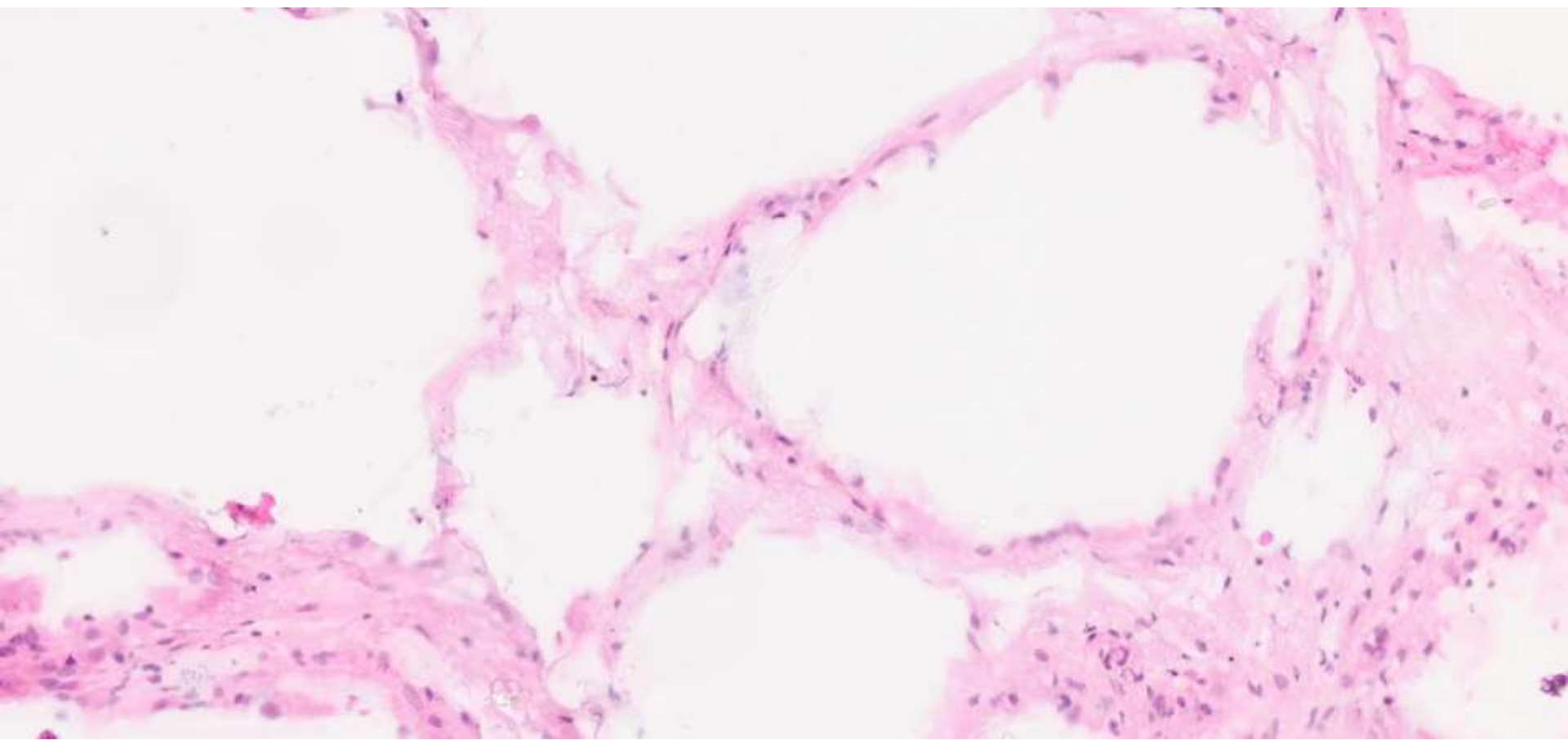












# 22-0807

Direct link to scanned slide:

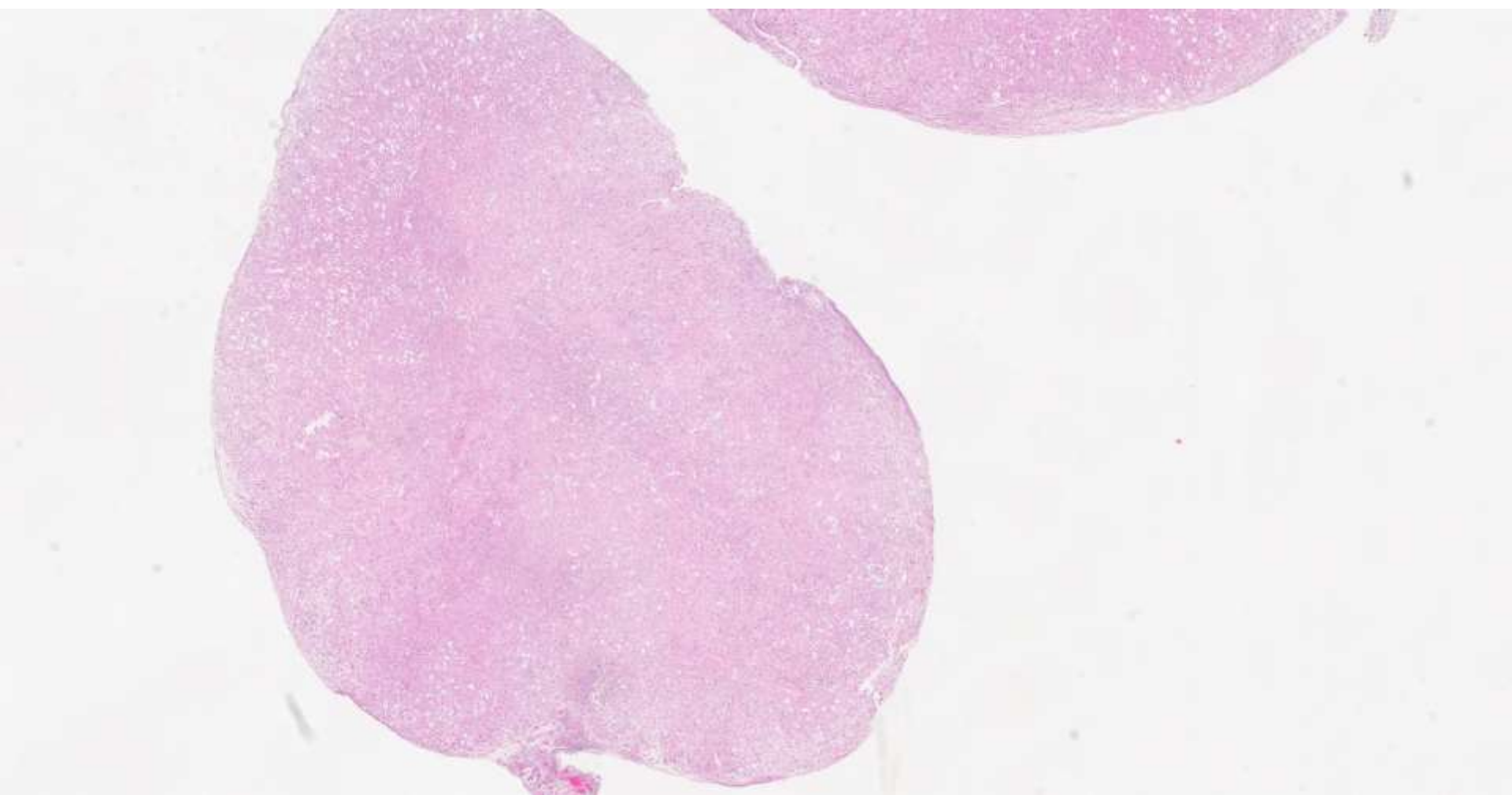
<https://pathpresenter.net/public/display?token=4b6e135c>

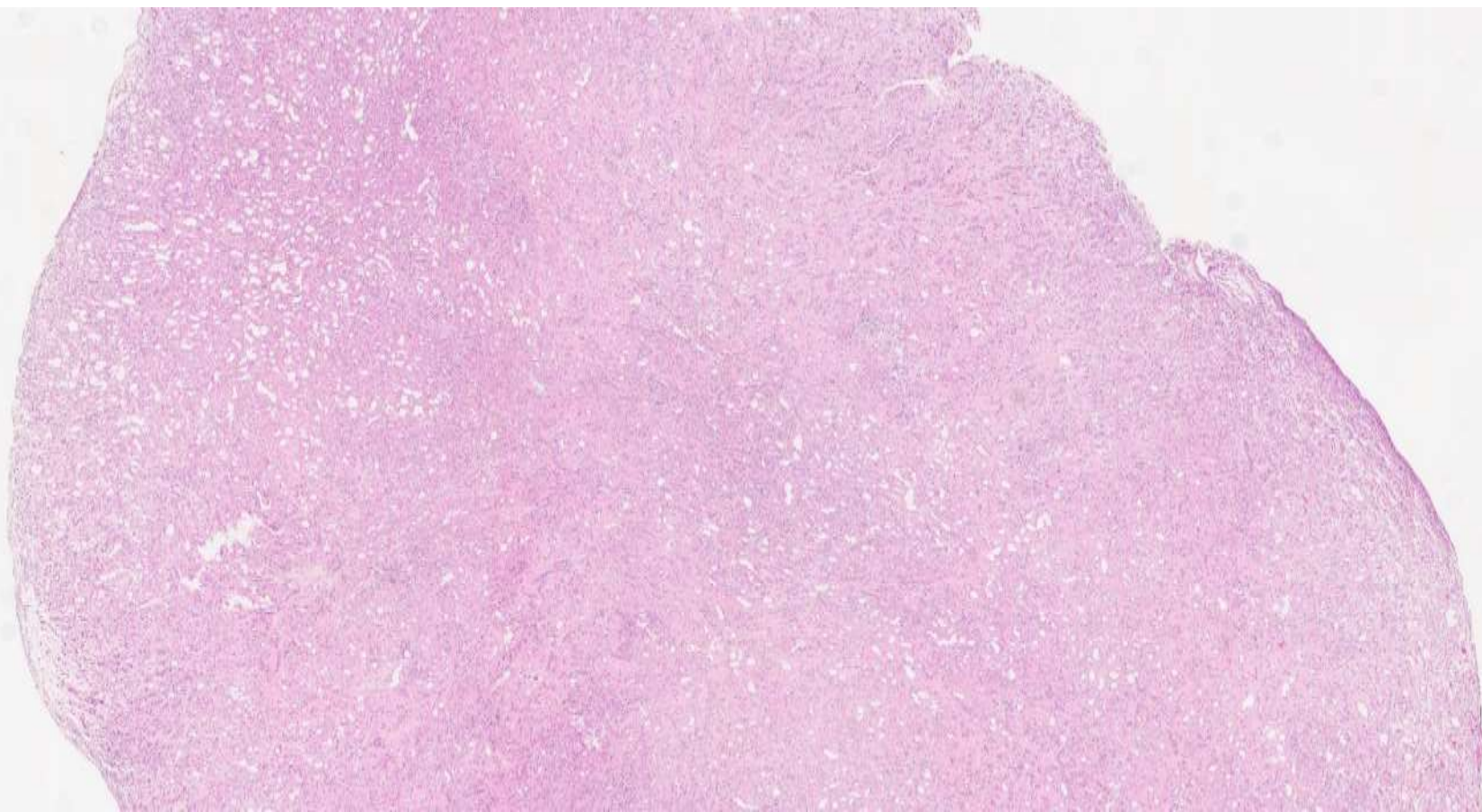
## **Ankur Sangoi; El Camino Hospital**

Middle-aged Indian F presents with abdominal pain, found to have acute cholecystitis and gallstones.

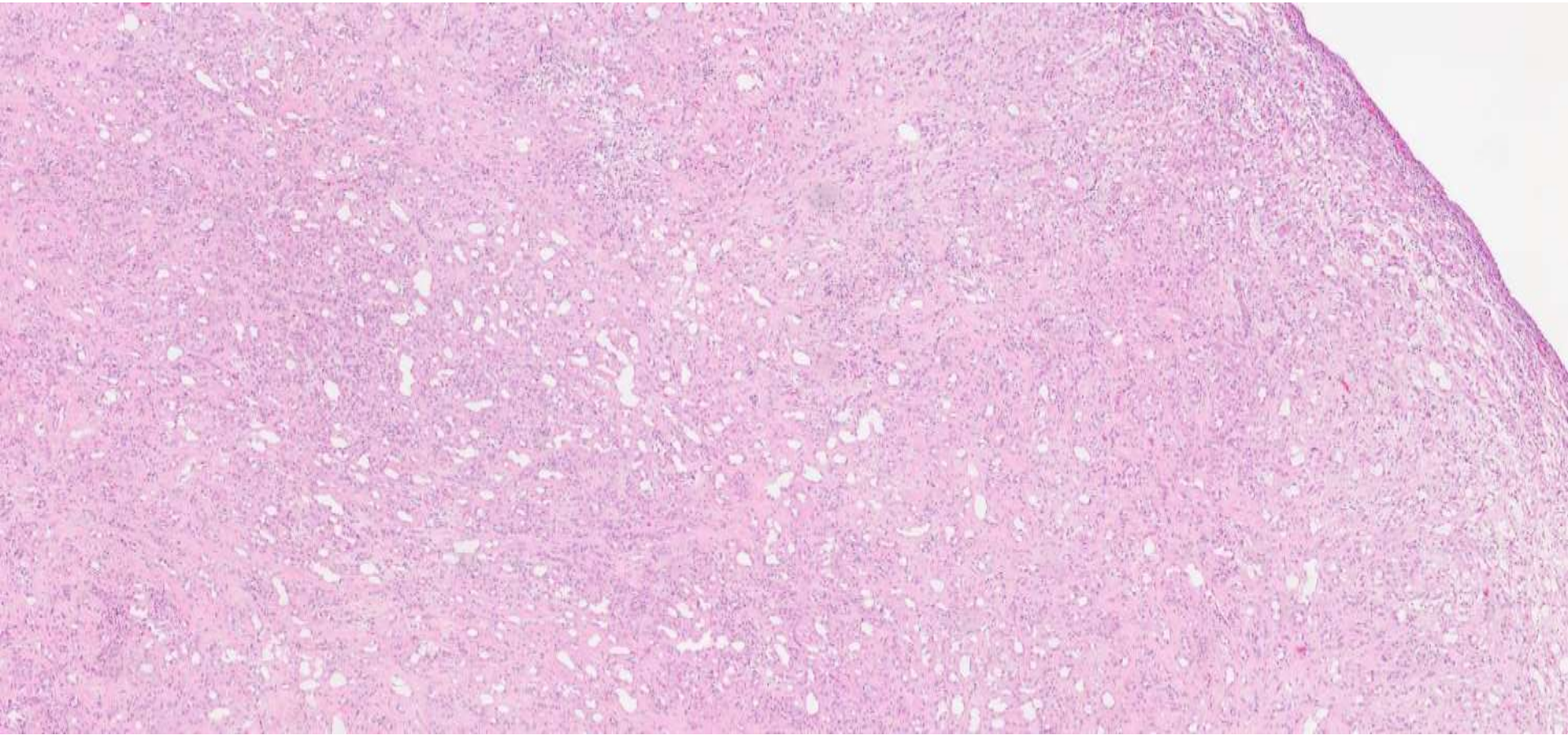
Cholecystectomy and “pericholecystic lymph node” excision performed.



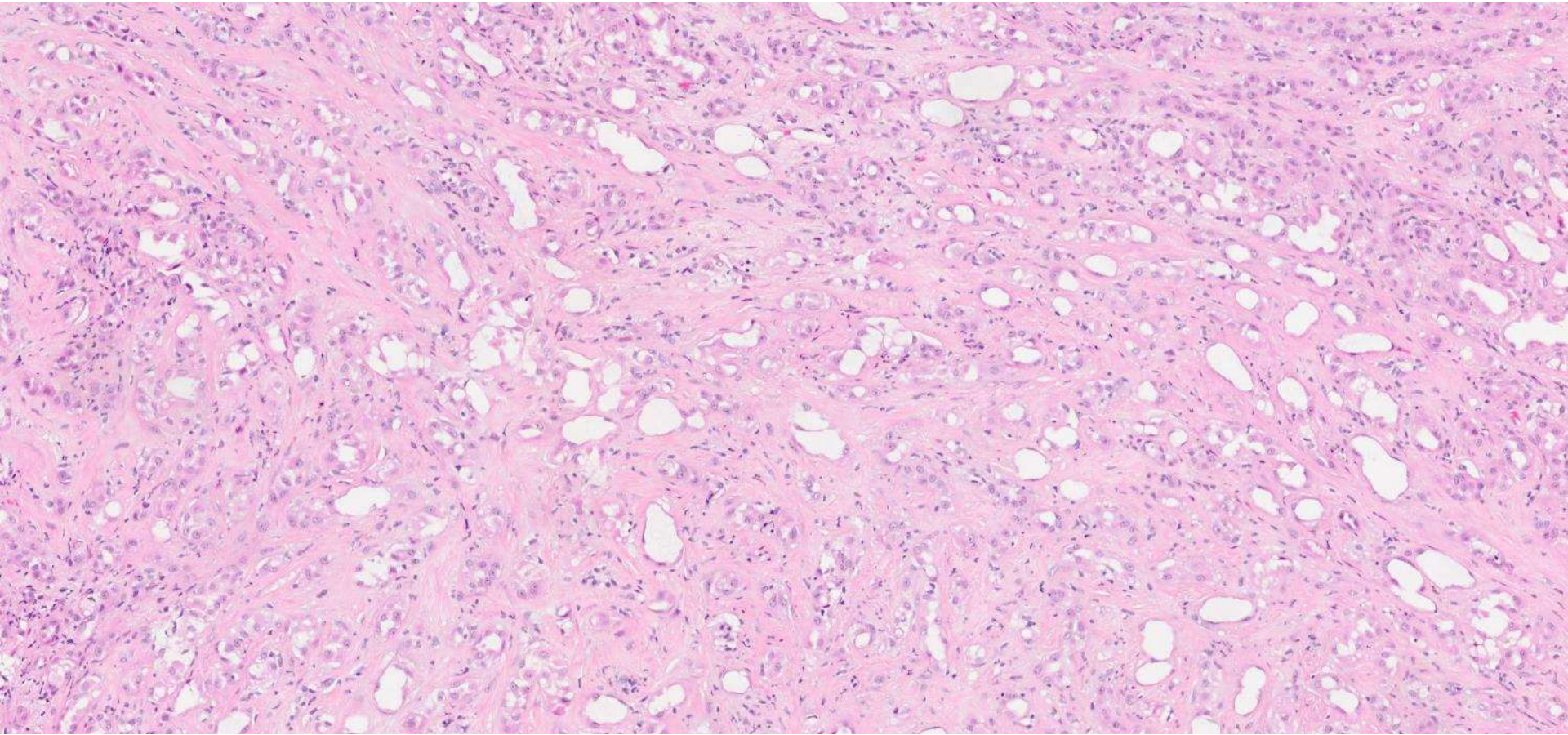




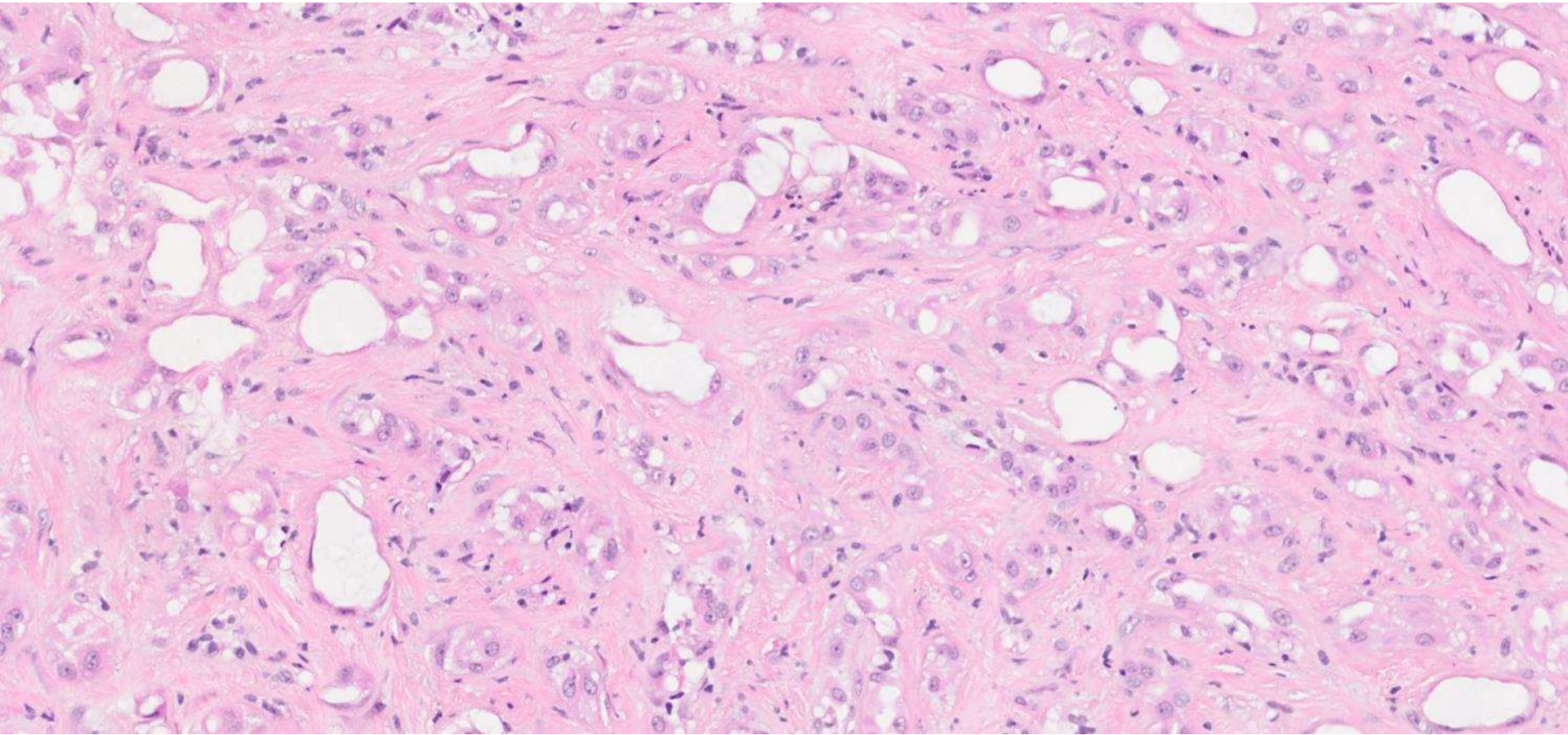


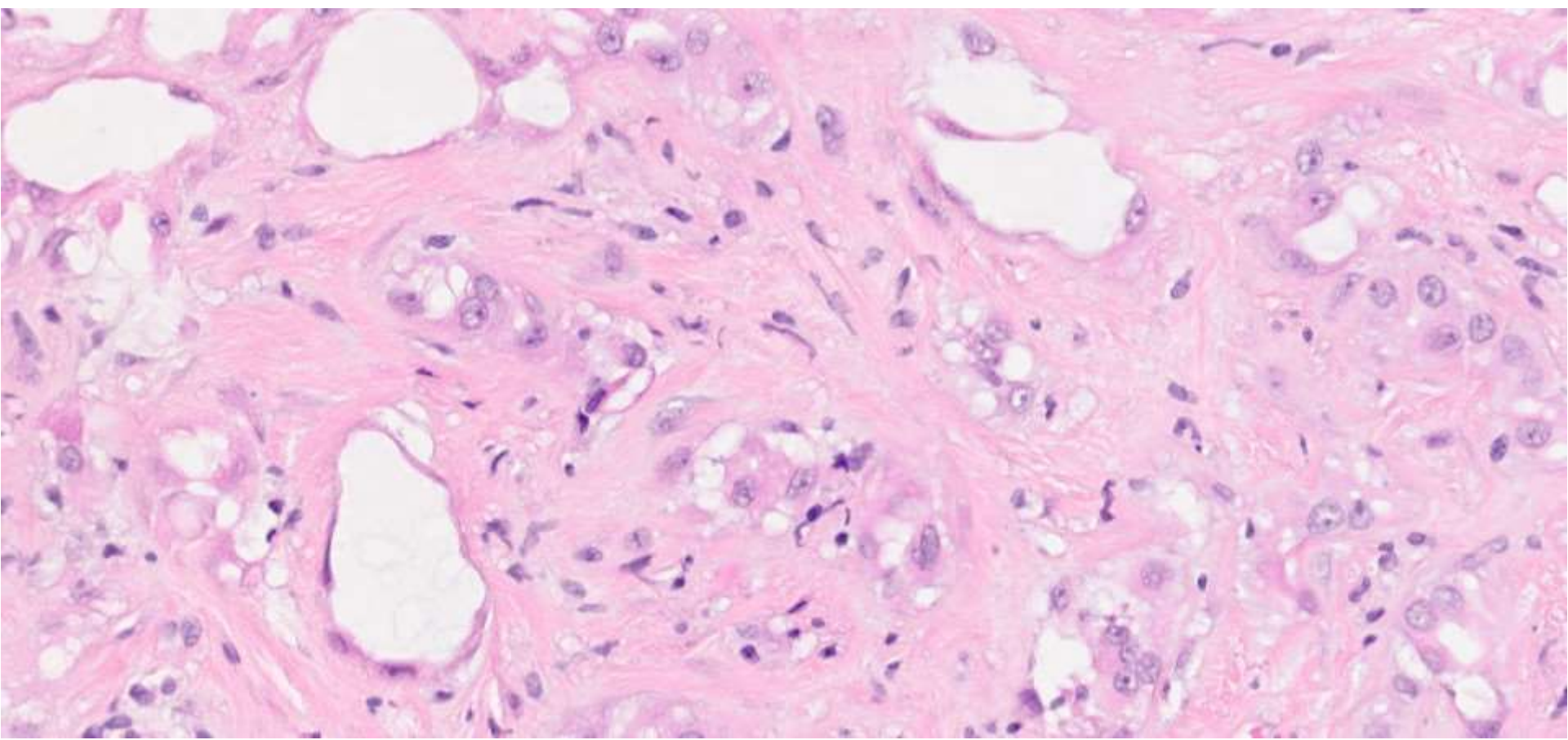














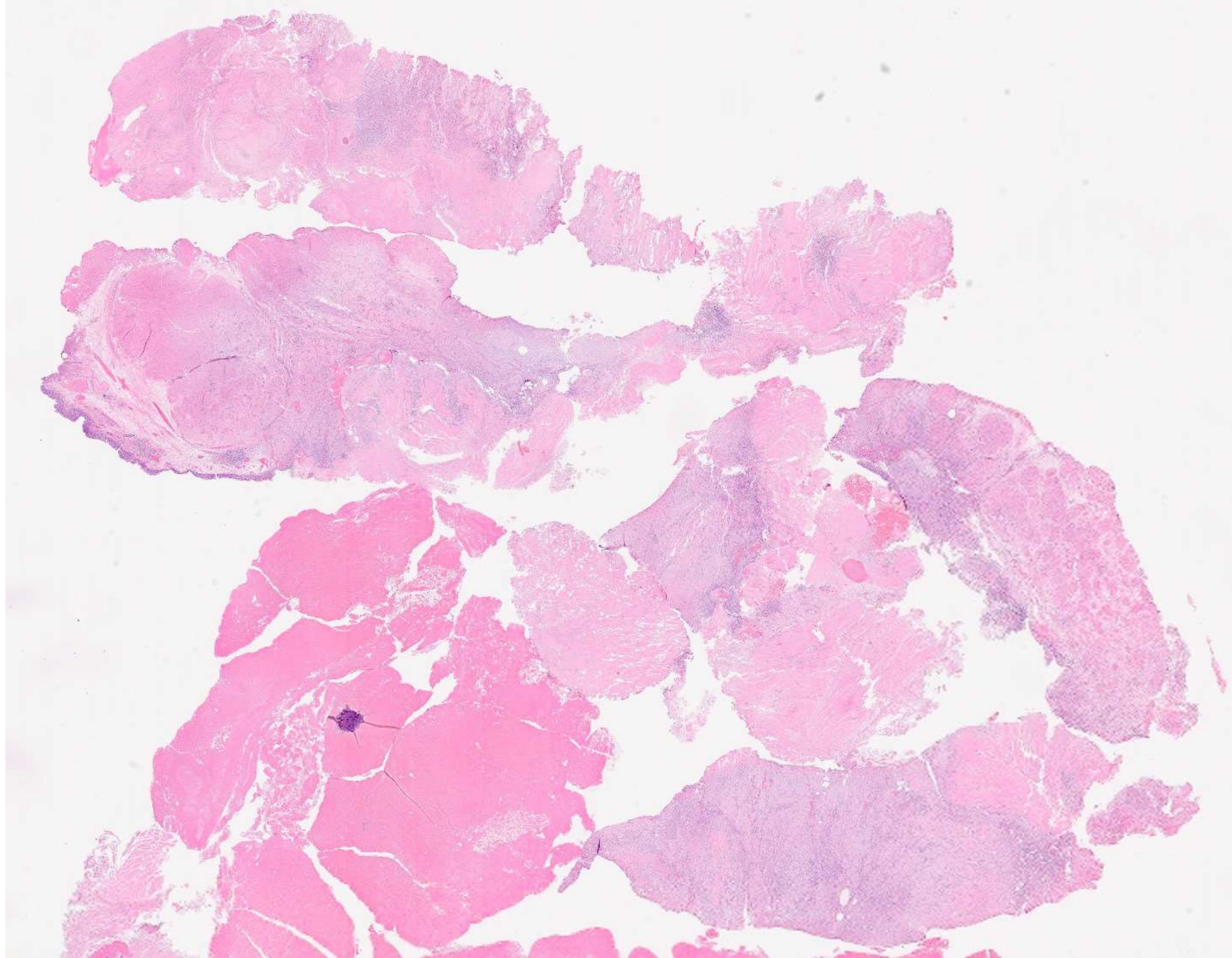
# 22-0808

Direct link to scanned slide:

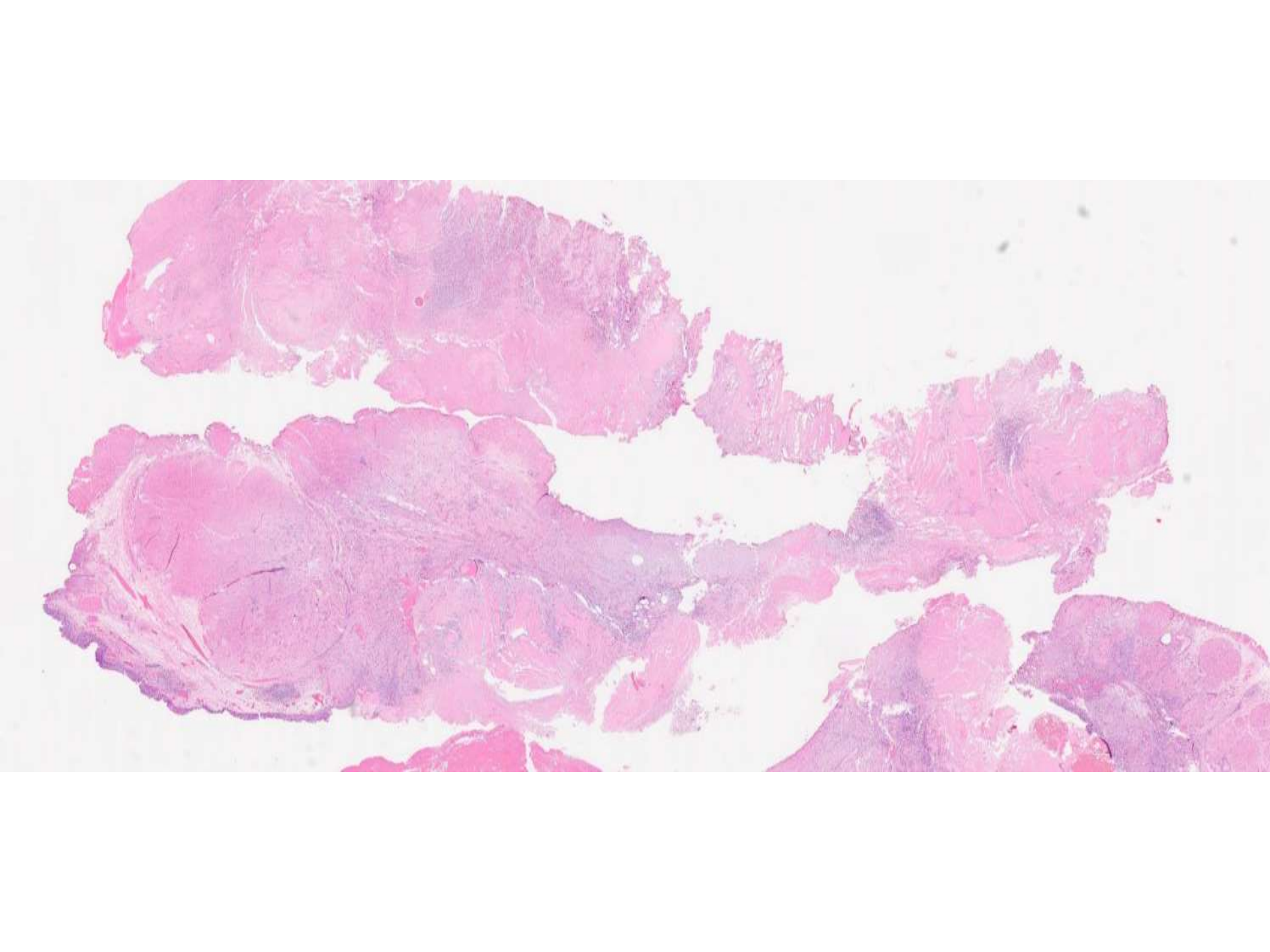
<https://pathpresenter.net/public/display?token=7655283d>

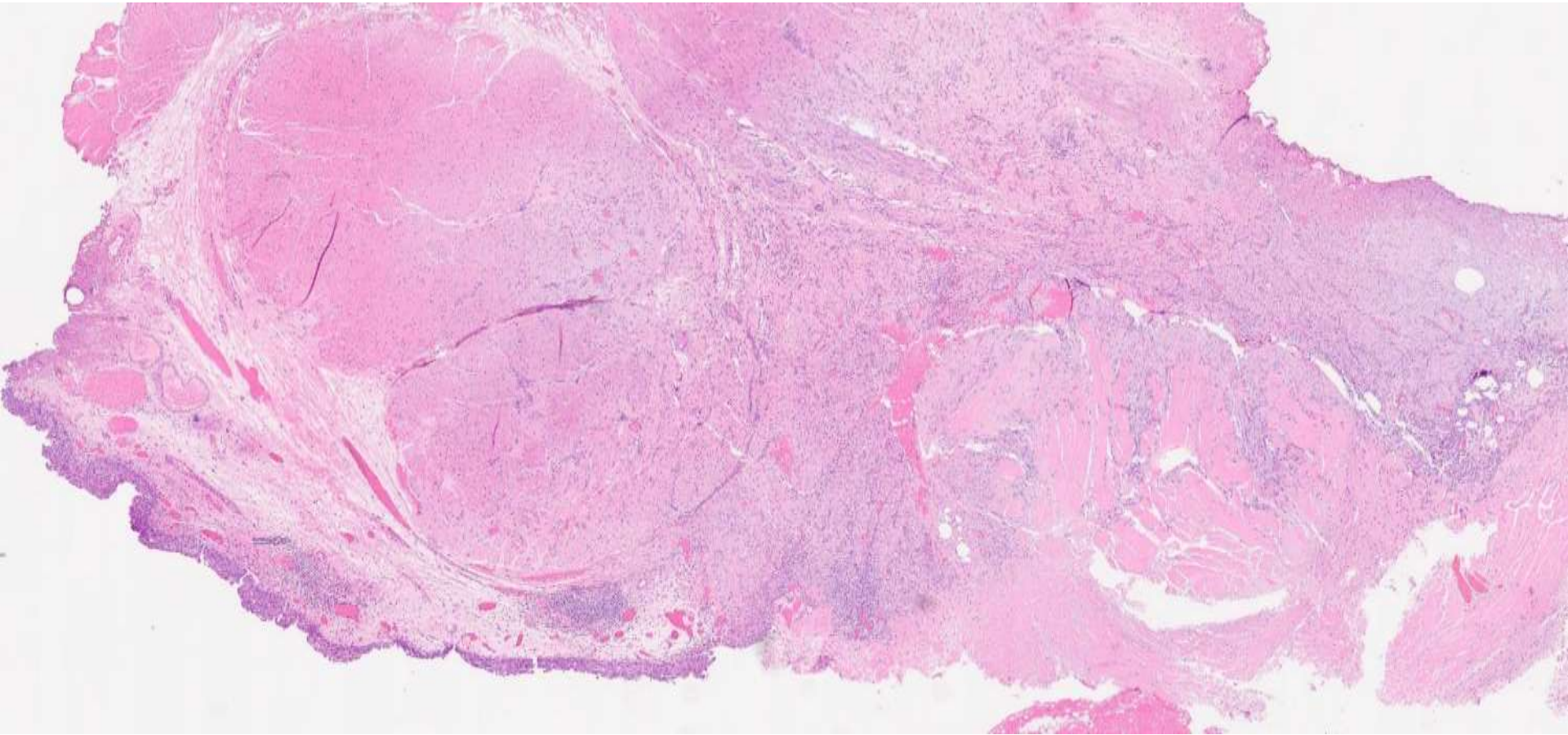
**Ankur Sangoi; El Camino Hospital**

70ish M, TURBT.

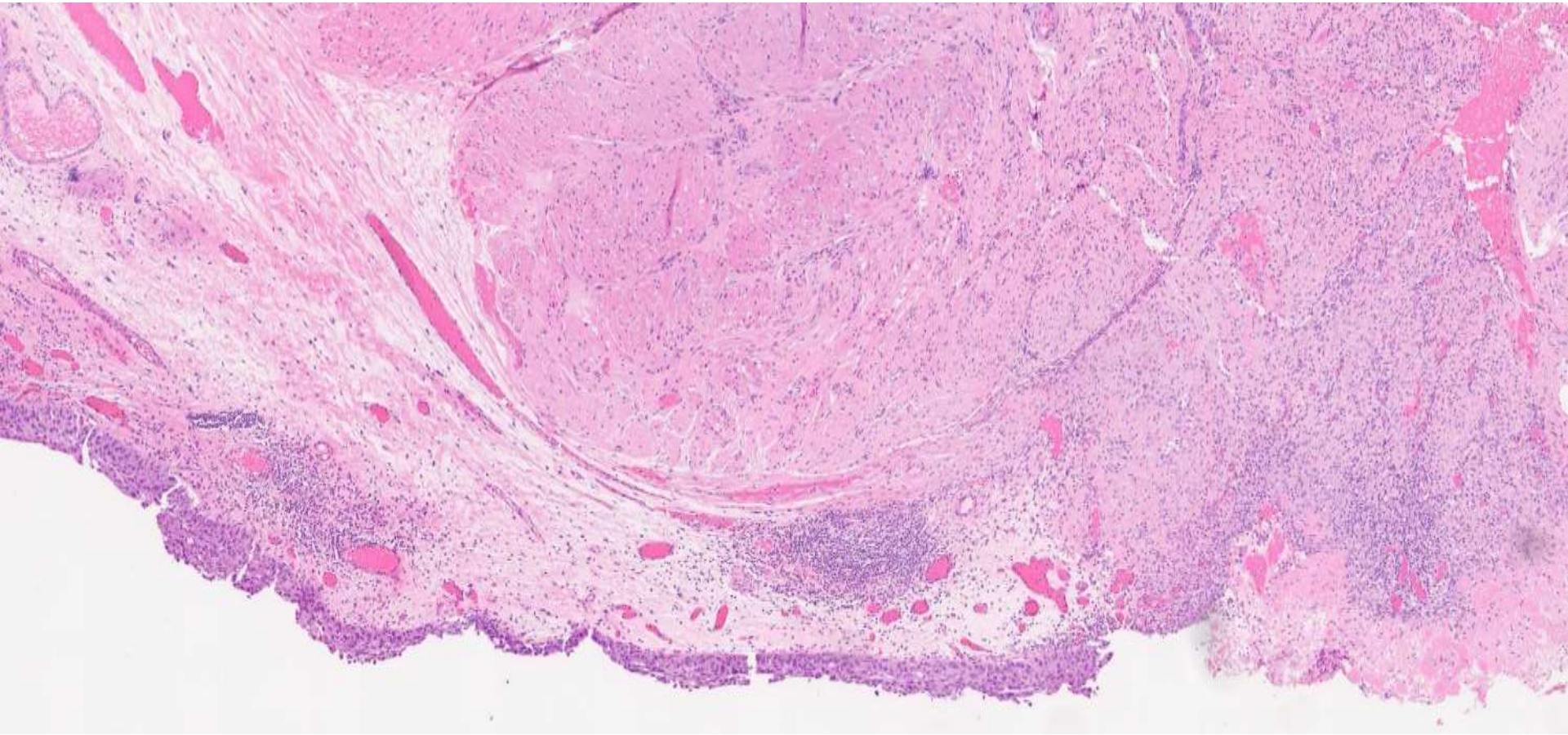




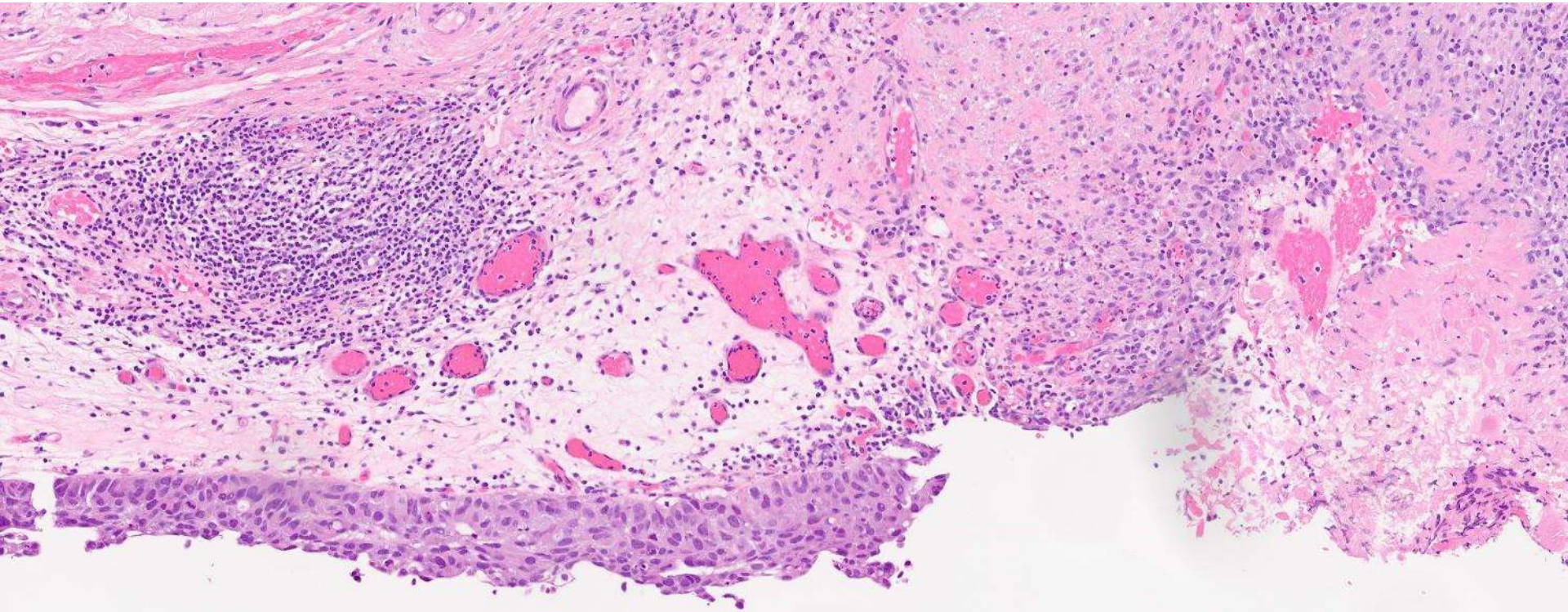




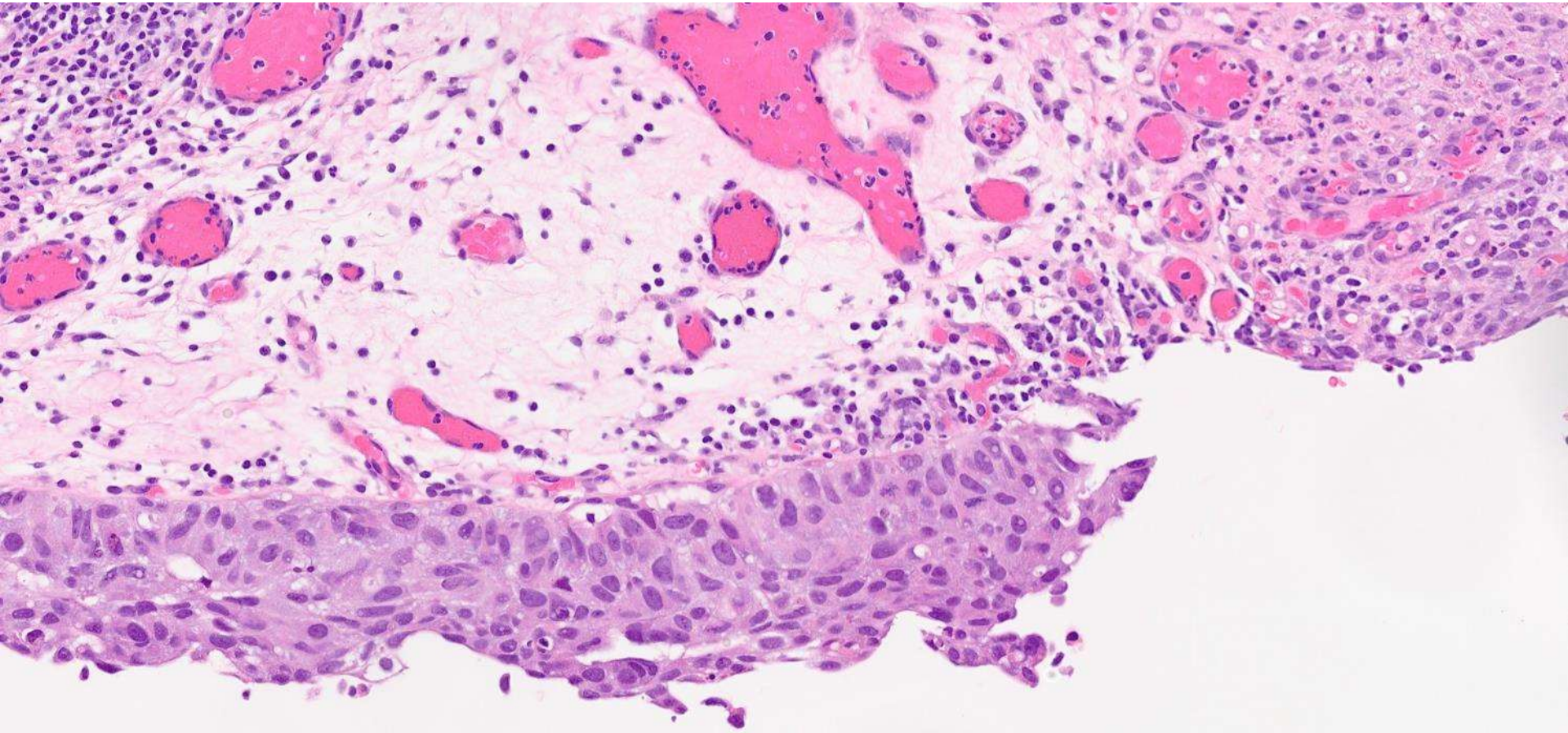


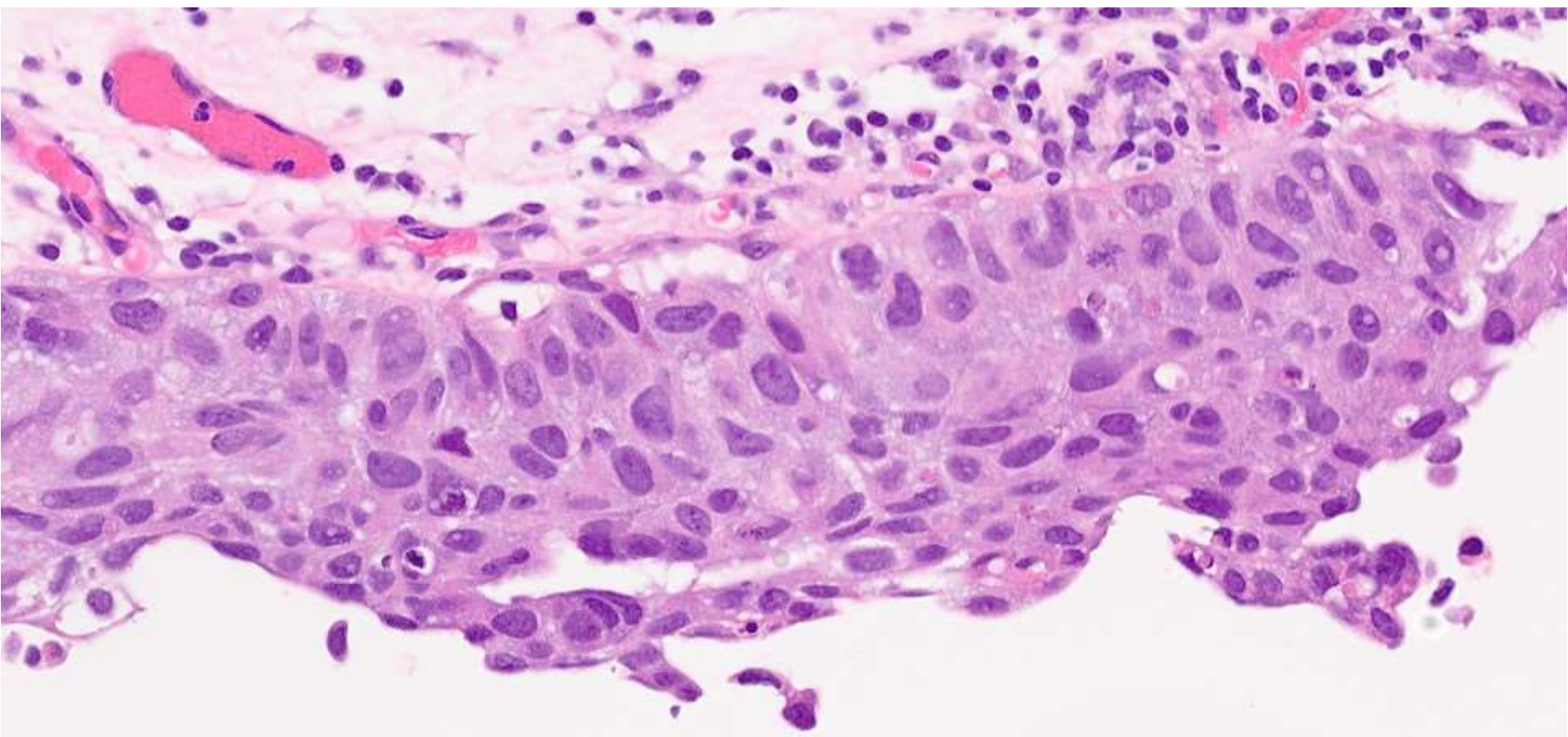














# DIAGNOSIS?



EVALUATION QR CODE!  
Hold smartphone camera on code

