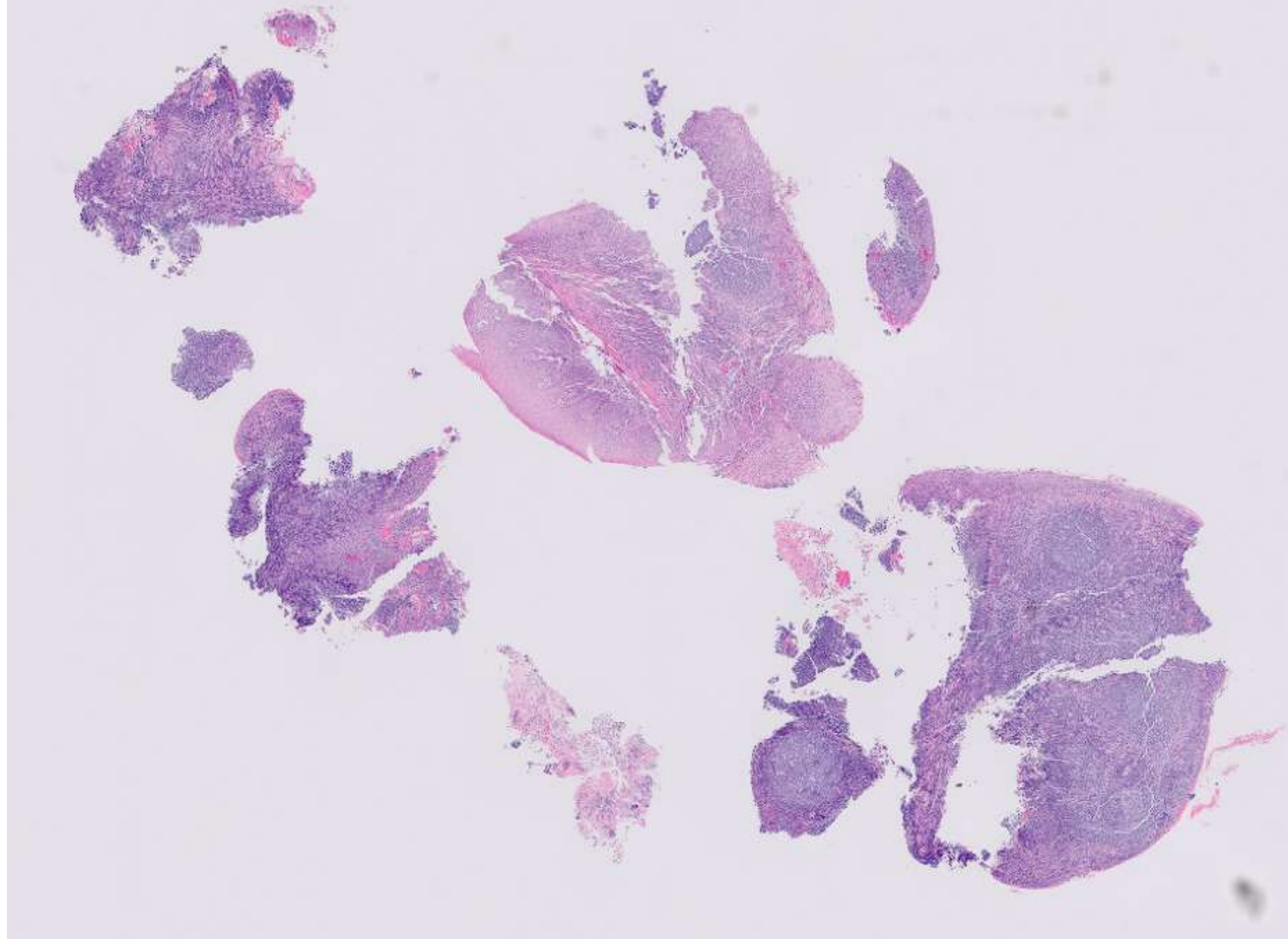
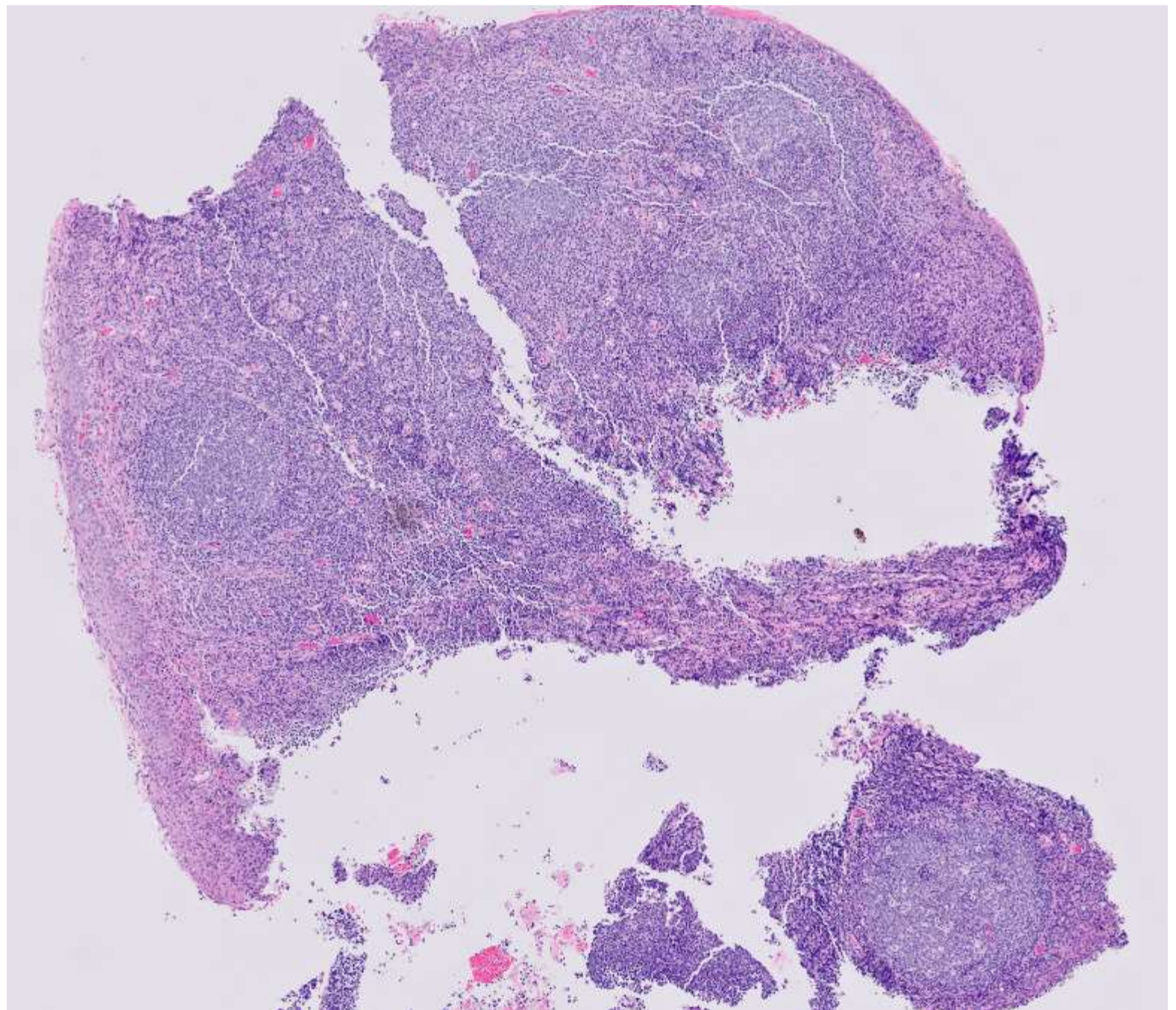


22-0701

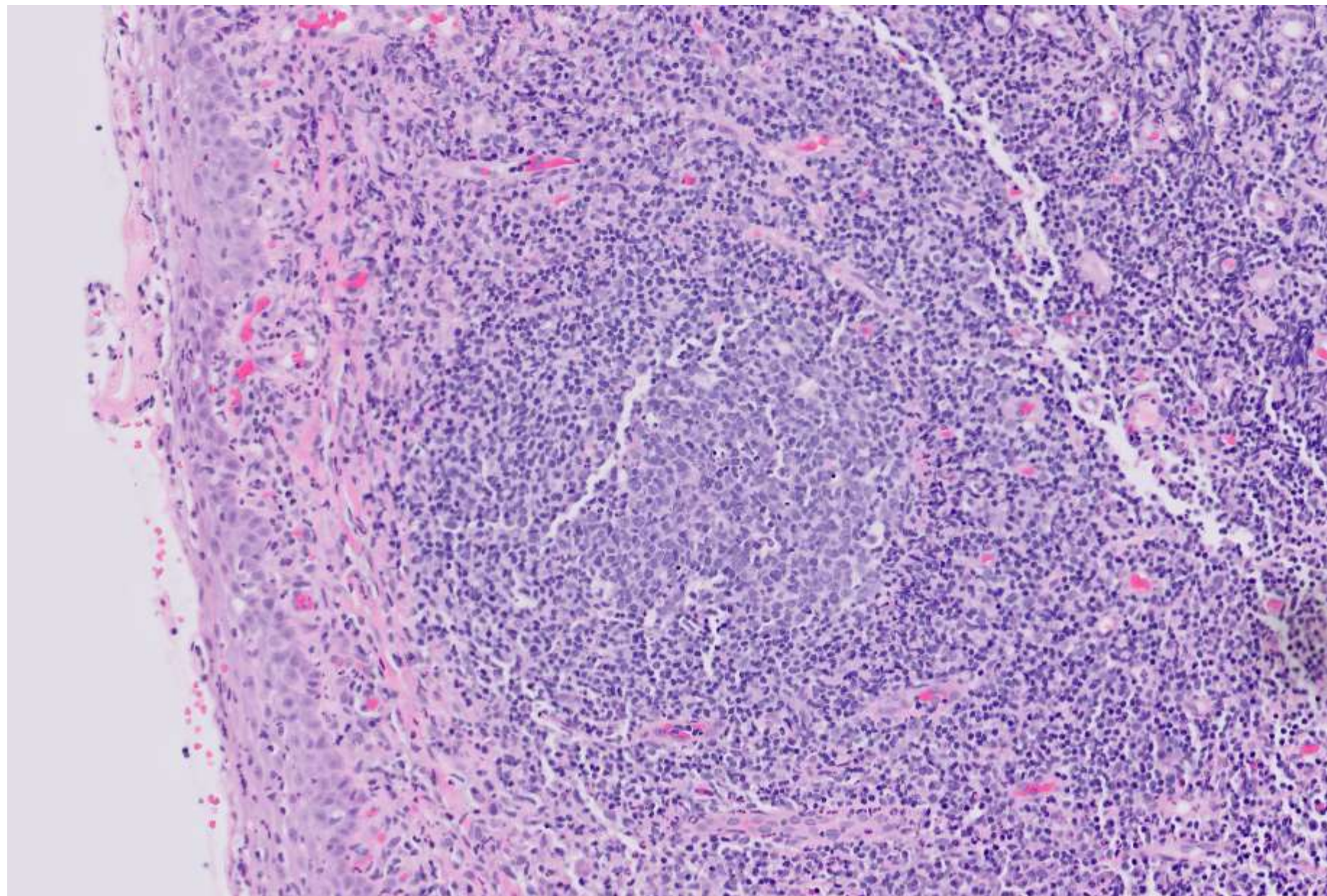
**Emily Chan; UCSF**

20ish M with recurrent right tonsillary swelling for one year. Biopsy of area with shallow ulceration.

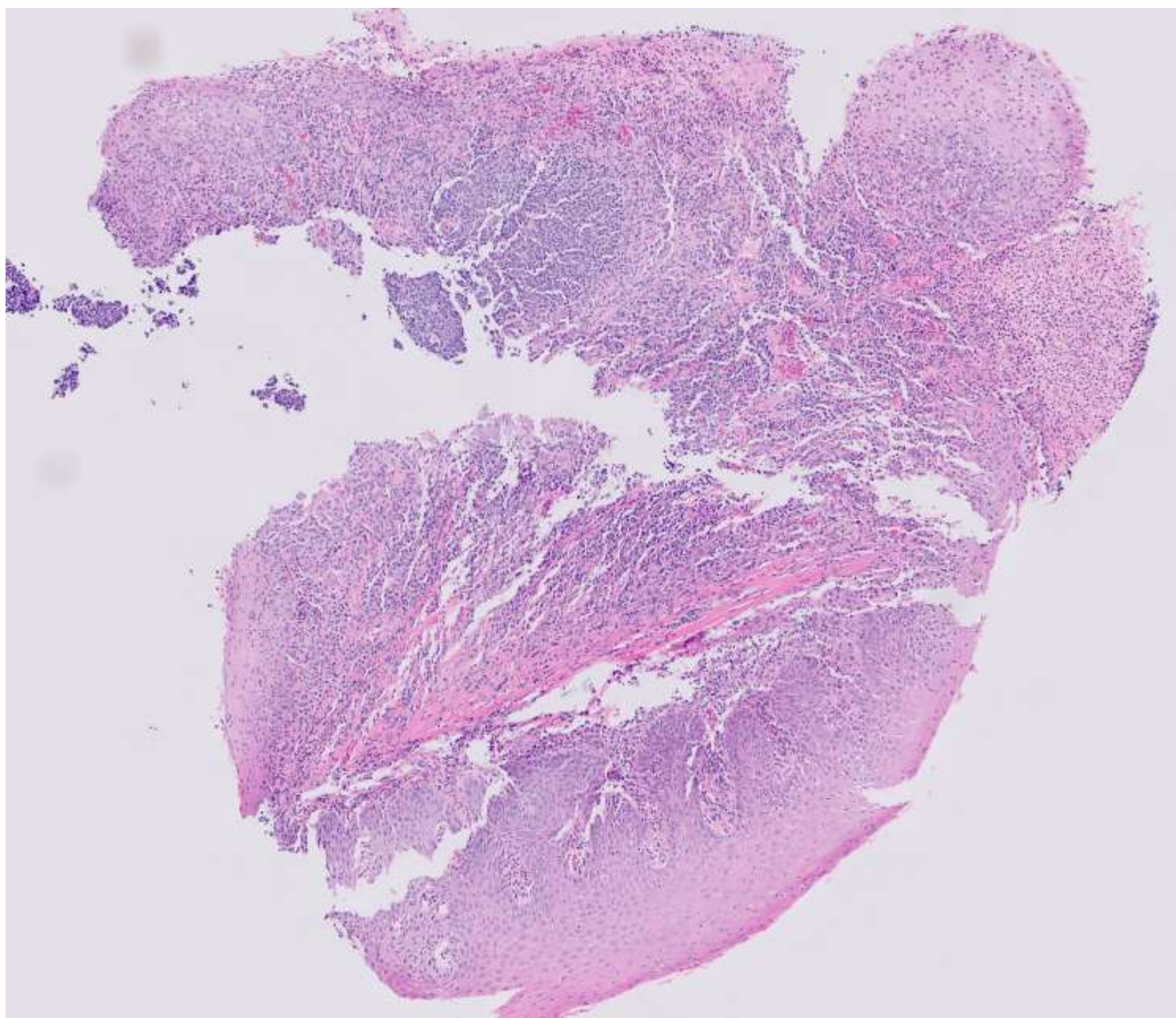




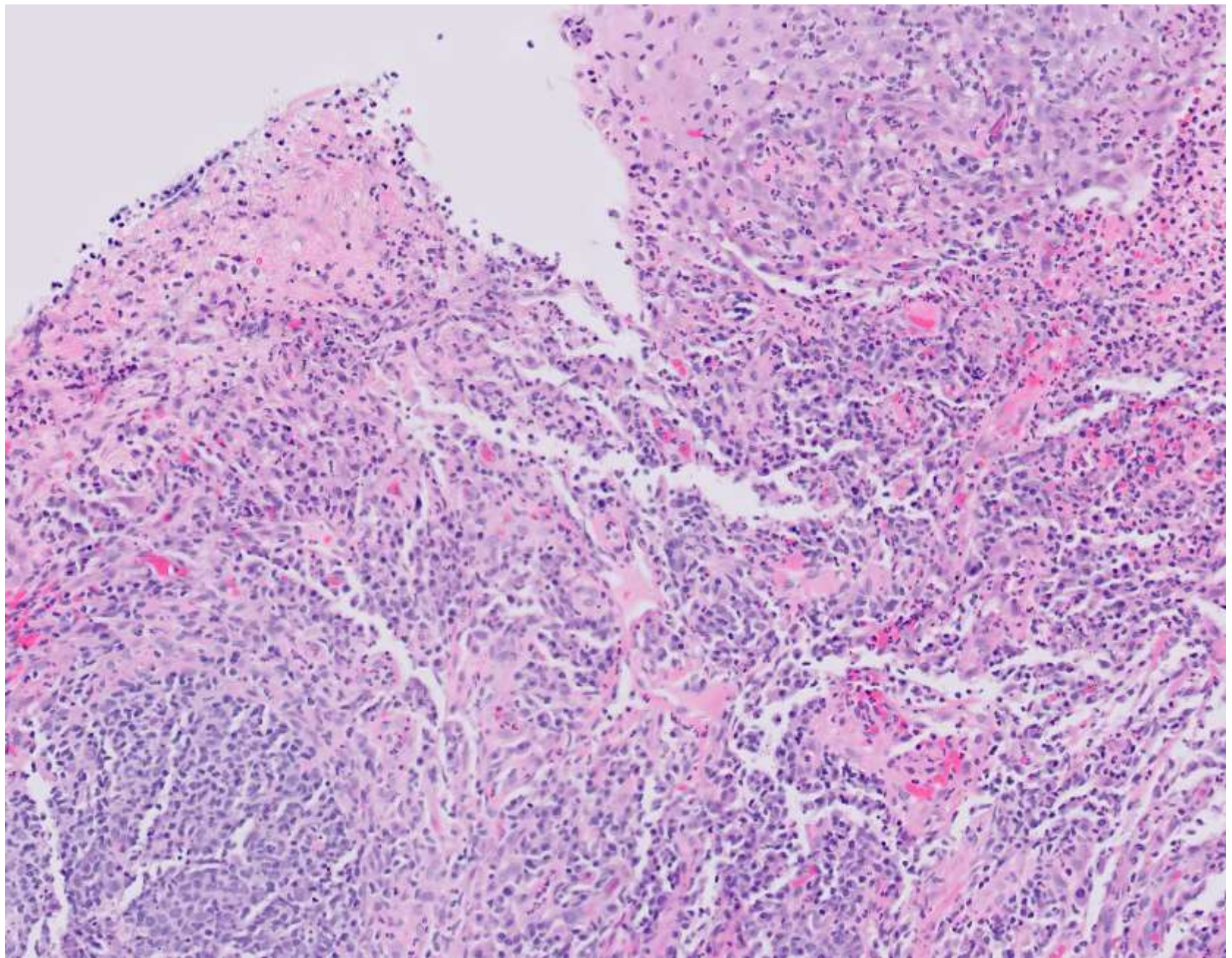




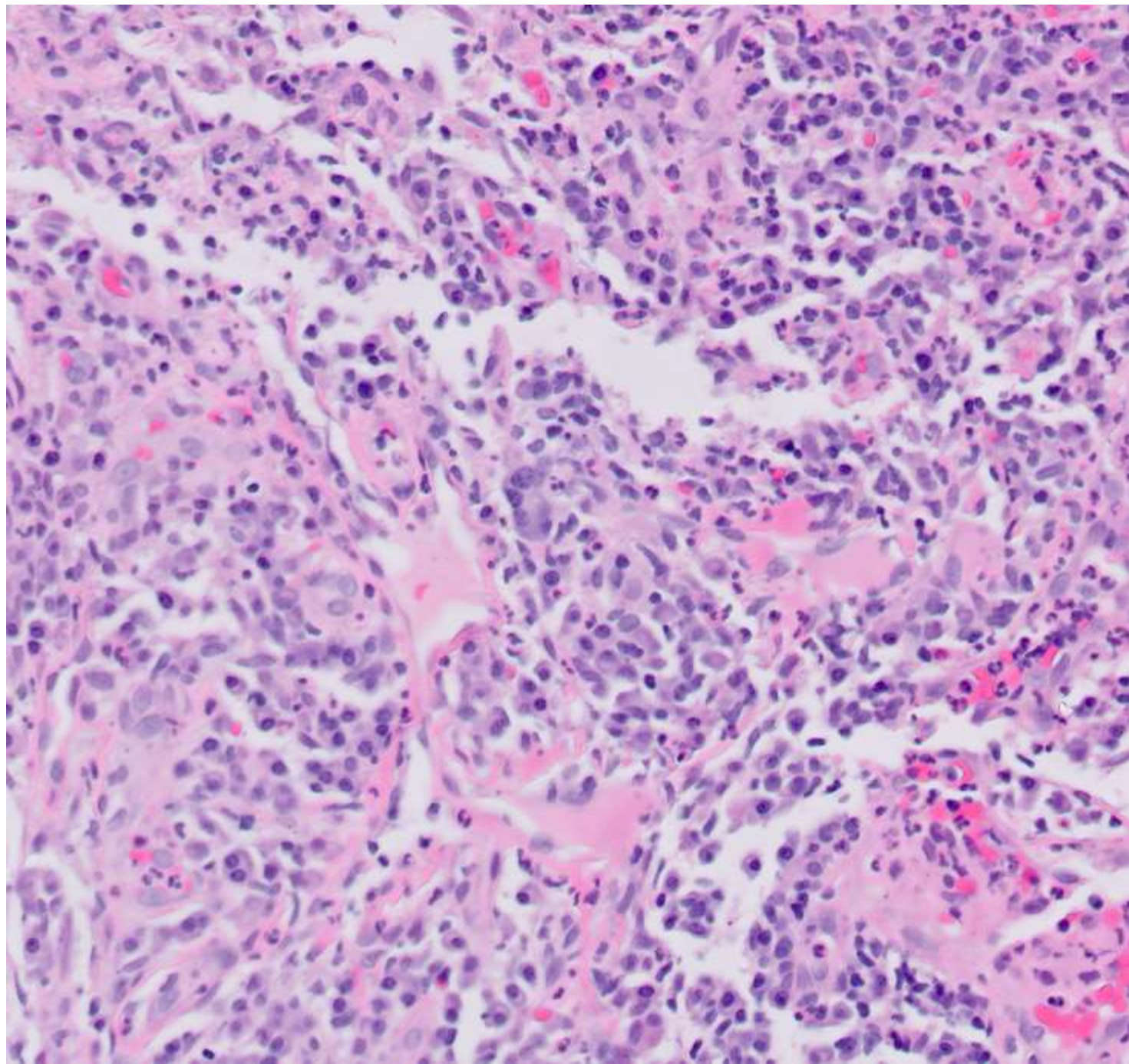












# DIAGNOSIS?

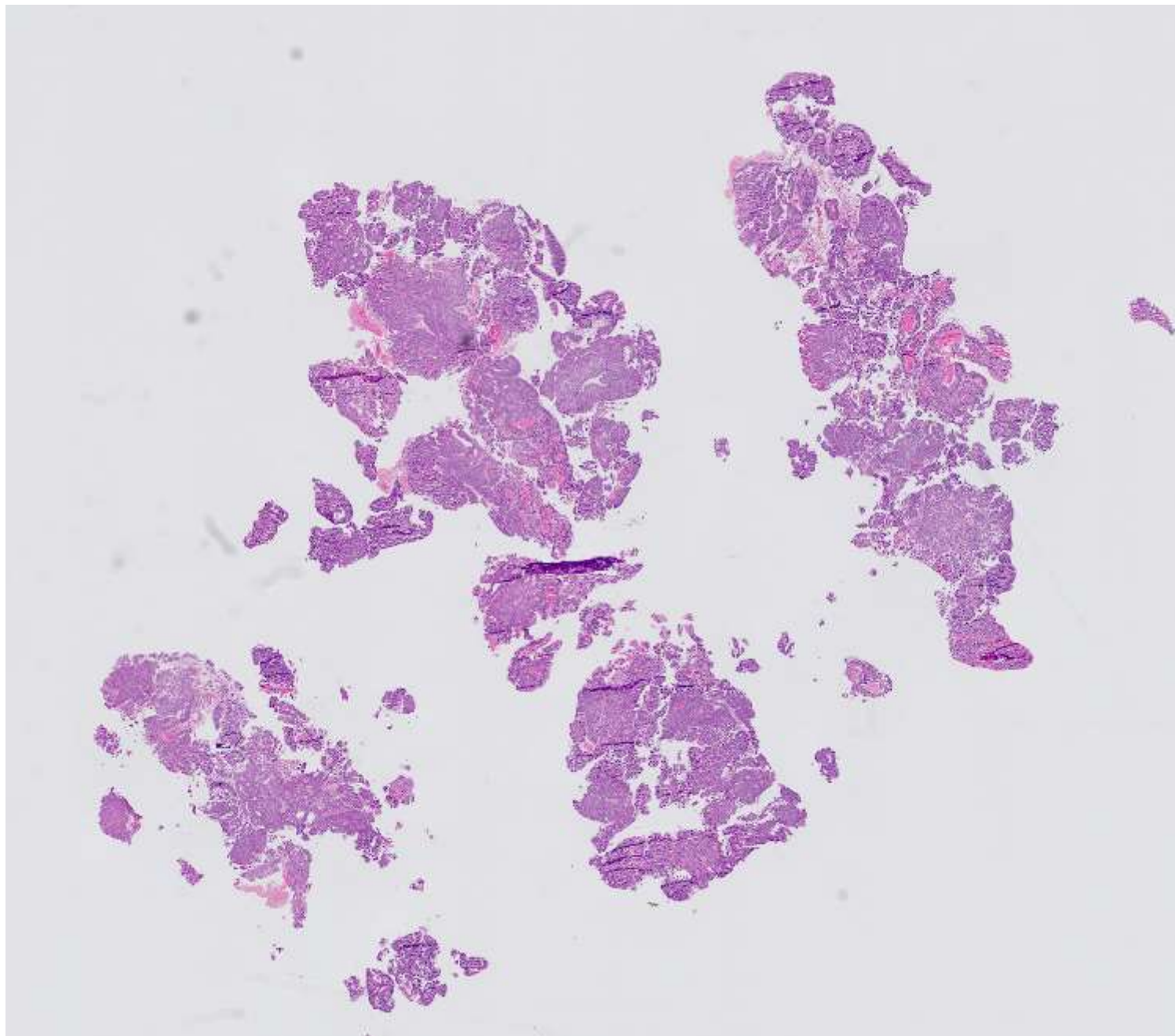




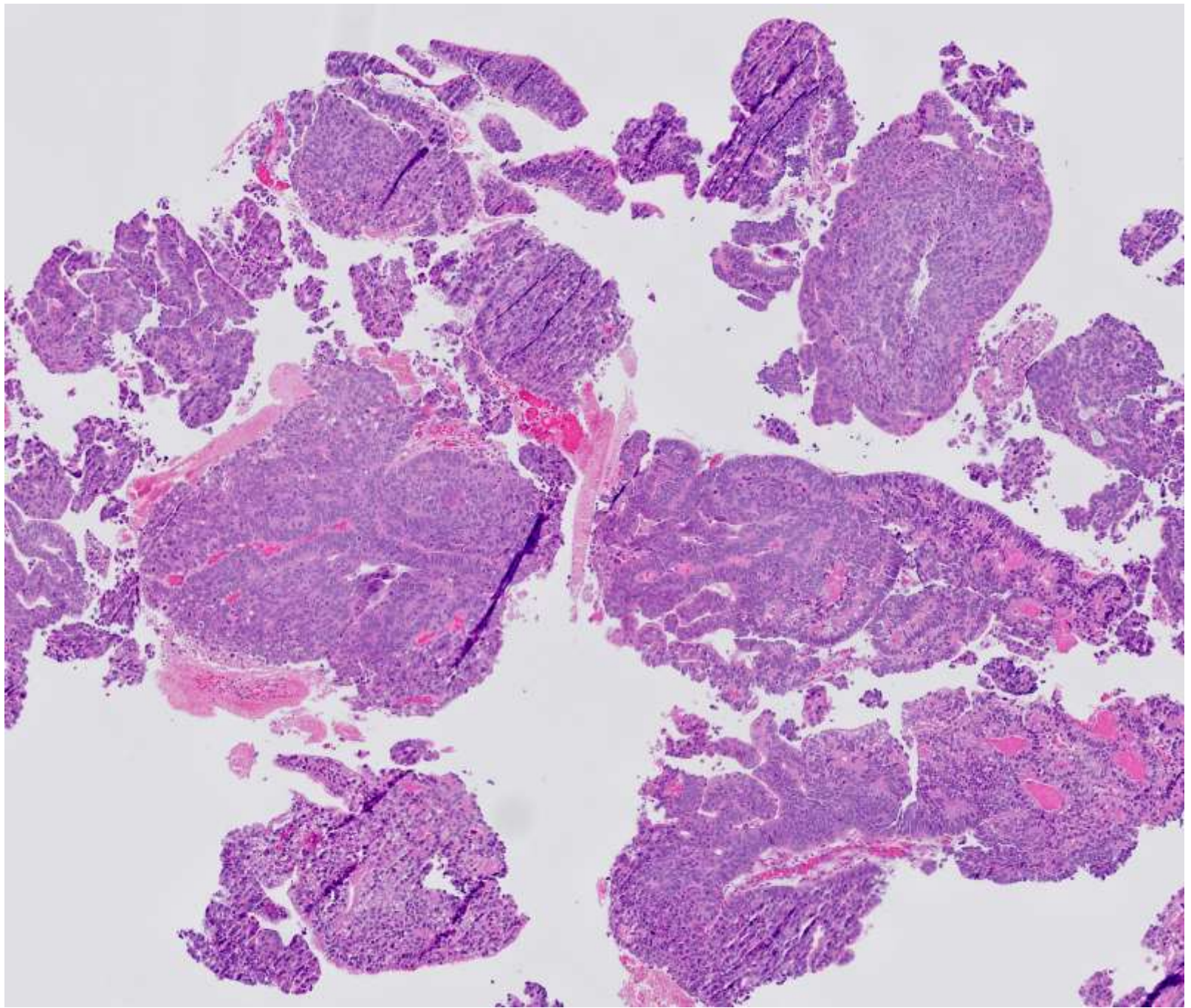
22-0702

**Emily Chan; UCSF**

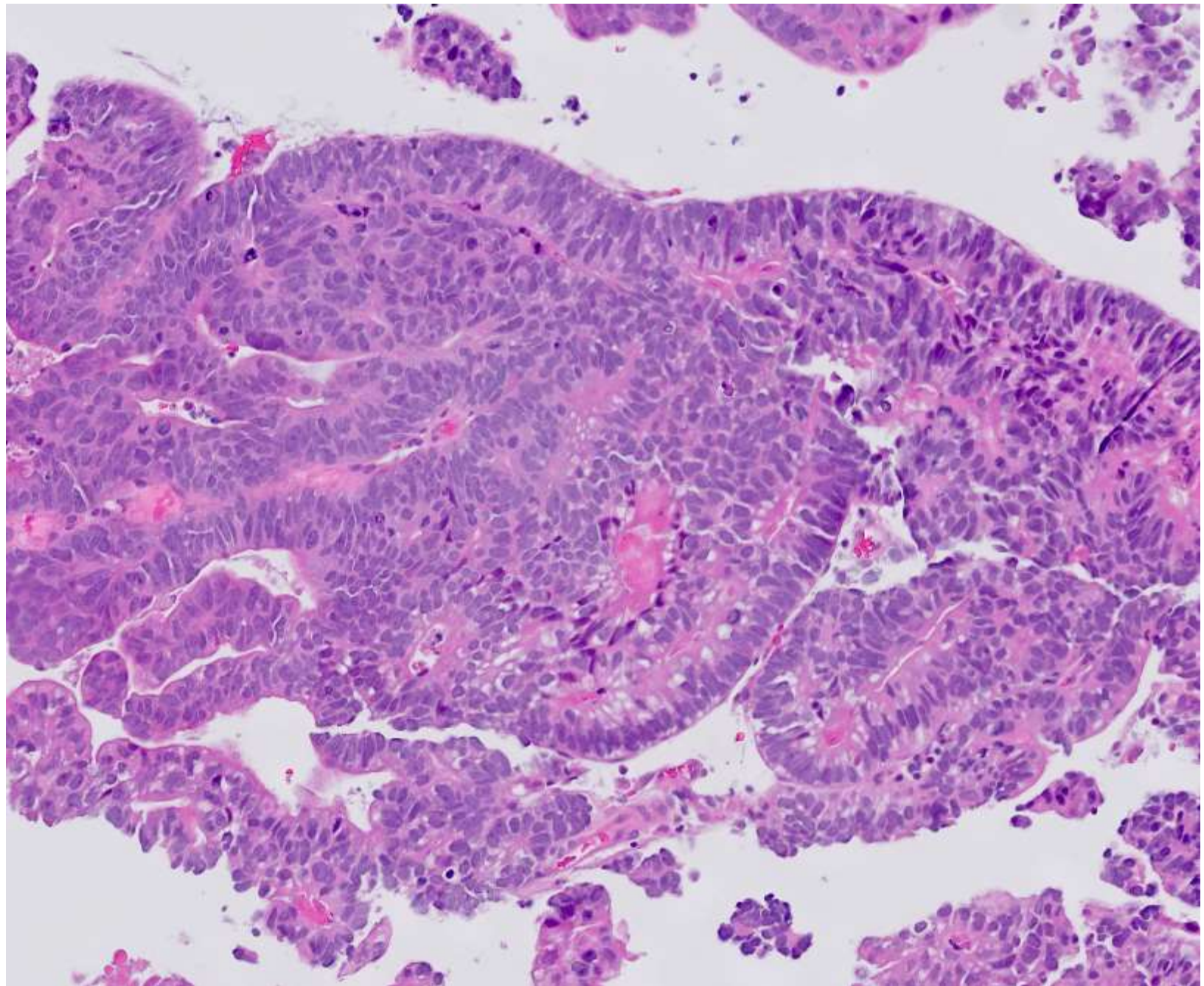
80ish M with dysuria. Cystoscopy showed 3mm right posterior wall mass with surrounding erythema.



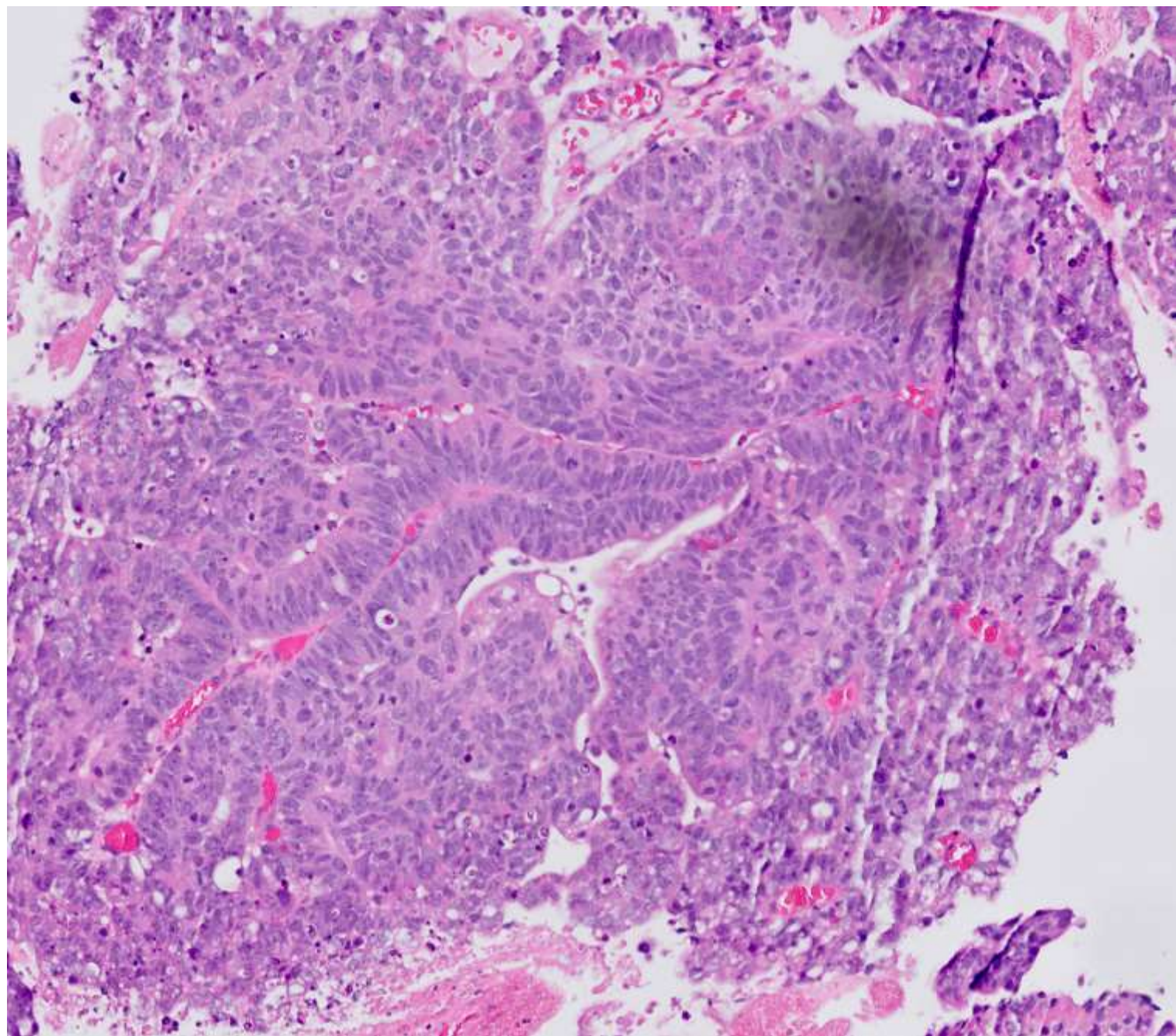




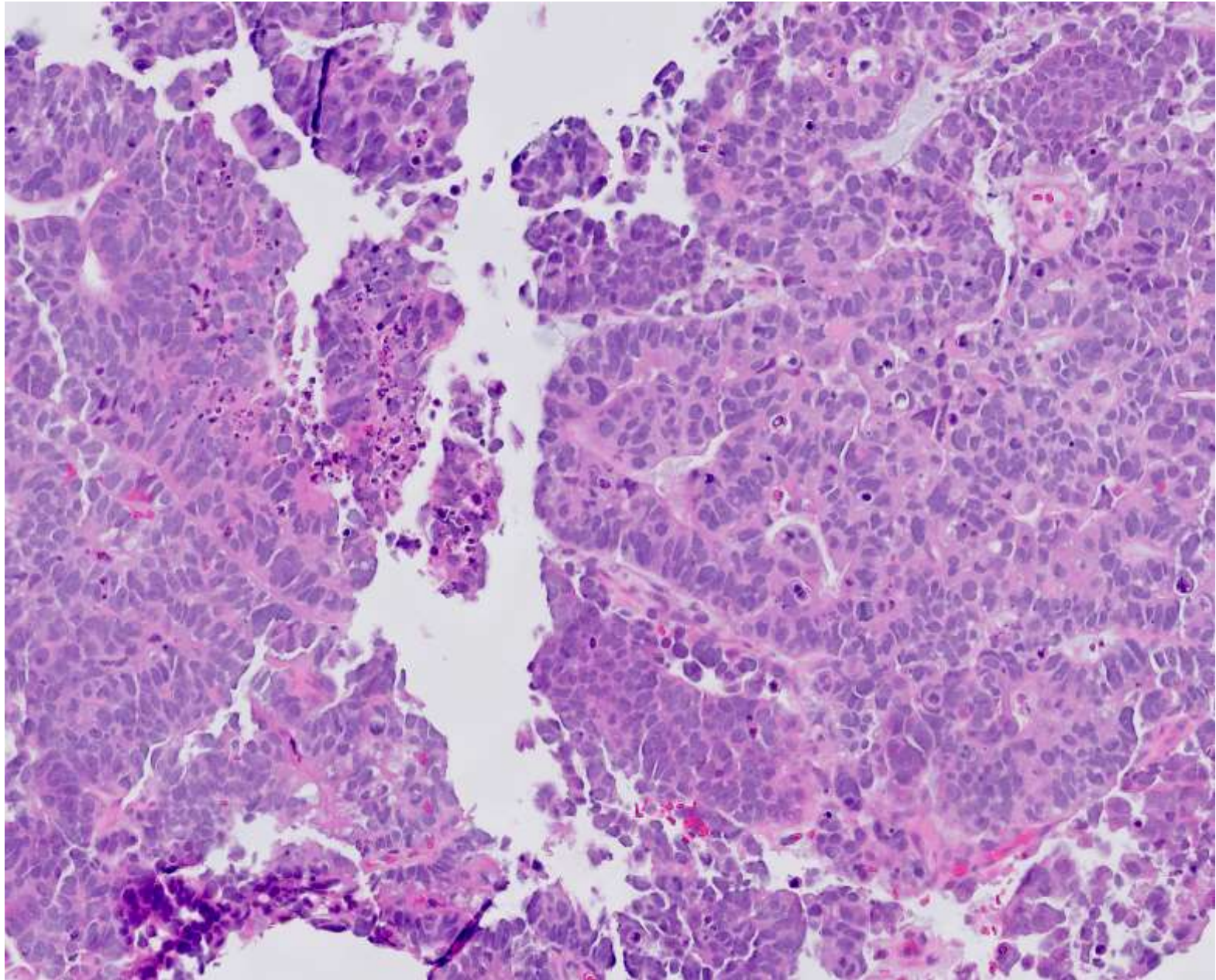




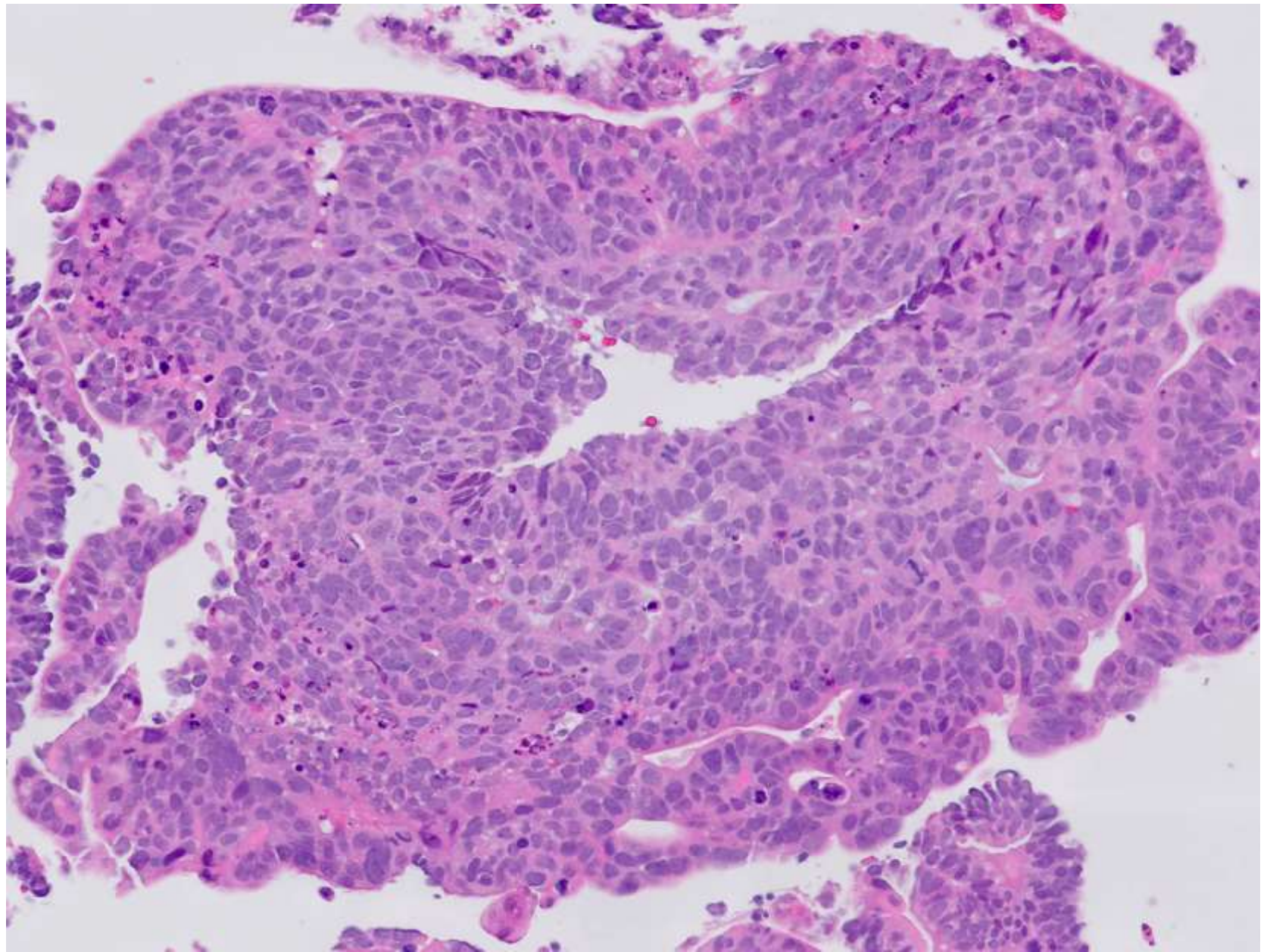




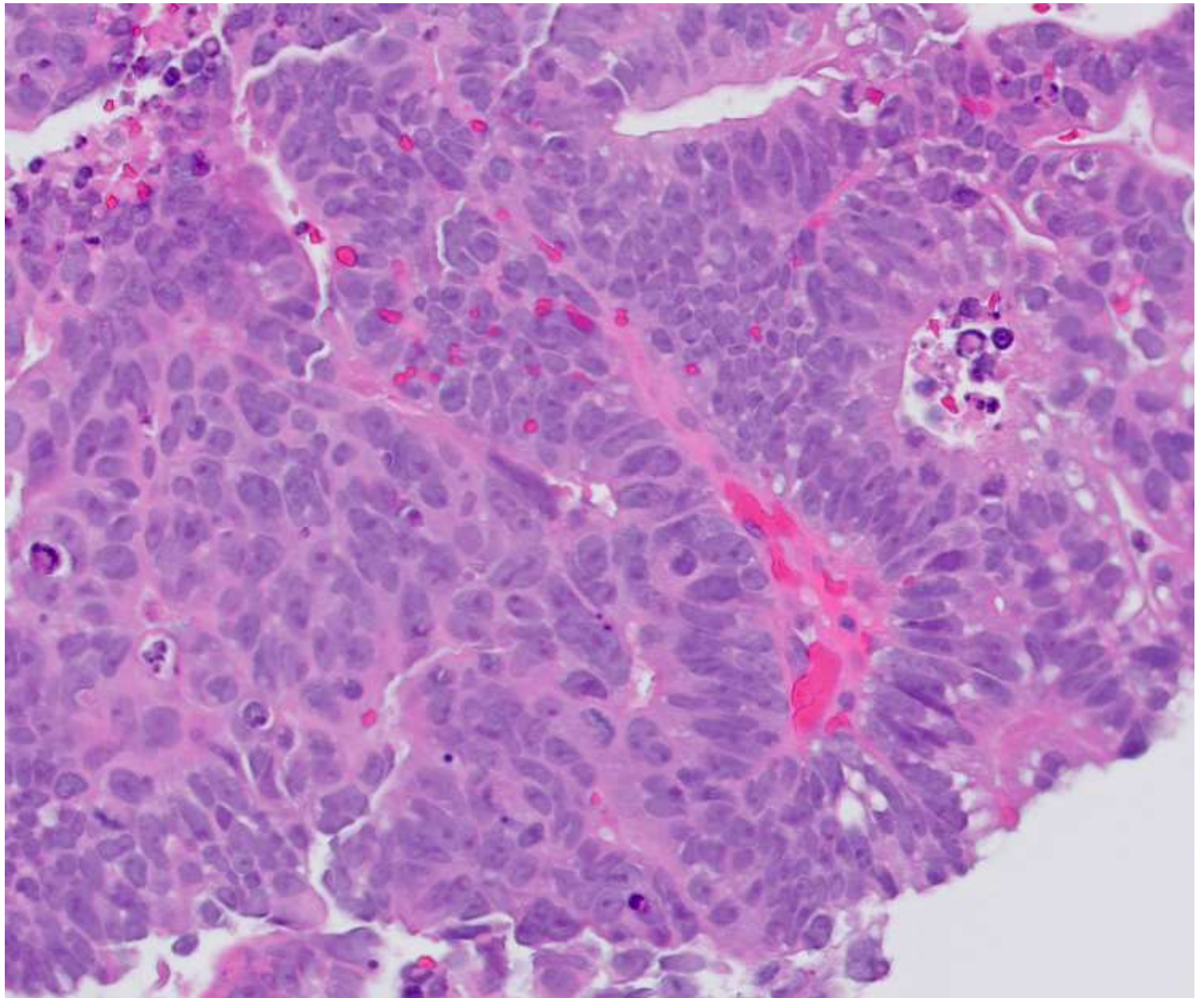






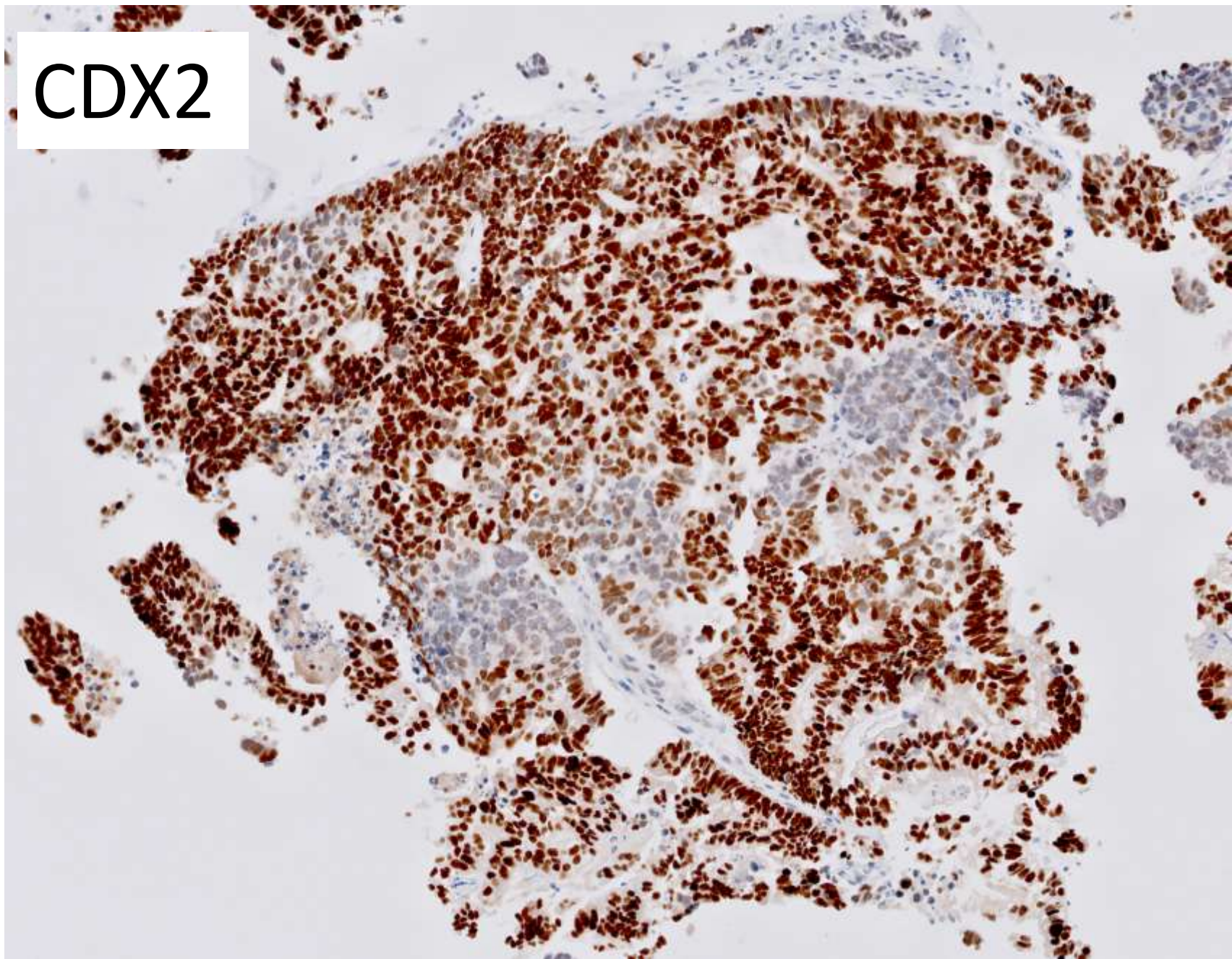








CDX2



# DIAGNOSIS?





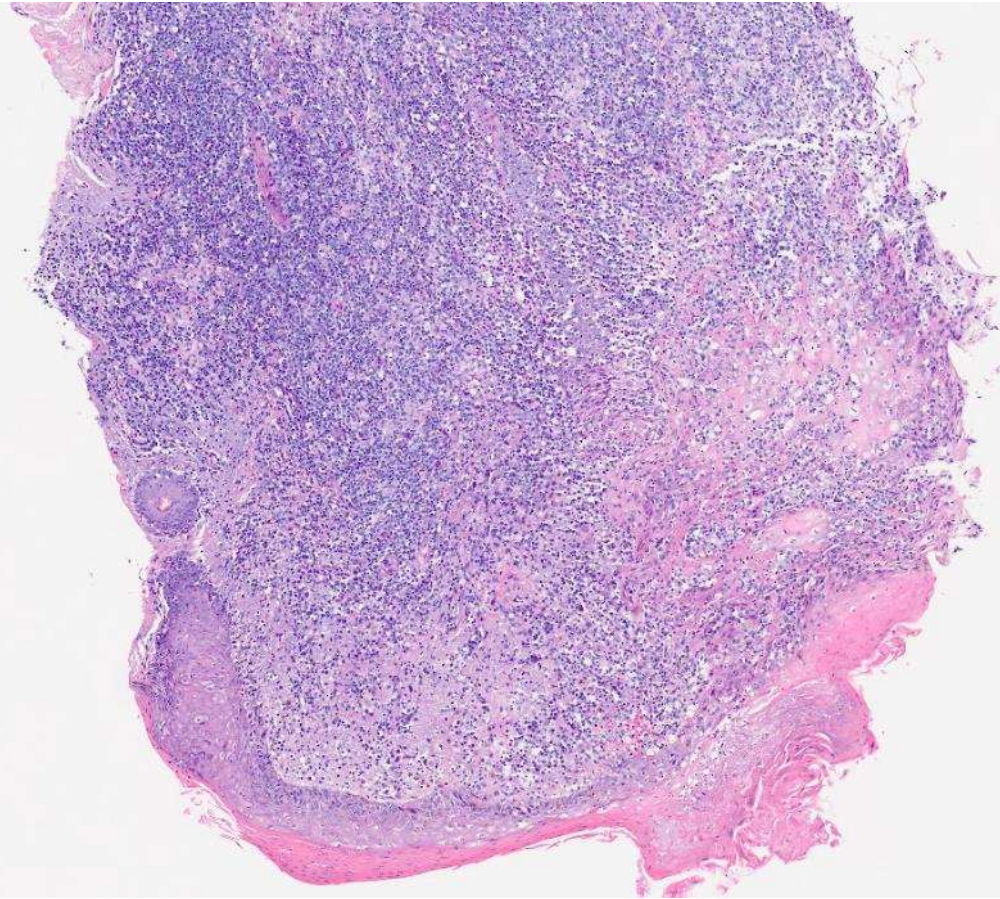
22-0703

Direct link to scanned slide:

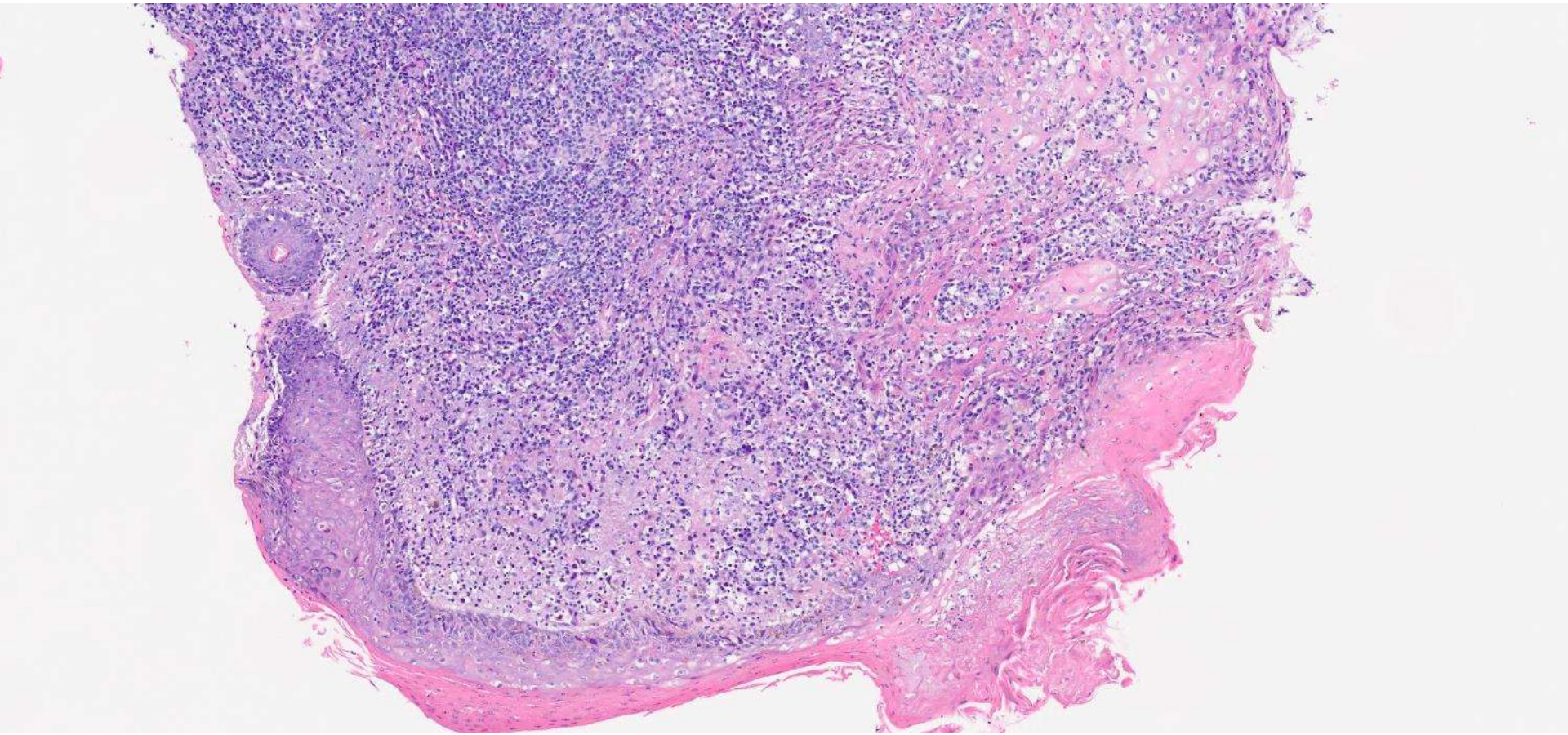
<https://pathpresenter.net/public/display?token=fff8b21d>

**Harris Goodman; Alameda Health System**

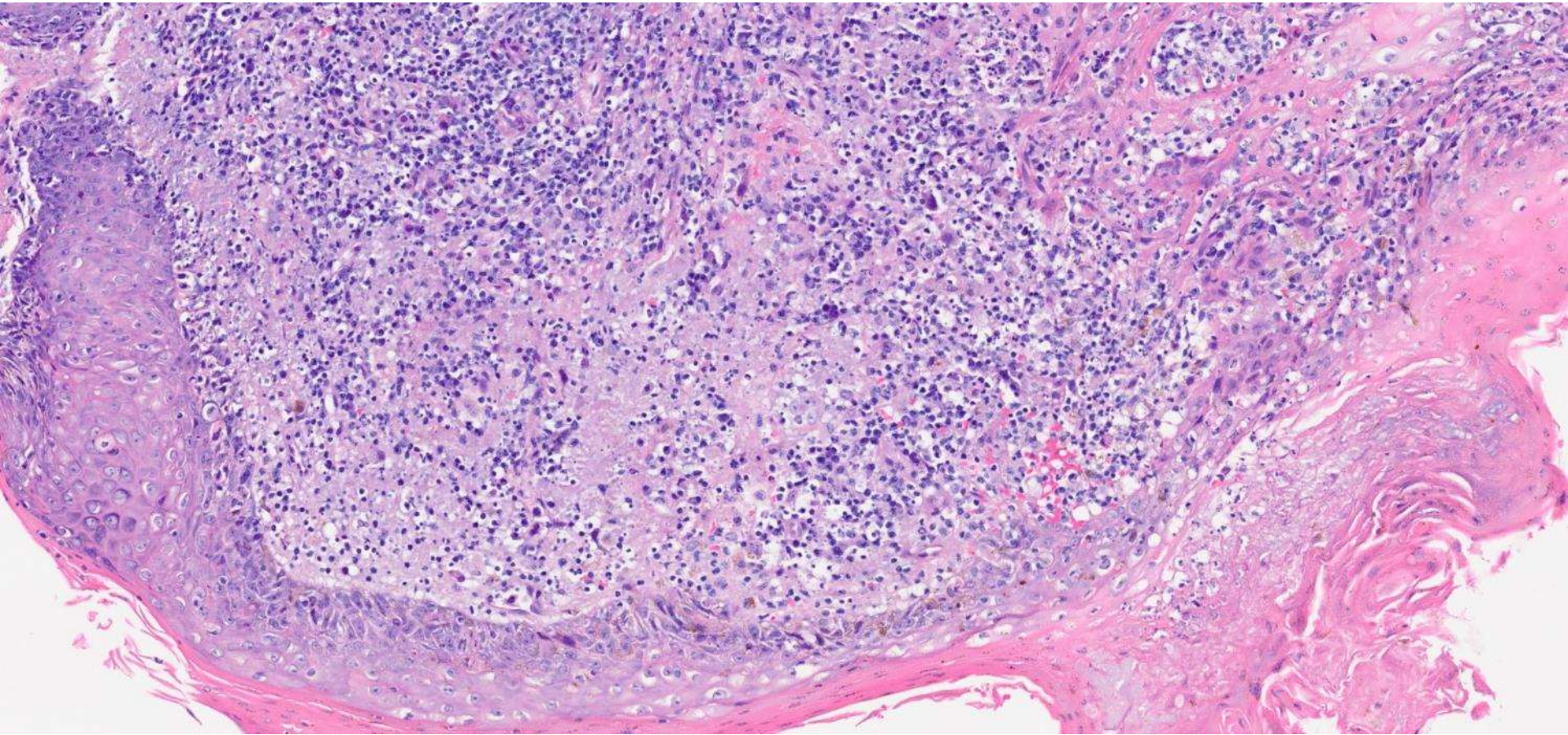
60ish F with plaque over bridge of nose, rosacea rule  
out infection.



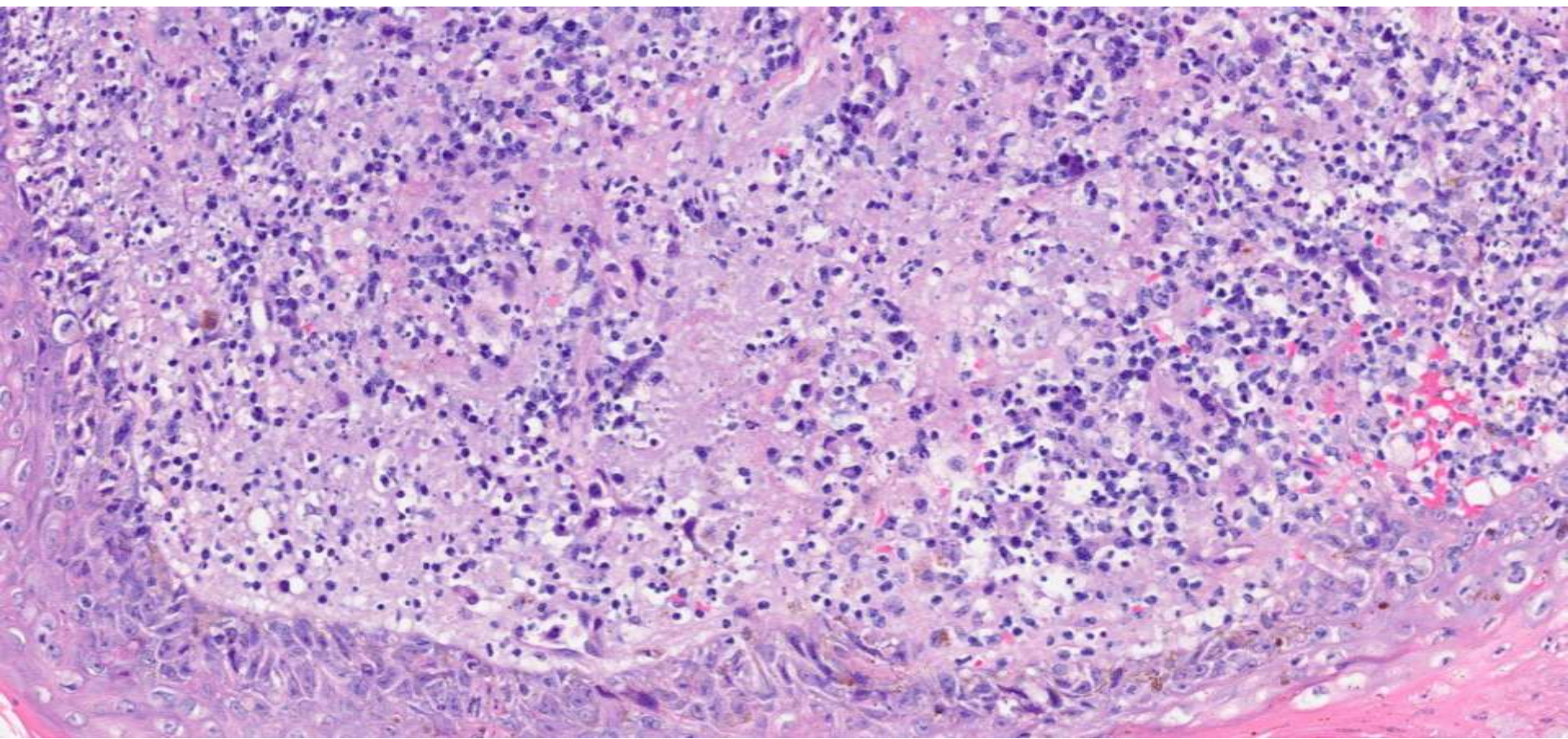




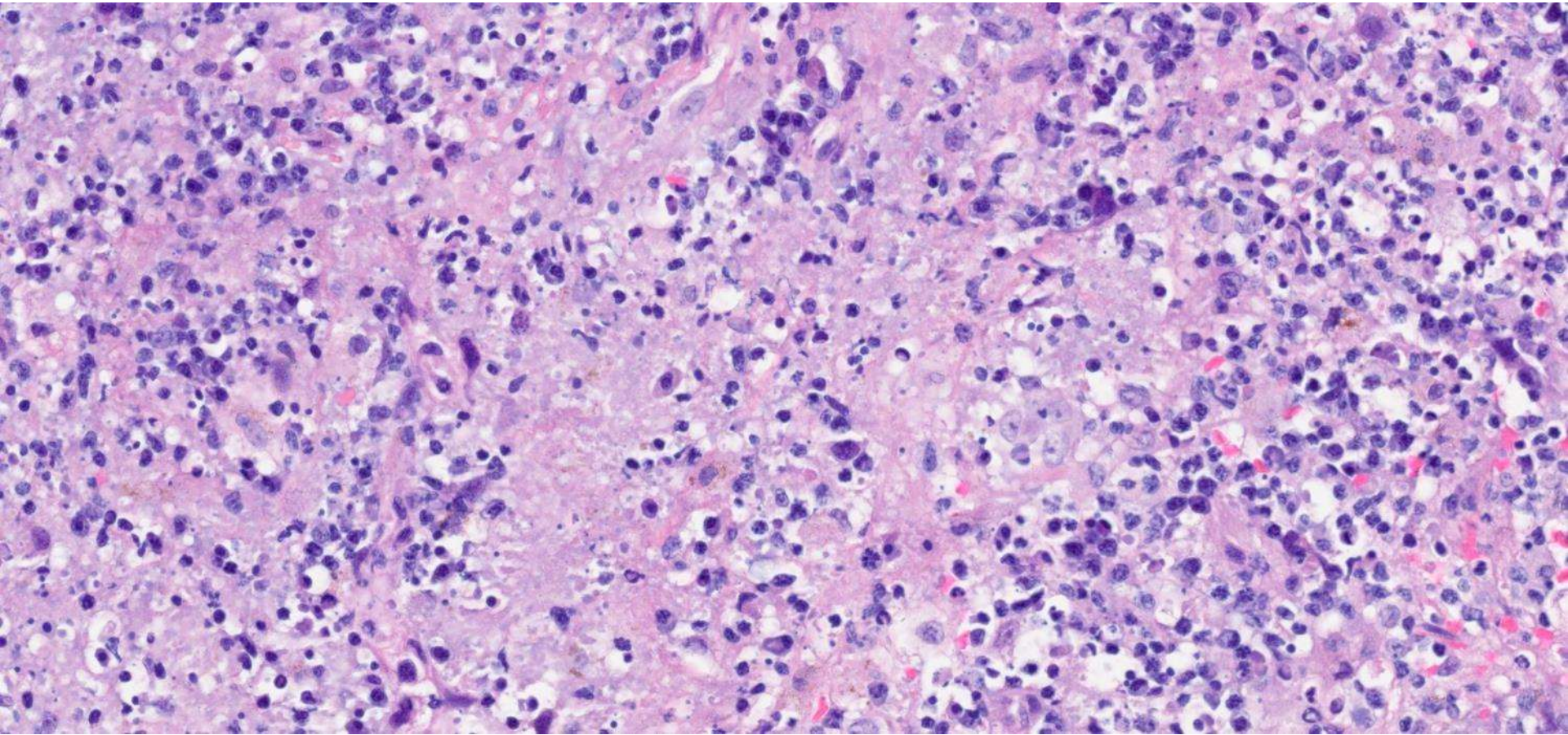




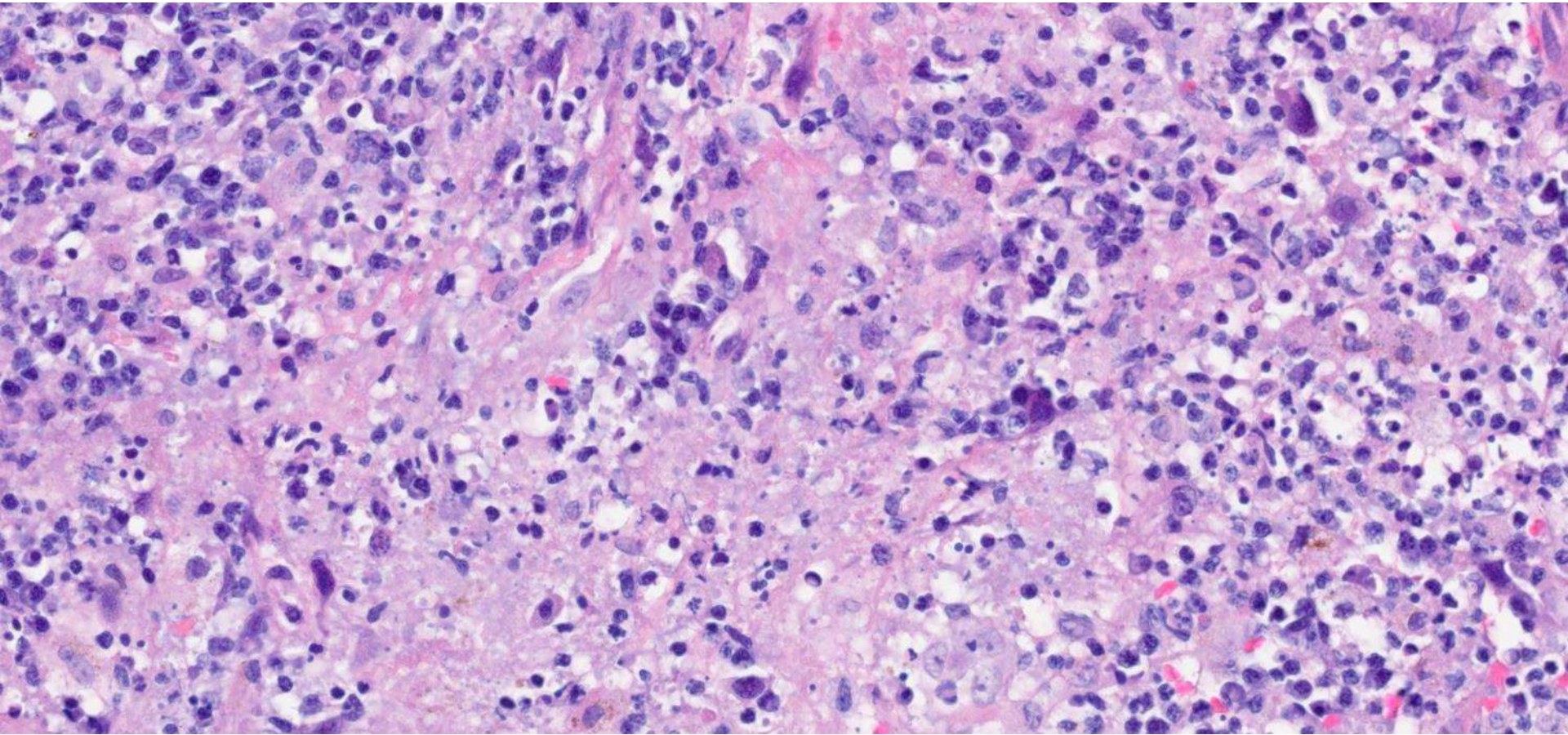




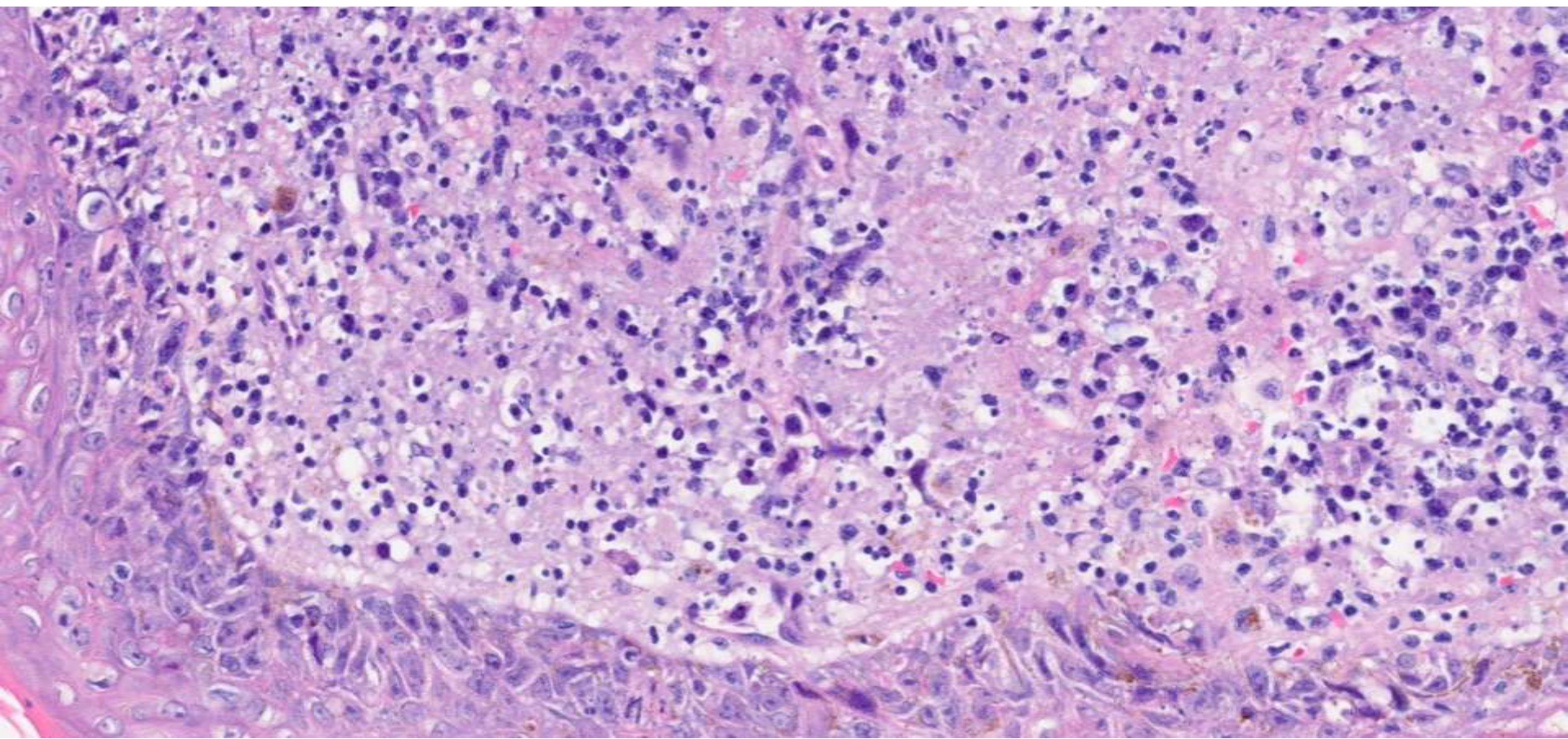




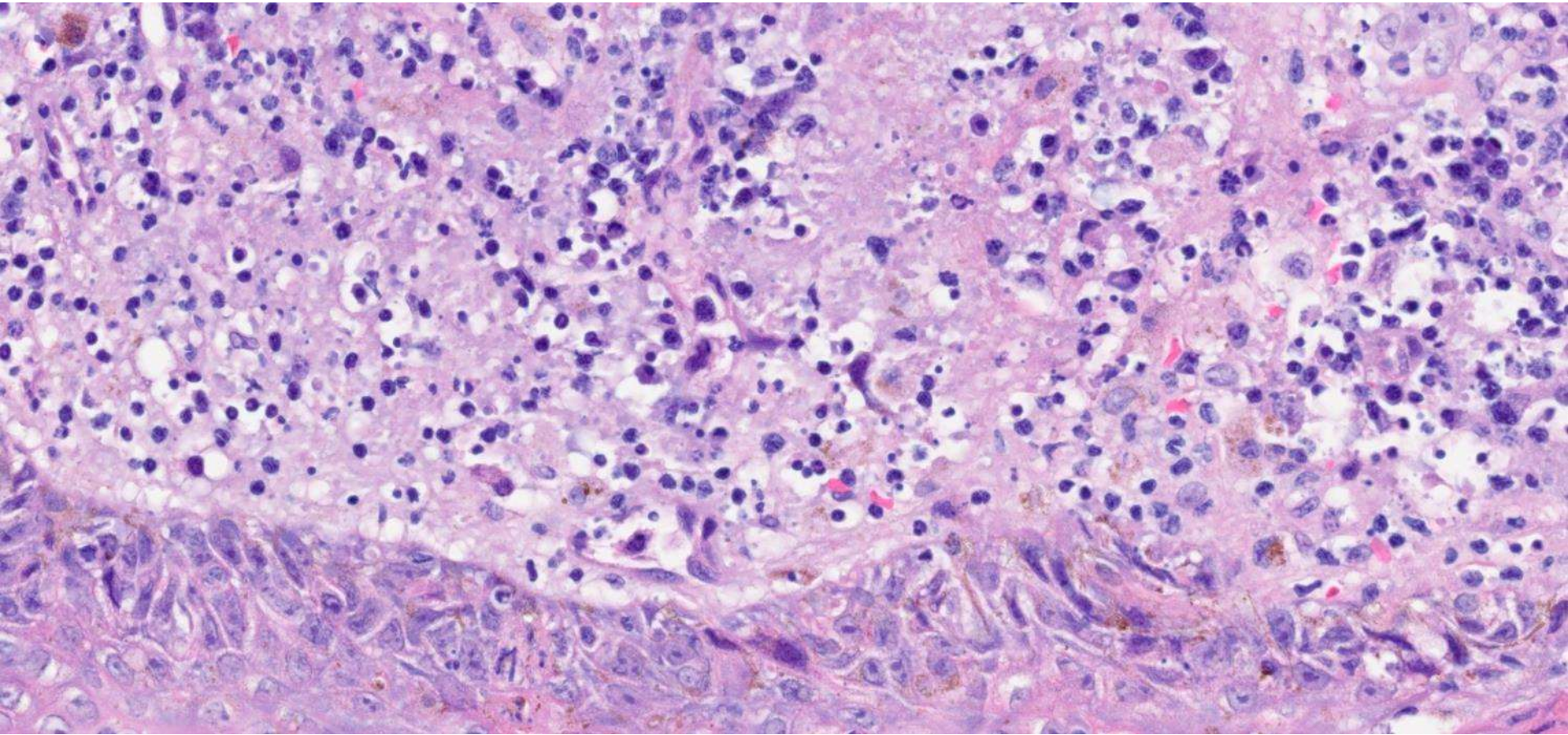












# DIAGNOSIS?





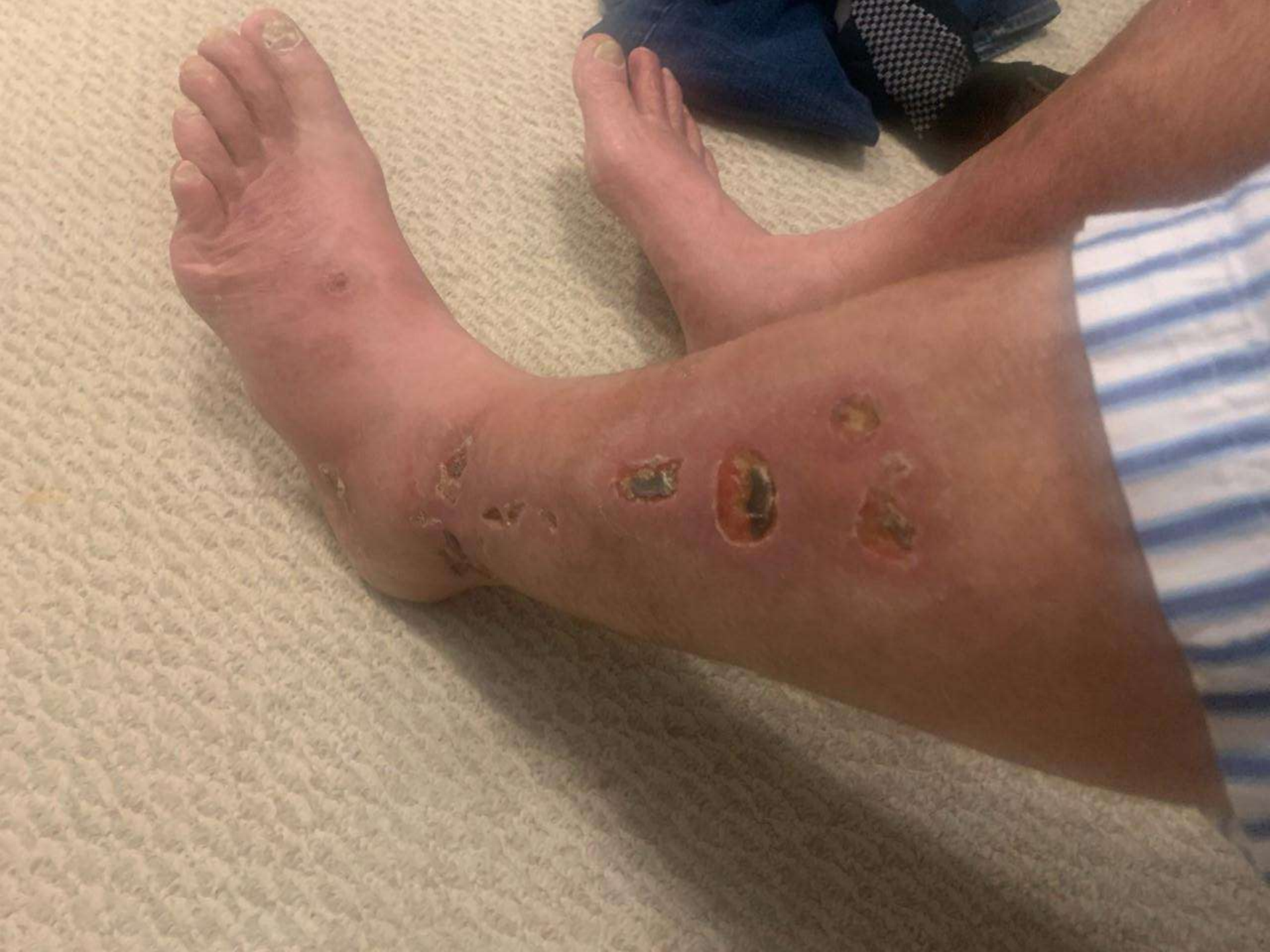22-0704

Direct link to scanned slide:

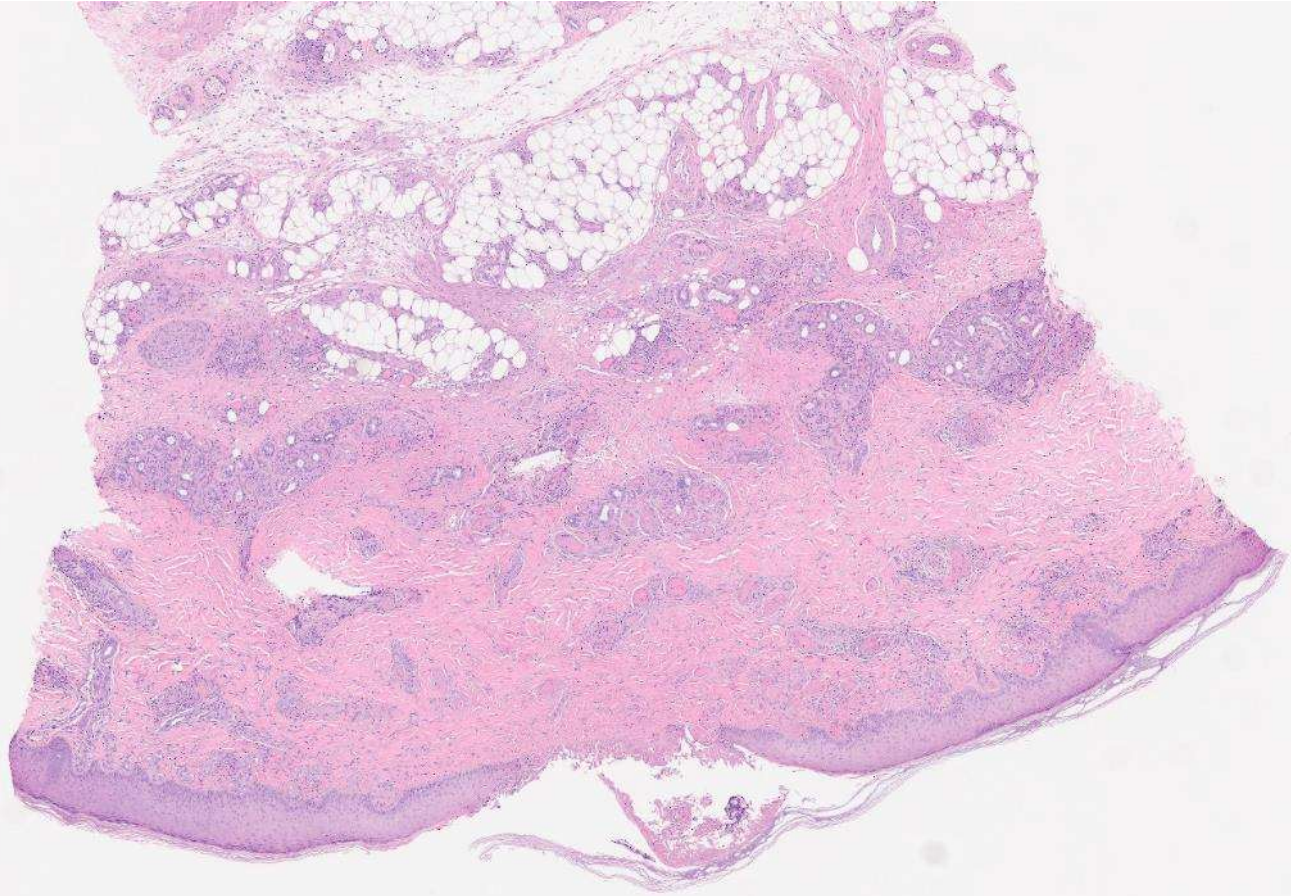
<https://pathpresenter.net/public/display?token=70b44996>

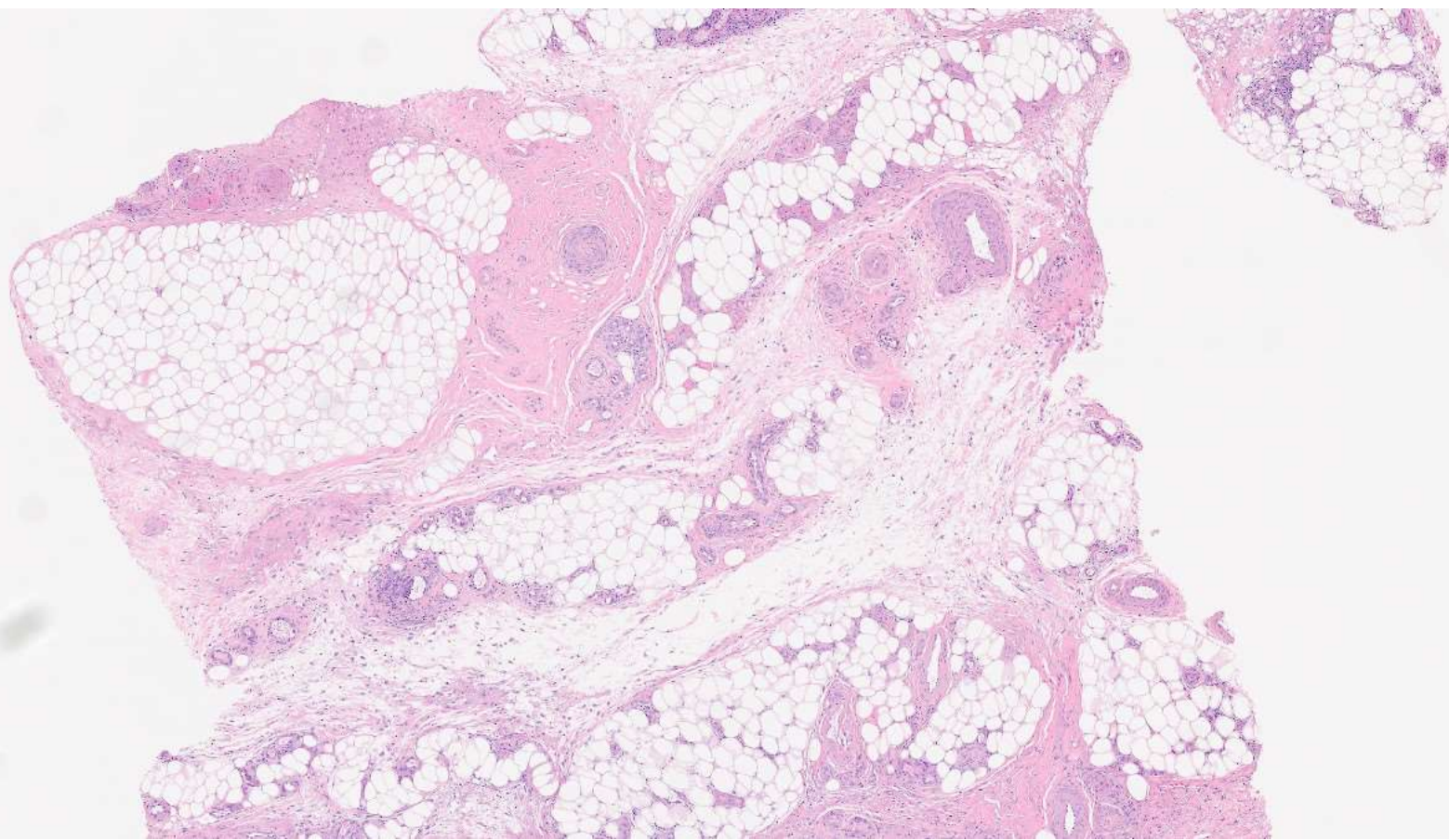
**Harris Goodman; Alameda Health System**

60ish M surgeon with bilateral non-healing lower leg  
wounds for over a year.

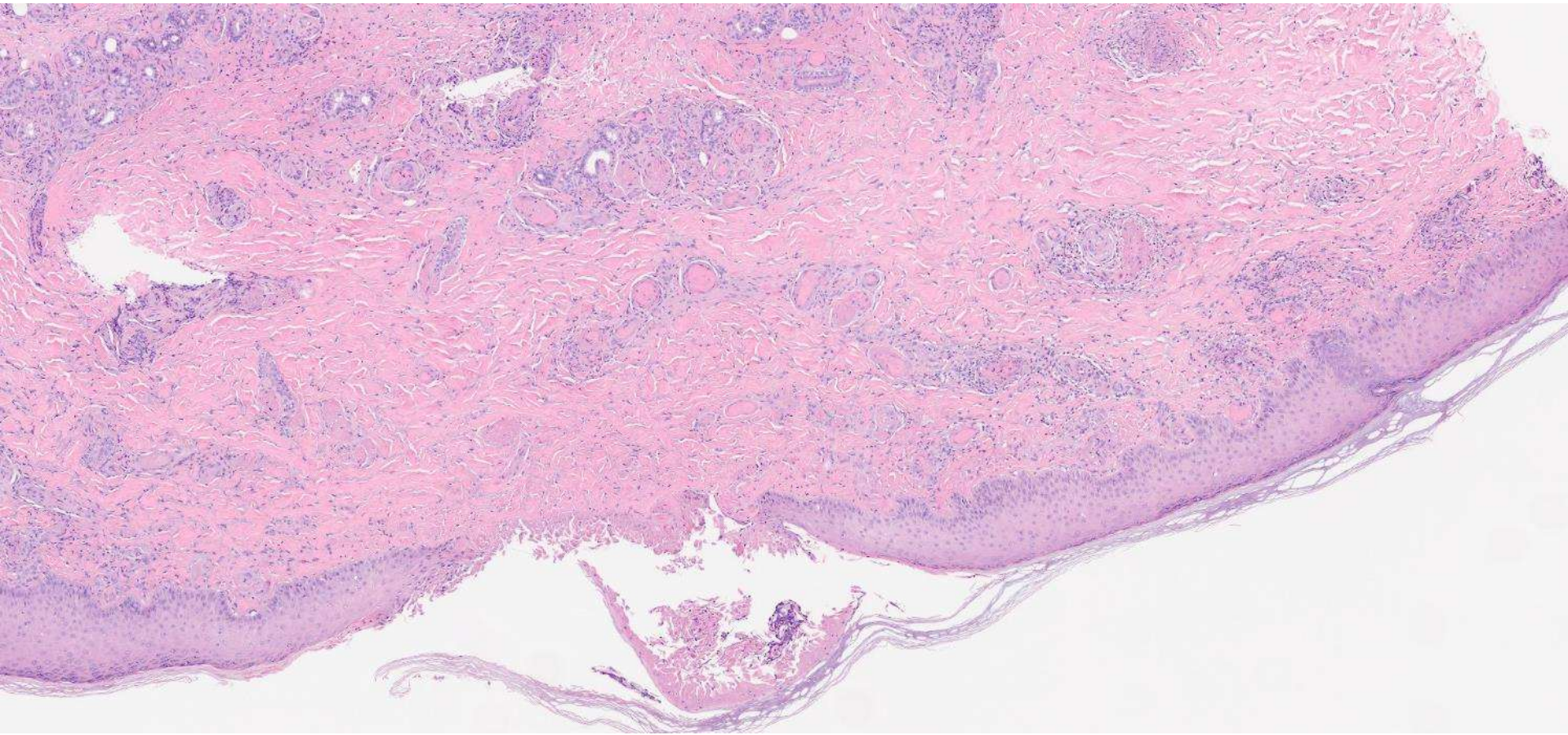




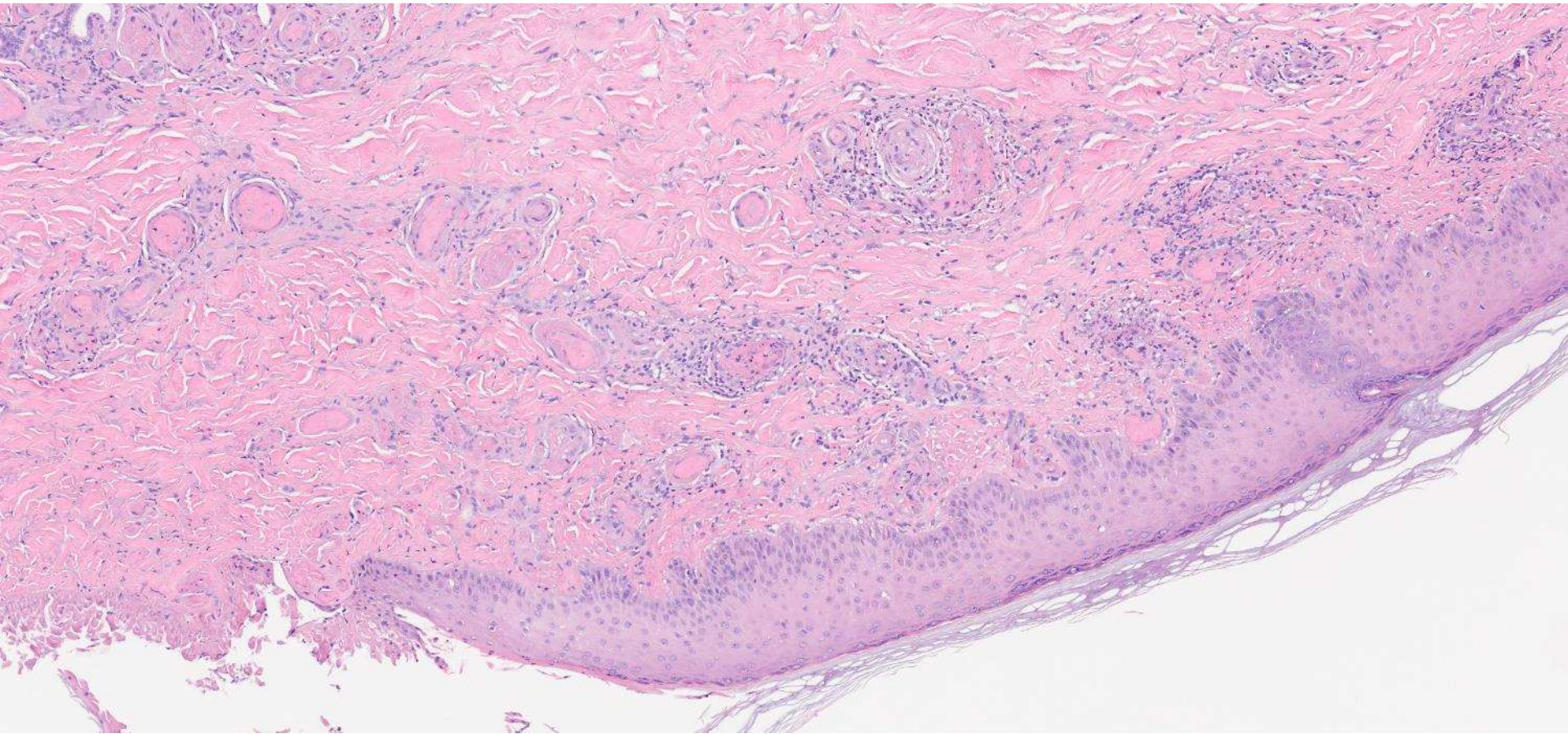




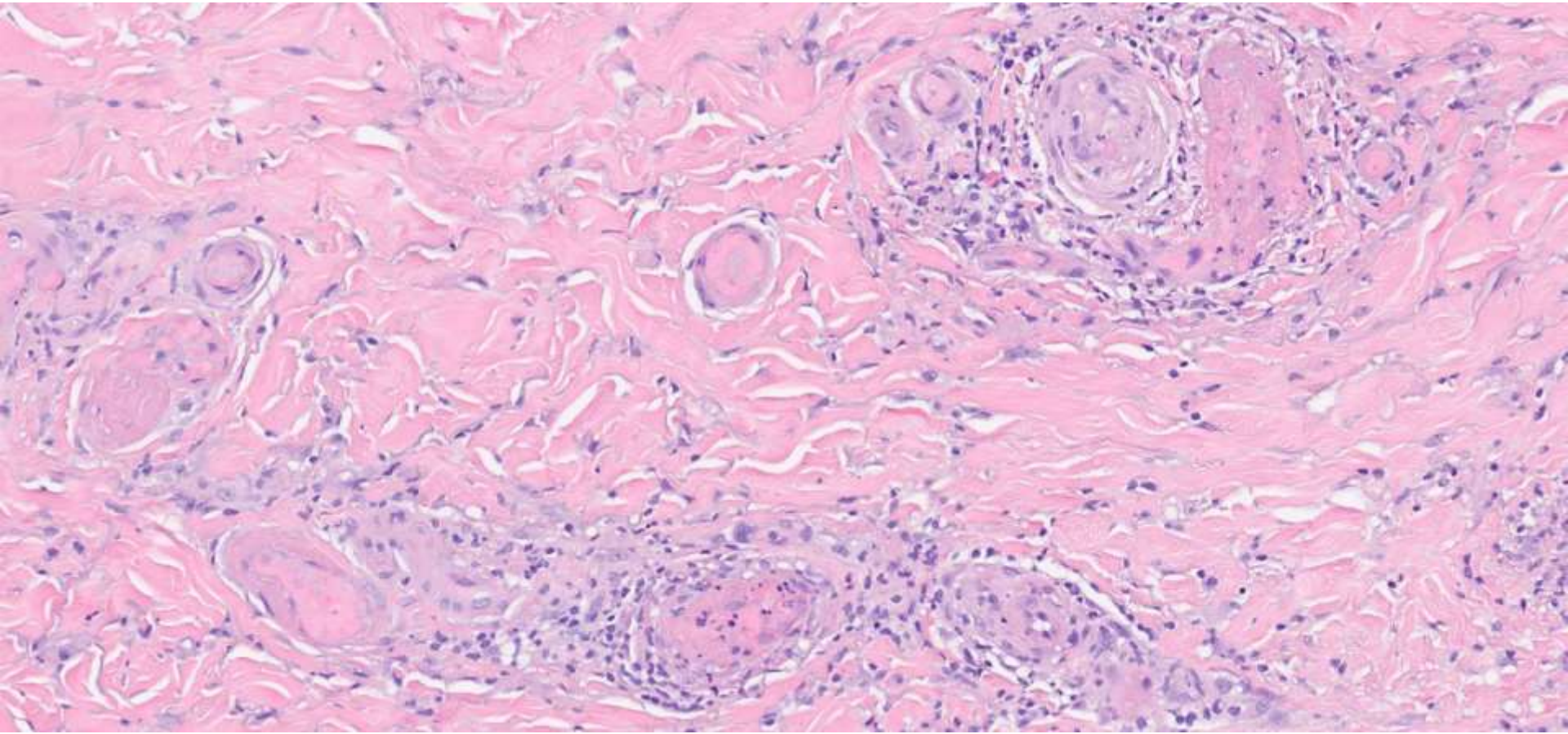




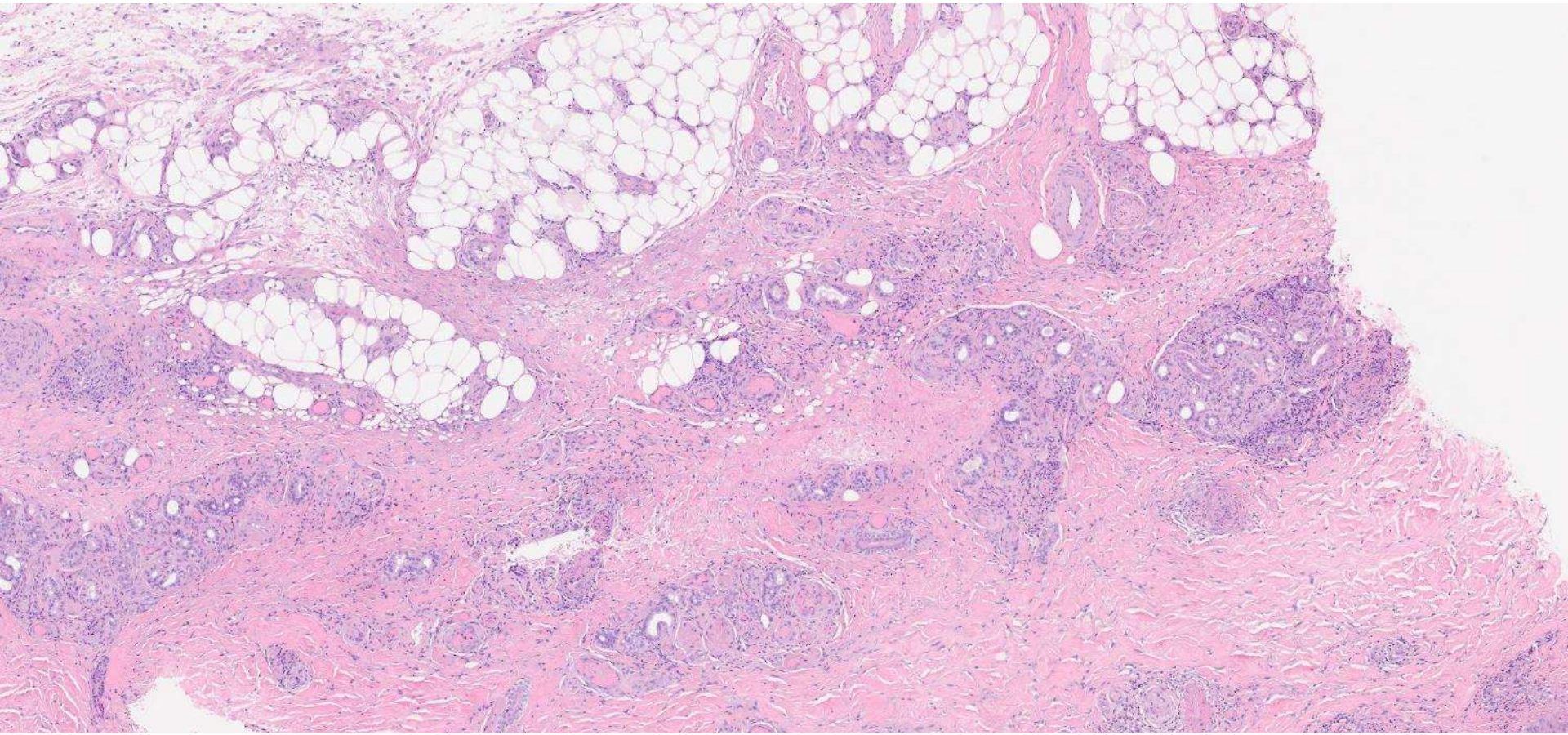




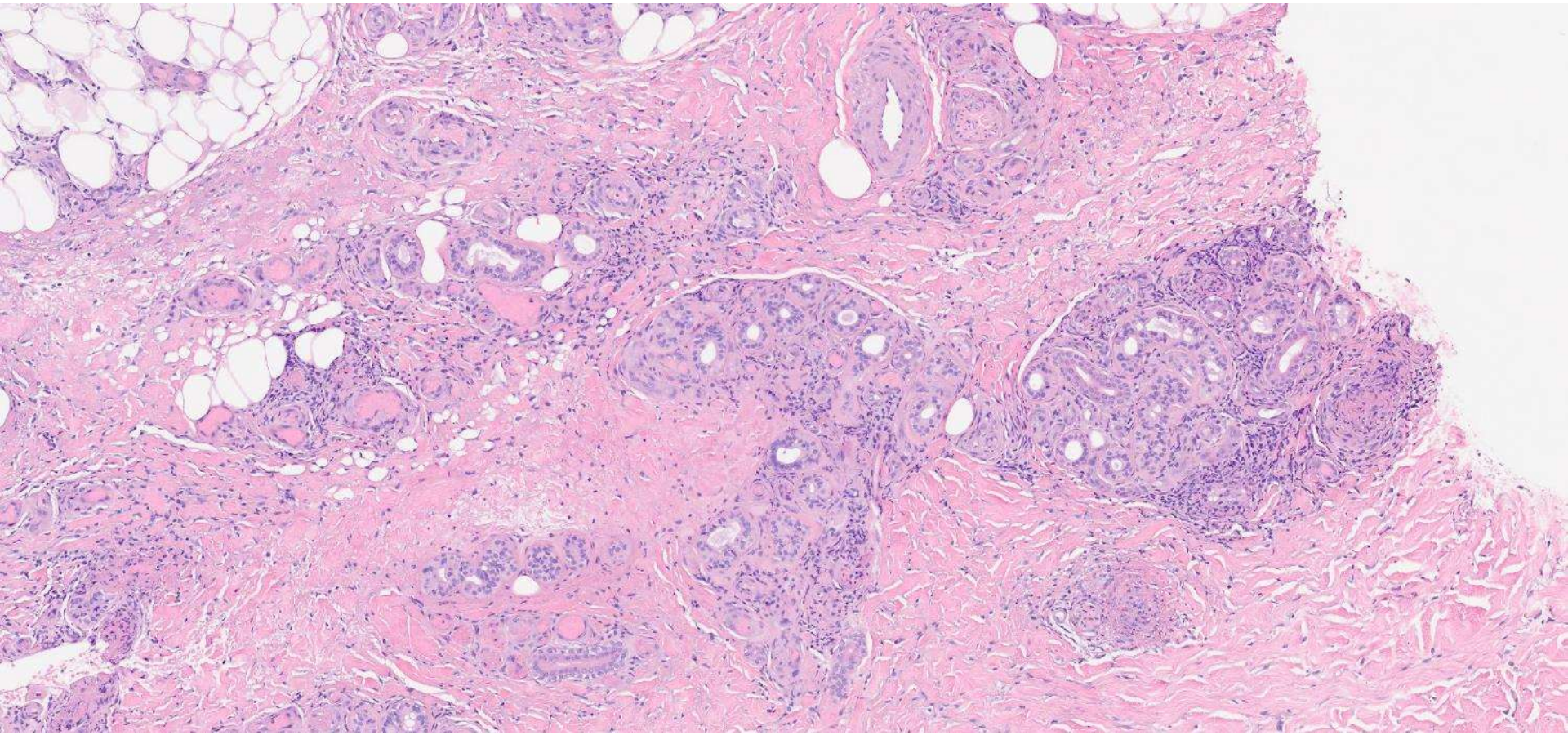




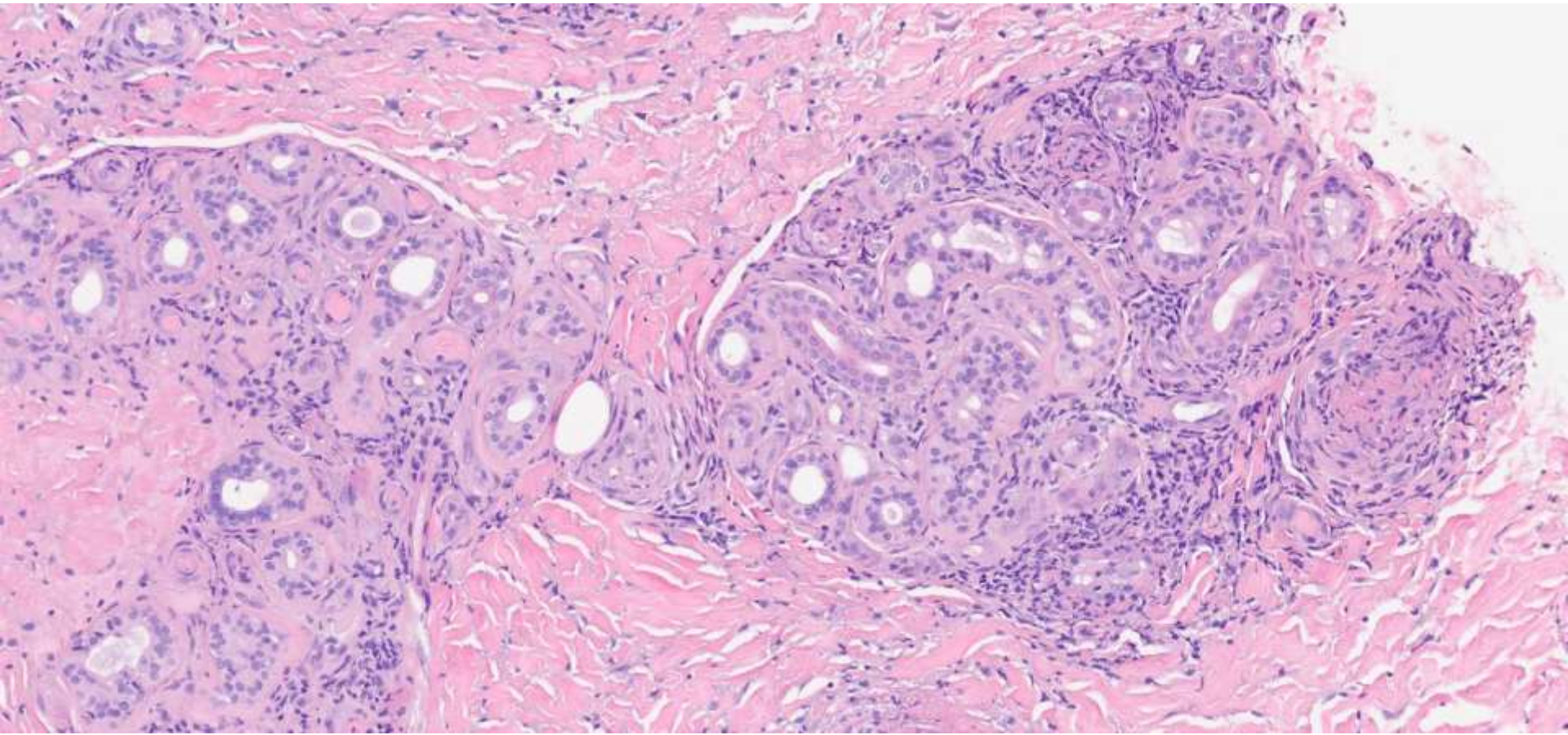




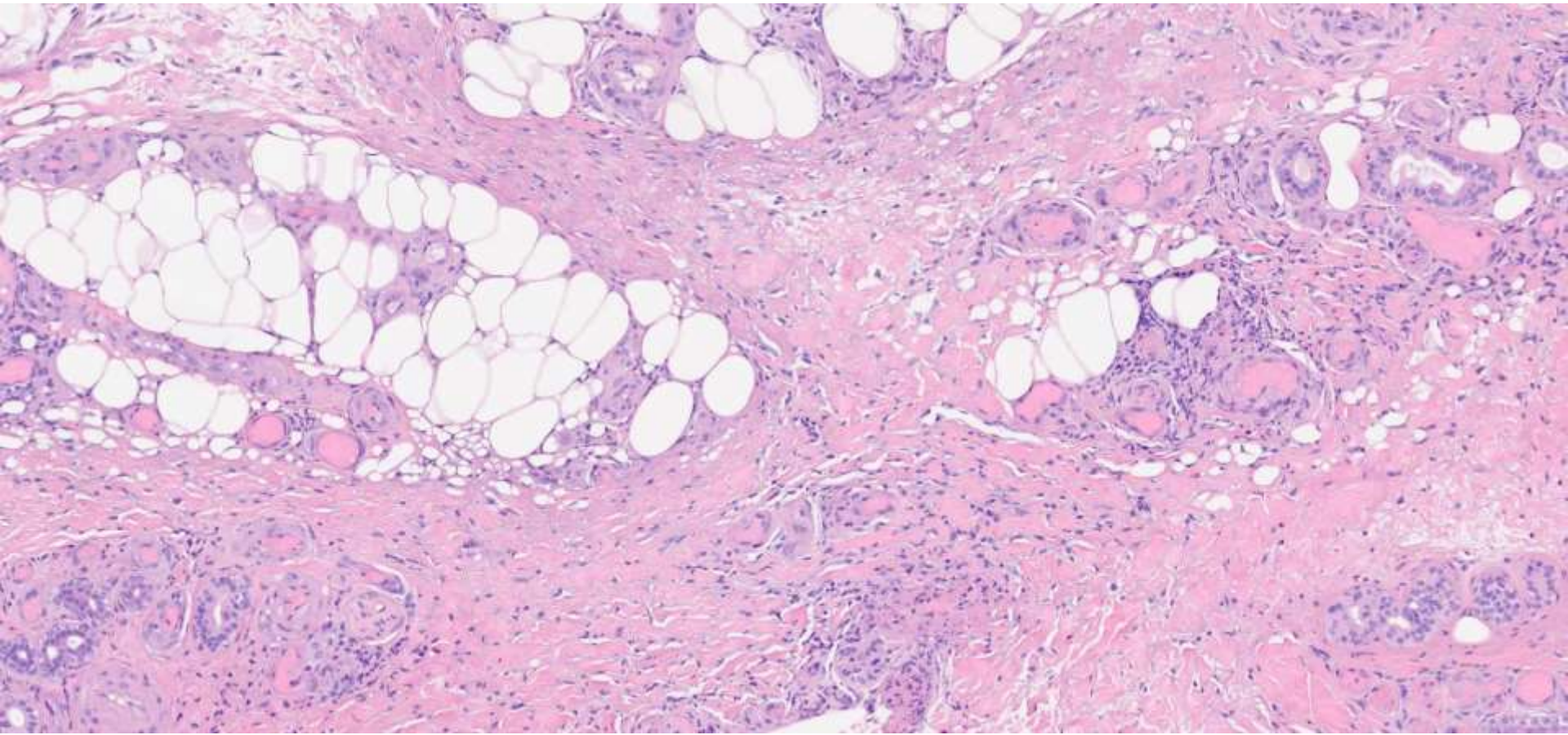












# DIAGNOSIS?

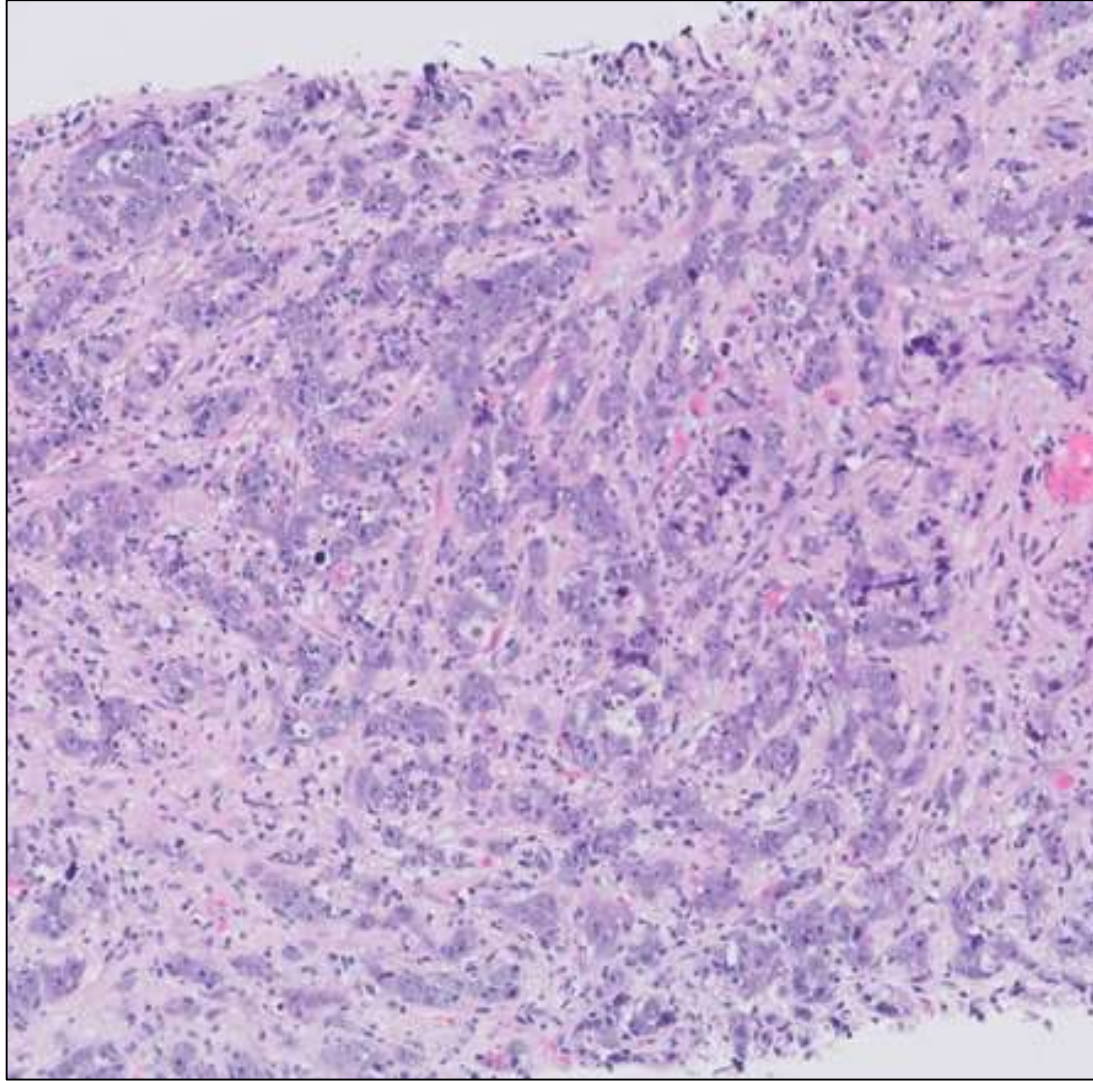




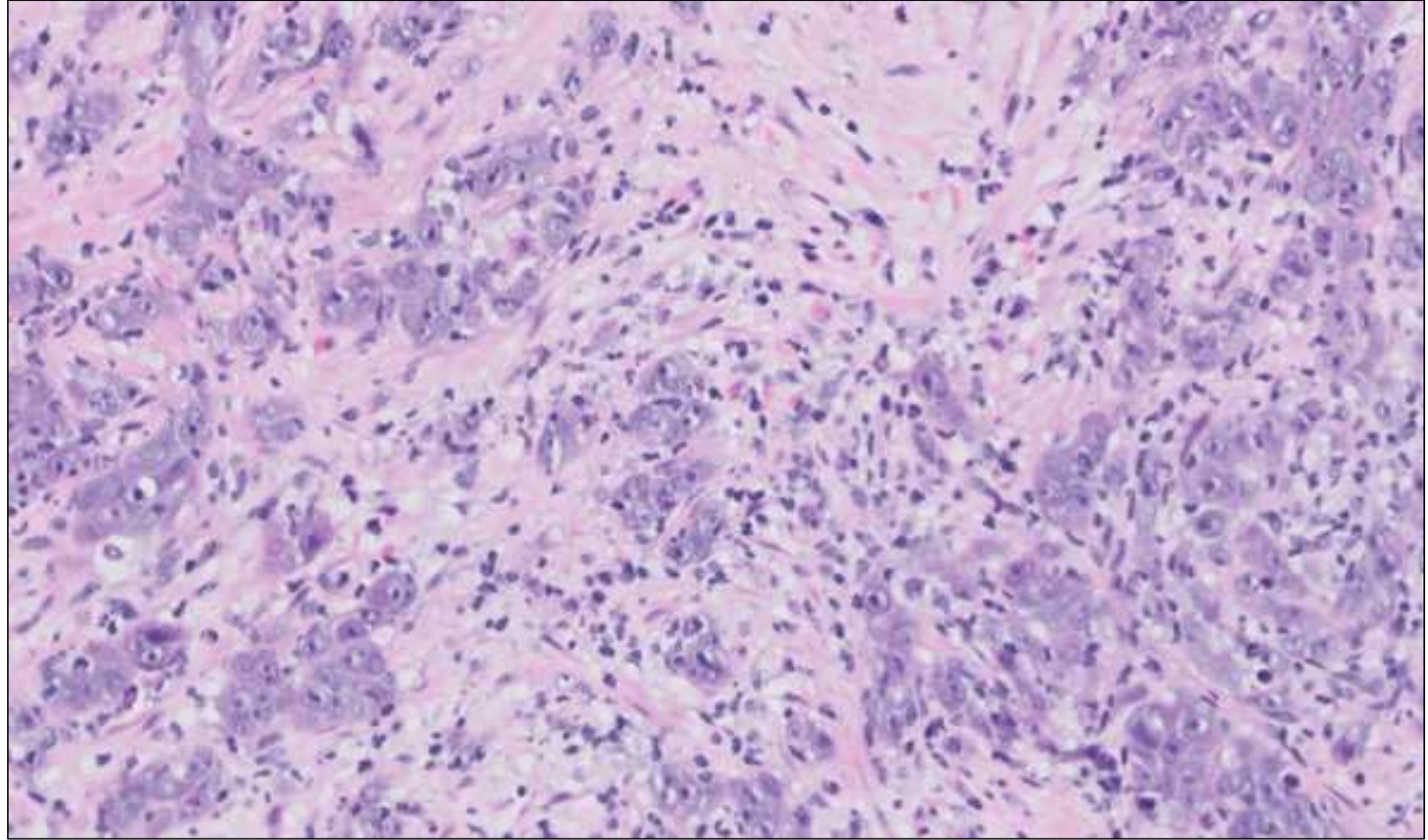
# 22-0705

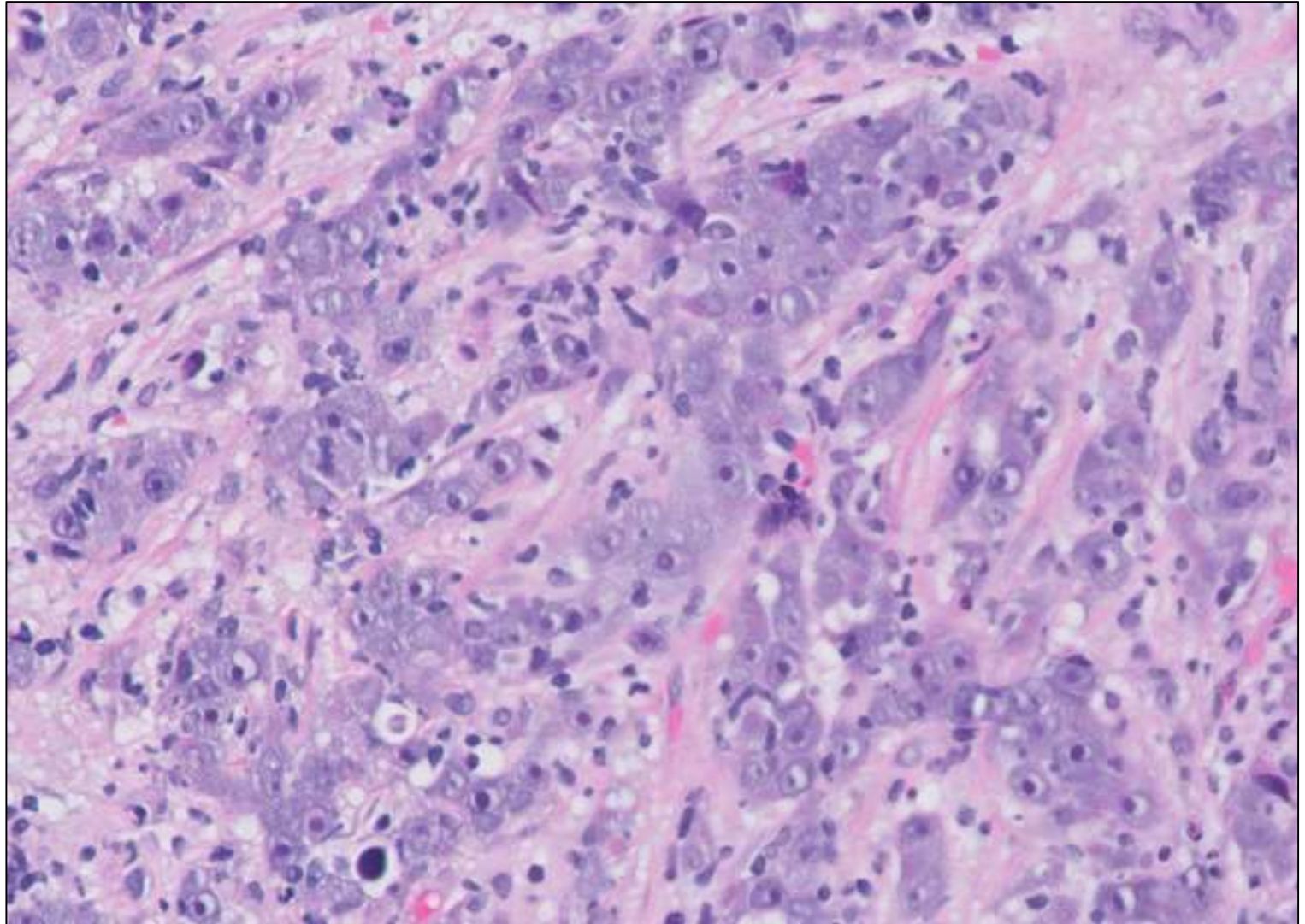
## **Alexander Kikuchi/Sanjay Kakar; UCSF**

50ish M with h/o HCV cirrhosis status post treatment and SVR, now with two malignant appearing masses (up to 4.1 cm) on MRI, as well as CT angiography showing an occluded superior mesenteric vein, splenic vein and portal circulation by thrombus, as well as an irregularly shaped 3.5 cm hypoattenuated lesion in hepatic segment 4A suspicious for an abscess. AFP, CA19-9, and CEA were in normal range.

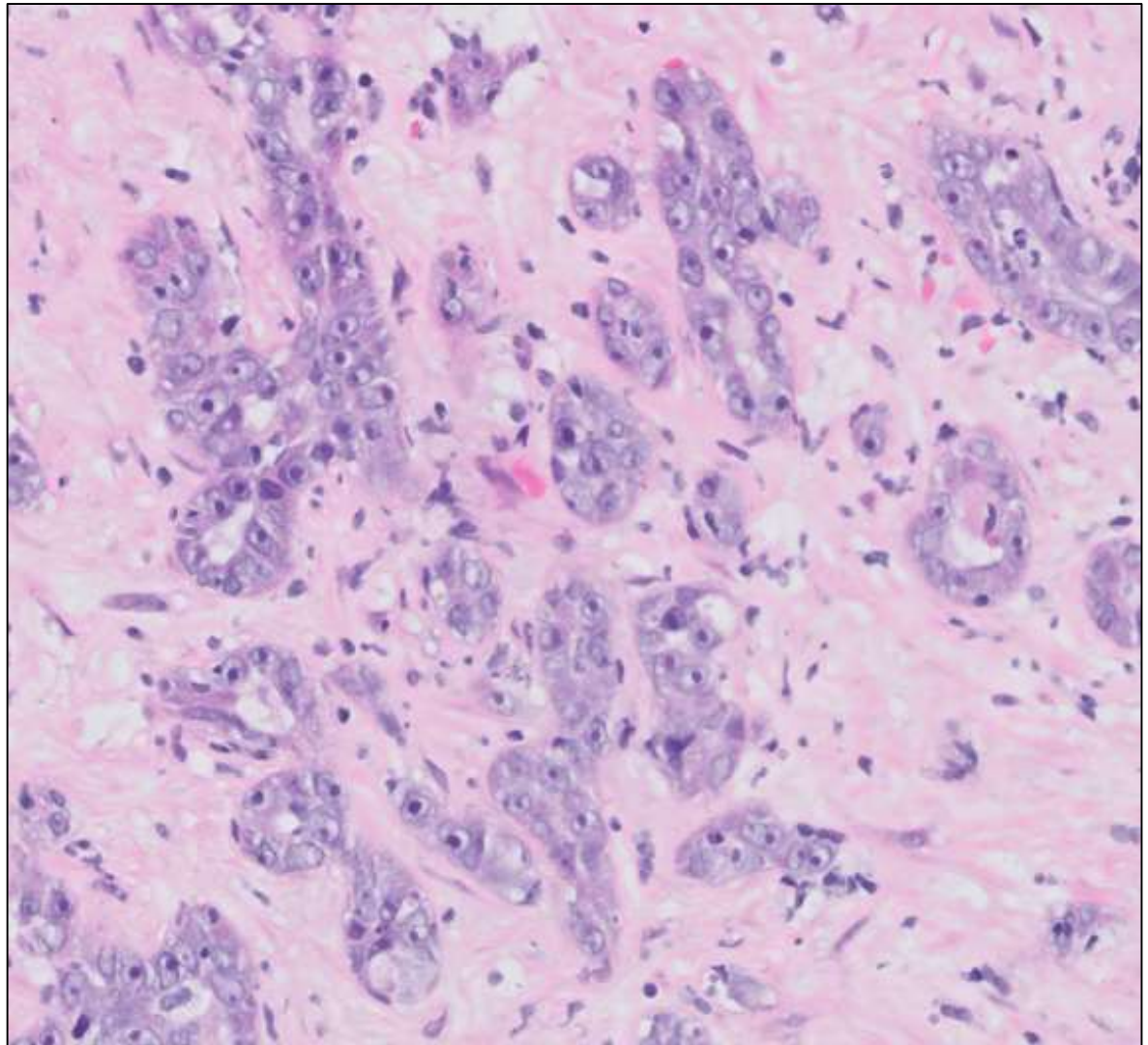
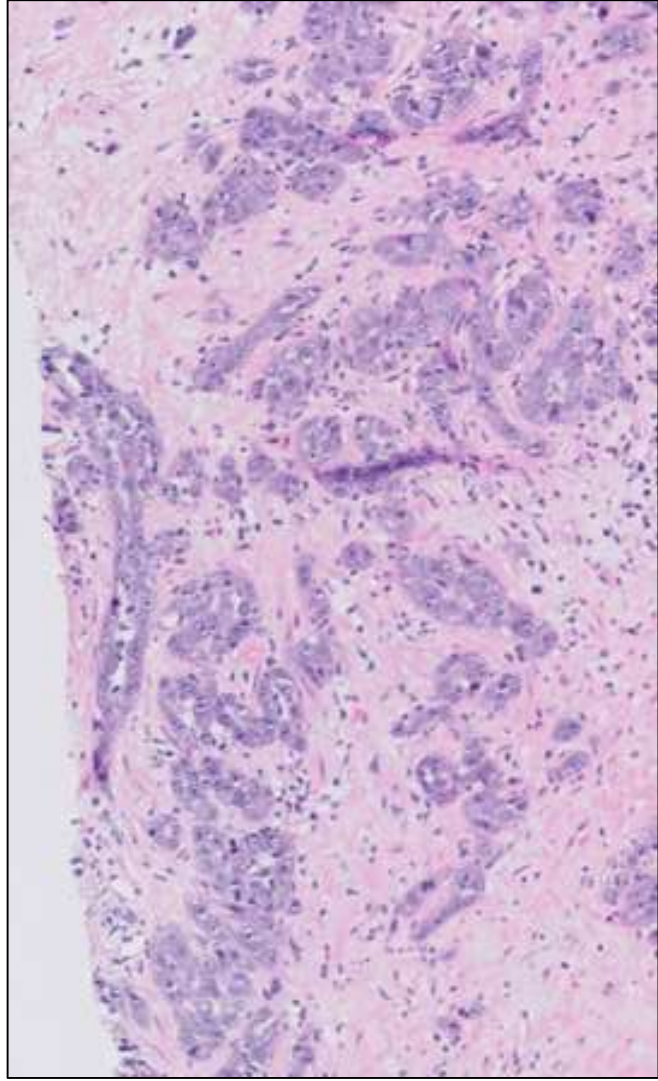




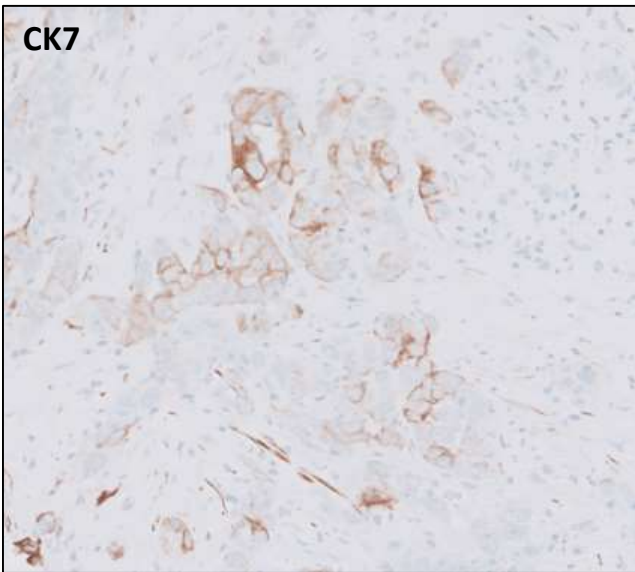




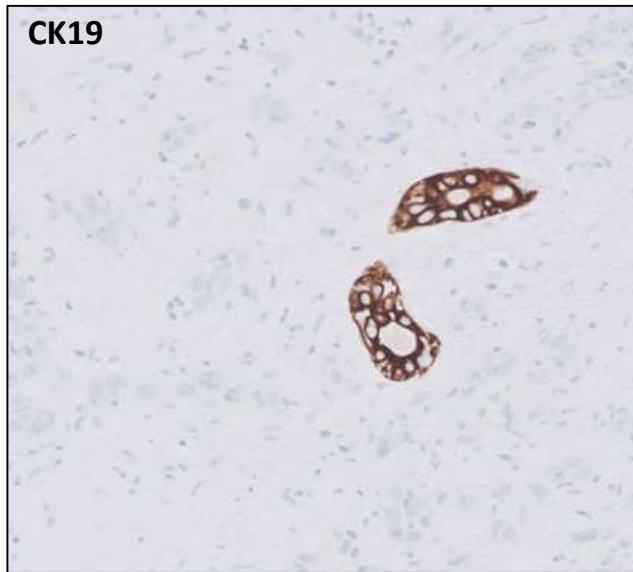



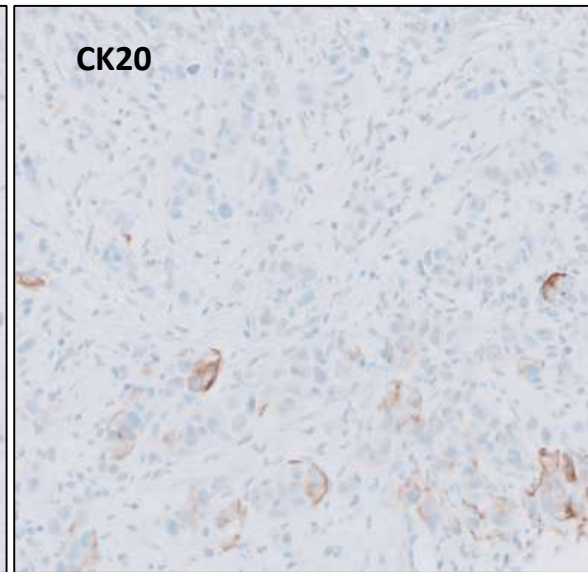
**CK7**



**CK19**

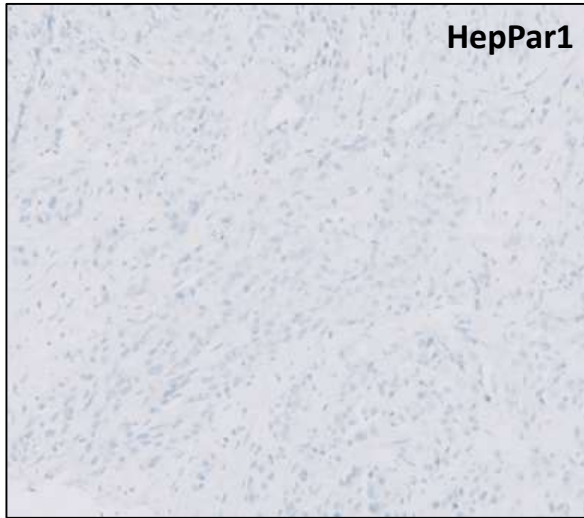


**CK20**

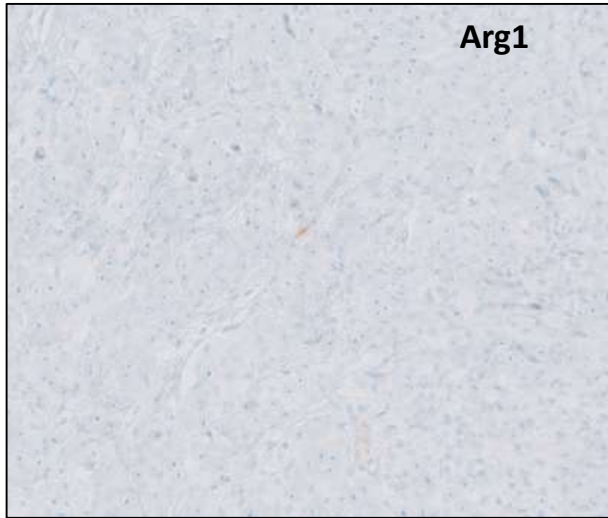




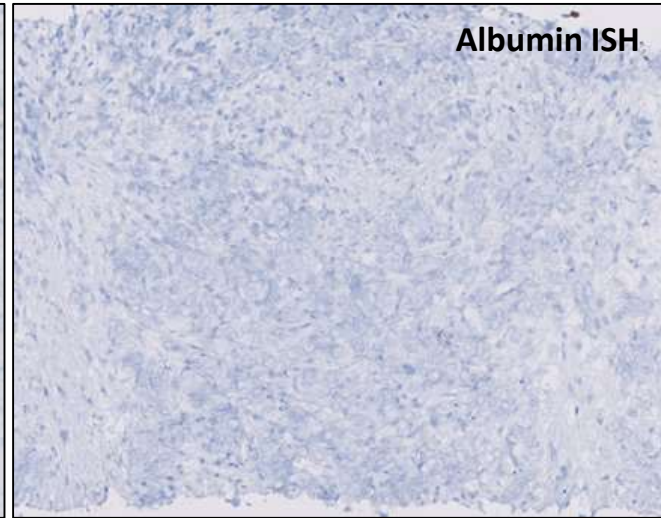
**HepPar1**



**Arg1**



**Albumin ISH**



## **Additional negative stains**

- CK19, CK 5/6, MOC31
- NKX3.1, PAX8, TTF1, synaptophysin, CDX2
- Calretinin, WT1



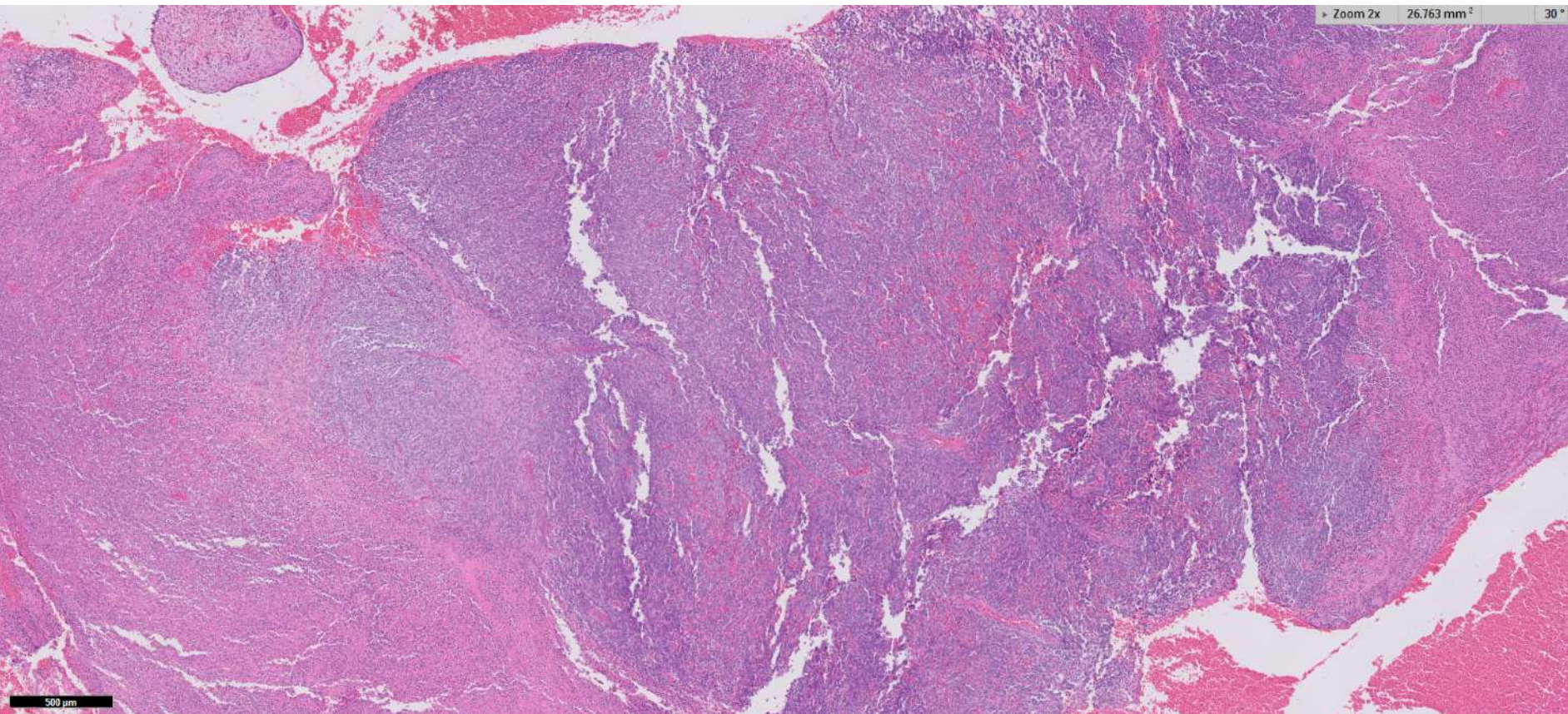
# DIAGNOSIS?



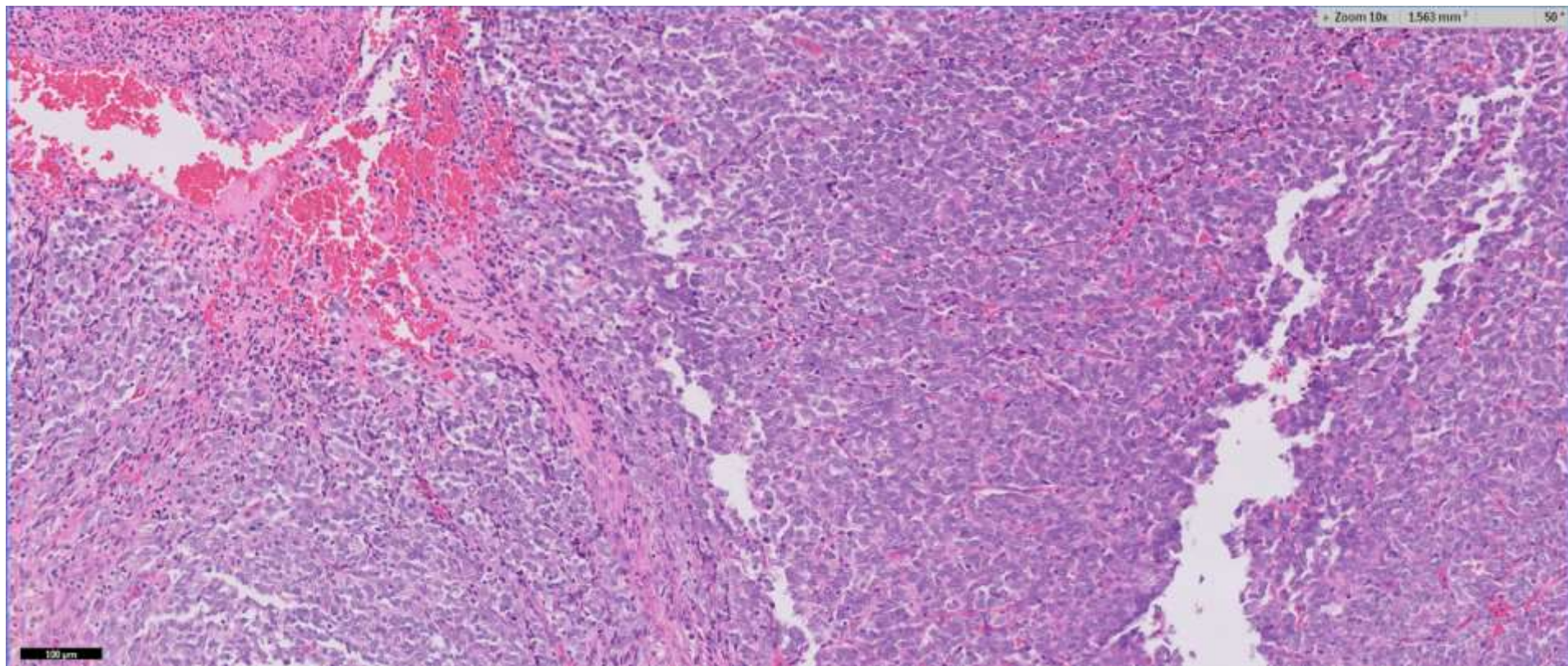
22-0706

**Diane Libert/Brooke Howitt; Stanford**  
60ish F with necrotic endometrial mass.

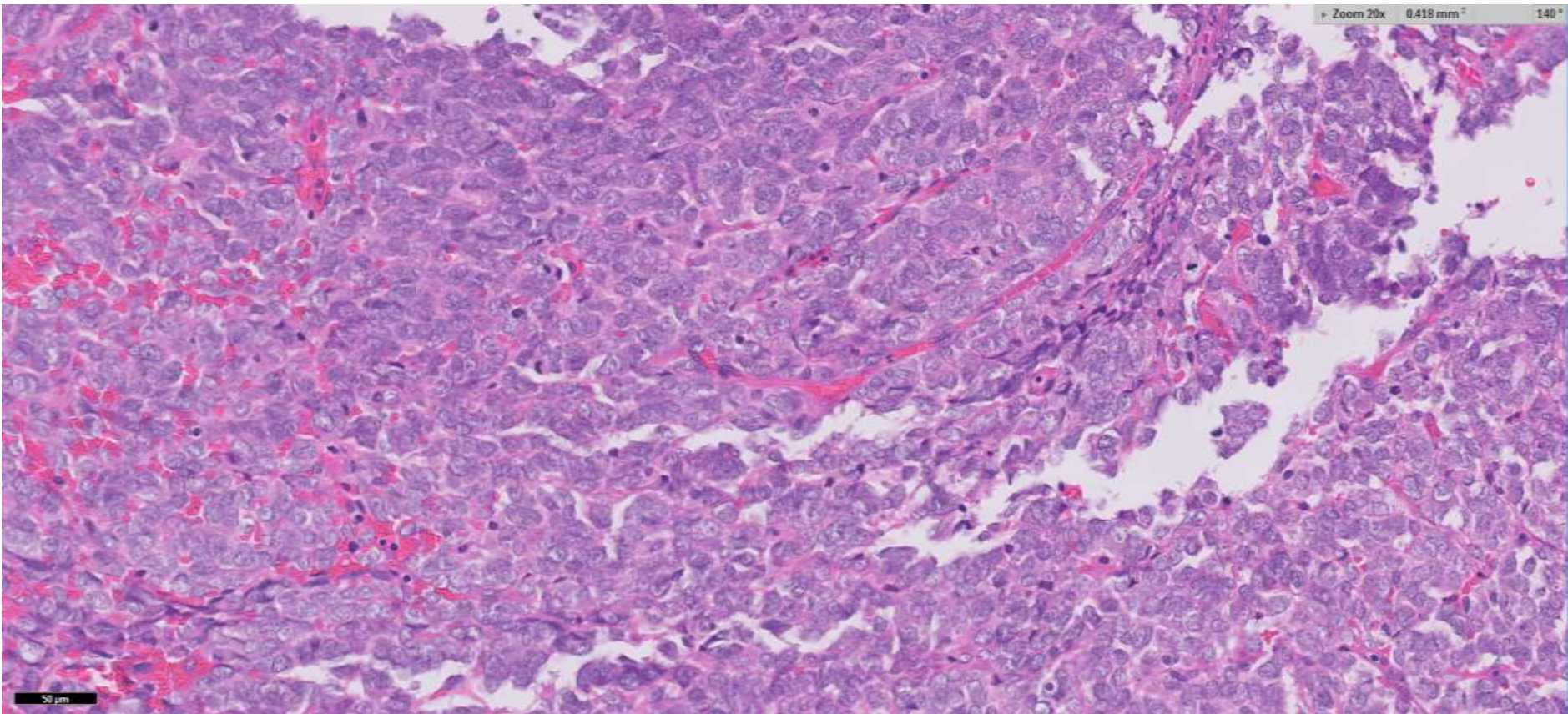




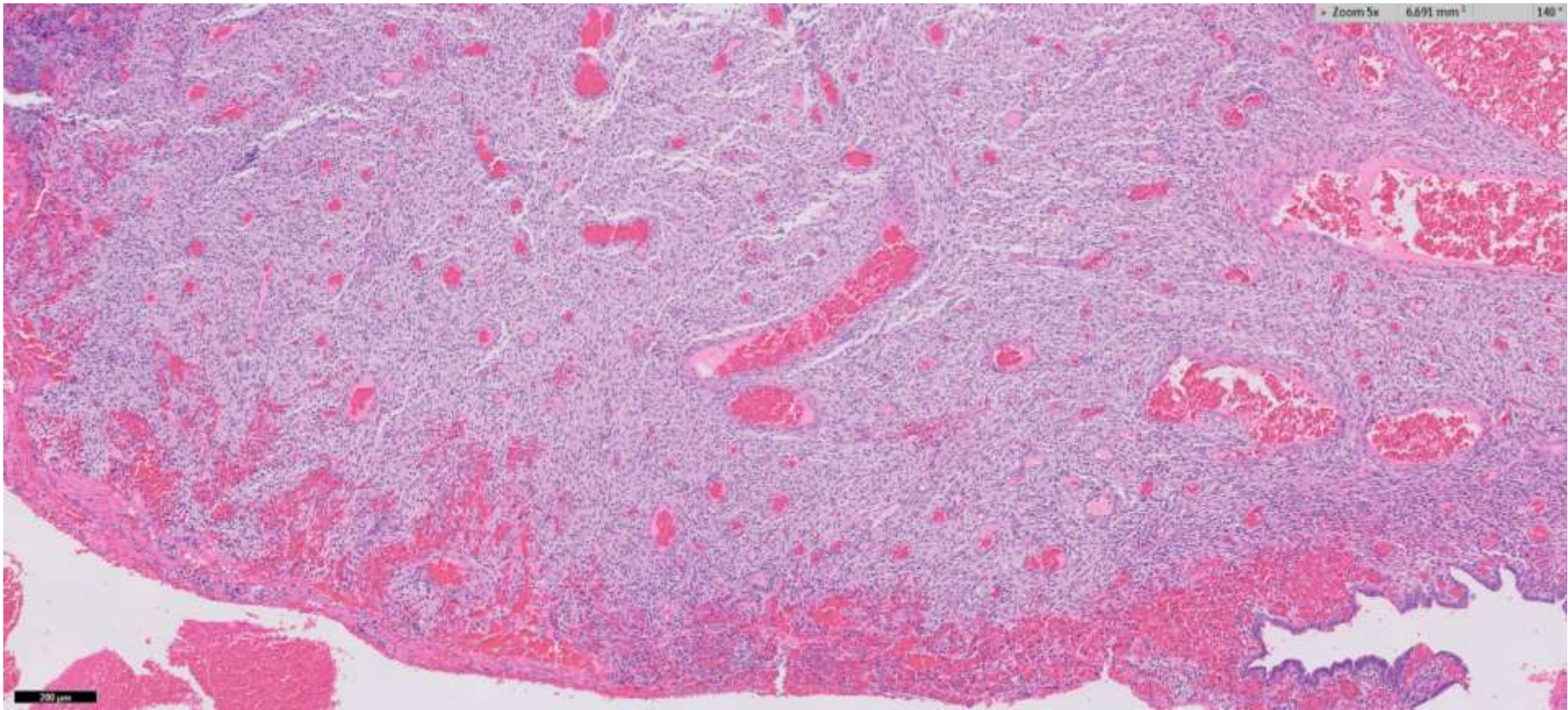




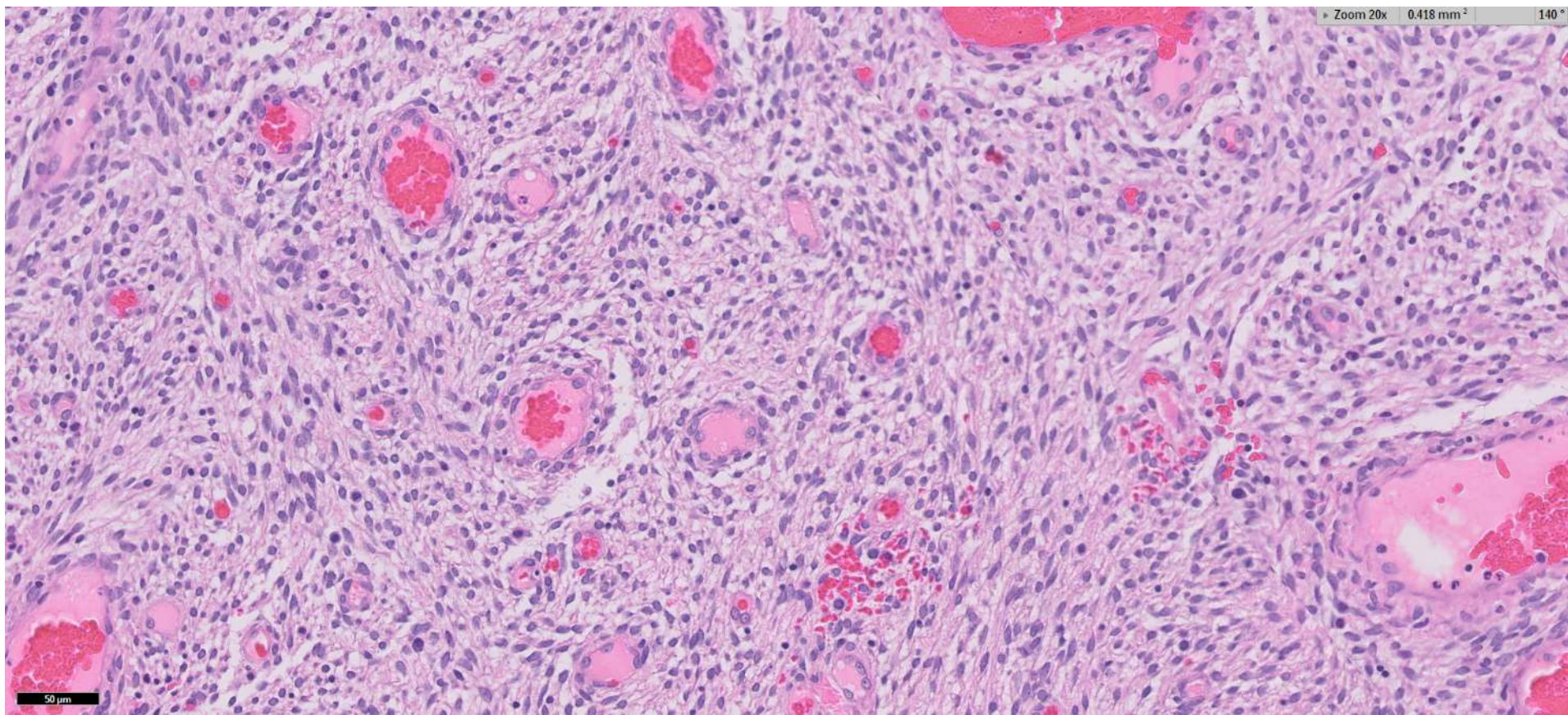












# DIAGNOSIS?





# 22-0707

**Linlin Wang; UCSF**

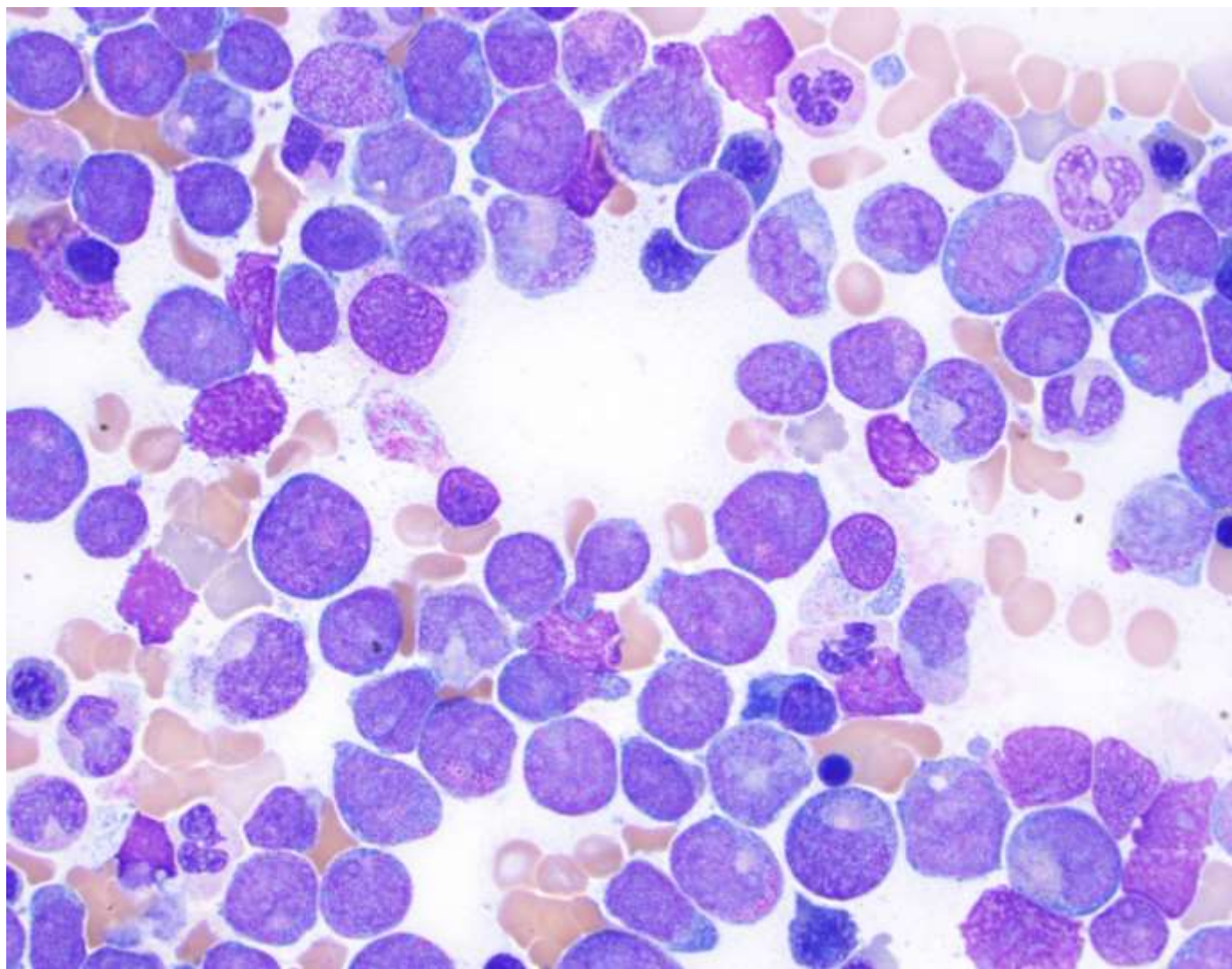
40ish F presents with fatigue, easy bruising, gum bleeding, and increased blasts on peripheral blood smear. She underwent bone marrow biopsy for new leukemic workup.

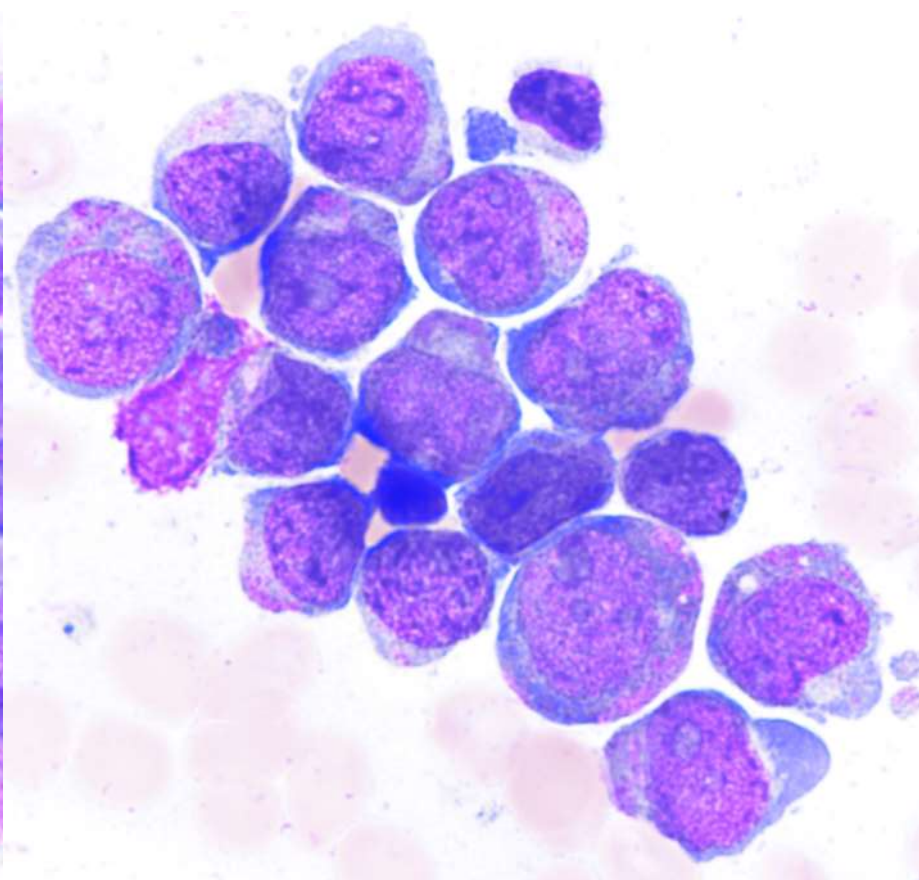
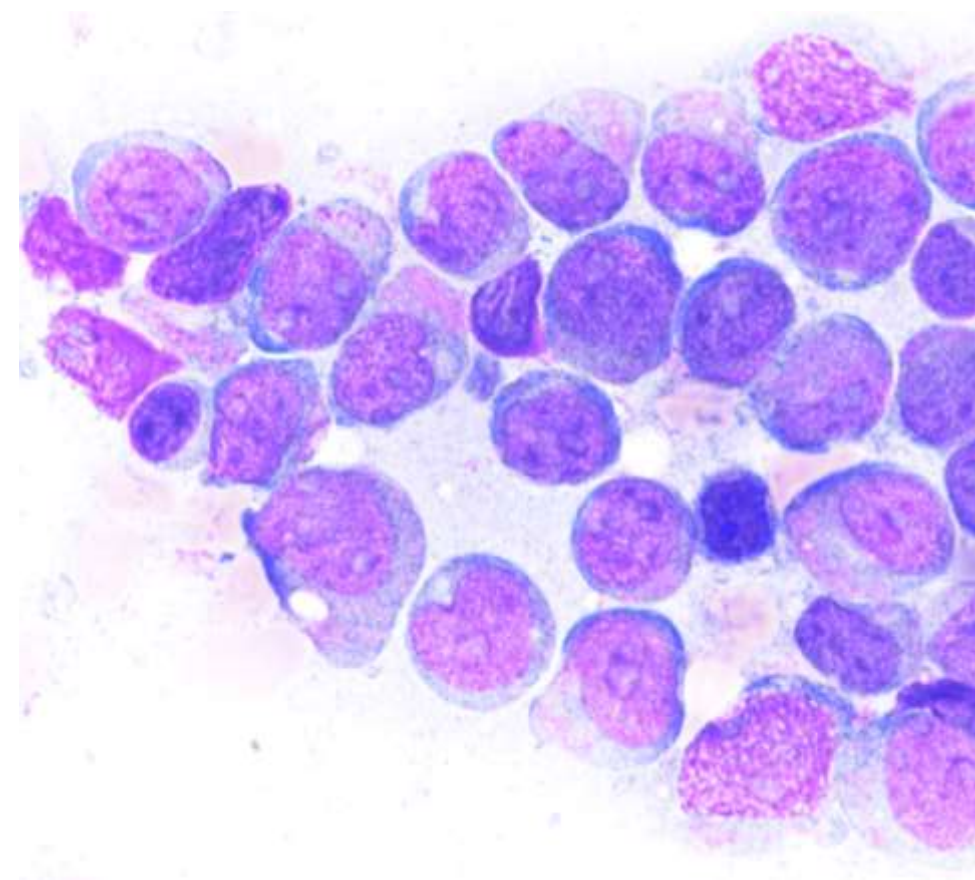
40ish woman presented with fatigue, easy bruising, gum bleeding and increased blasts on peripheral blood smear. She underwent bone marrow biopsy for new leukemic workup.

CBC: WBC  $8.6 \times 10^9/L$ , Hb 8.5 g/dL, Platelets  $32 \times 10^9/L$

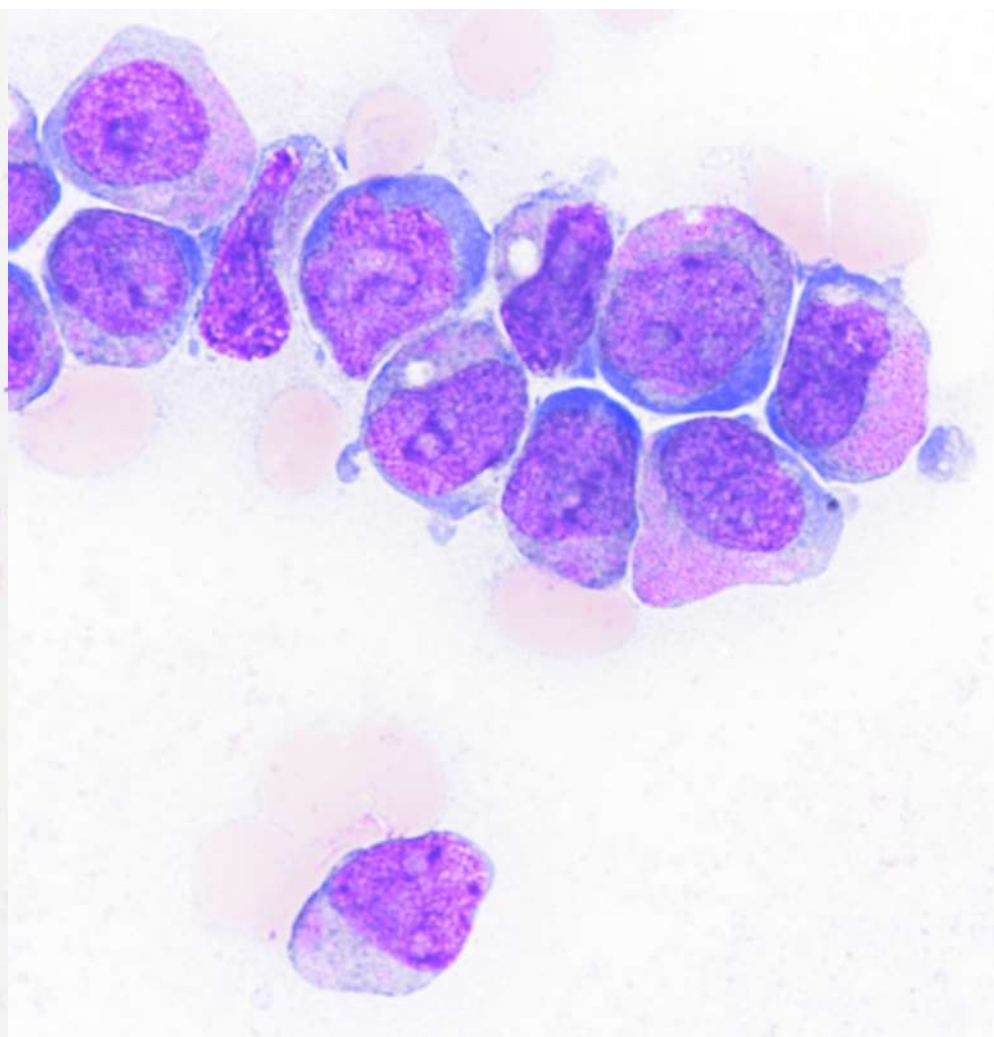
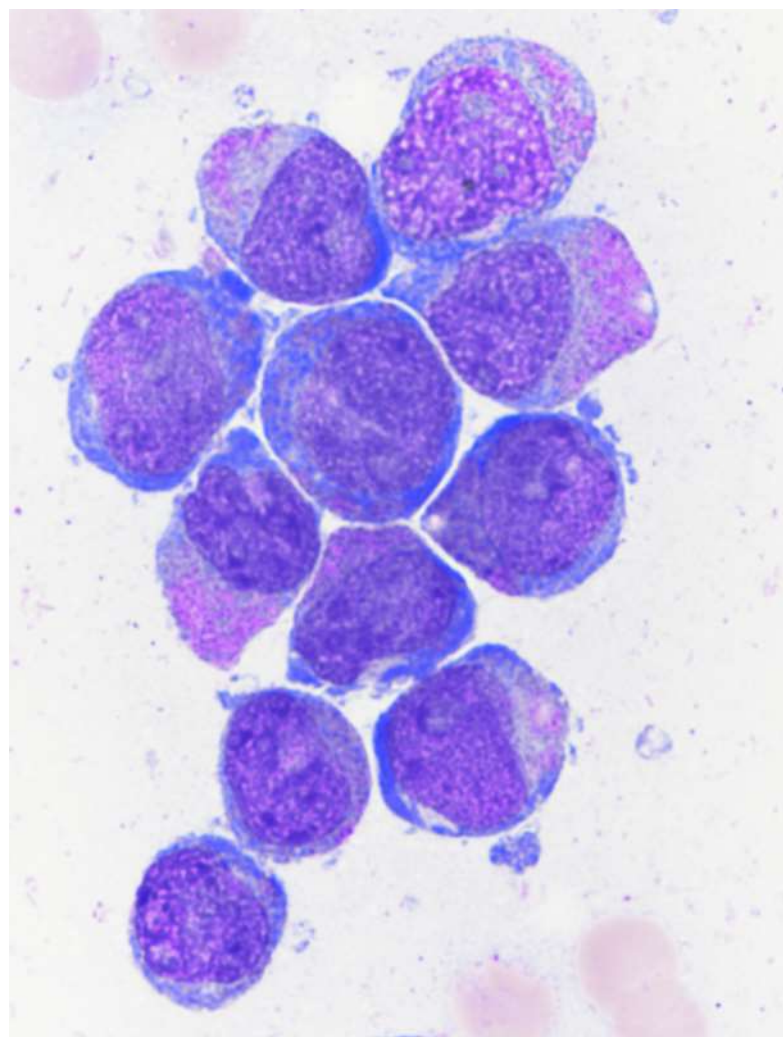
Linlin Wang, UCSF

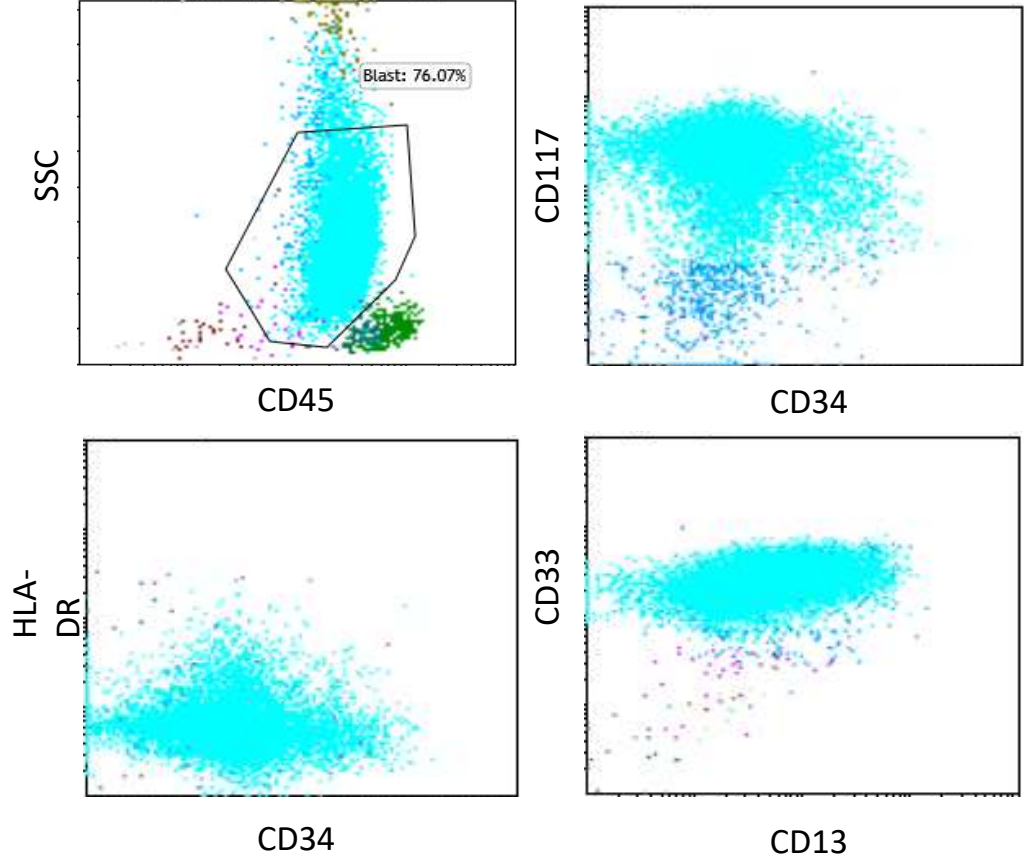














# DIAGNOSIS?



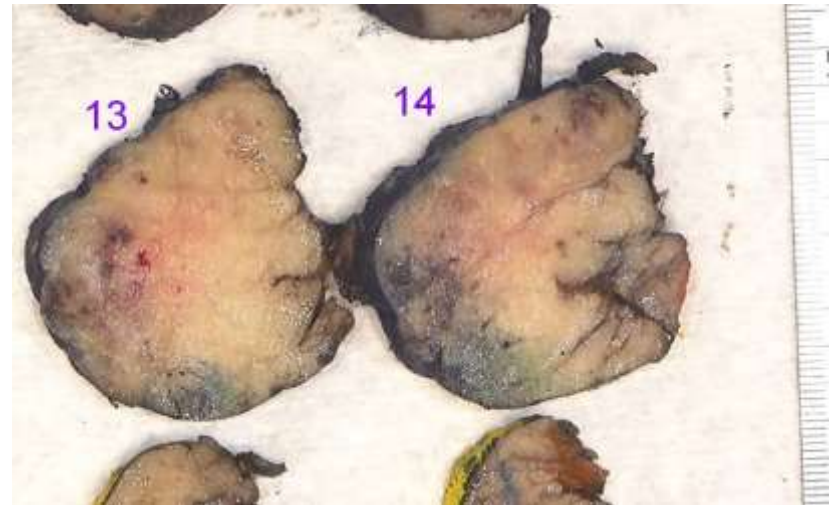
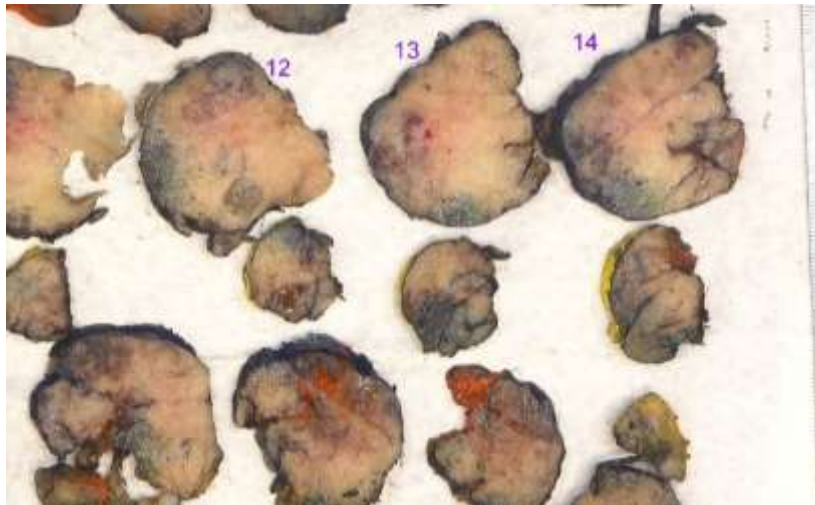
22-0708

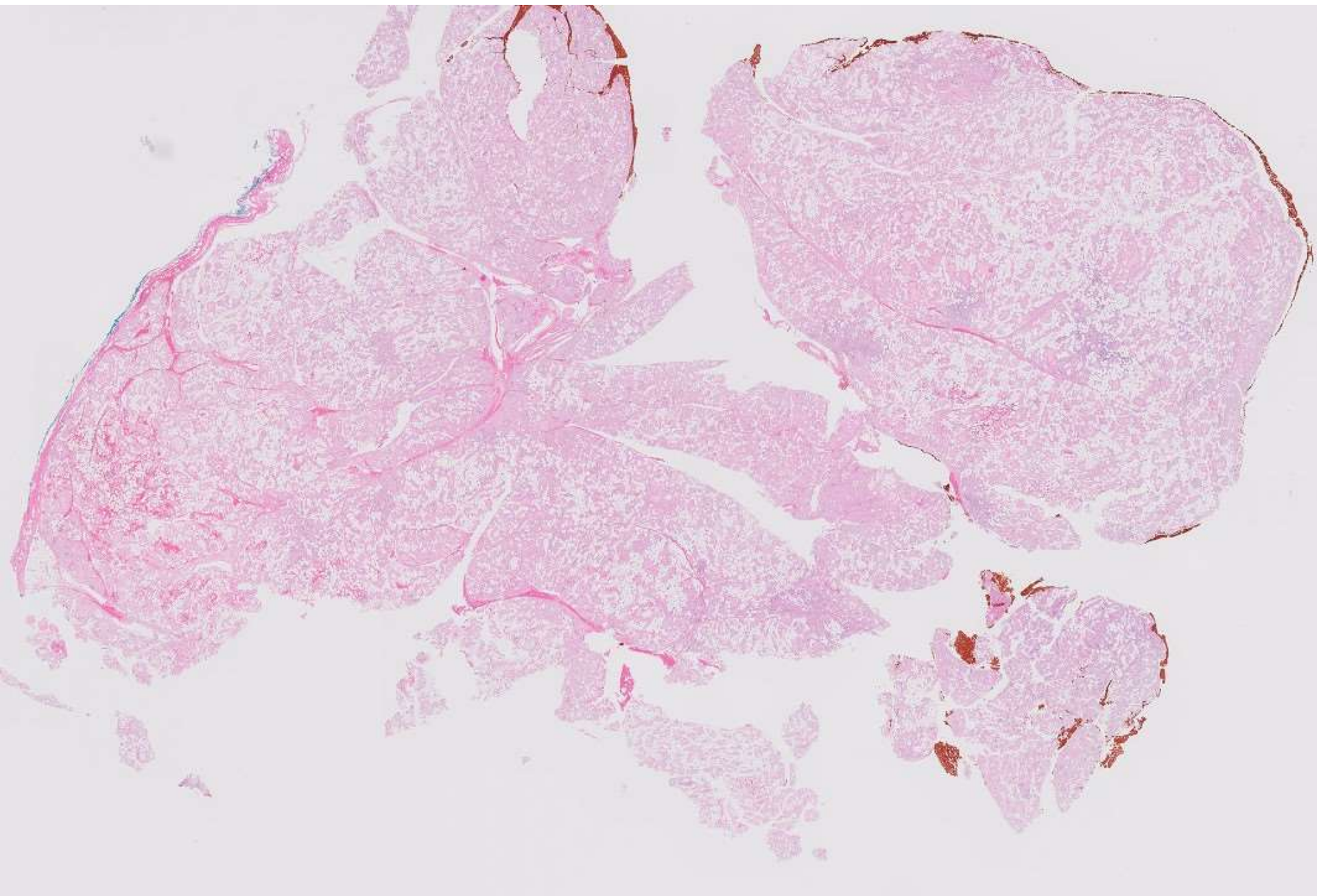
**Xiaoming Zhang/Olumide Odeyemi/Megan Troxell;  
Stanford**

50ish F with 15cm anterior neck mass. History of end-stage renal disease.

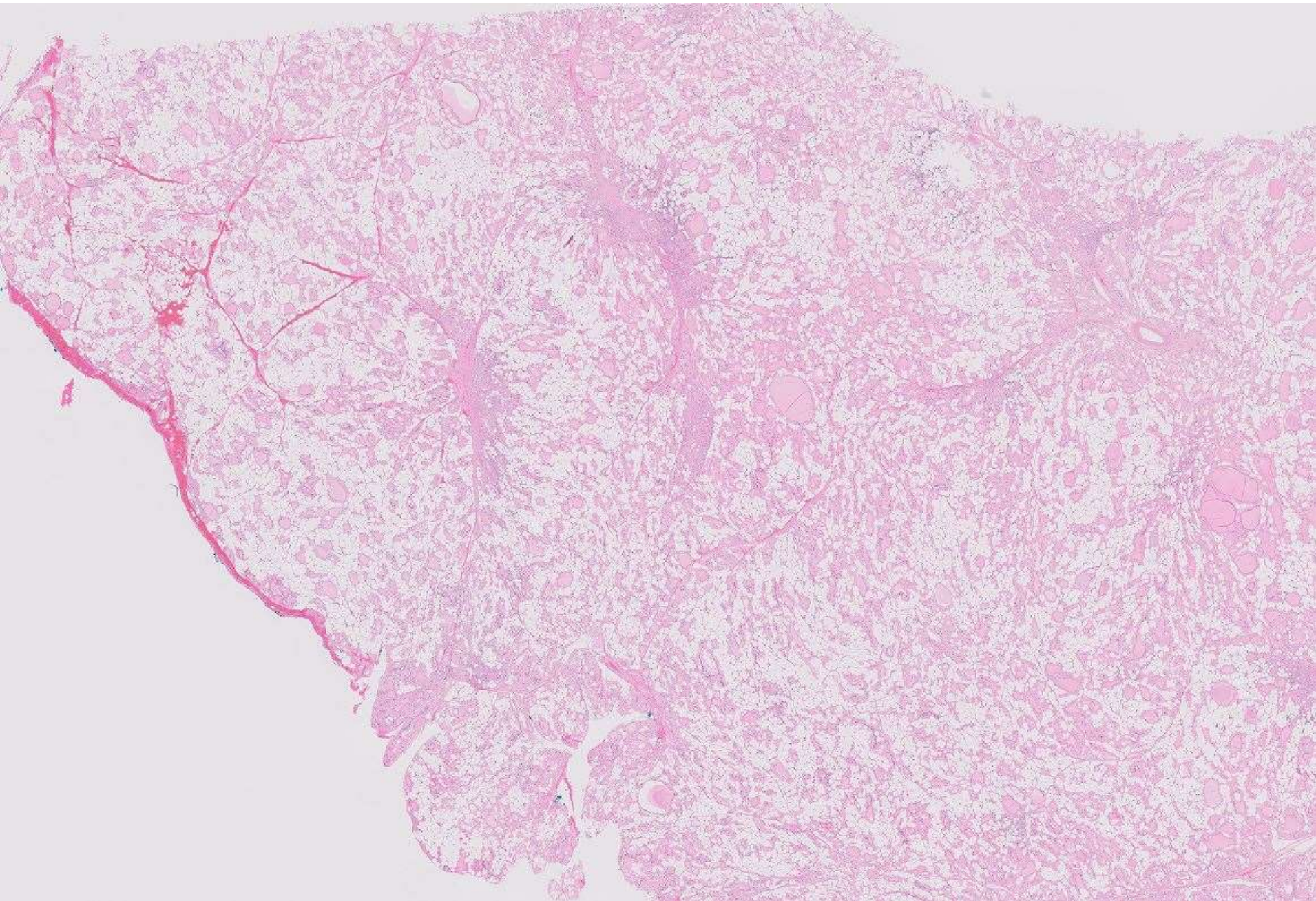


# Gross Pathology

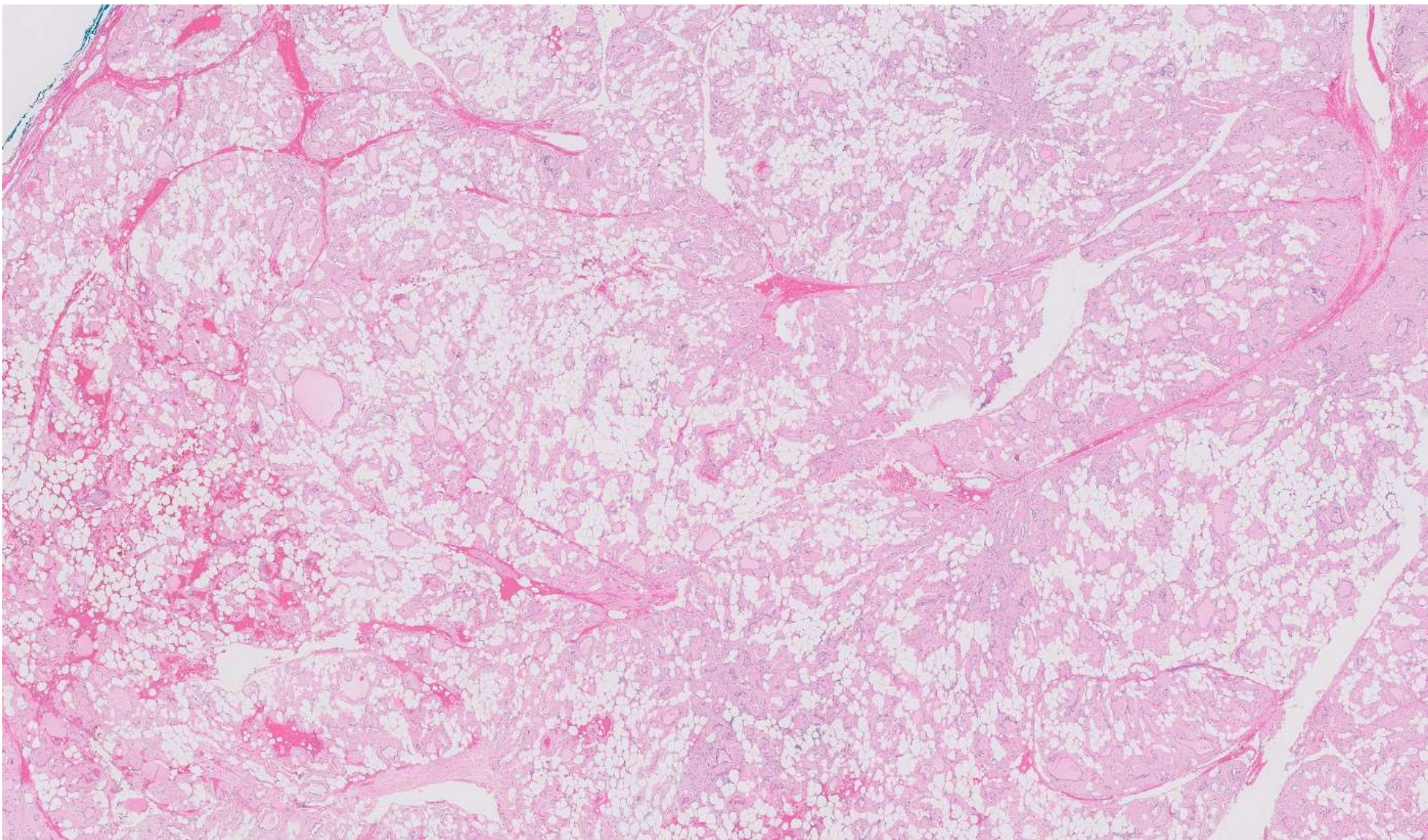




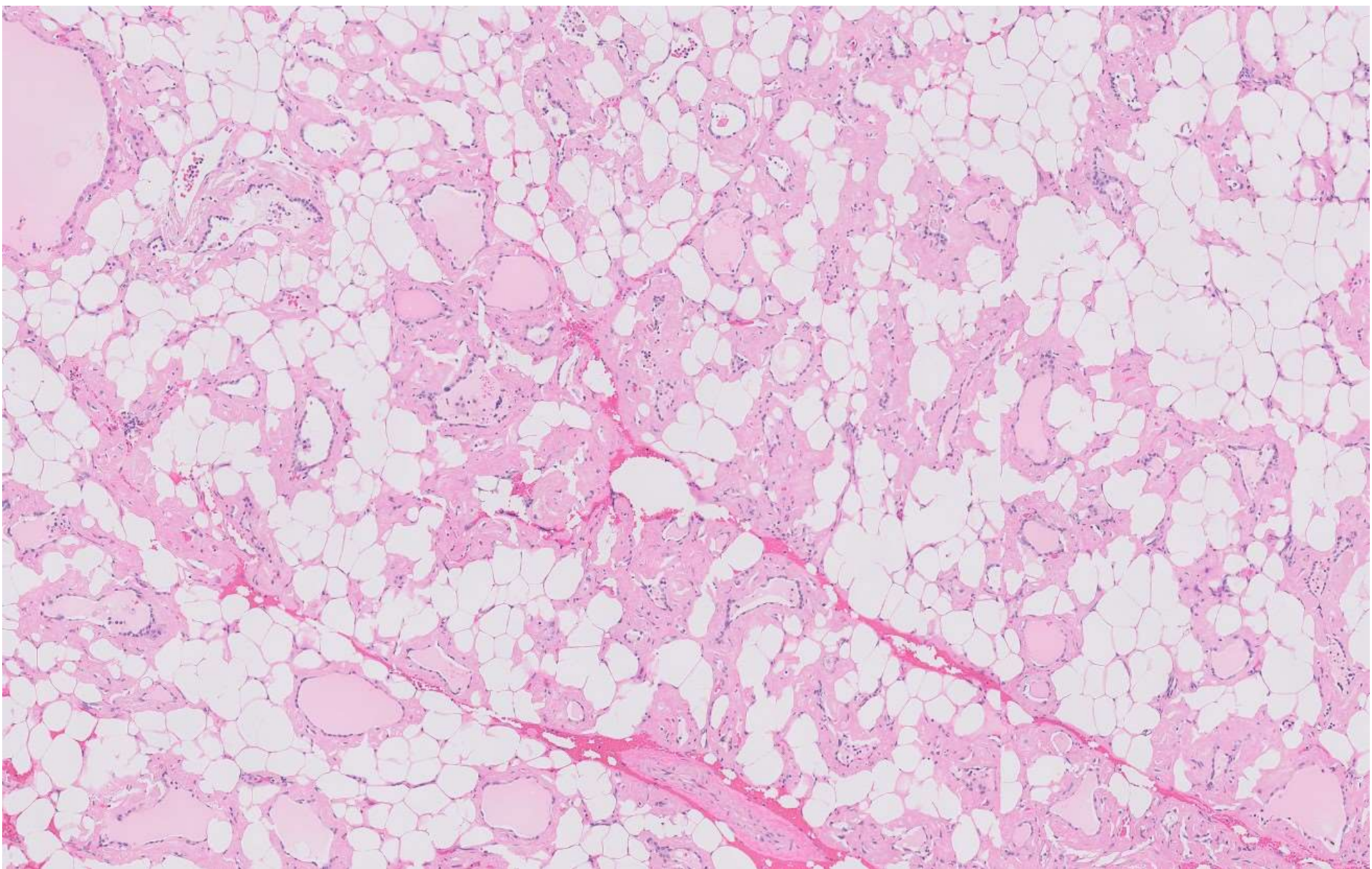




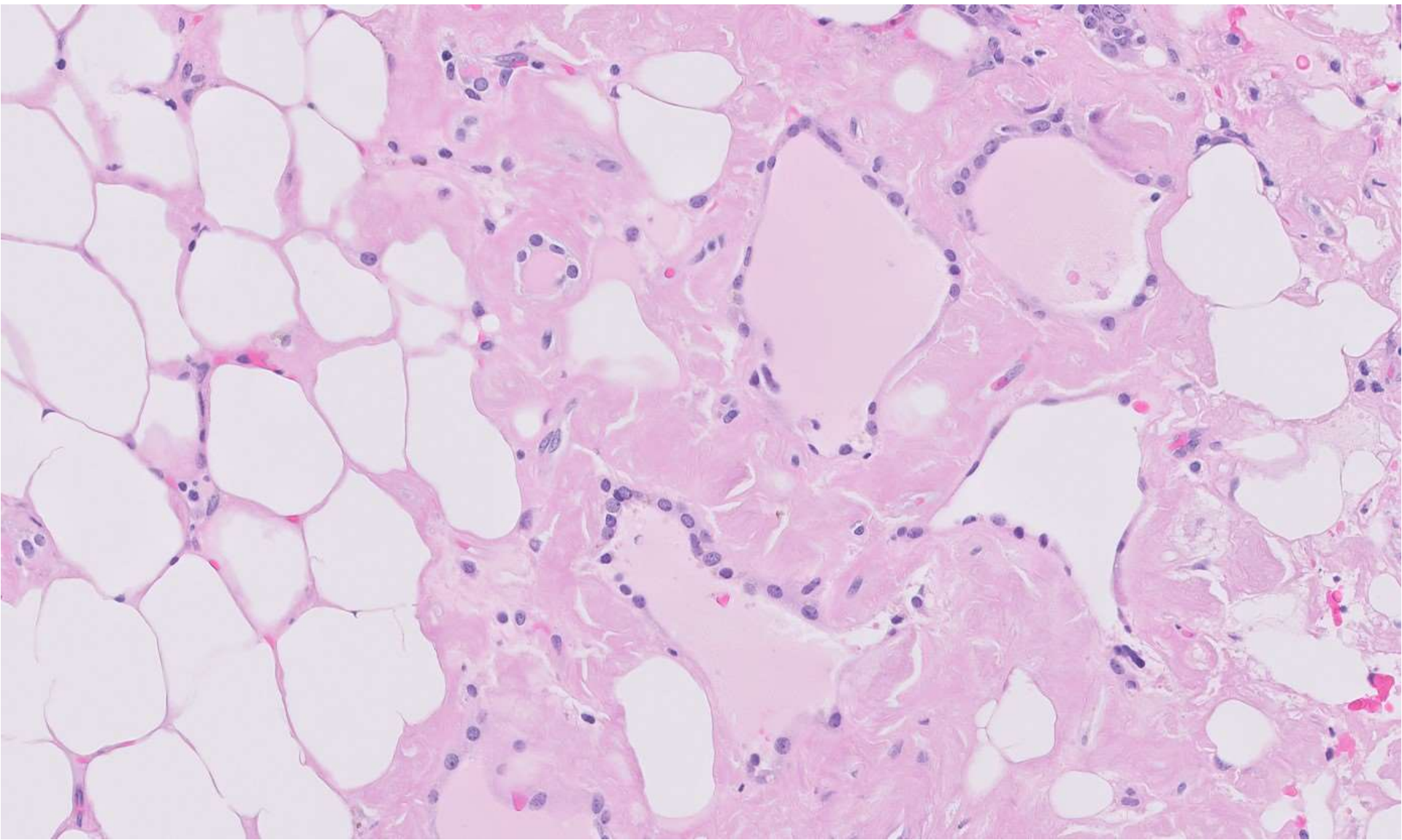




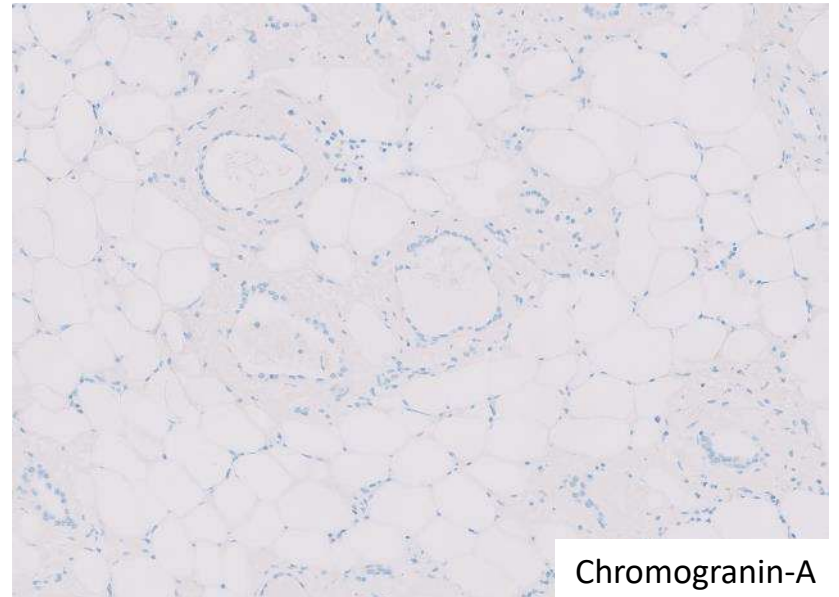
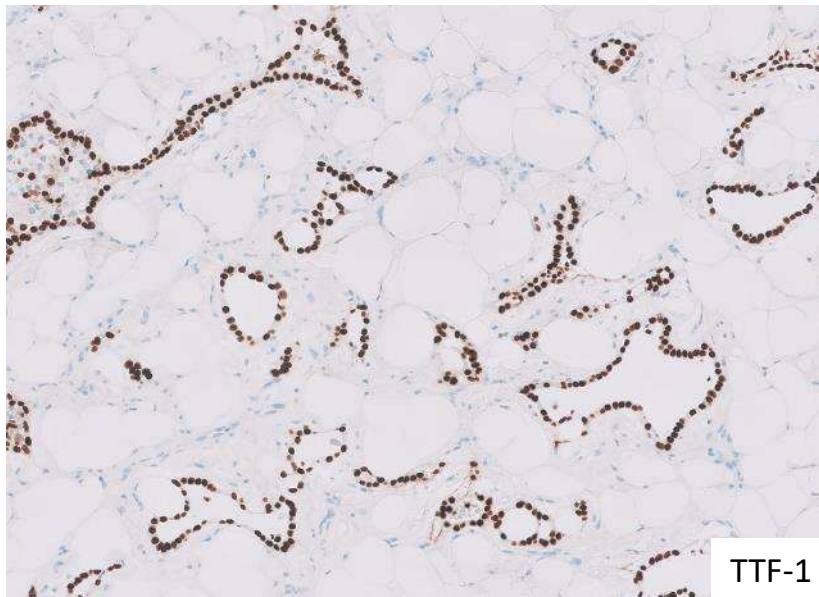











# DIAGNOSIS?

