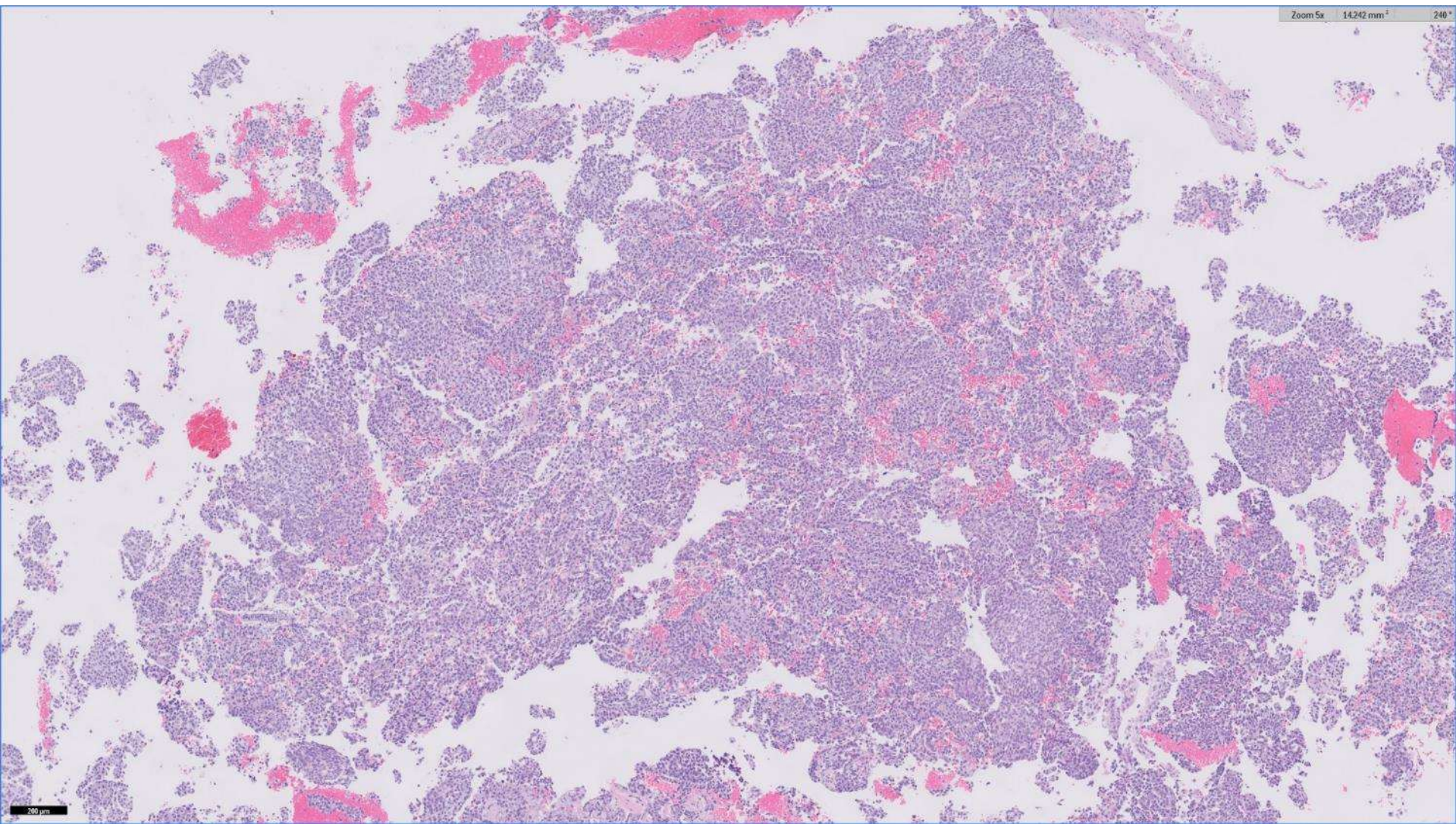
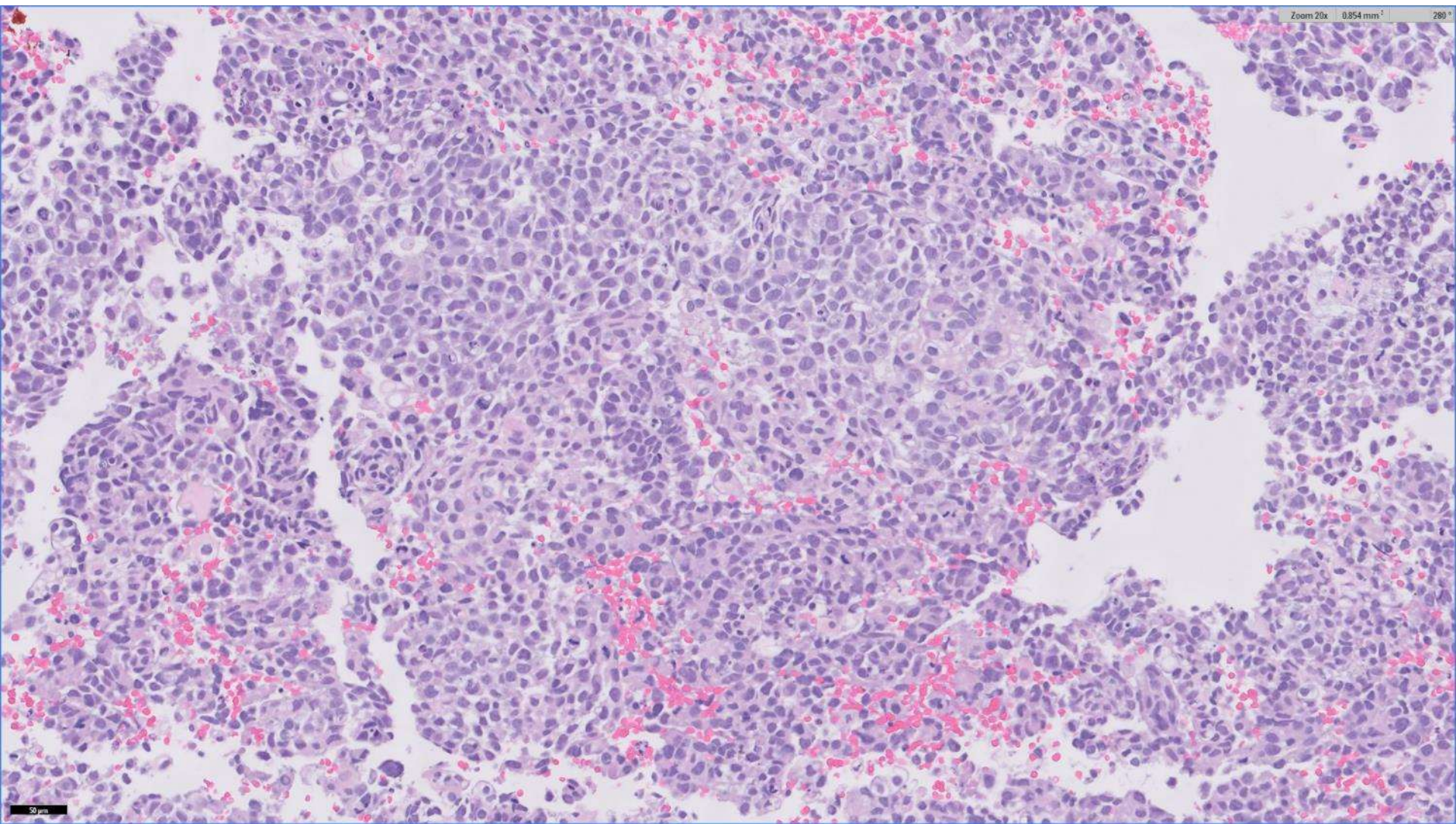


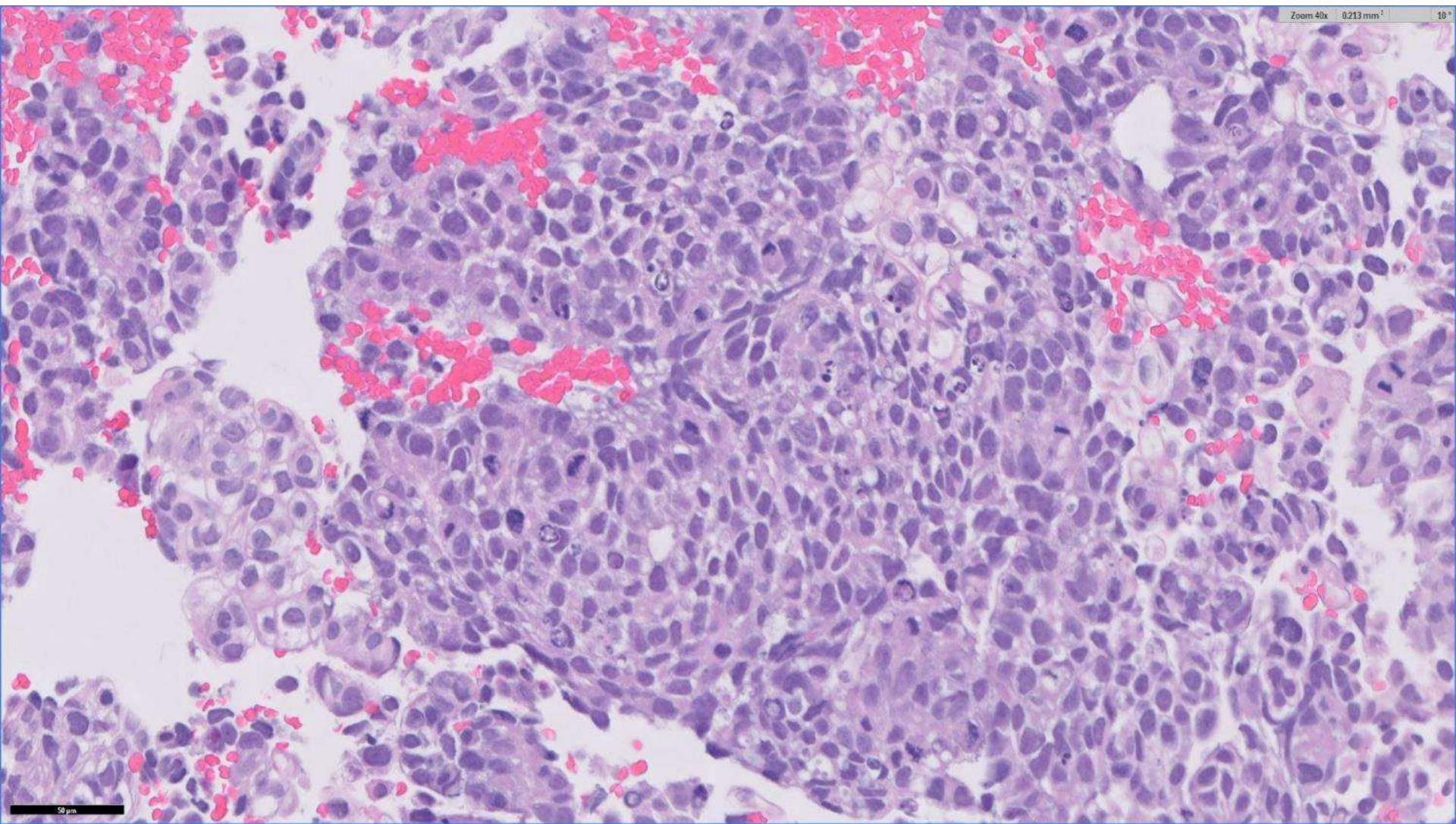
22-0101

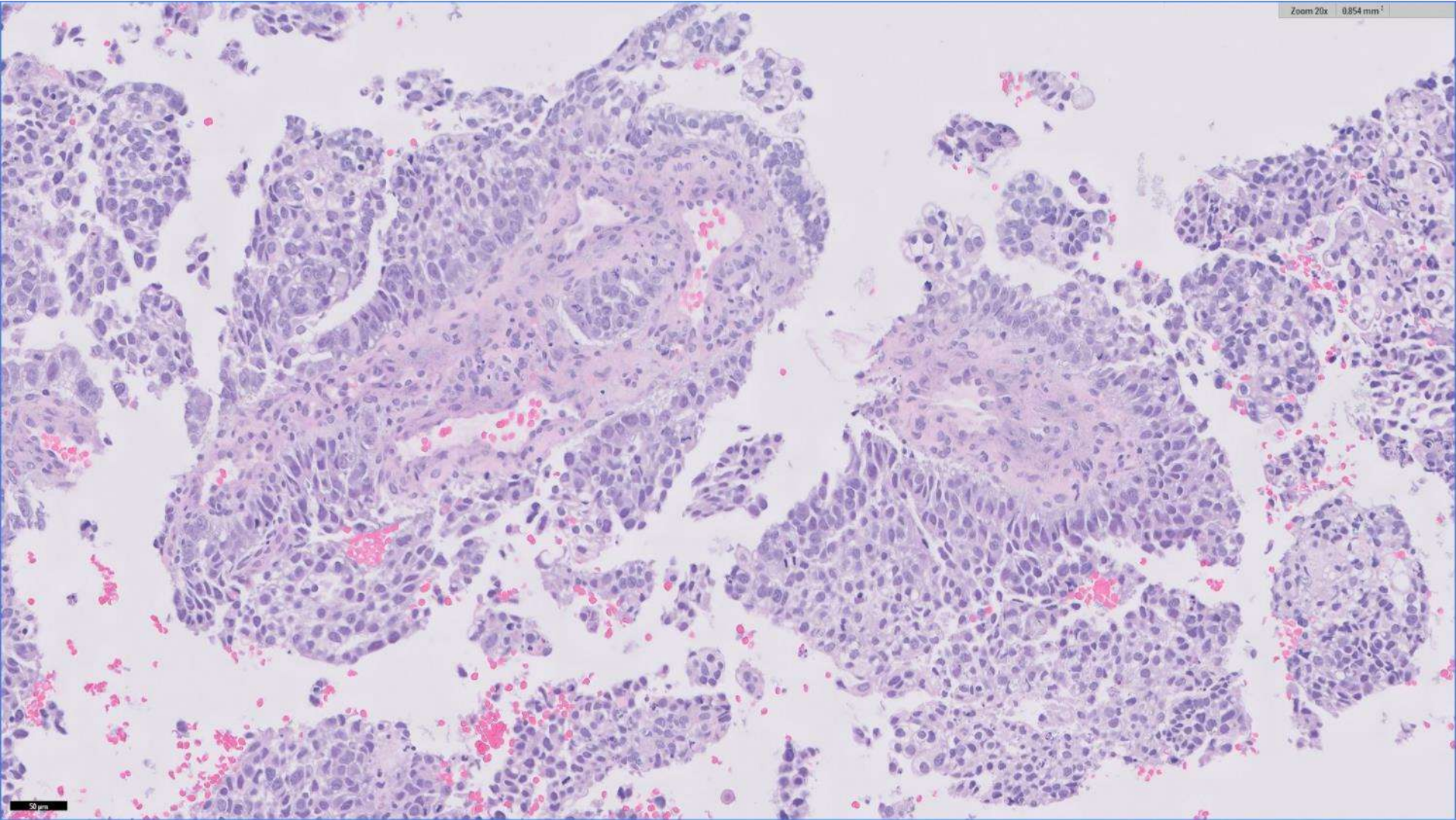
Nicholas Ladwig; UCSF

82-year-old F with post-menopausal bleeding and an enlarged uterus who underwent endometrial biopsy.







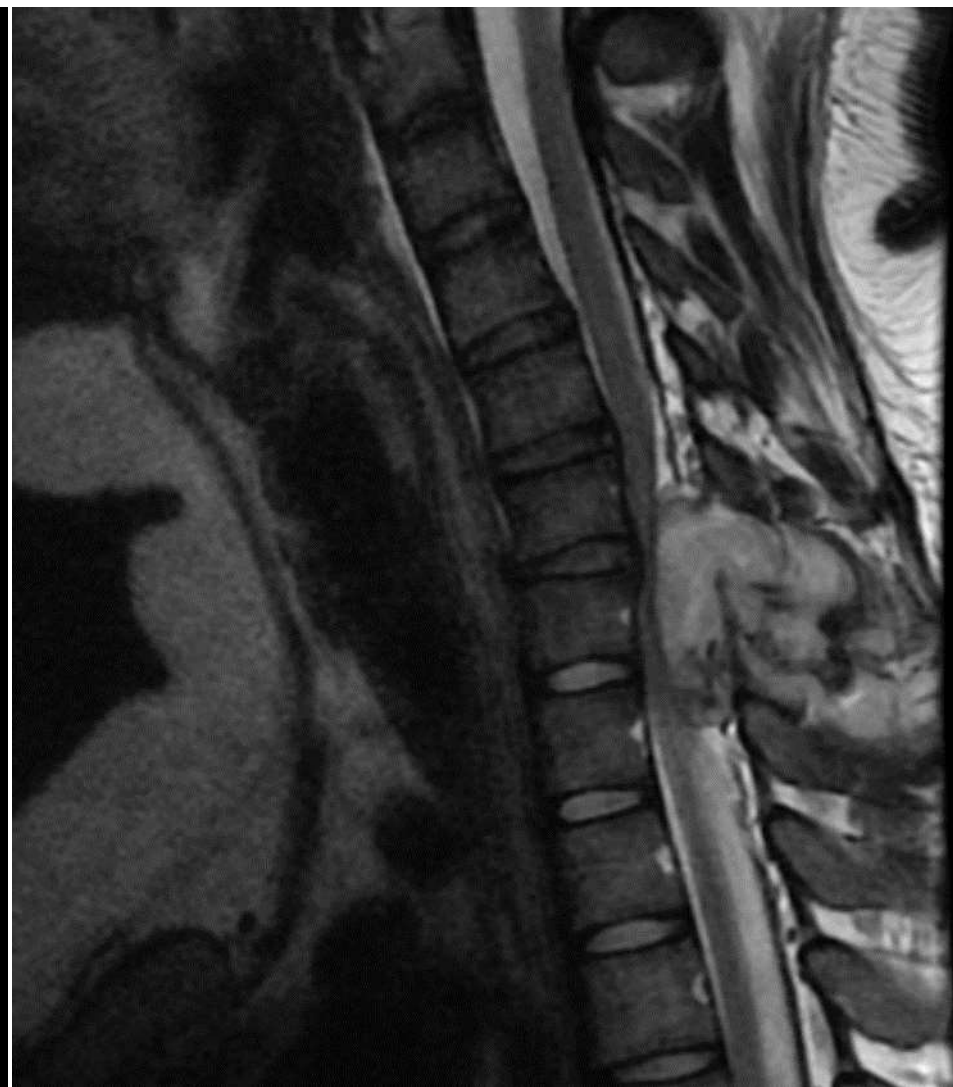
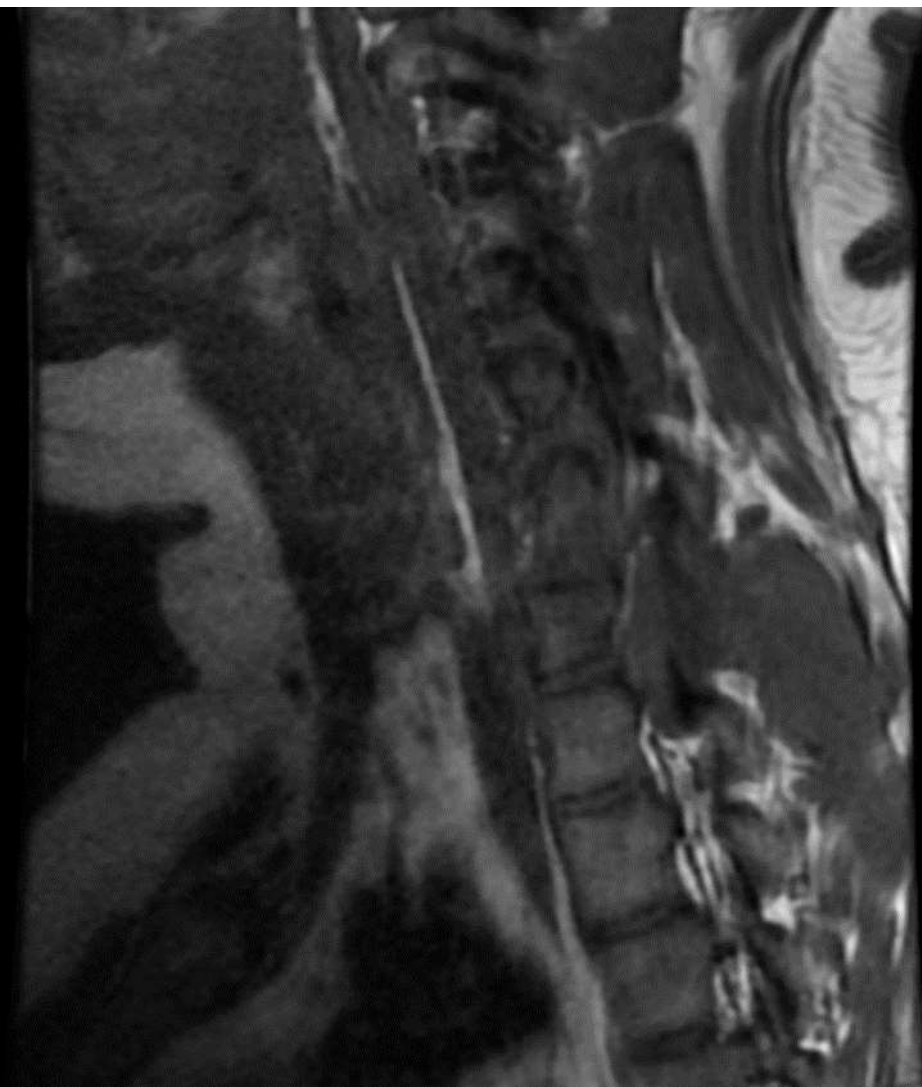
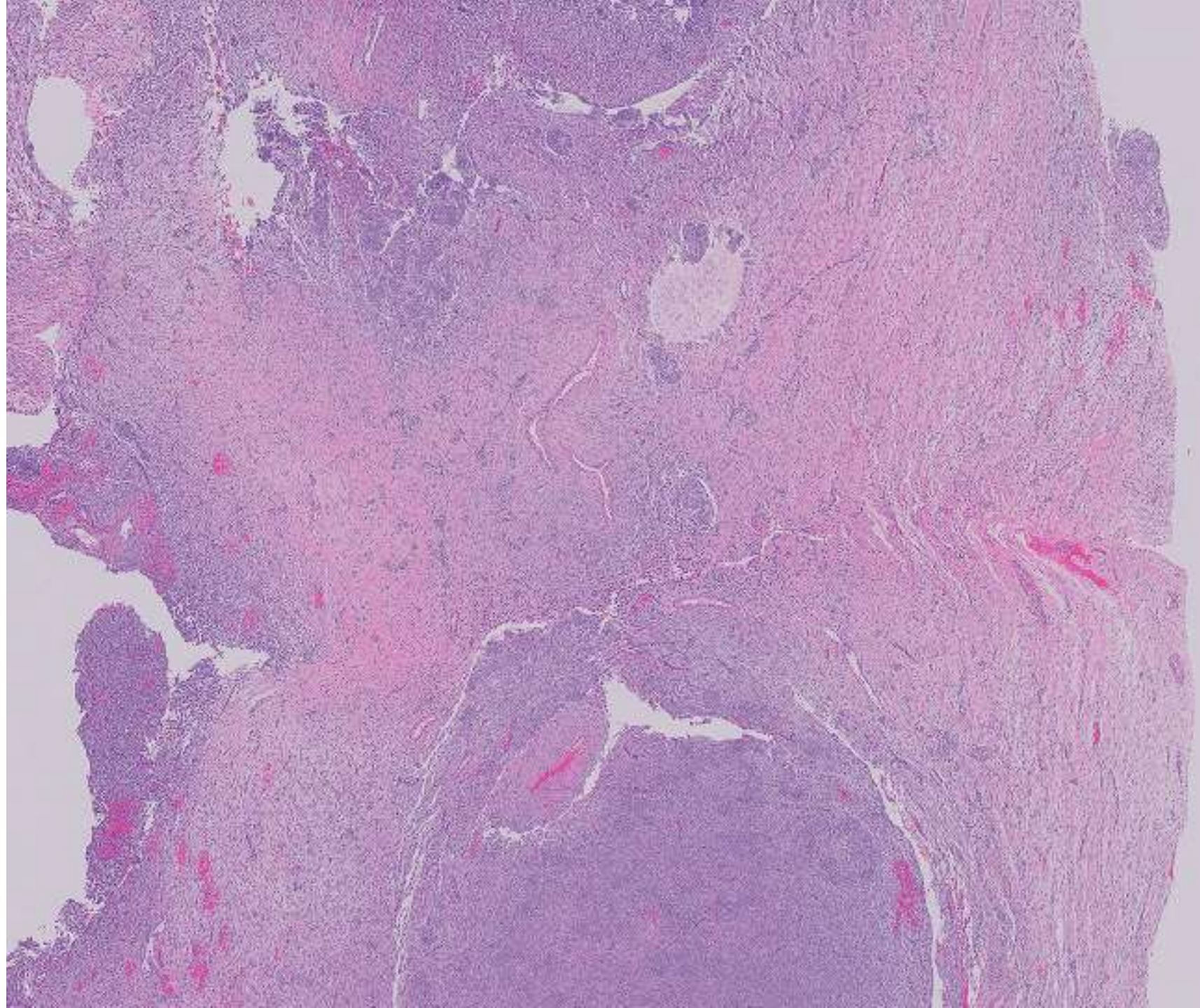


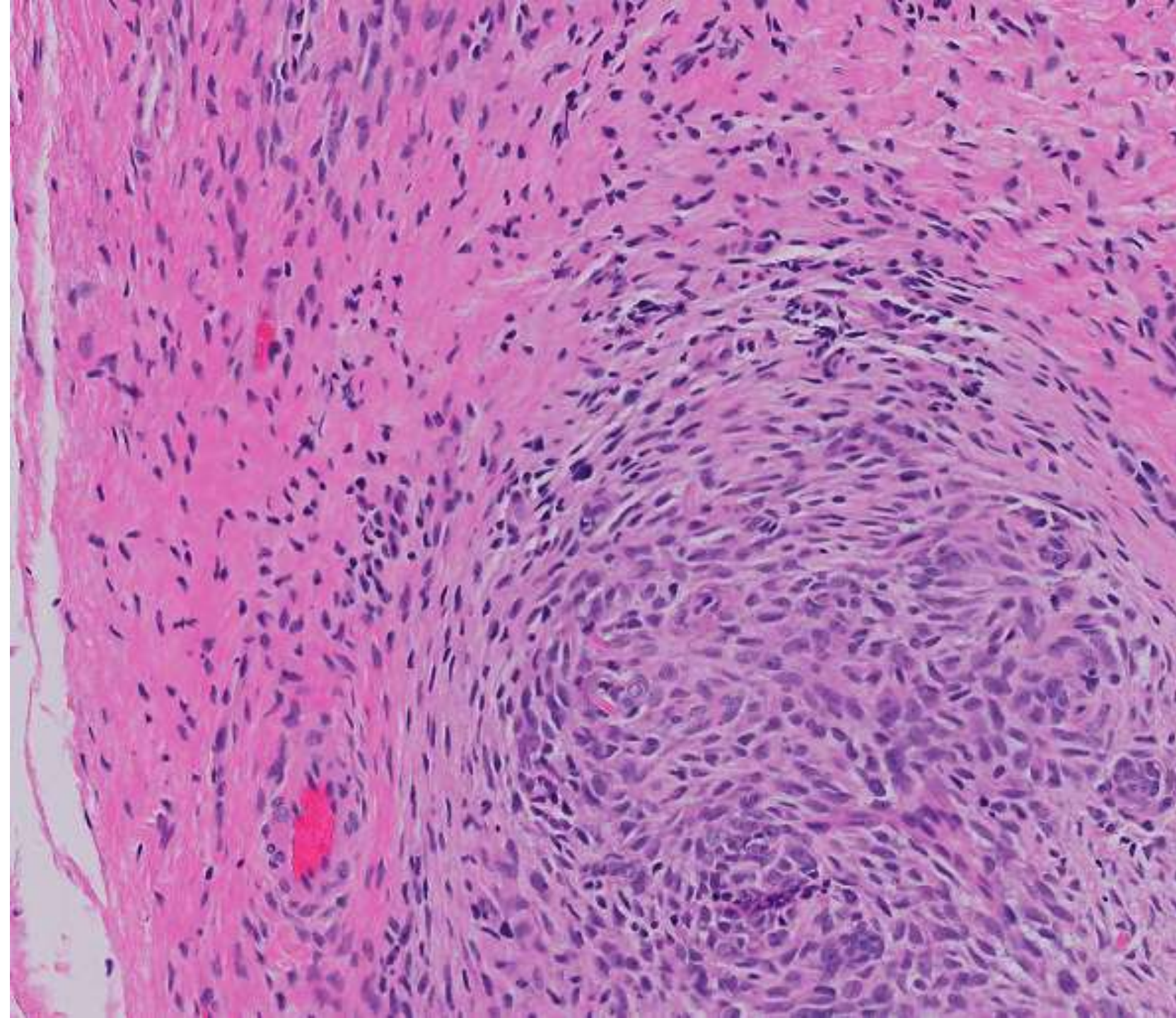
22-0102

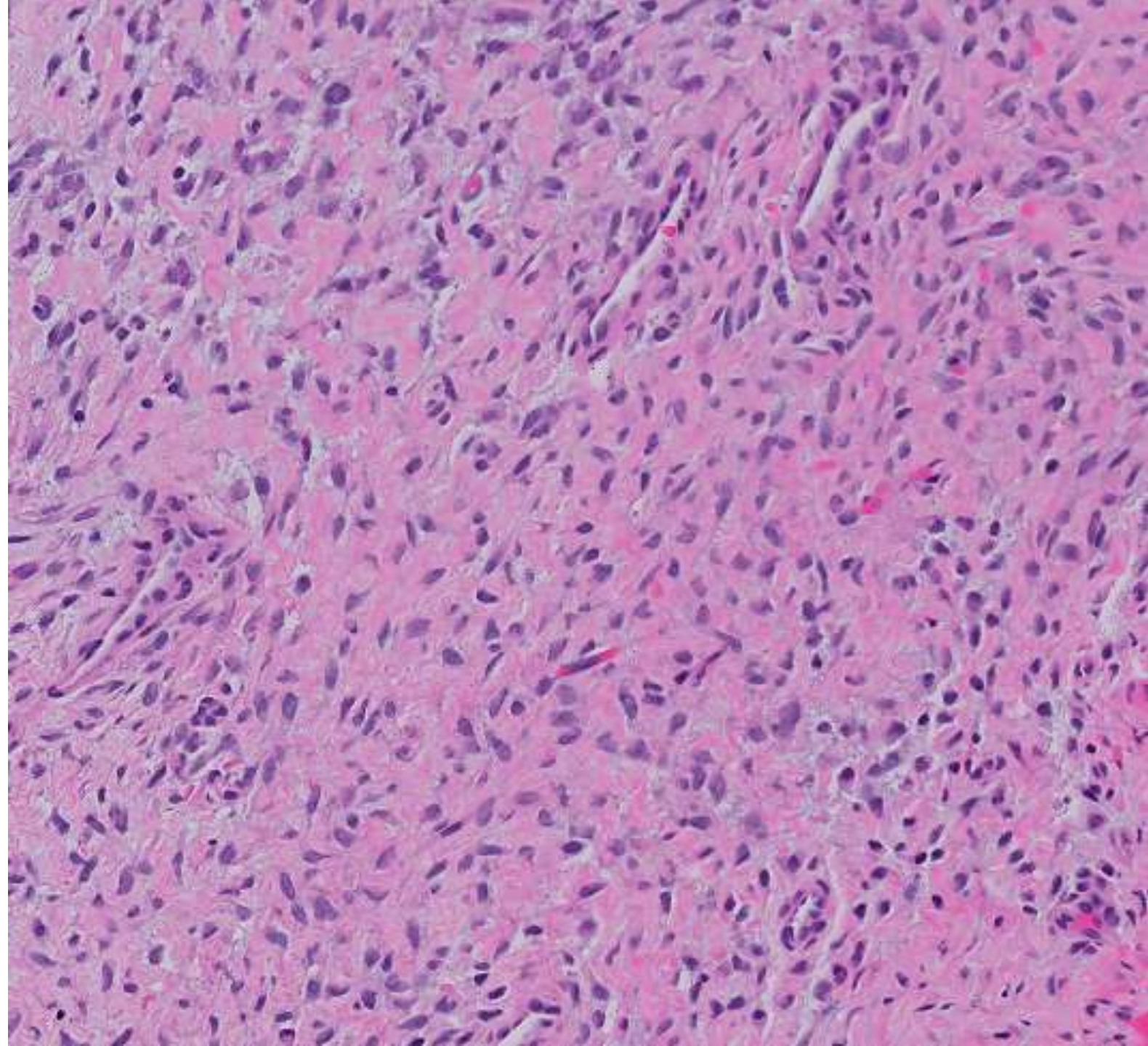
Angus Toland/Hannes Vogel; Stanford

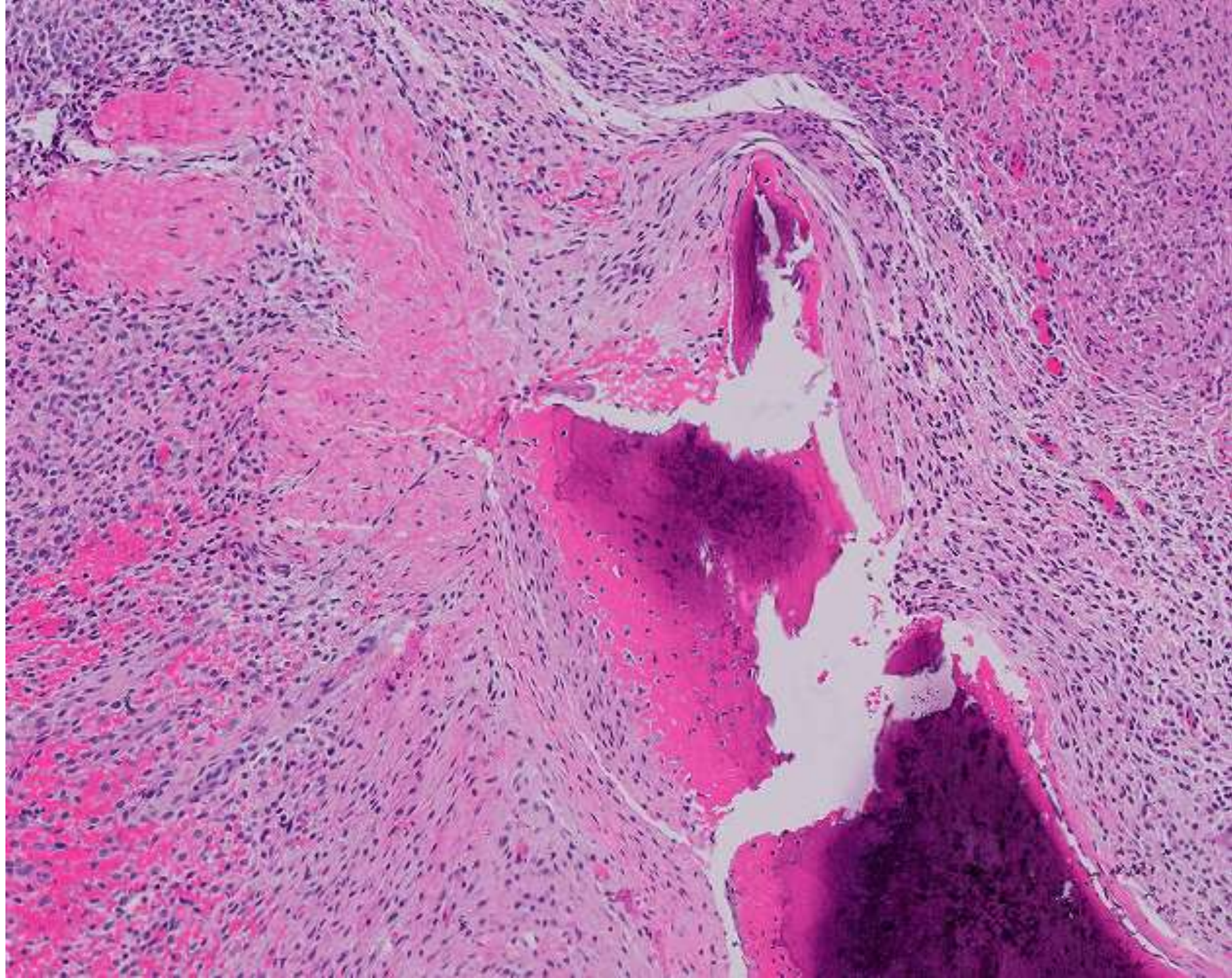
16-year-old girl presenting with rapidly progressive bilateral lower extremity numbness and tingling. MRI showed a large mass with vertebral body destruction from C6-T11 with cord compression.

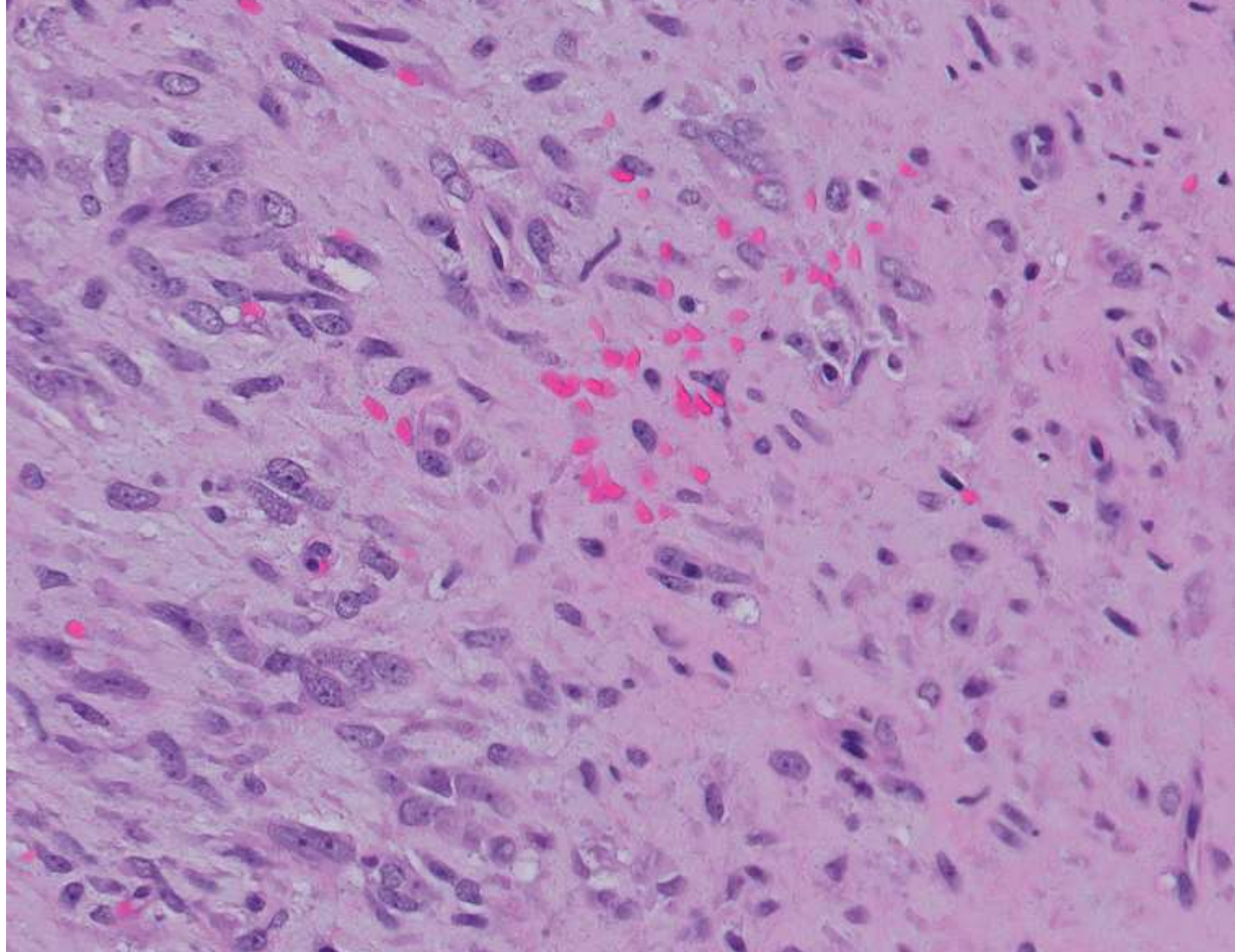


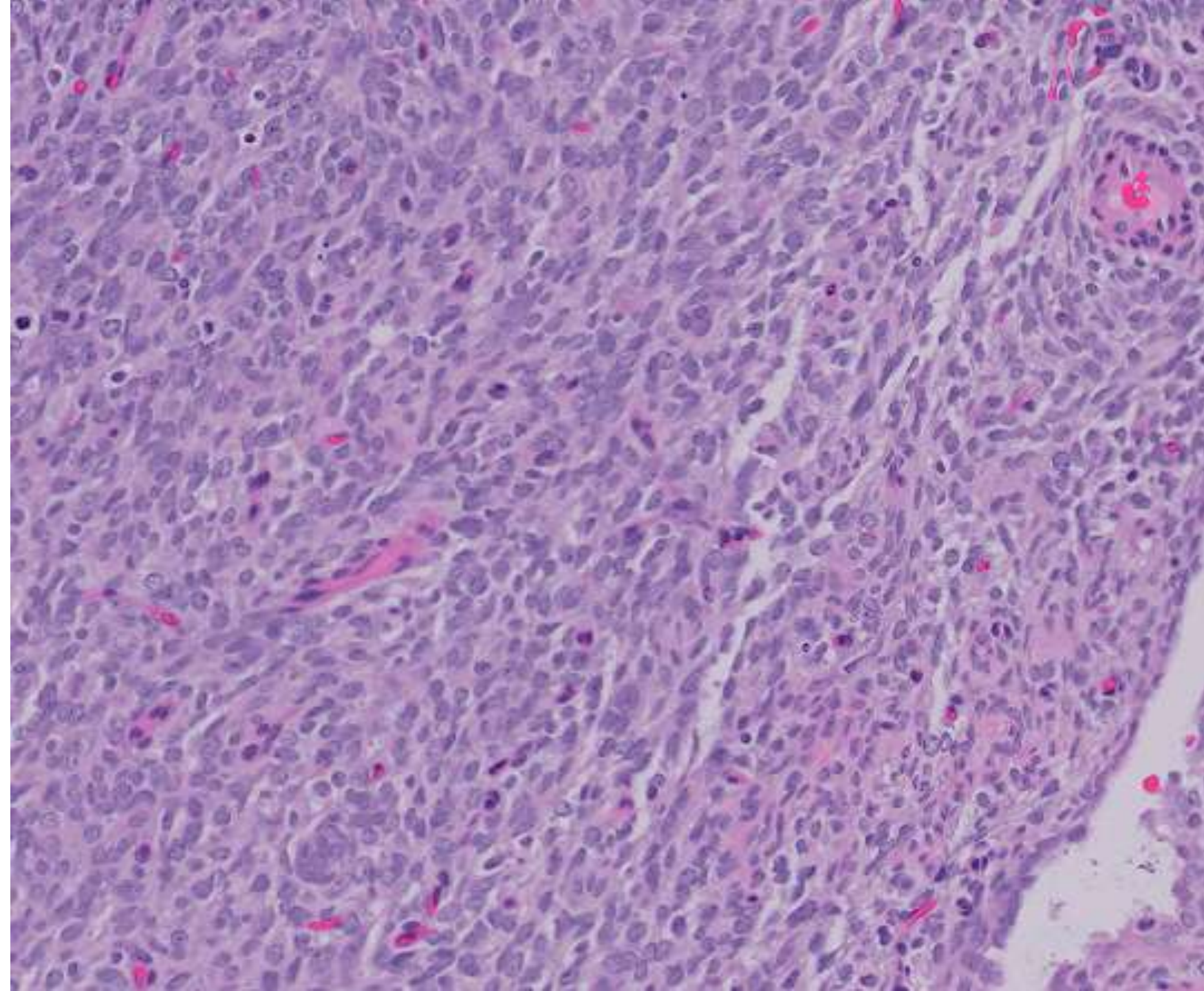


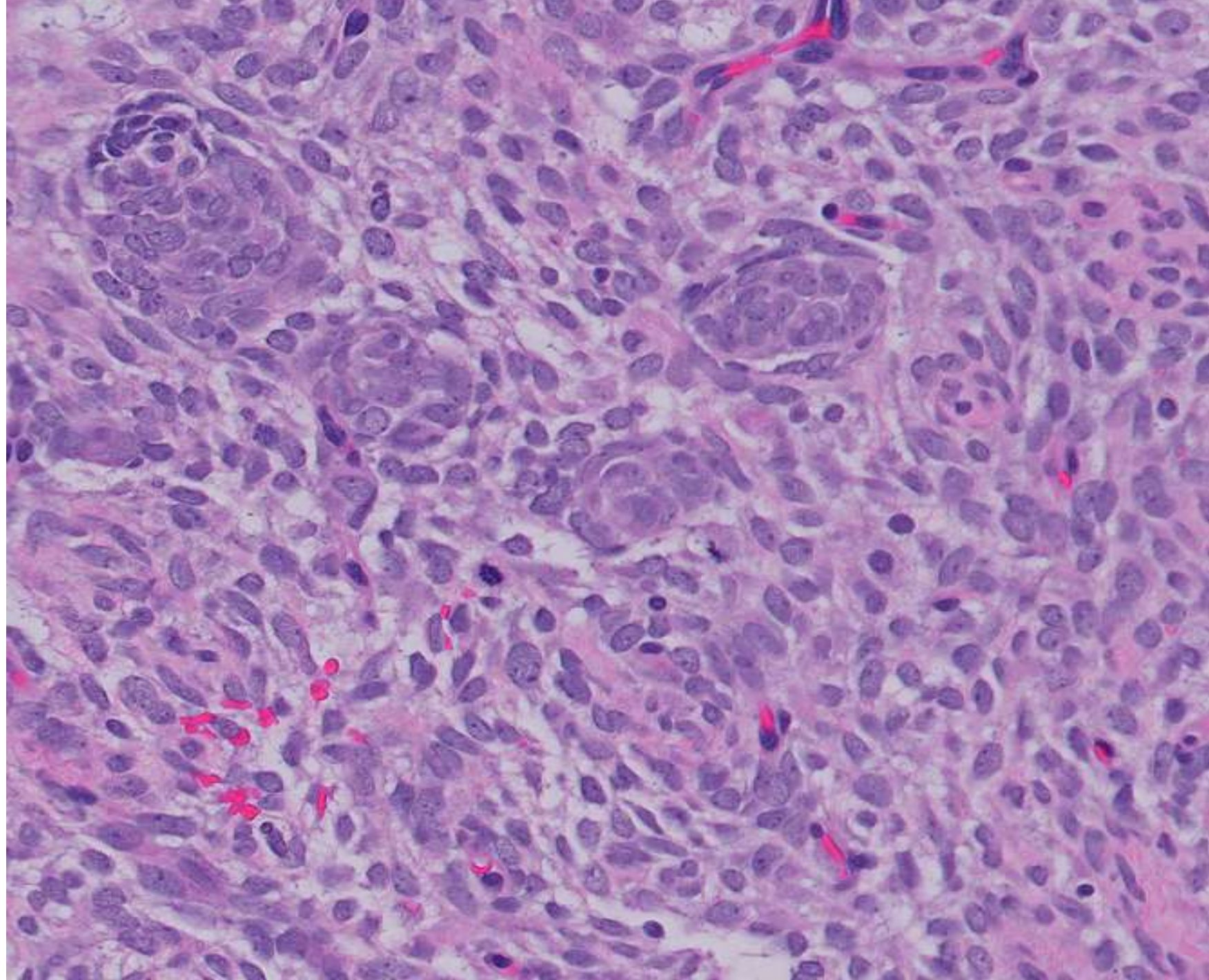


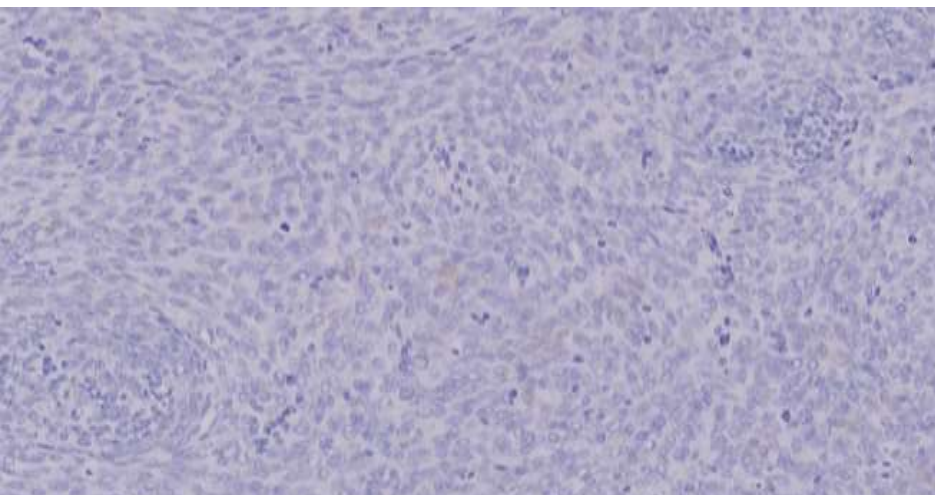




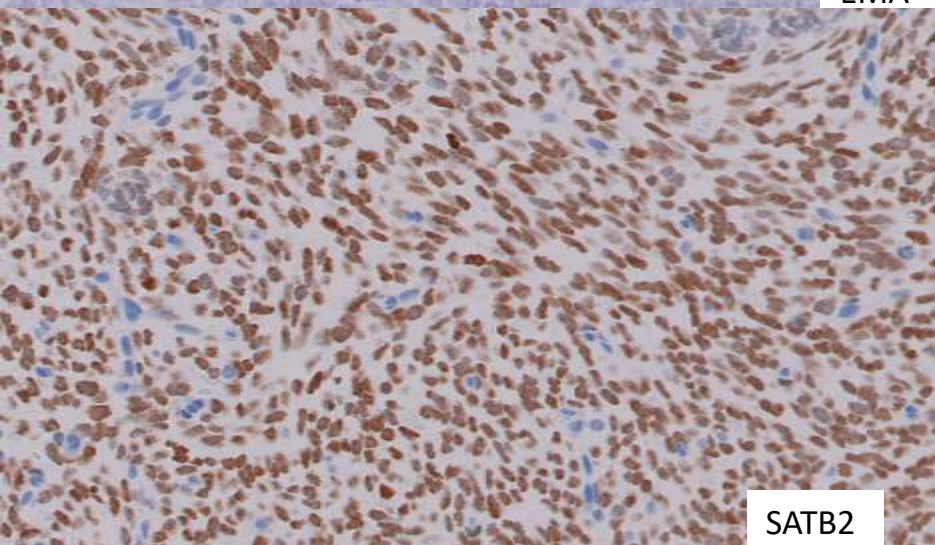




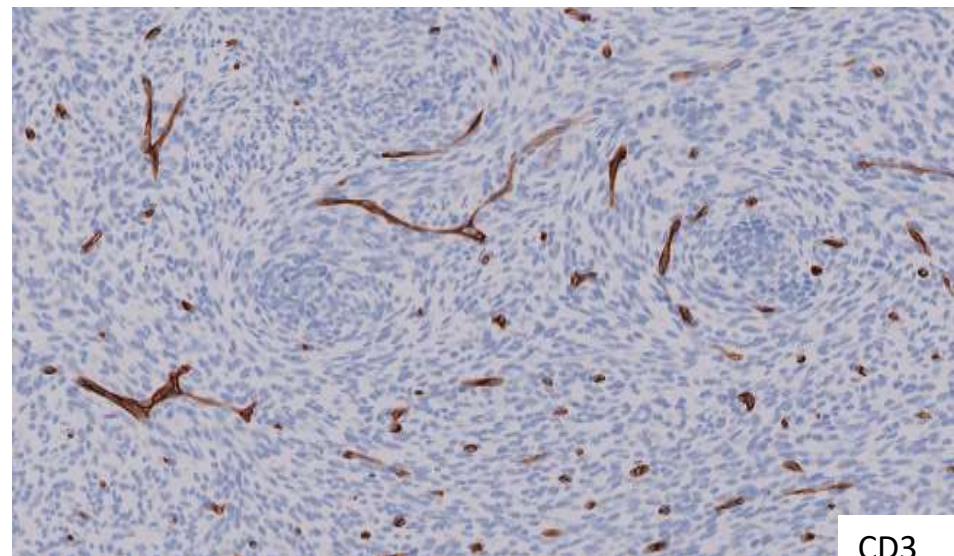




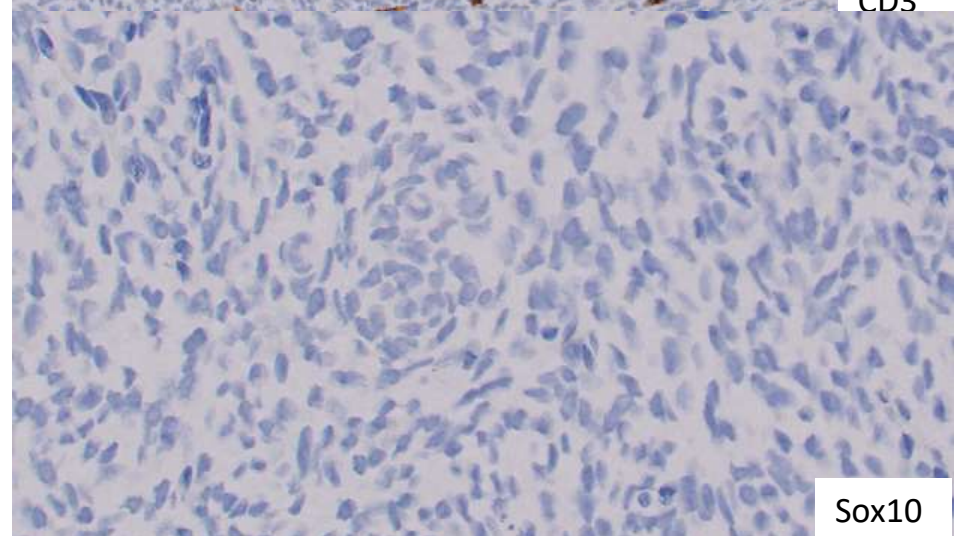
EMA



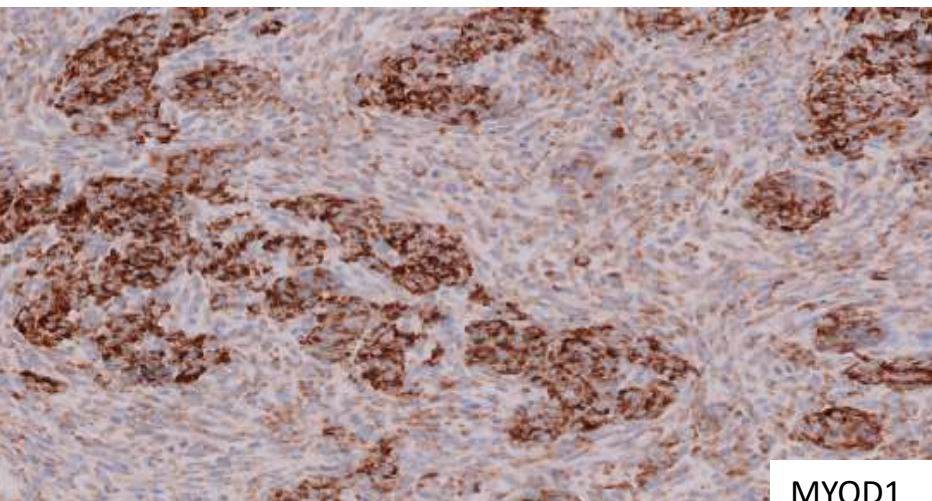
SATB2



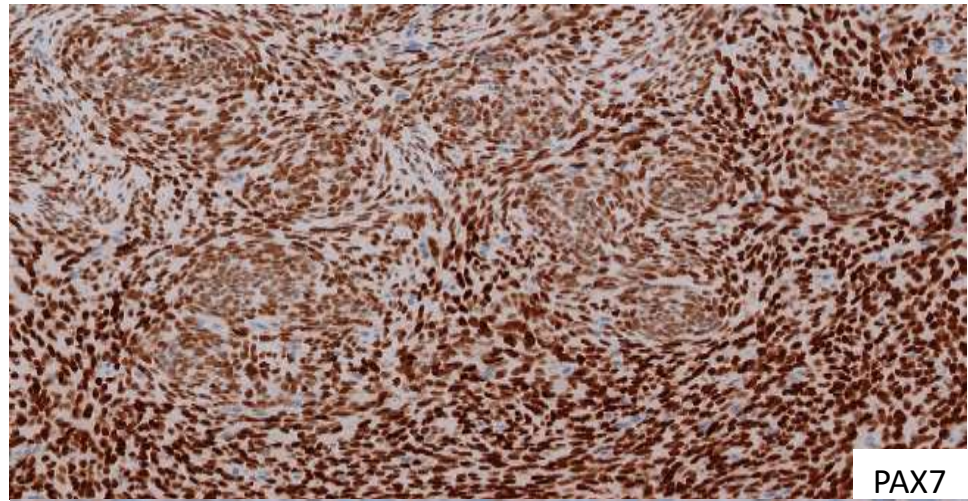
CD3



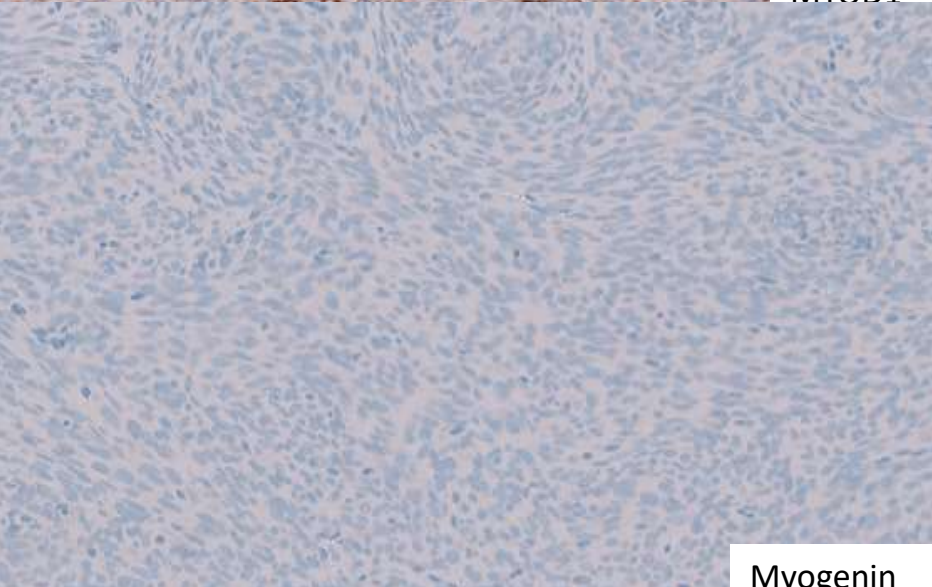
Sox10



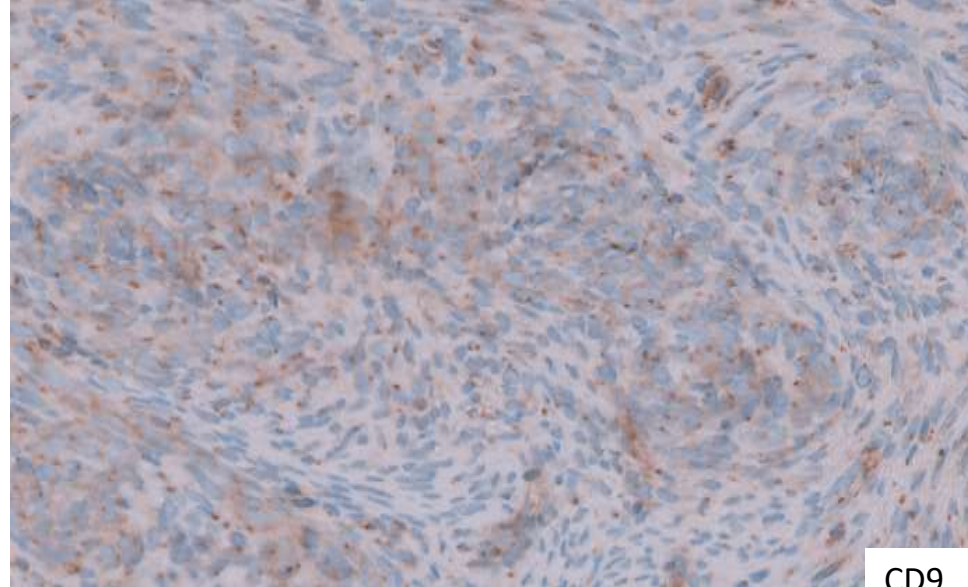
MYOD1



PAX7



Myogenin



CD9
9

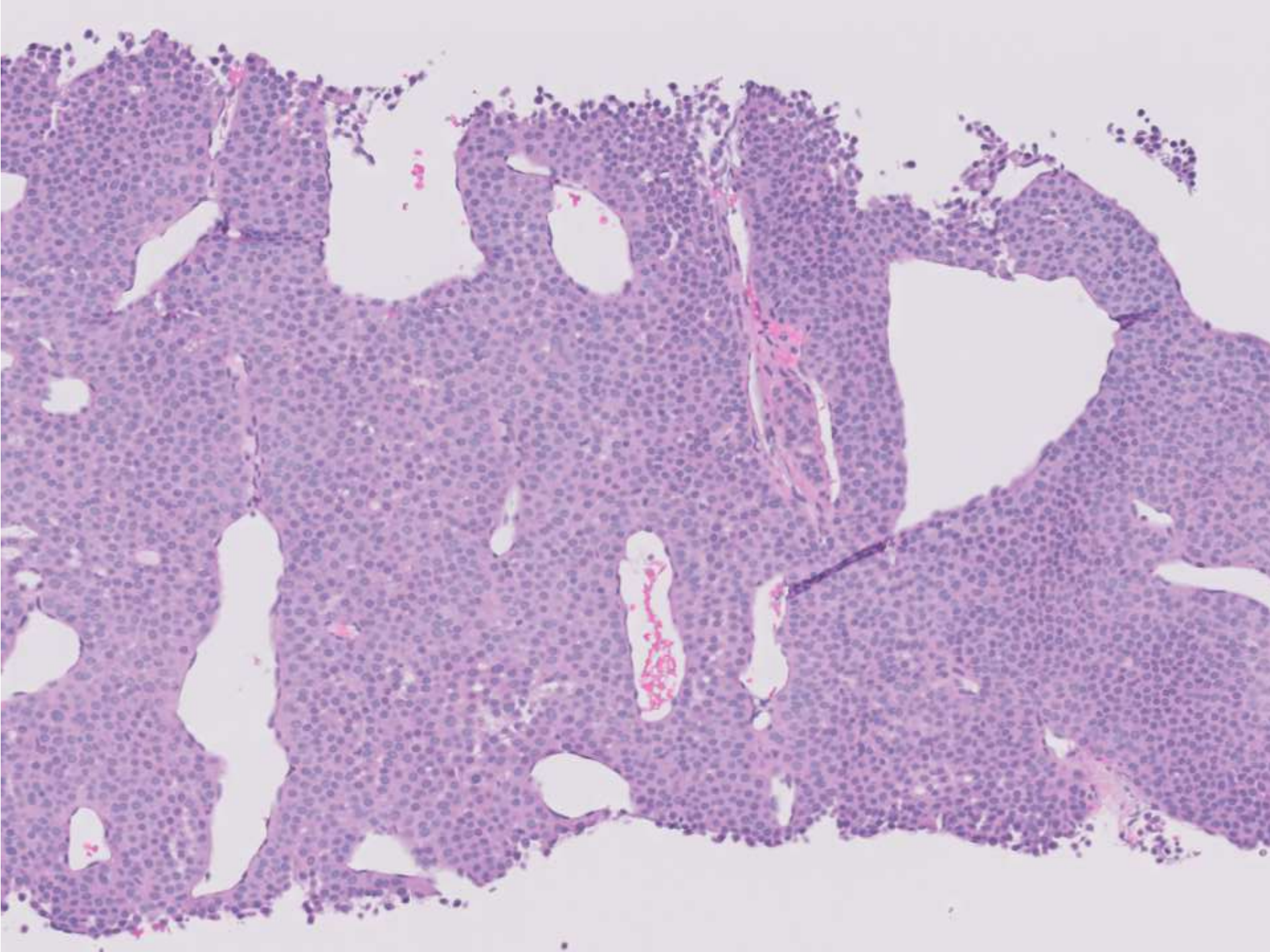
Positive	Negative
PAX7	CD99 (non-membranous)
SATB2	Desmin, SMA
INI1 (Intact expression)	Myogenin, MyoD1
	ERG, CD34, CD31
	EMA, SSTR2A
	CK mix
	WT-1 (N-terminal)
	S100, Sox10
	MPO
	ALK
	NUT

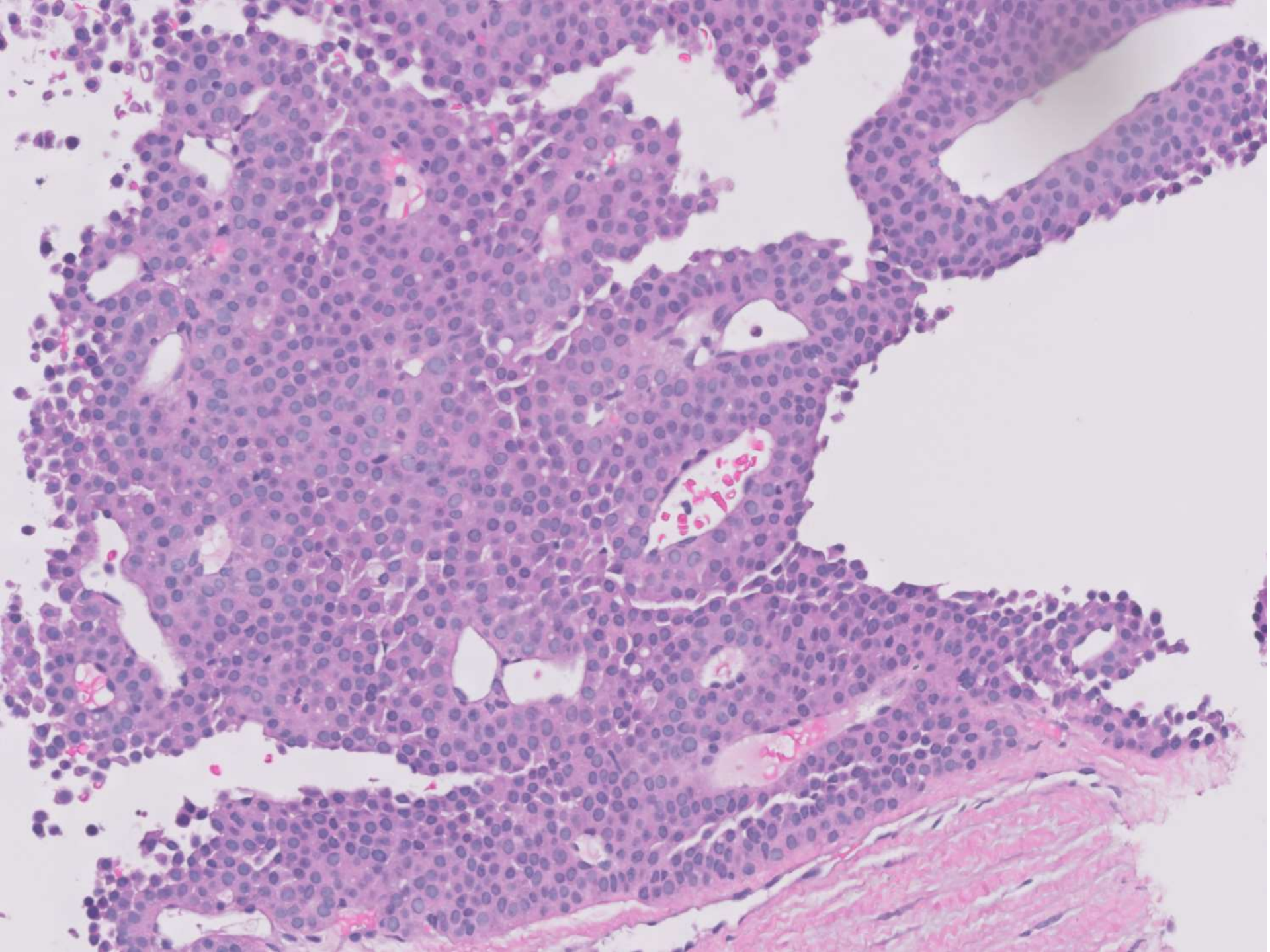


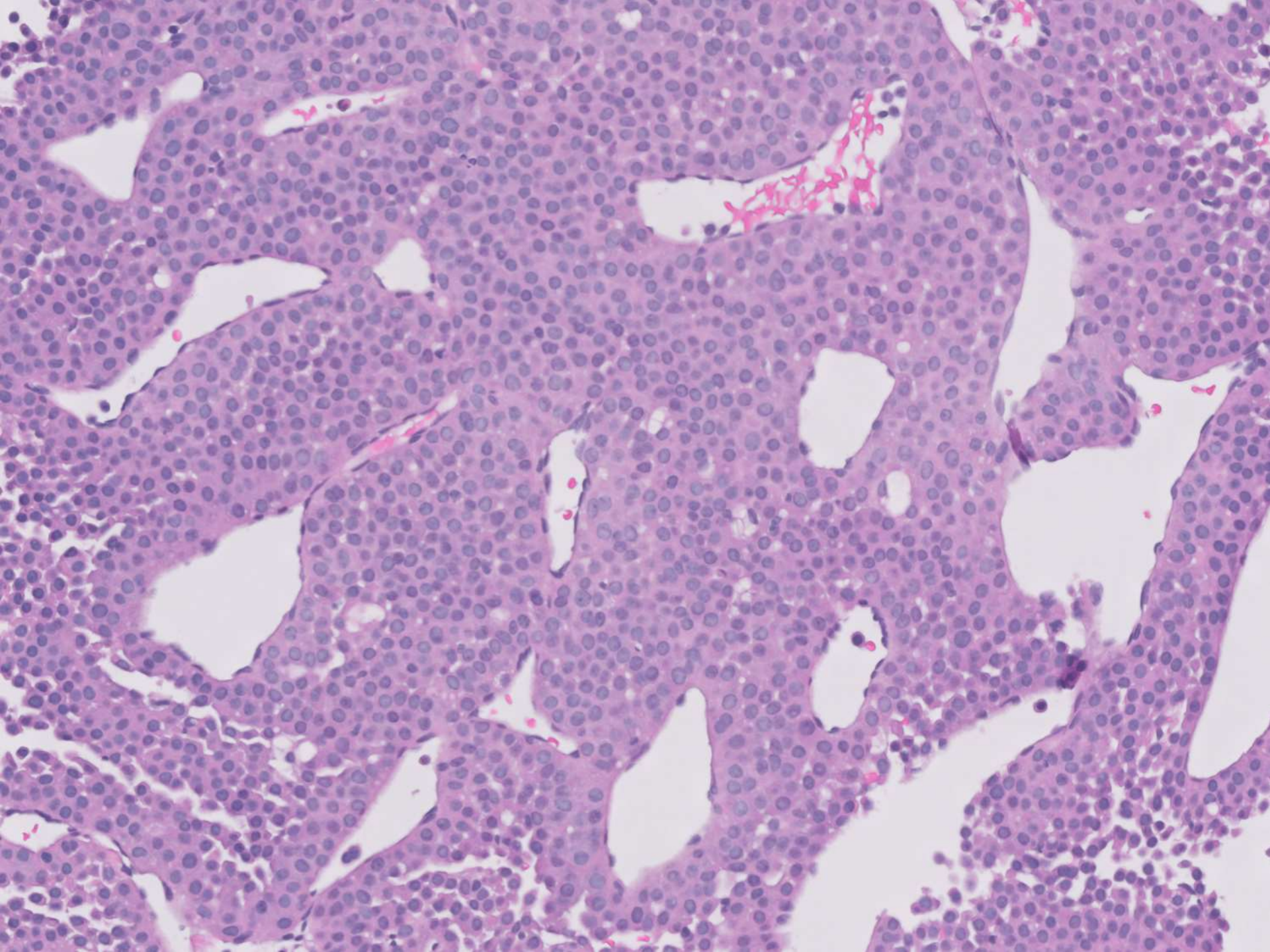
22-0103

Sanjay Kakar; UCSF

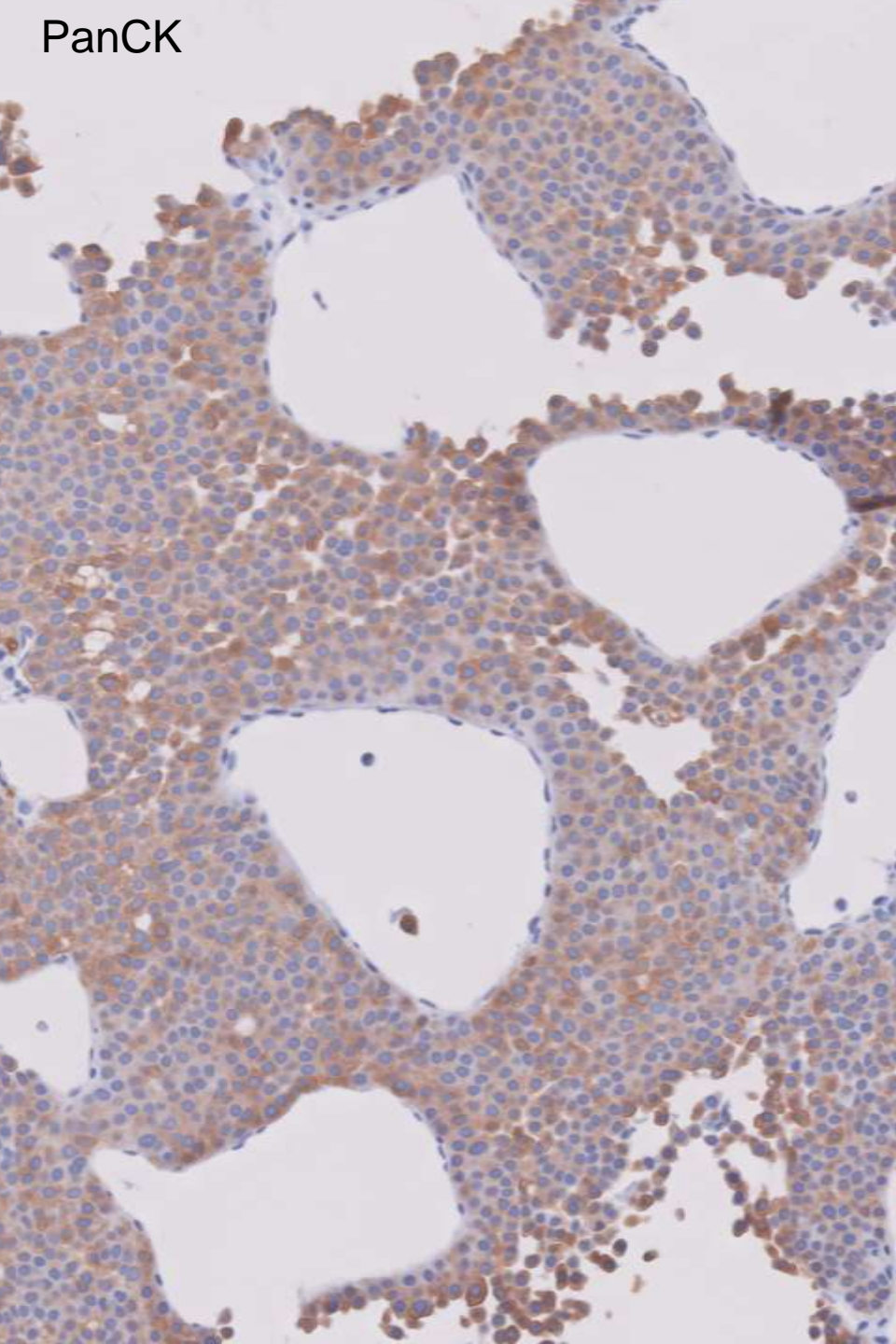
23-year-F with multiple liver masses in segments 7 and 8, largest measuring 23cm (others 4-5cm), without extrahepatic mass and no history of liver disease.



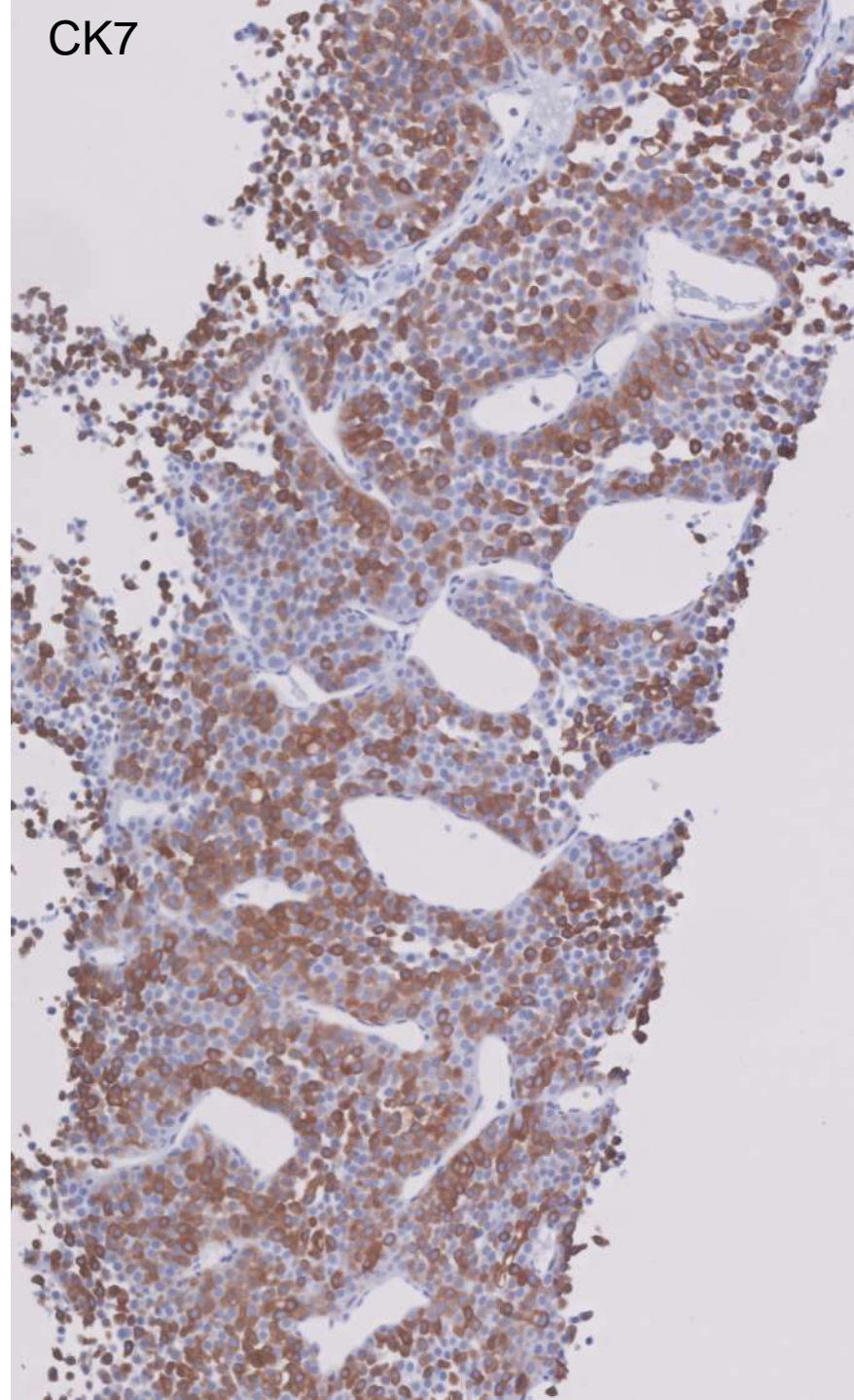




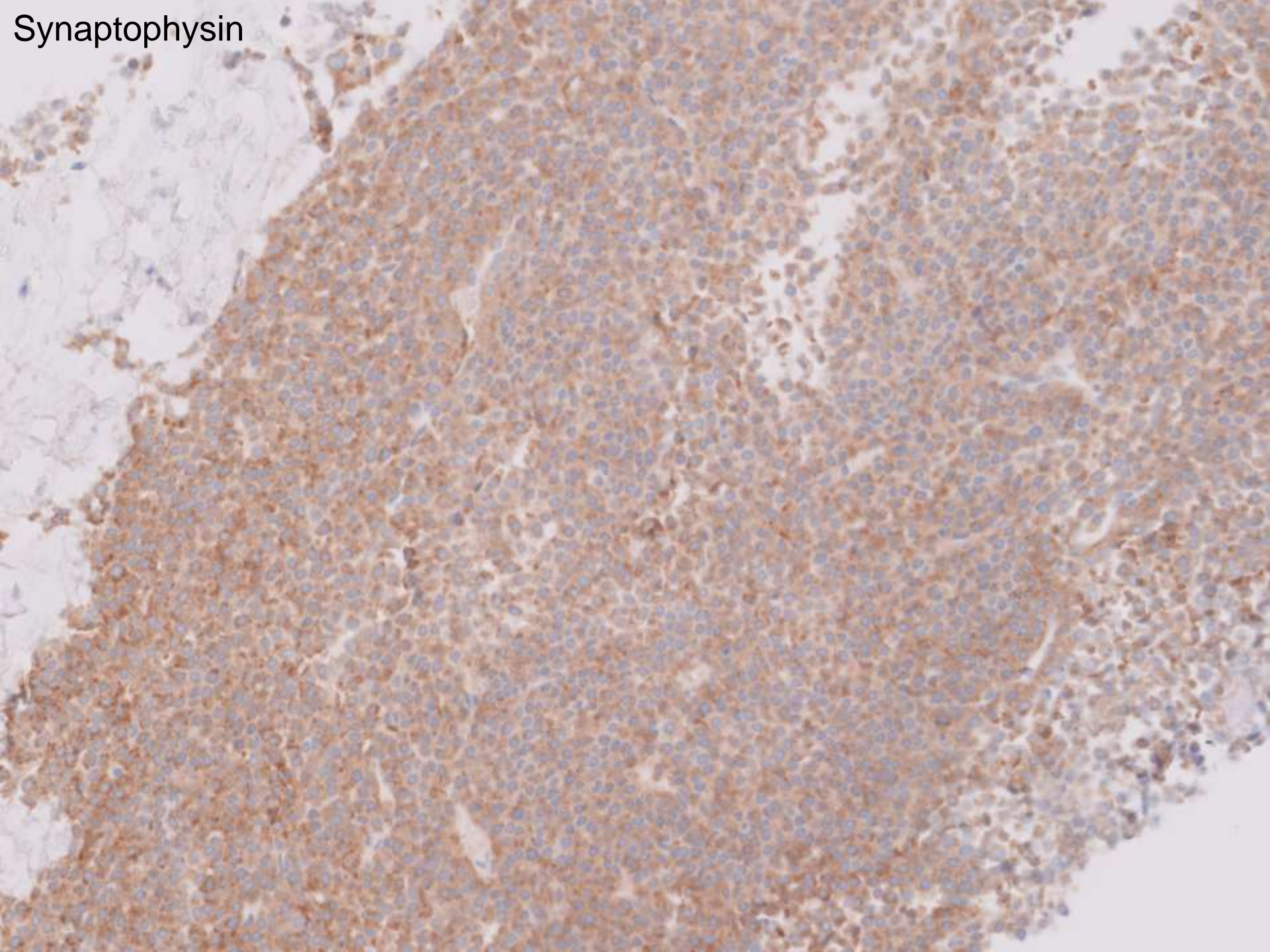
PanCK



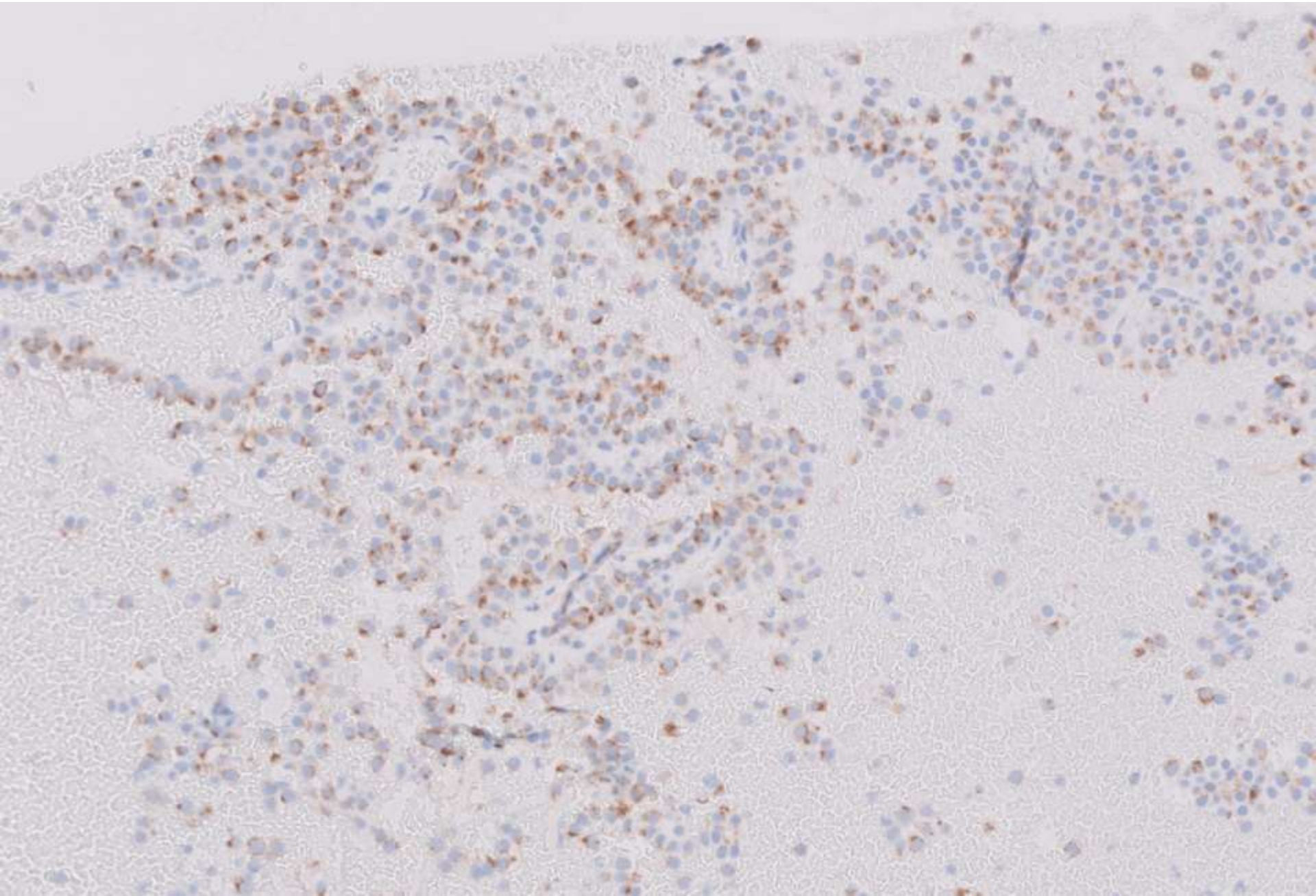
CK7



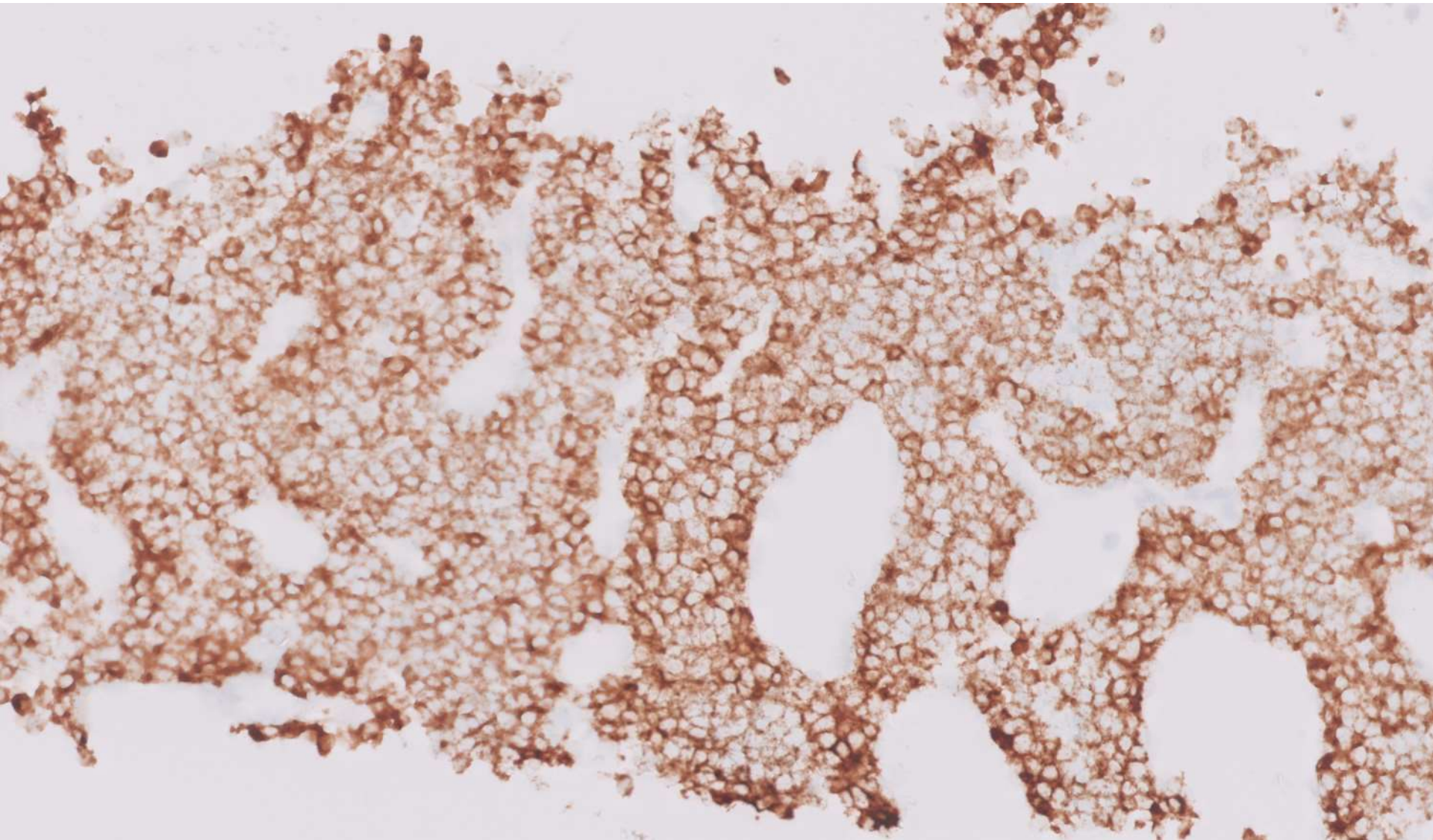
Synaptophysin



Chromogranin (cell block)



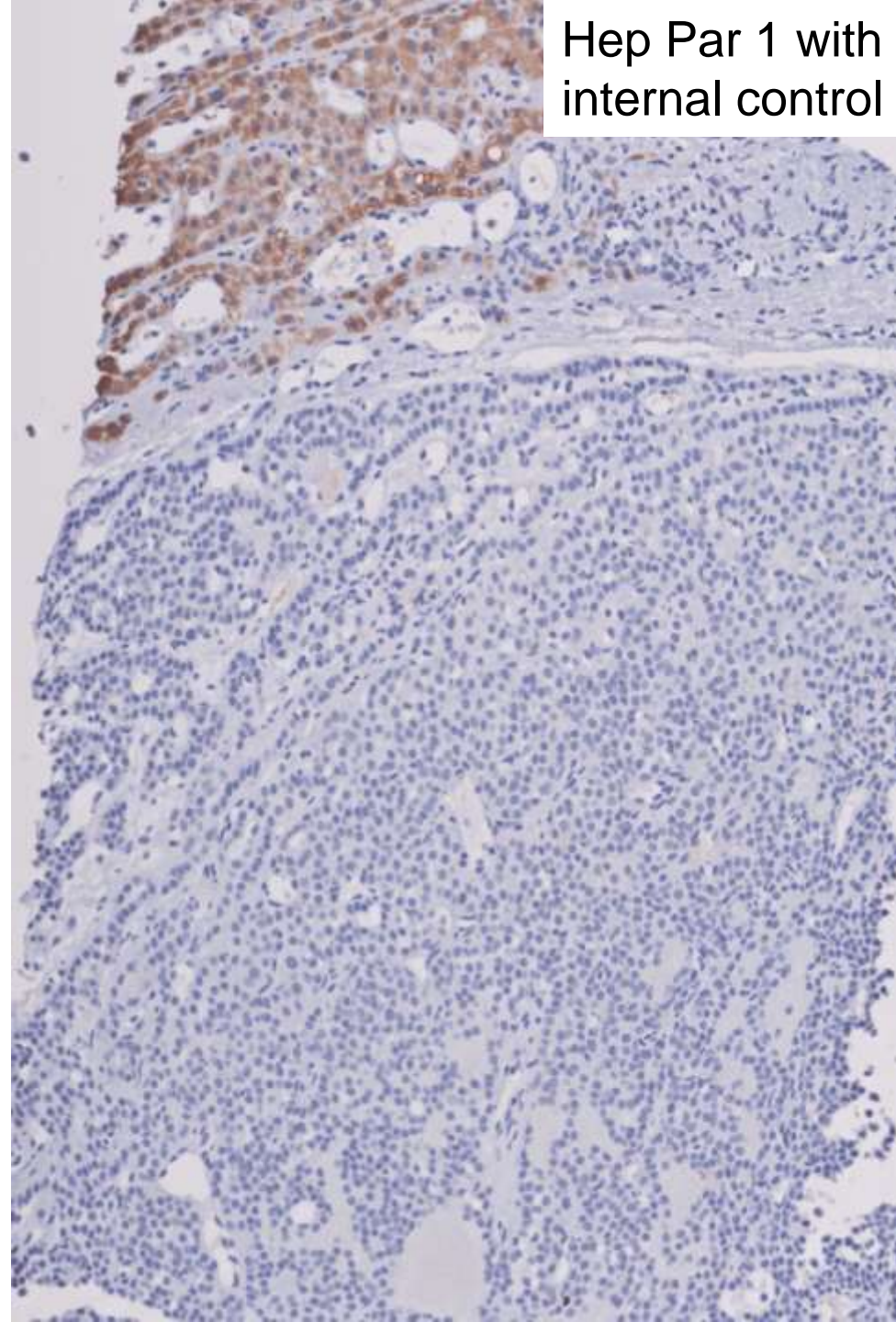
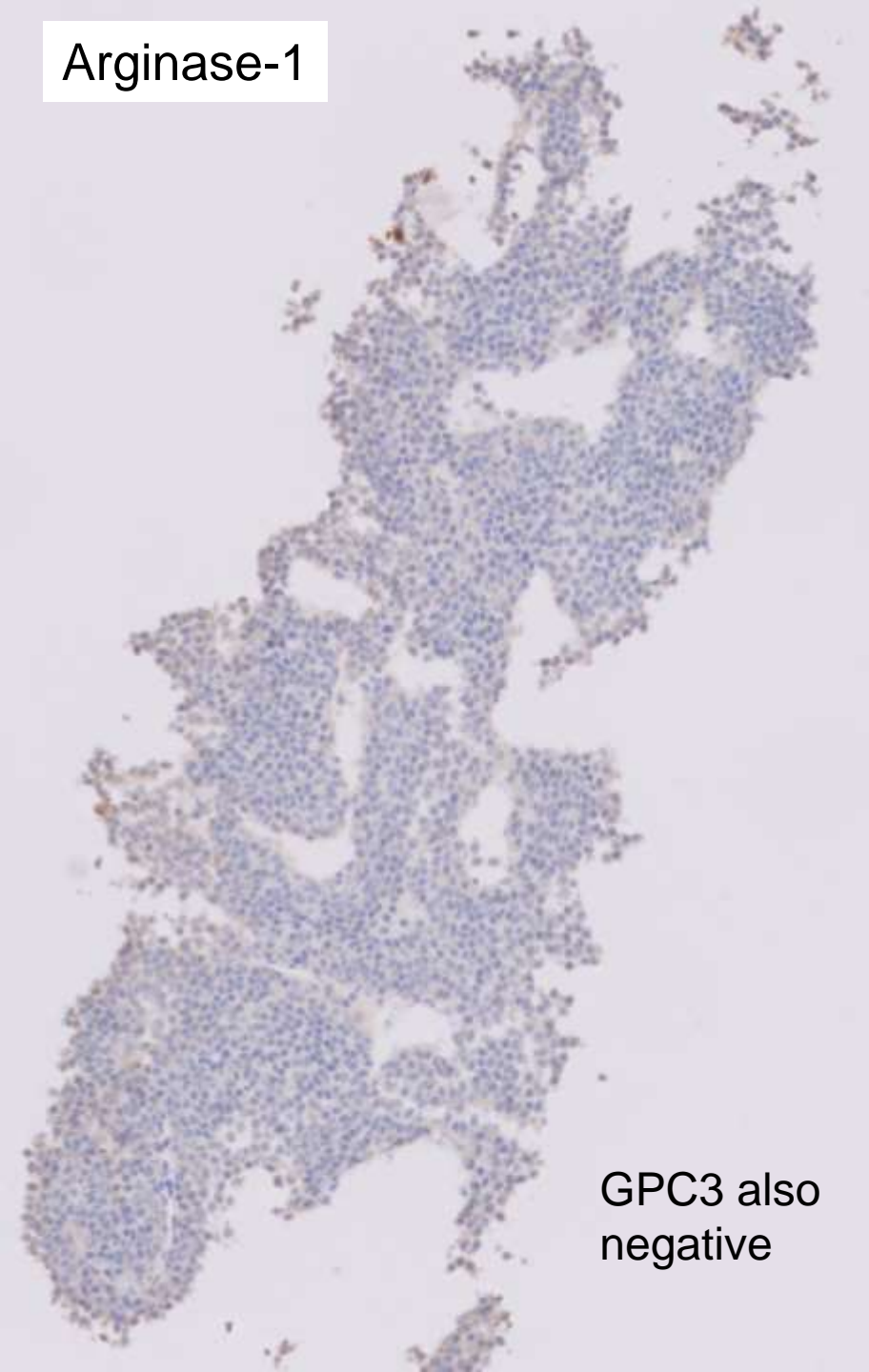
Albumin ISH



Arginase-1

GPC3 also
negative

Hep Par 1 with
internal control





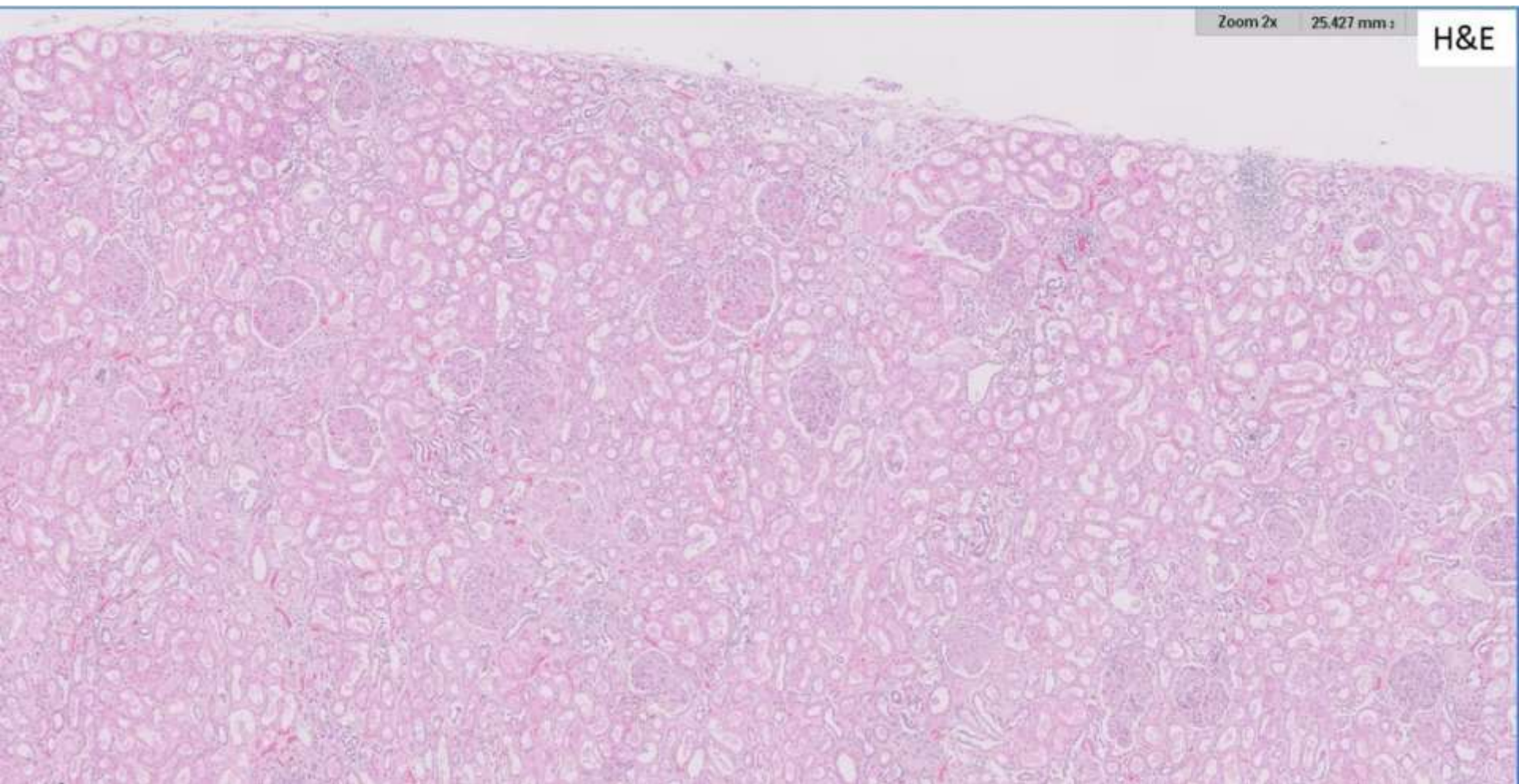
22-0104

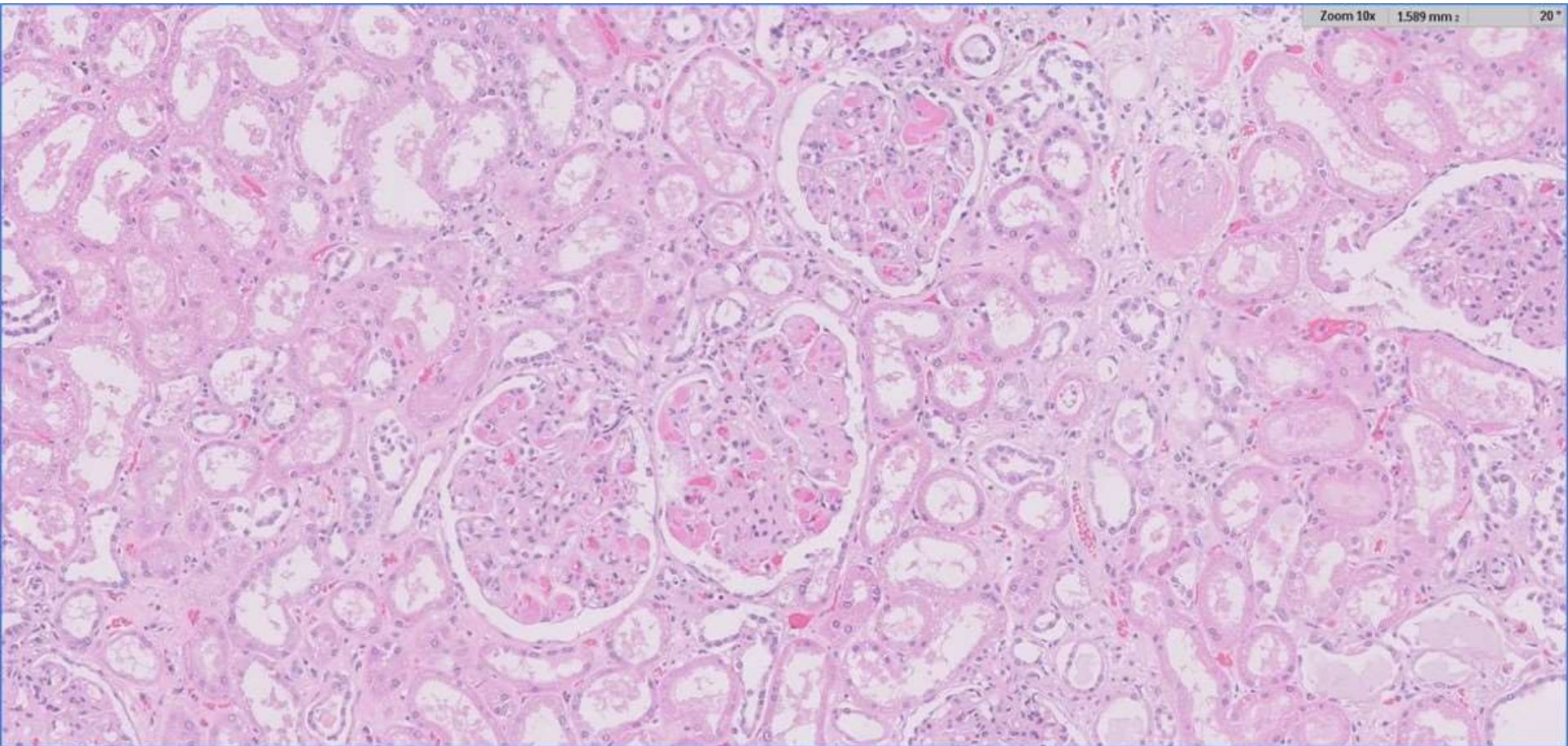
Alexandra Chang-Graham/Megan Troxell; Stanford

Elderly year-old woman with history of rheumatoid arthritis, on methotrexate, with months of abdominal pain. She developed a skin rash and presented to a hospital where she was determined to have new-onset acute renal failure requiring dialysis. She developed pancytopenia and acute hypoxic respiratory failure. Her status declined and she passed away.

Zoom 2x 25.427 mm:

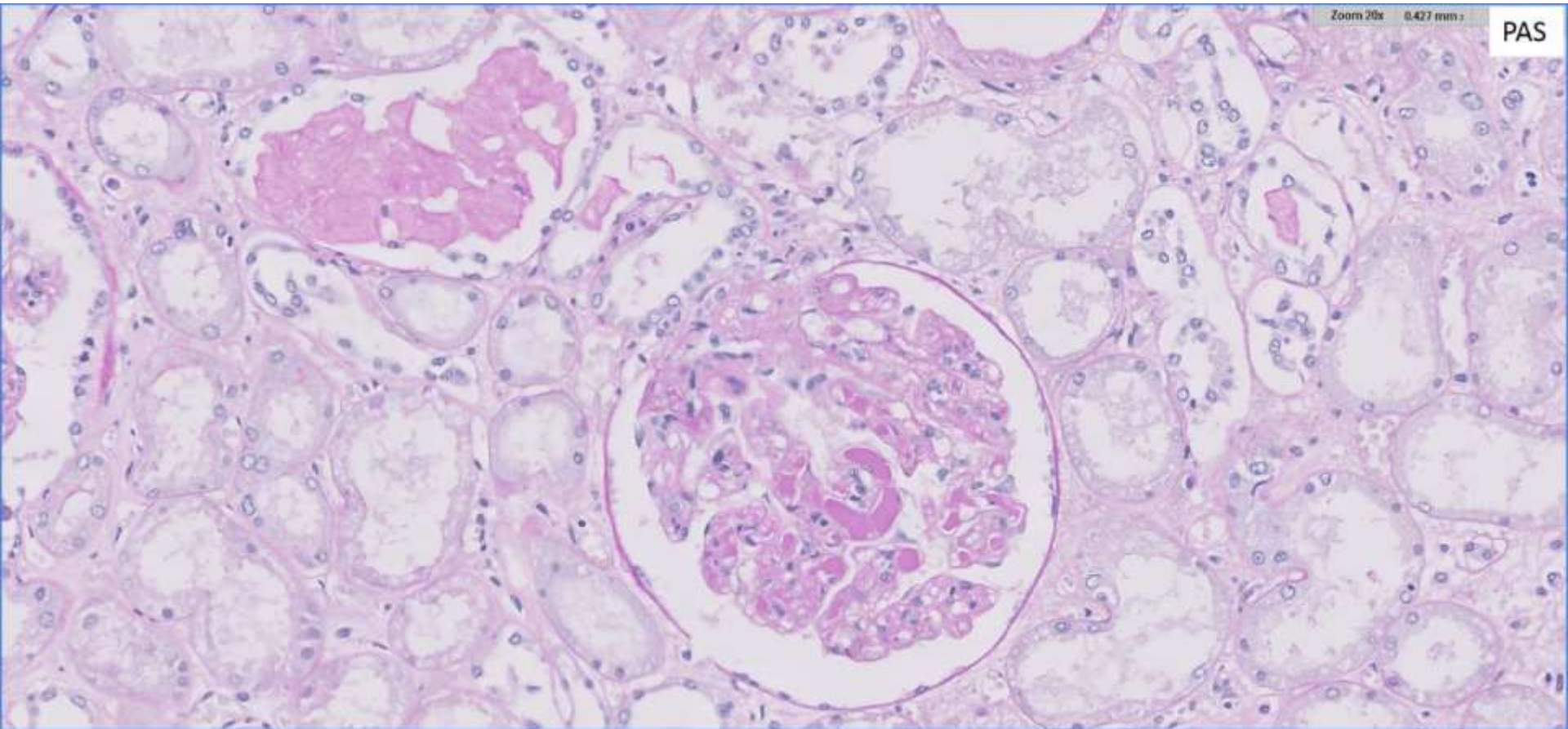
H&E





Zoom 20x 0.427 mm

PAS

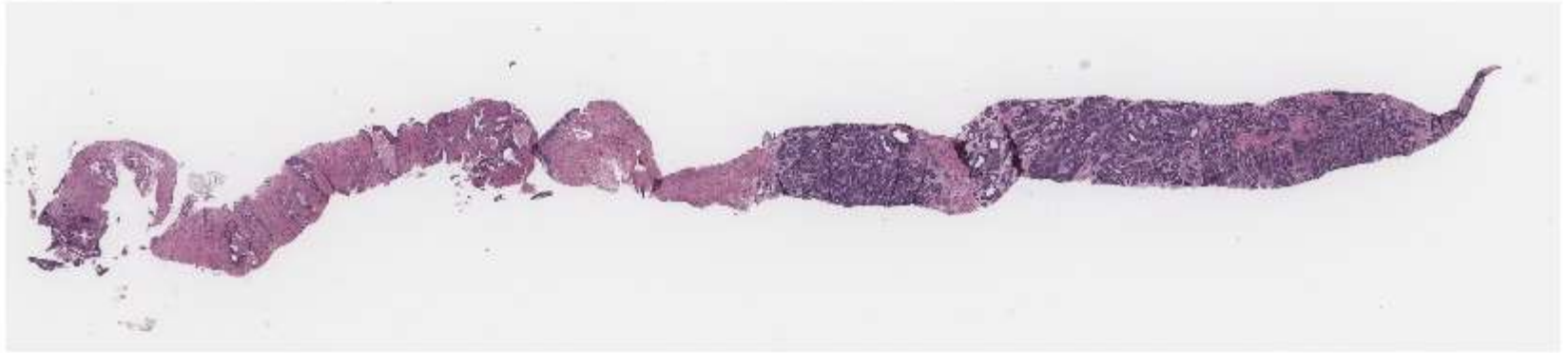


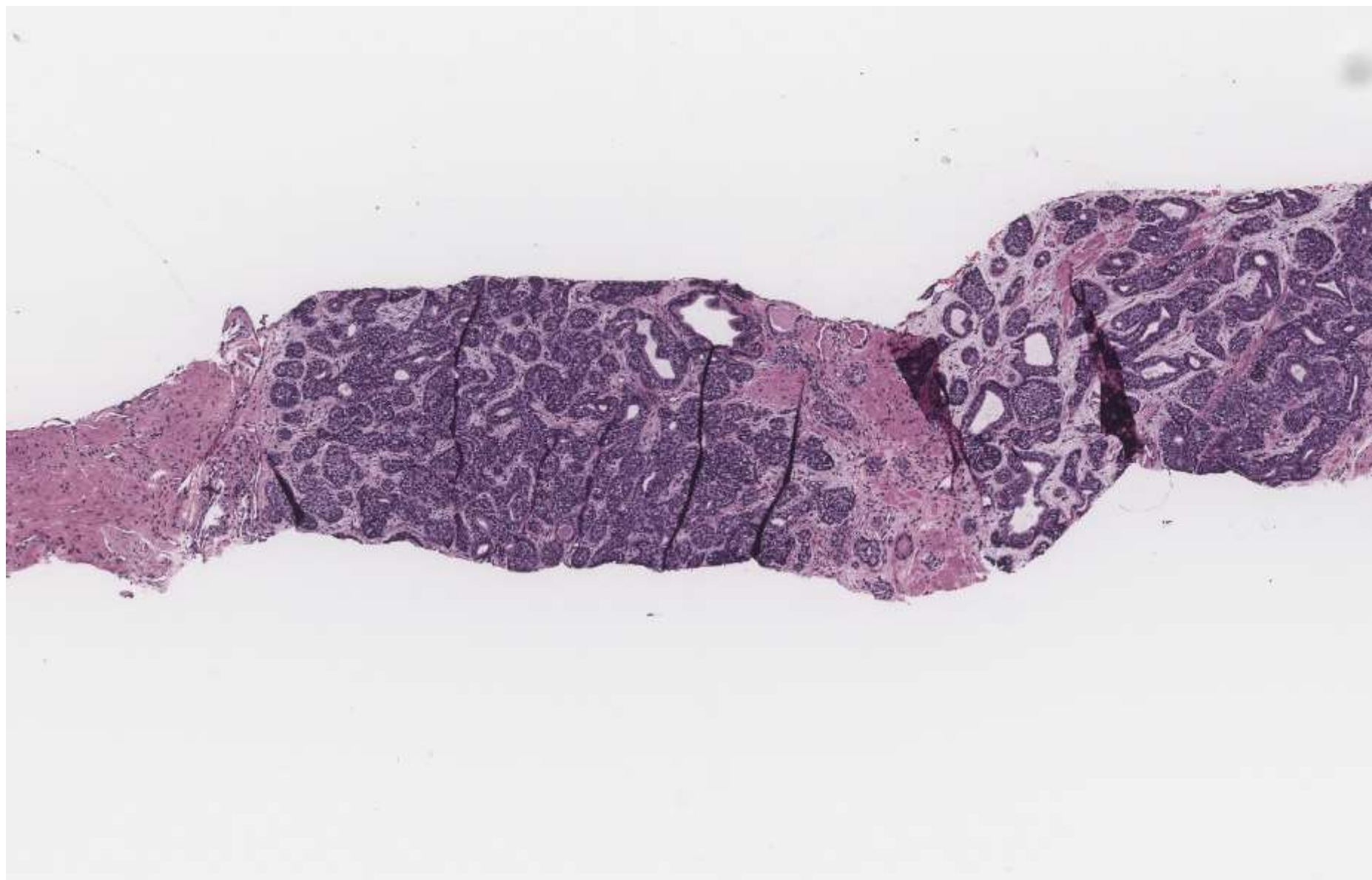

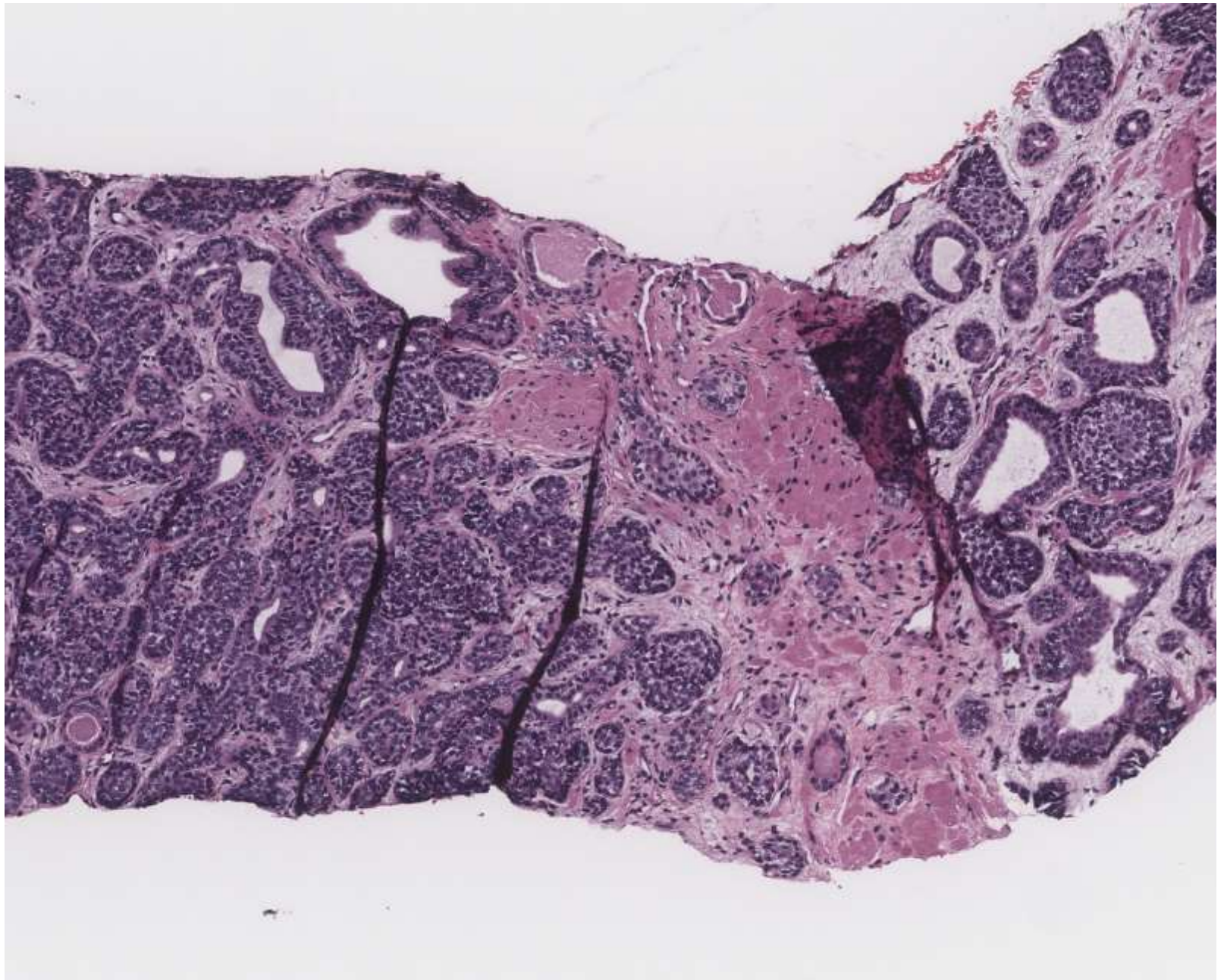
22-0105

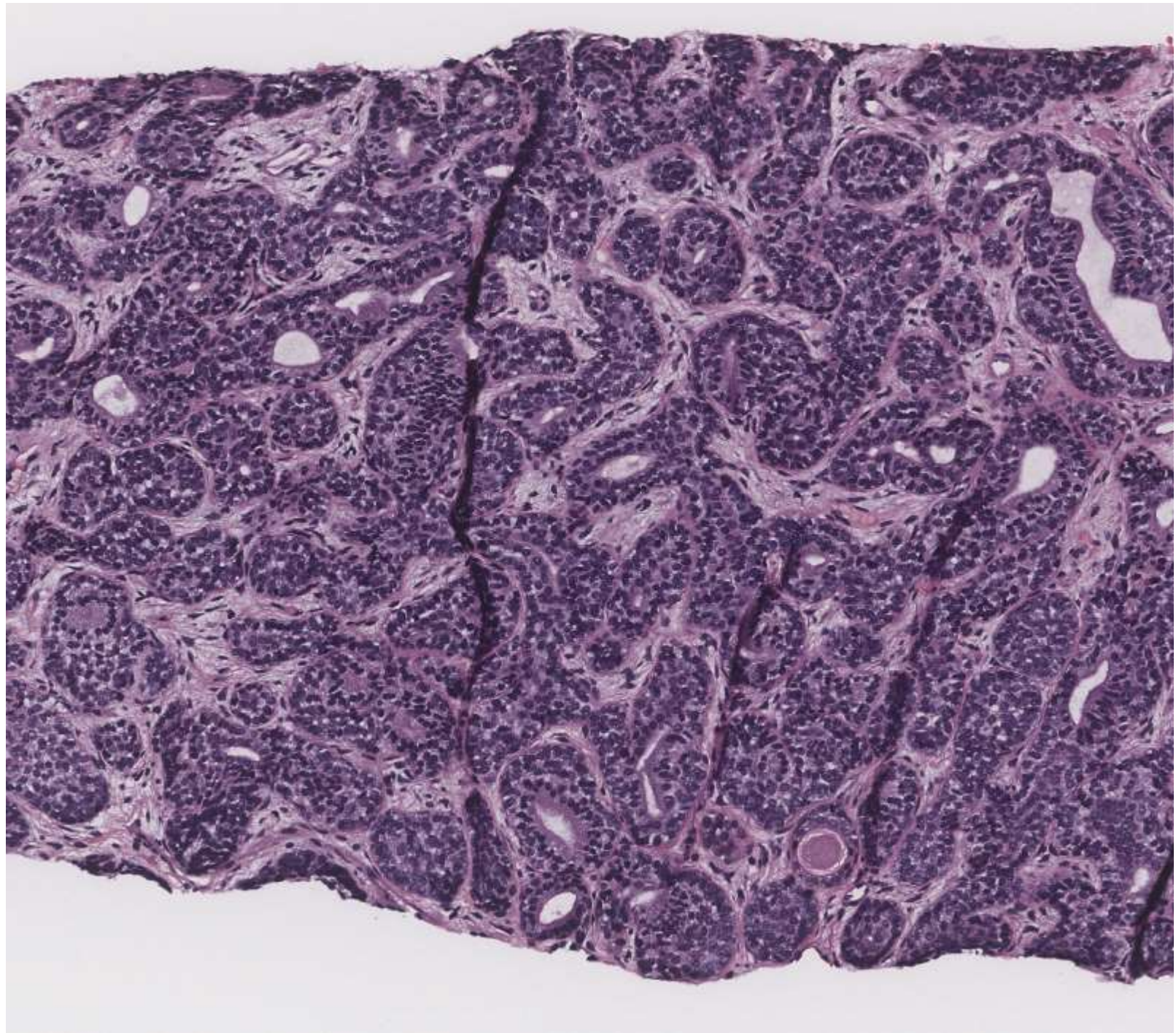
Chien-Kuang Ding/Zhen Yan/Emily Chan; UCSF

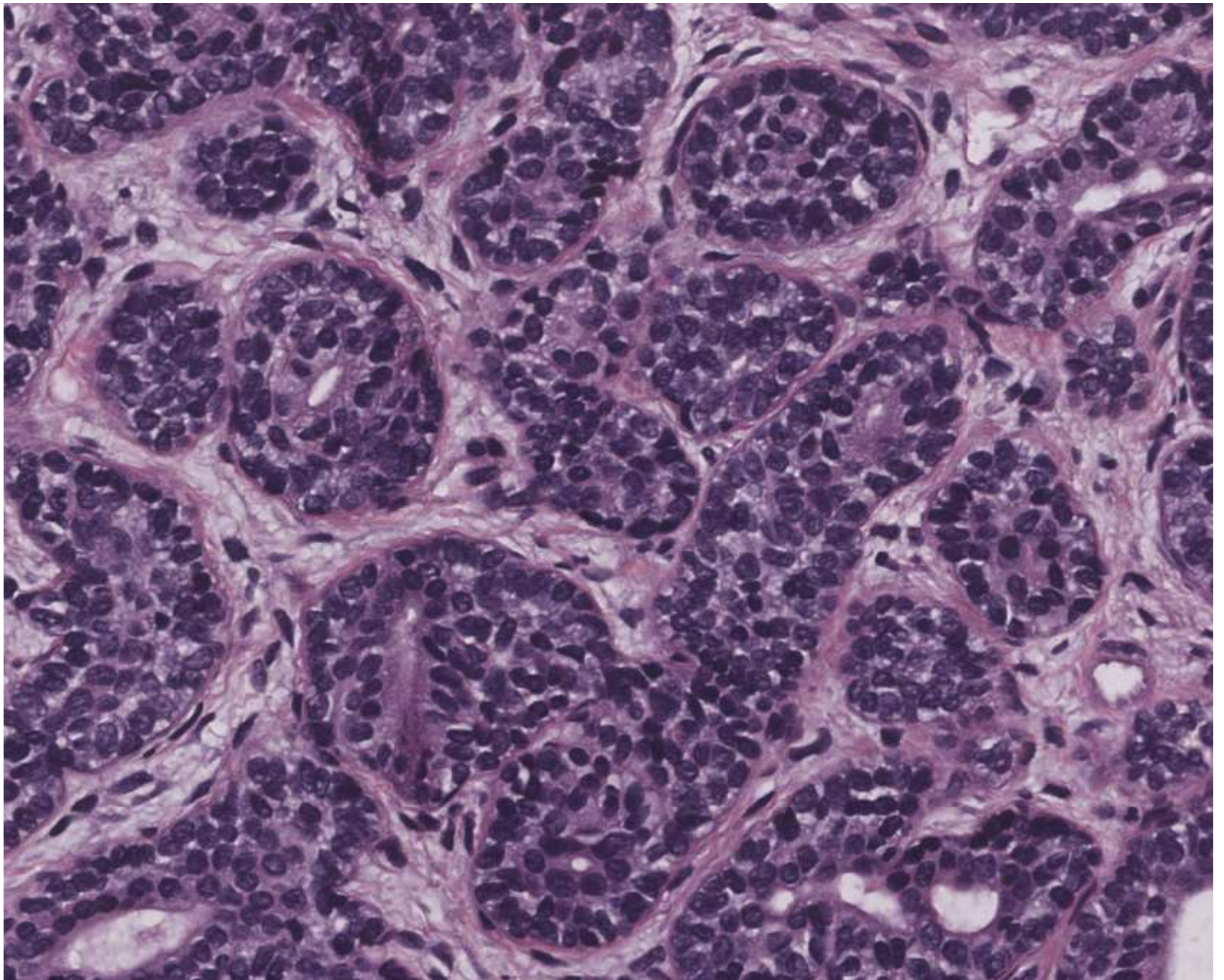
Adult M with elevated PSA, undergoes prostate biopsy.

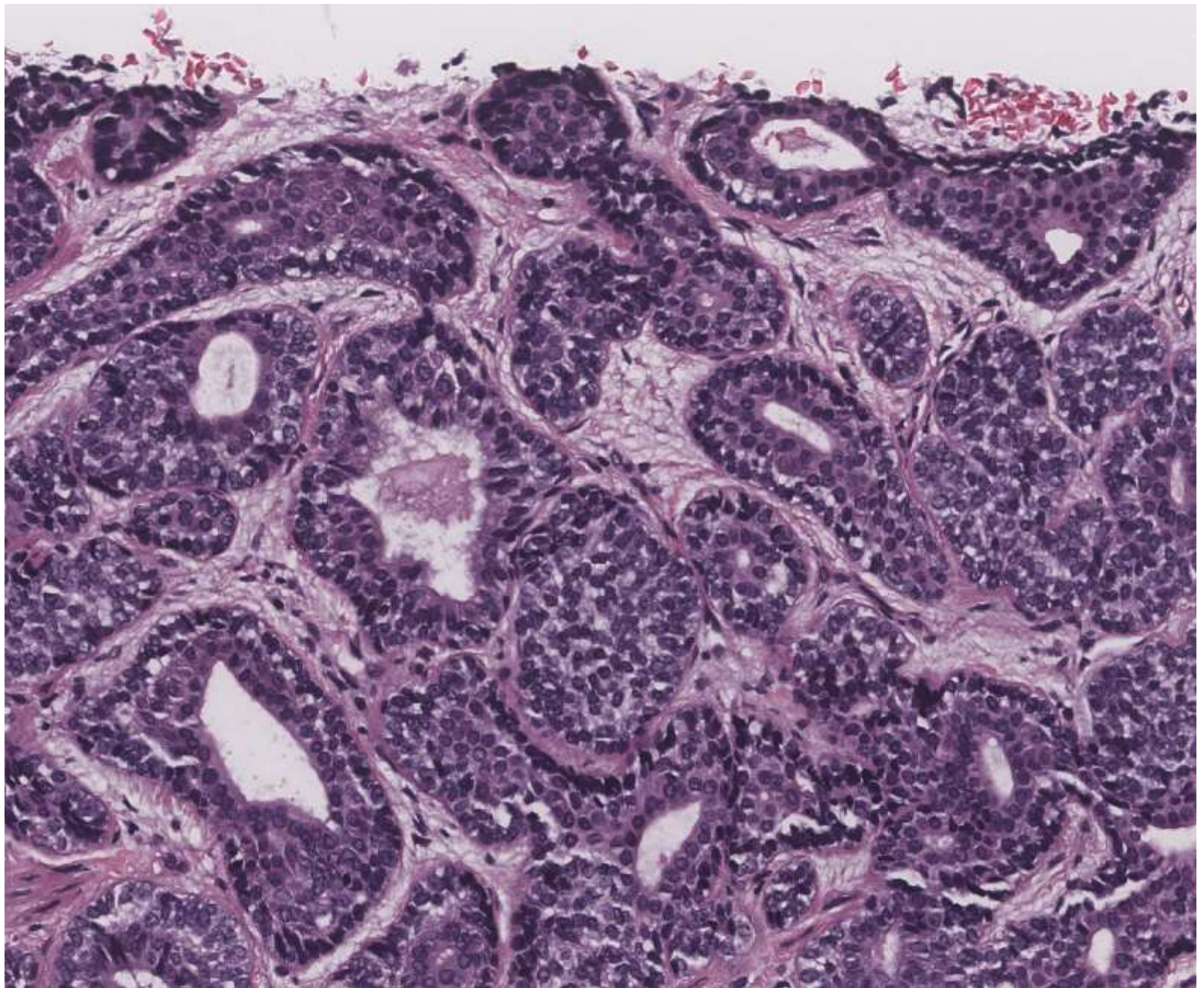














22-0106

Jeffrey Nirschl/Hannes Vogel; Stanford

60-year-old M with hypertension and T2DM who presented with acute-onset left-sided right gaze palsy and lip smacking. Brain MRI showed extra-dural based mass measuring 3.1cm.

Case History

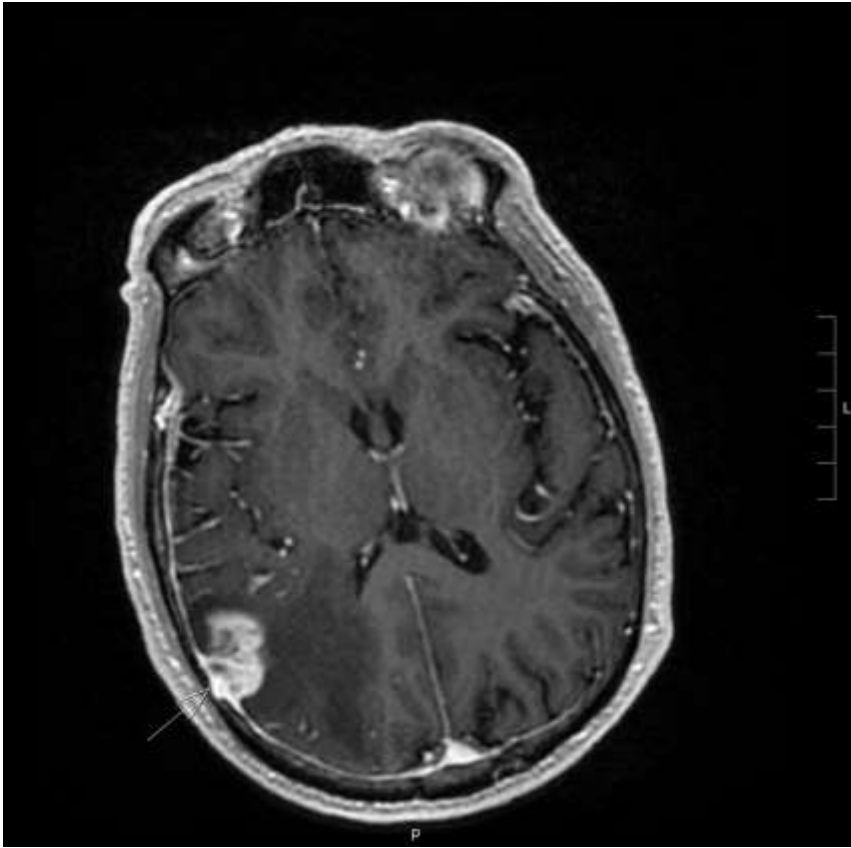
~60-year-old male with hypertension and T2DM who presented with acute-onset left sided, right gaze palsy, and lip smacking

- **Imaging data:**

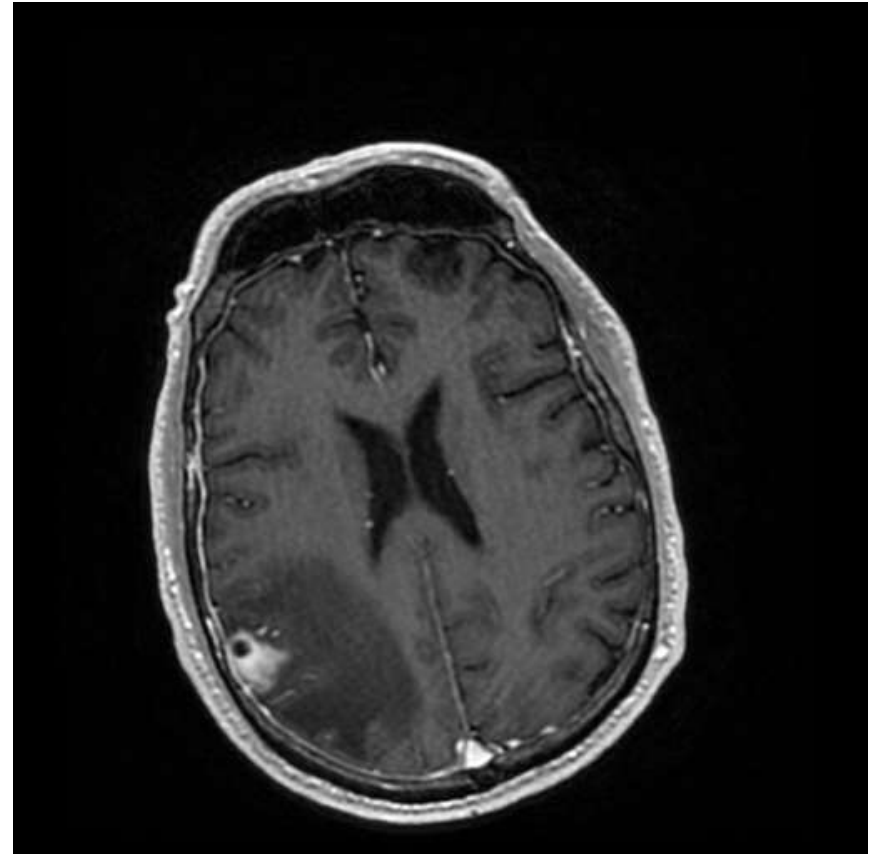
- › **Brain MRI:**

- › Heterogeneously enhancing with irregular margins
 - › Extra-axial dural-based mass with intraparenchymal extension versus a parenchymal intra-axial lesion invading the dura
 - › Located at the right parietal/parieto-occipital junction
 - › Measuring 3.1 x 1.8 x 3.7 cm

Brain MRI

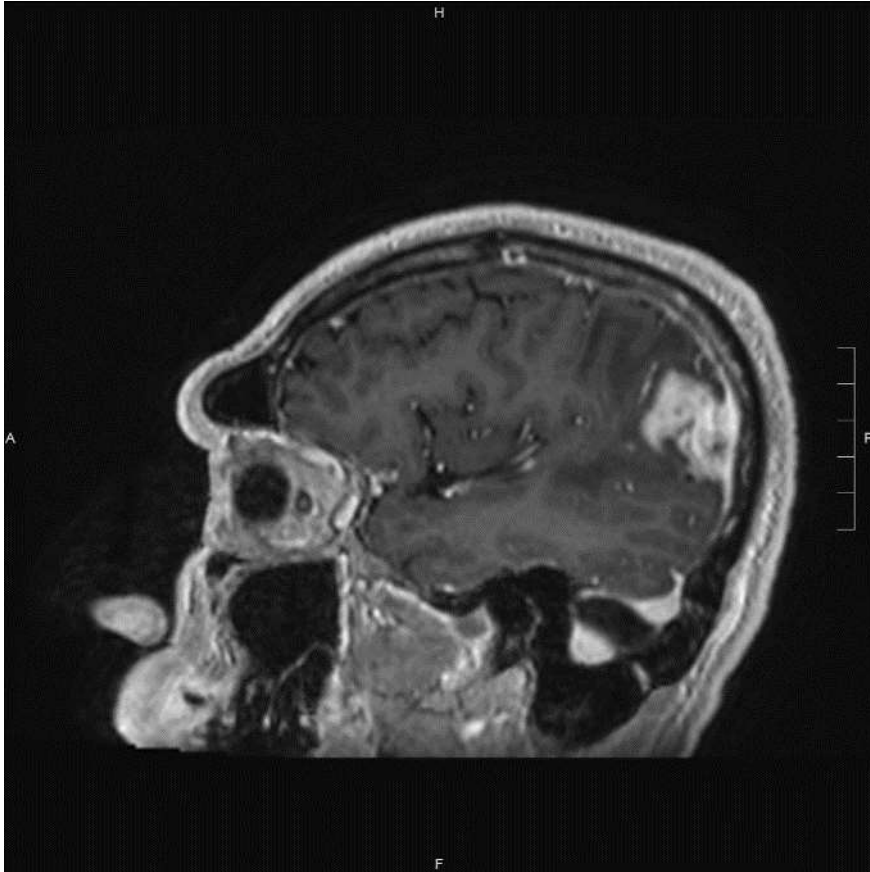


Axial T1 w/contrast

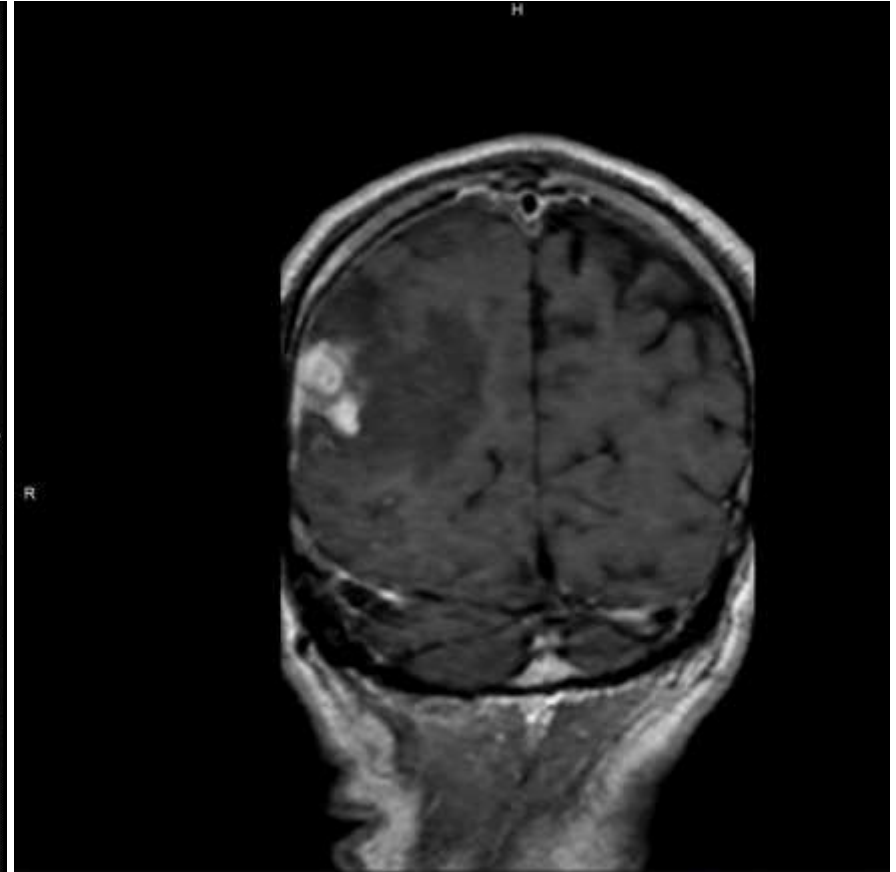


Axial T1 w/contrast

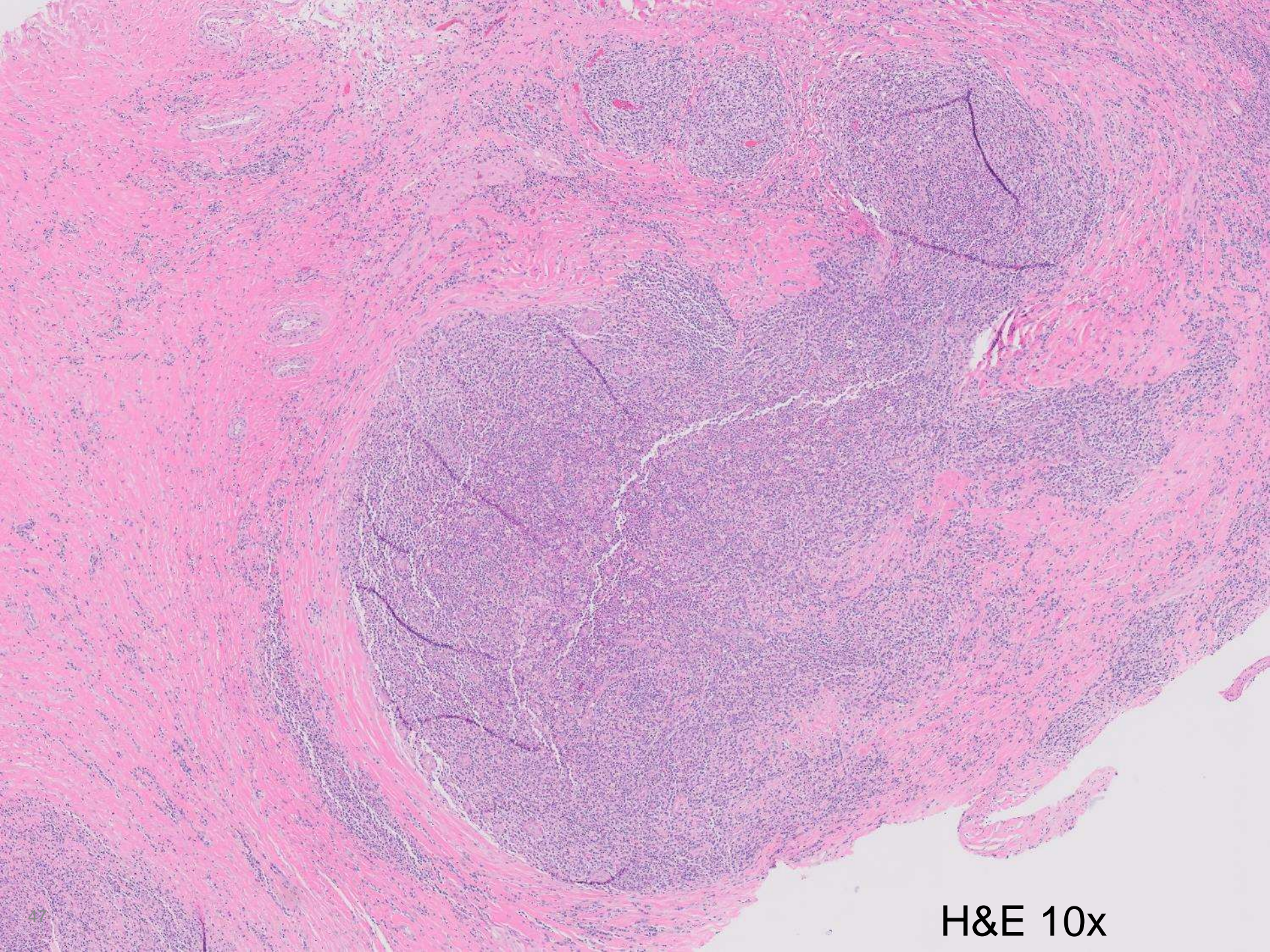
Brain MRI



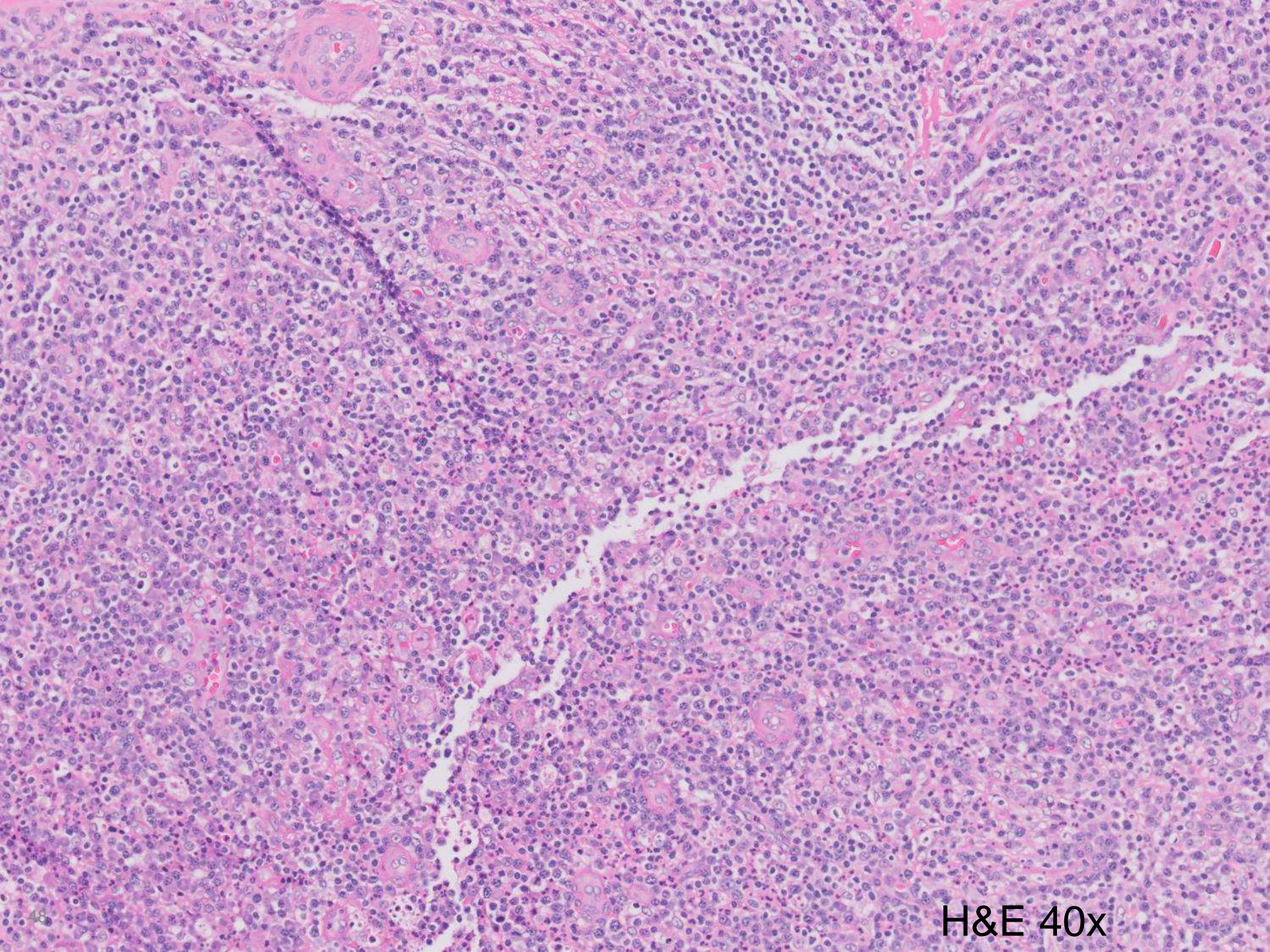
Sagittal T1 FLAIR



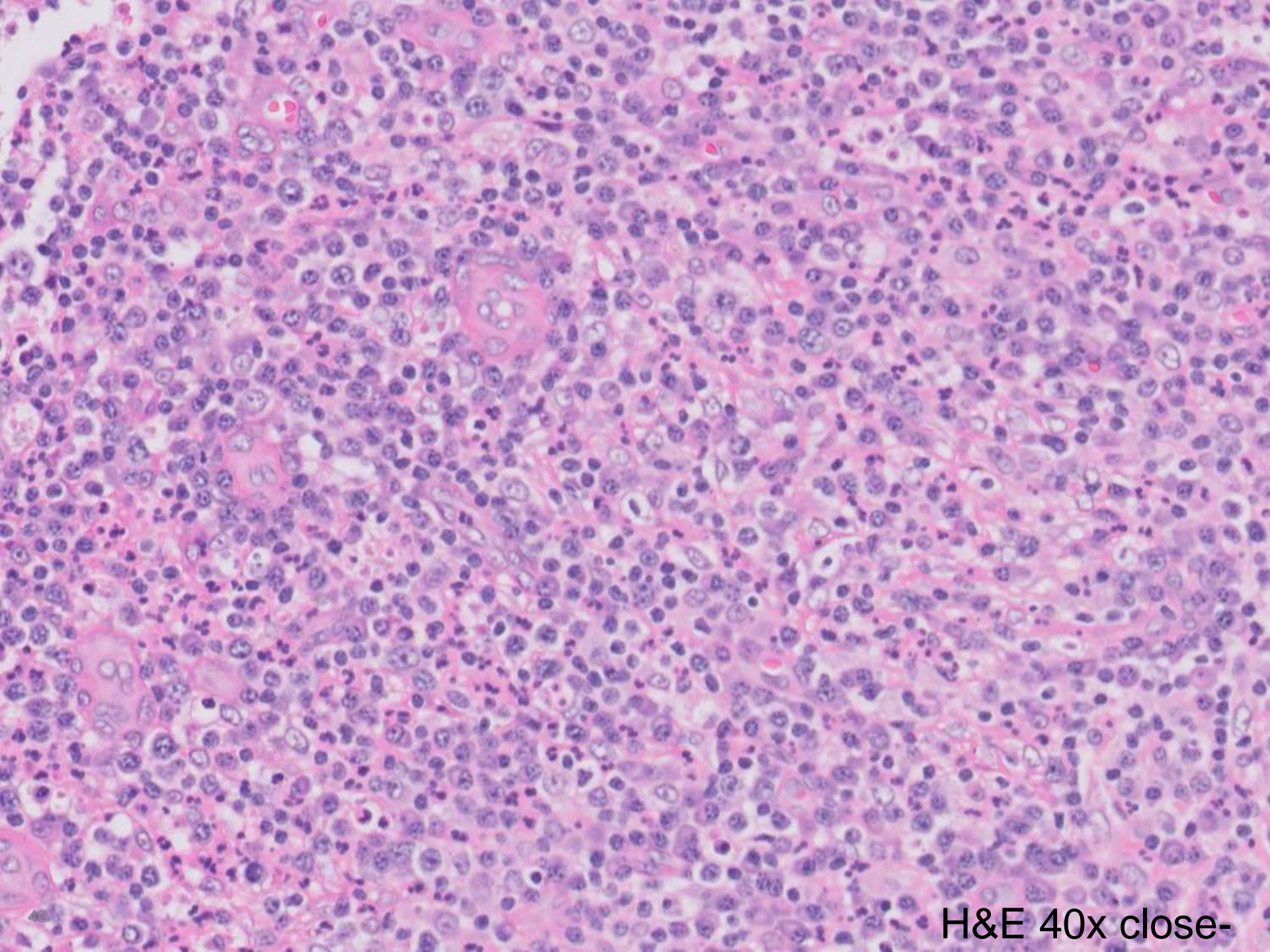
Coronal w/contrast



H&E 10x



H&E 40x





22-0107
scanned slide avail!

Ankur Sangoi; El Camino Hospital

50-year-old M with renal mass, radical nephrectomy
performed.

