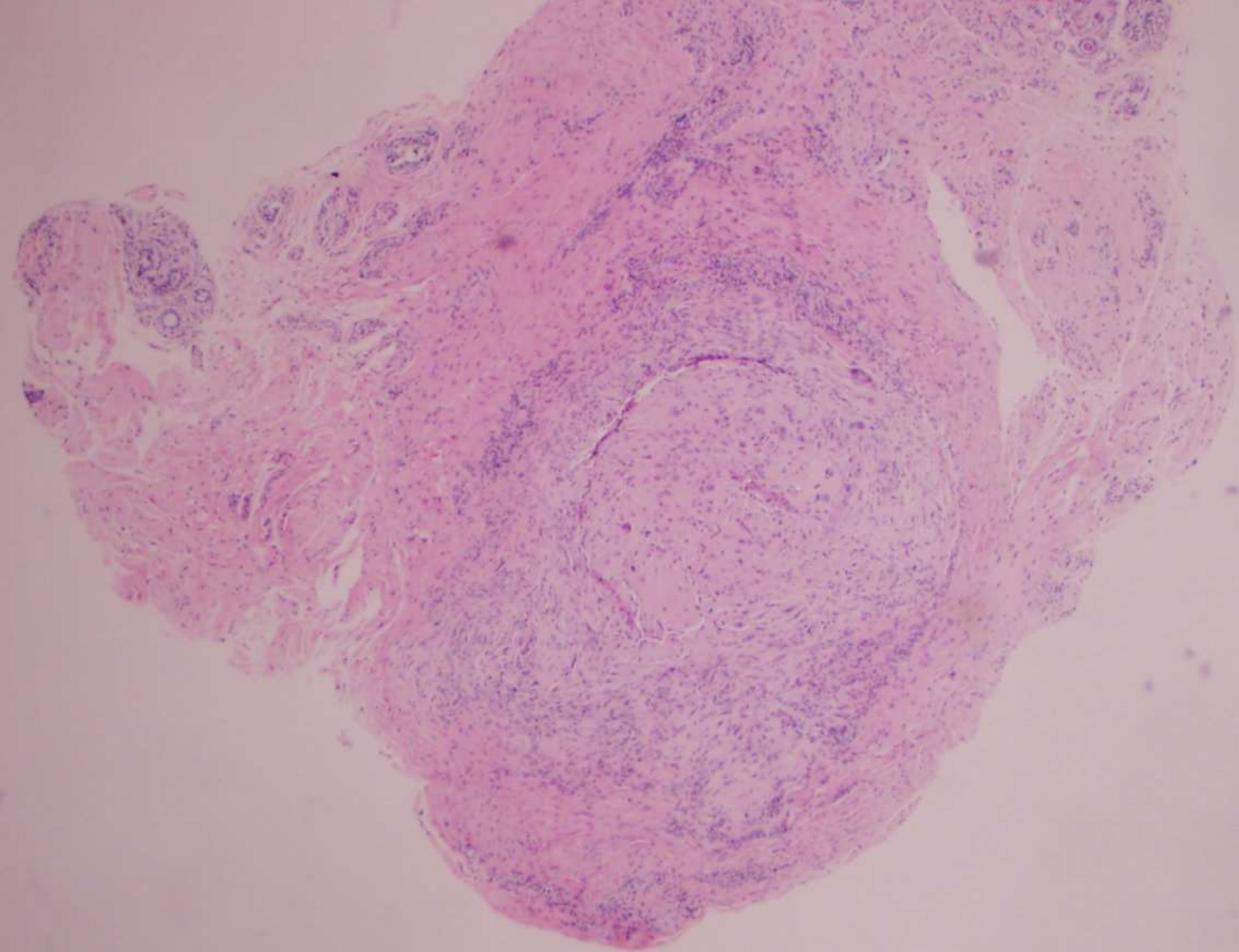
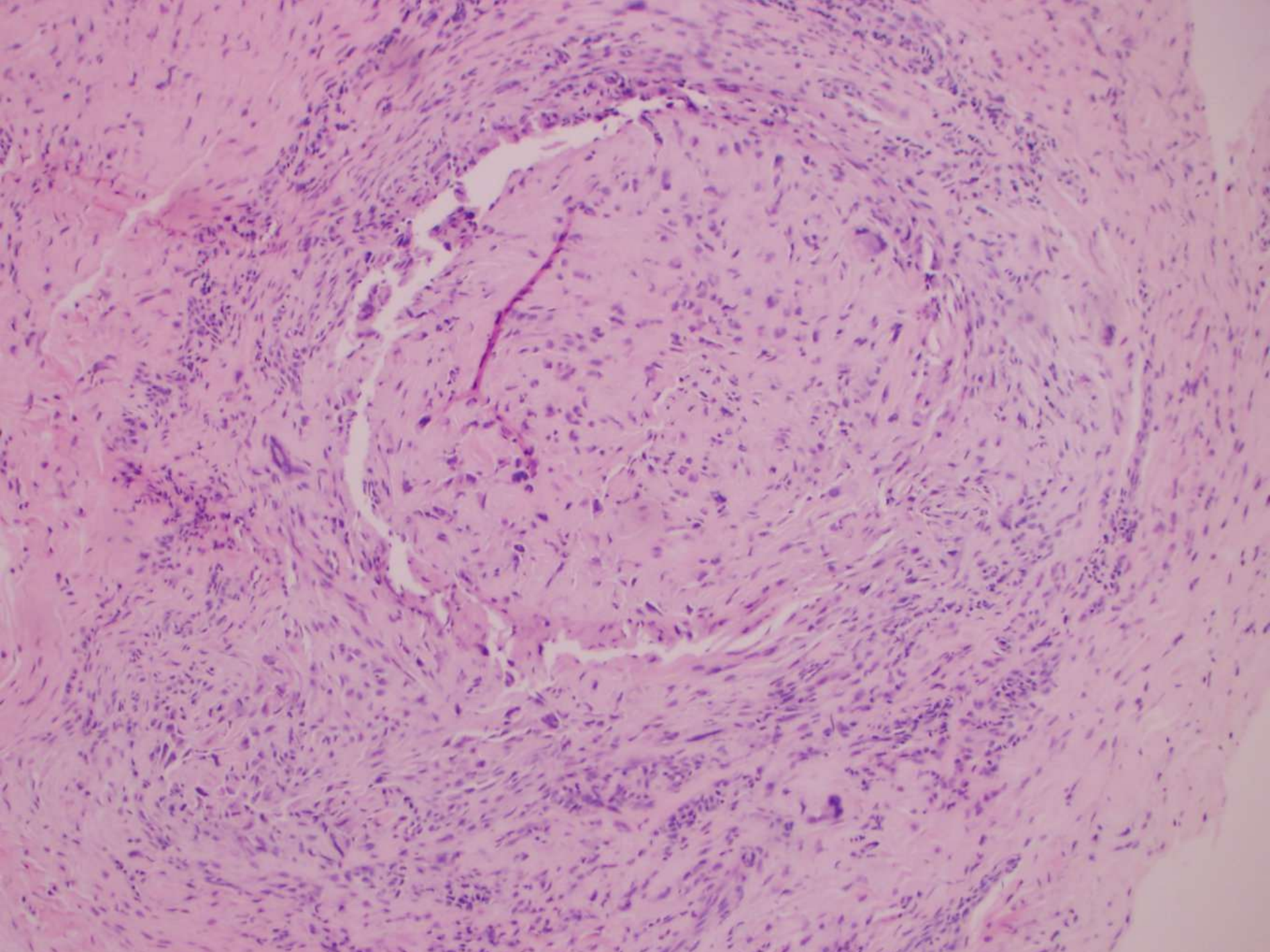


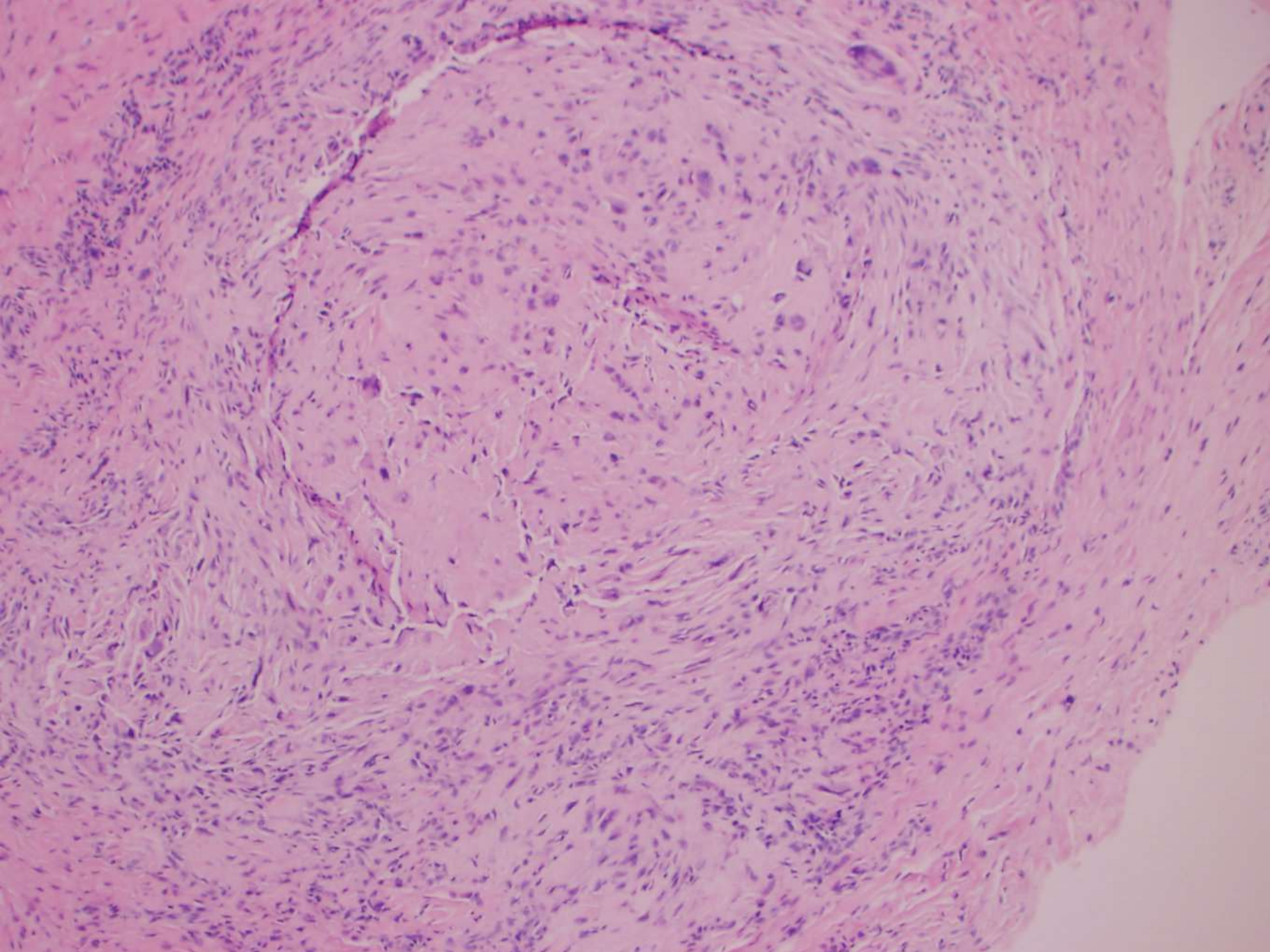
21-1101

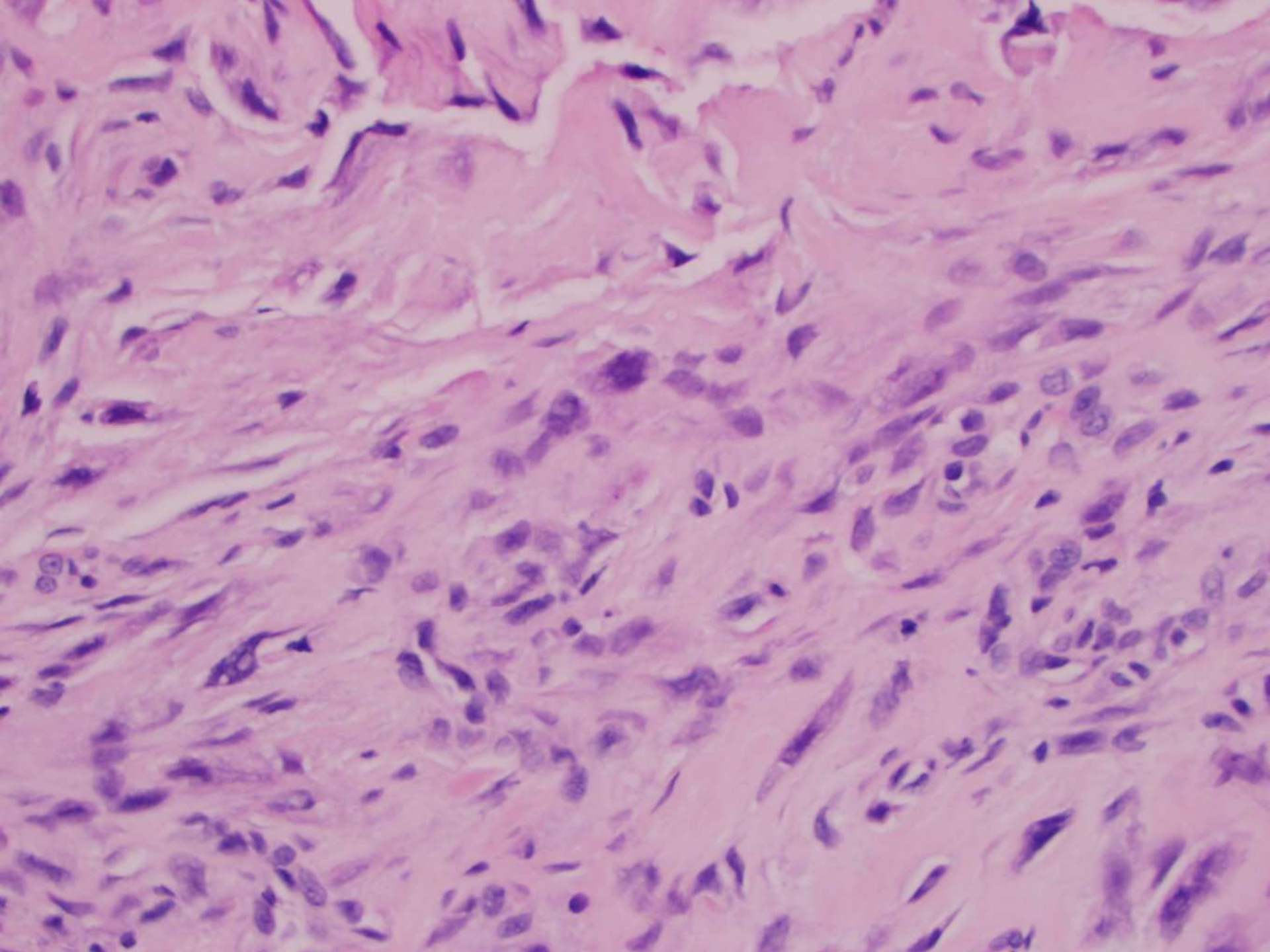
Greg Rumore; Kaiser Diablo

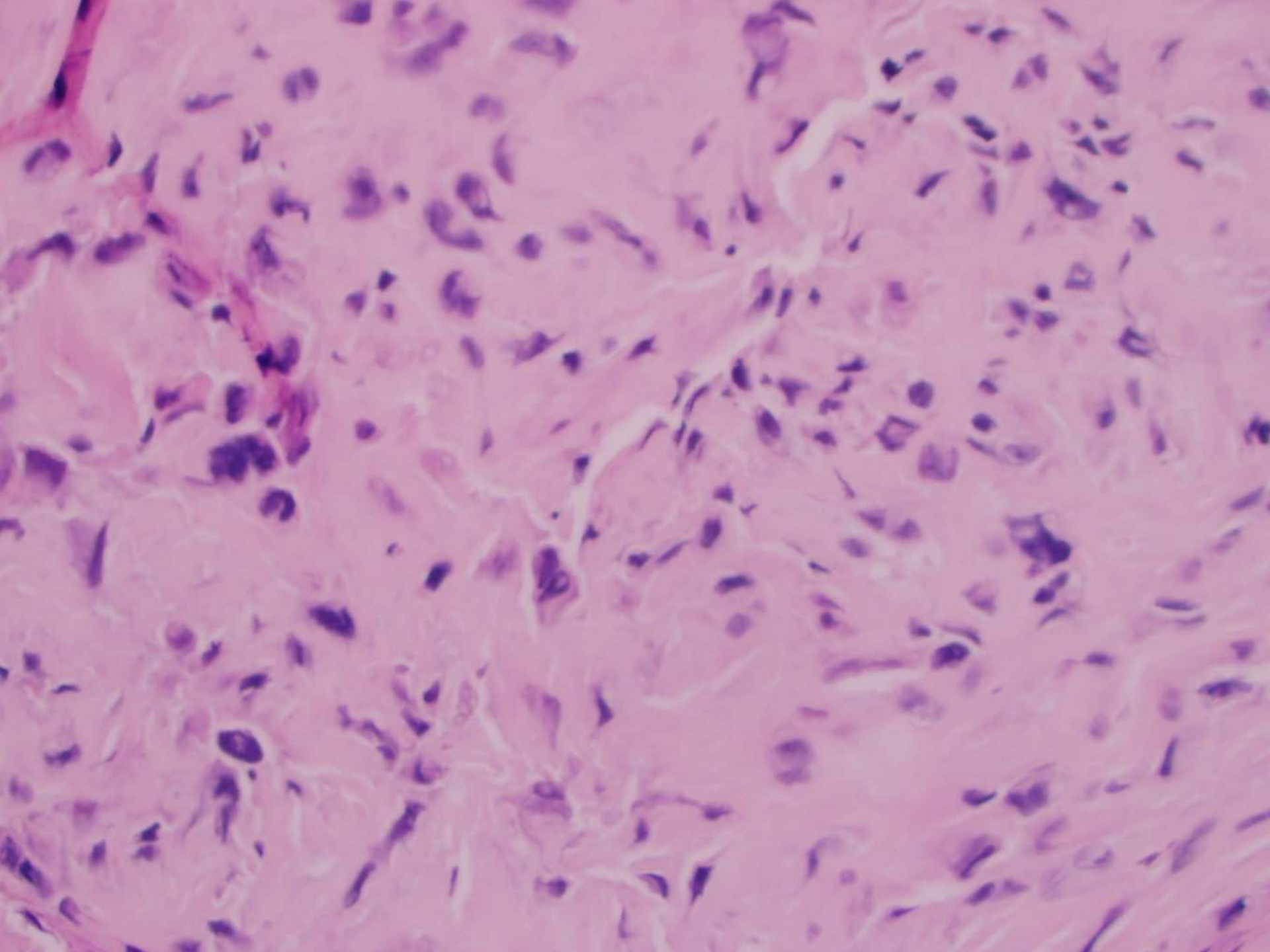
56-year-old F with finger mass for several months.

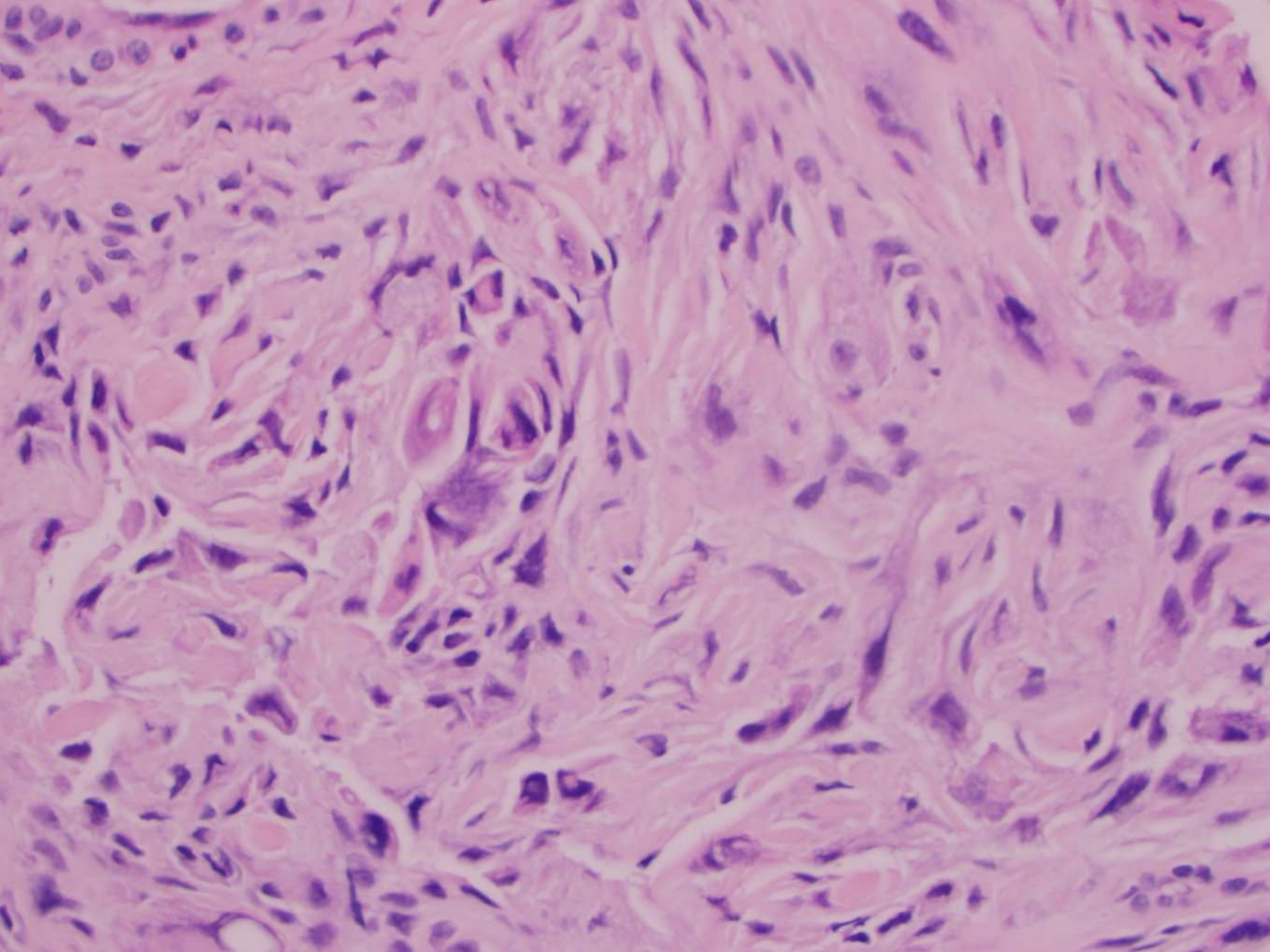












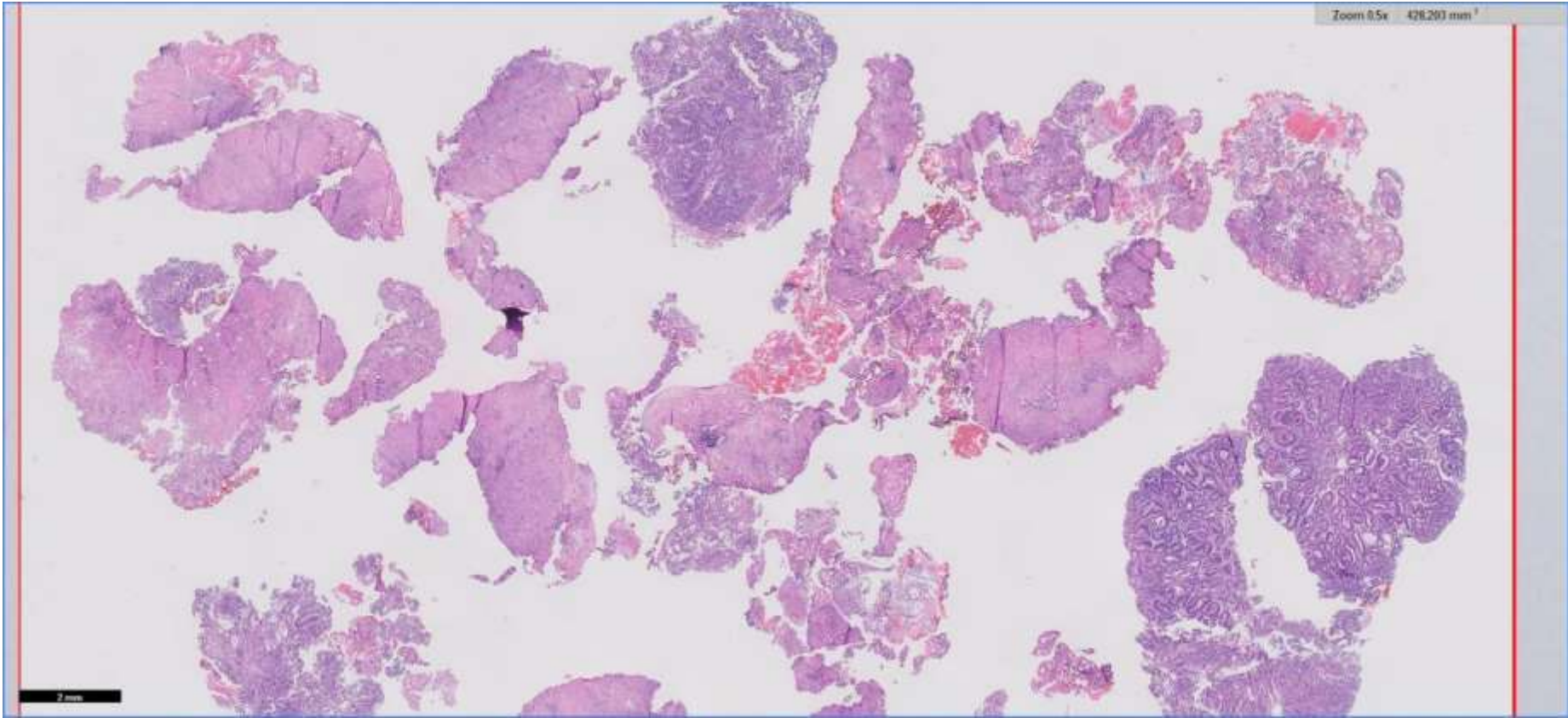


21-1002

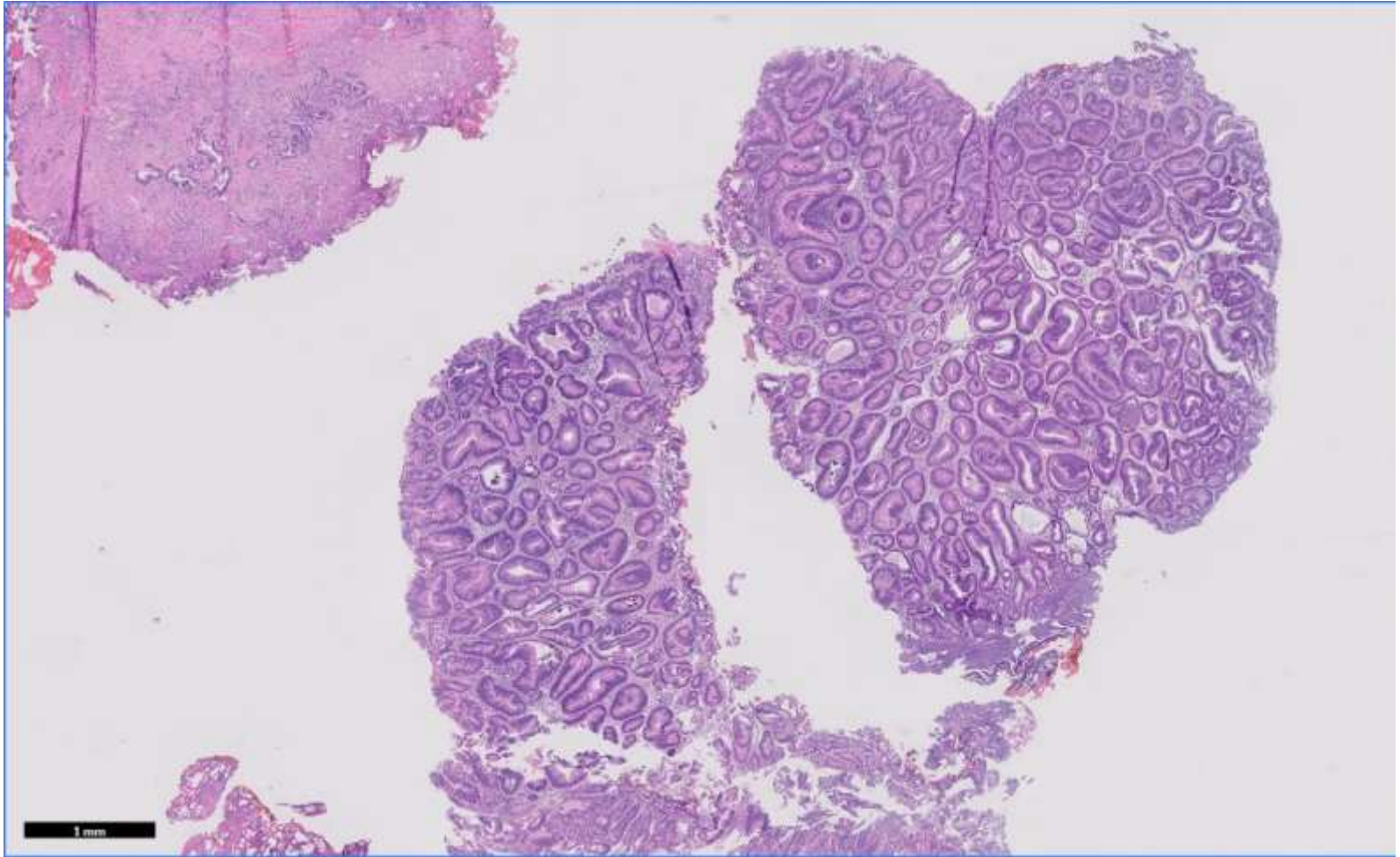
Osama Khan/Ali Lowe; Stanford

67-year-old F with bladder dome tumor.

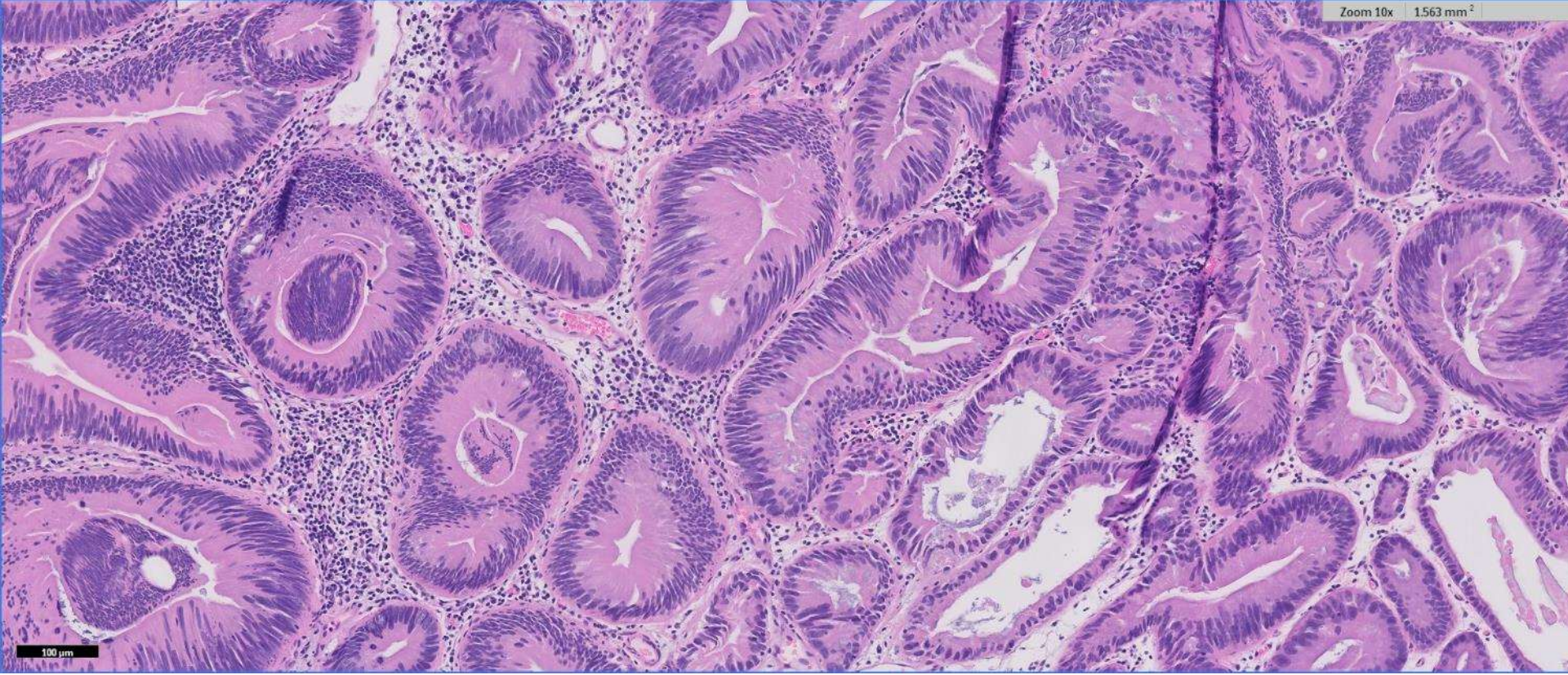
Zoom 0.5x 426203 mm²



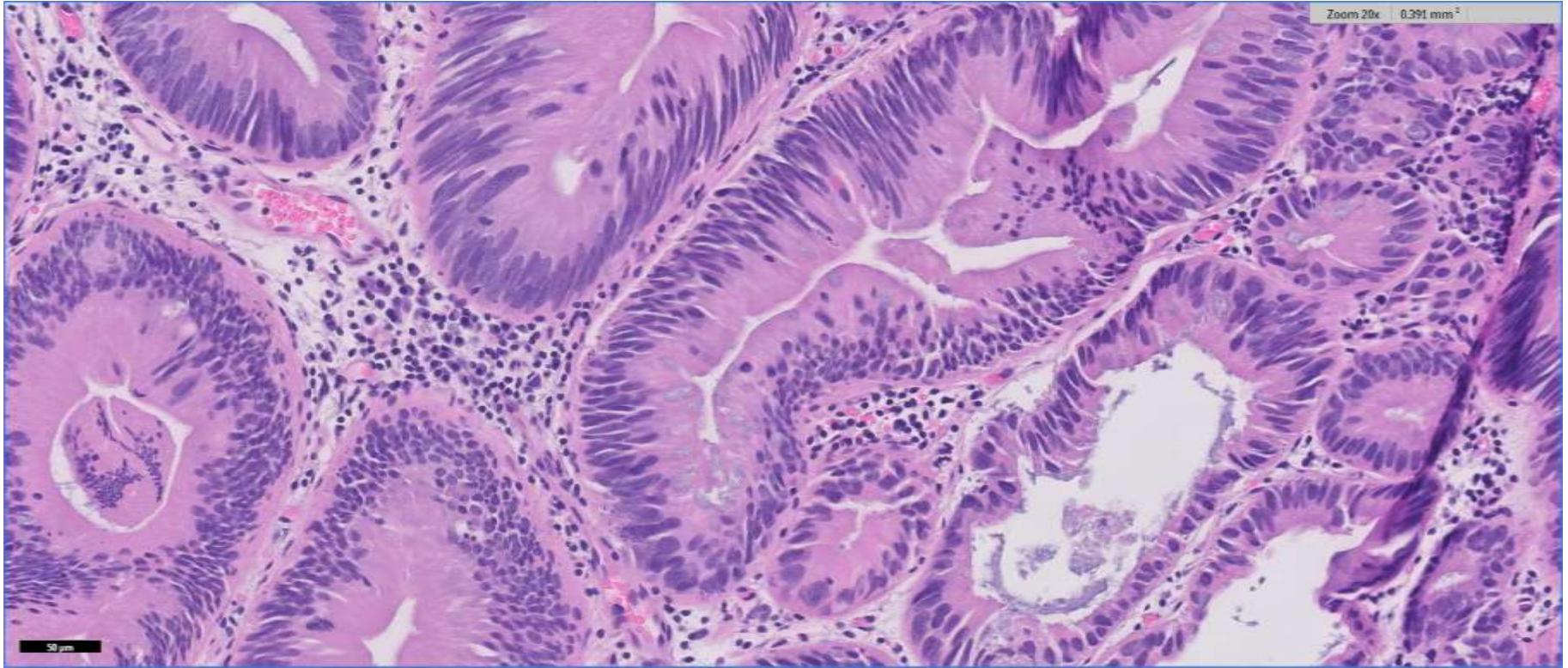
2 mm

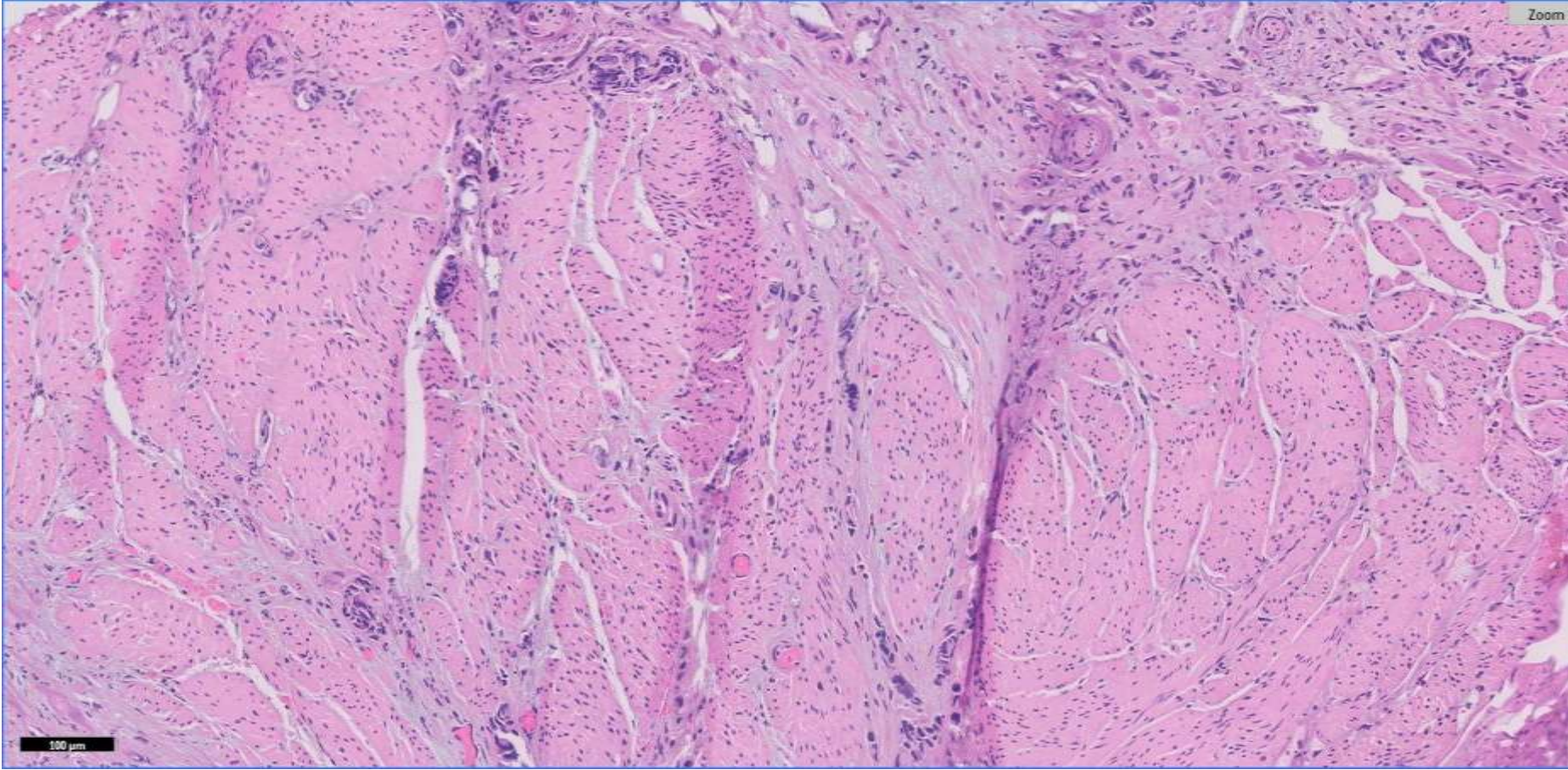


Zoom 10x 1.563 mm²



100 μ m



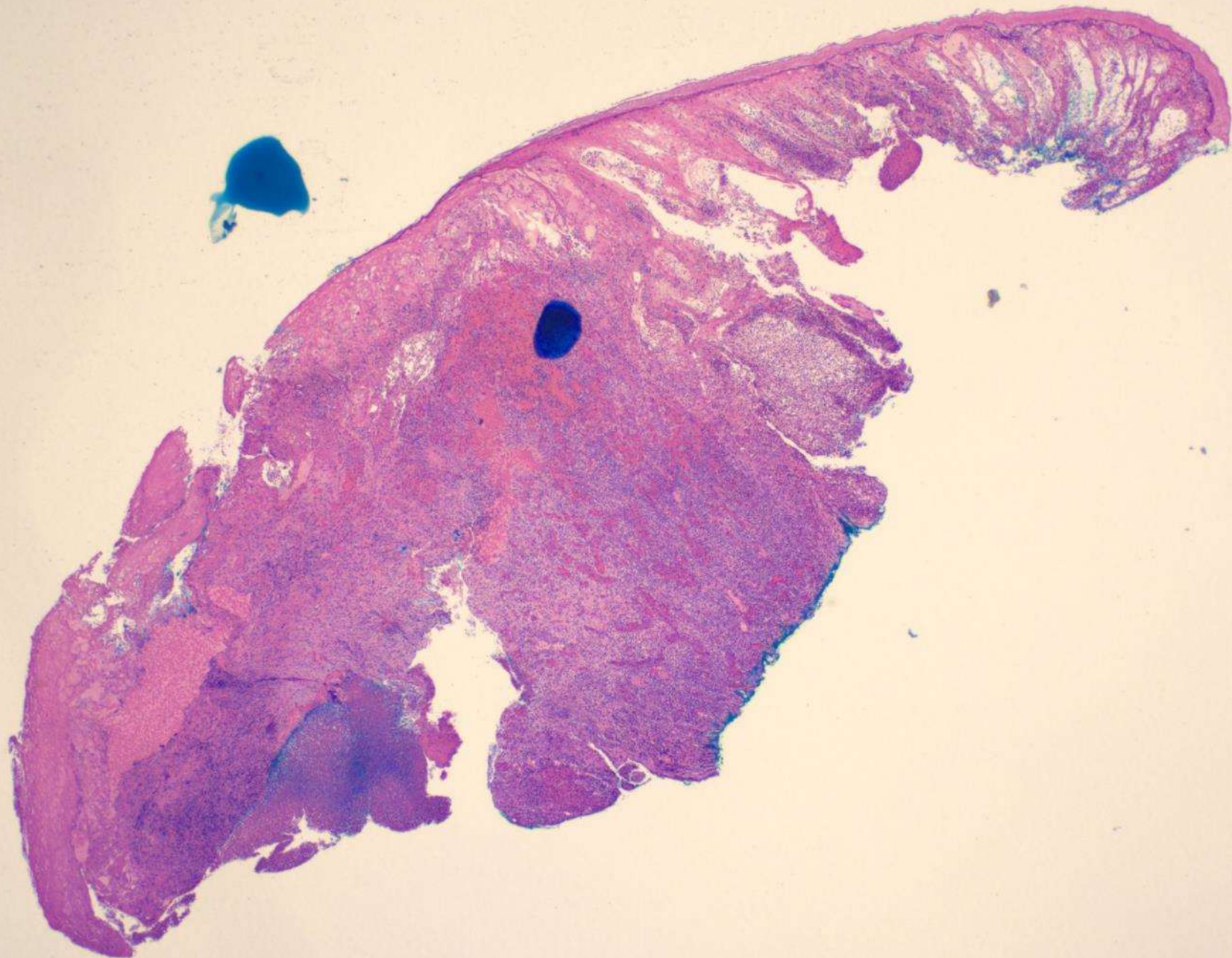


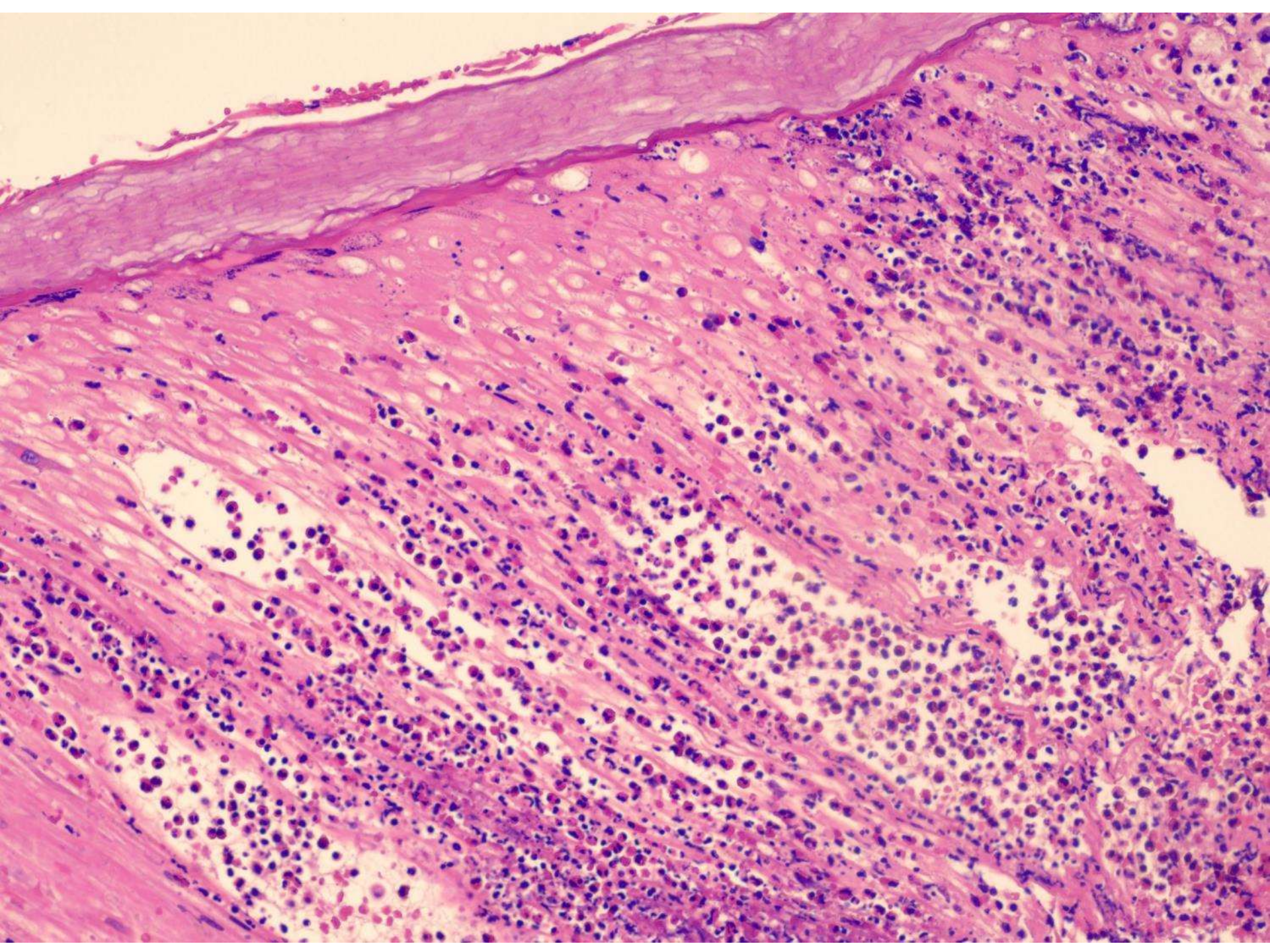


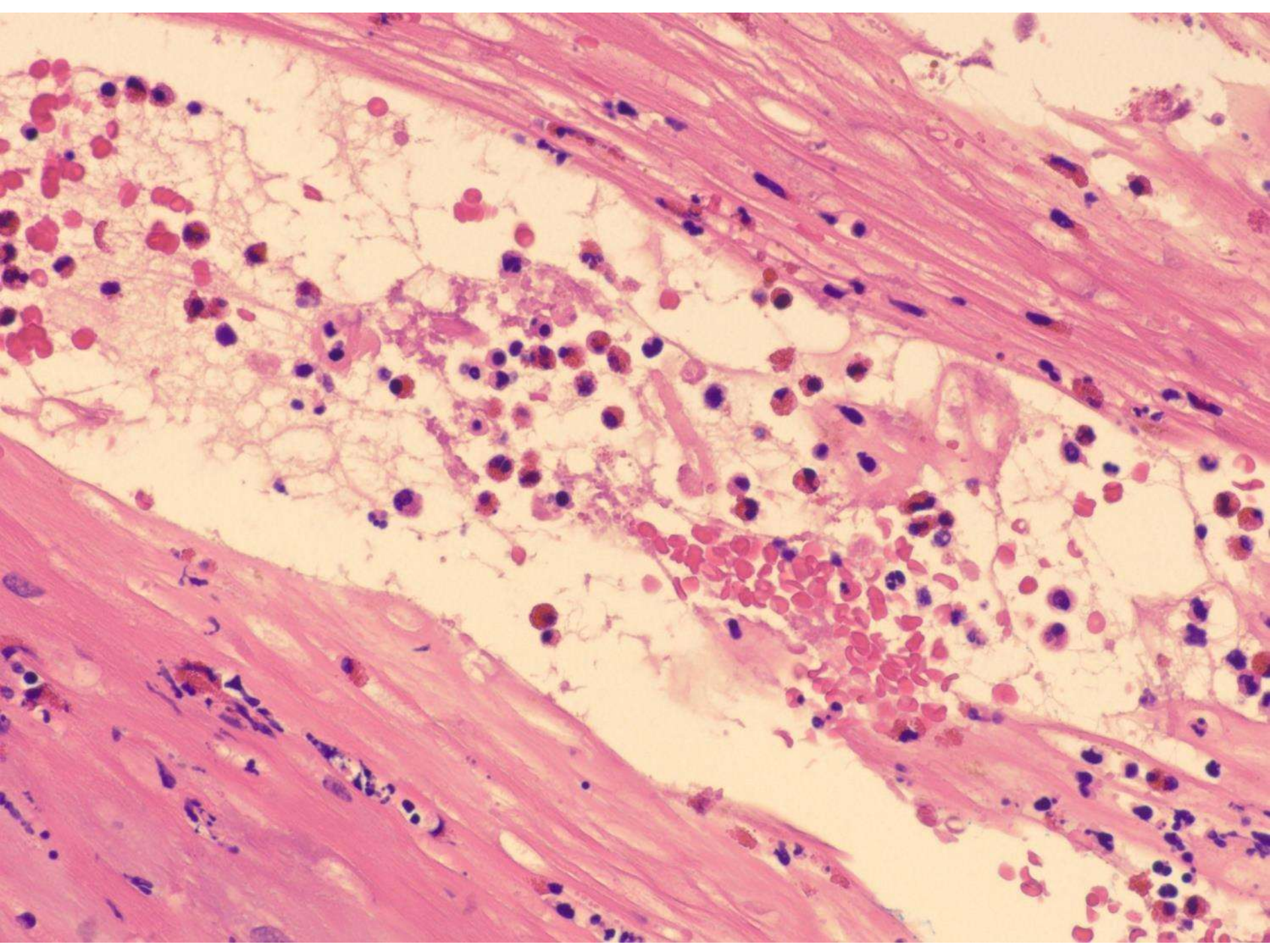
21-1003

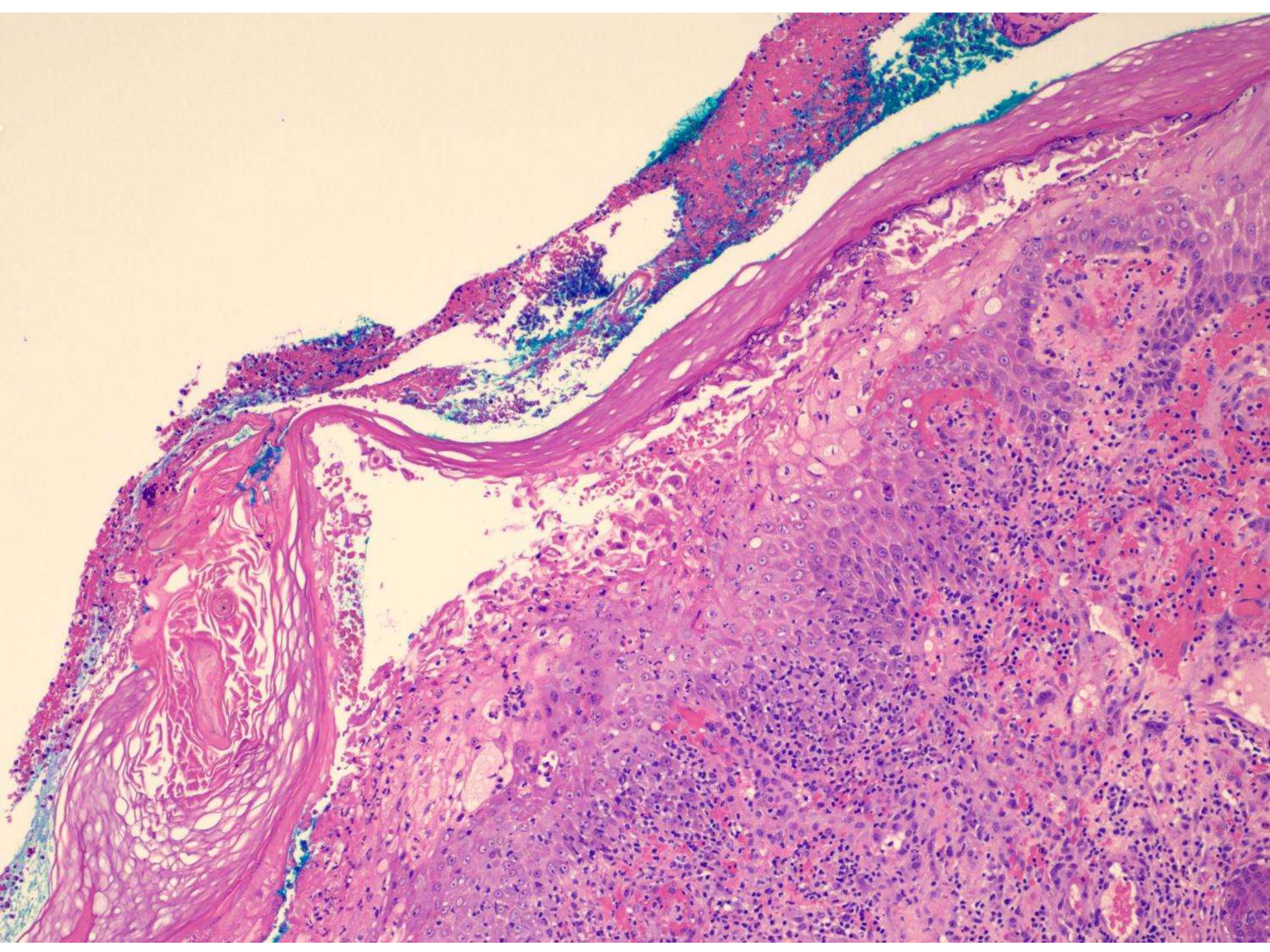
Beth Ruben; PAMF

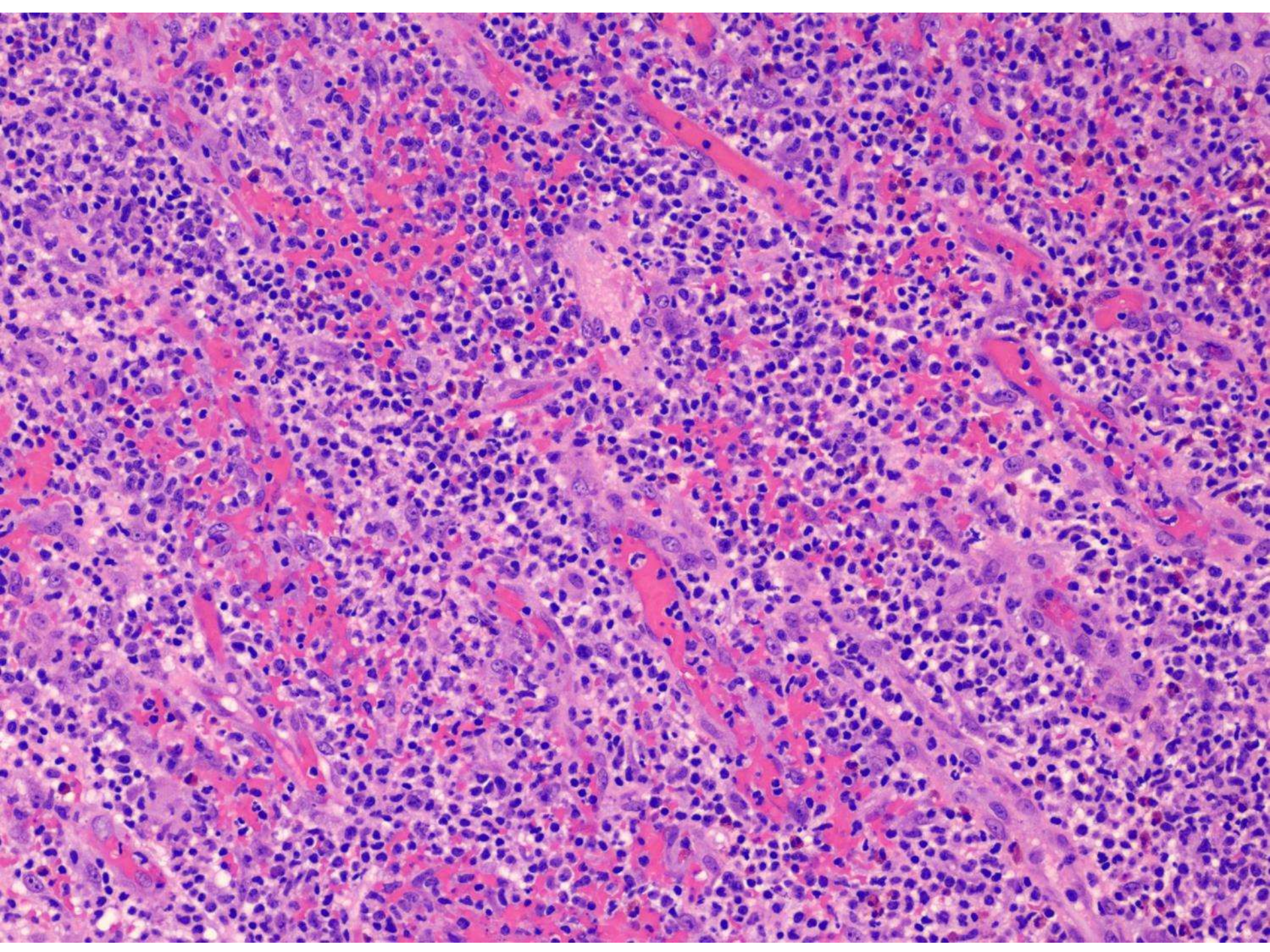
39-year-M with lacerated hand cleaning goat meat in central valley. Sutures placed and removed 3 weeks earlier, but wound persists.

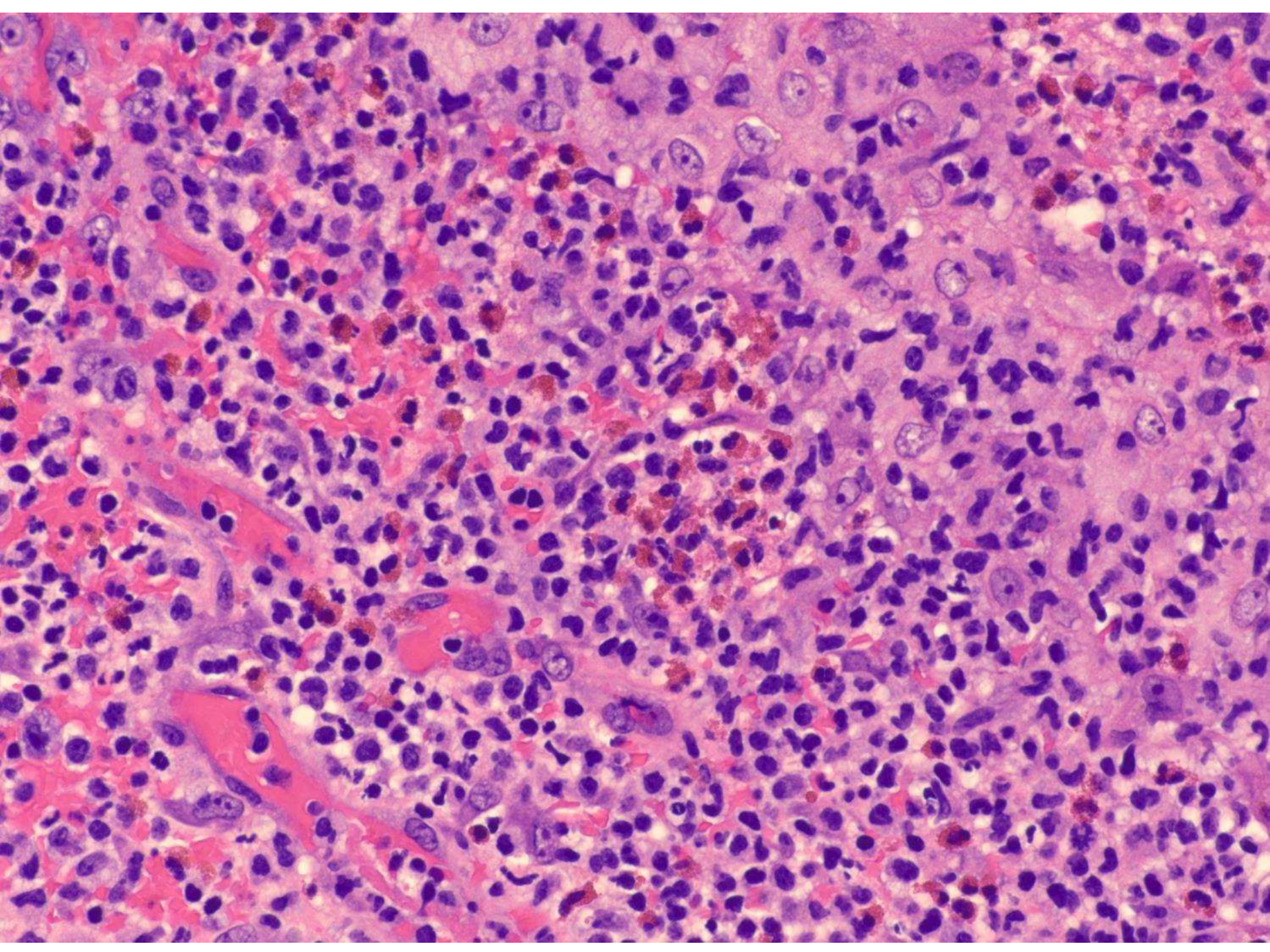


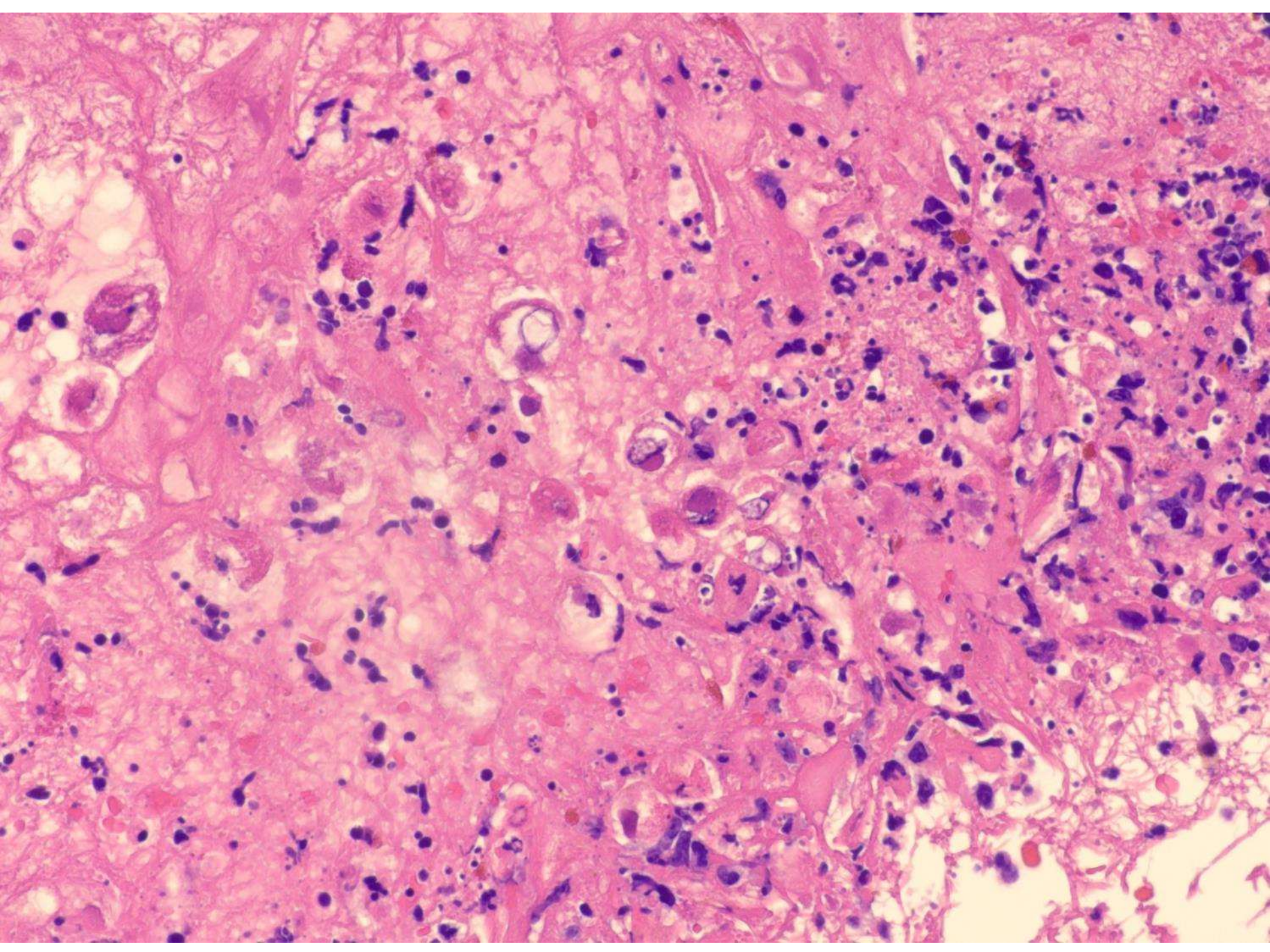


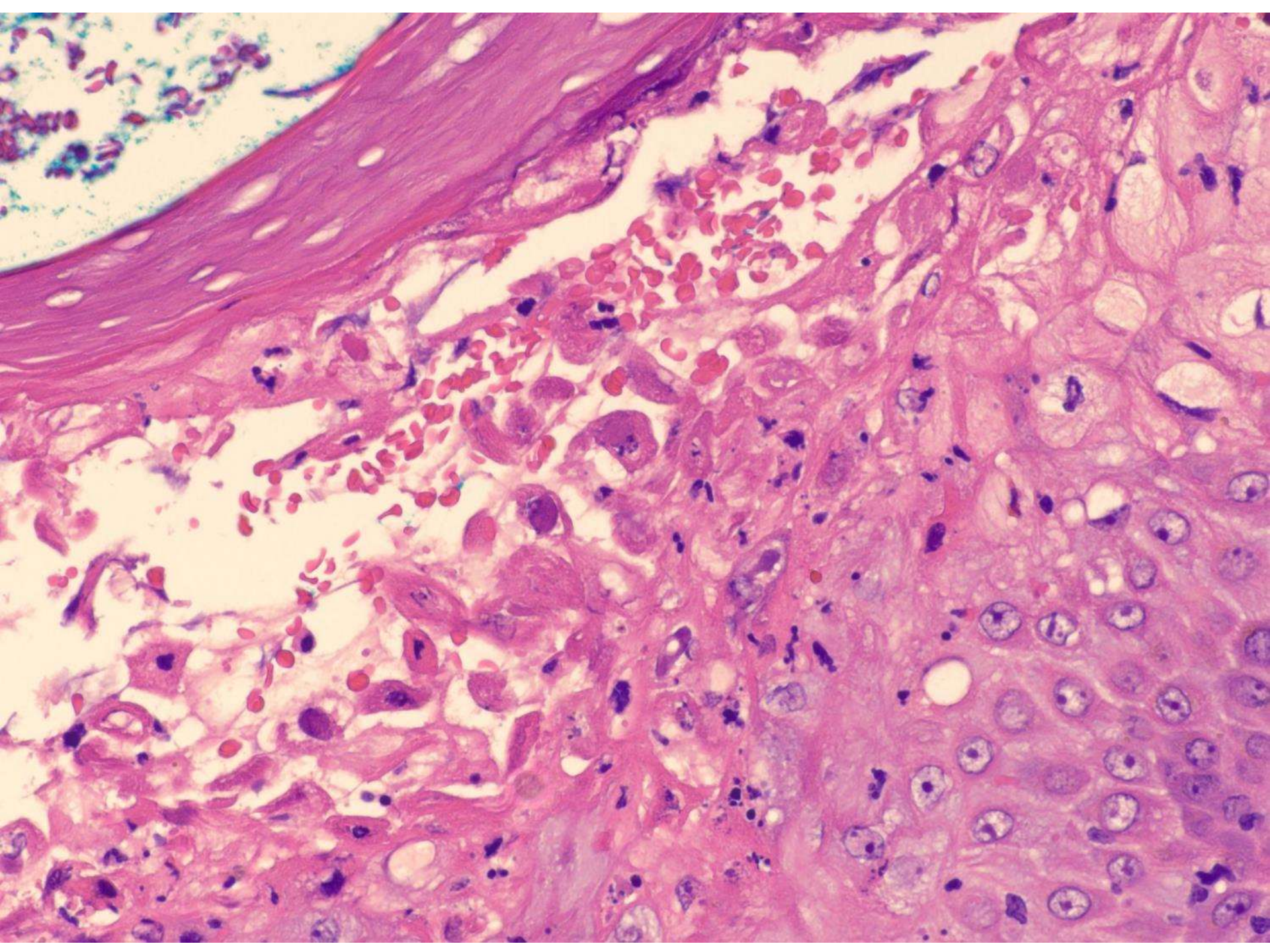


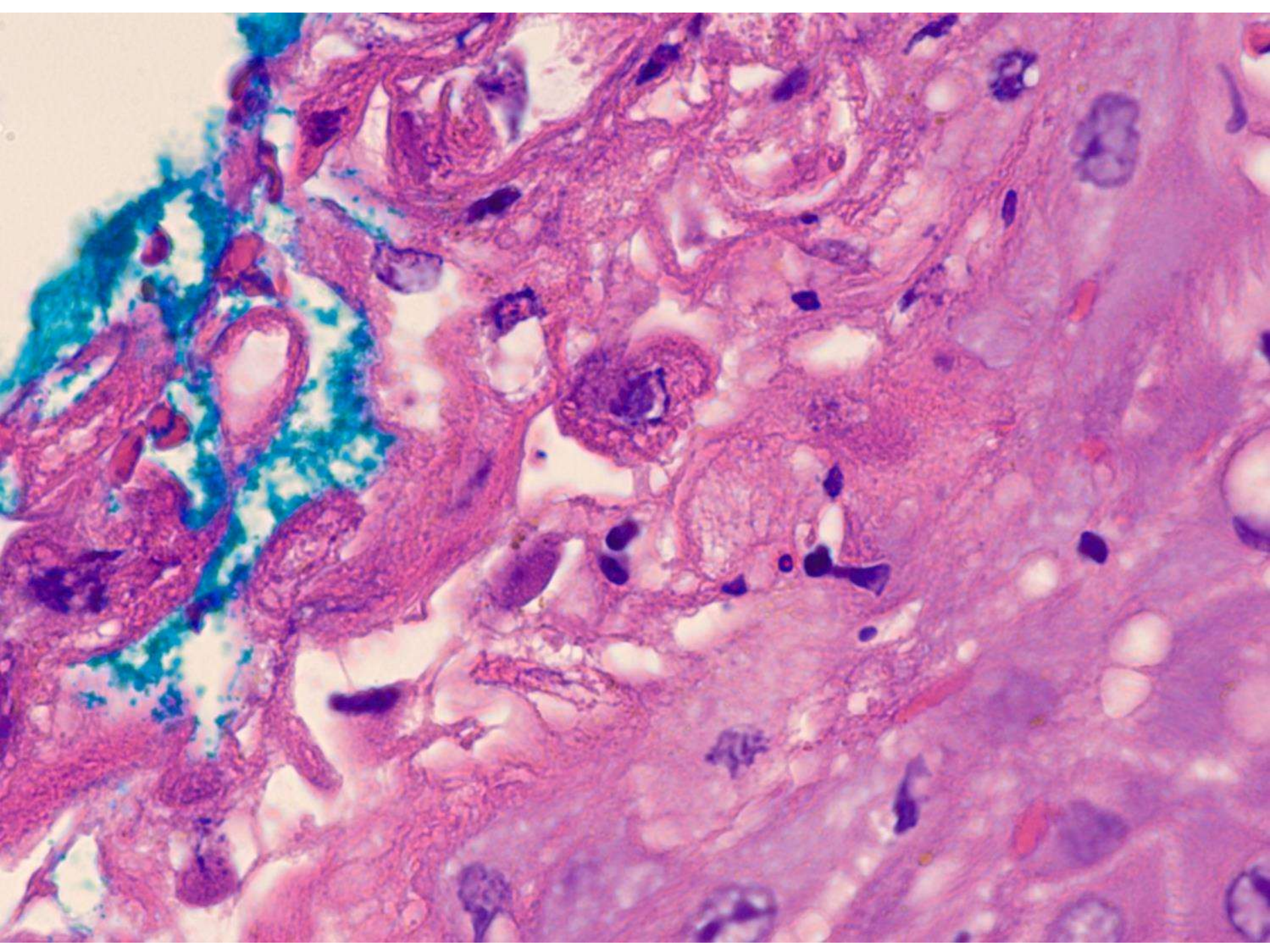


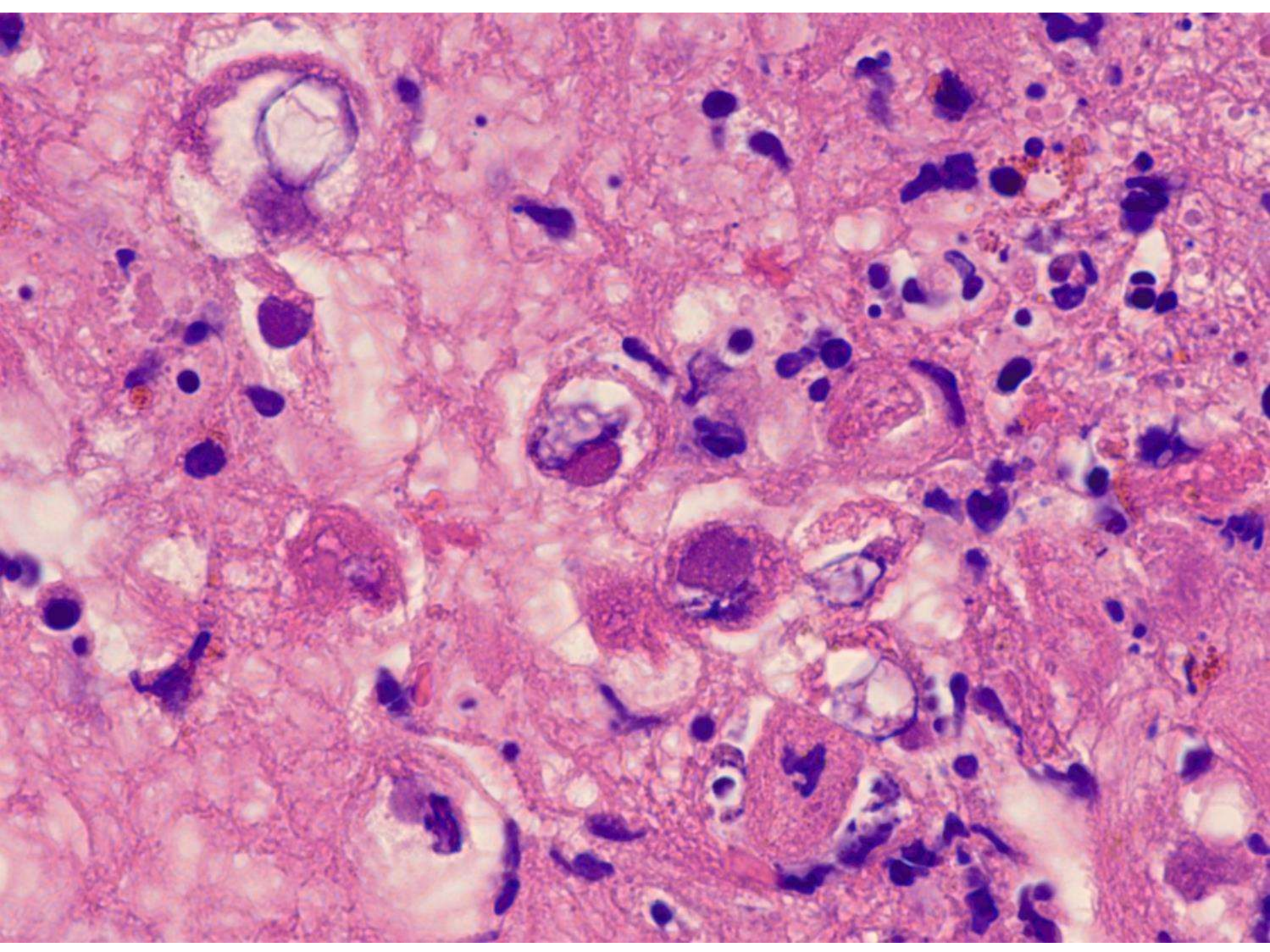


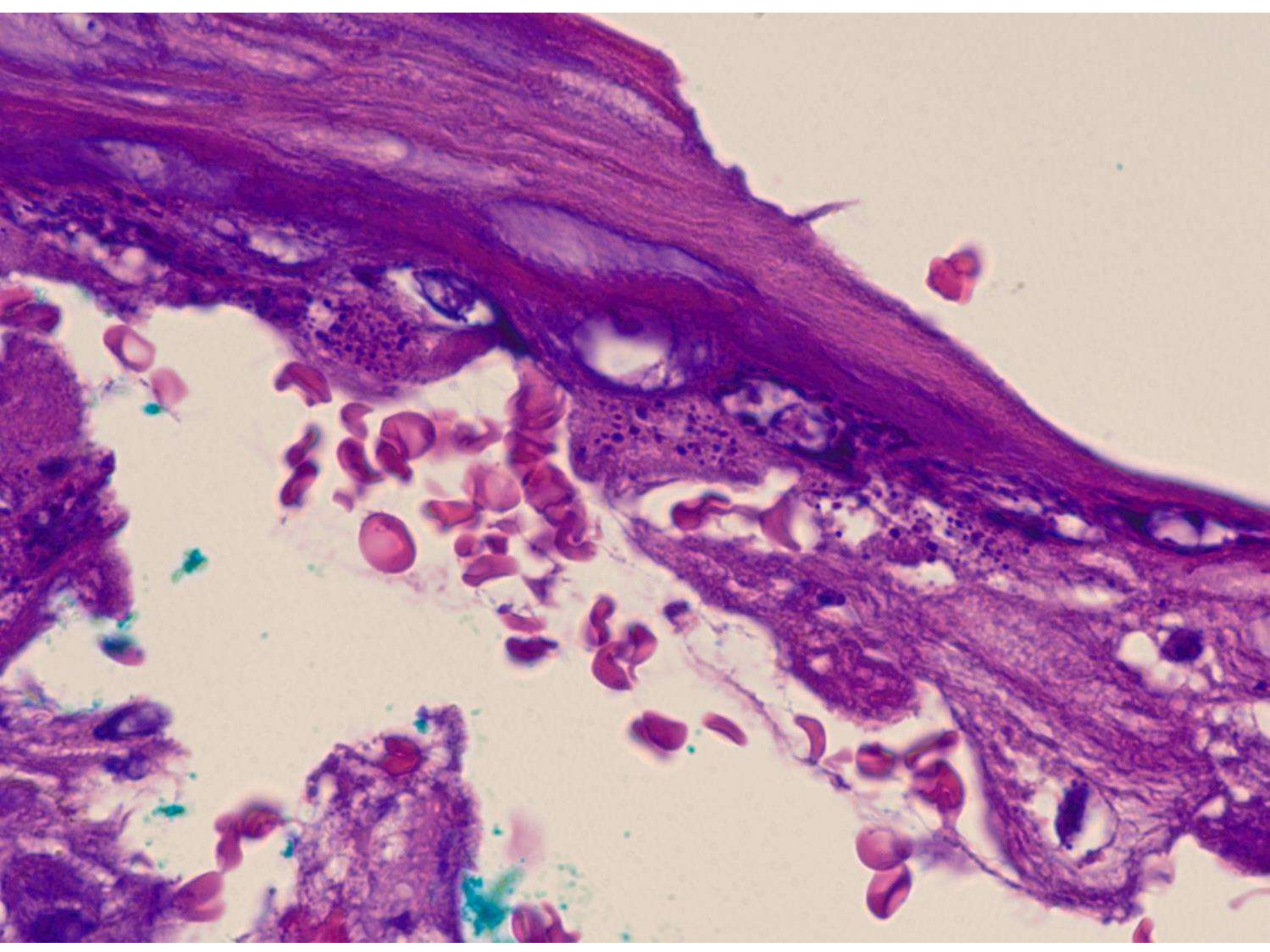


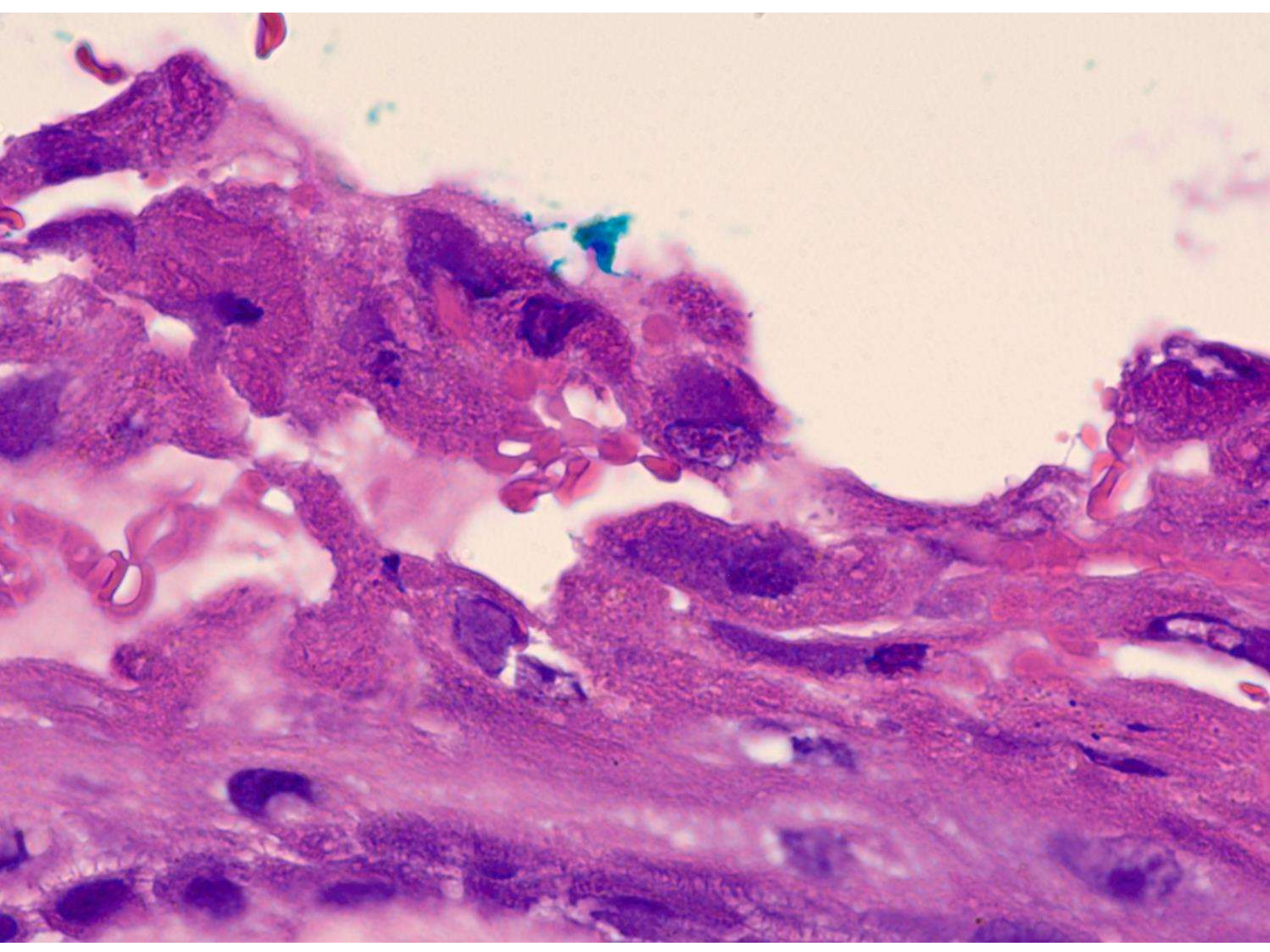










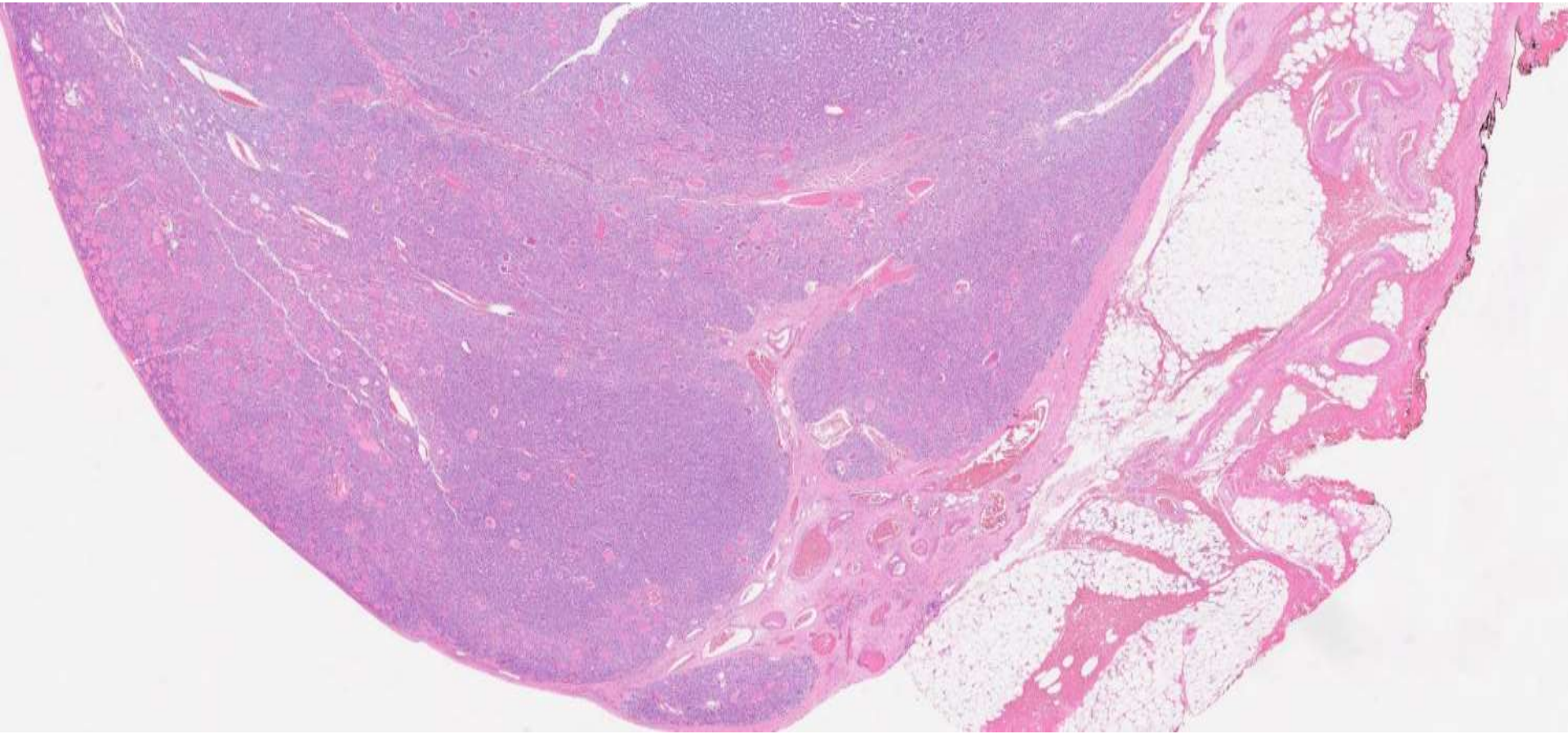


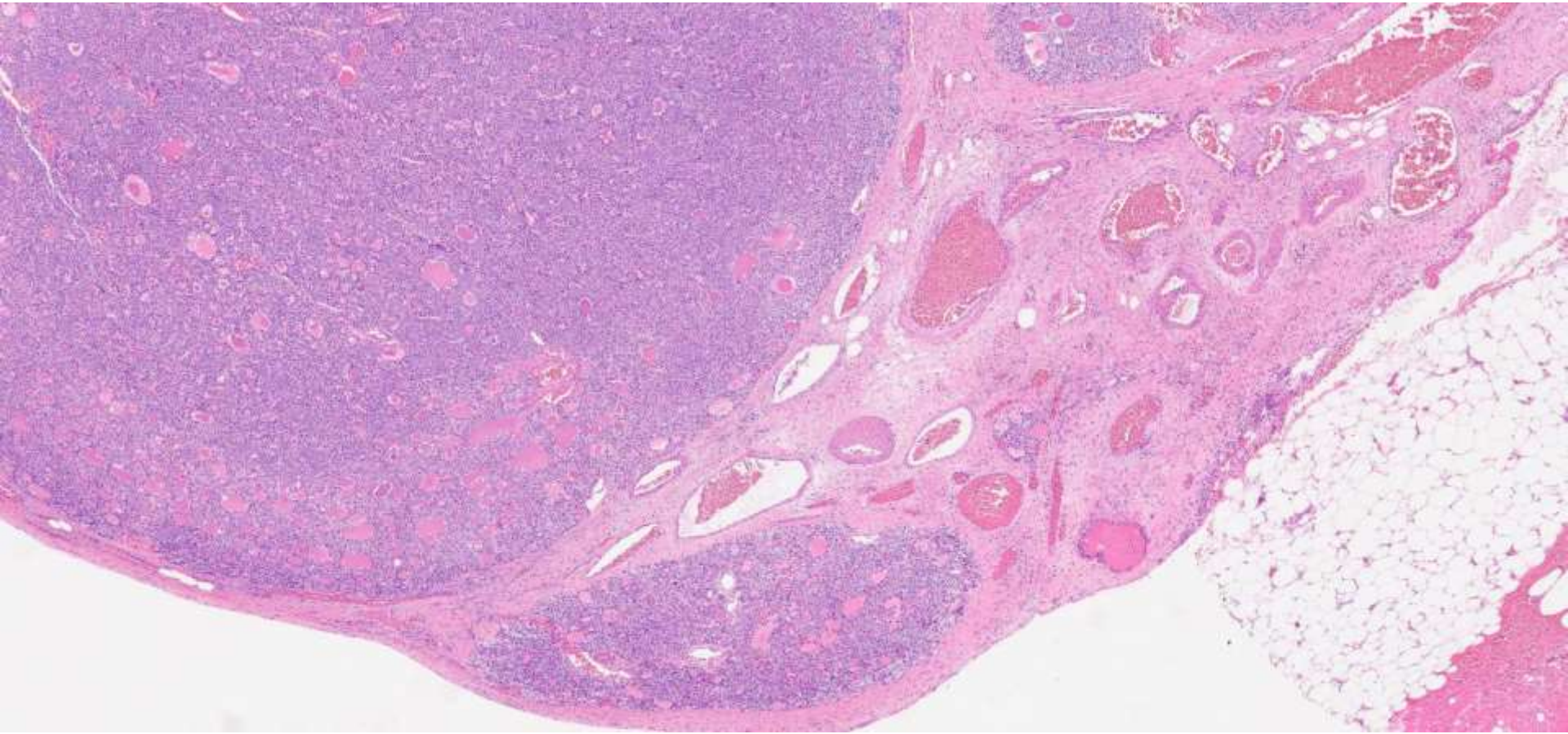


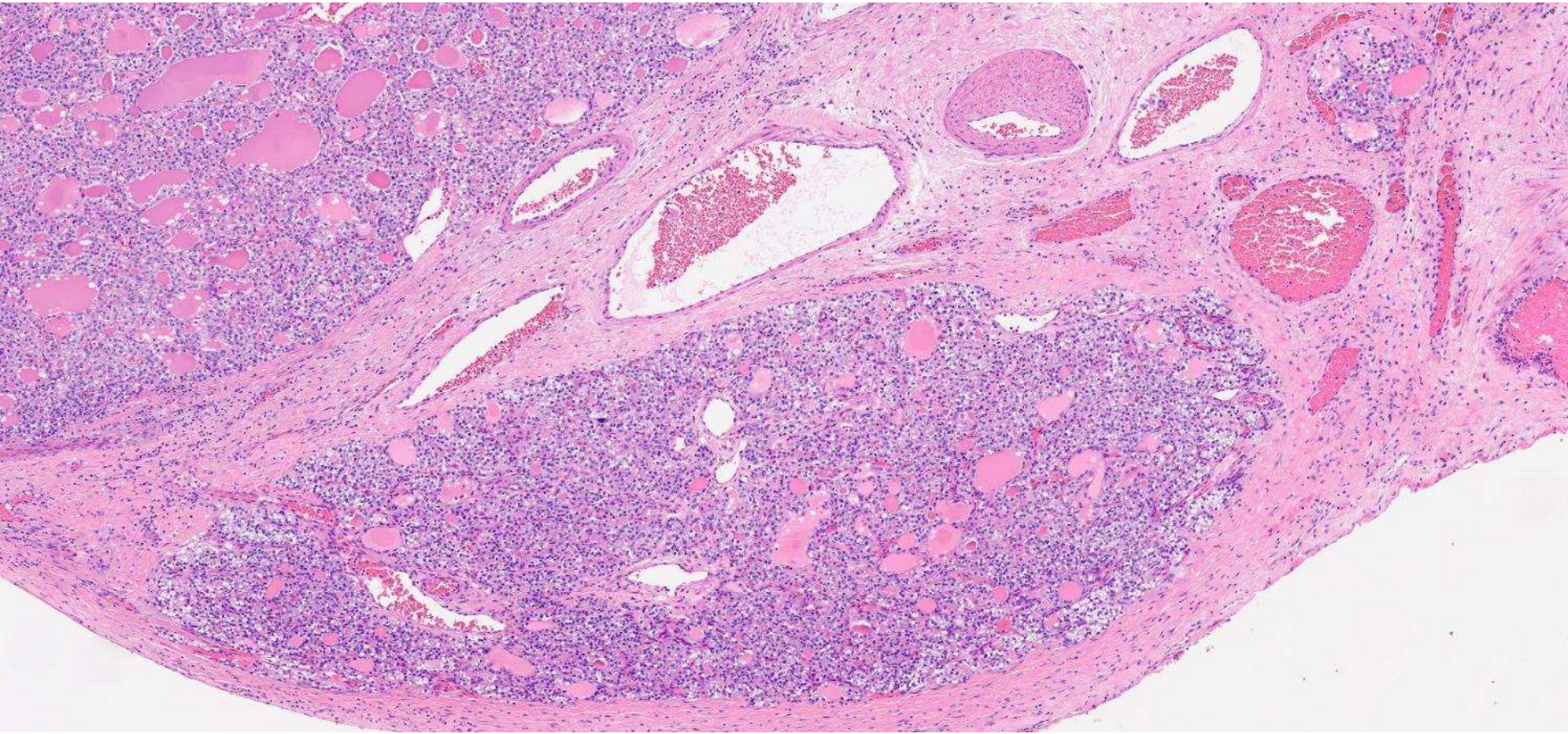
21-1004

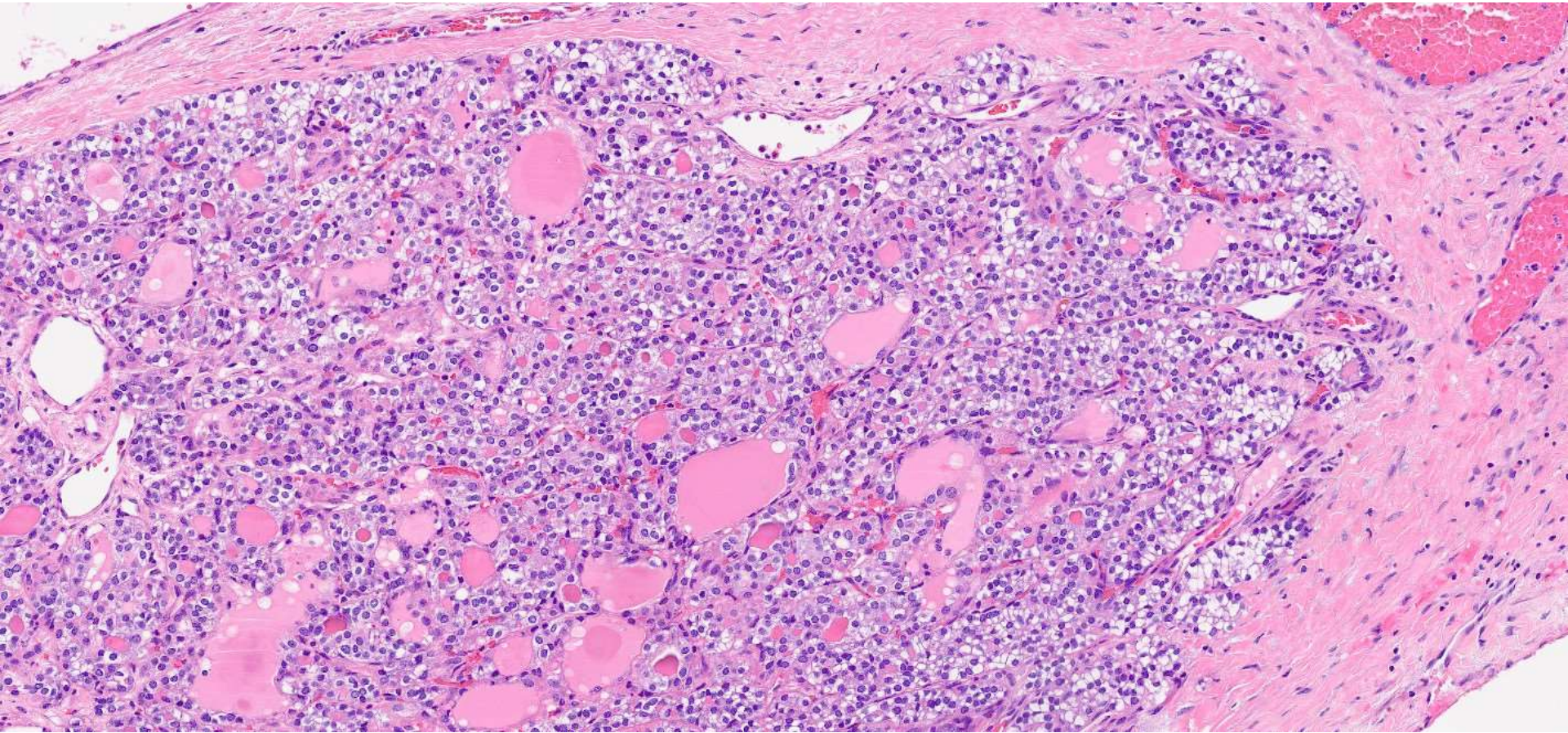
Lucas Massoth; El Camino Hospital

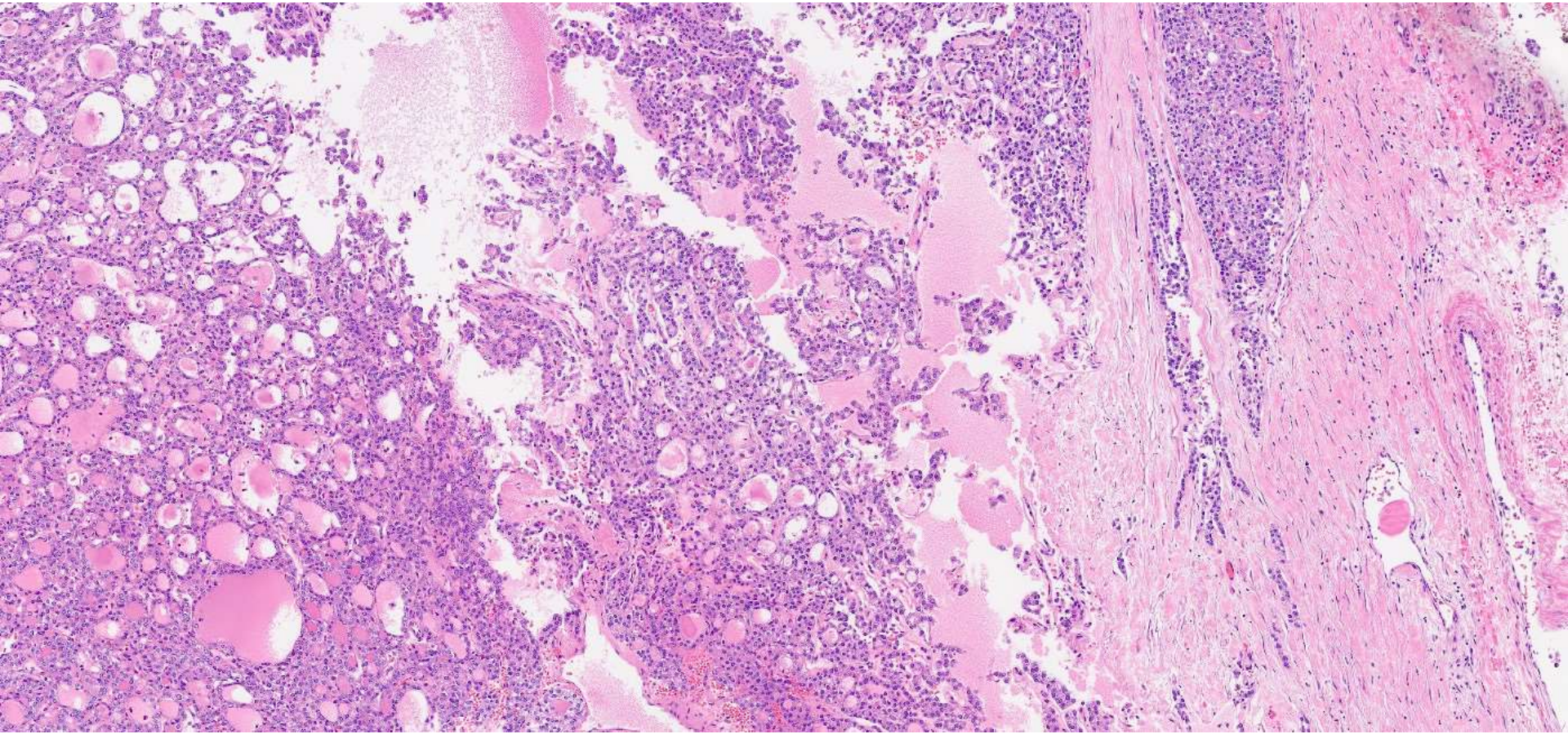
35-year-old F with interior abdominal mass excision.

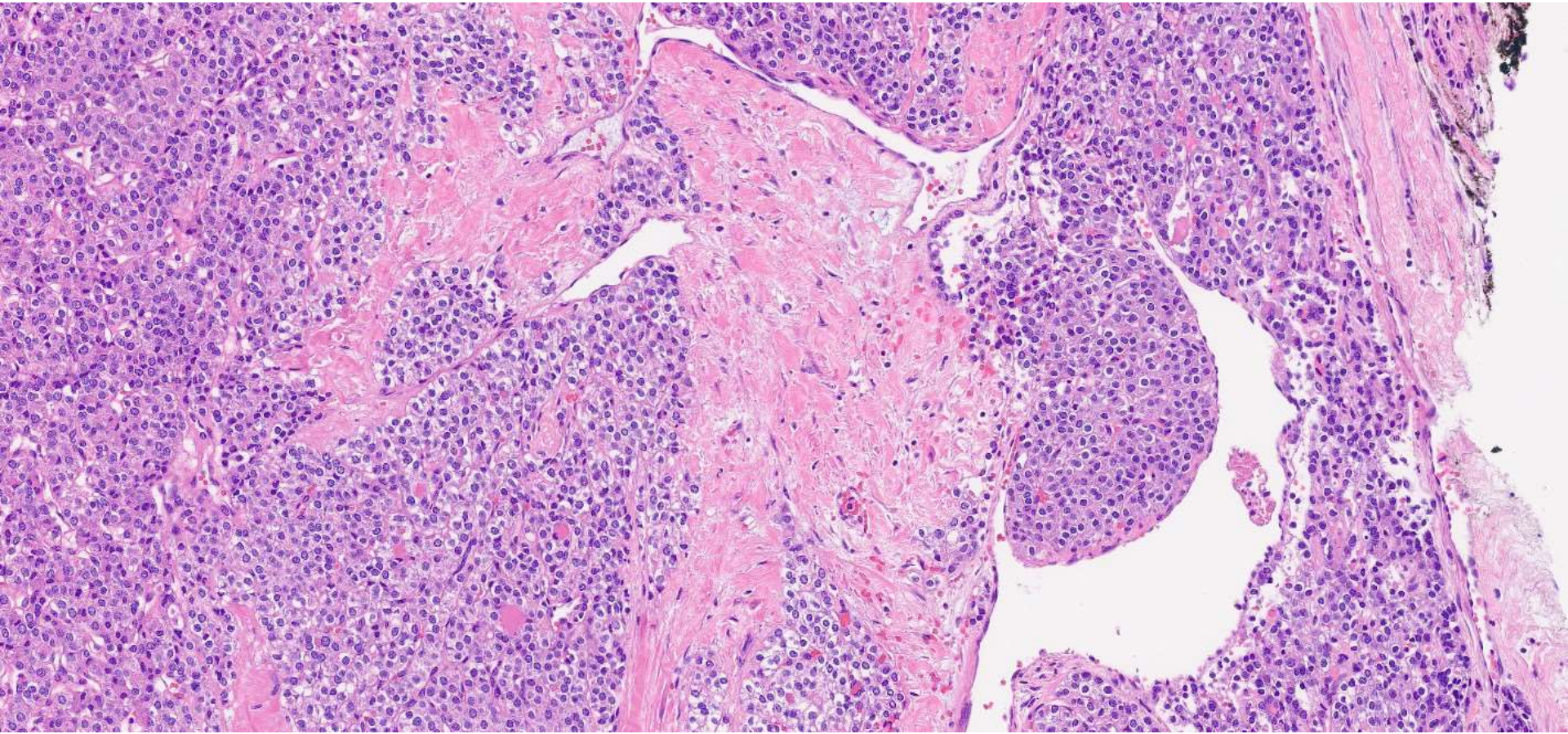


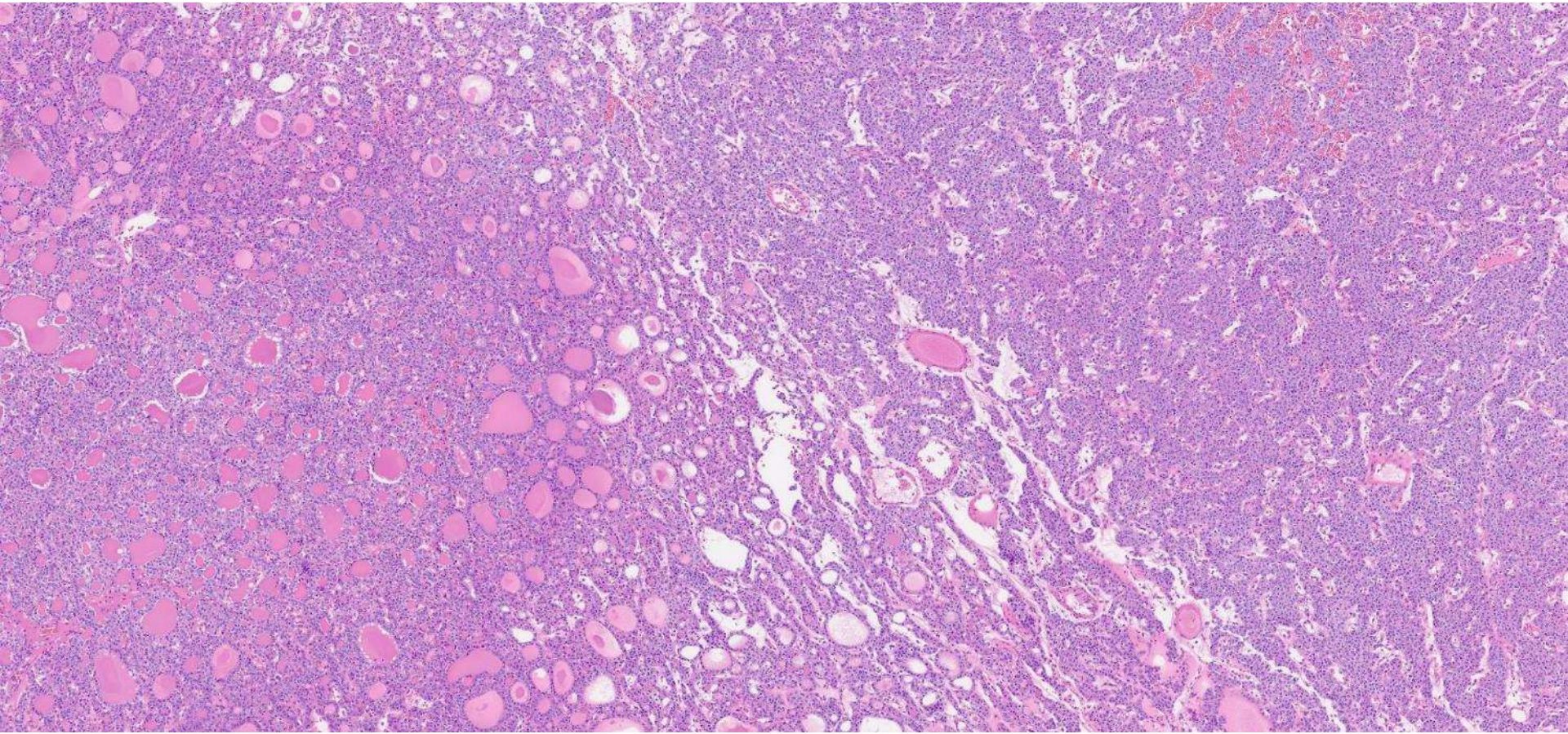


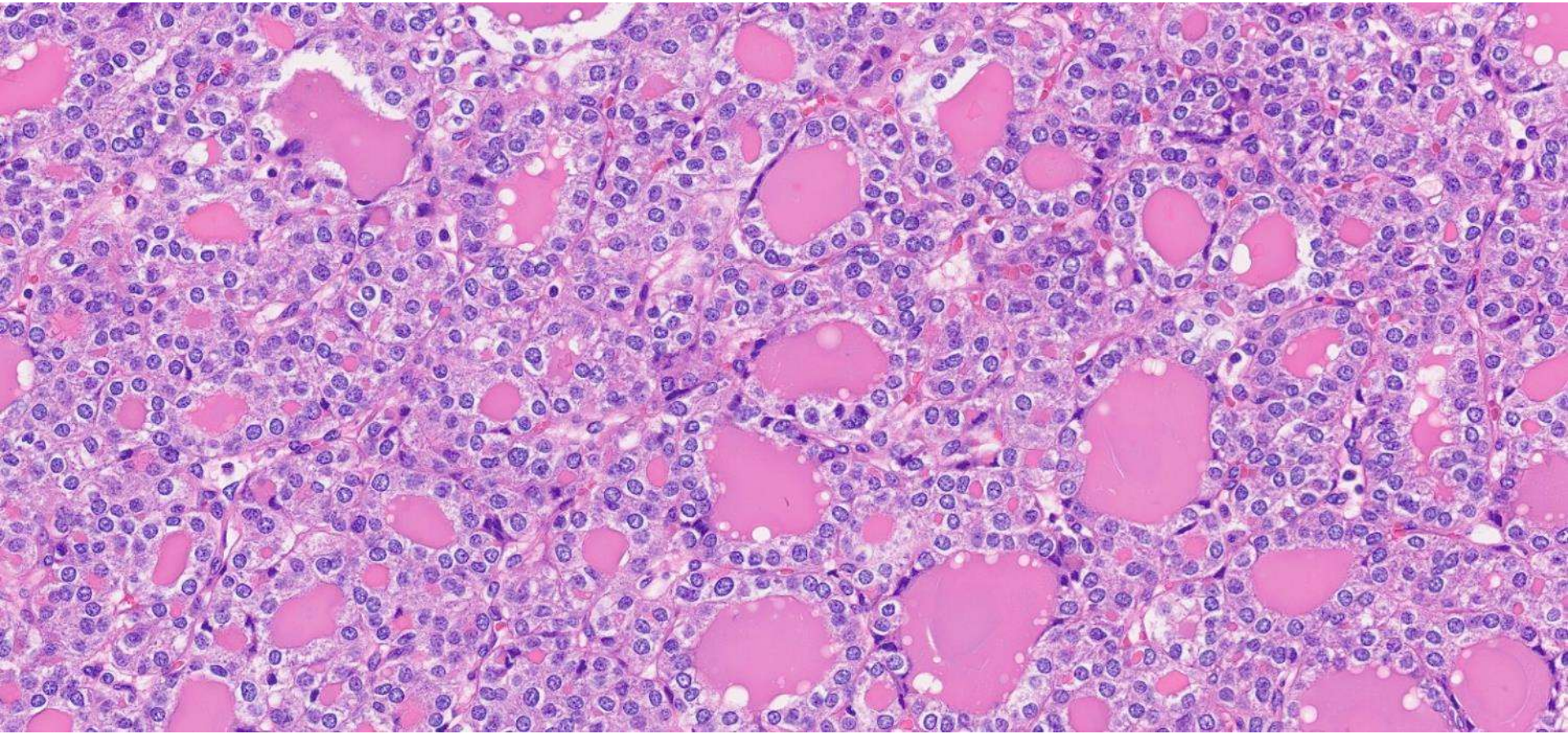


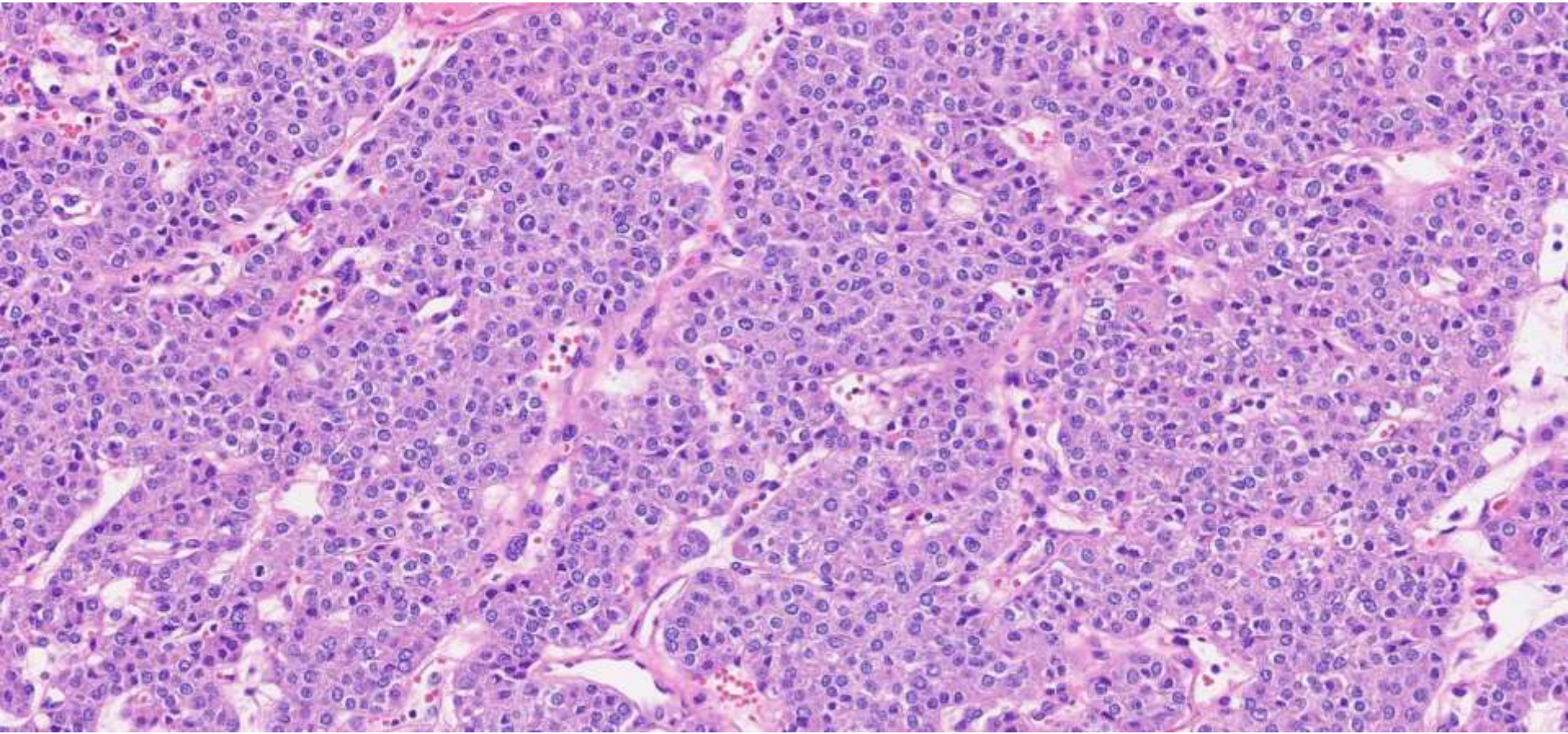










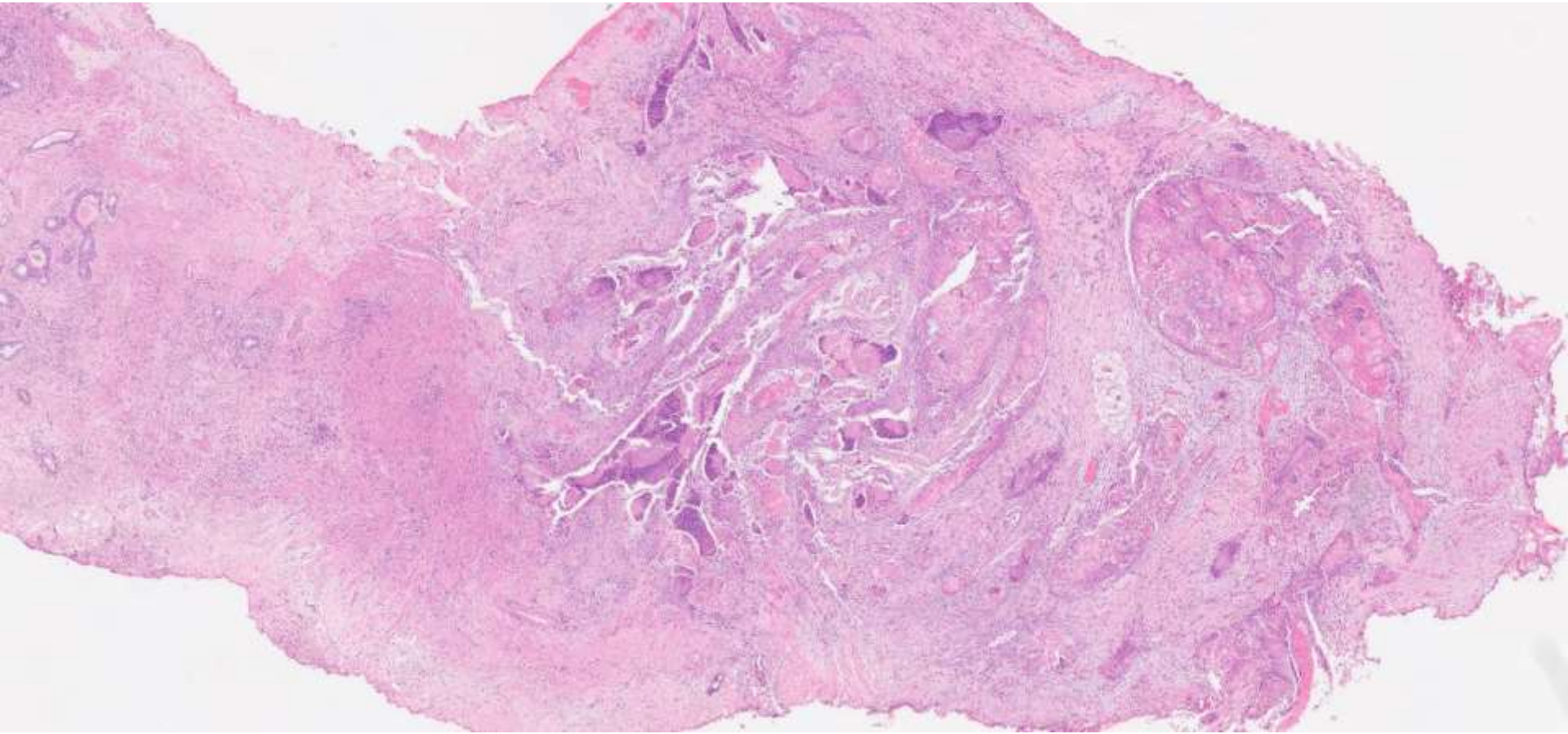


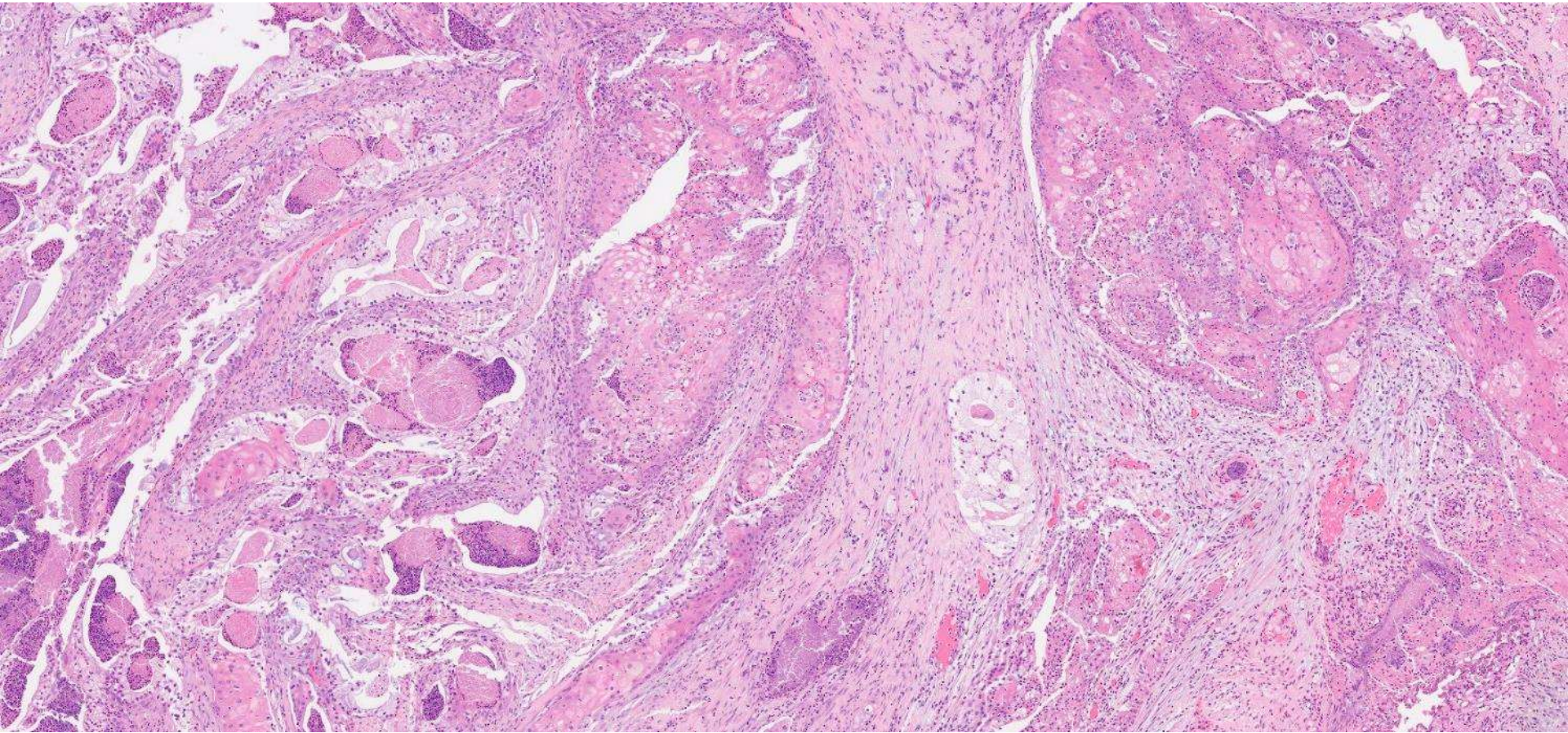


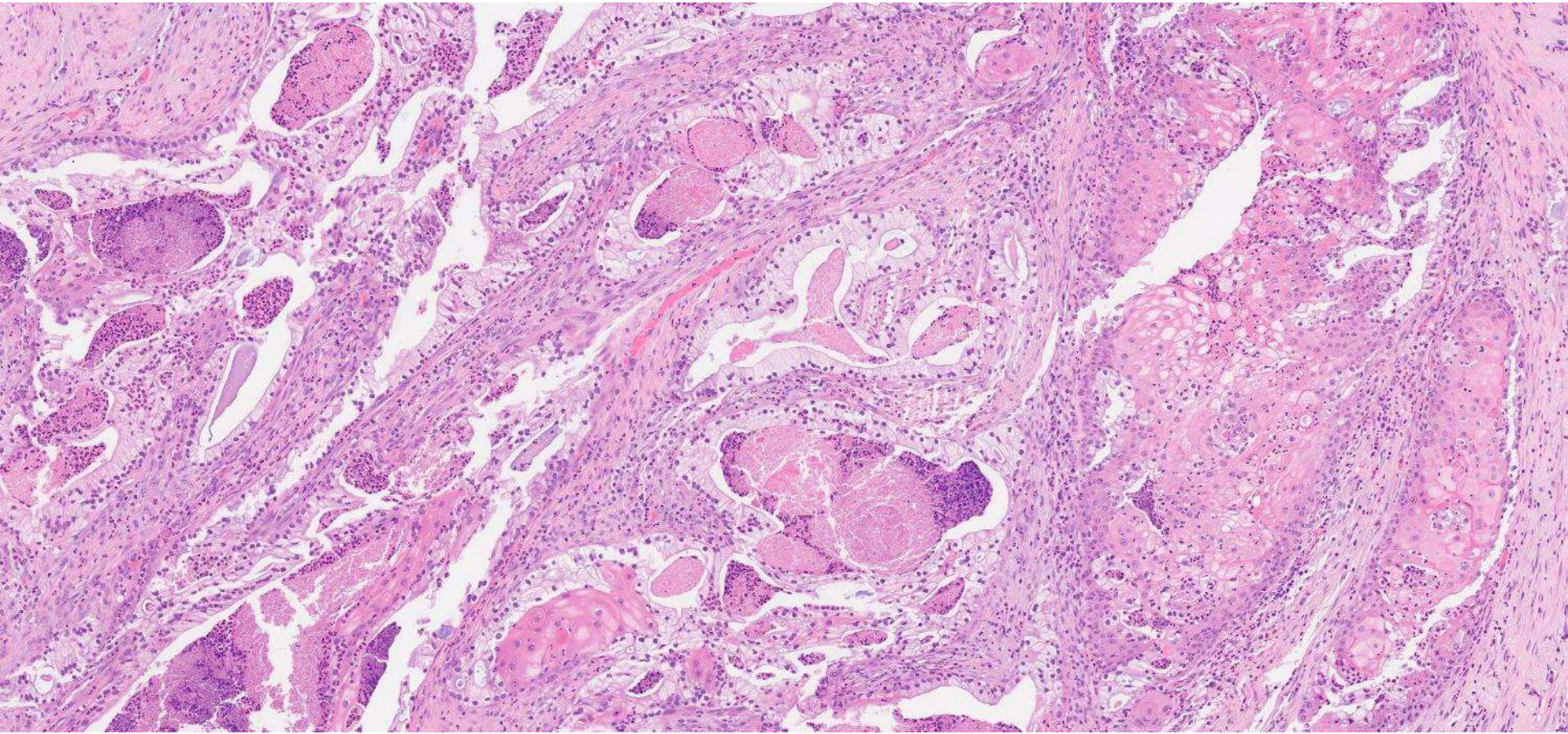
21-1005

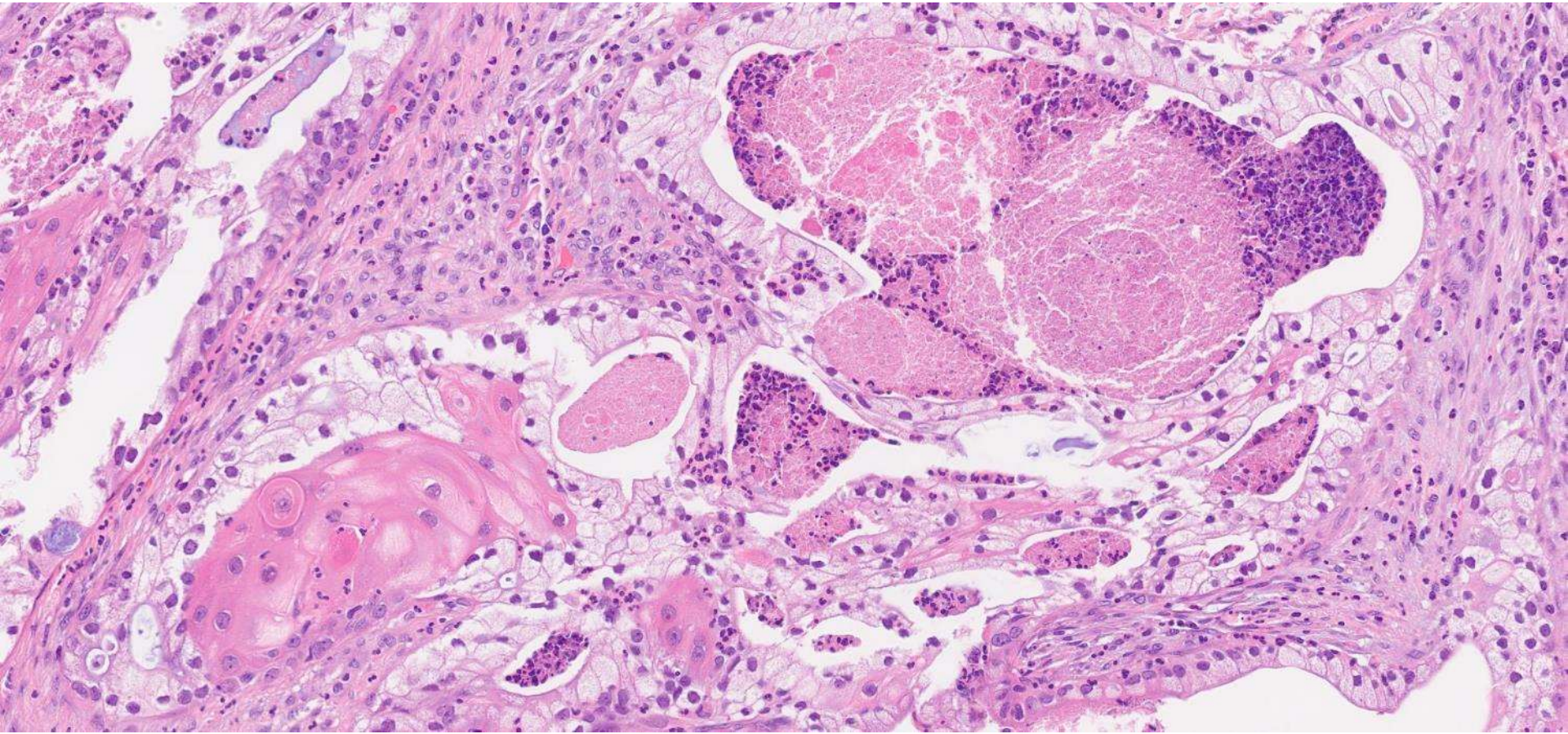
Ankur Sangoi; El Camino Hospital

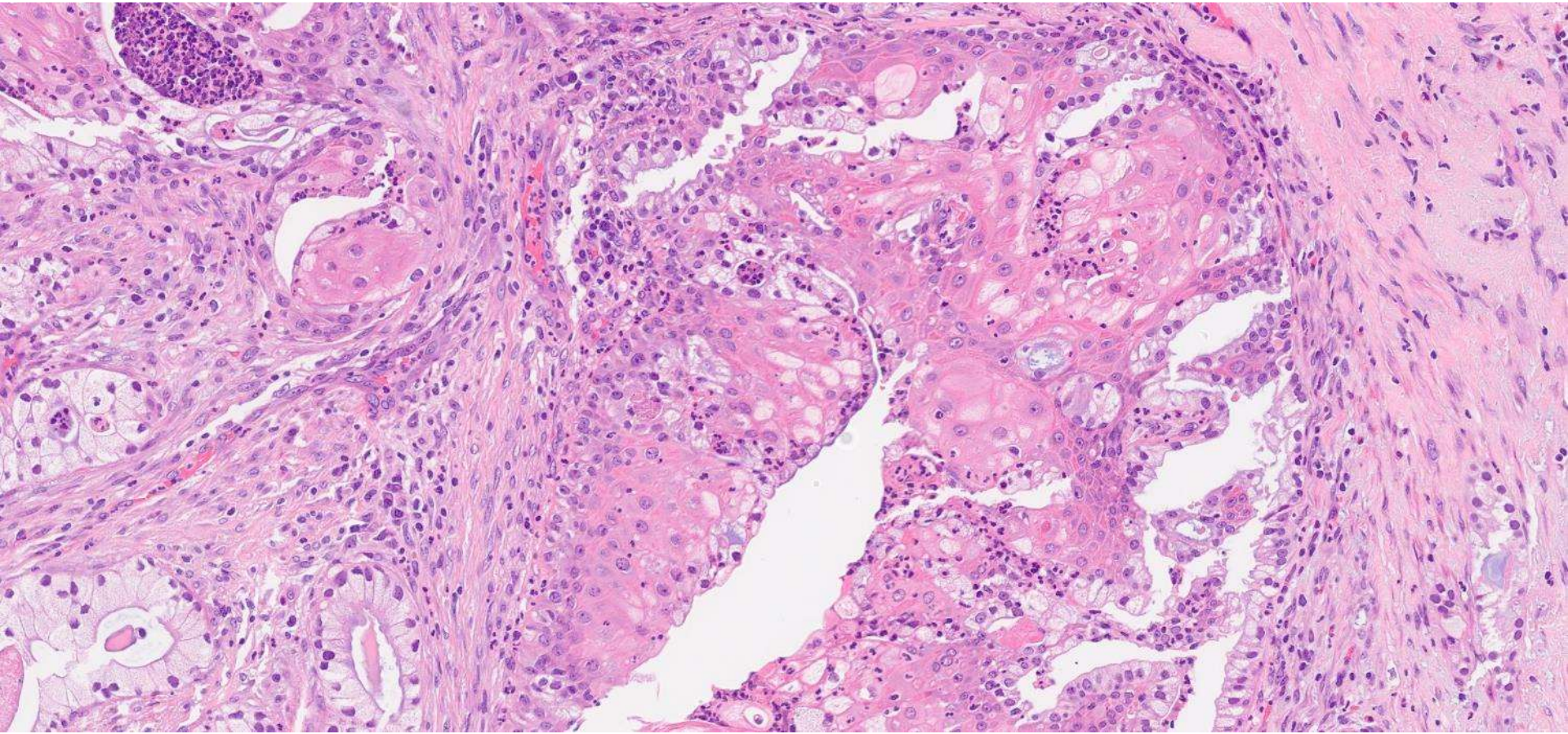
87-year-old F with BPH, undergoes TURP.

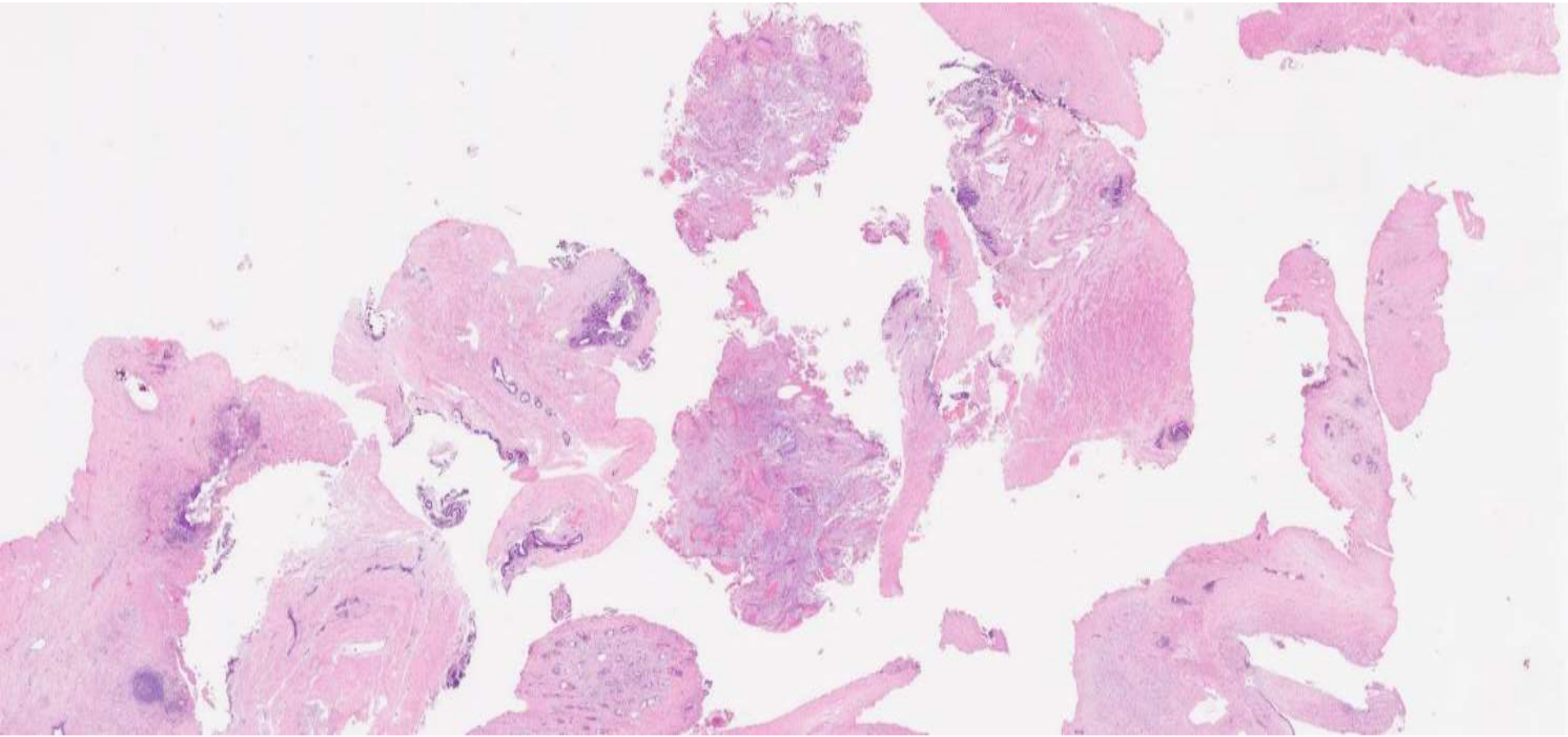


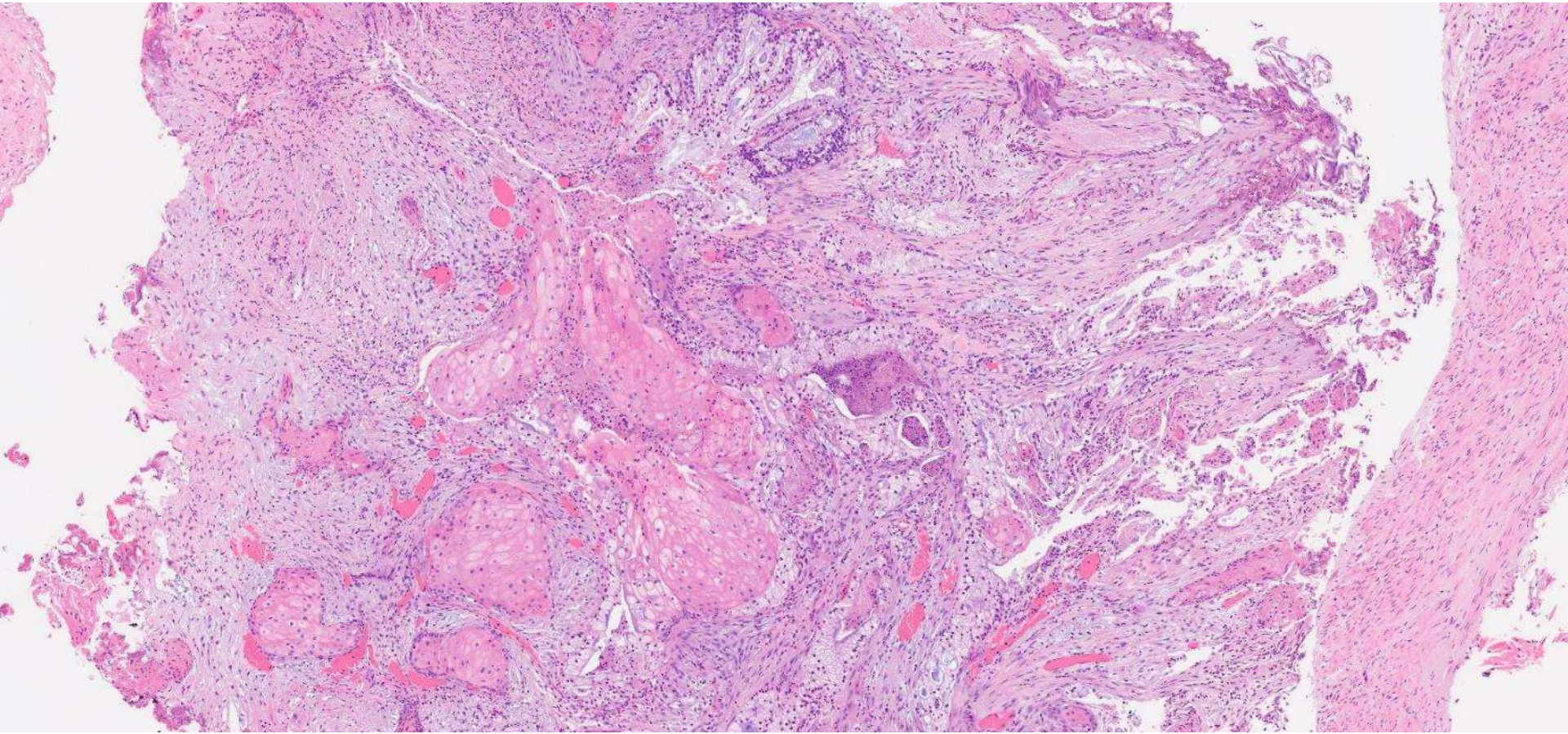


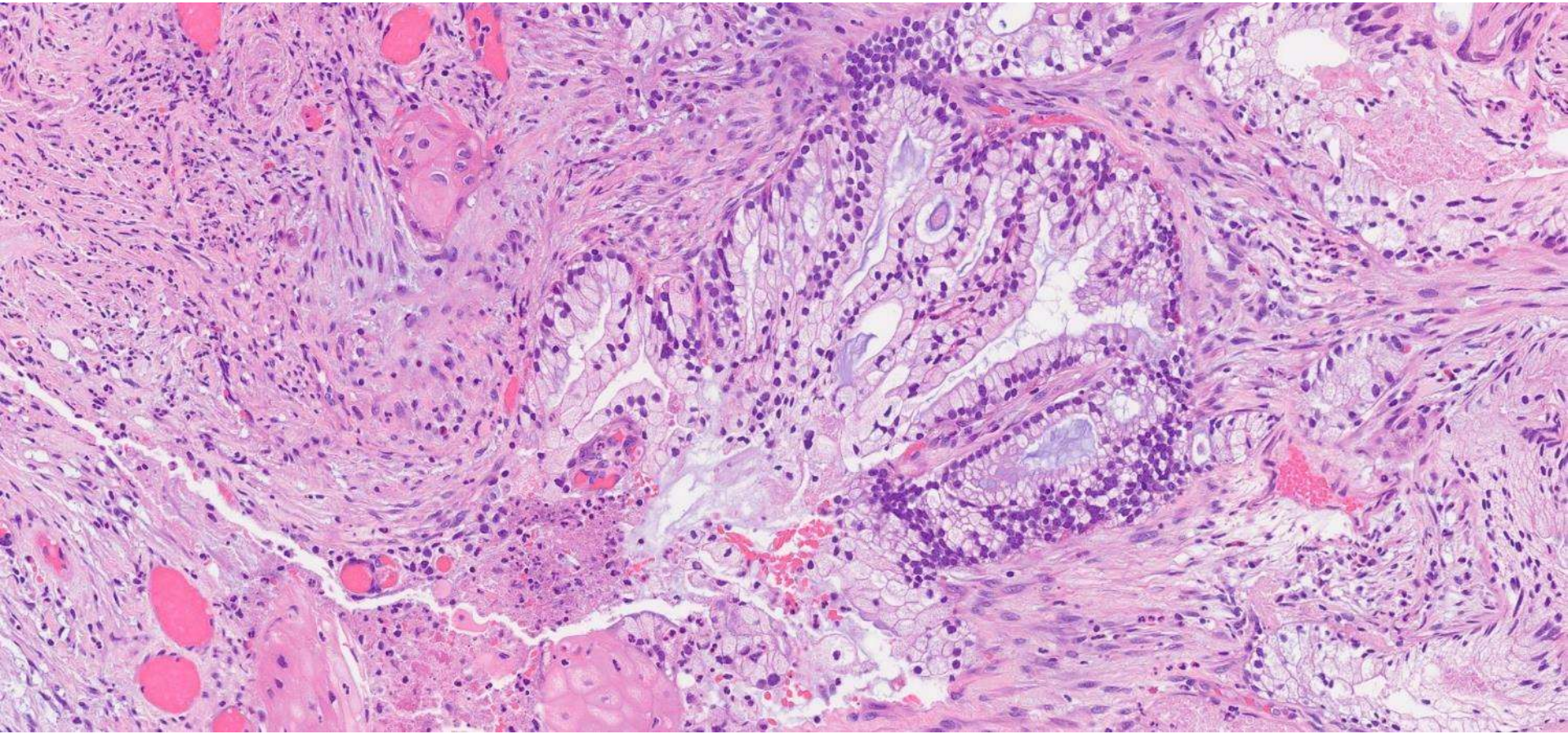


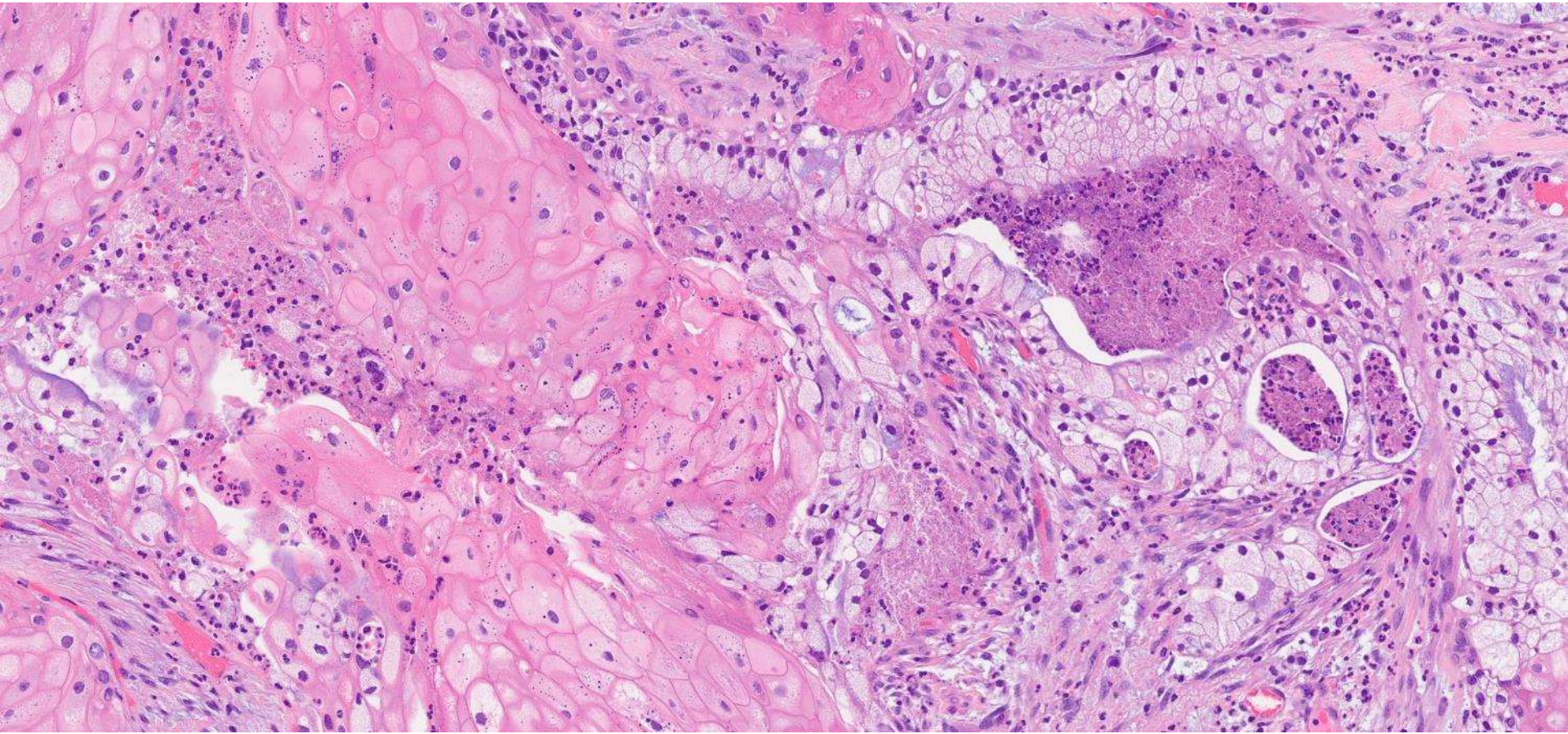










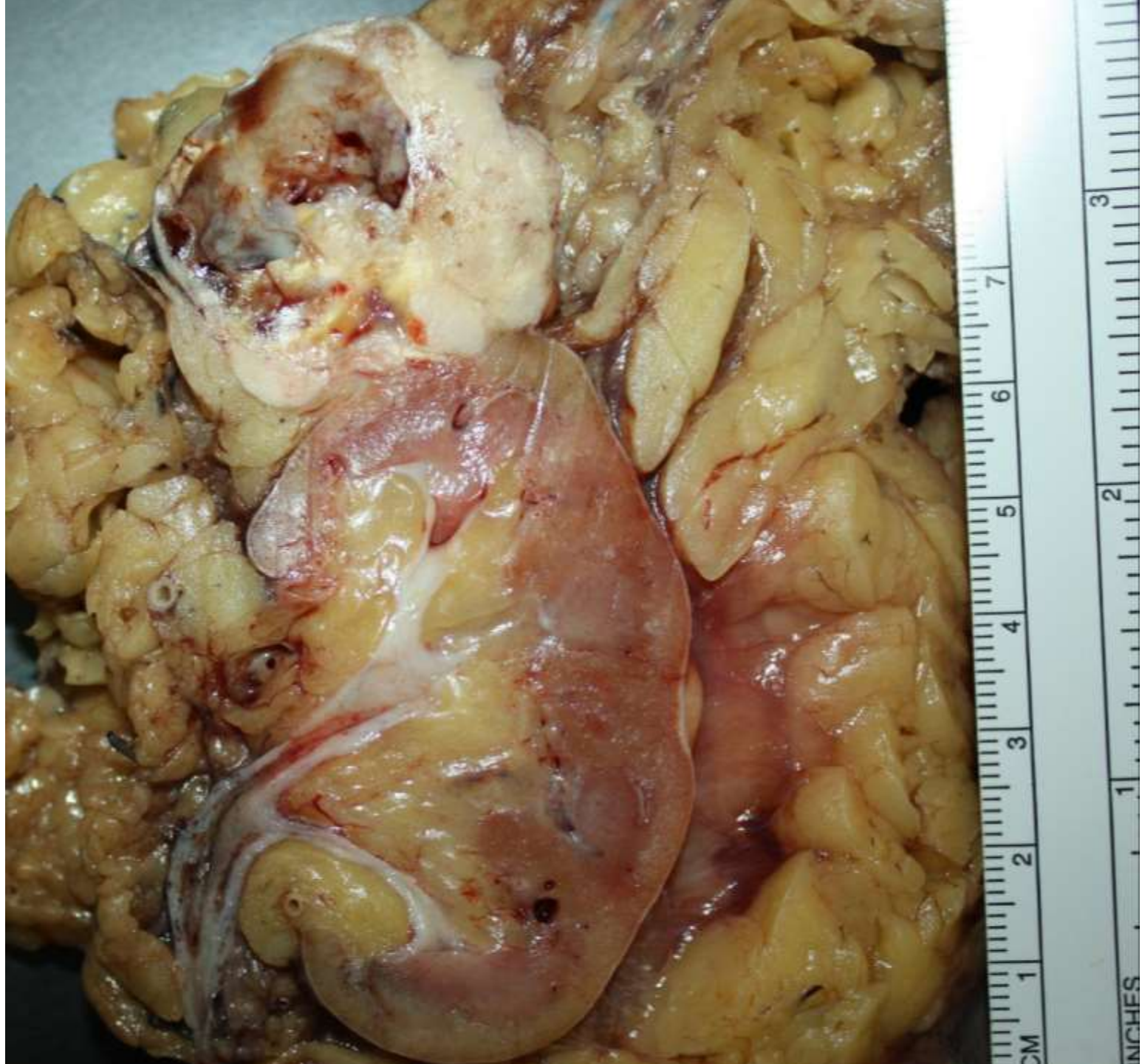

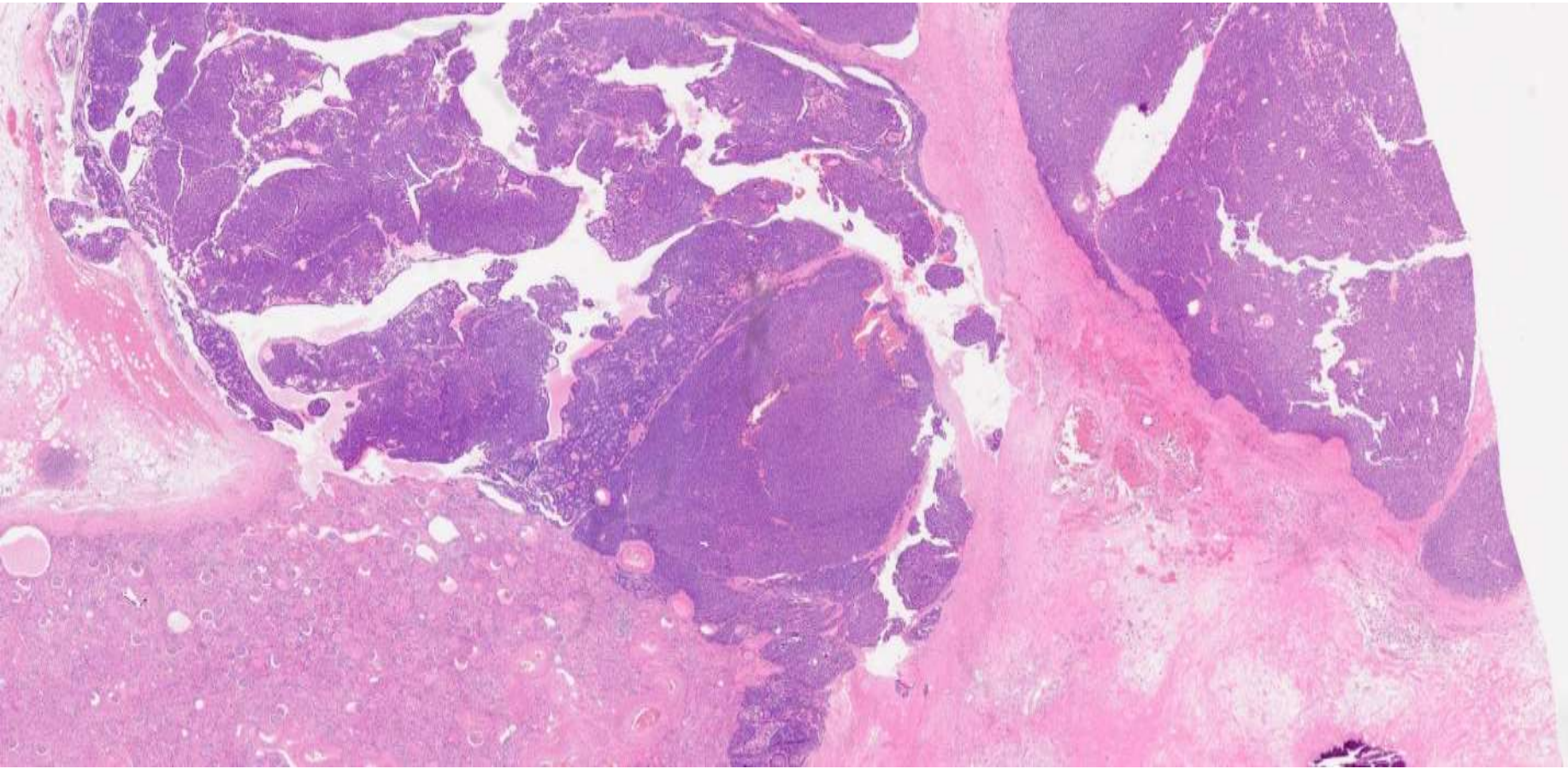


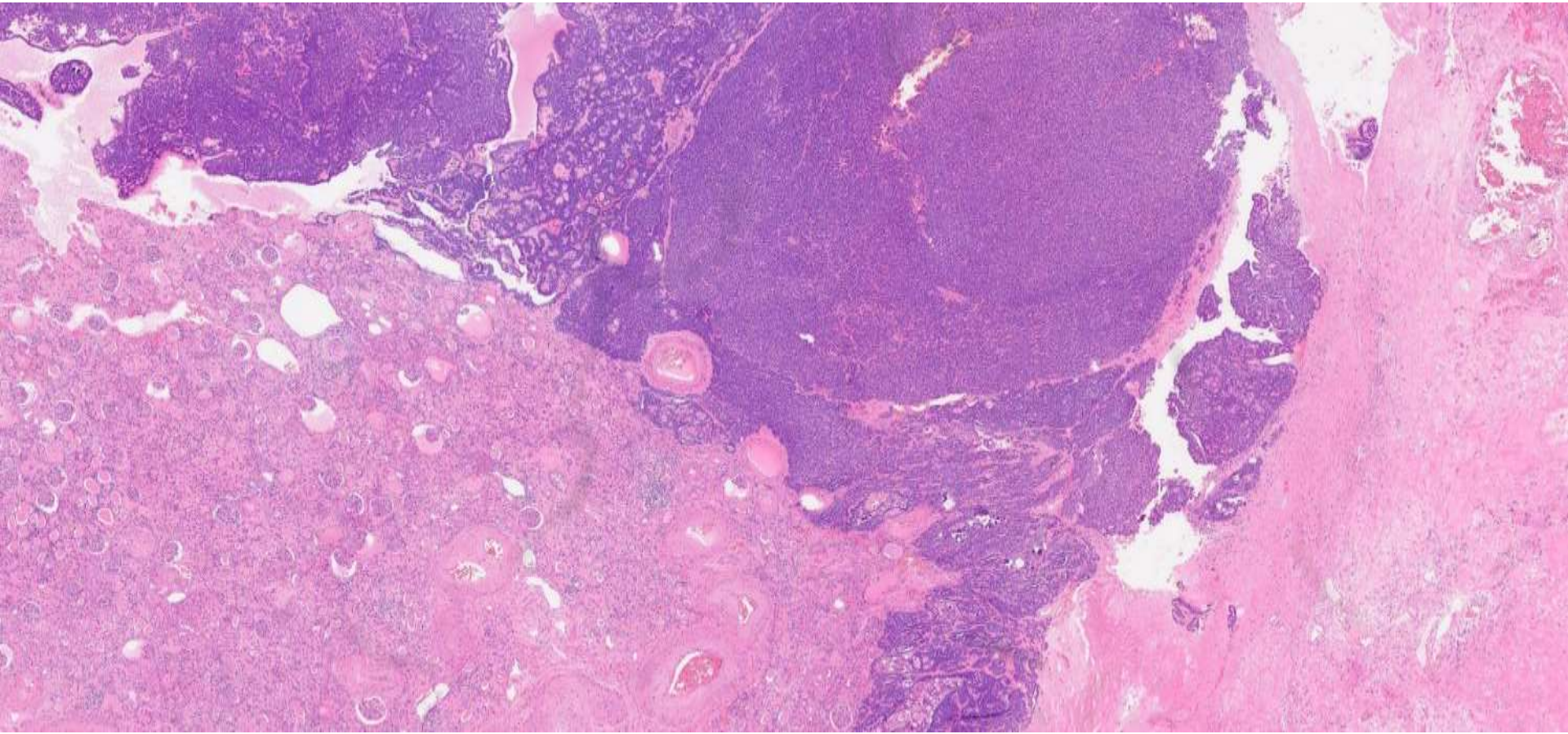
21-1006

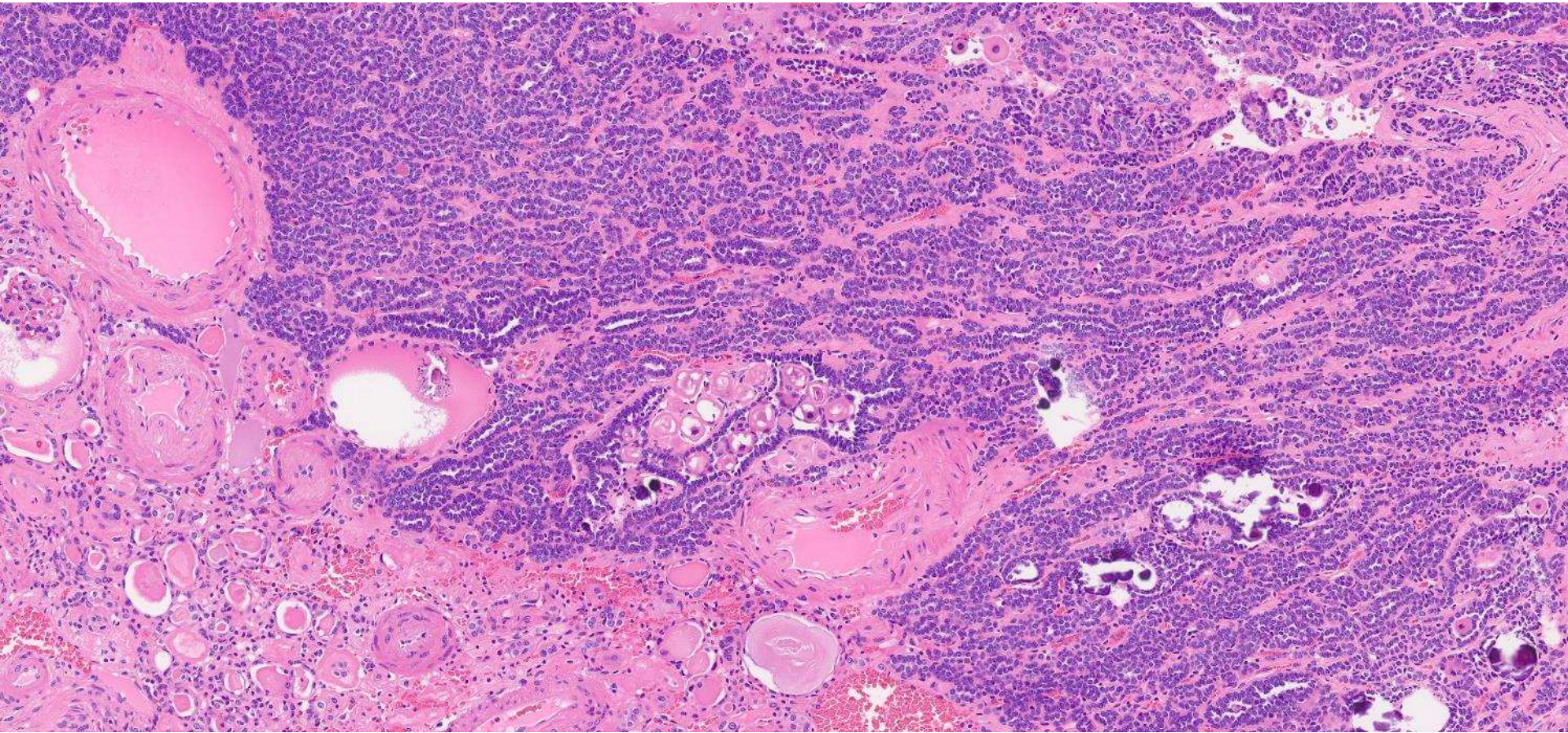
Ankur Sangoi; El Camino Hospital

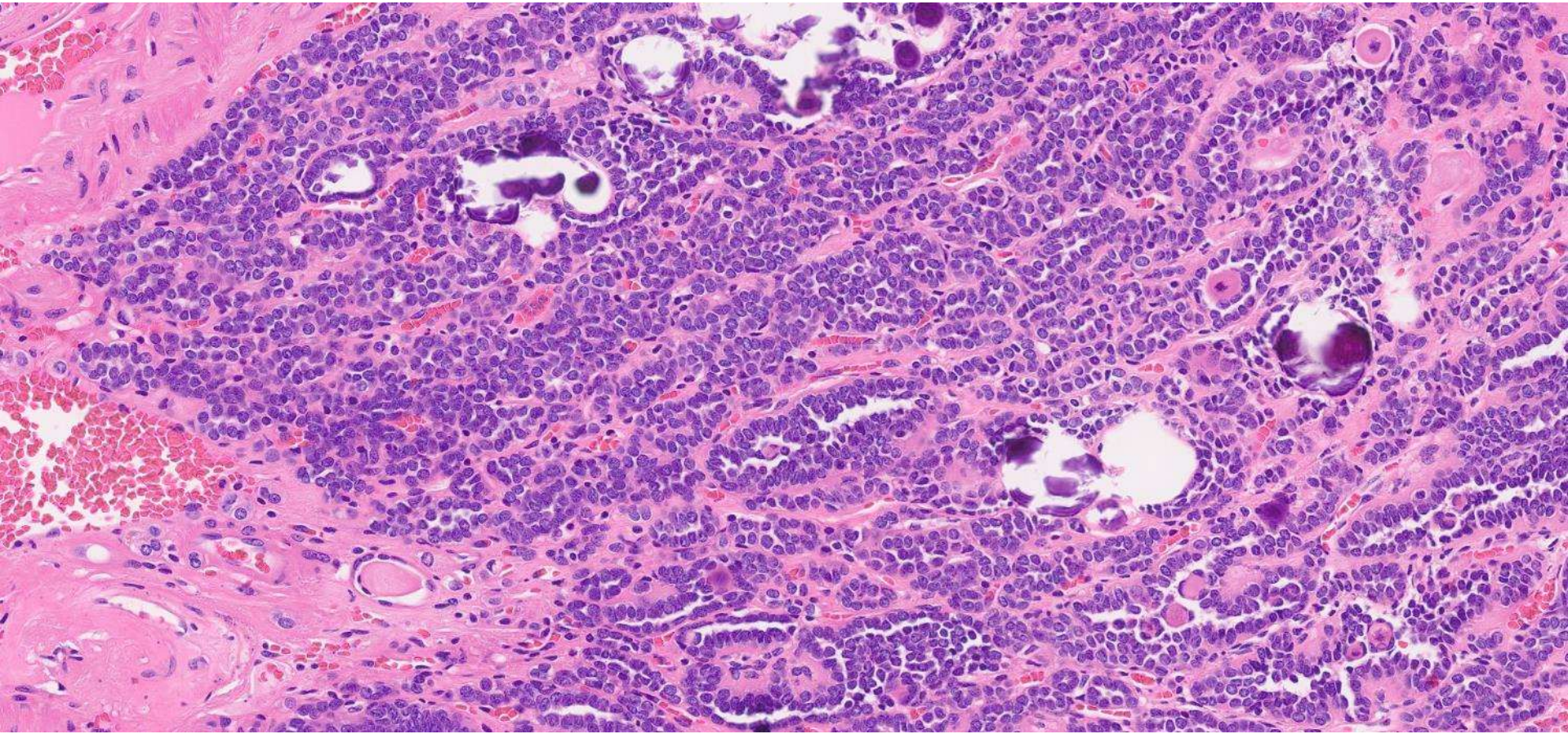
81-year-old F with 4.7cm renal mass, radical nephrectomy performed.

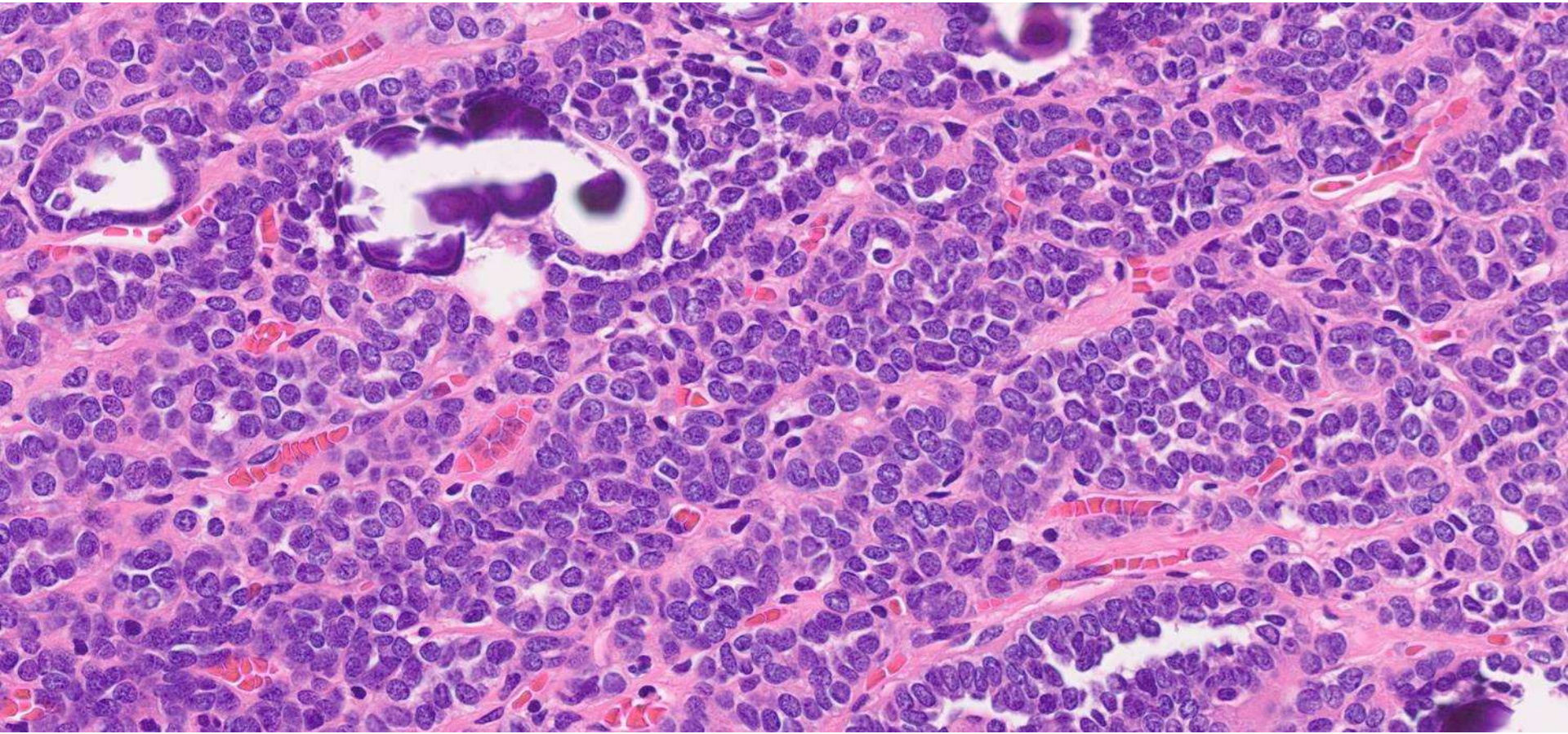


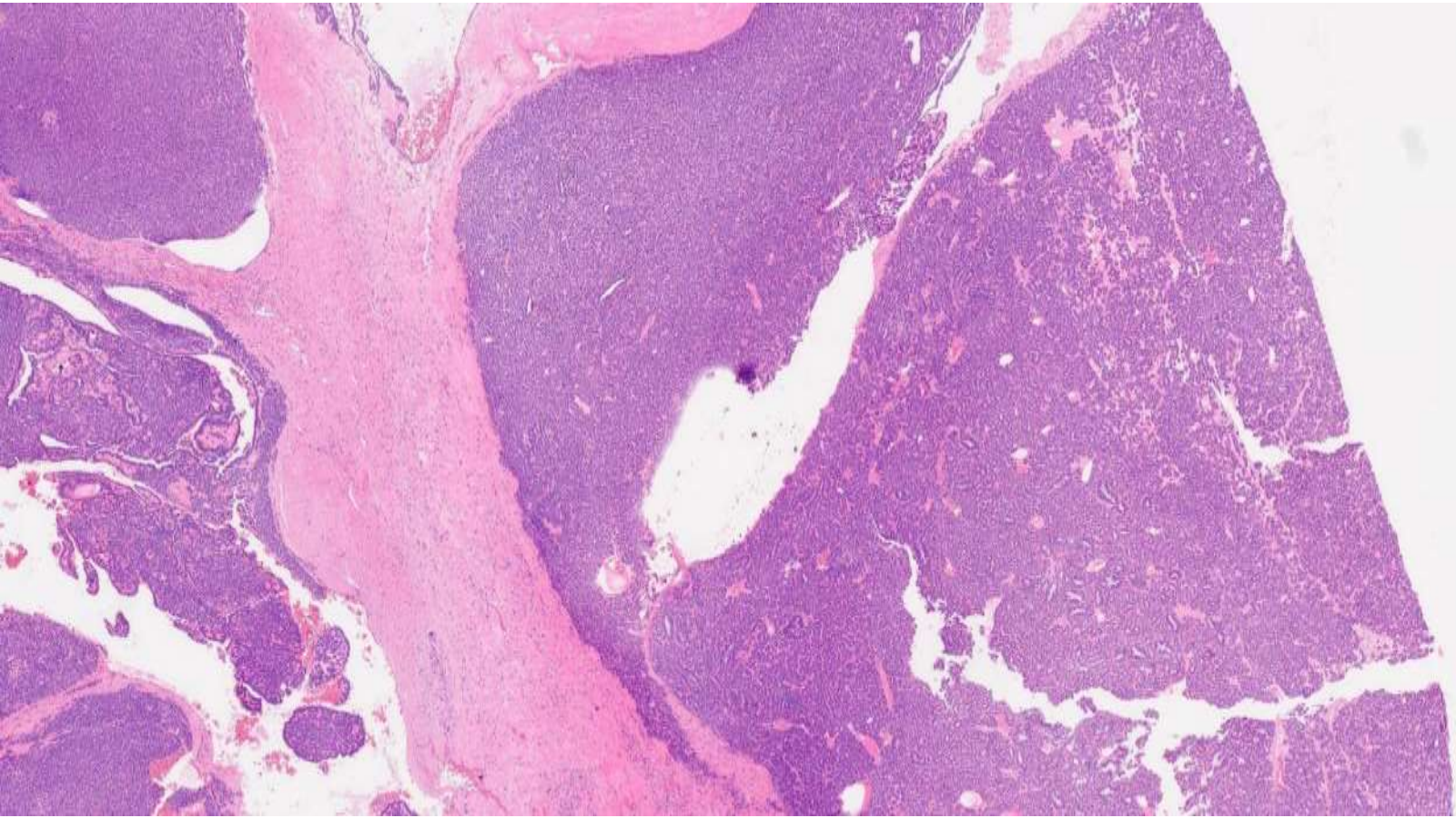


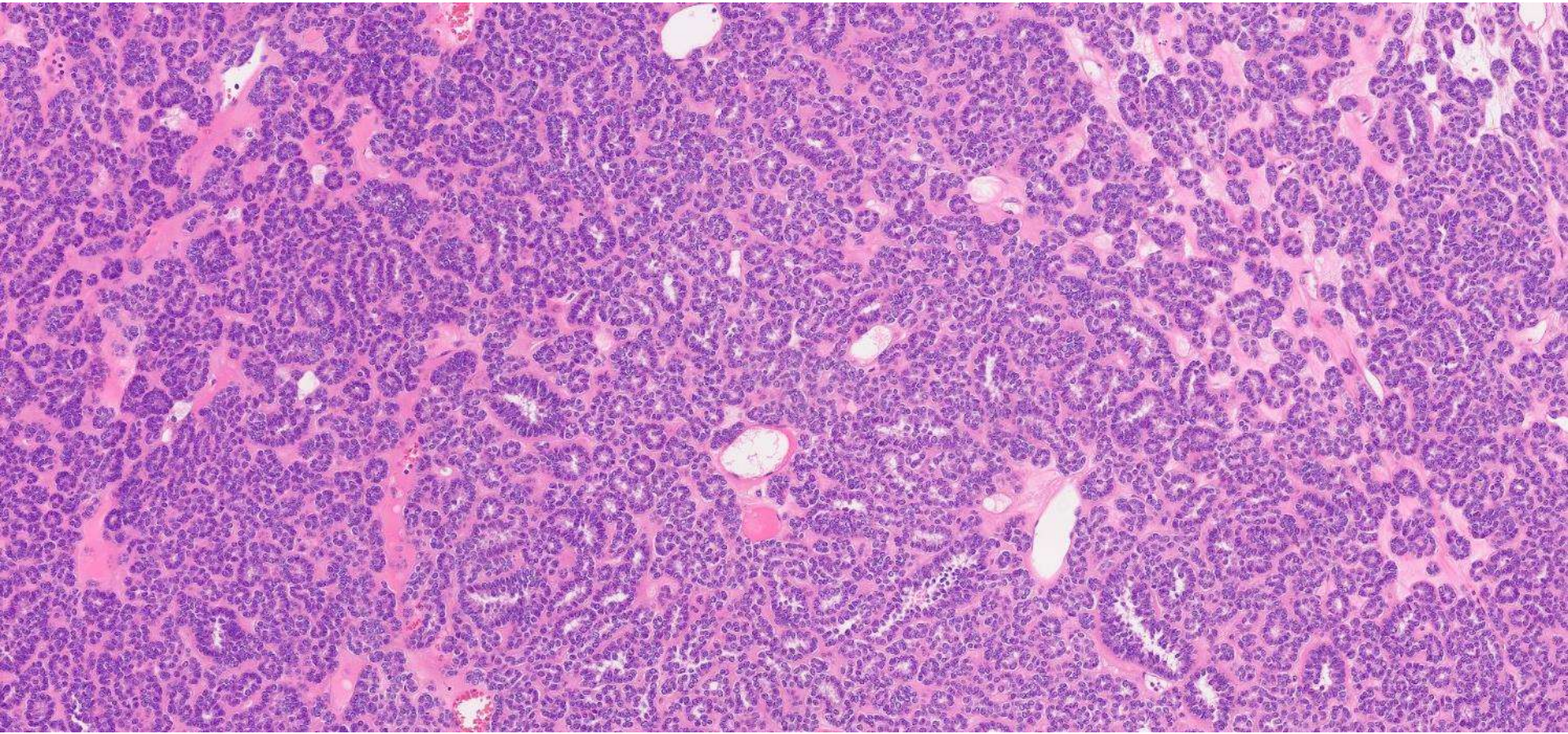


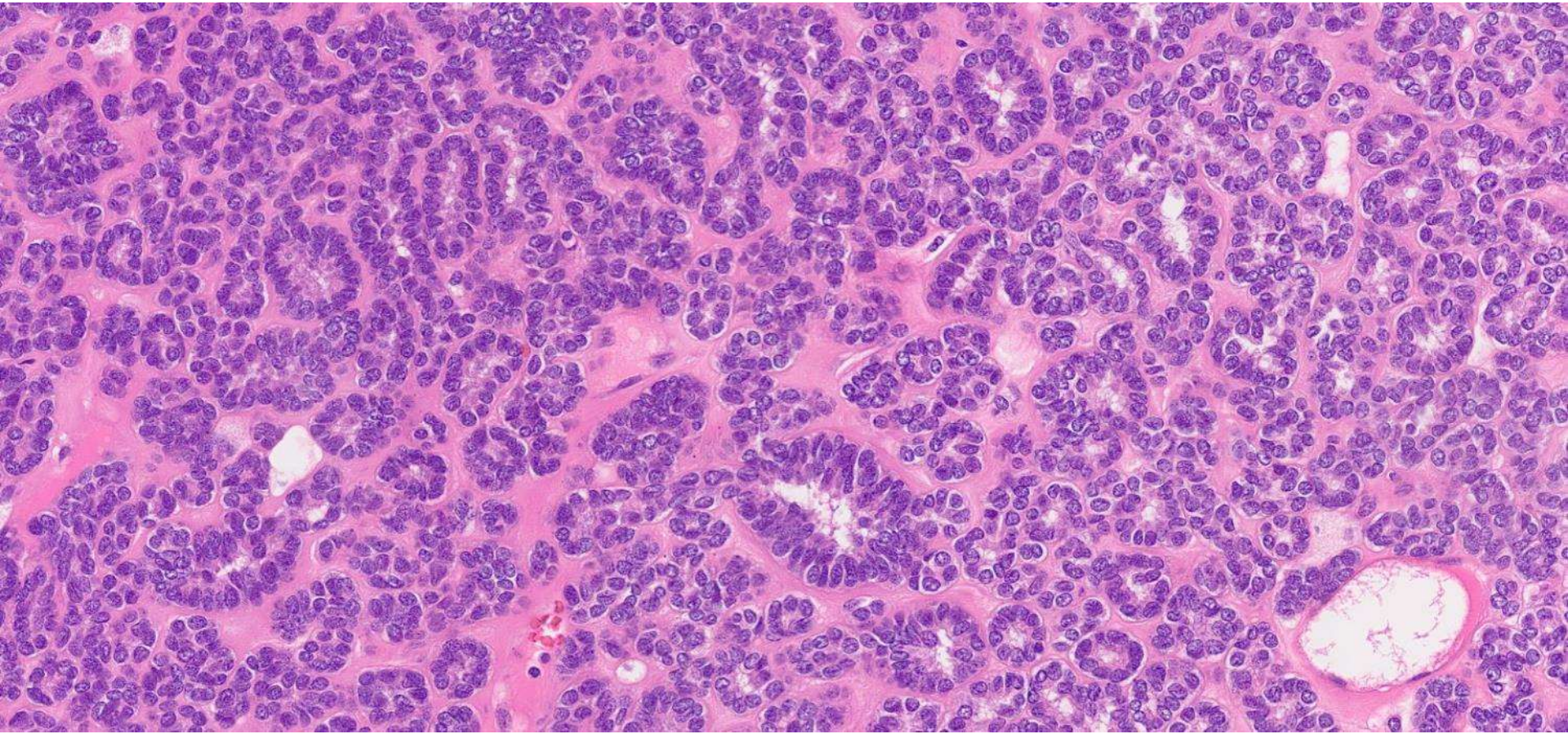


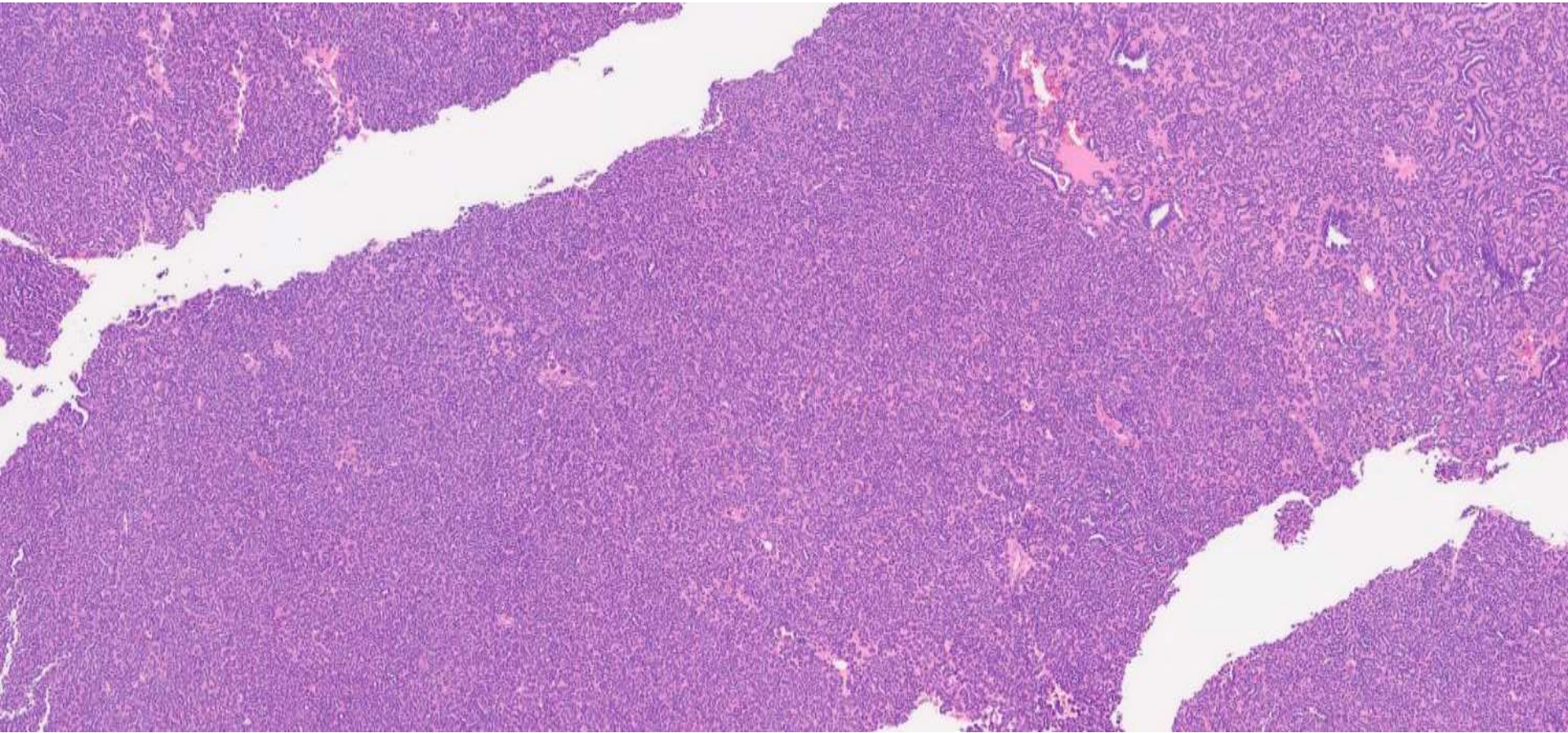


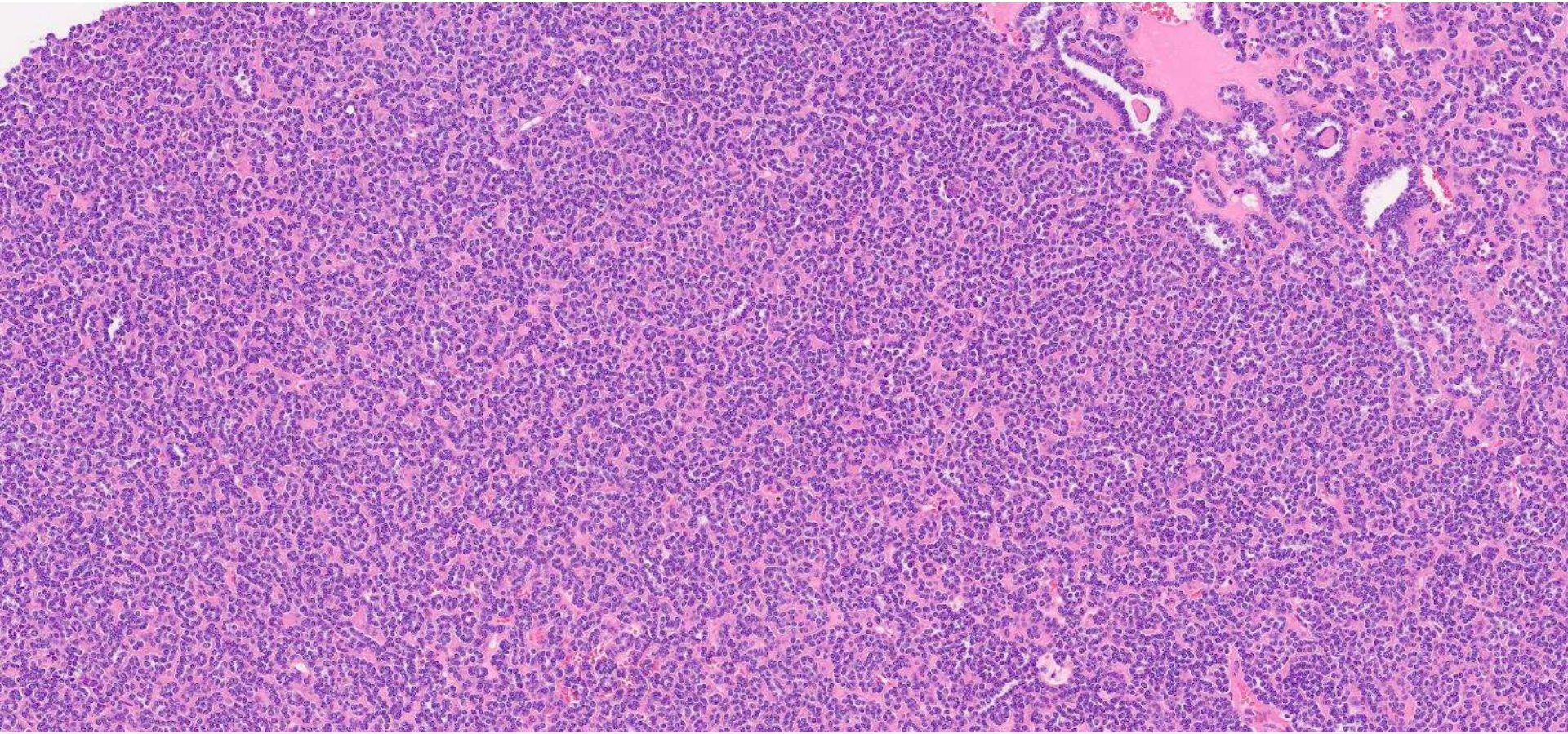


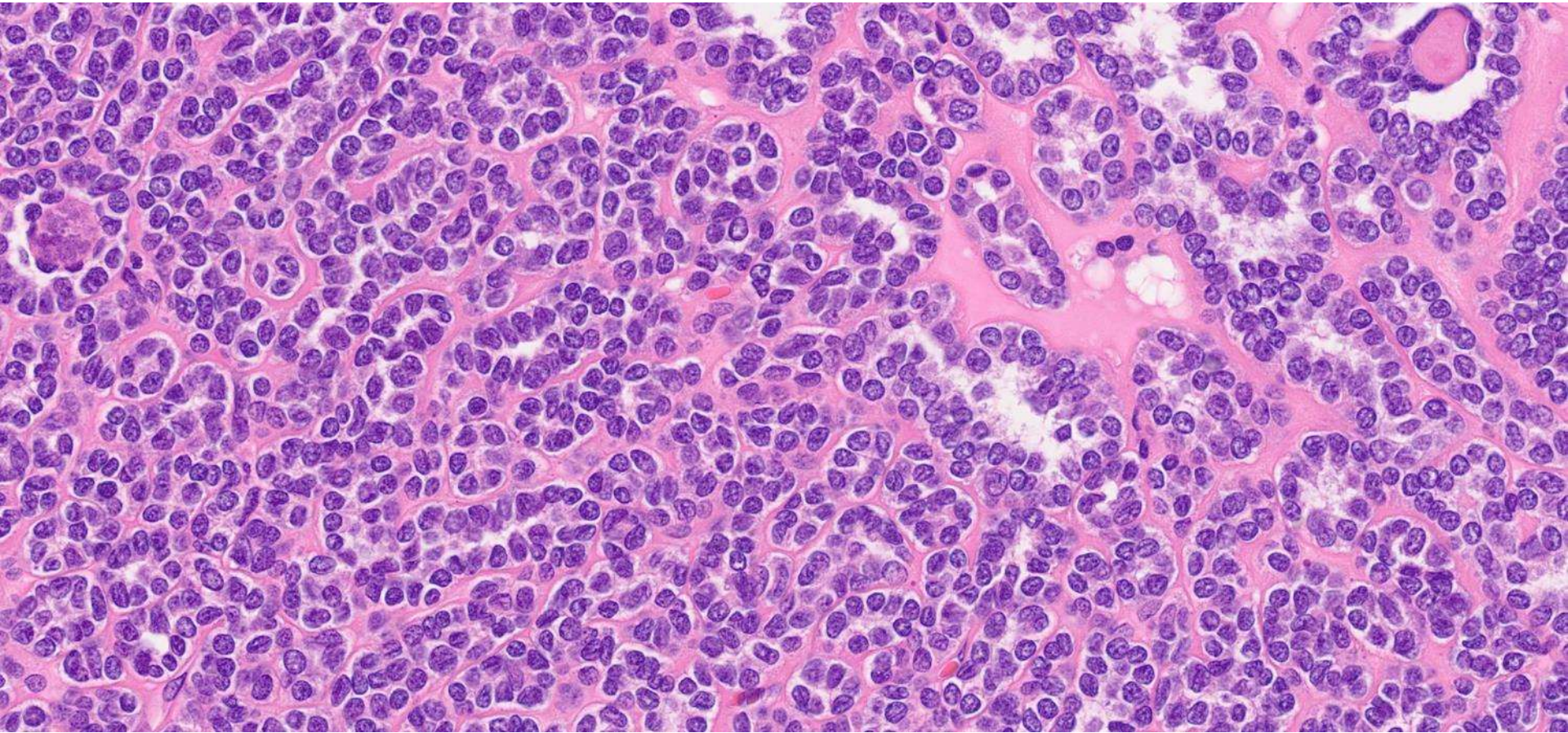














21-1007

Ankur Sangoi; El Camino Hospital

50-year-old F undergoes TAH for endometrial cancer. Frozen section of endomyometrium performed.

