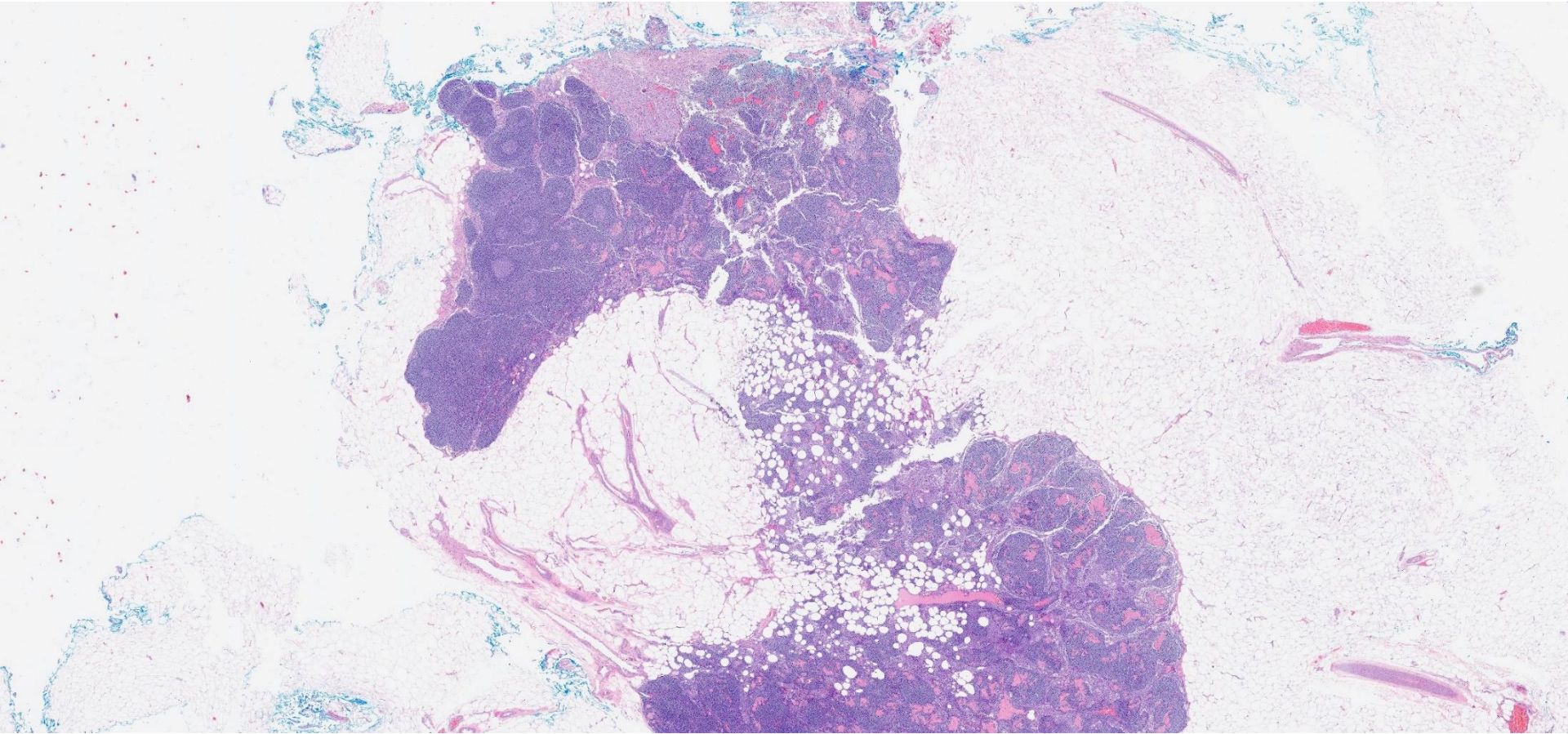
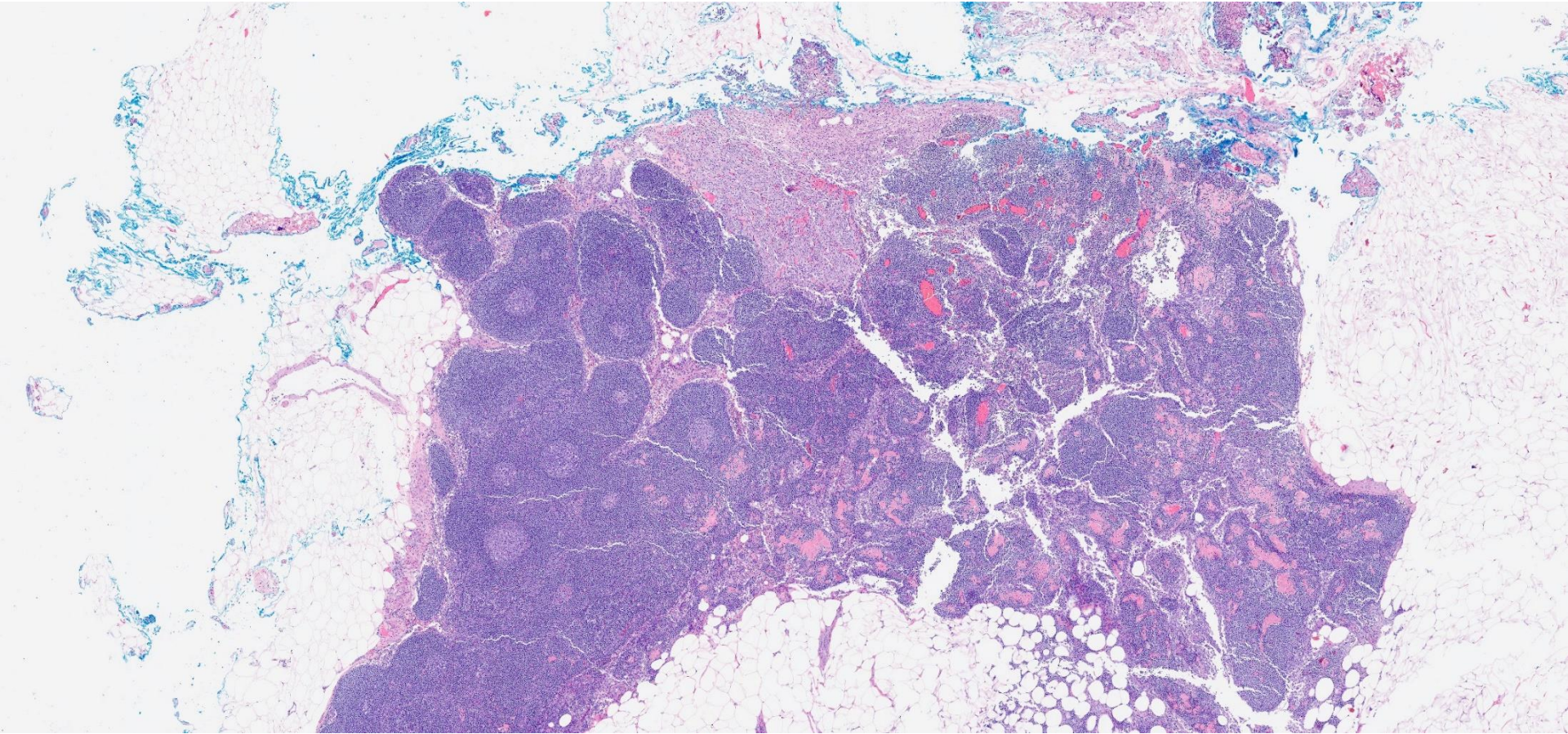


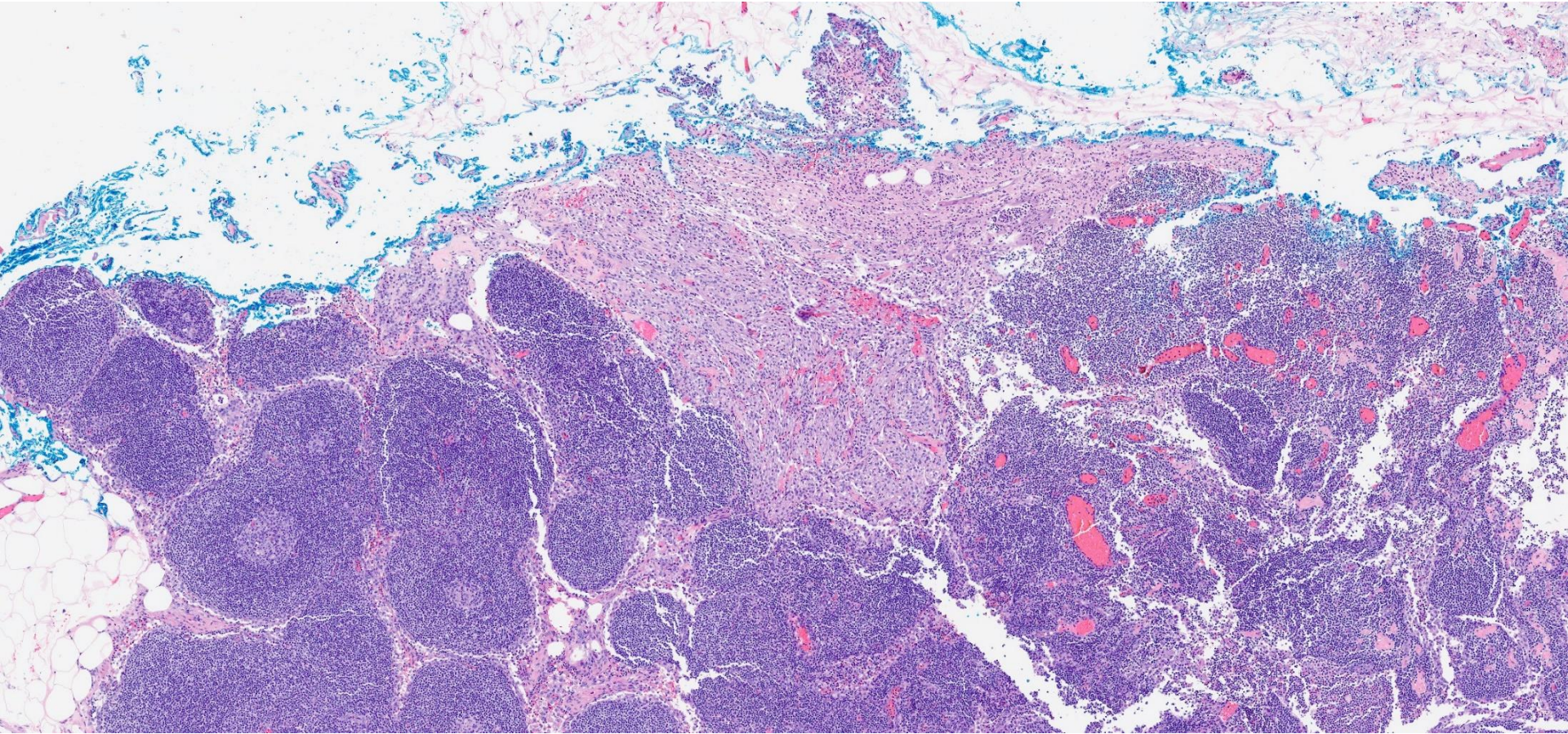
21-0801

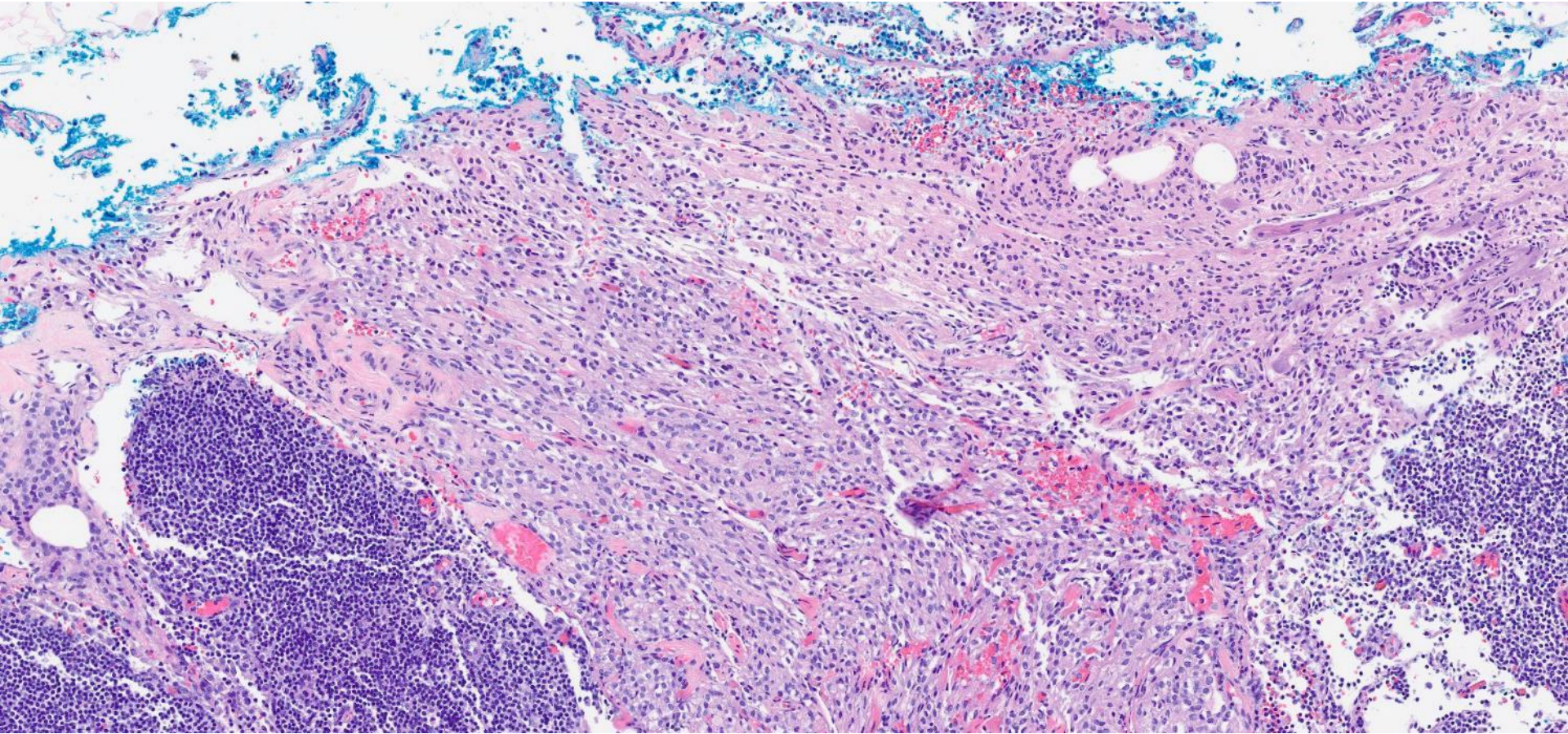
Keith Duncan; Mills-Peninsula

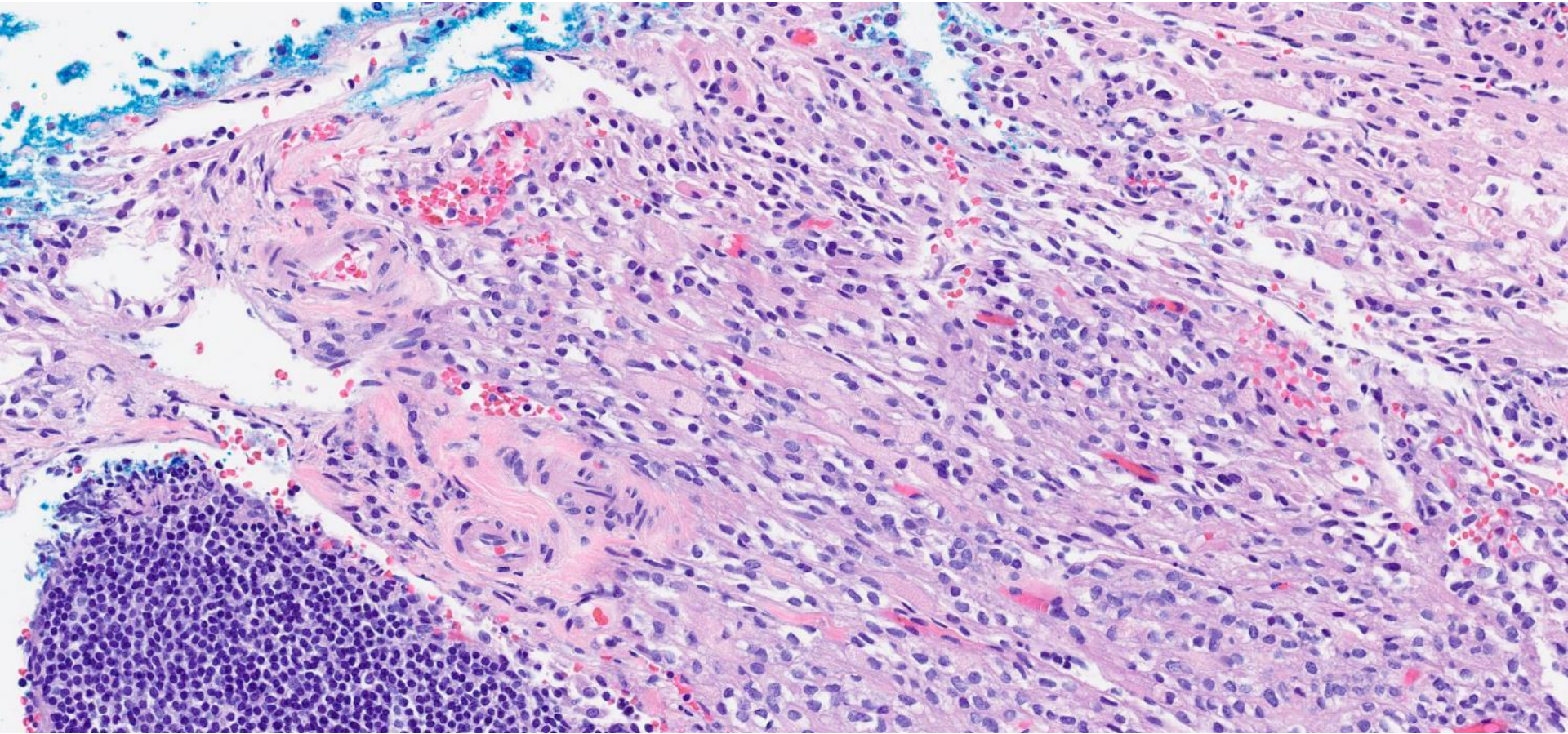
53-year-old F underwent TAH/BSO for complex atypical hyperplasia. Sentinel lymph node bx shown.

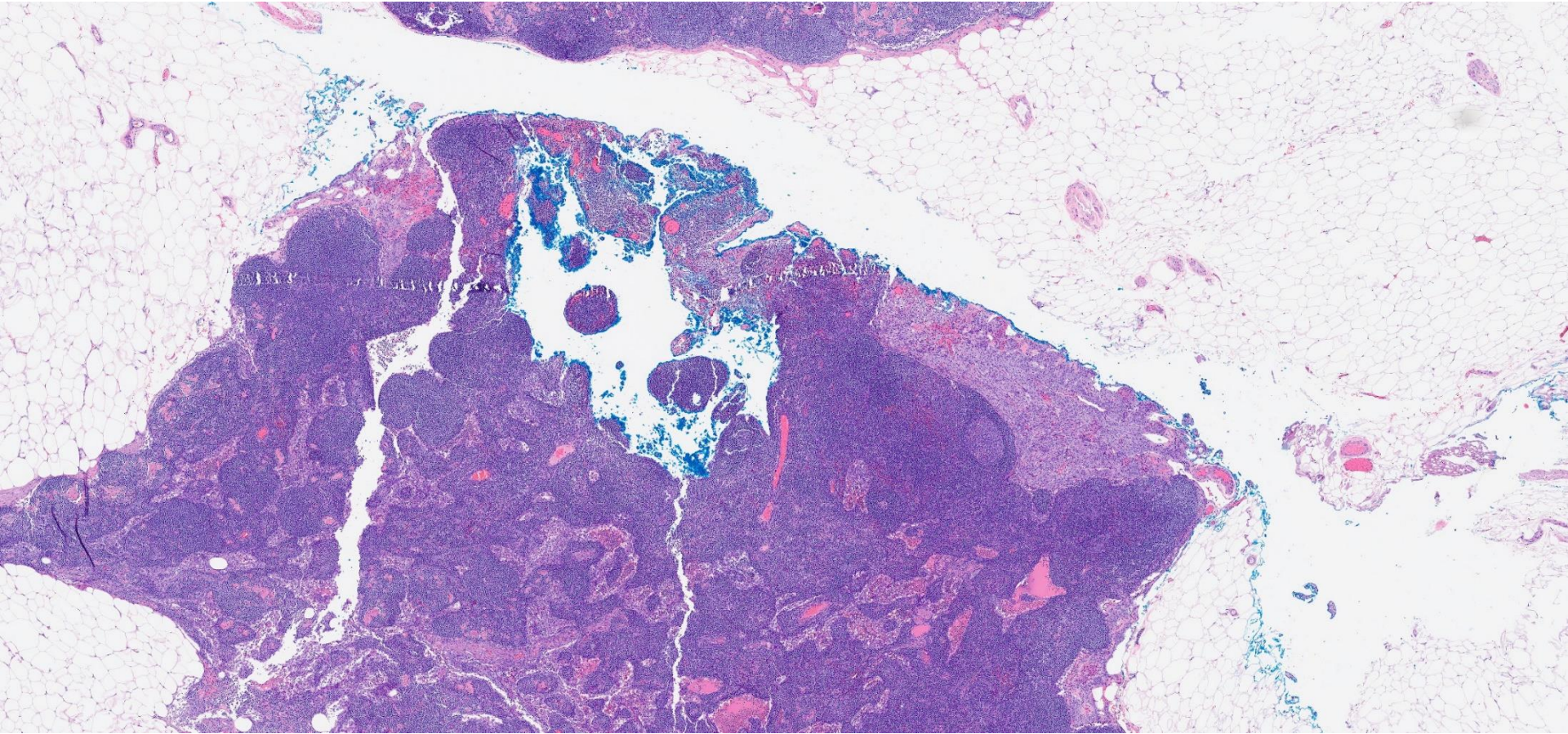


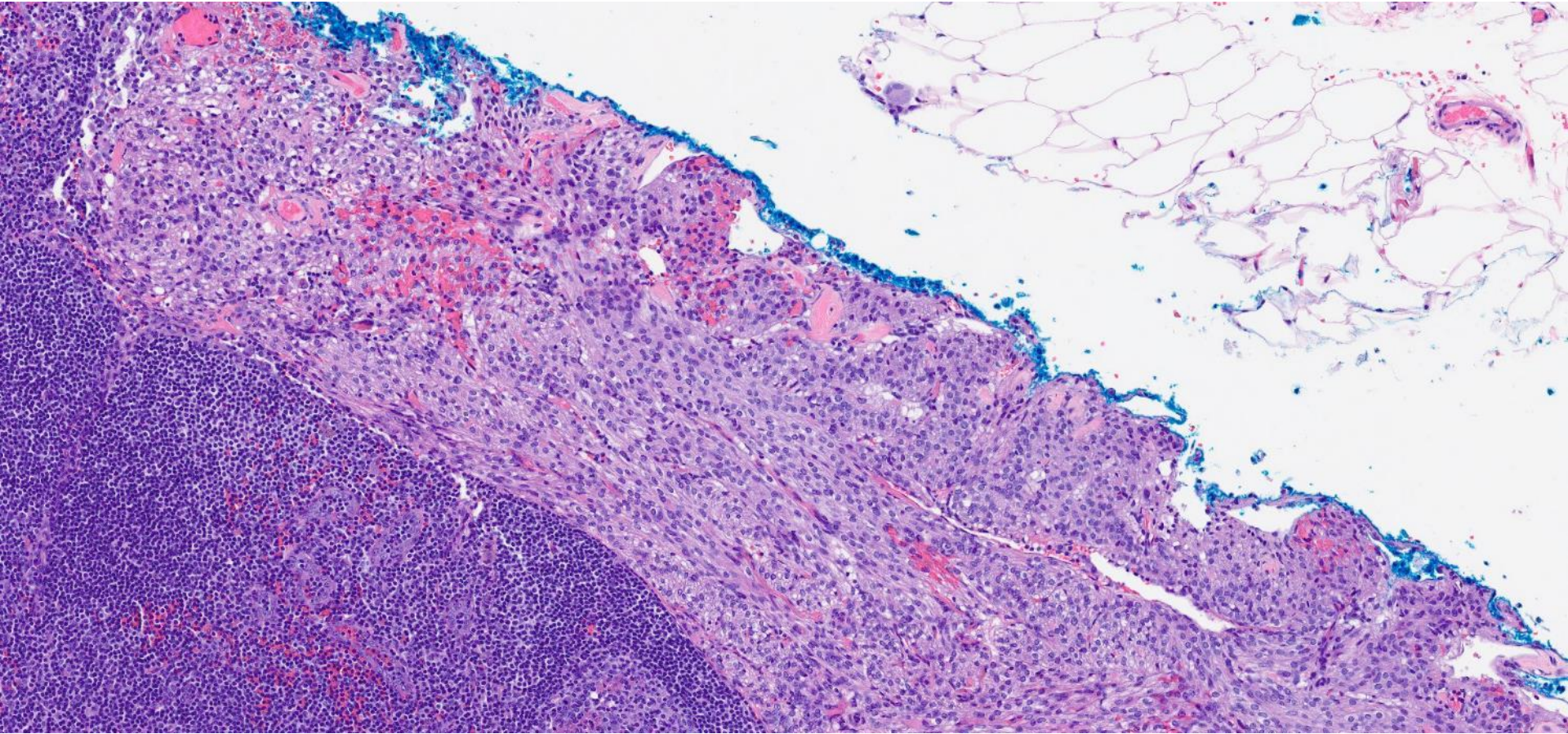


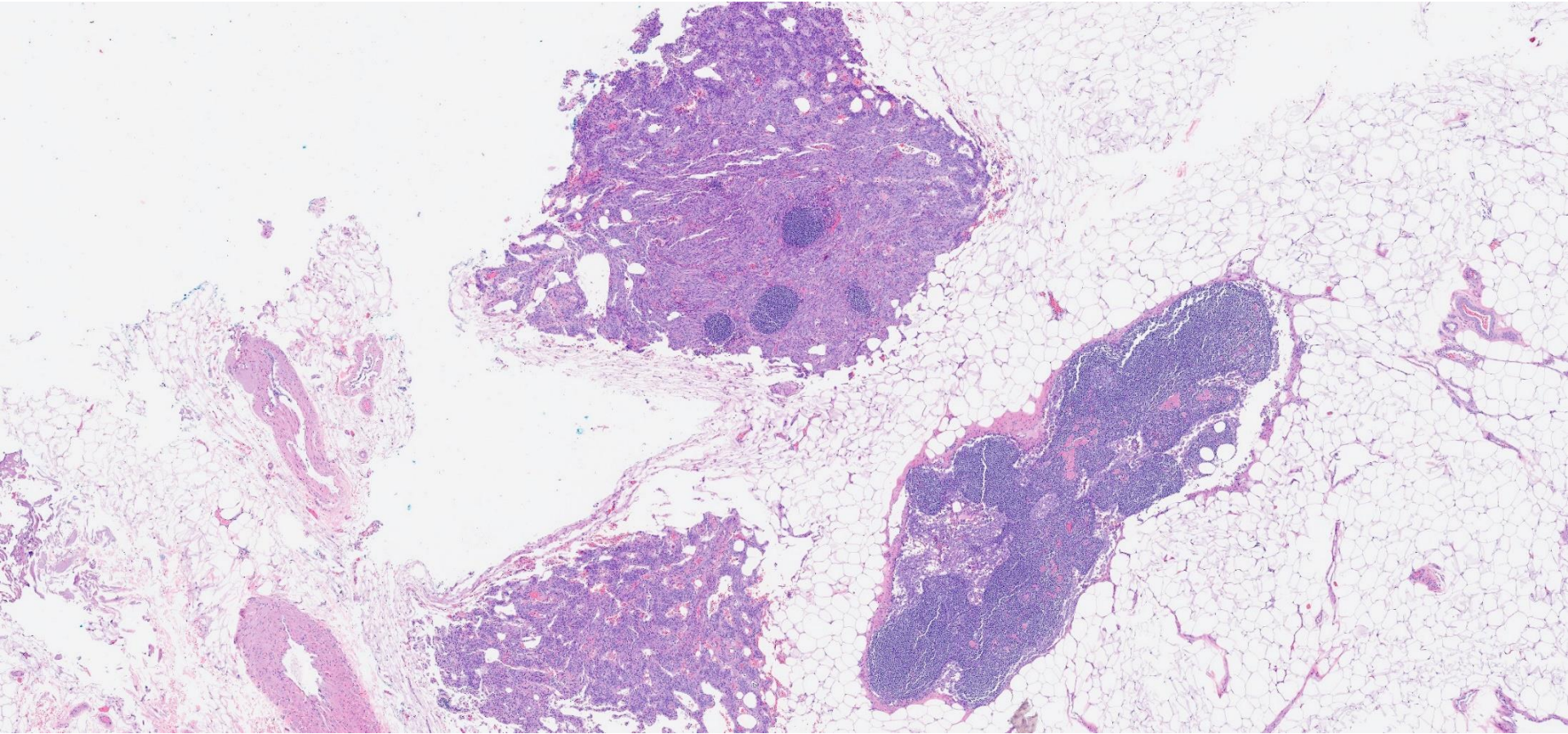


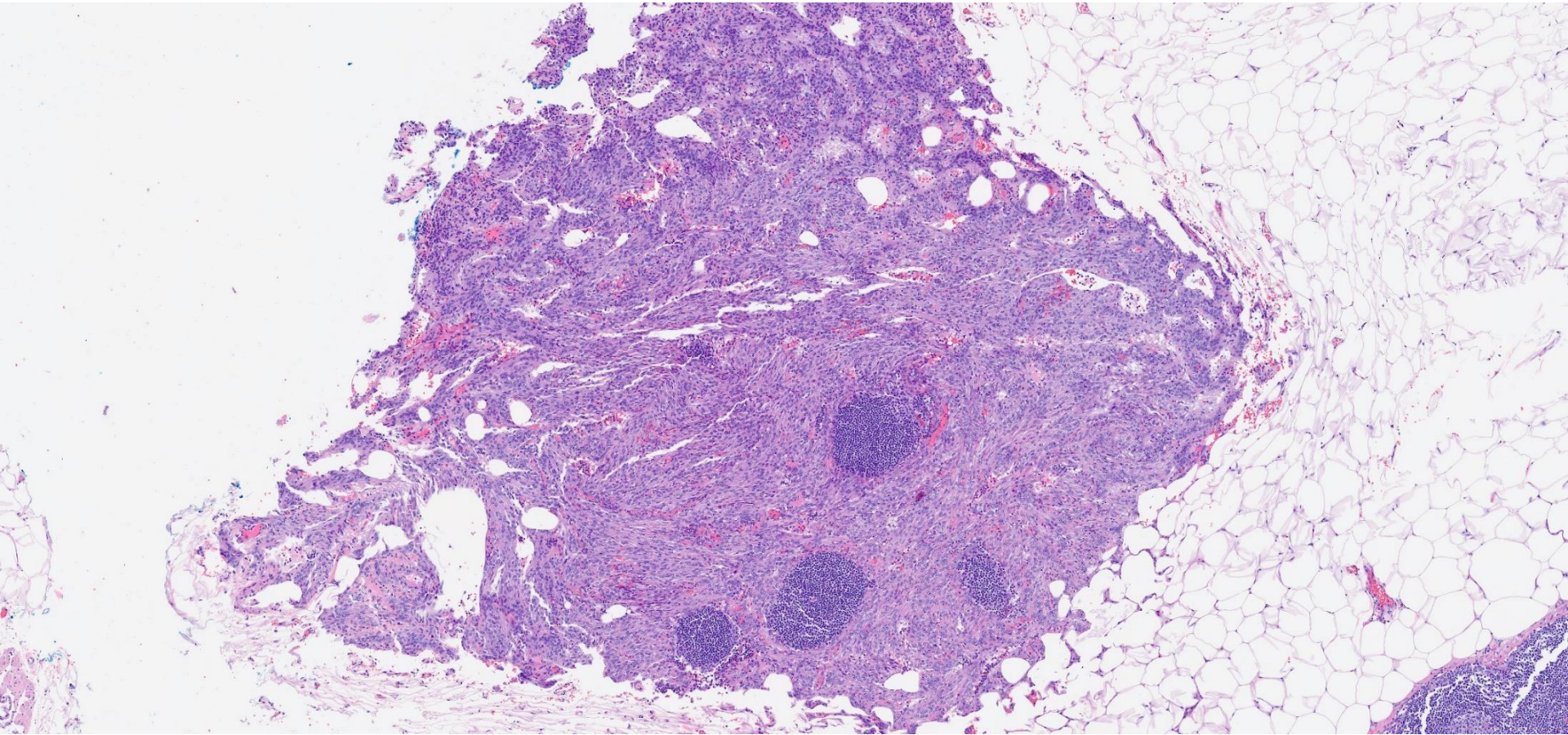


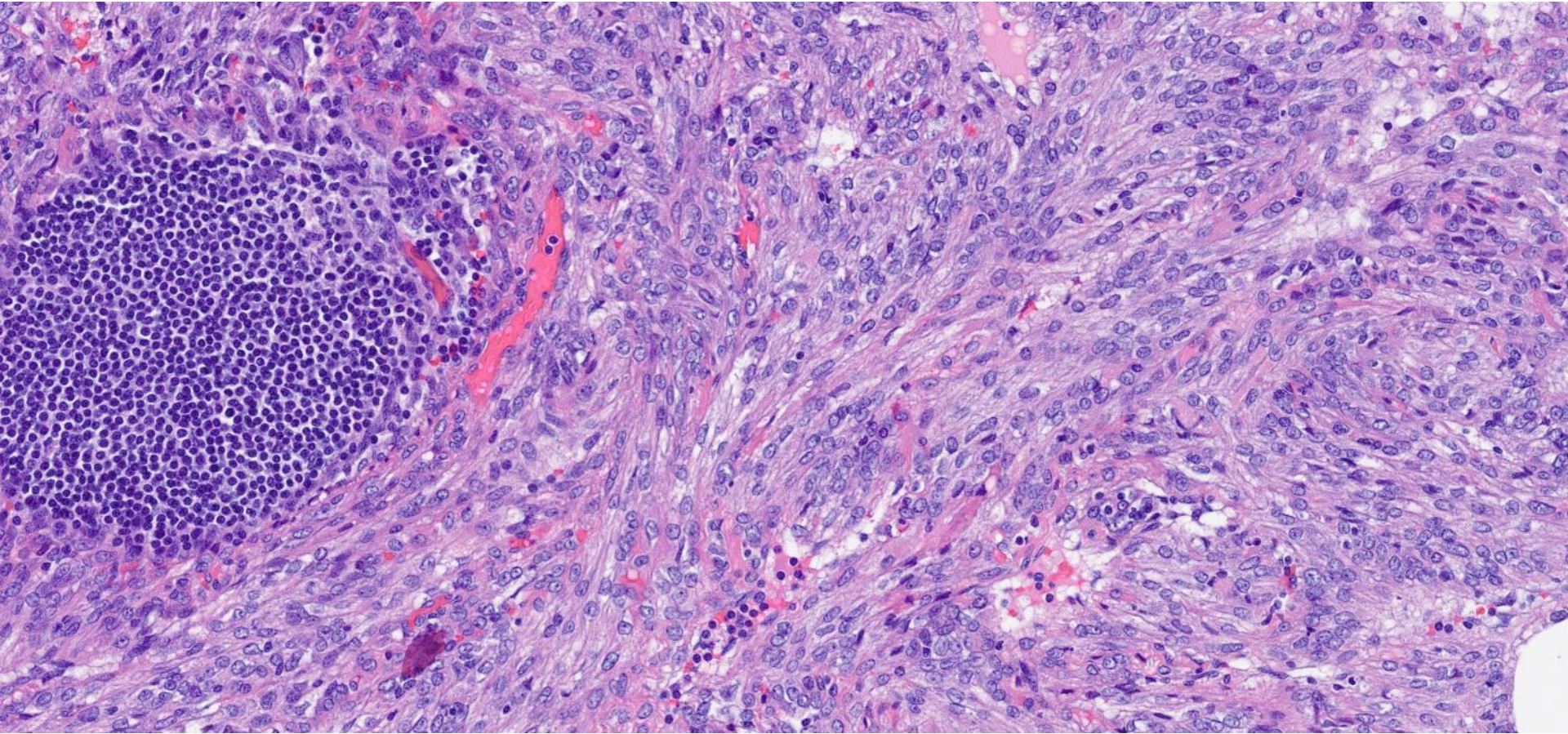


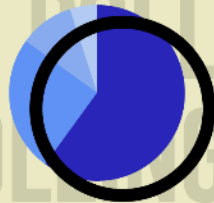







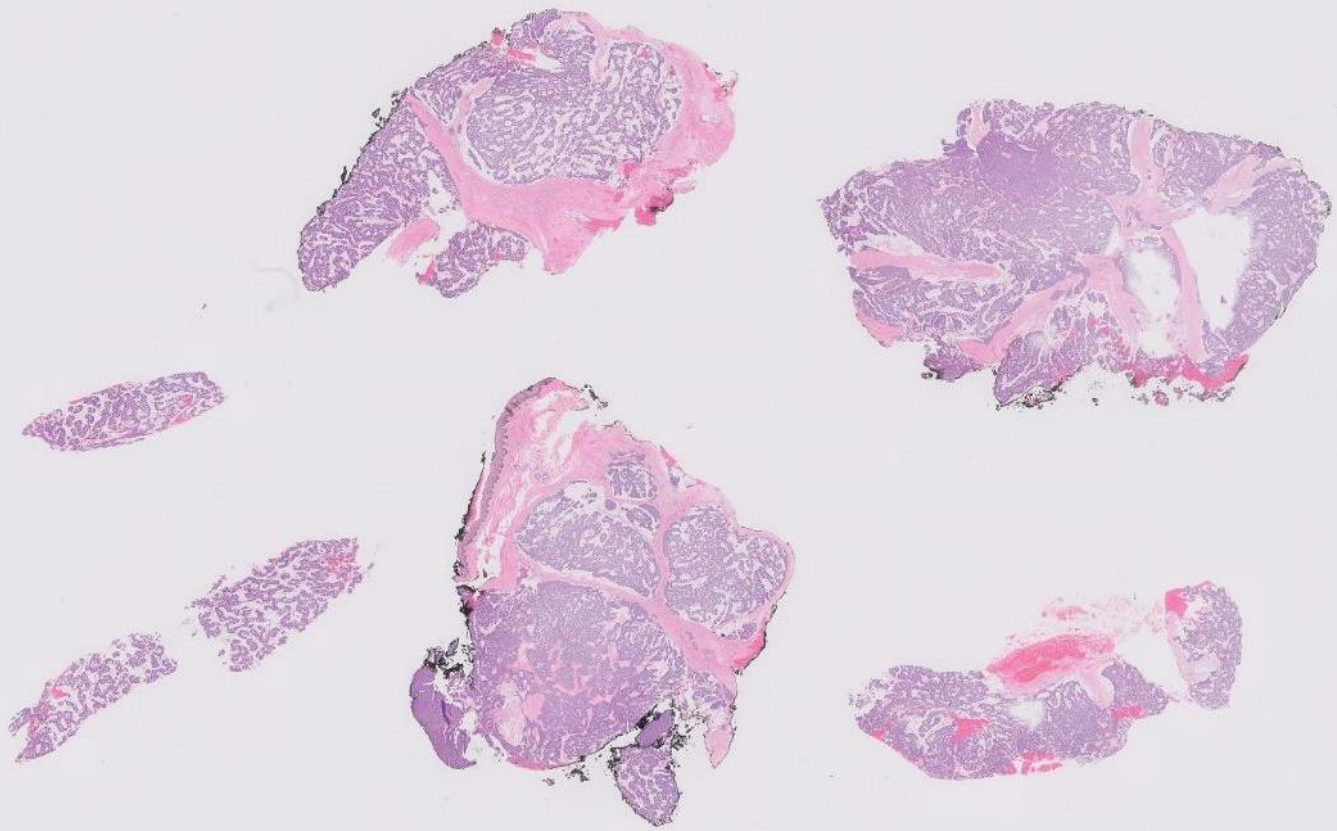


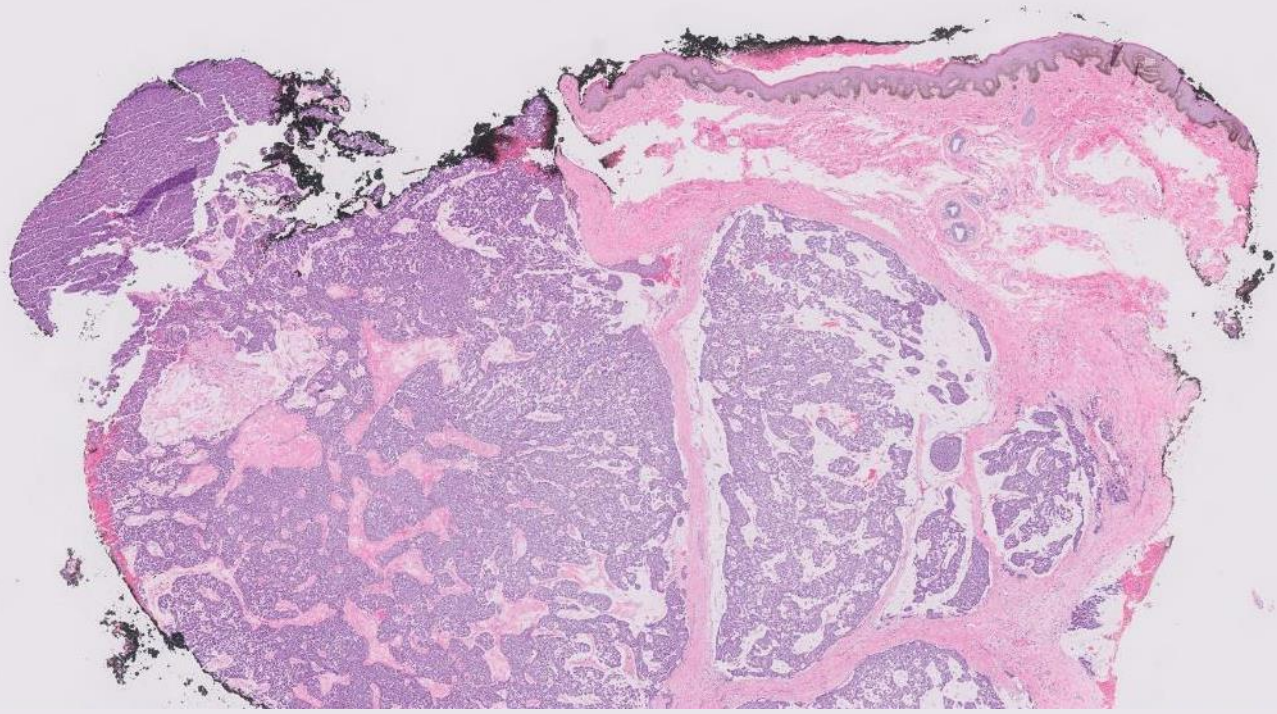


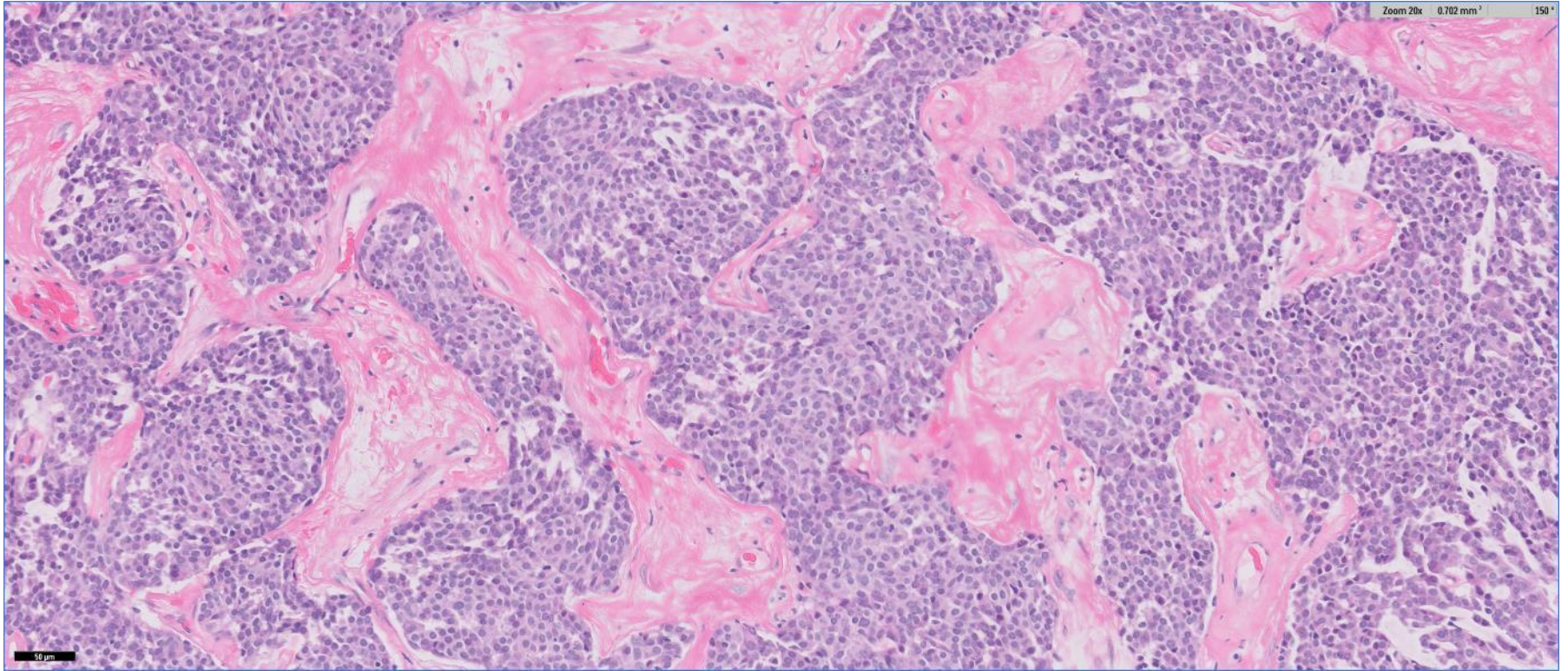
21-0802

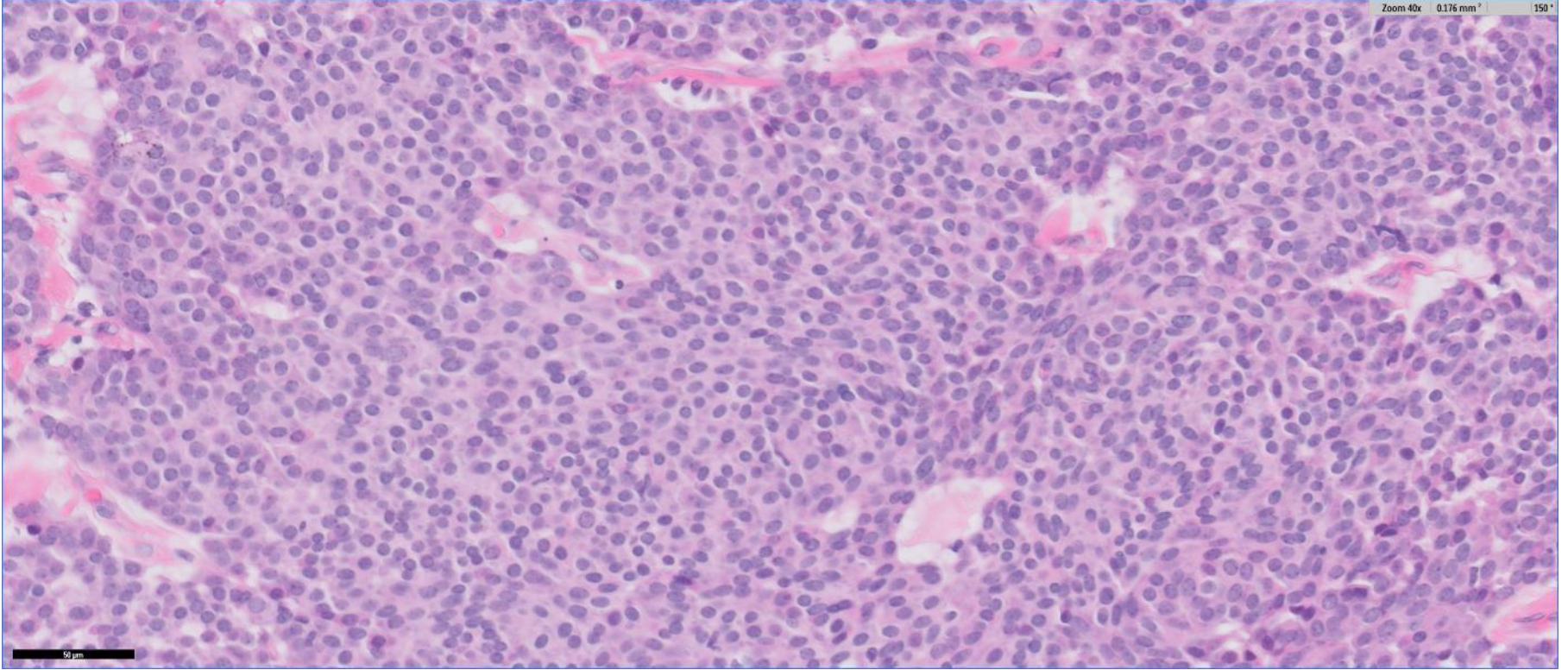
Nicholas Ladwig; UCSF

73-year-old F with non-painful, ball-like vulvar mass (3cm) present for 3 months.

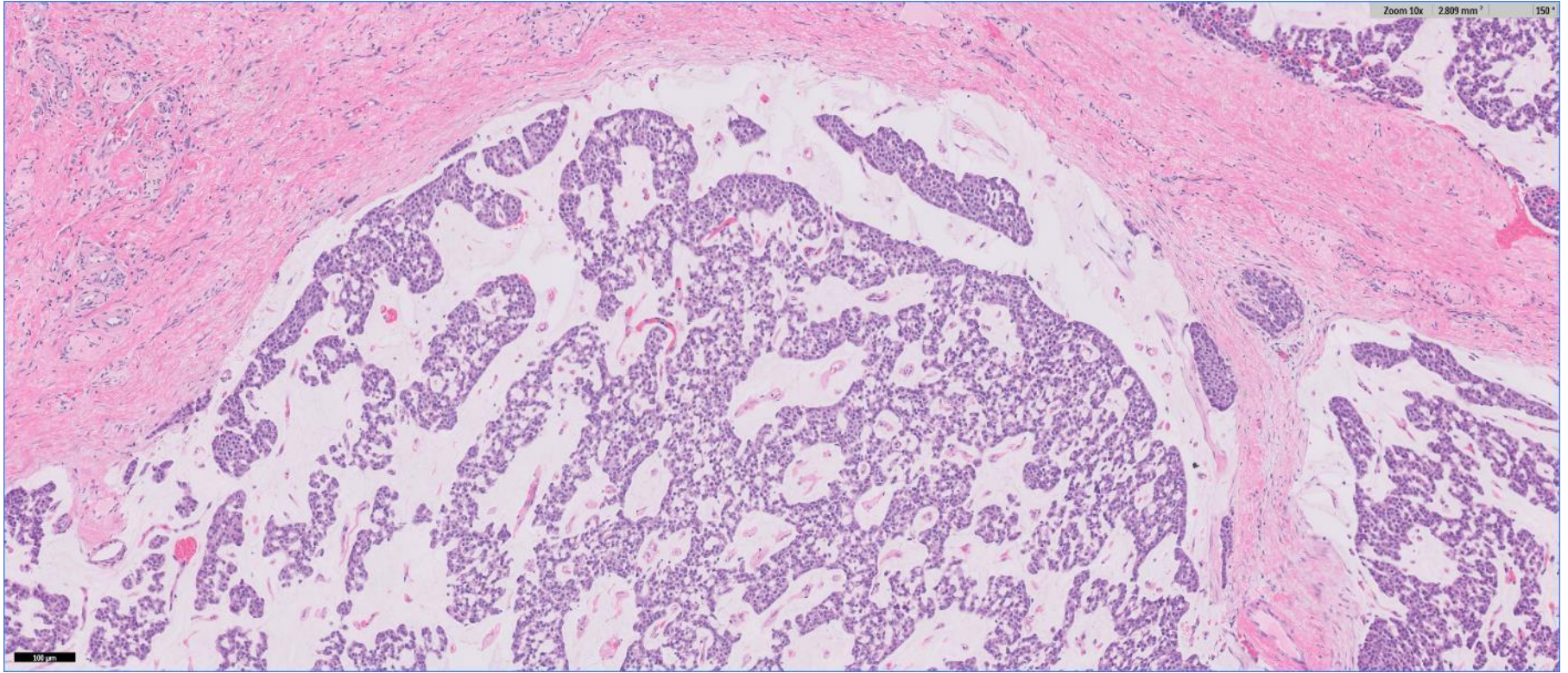


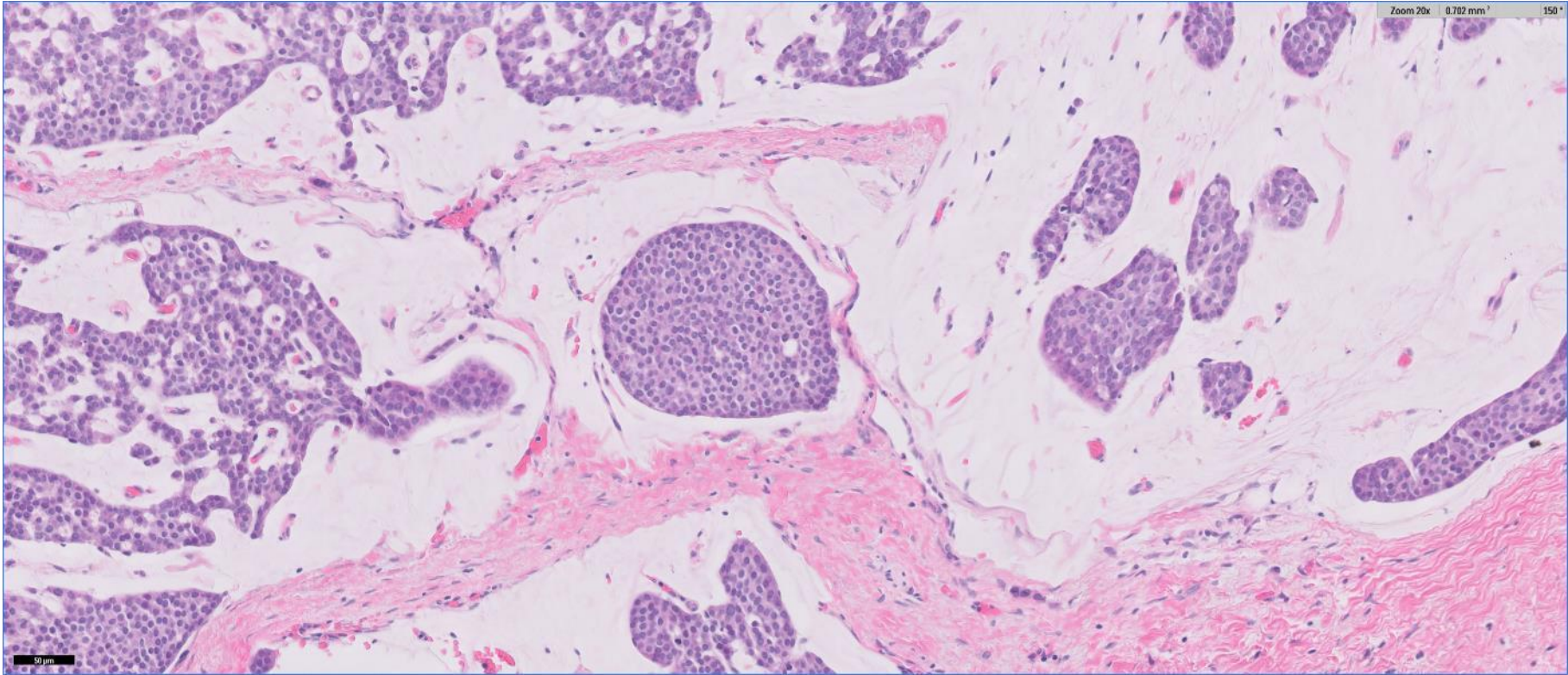






50 µm





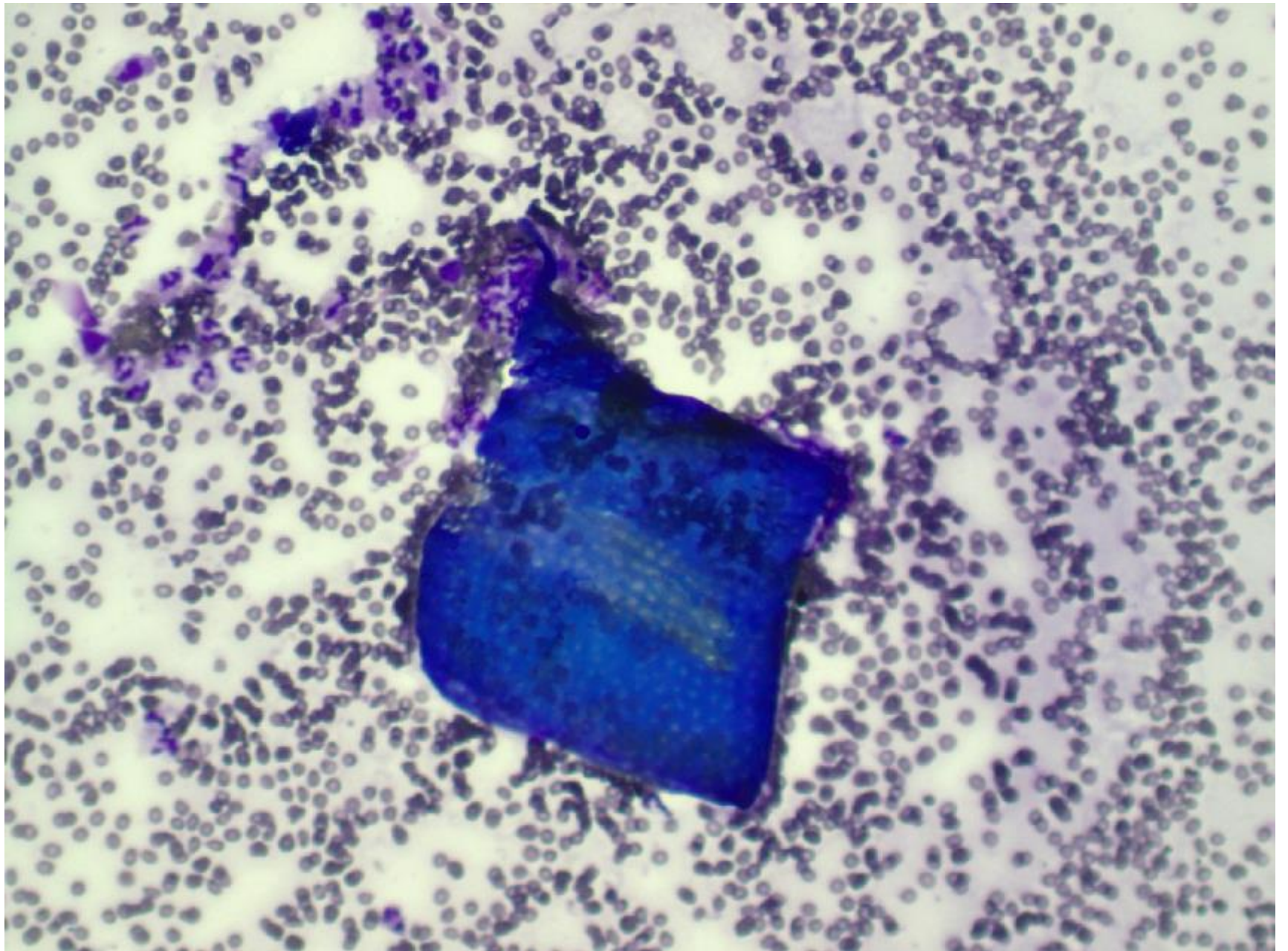
50 μm

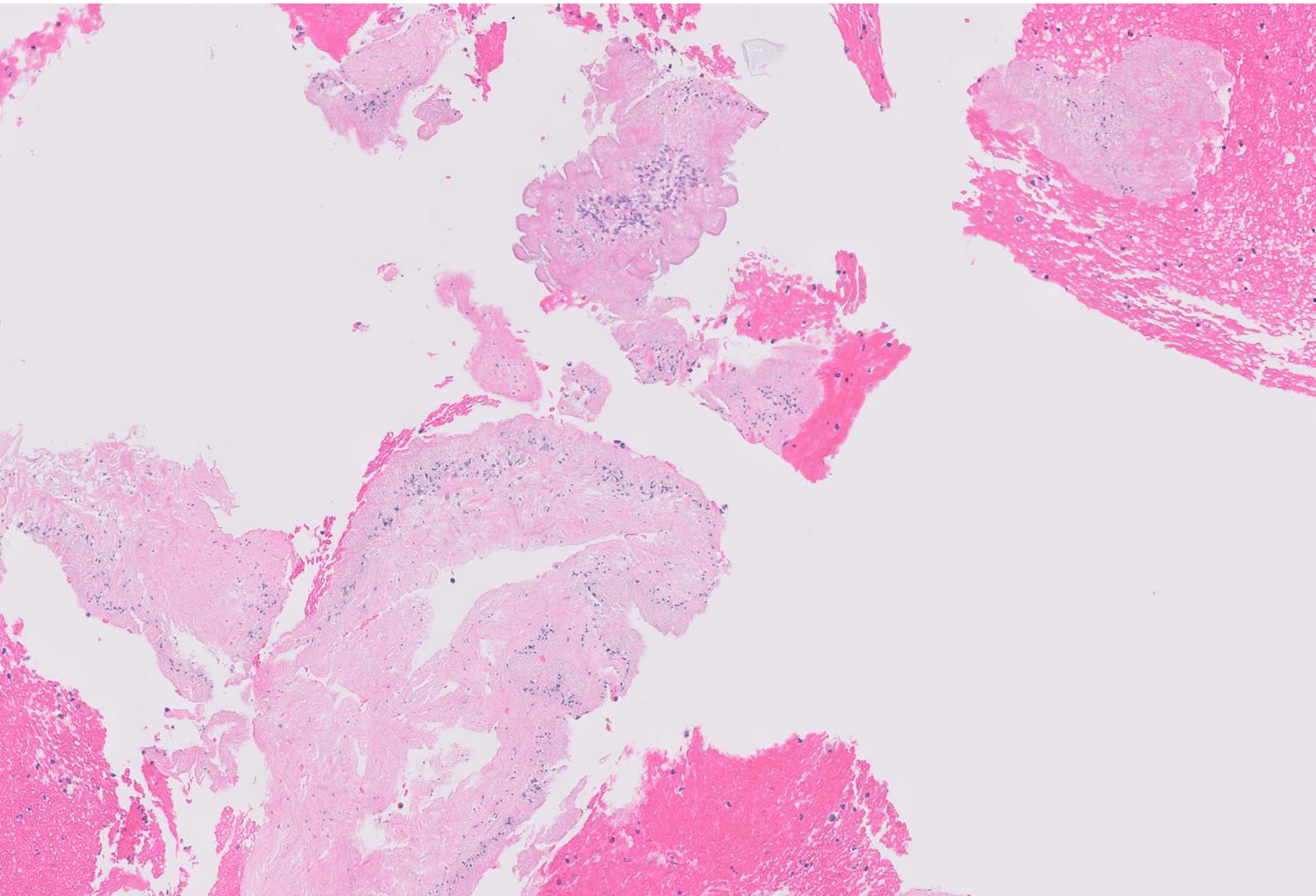


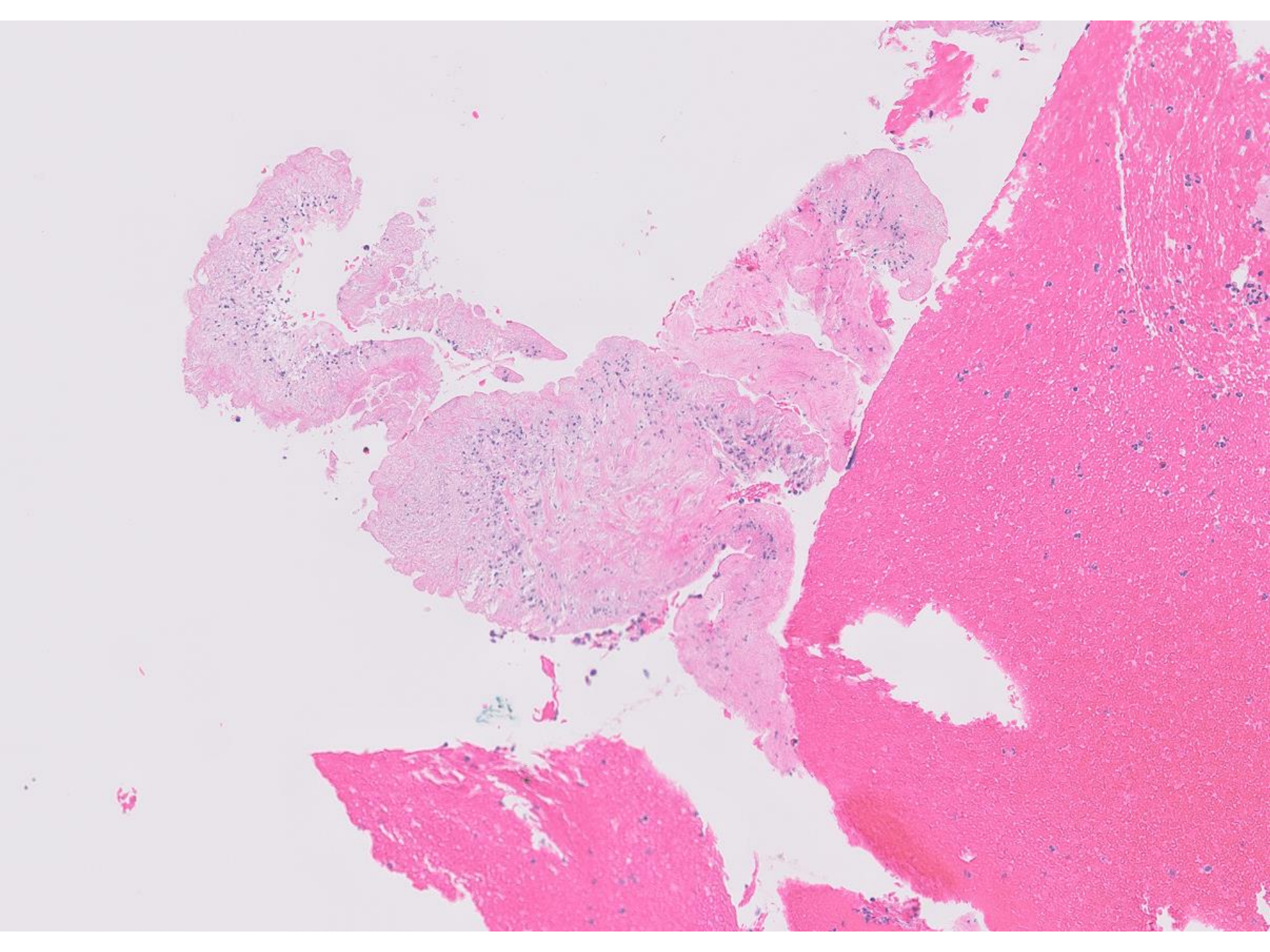
21-0803

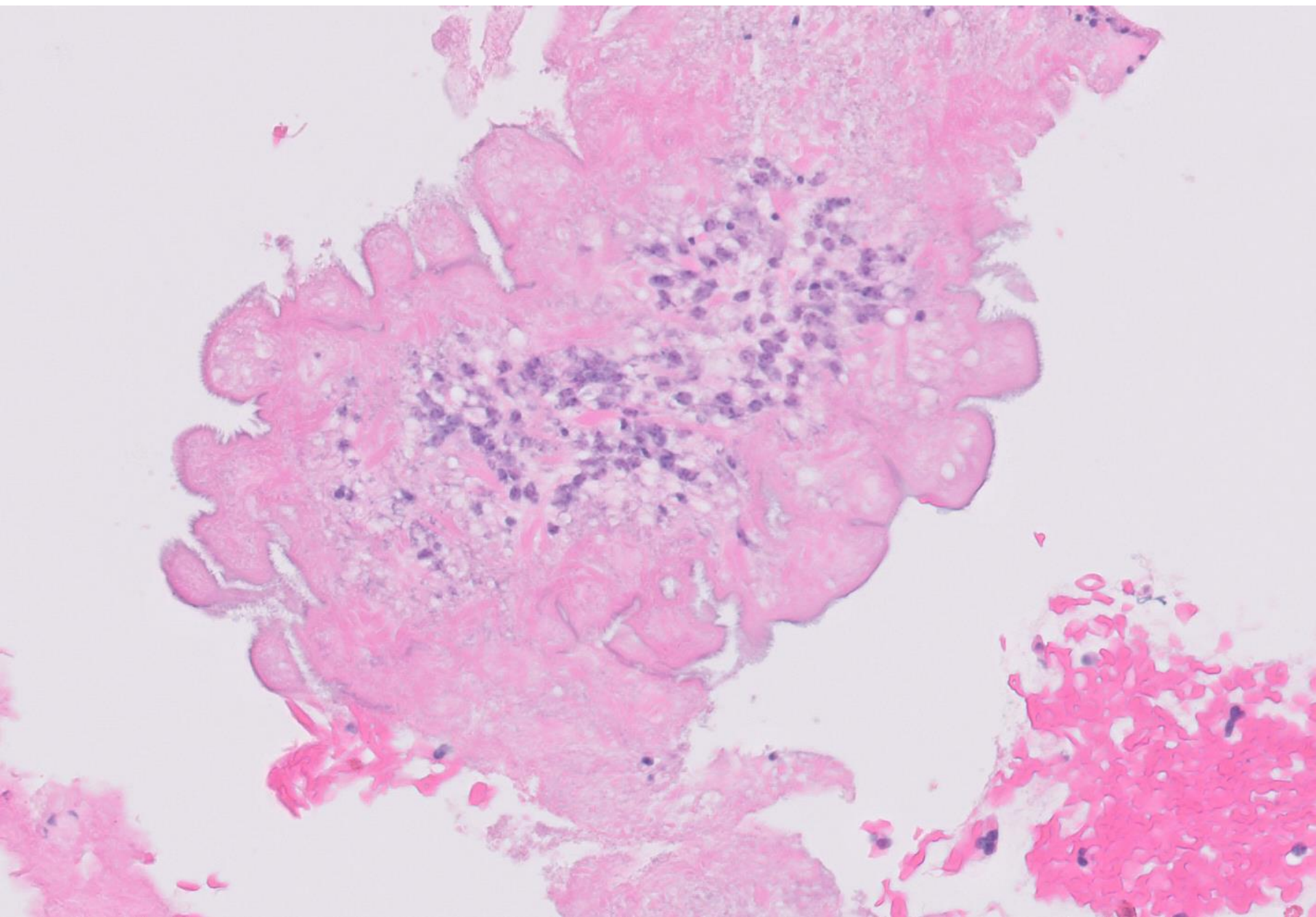
Marie Perrone; Cascade Pathology Services; Portland, OR

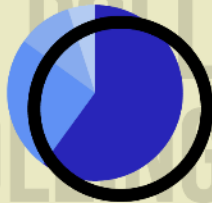69-year-old M with cystic posterior neck lump. MRI reported: well-circumscribed 11x8x22mm right posterior neck cystic mass deep to trapezius, no reduced diffusion to suggest abscess with minimal surrounding stranding to suggest necrotic lymph node; elongated appearance may suggest cystic schwannoma or lymphocele. FNA with cell block performed.







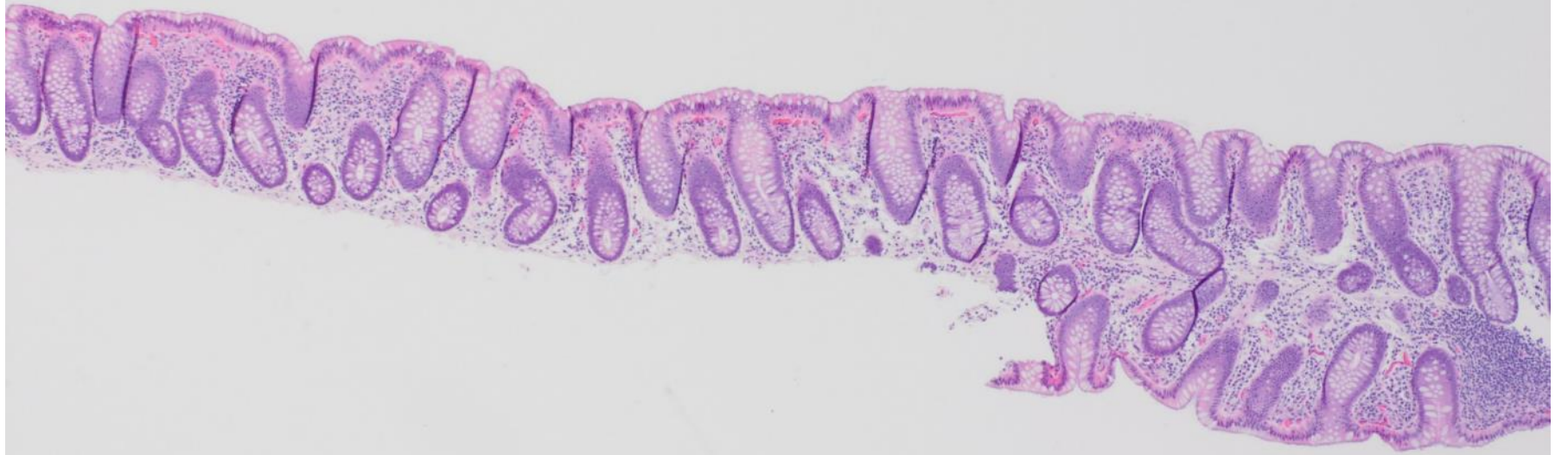


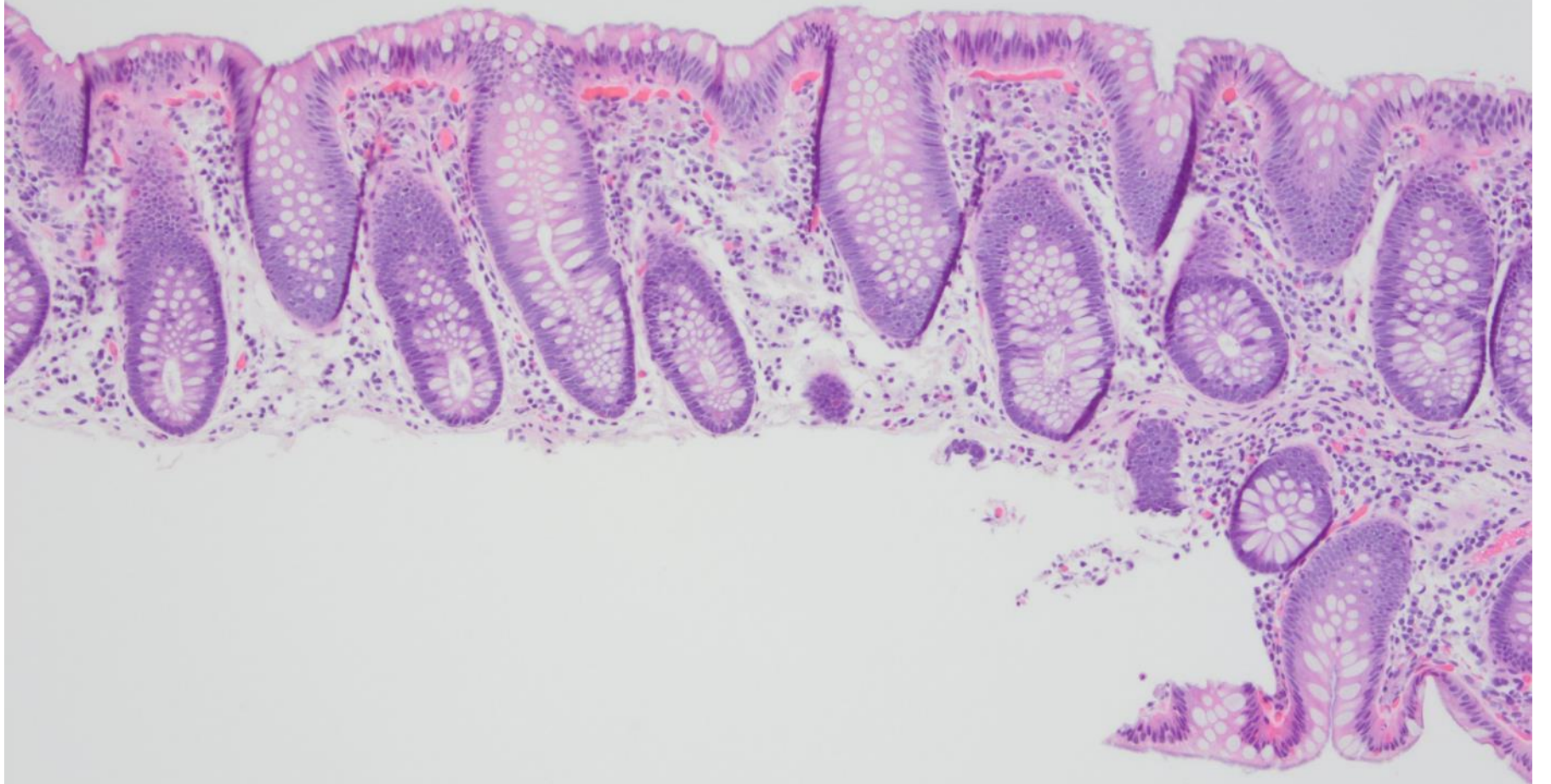


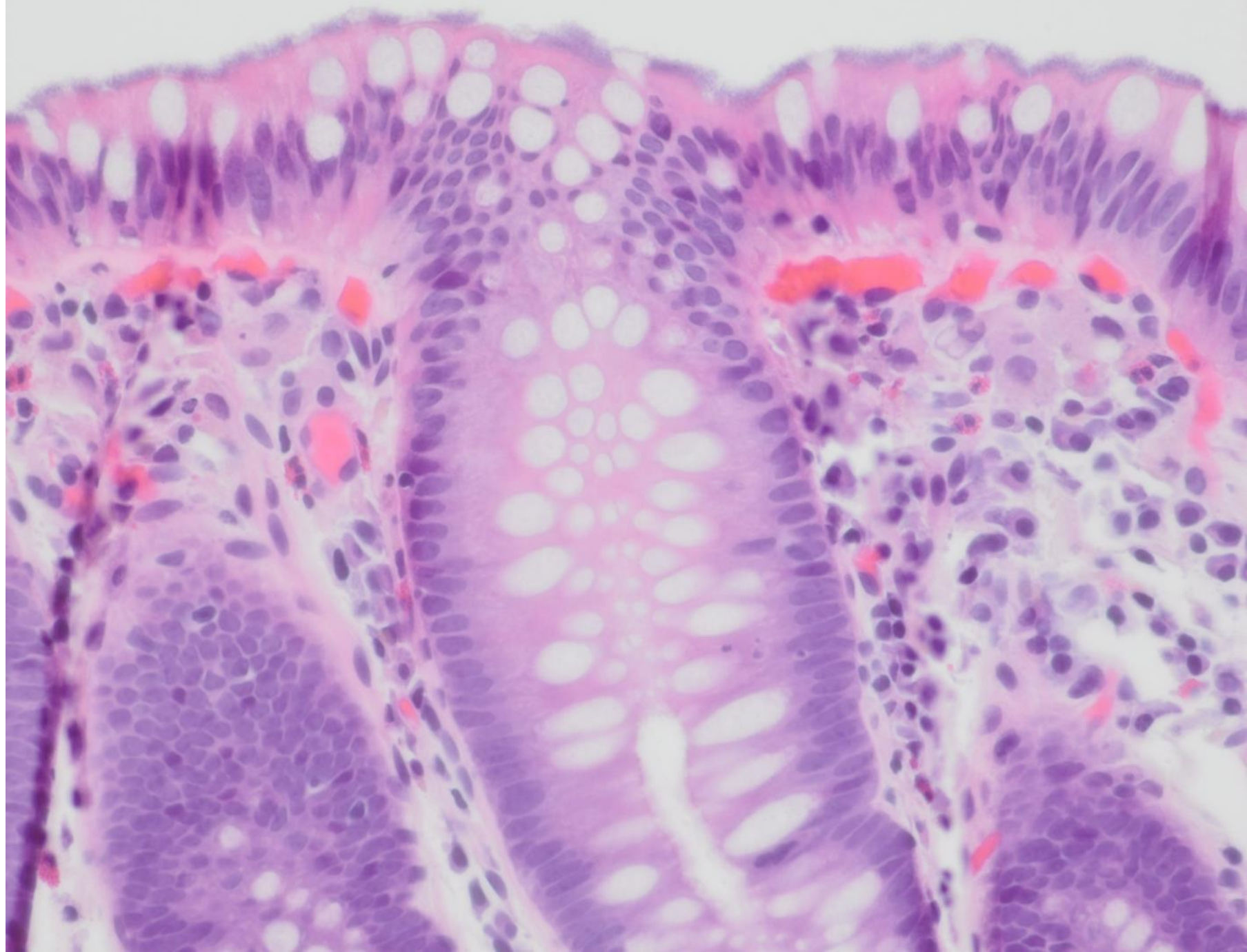
21-0804

Richard Garcia-Kennedy; CPMC

36-year-old M undergoes right colon biopsy, r/o inflammation.





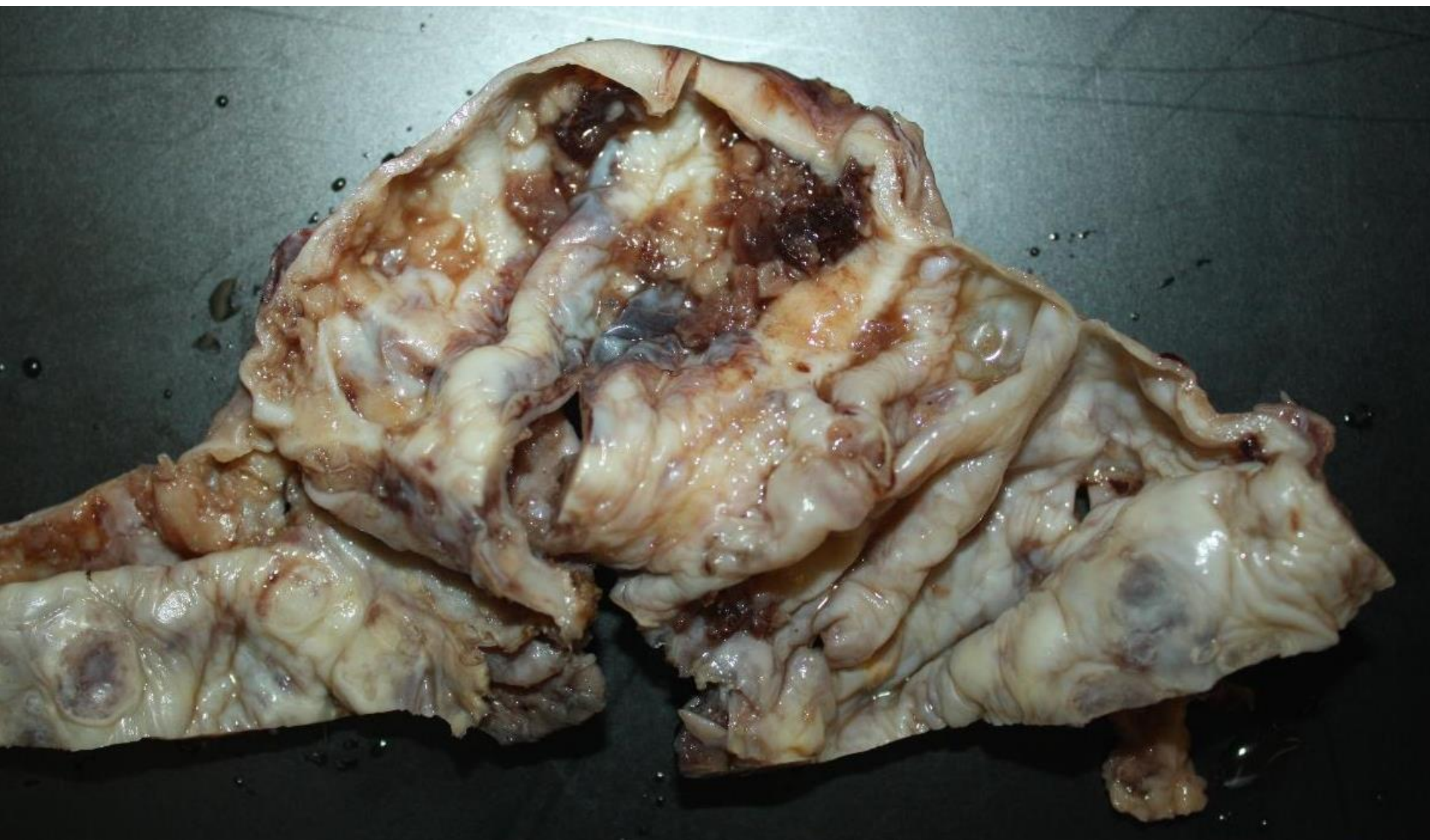


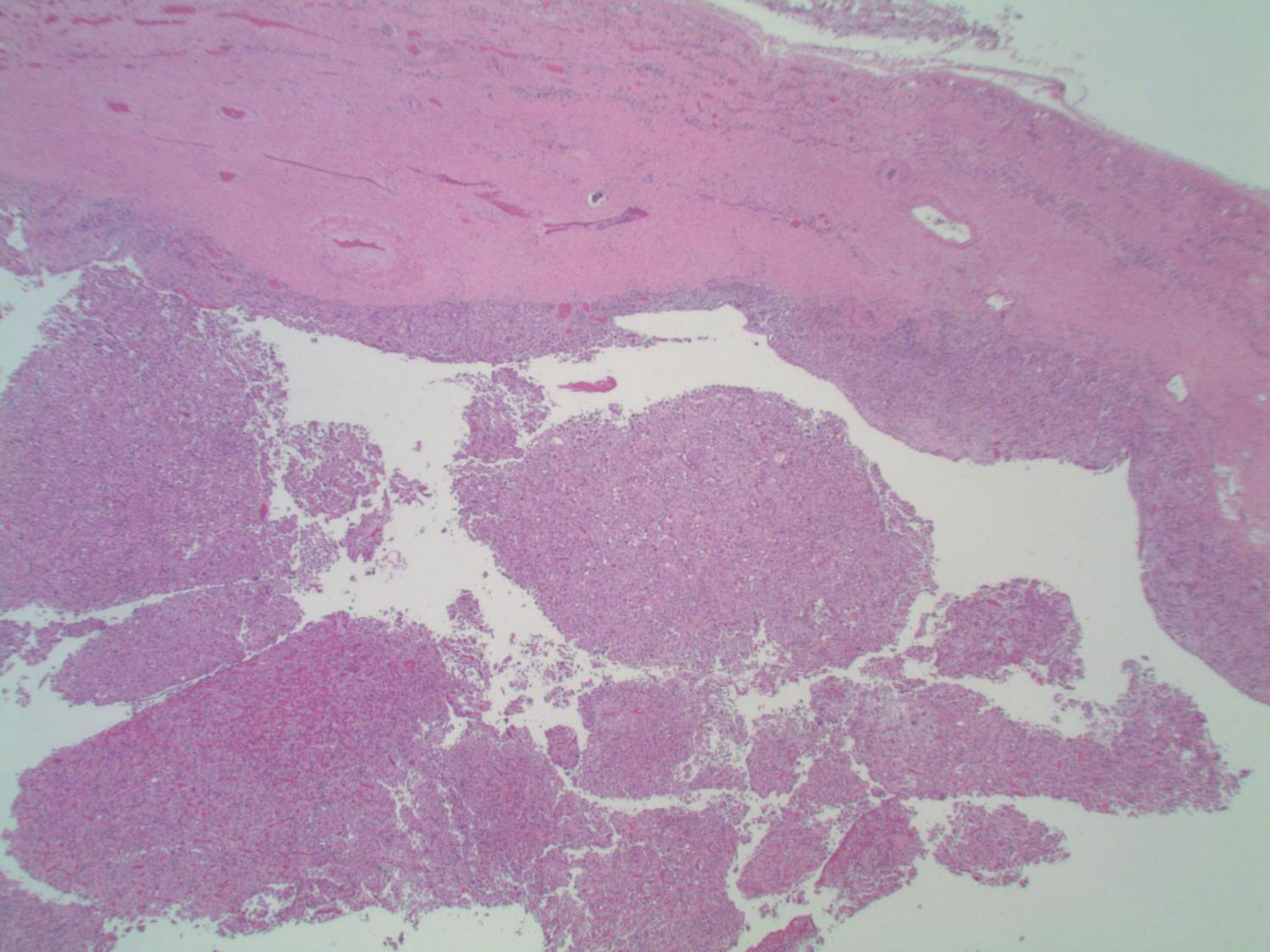


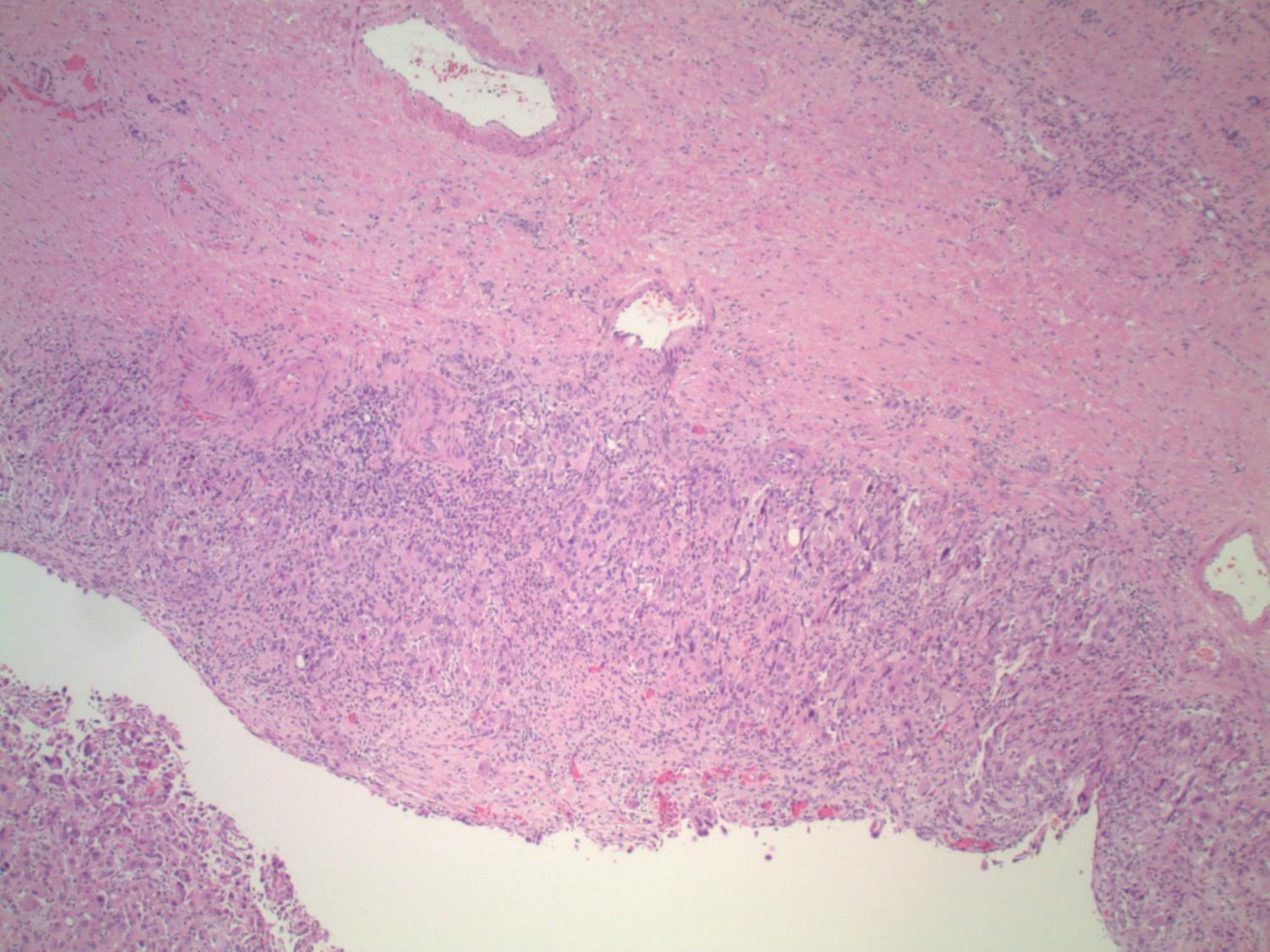
21-0805

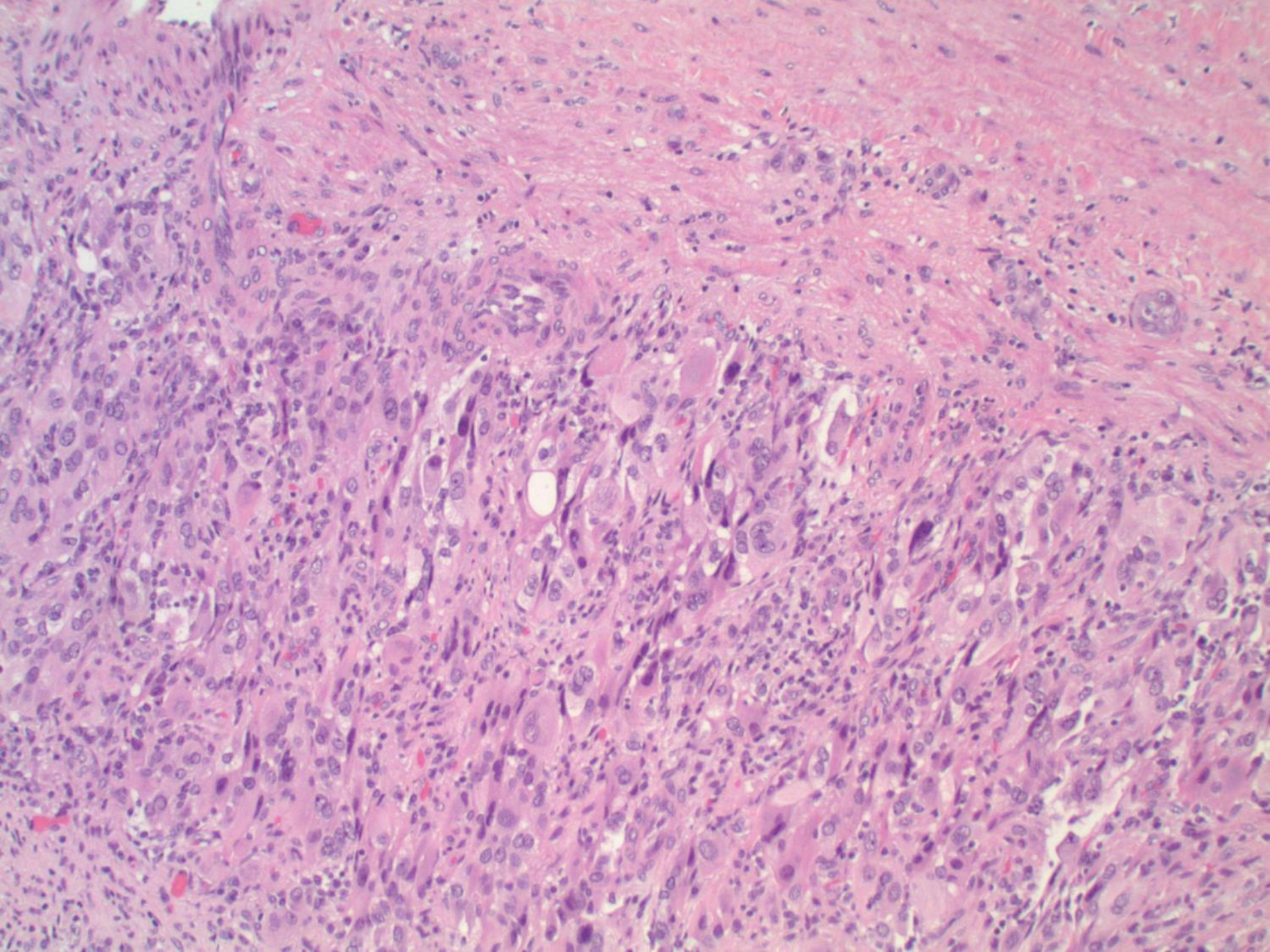
Ankur Sangoi; El Camino Hospital

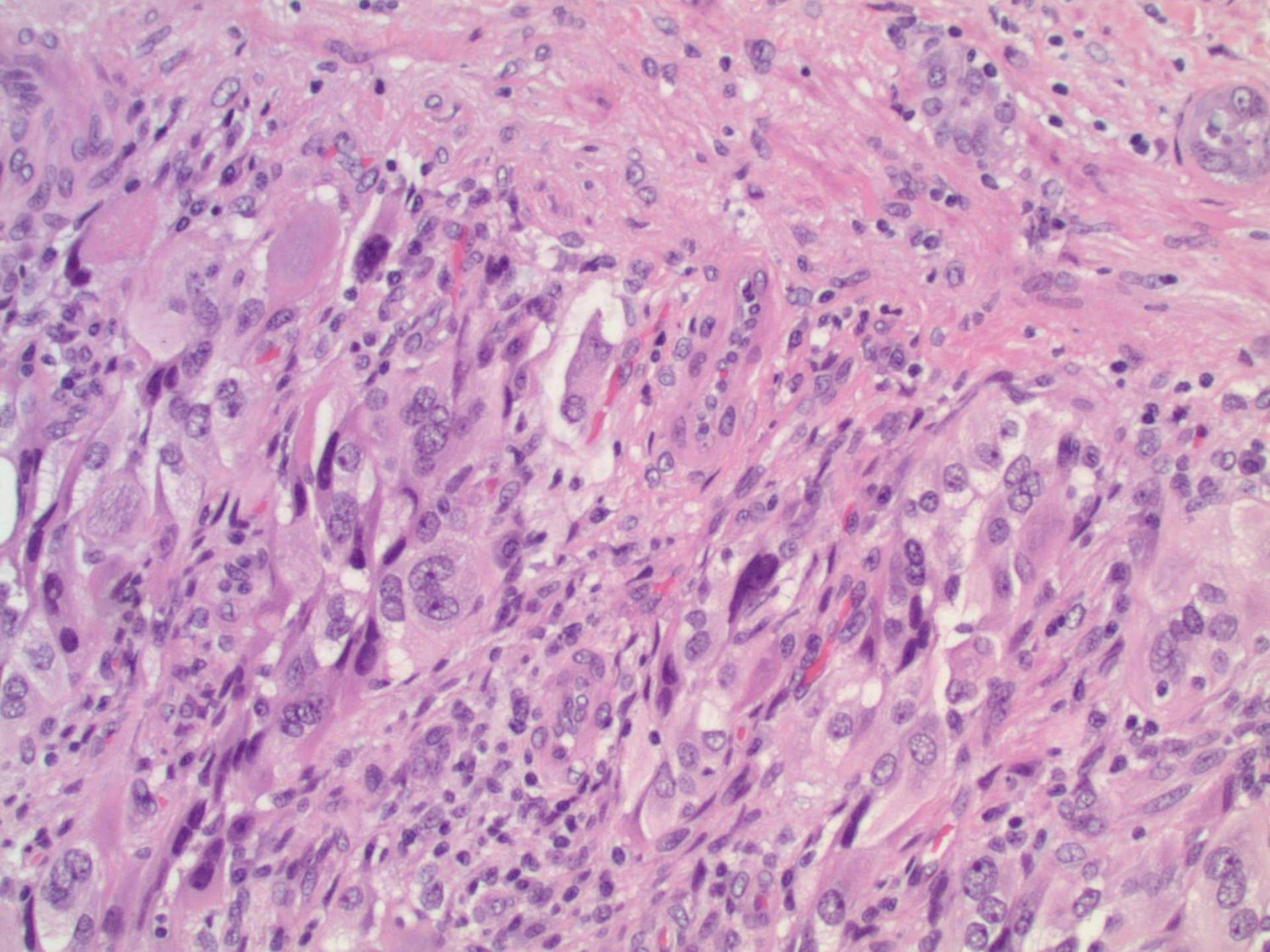
Middle-aged adult F undergoes partial nephrectomy for 8cm renal mass.

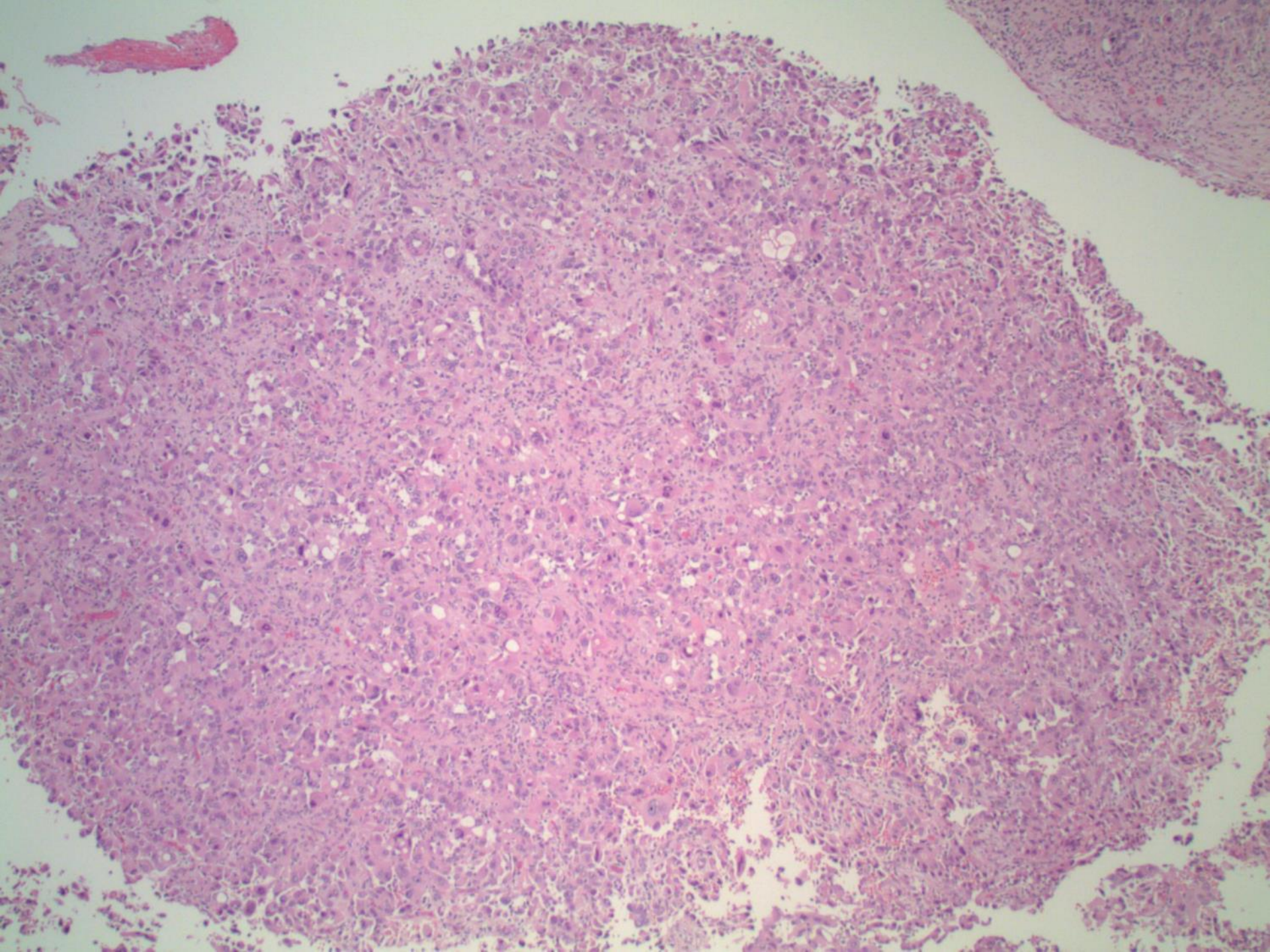


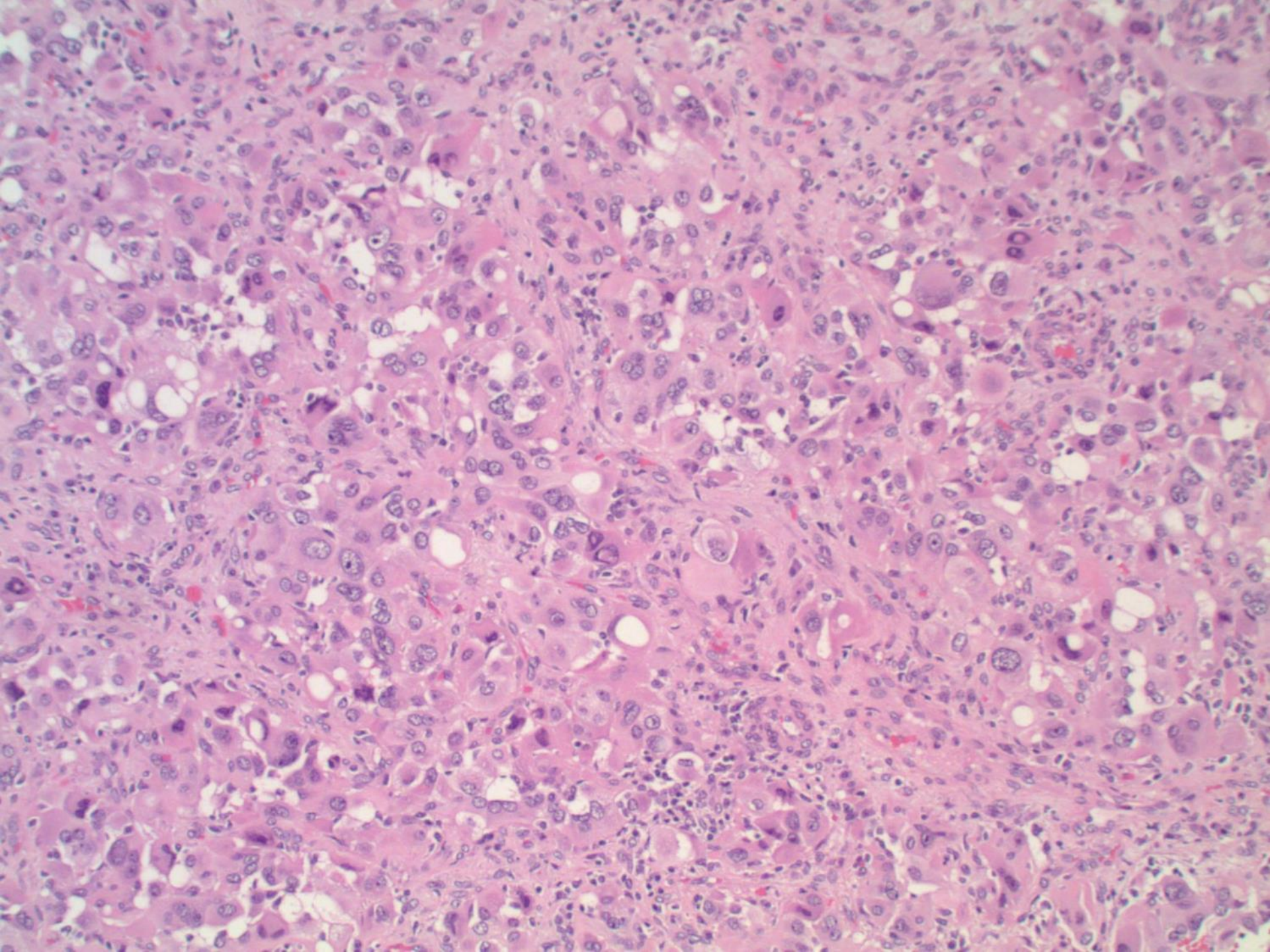


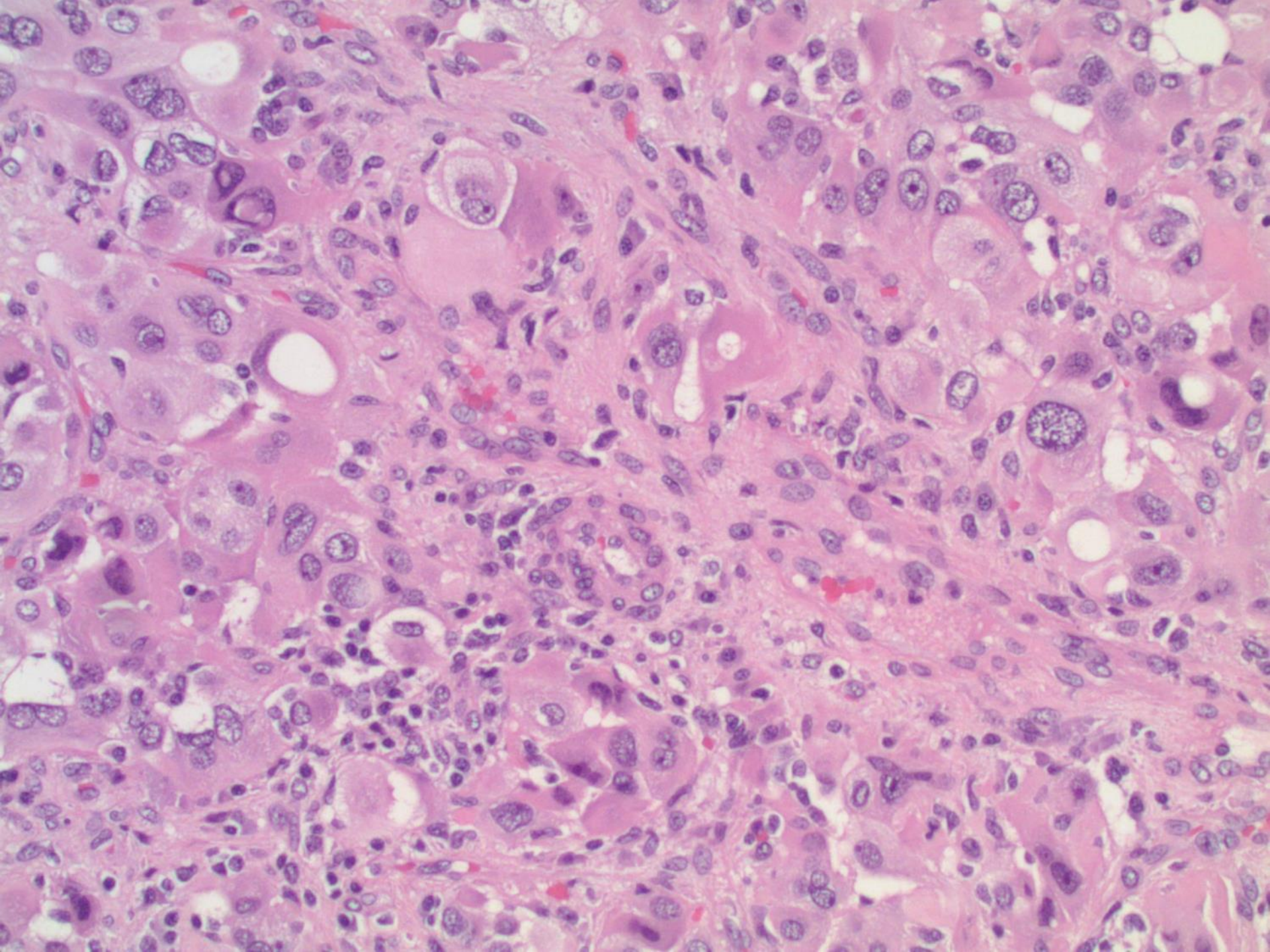












initial IHC summary

POSITIVE: AE1/AE3, PAX8, AMACR

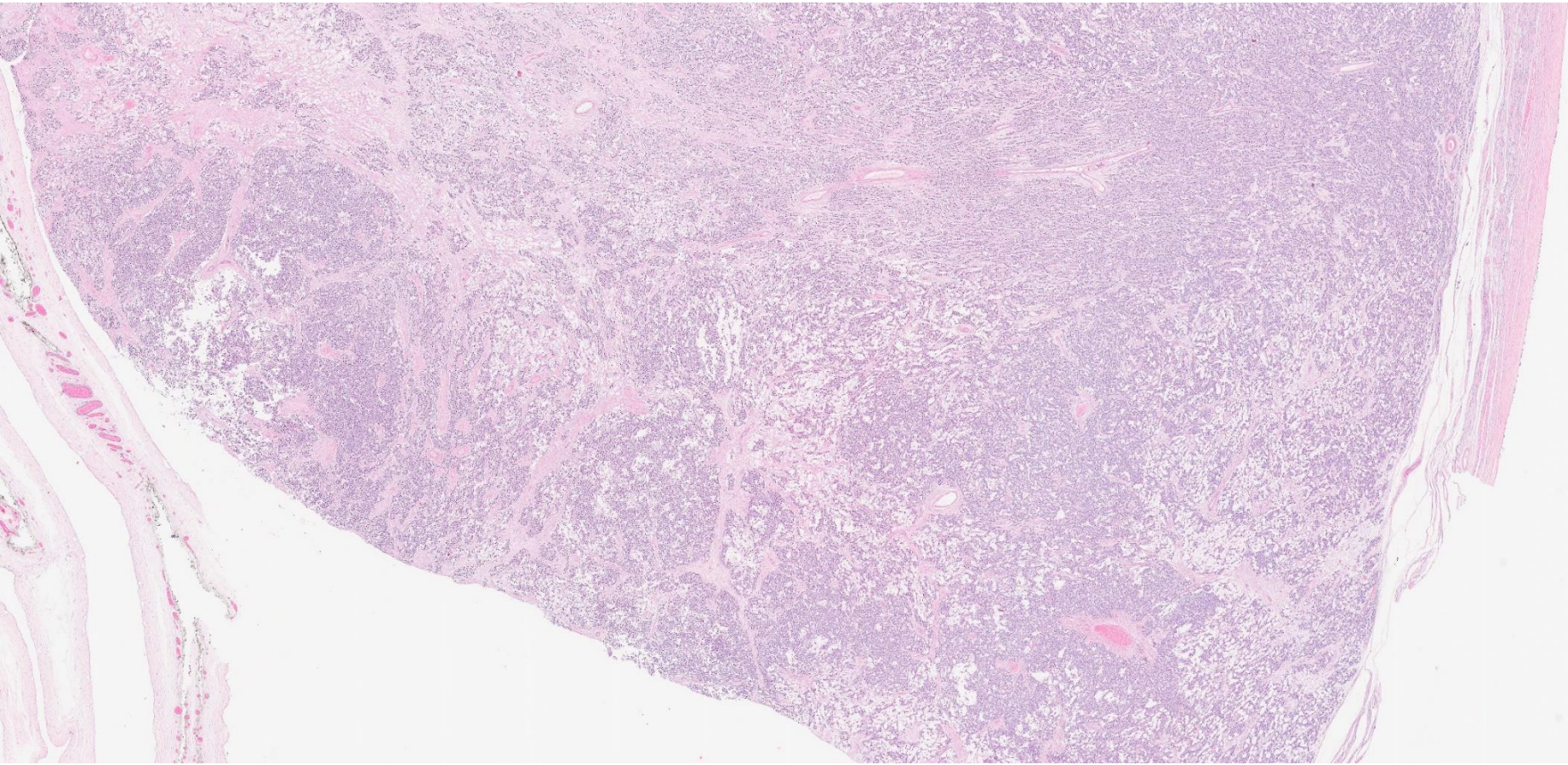
NEGATIVE: CK7, CK20, p63, GATA3, cathepsinK, S100, OCT3/4

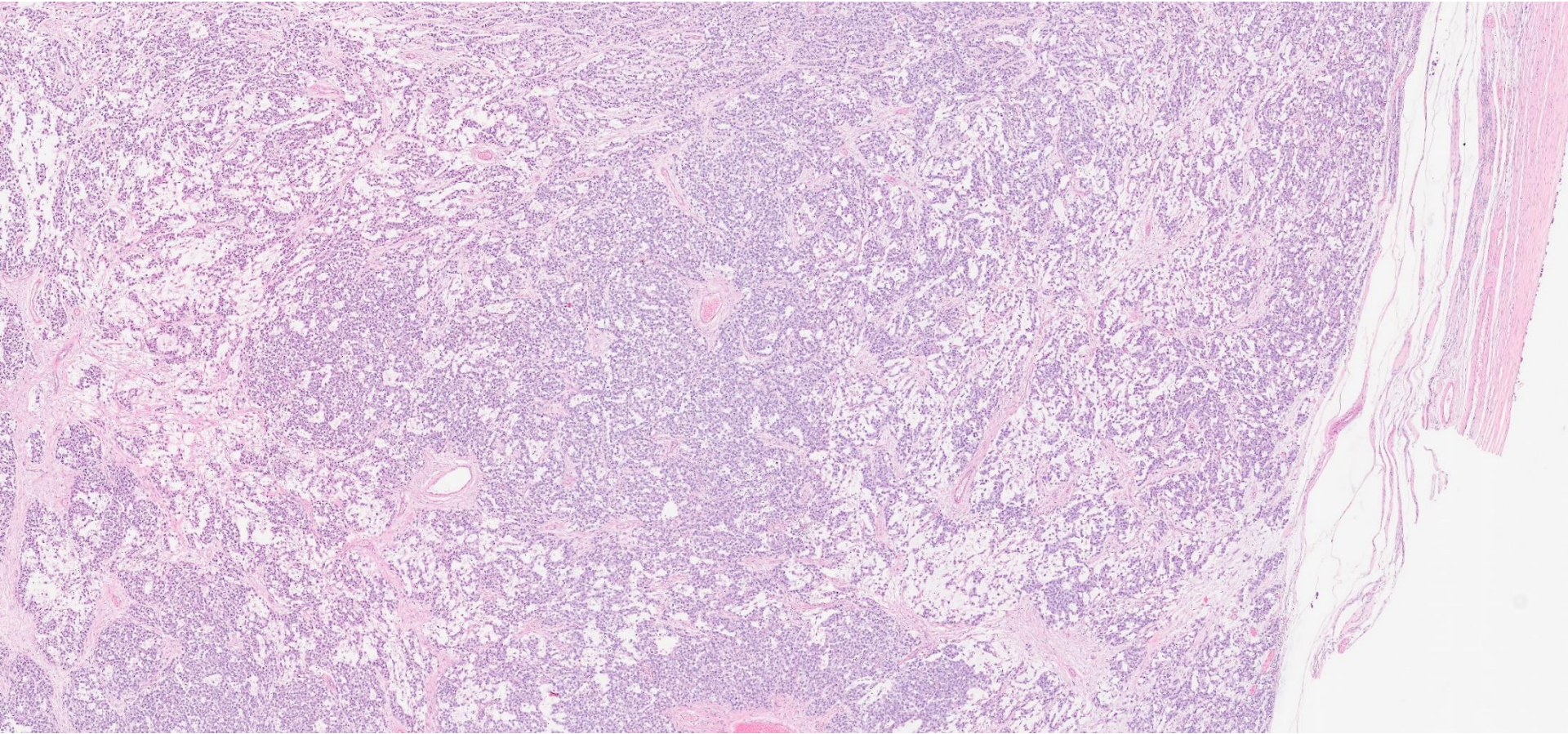


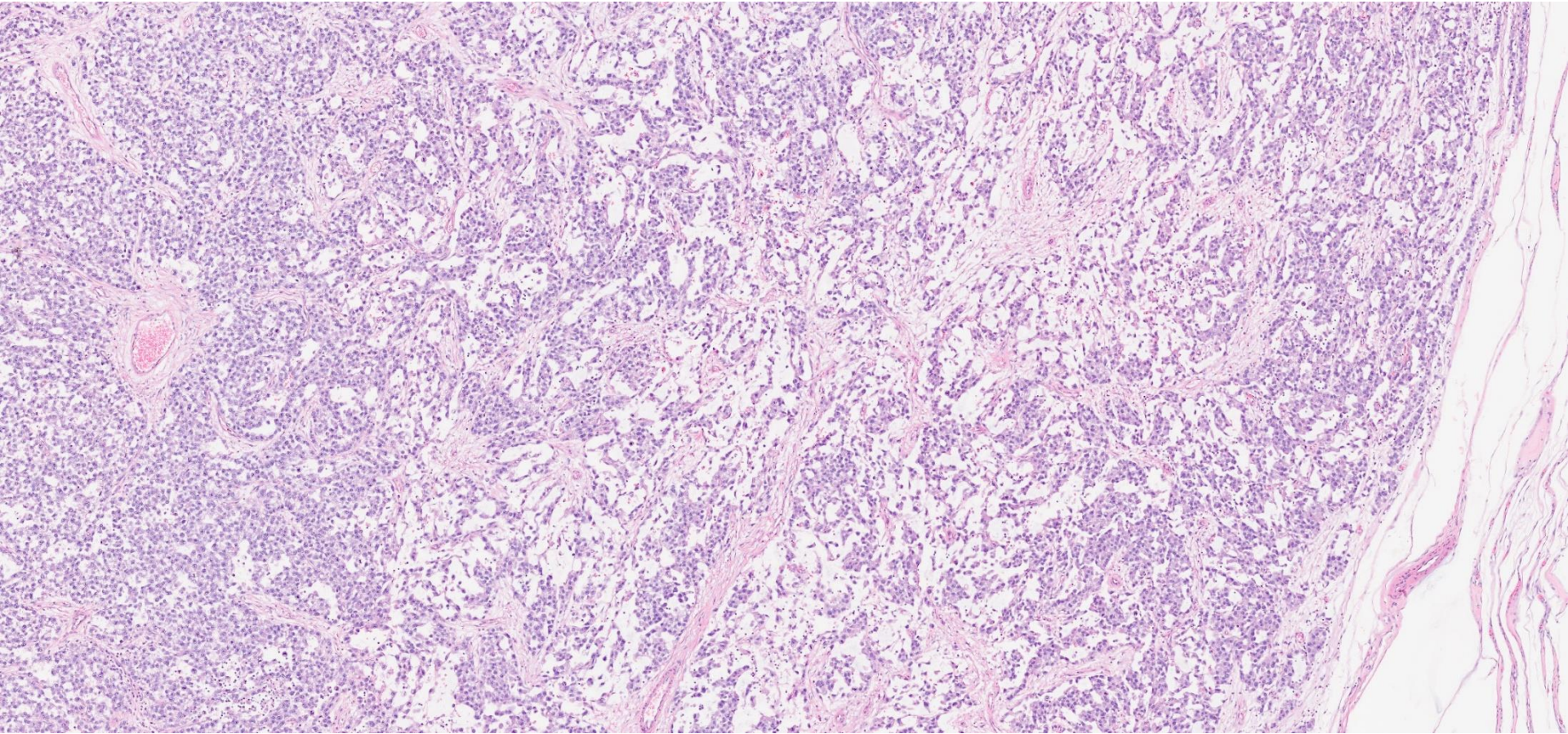
21-0806

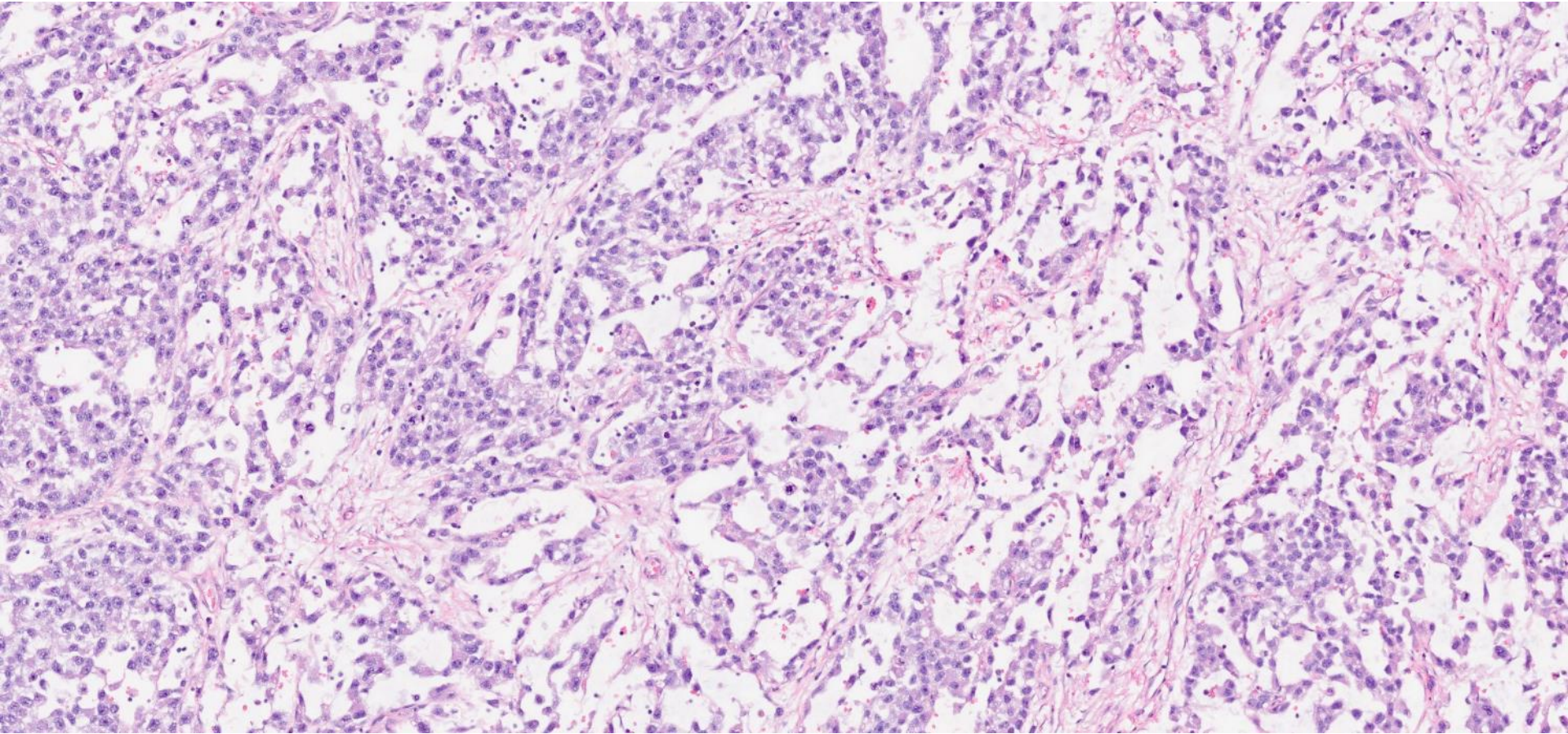
Ankur Sangoi; El Camino Hospital

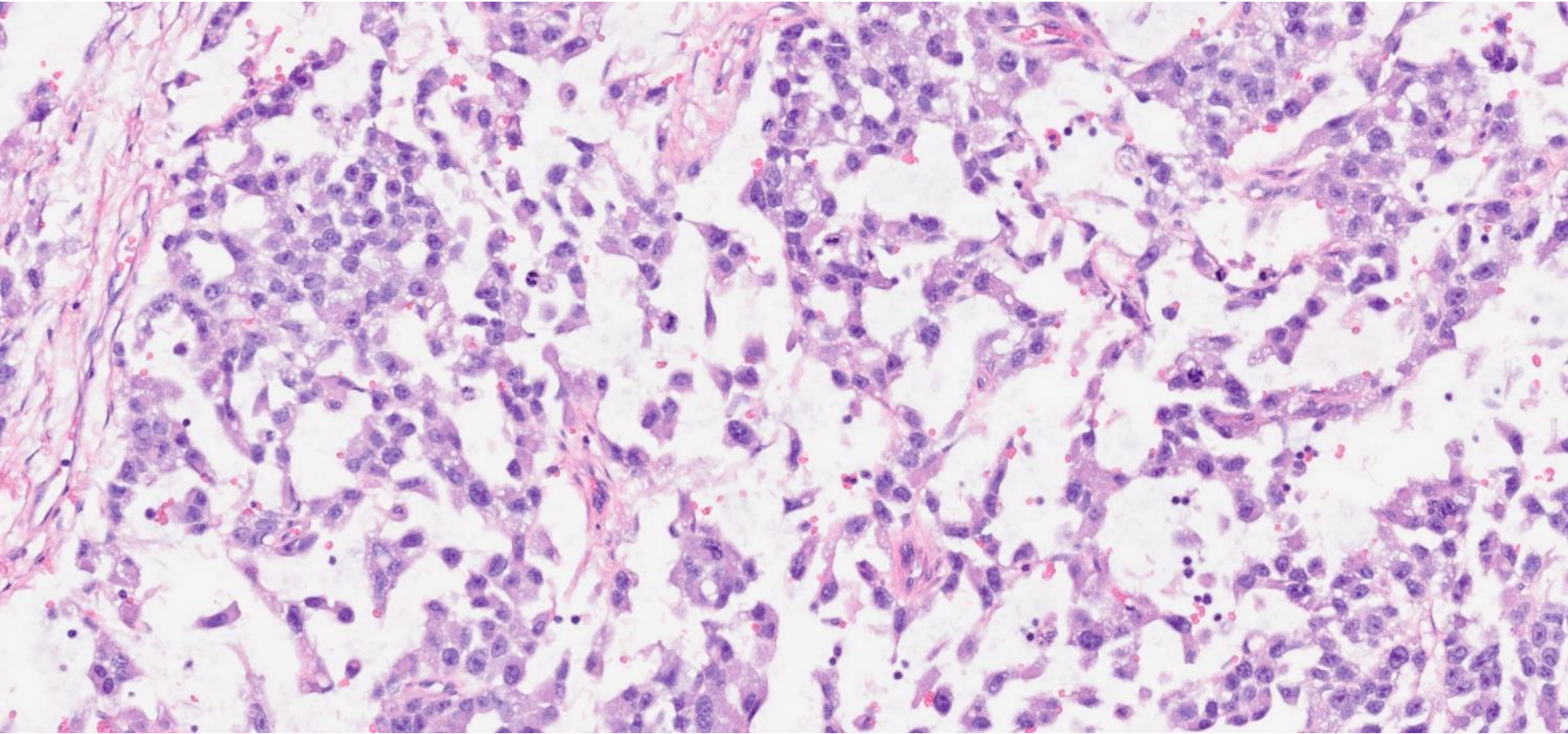
41-year-old M with 5.3cm testicular mass, grossly extending into hilar soft tissue. Section of central mass shown.

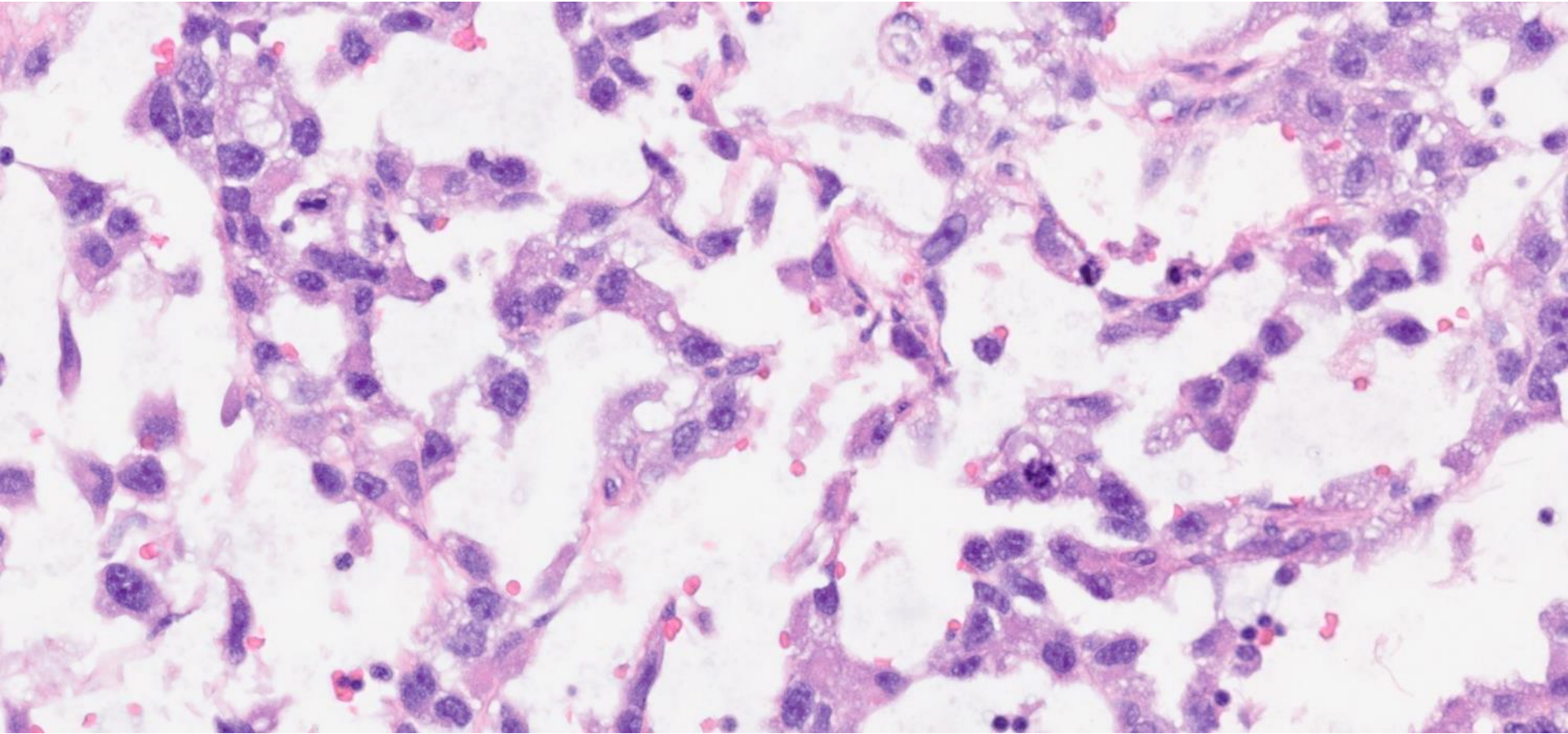










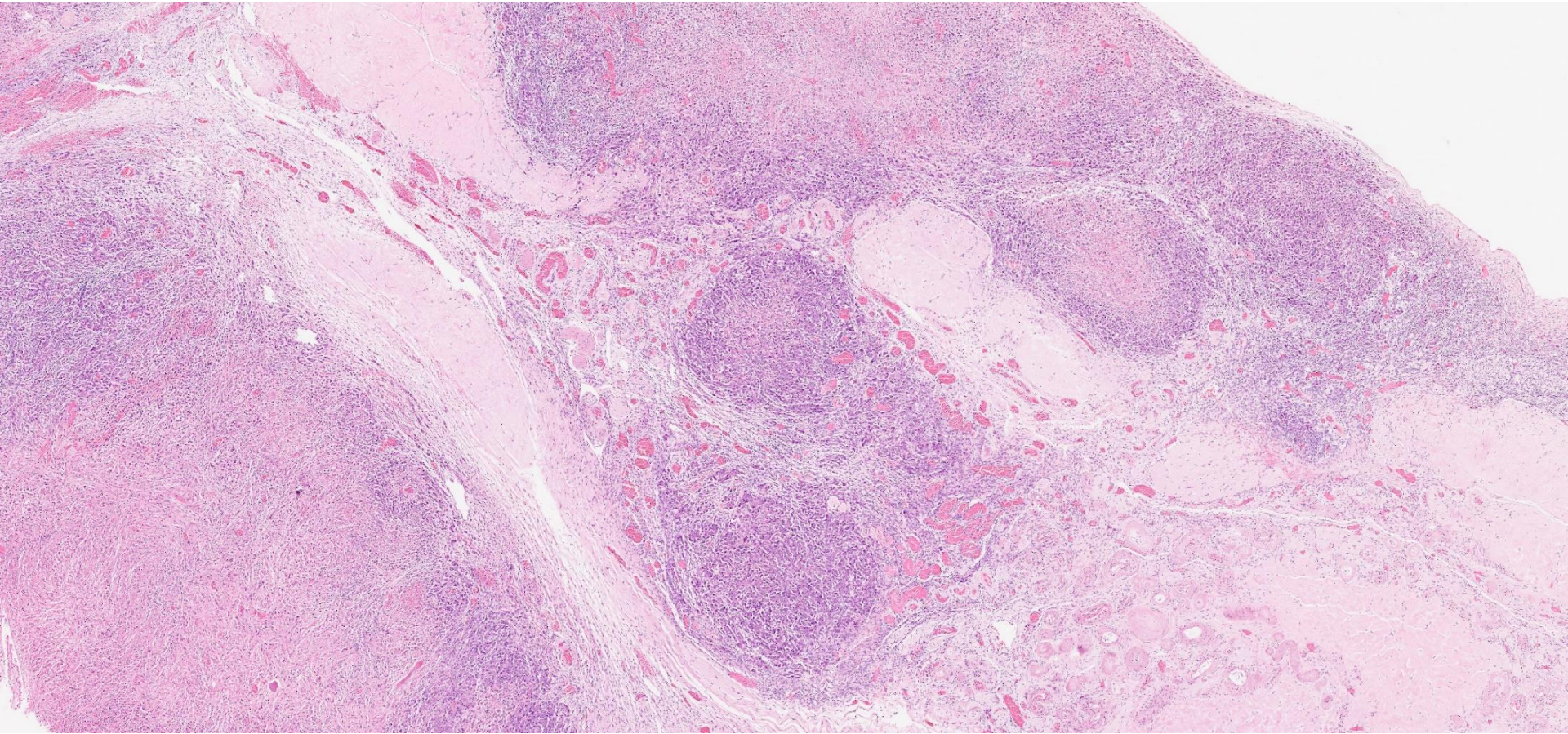


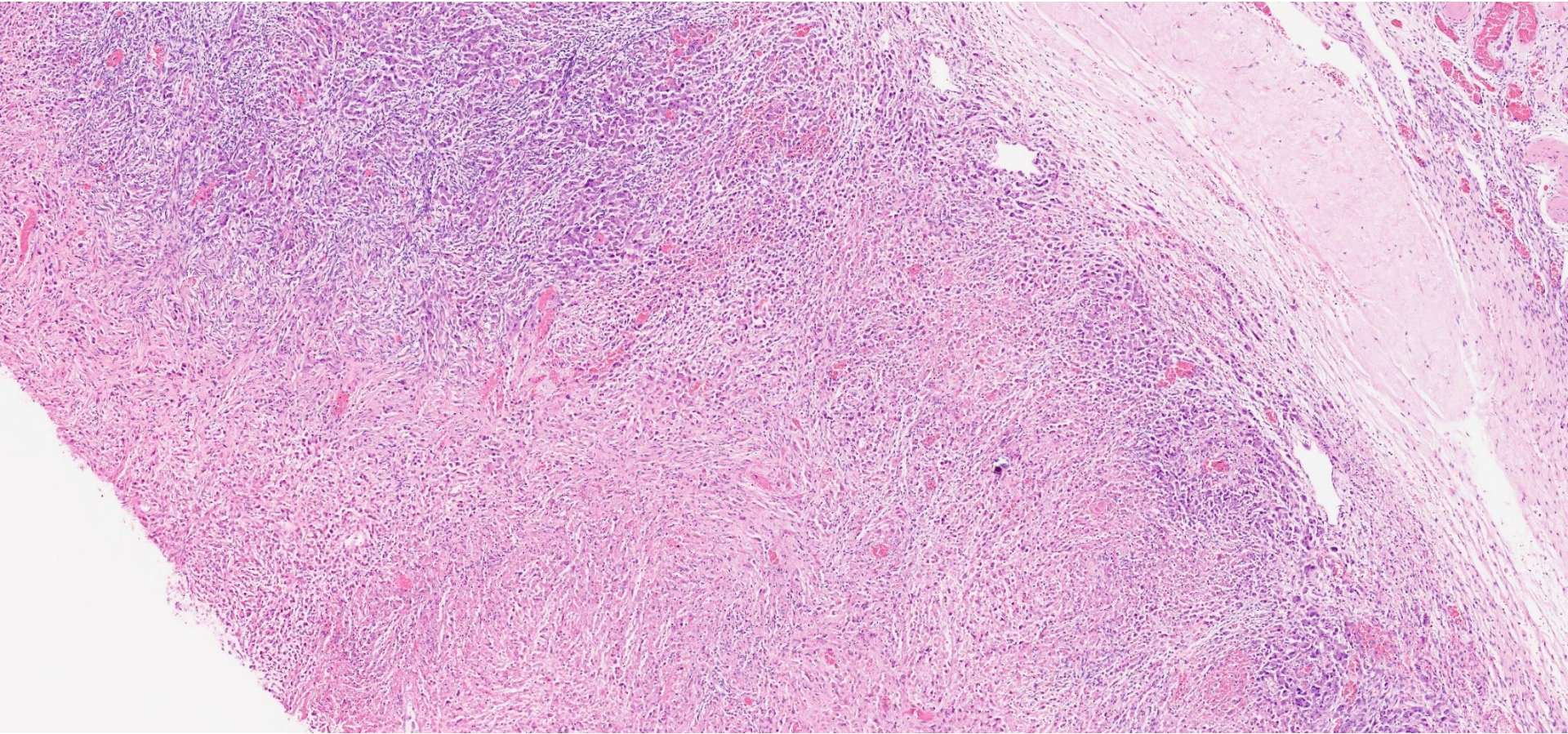


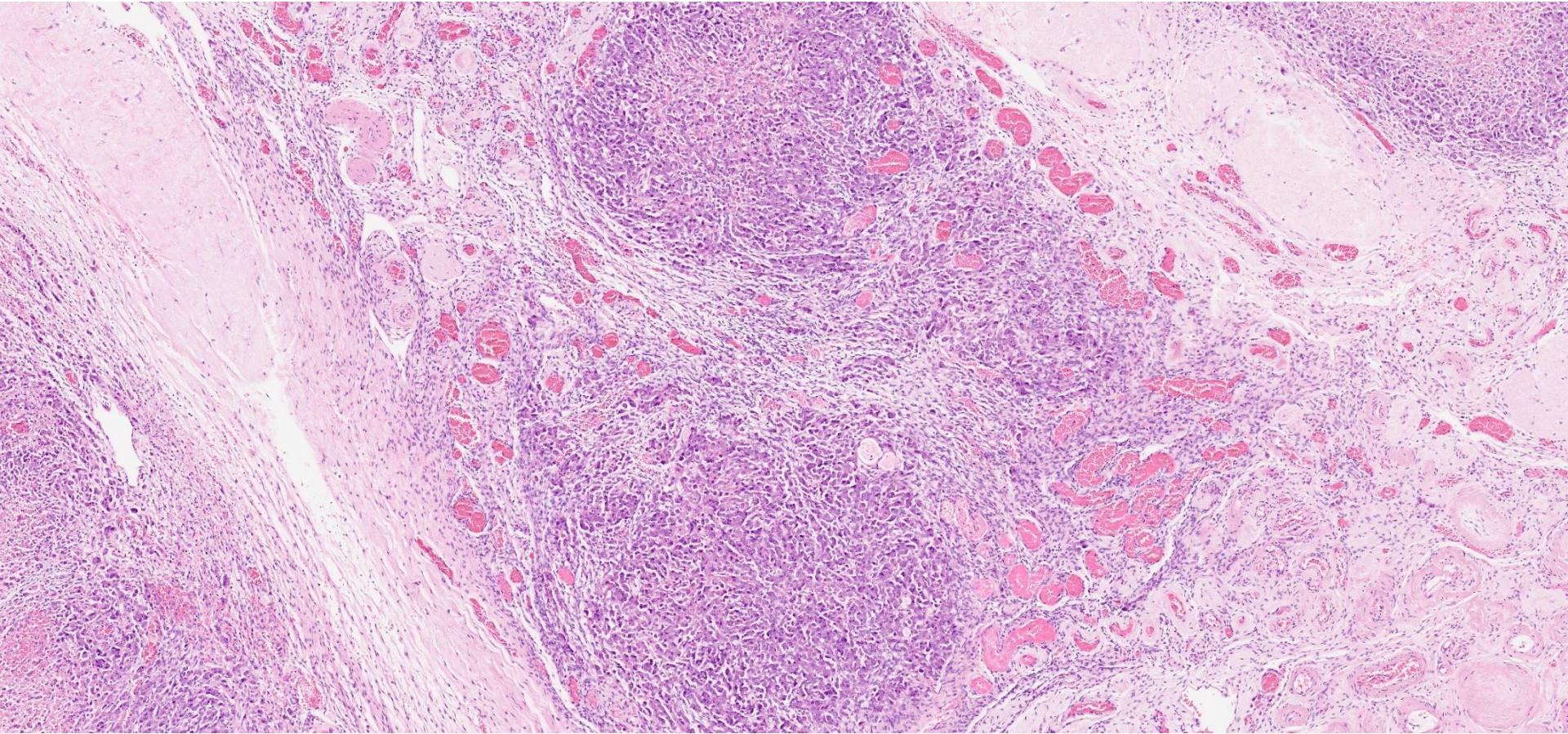
21-0807

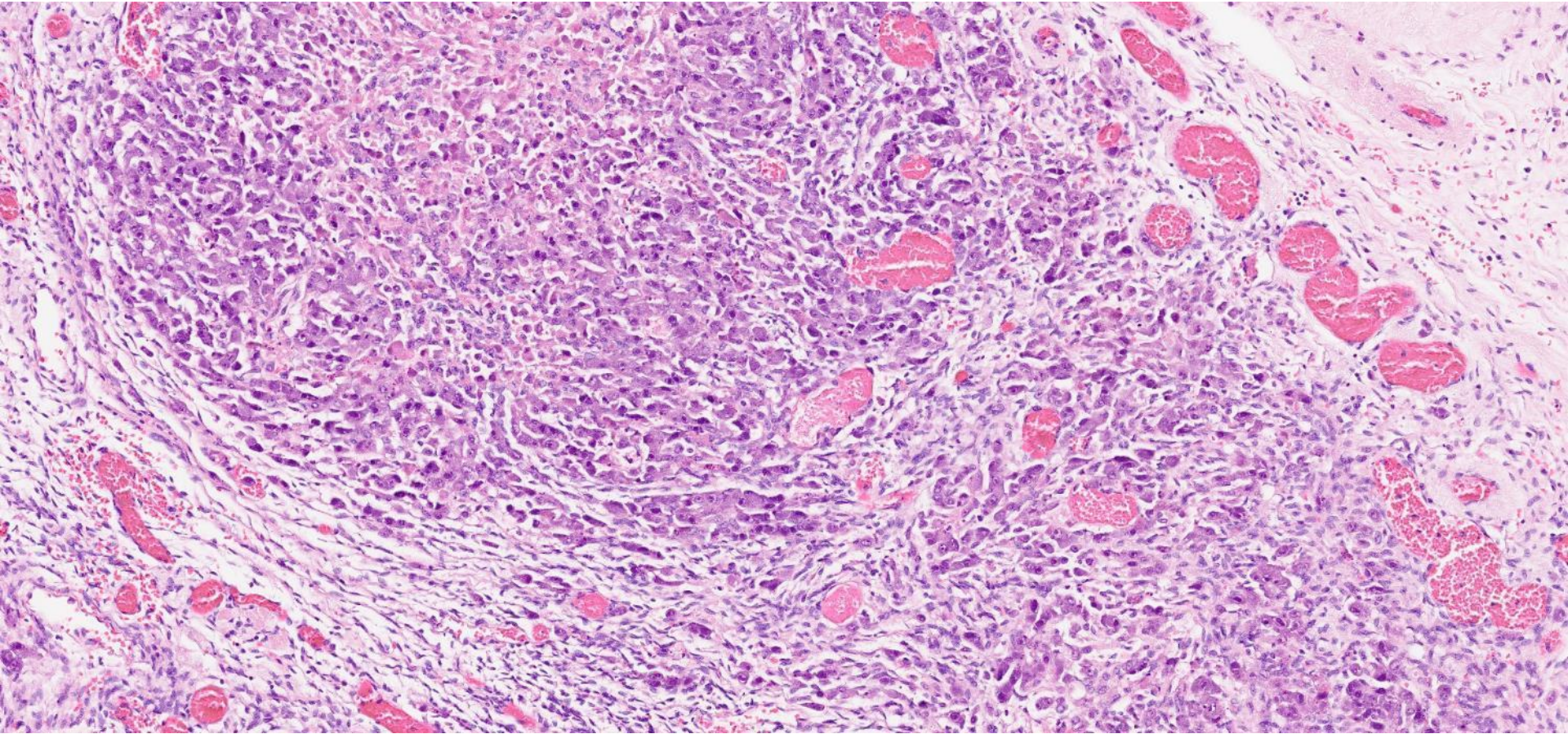
Ankur Sangoi; El Camino Hospital

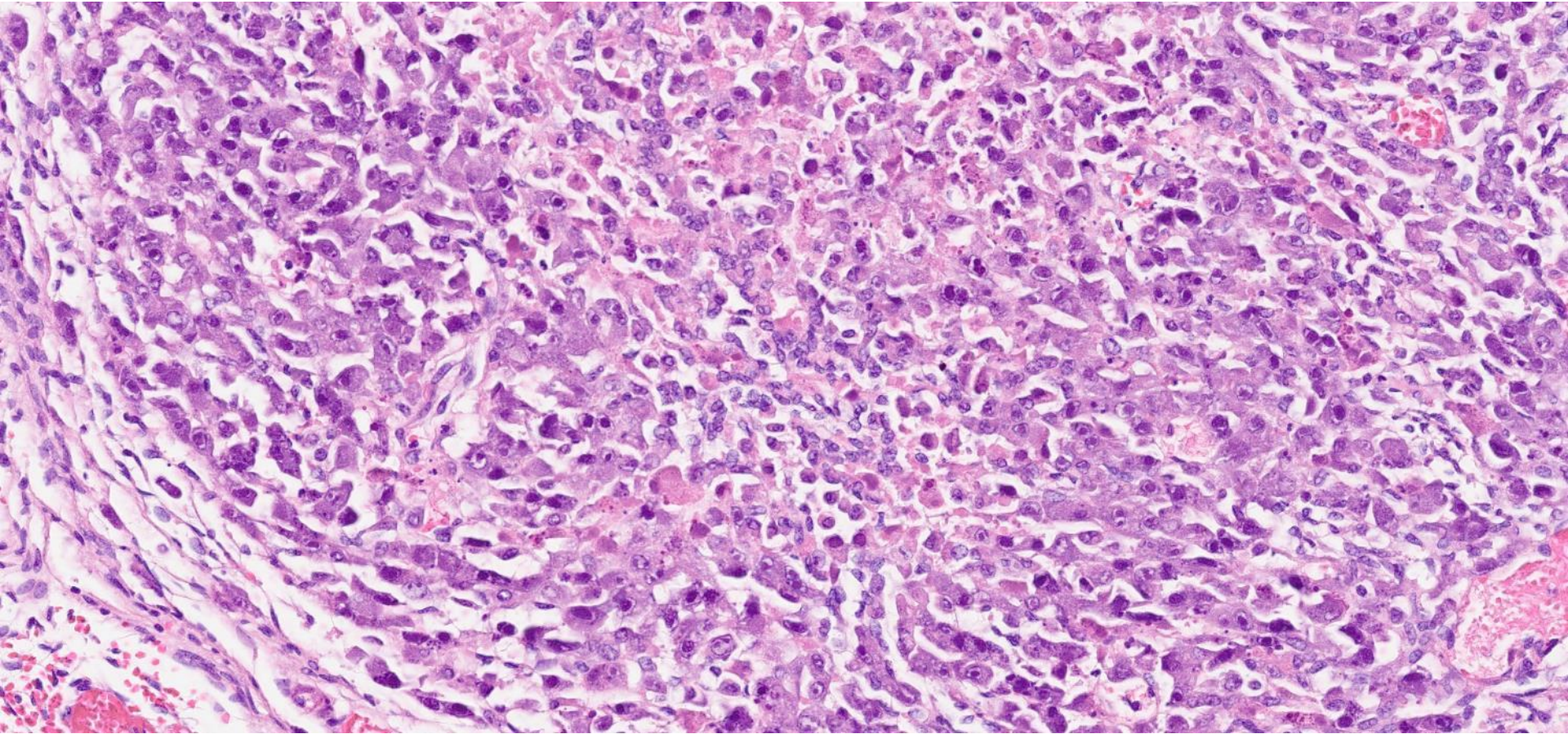
68-year-old F with hypersensitivity pneumonitis with suspected pneumonia and acute hypoxemic failure requiring intubation and subsequent steroids, who presented with acute onset shortness of breath. Despite intubation for worsening respiratory failure and steroids, she died. Section of grossly unremarkable shown.

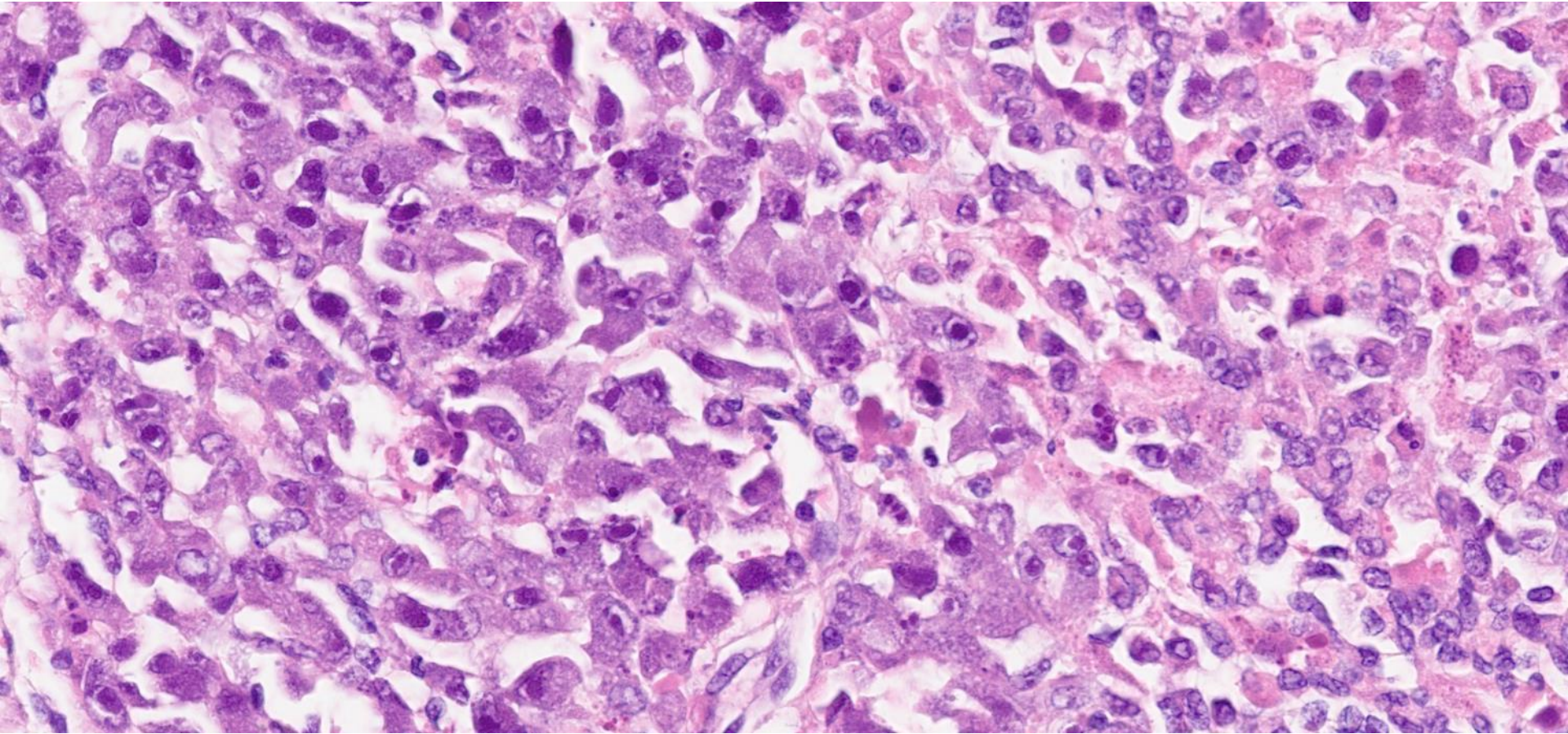


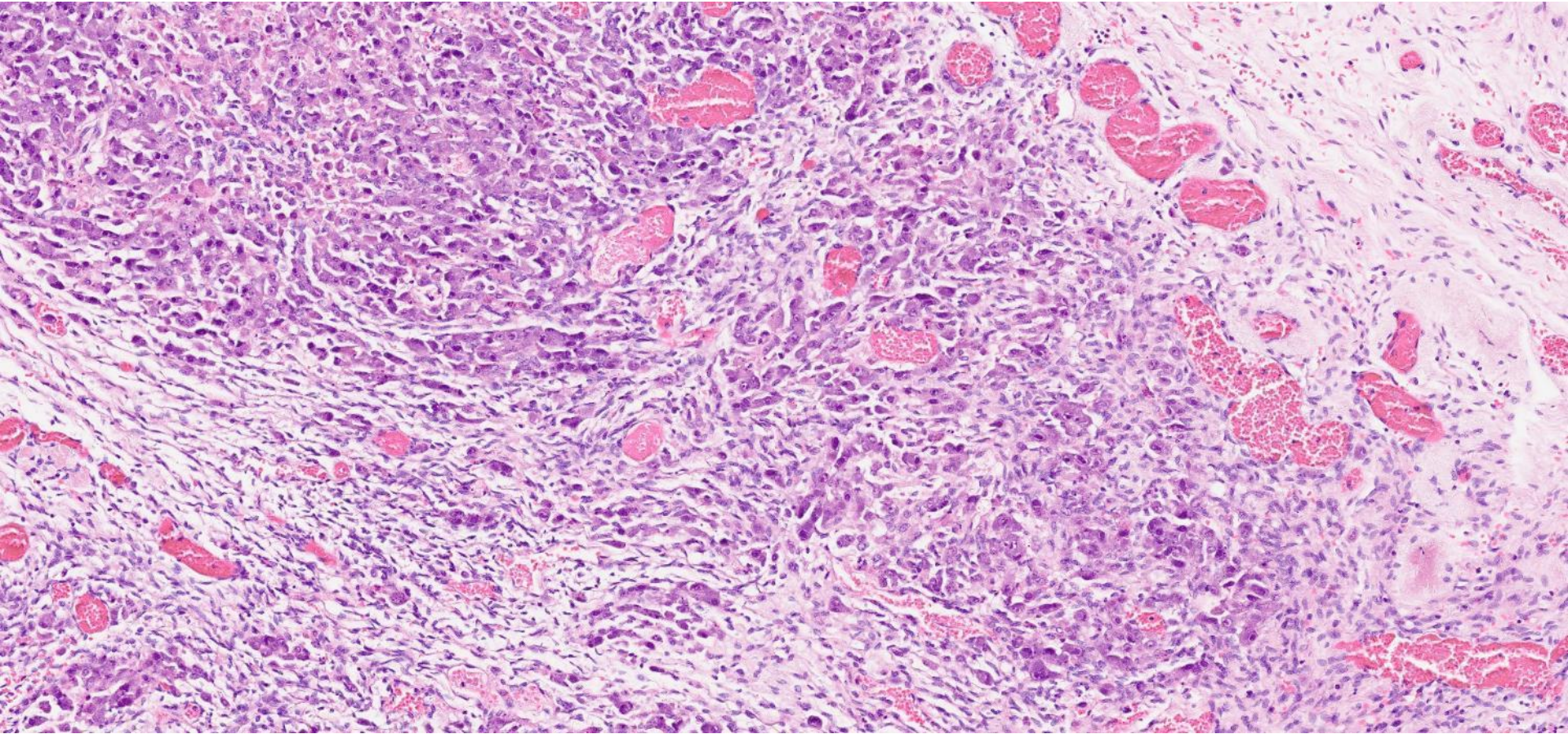


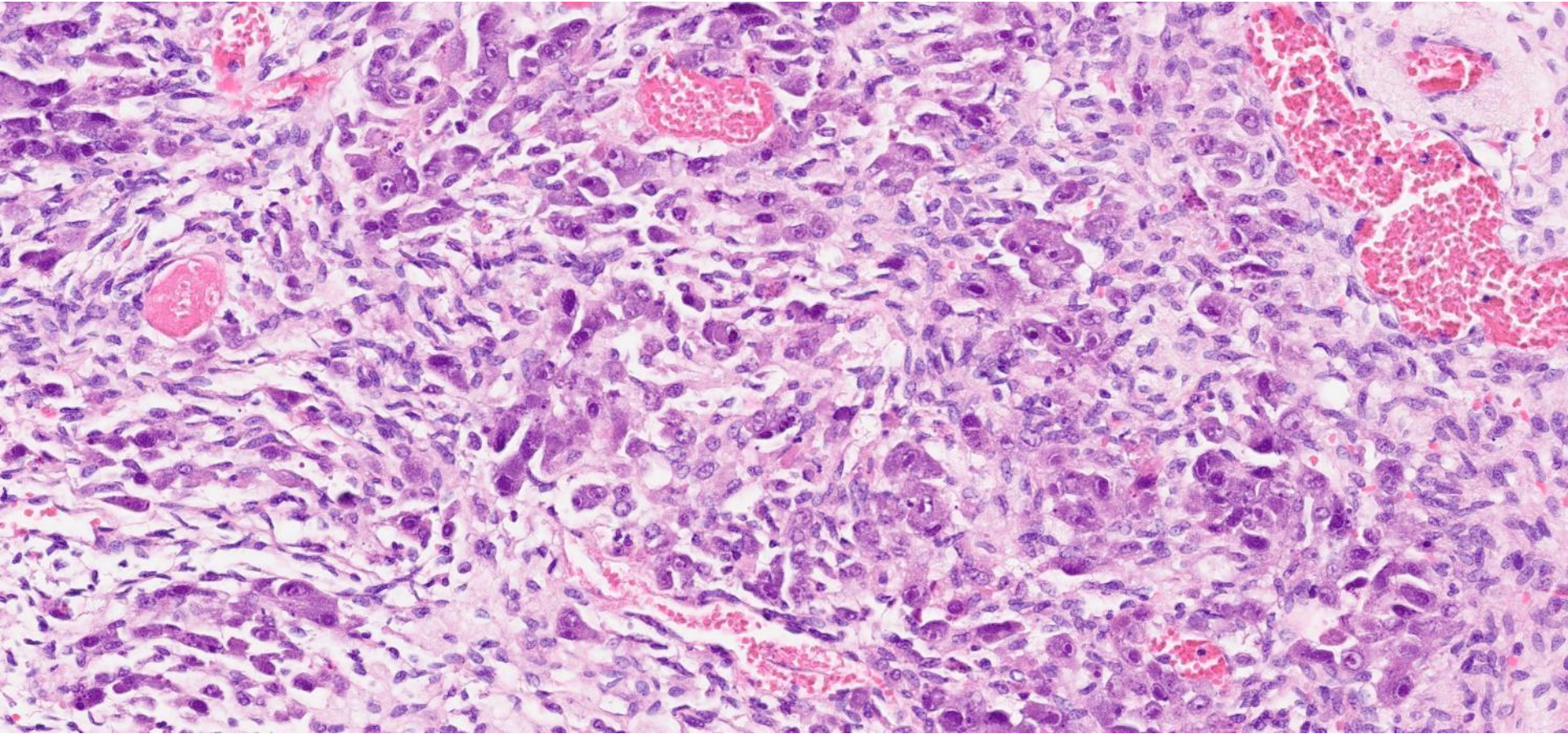














21-0808

Ankur Sangoi; El Camino Hospital

Adult human undergoes radical nephrectomy. Representative section of renal mass shown. What is the immunostain shown here?

