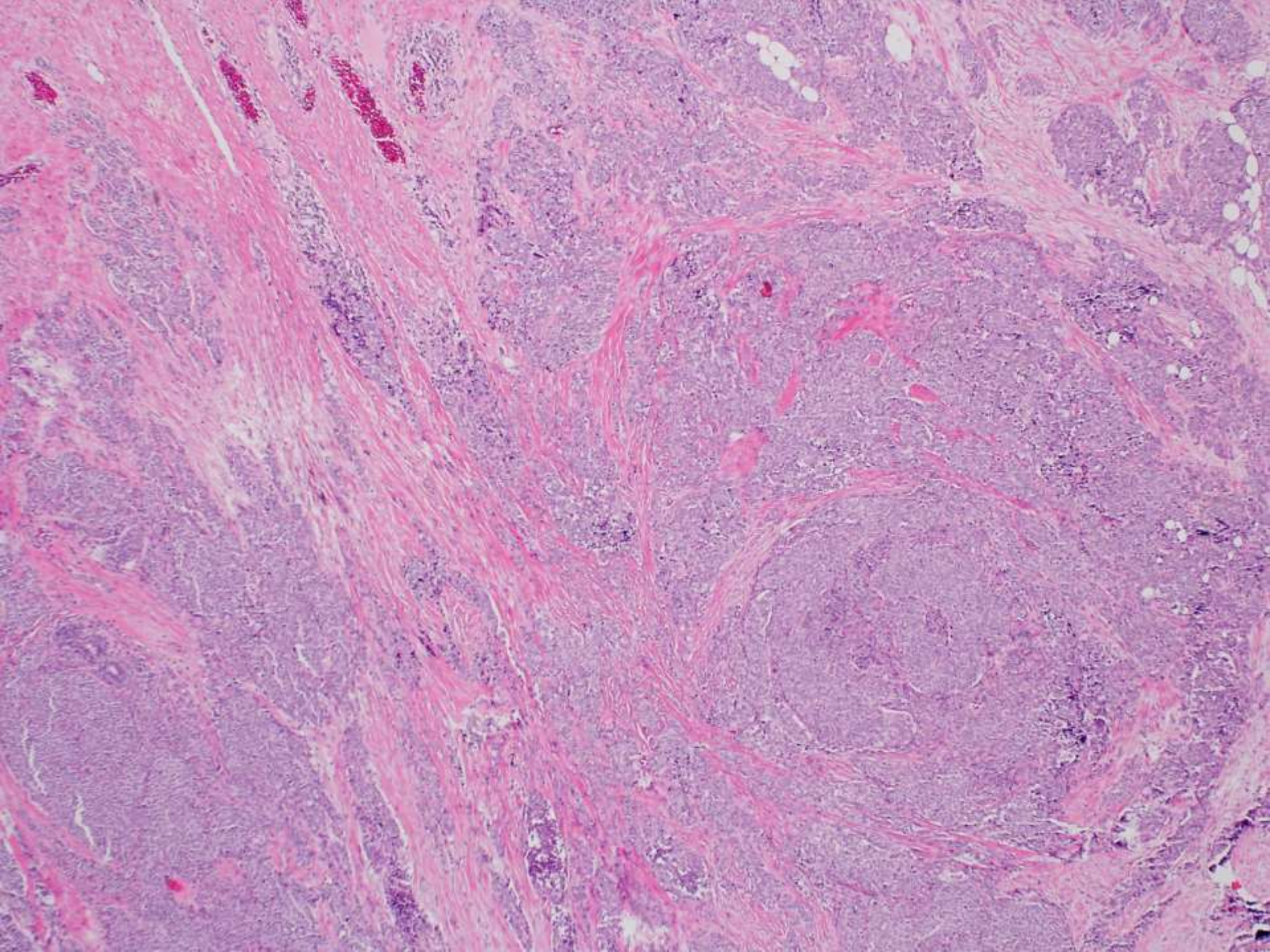
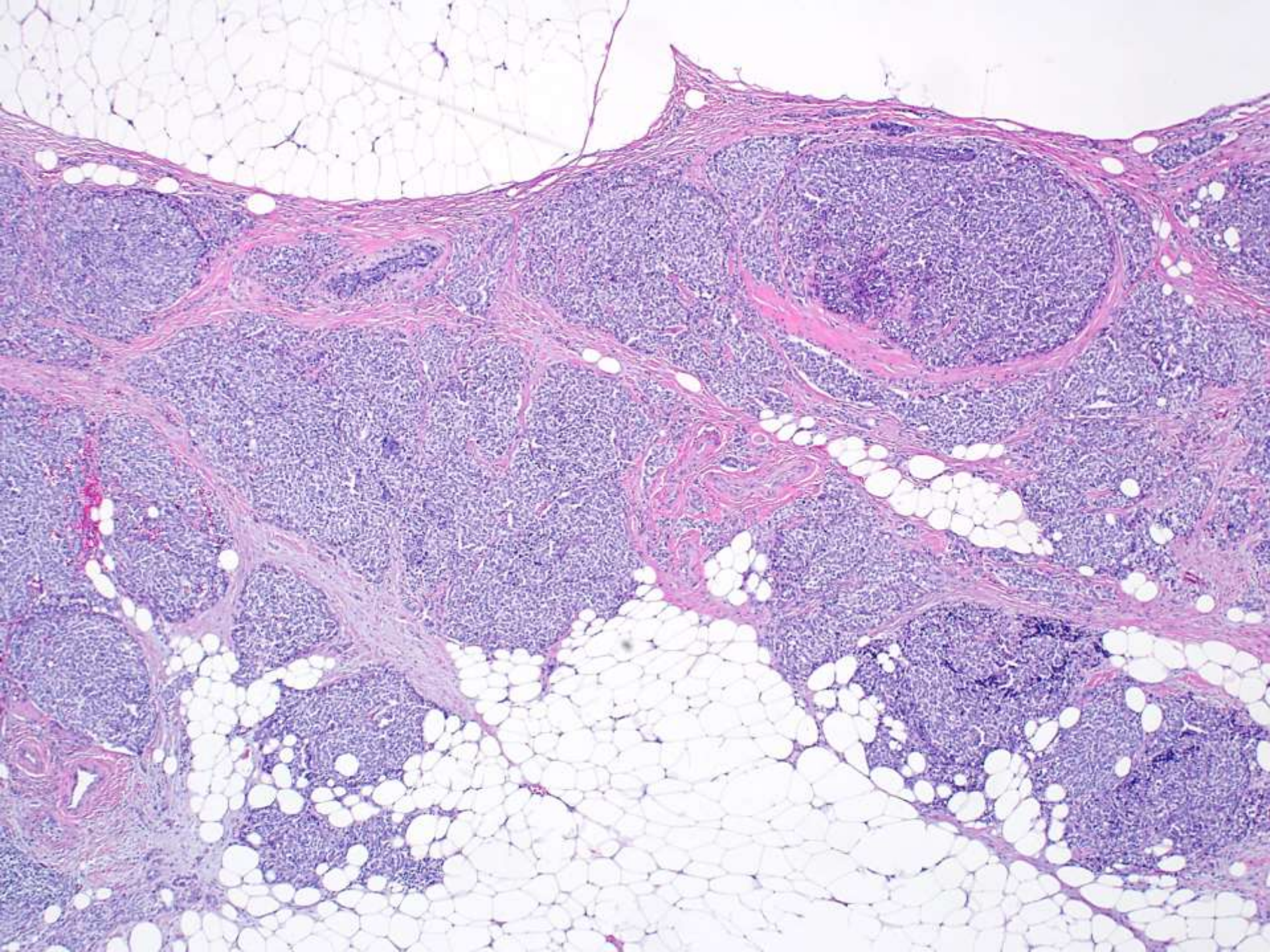


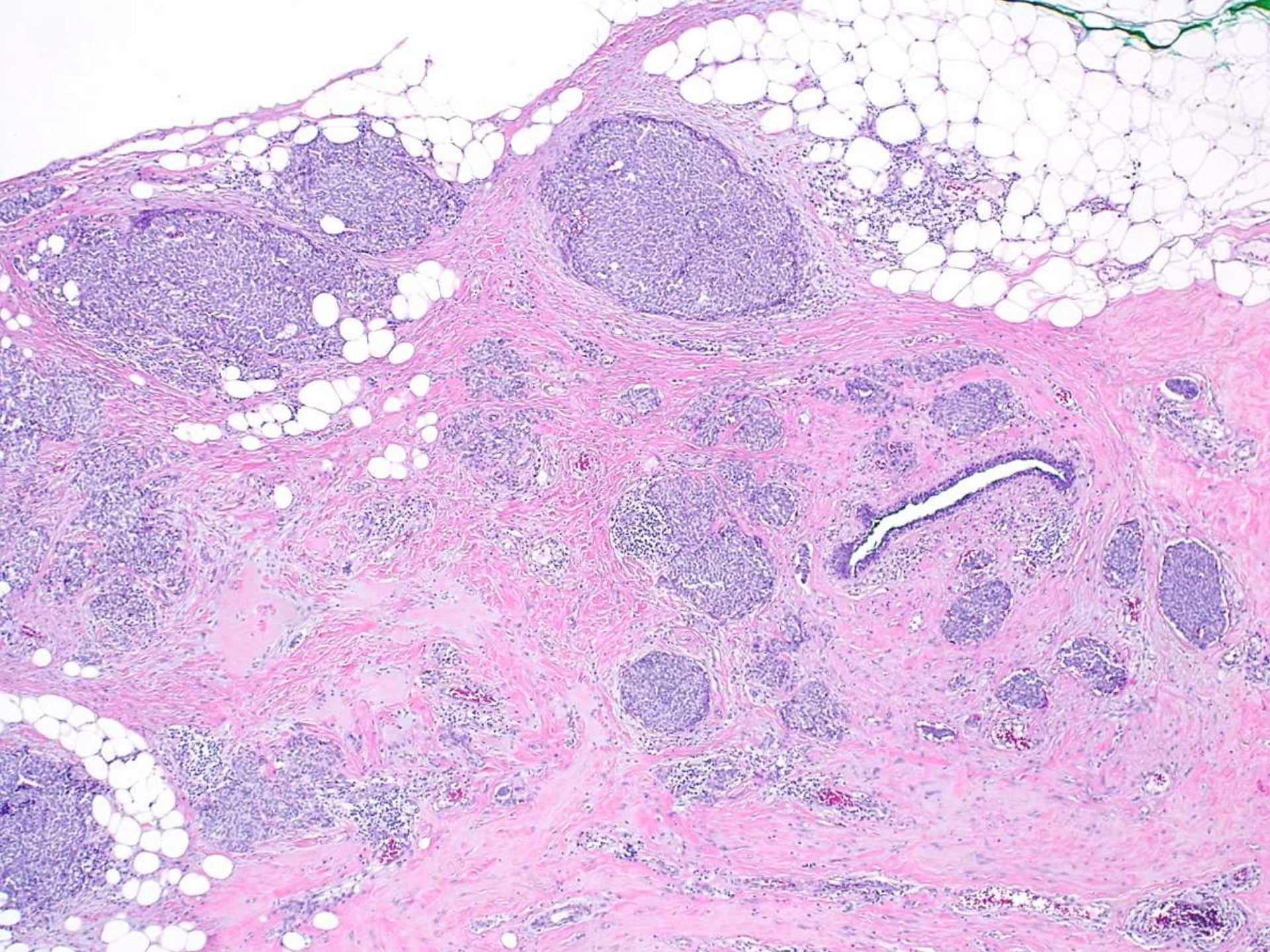
21-0701

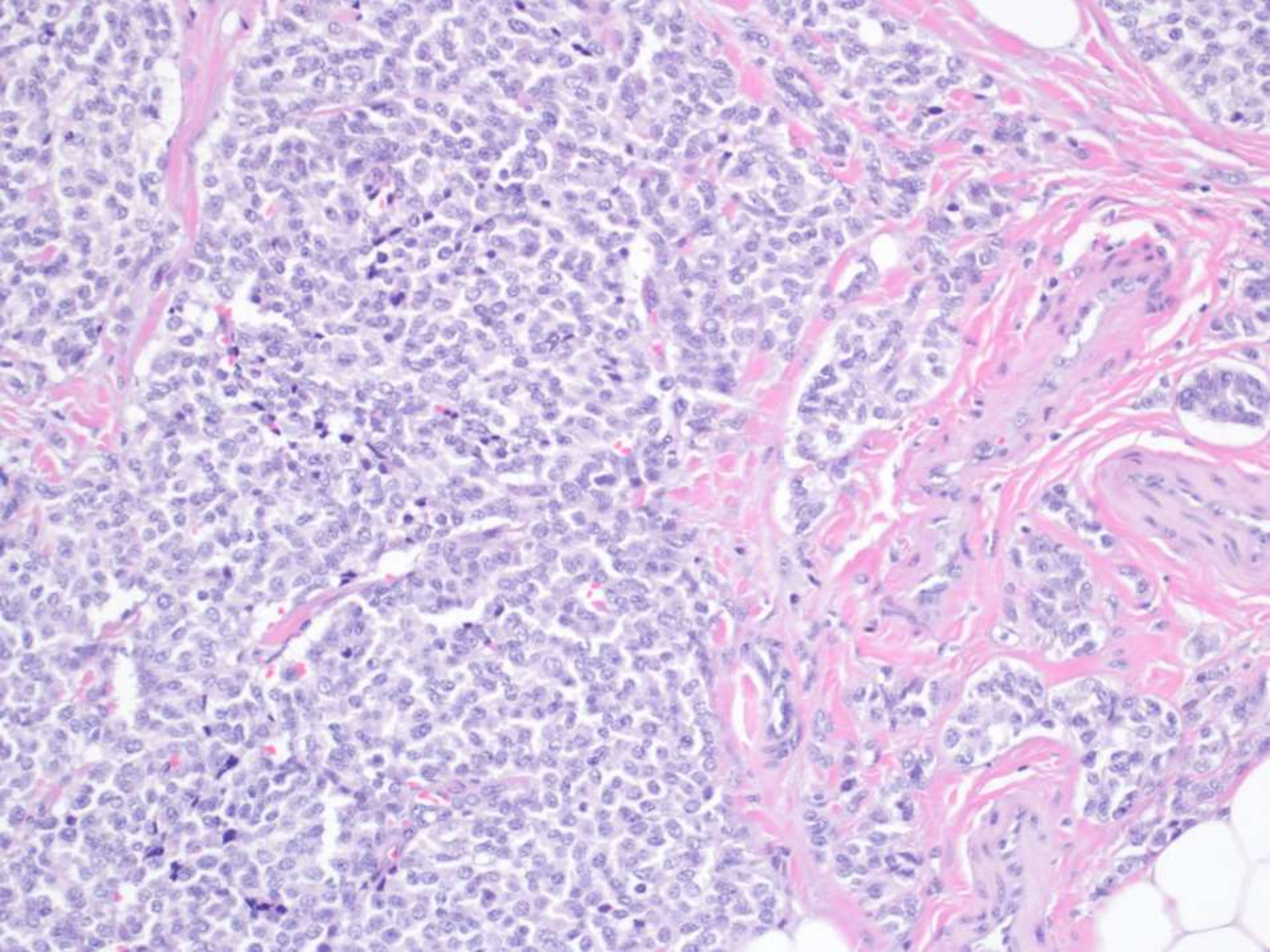
Megan Troxell; Stanford

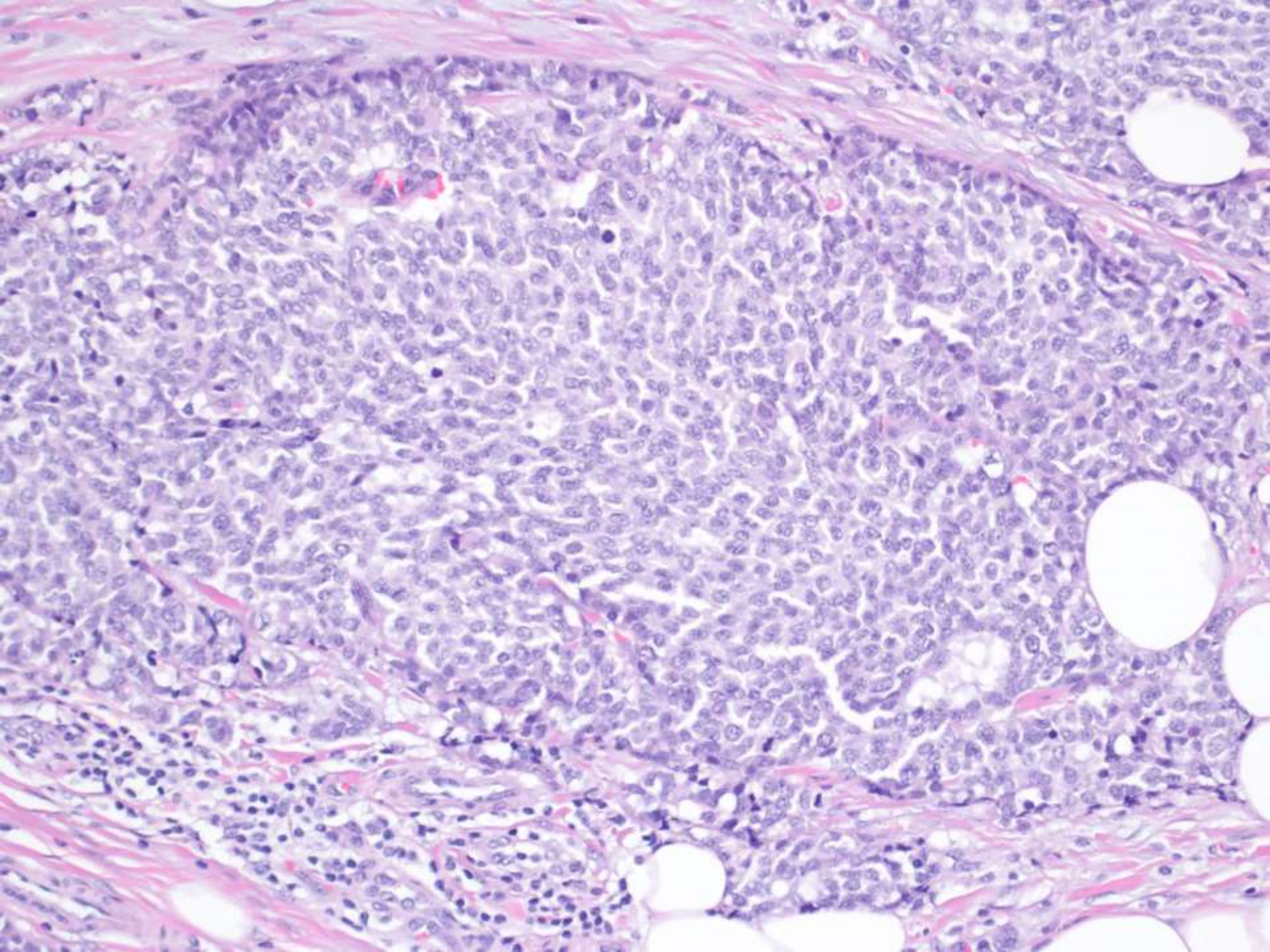
35-year-old F with breast lesion; needle biopsy
benign; lumpectomy performed.







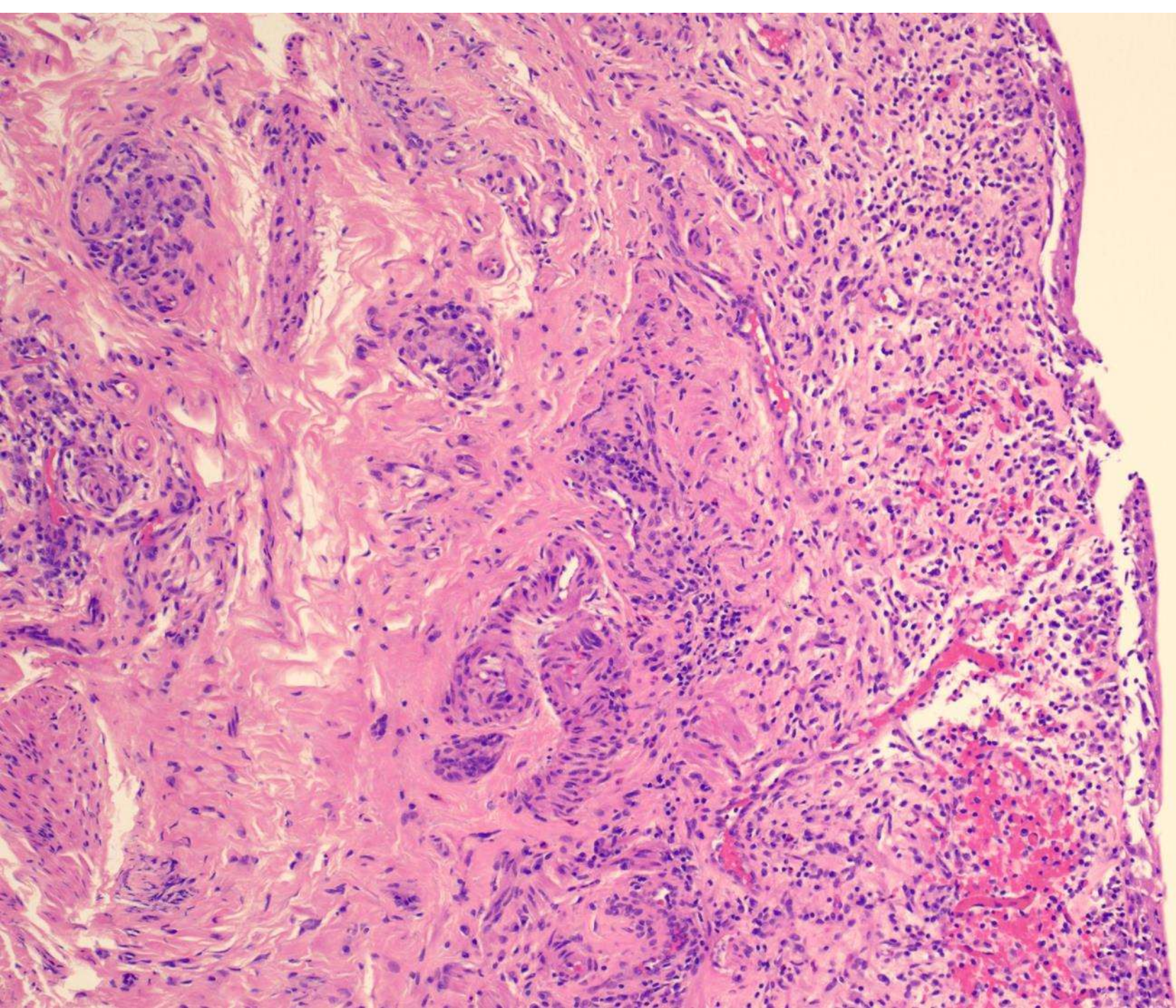


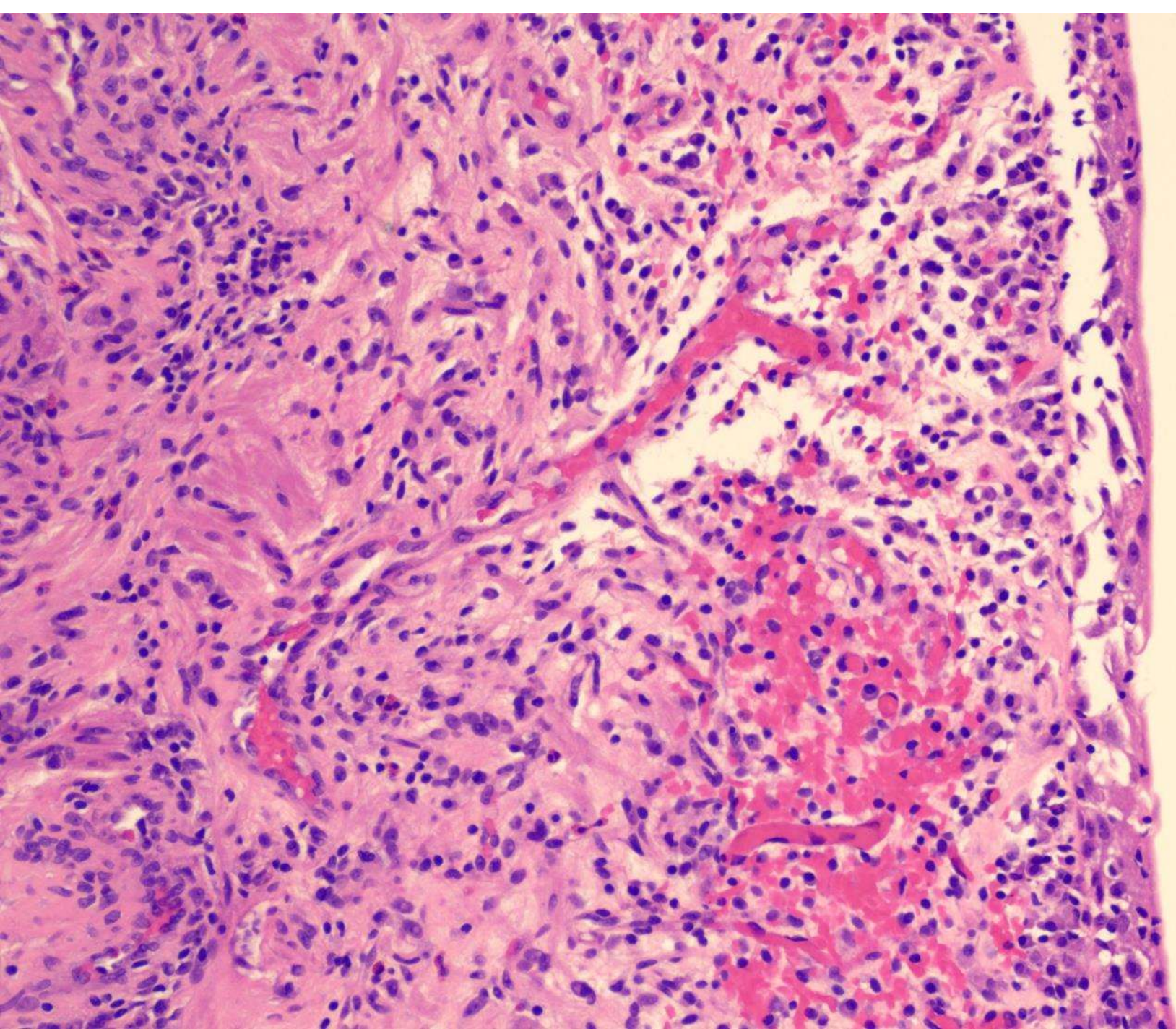


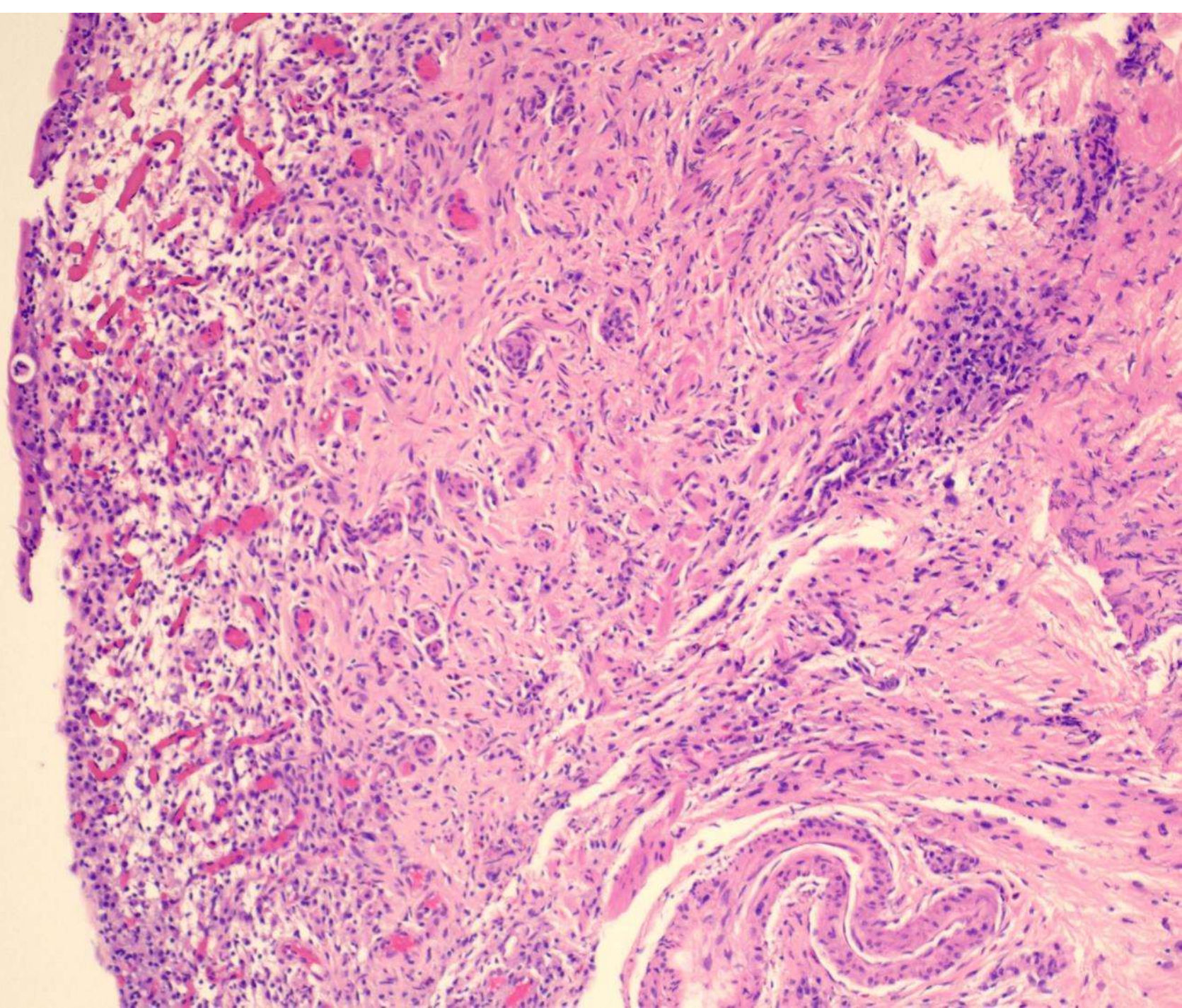
21-0702

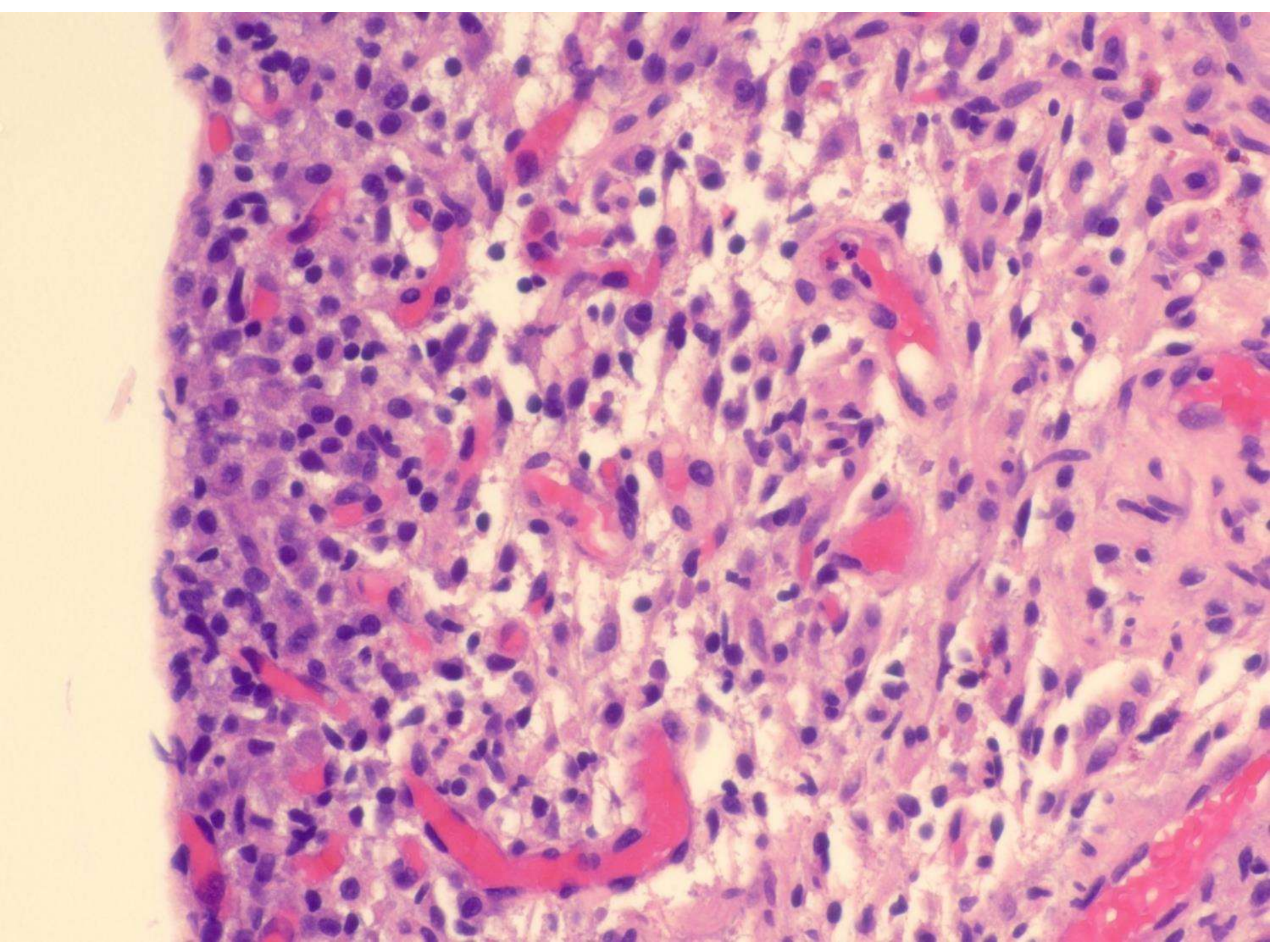
Charles Lombard, El Camino Hospital

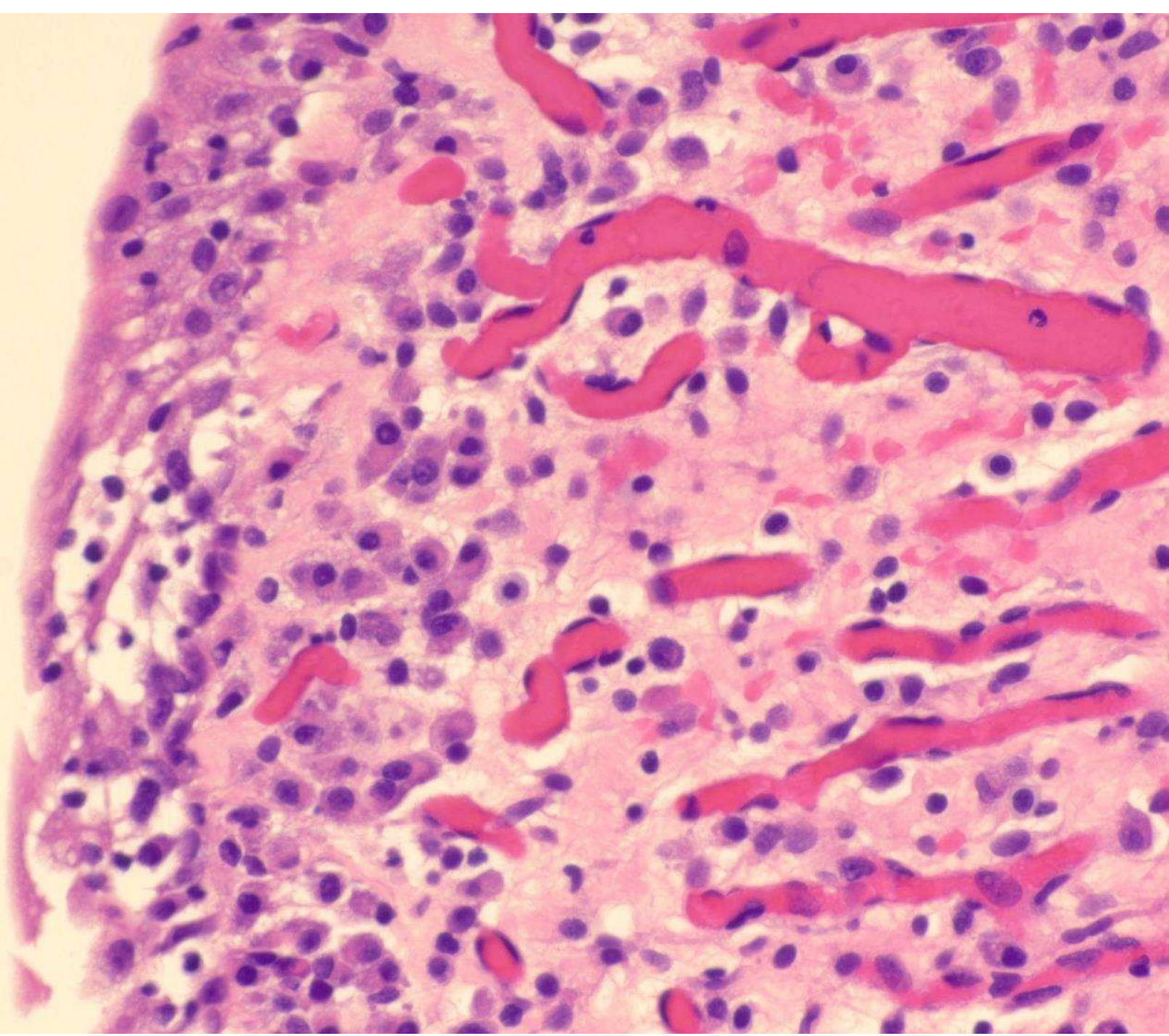
42-year-old M history of Henoch Schönlein Purpura and possible Crohn's disease has persistent urinary discomfort and bladder lesions.



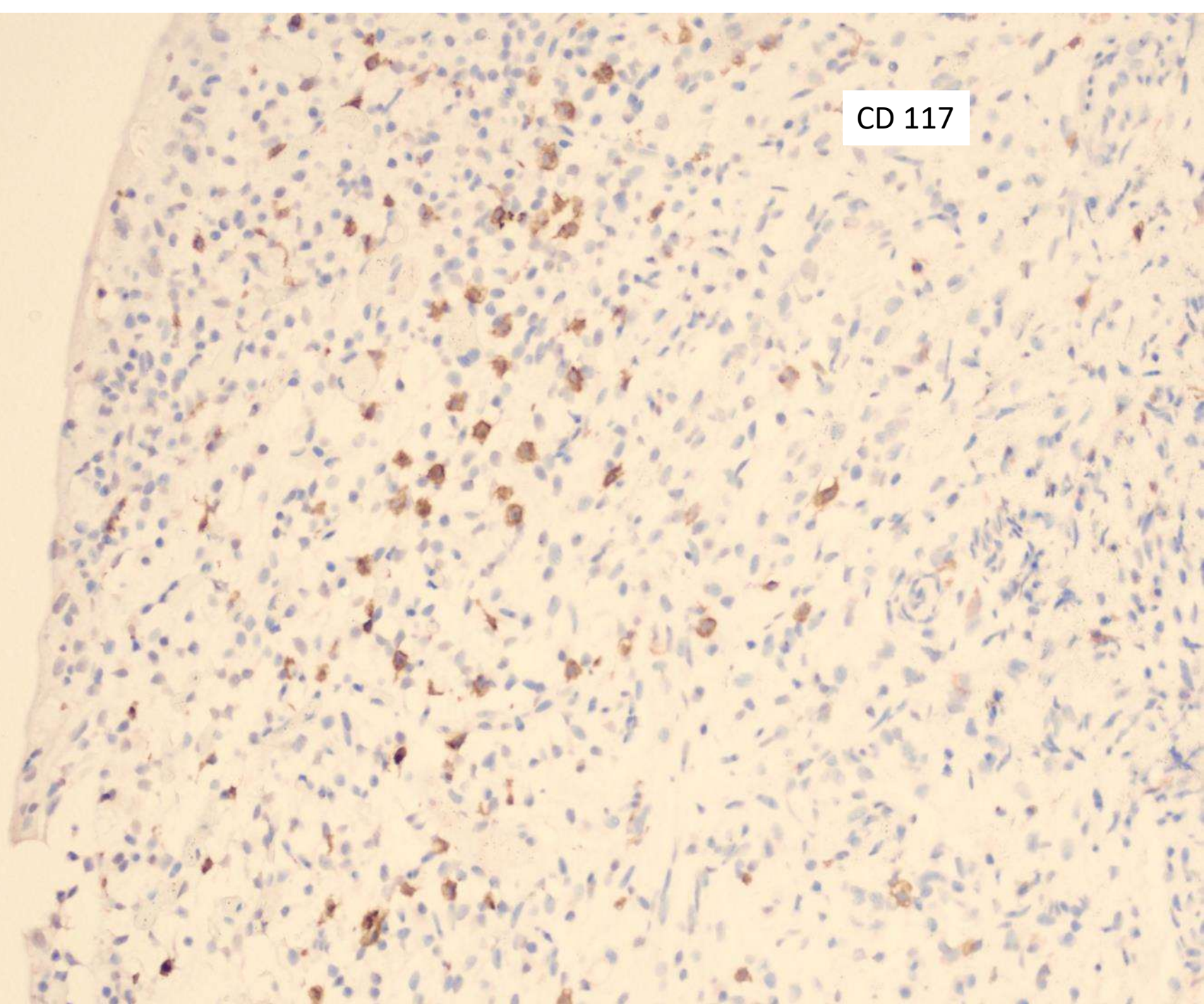




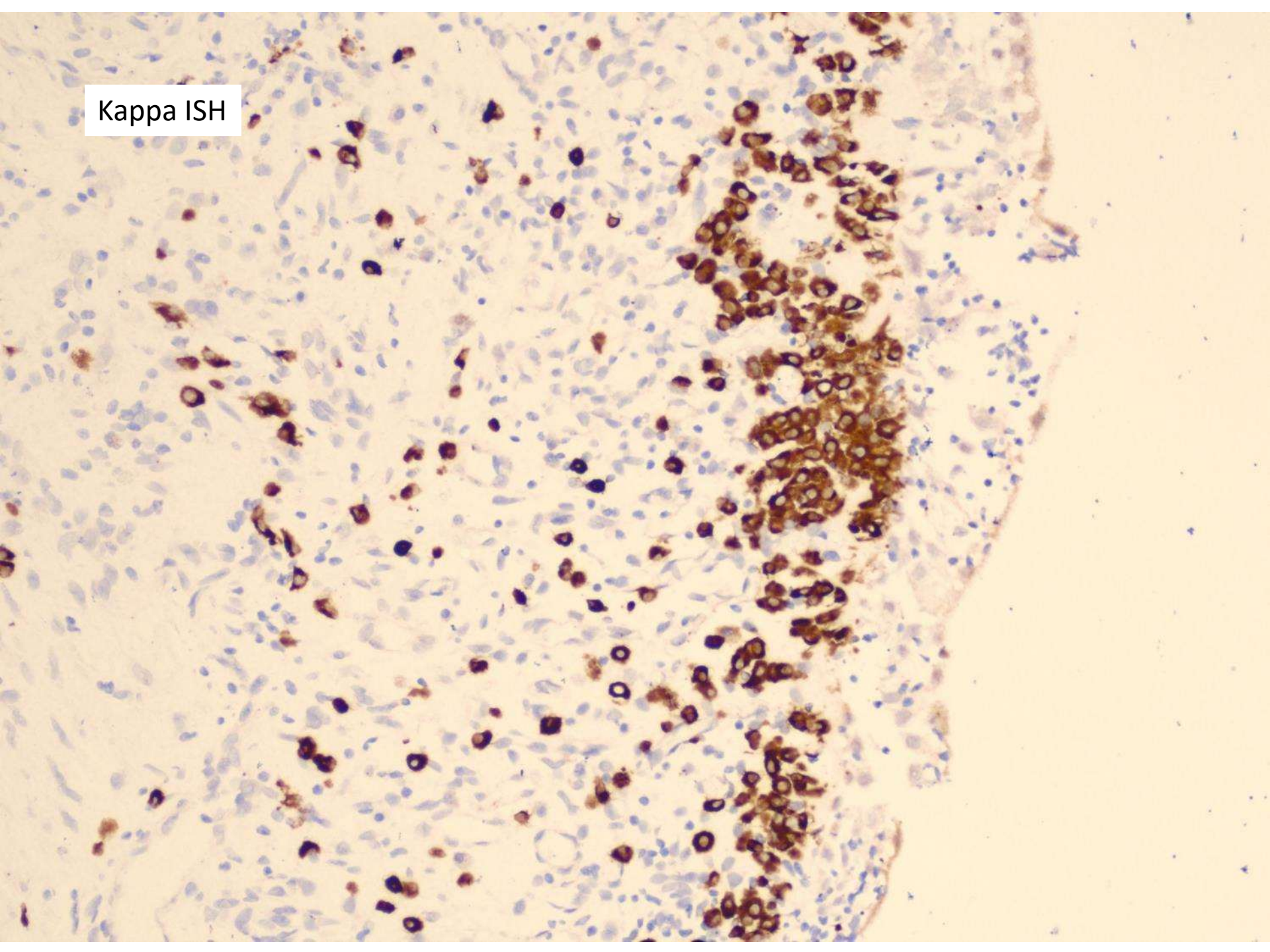




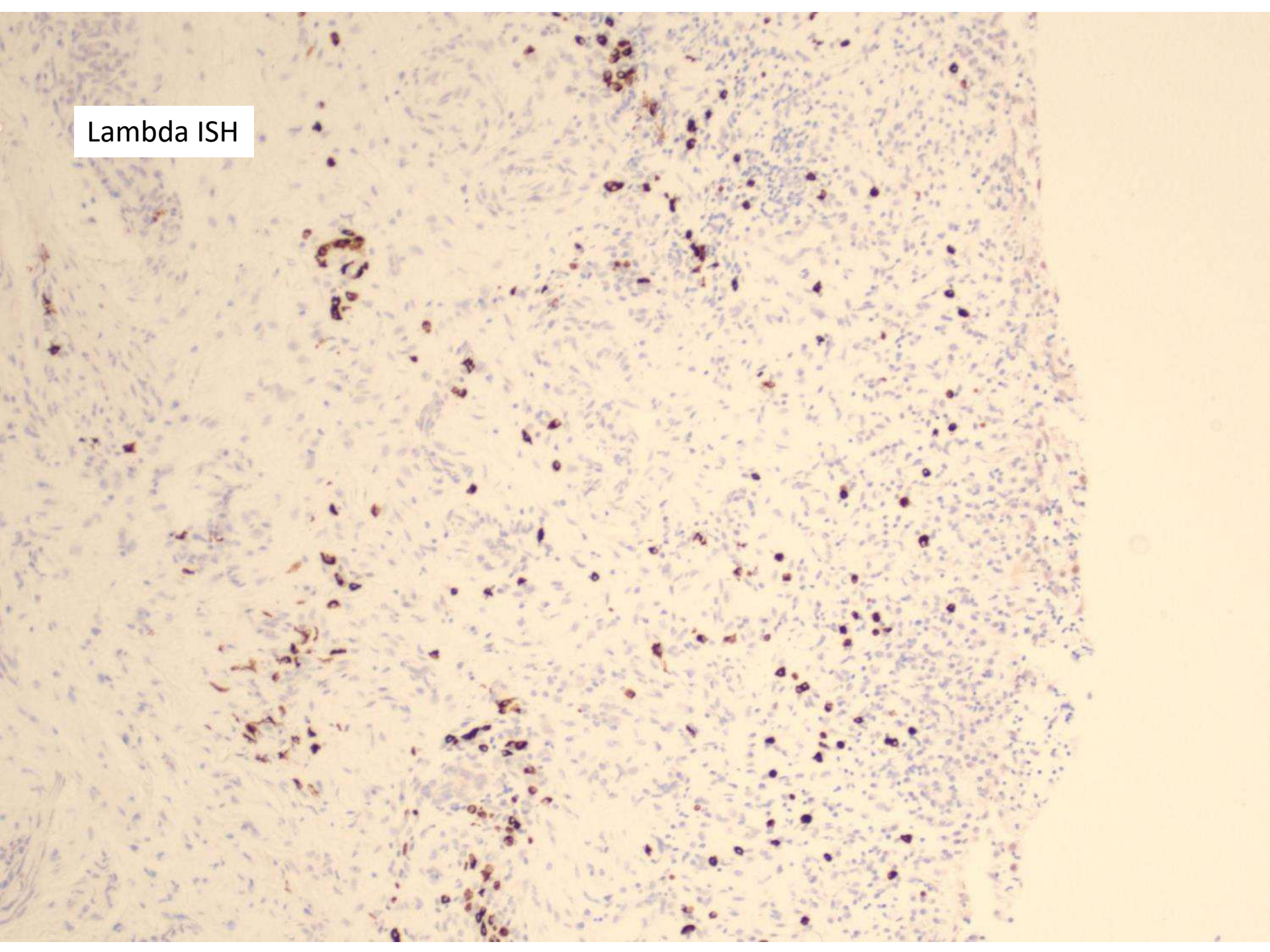
CD 117



Kappa ISH



Lambda ISH



21-0703

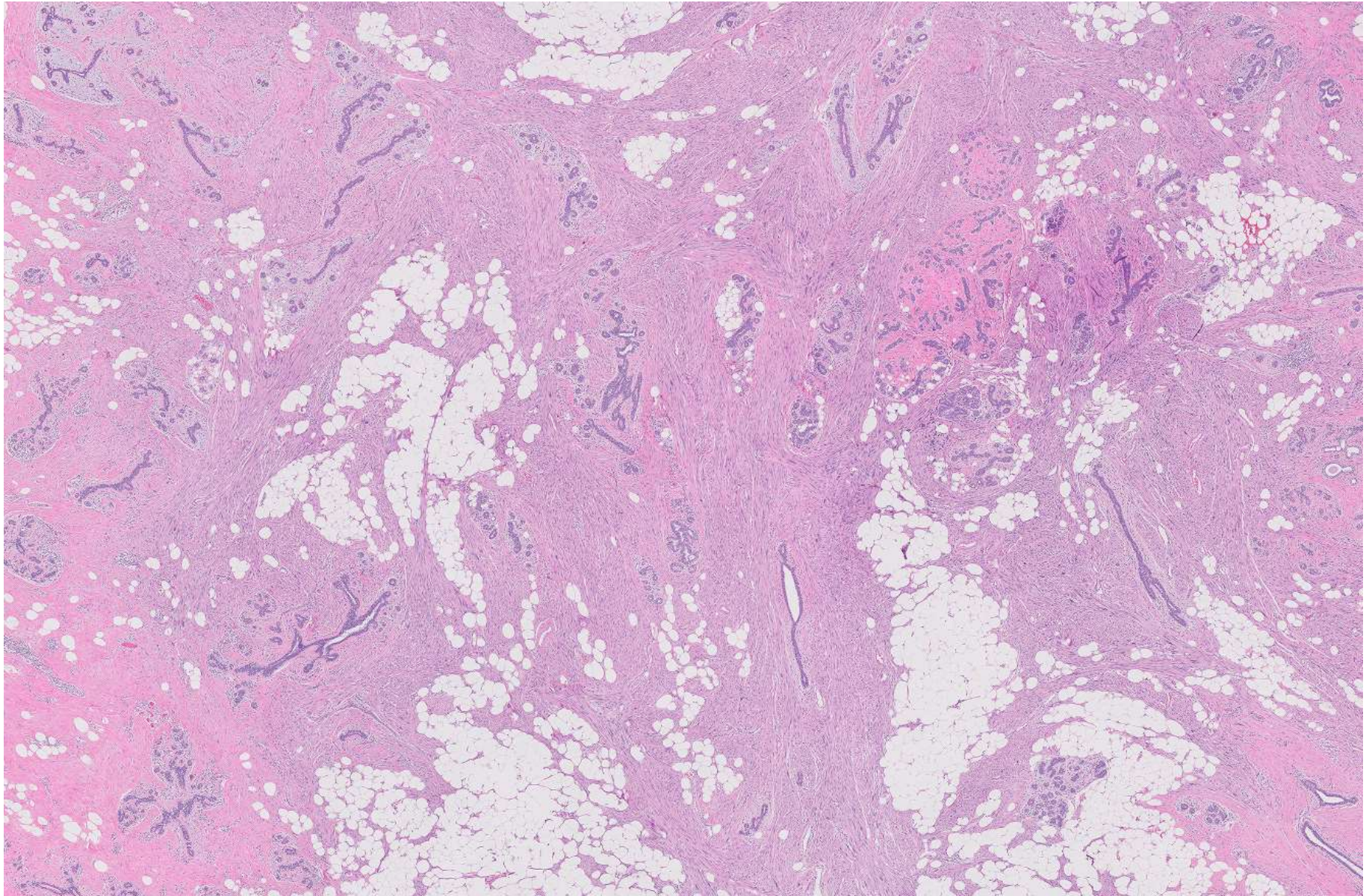
Ben Dulken/Gregory Bean; Stanford

20-year-old F with Li-Fraumeni syndrome, with history of borderline phyllodes tumor and DCIS.

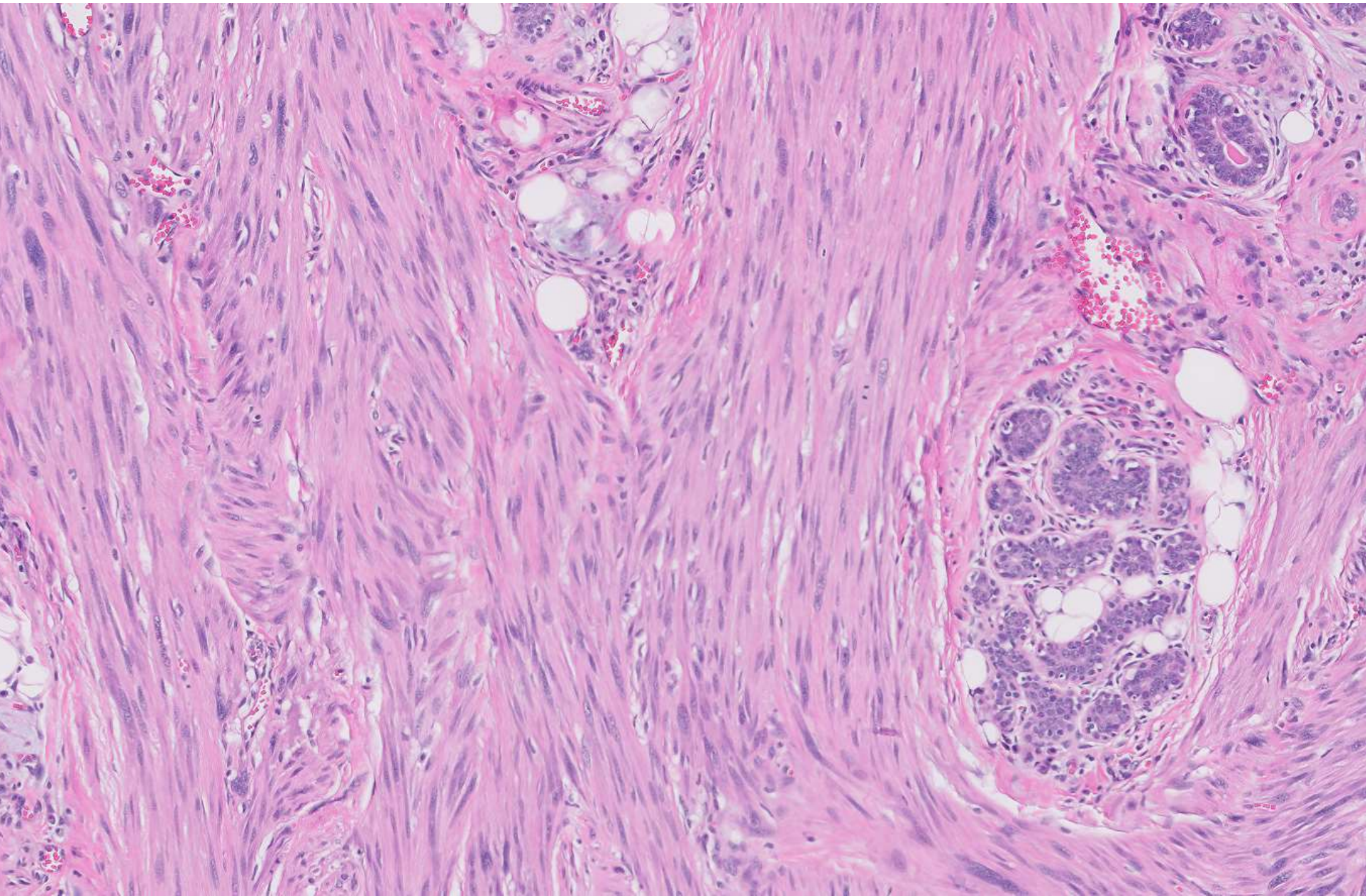
History

- 20Y female
- History of excision of borderline phyllodes tumor with small focus of DCIS.
- History of osteosarcoma of the humerus s/p resection and radiation at age 13.
- Undergoing bilateral mastectomy.
- Several targeted lesions in bilateral breasts by imaging.

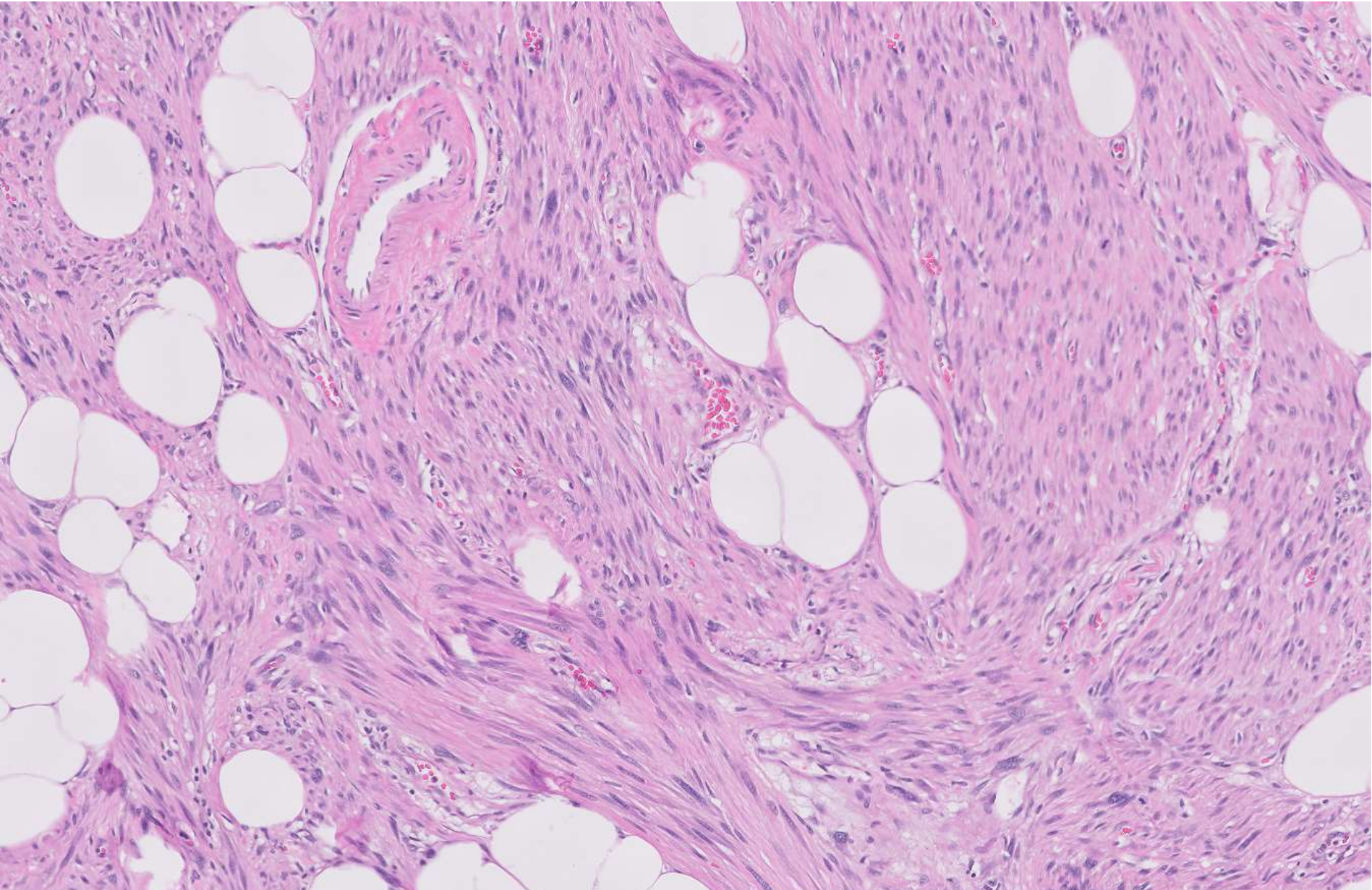
Infiltrative lesion in the left breast



Infiltrative lesion in the left breast



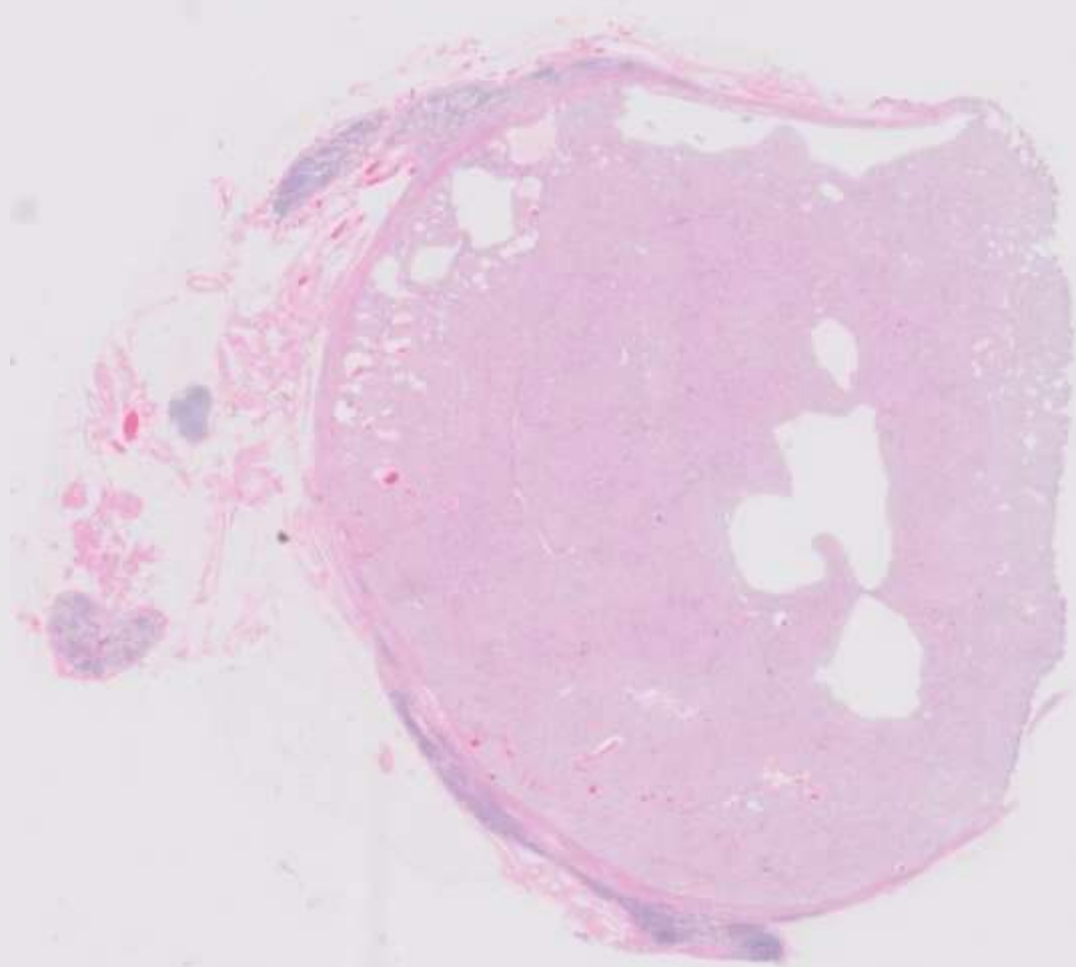
Infiltrative lesion in the left breast

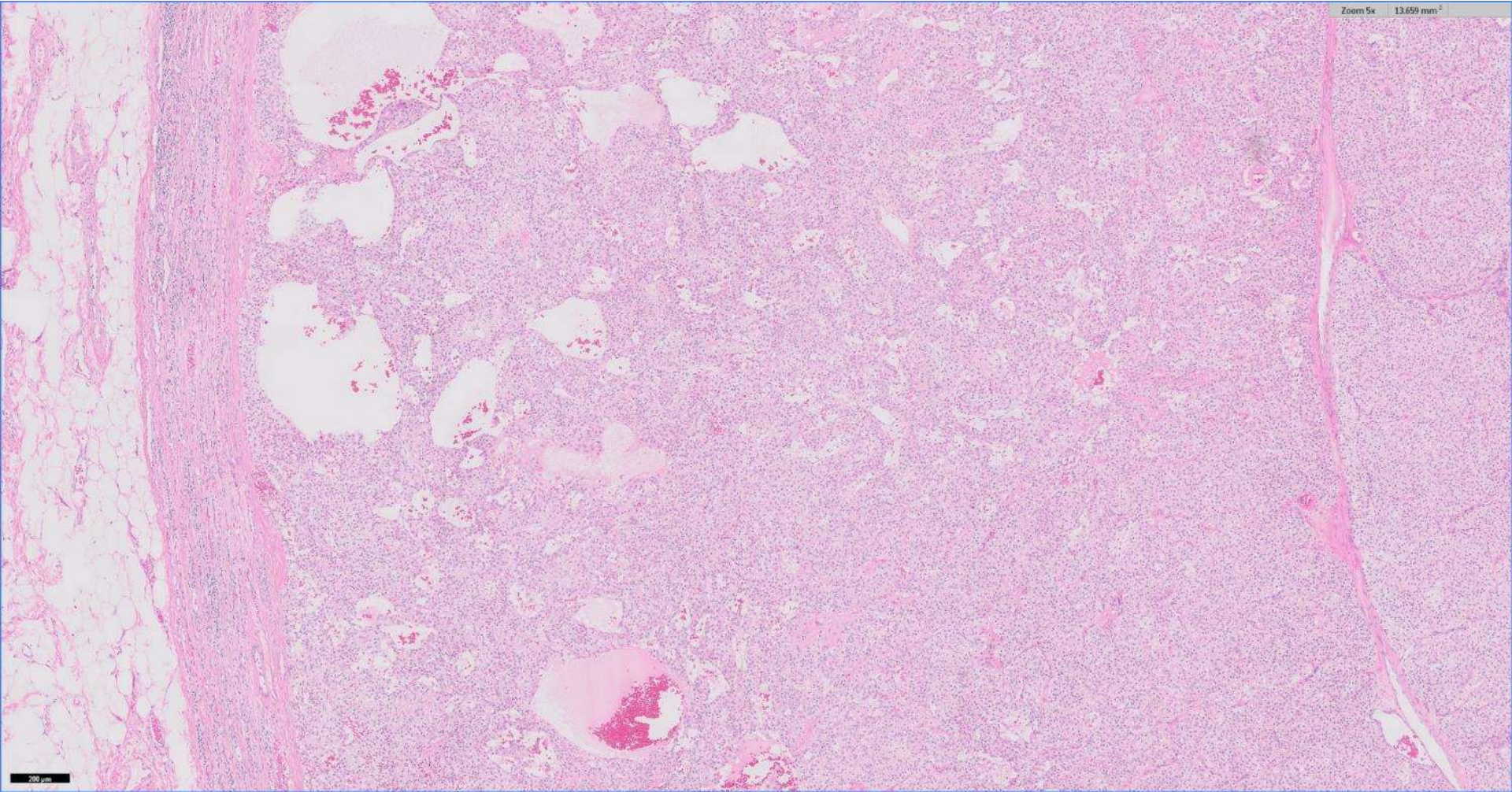


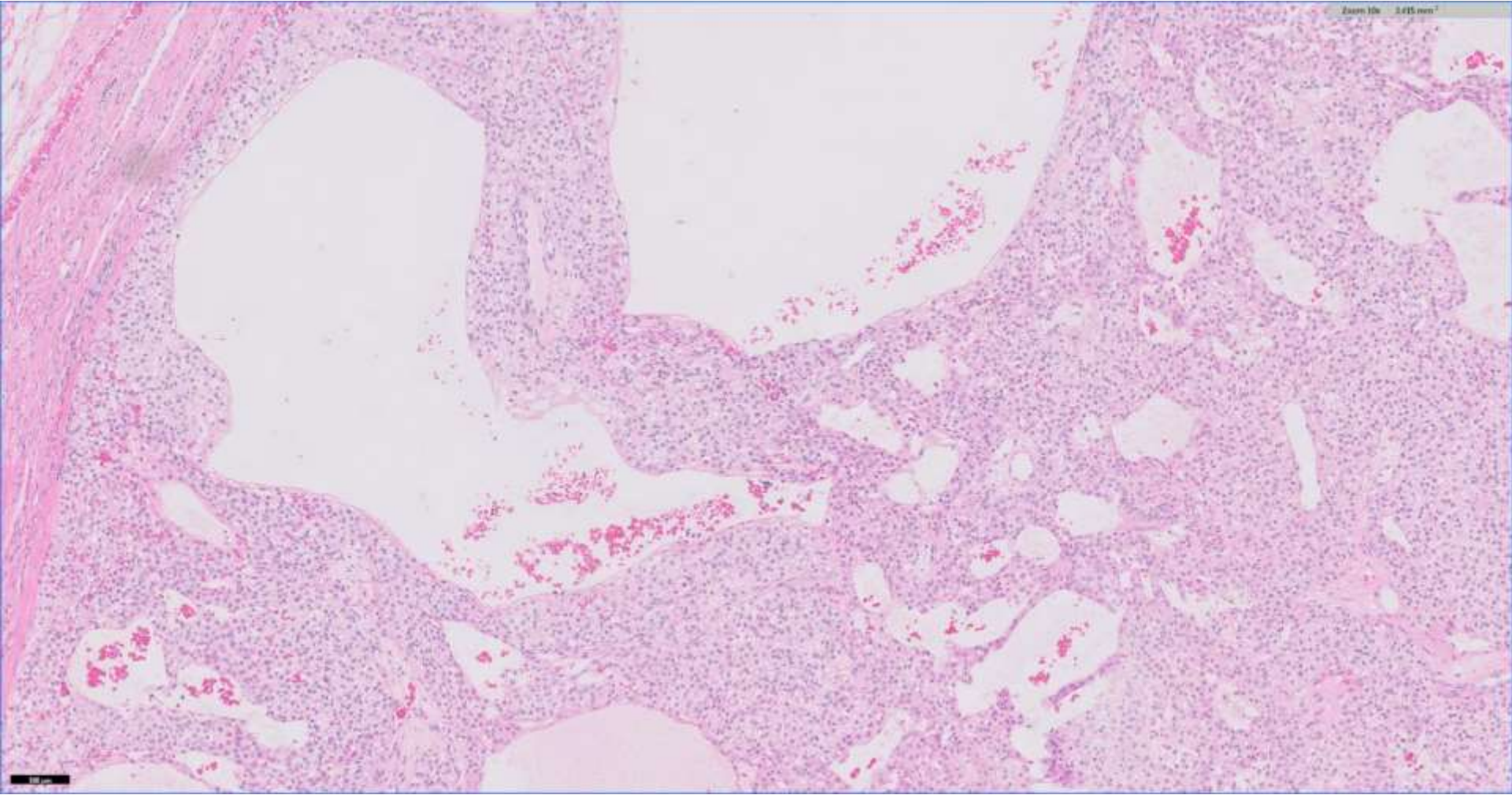
21-0704

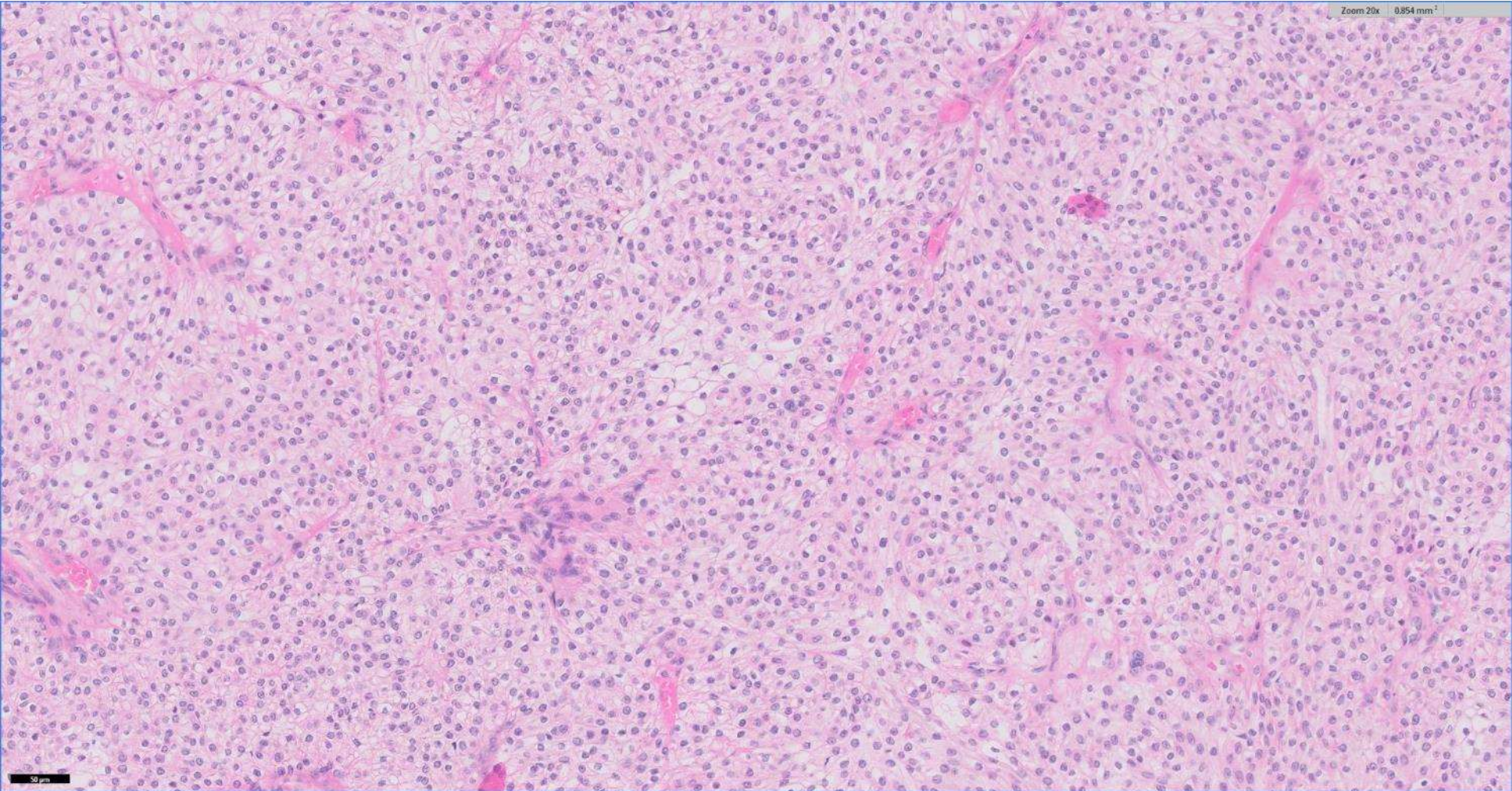
Nicholas Ladwig; UCSF

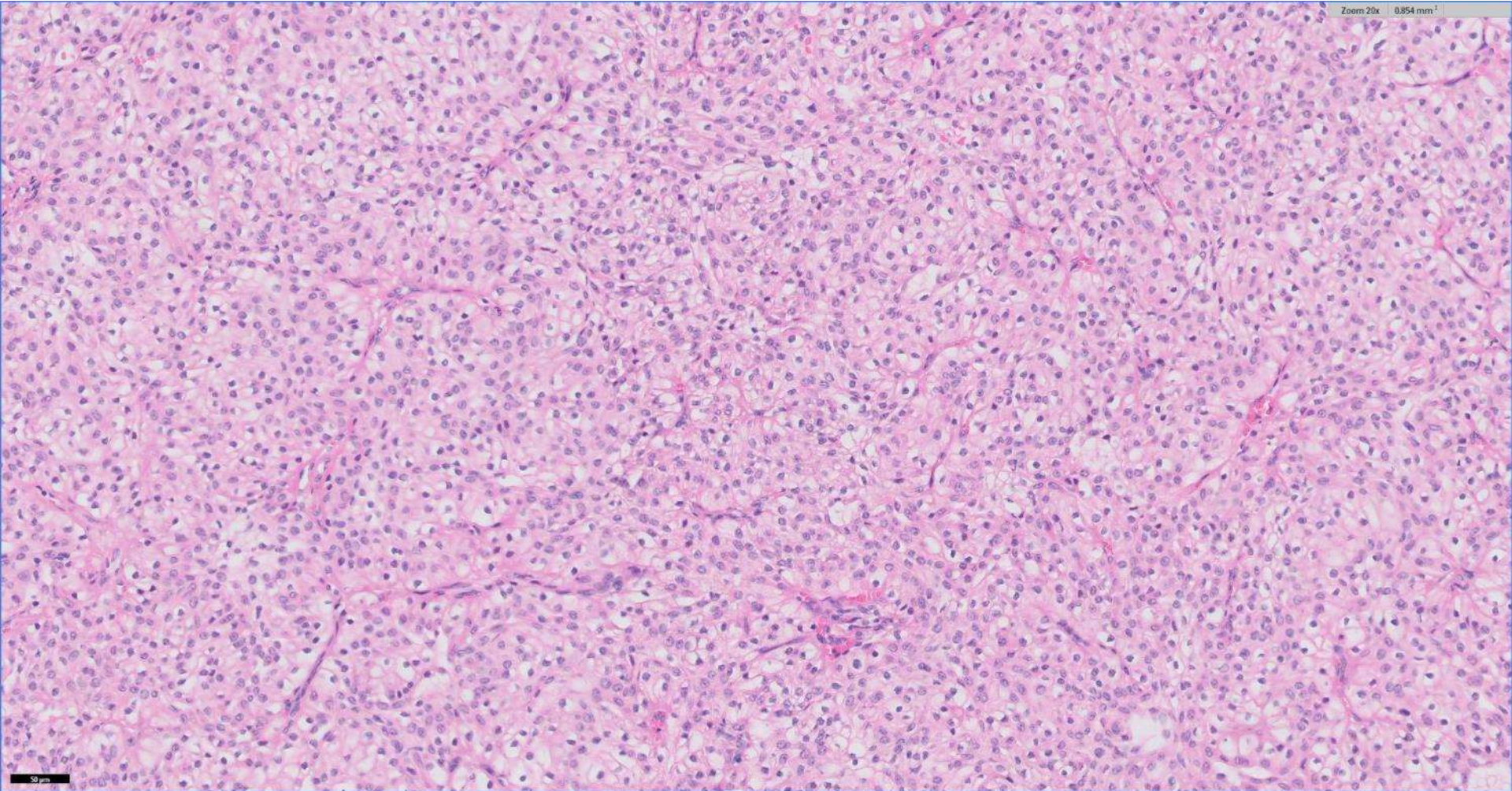
31-year-old F with tender right inguinal mass. Full-body PET scan showed low-level metabolism in a right inguinal lymph node (2.2 cm) with no other sites of hypermetabolism

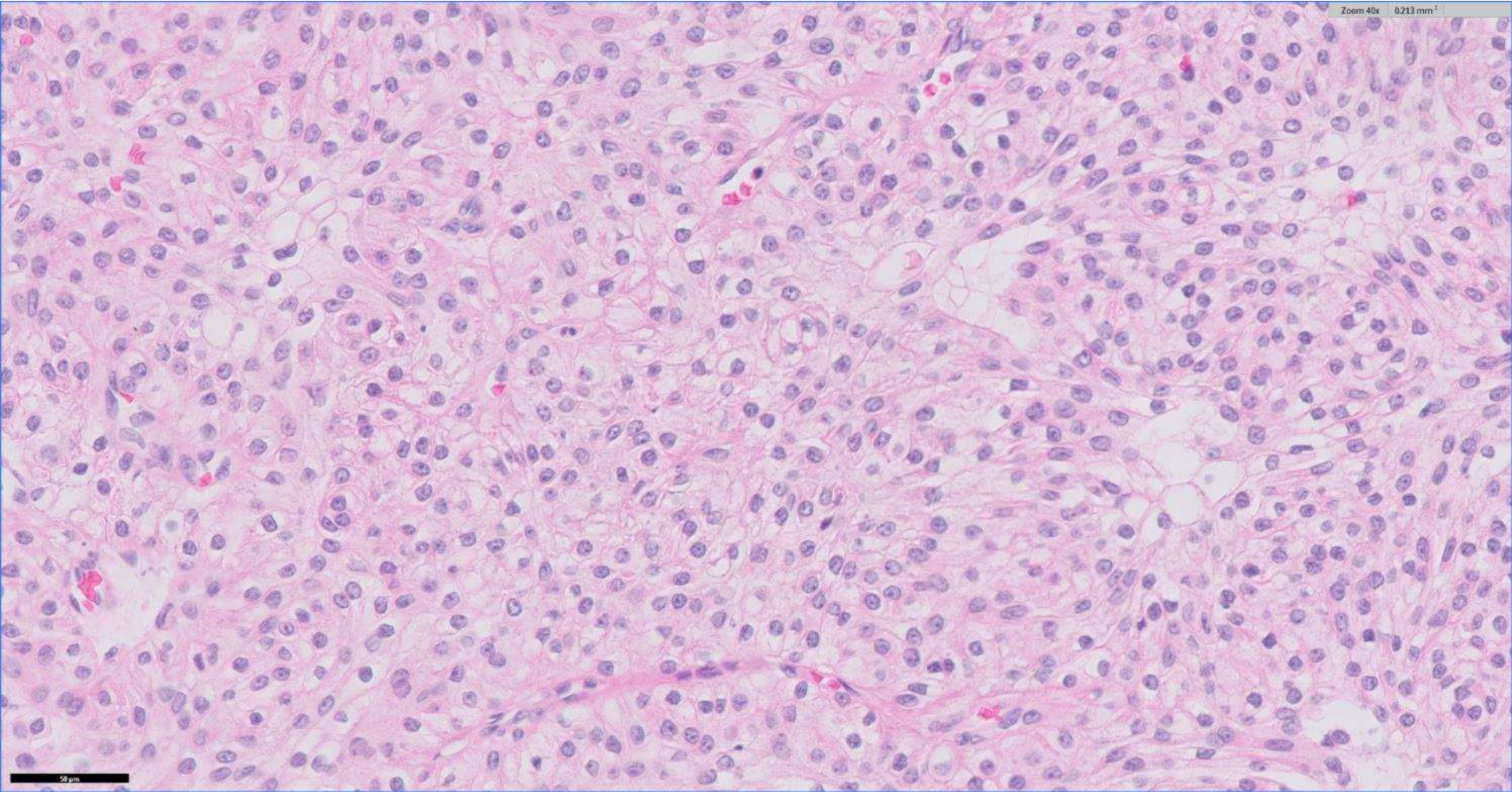


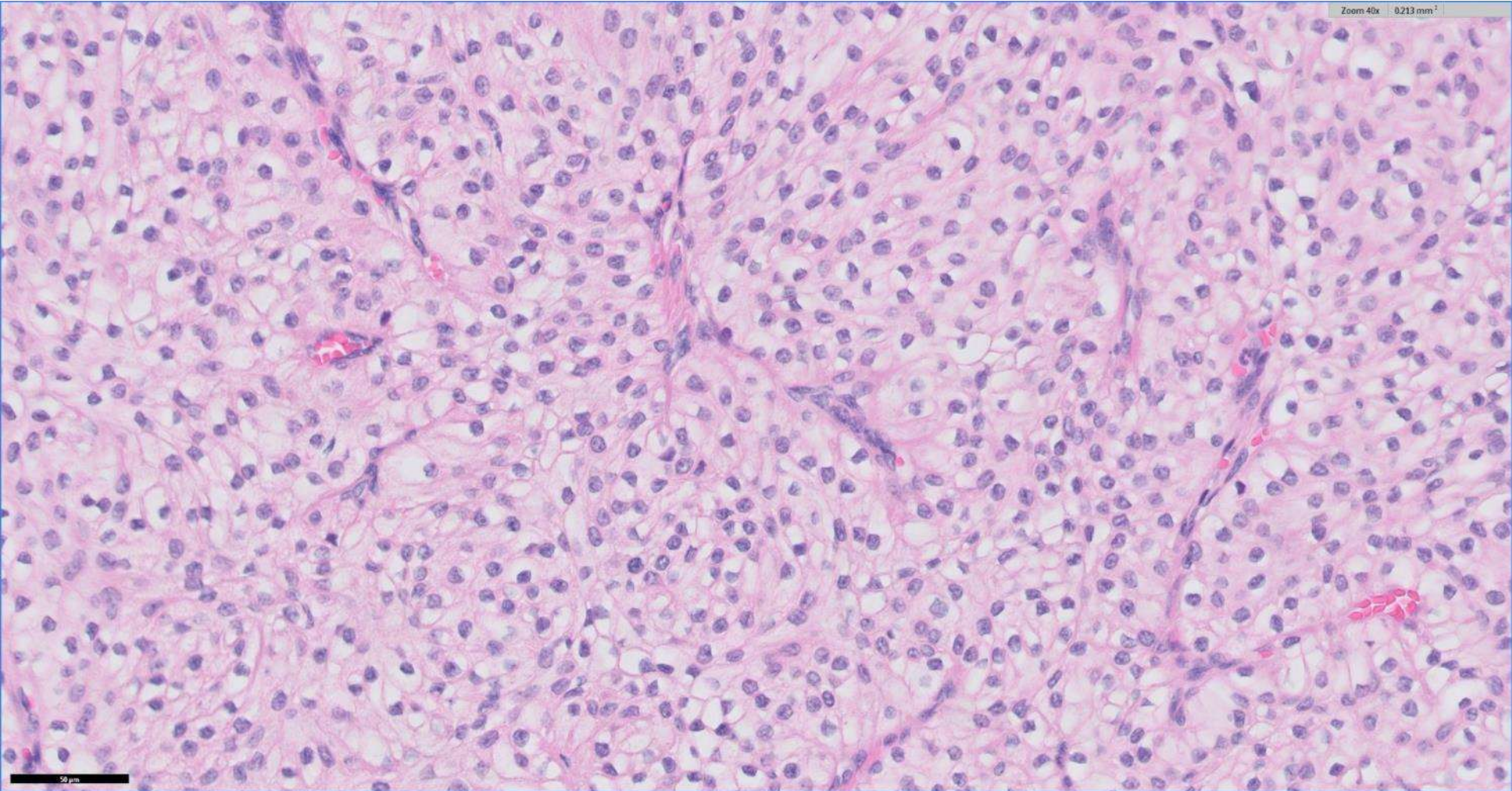










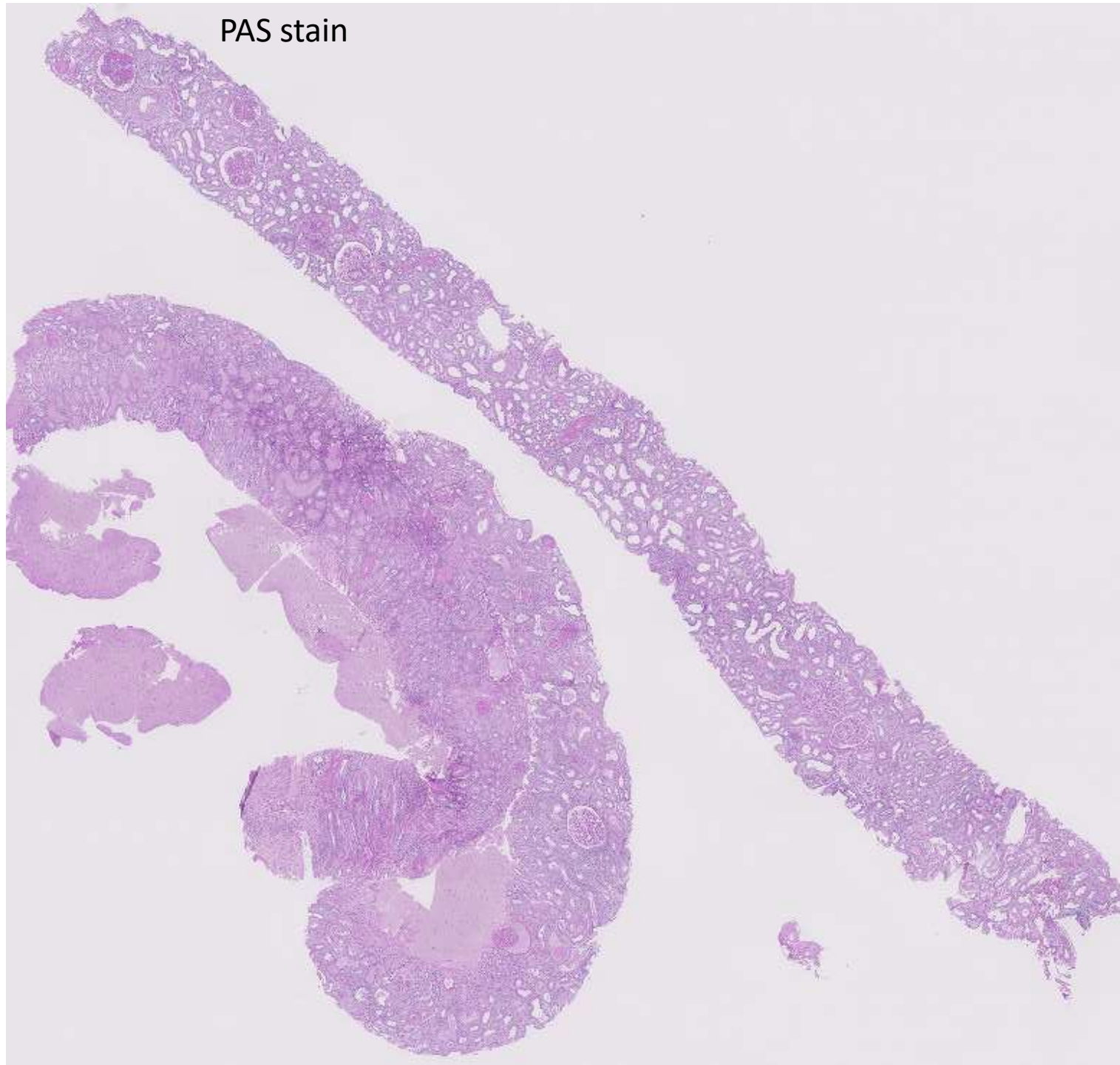


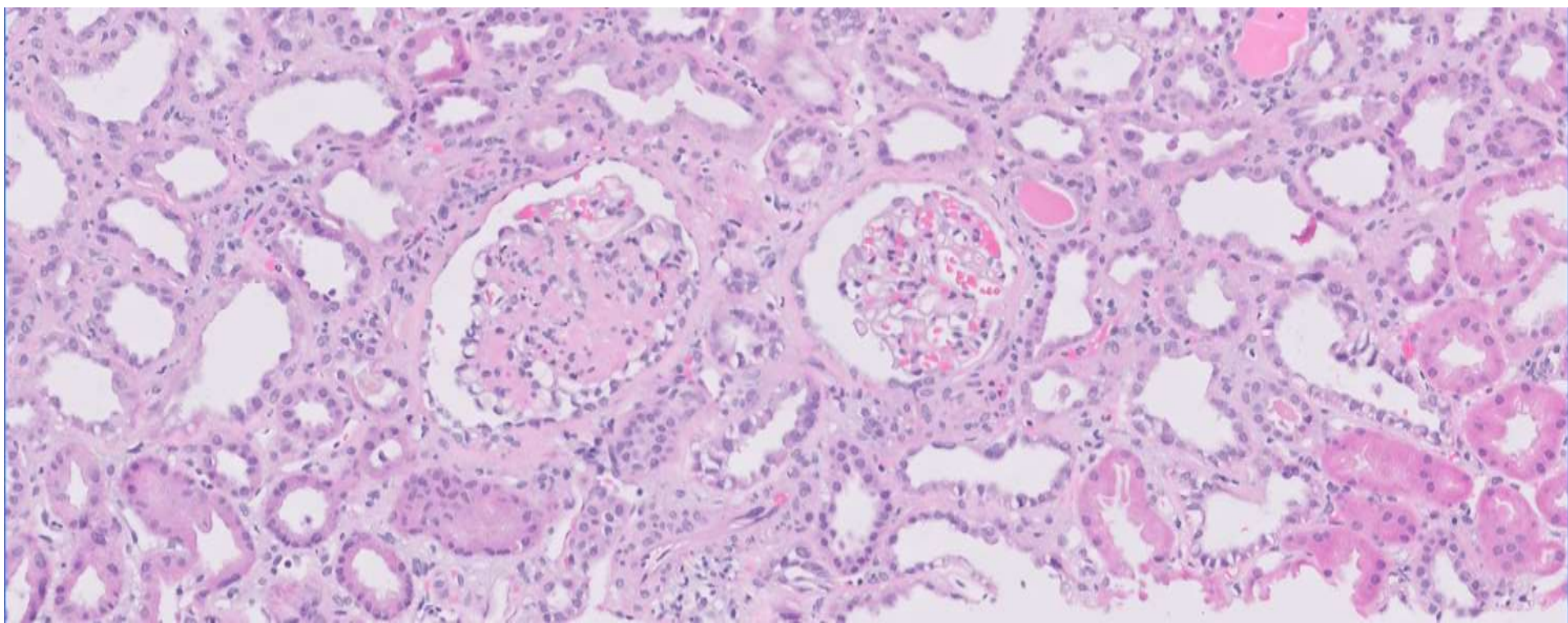
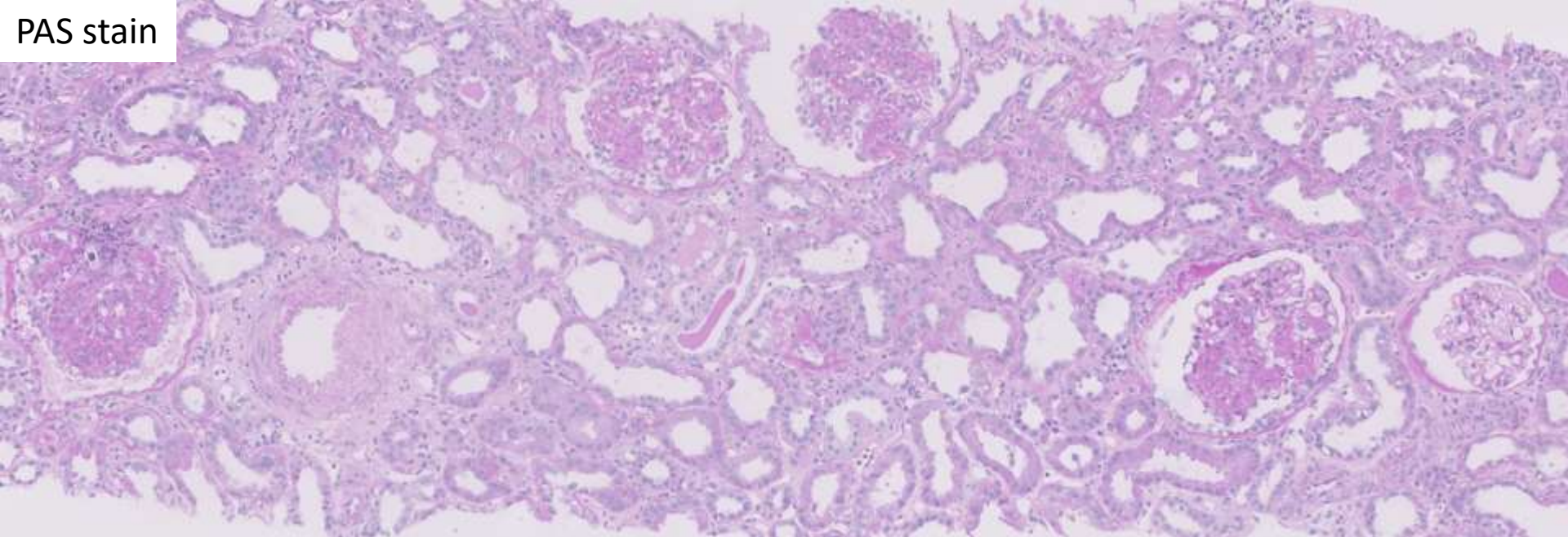
21-0705

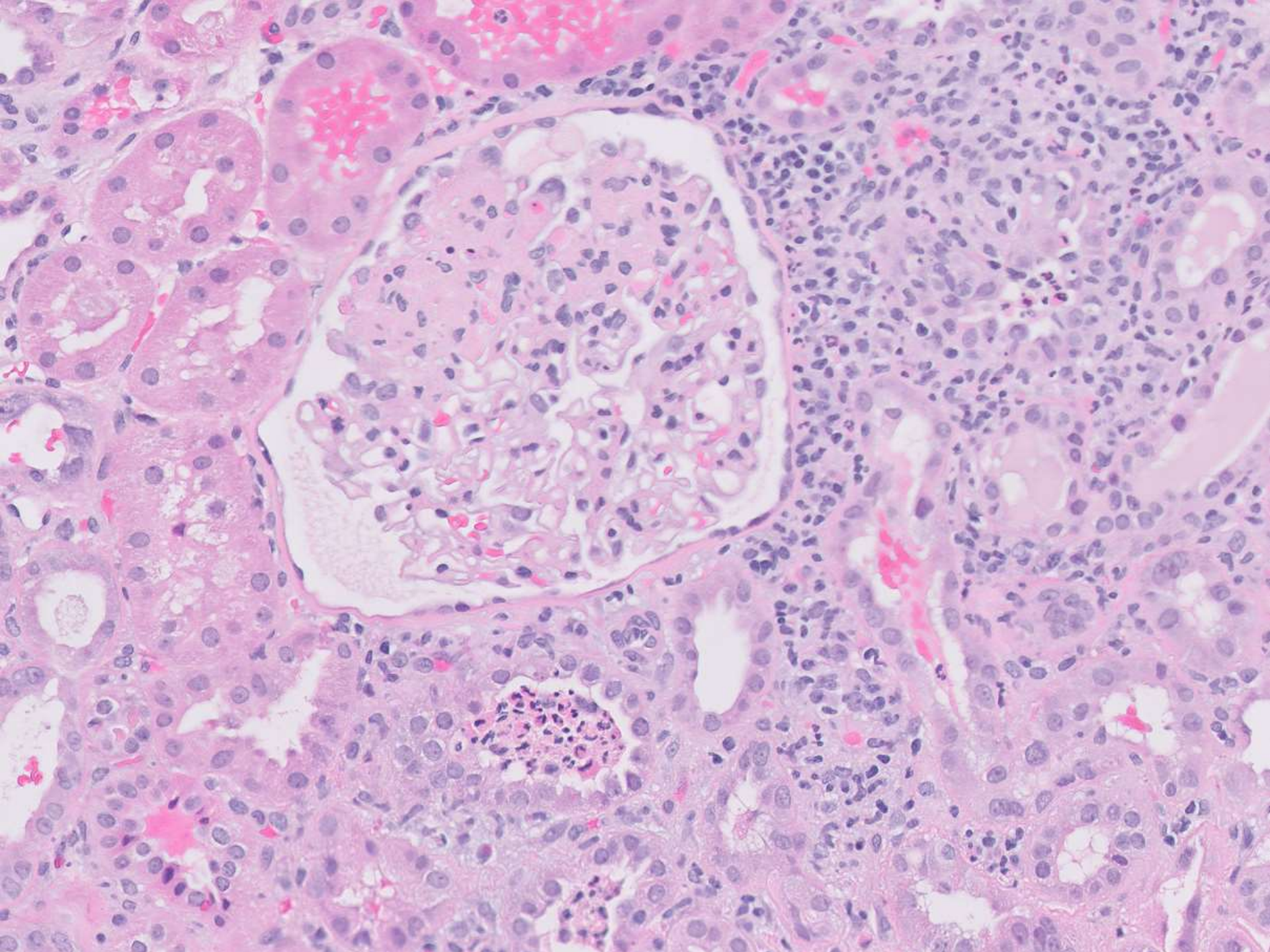
Paul Miller/Megan Troxell; Stanford

21-year-old African American man with recent COVID infection, pneumonia, flank pain. Rising creatinine and 11 gram/day proteinuria.

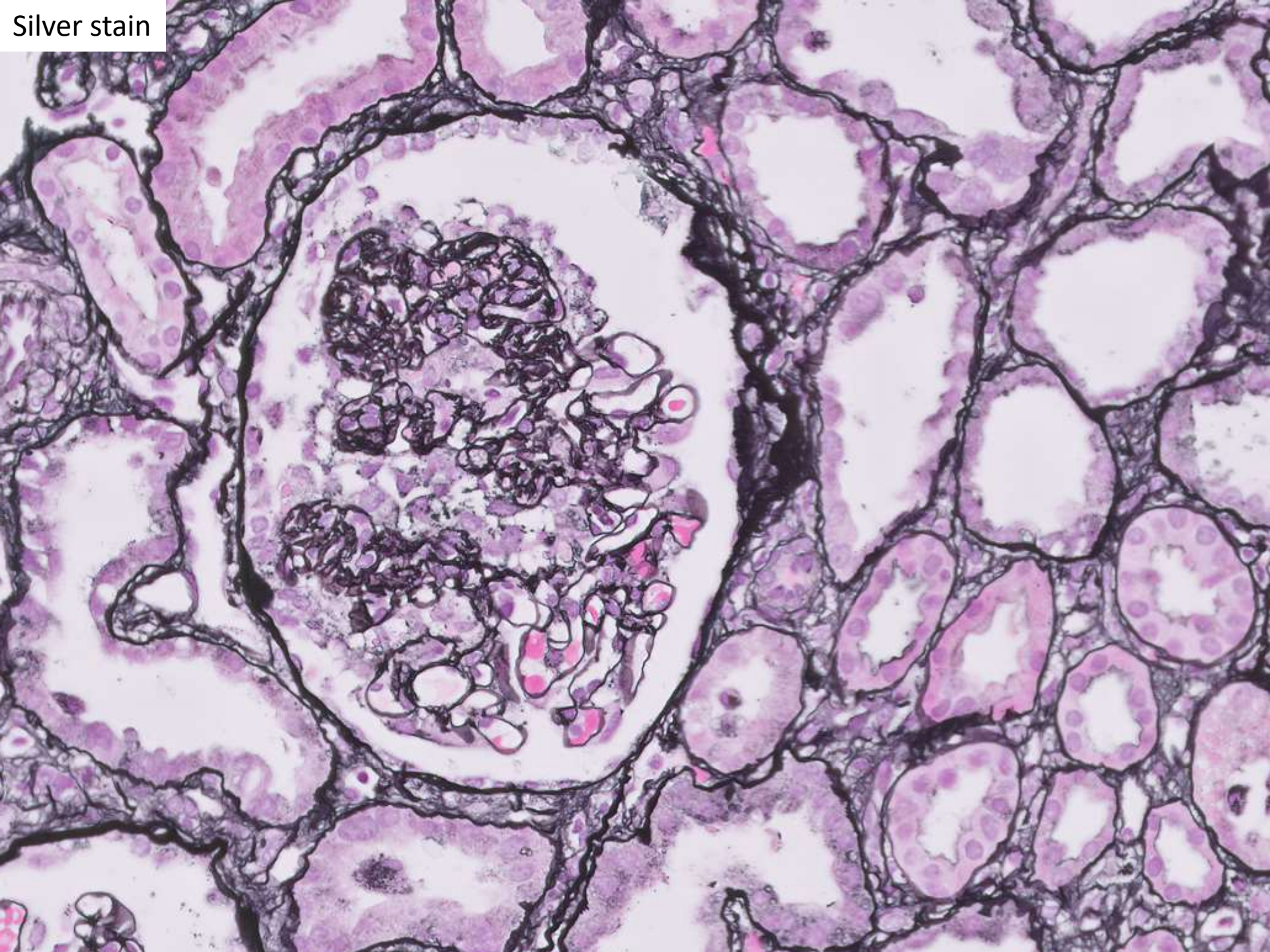
PAS stain



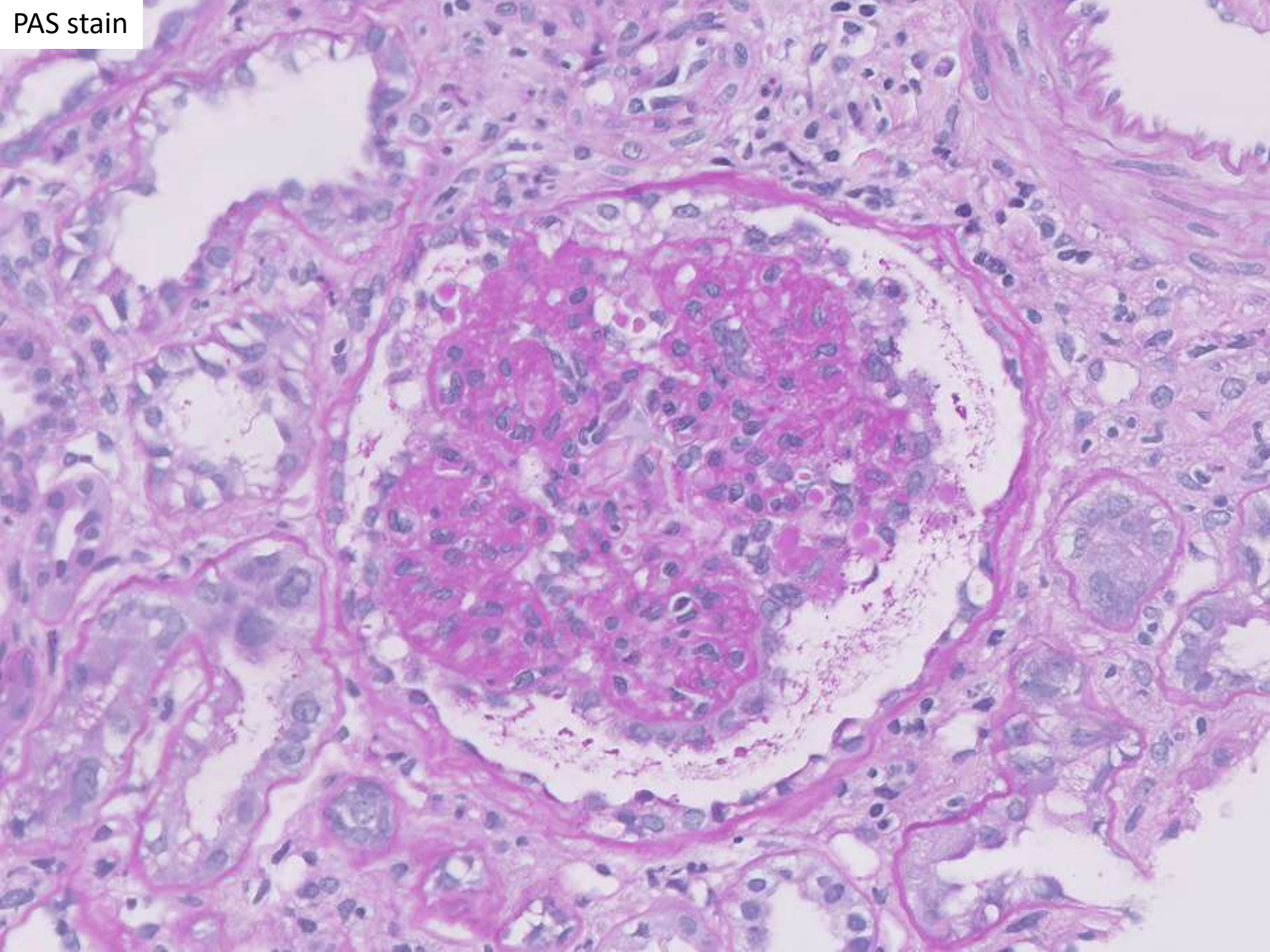




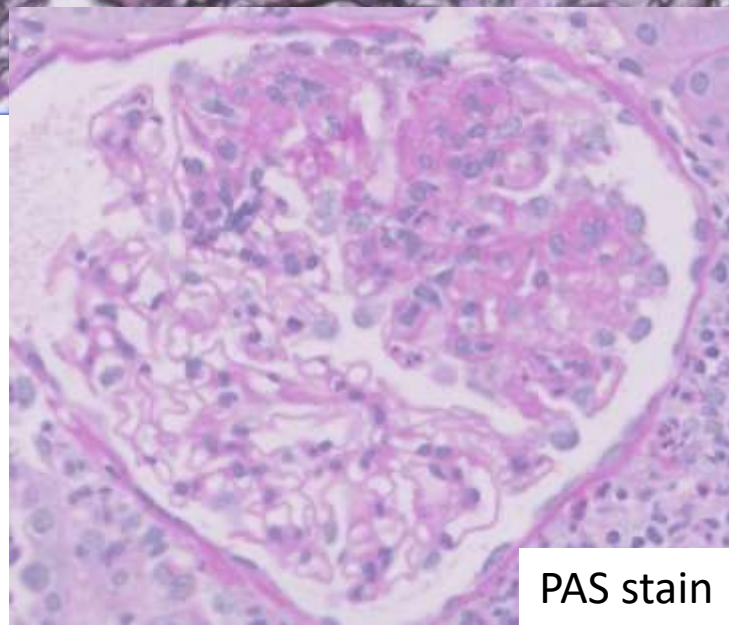
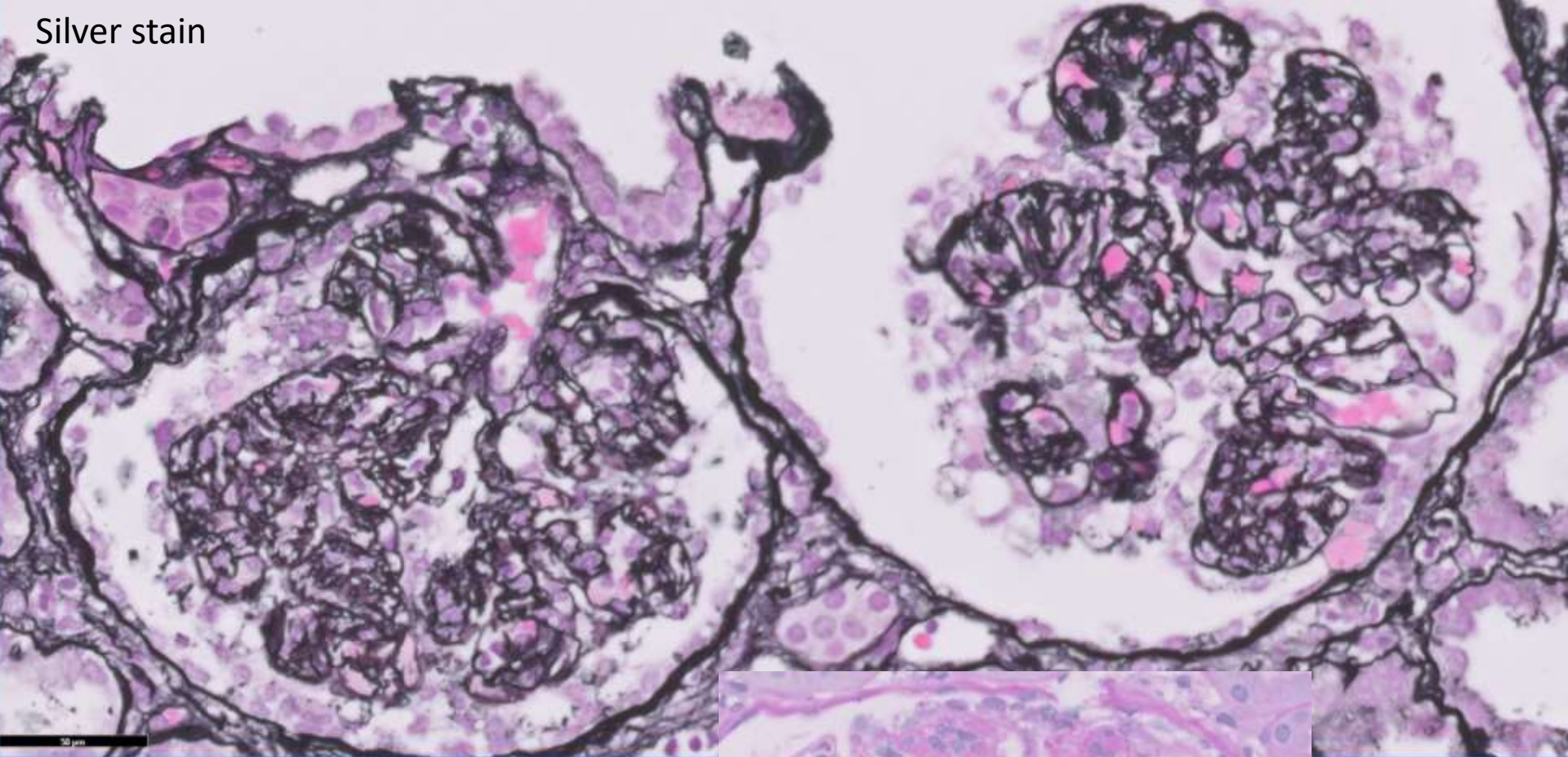
Silver stain



PAS stain



Silver stain

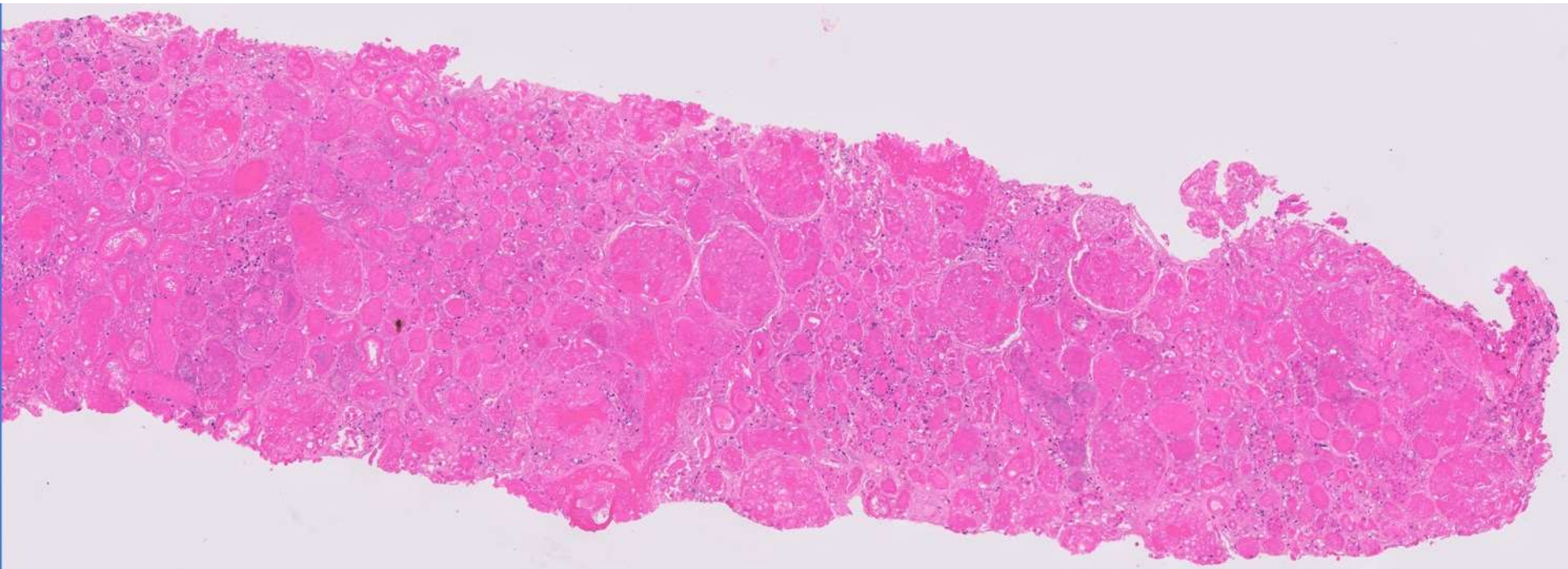


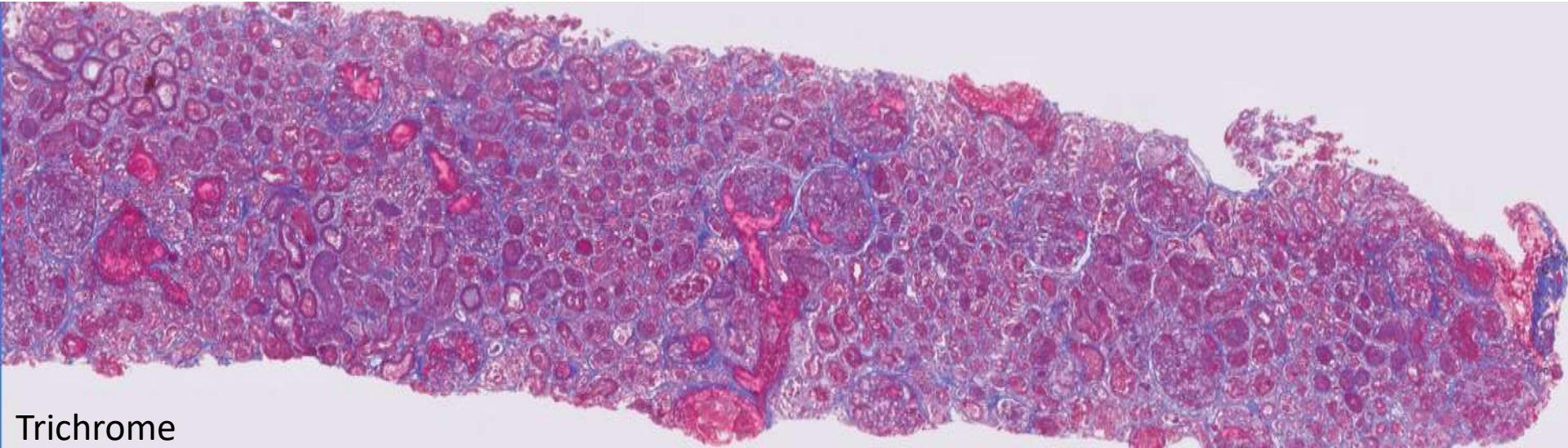
PAS stain

21-0706

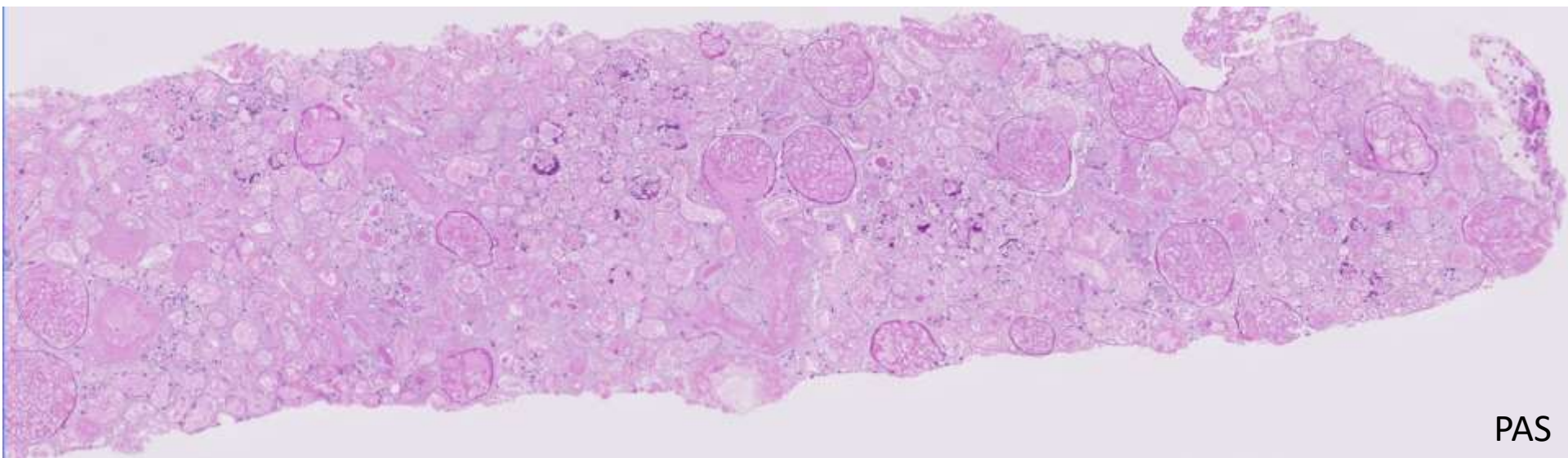
Megan Troxell; Stanford

6-year-old boy with Shiga toxin positive bloody diarrhea and thrombocytopenia, complicated by covid and Multisystem Infammatory Syndrome in Children (MIS-C). Renal biopsy during prolonged hospitalization.

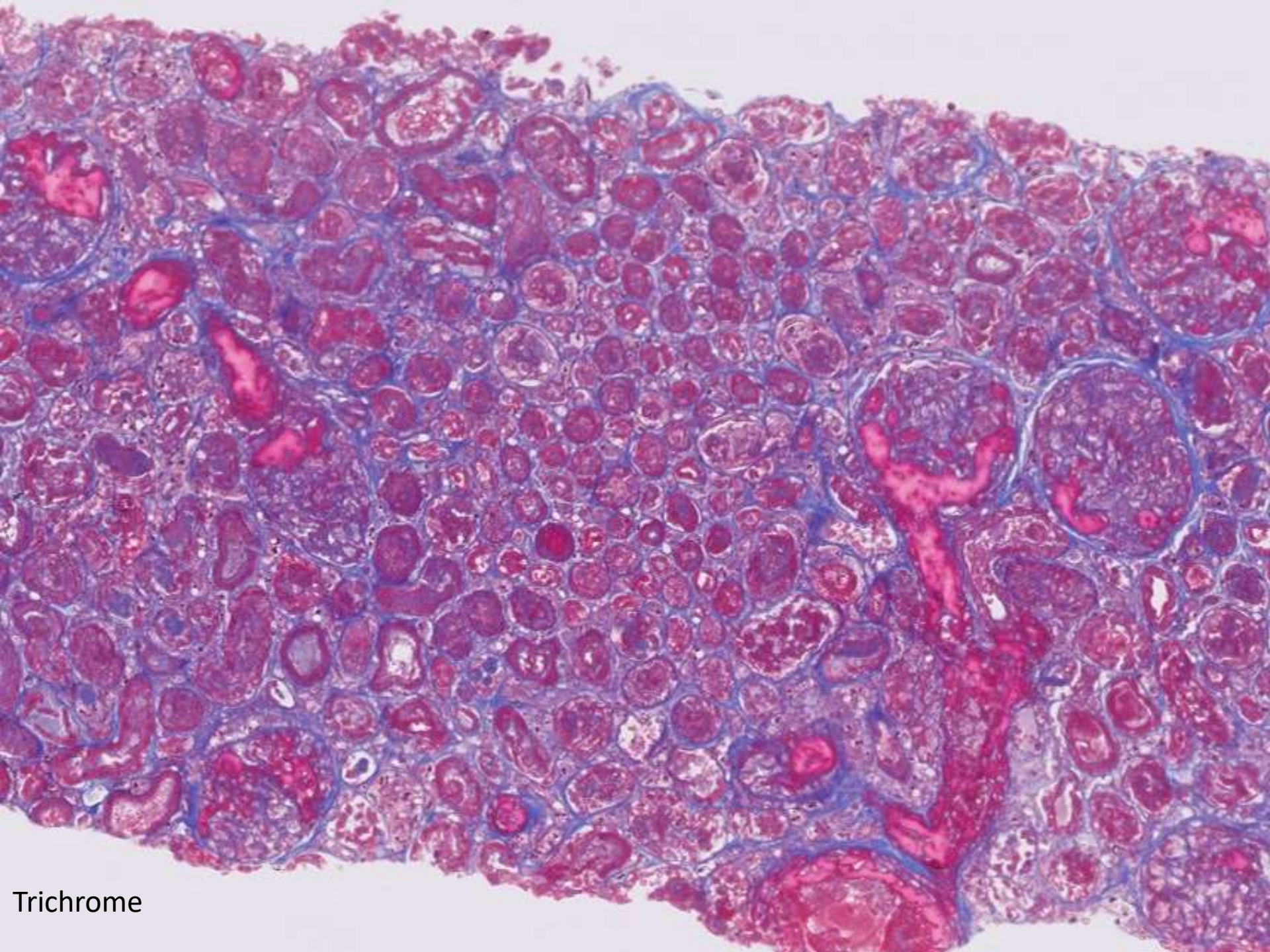




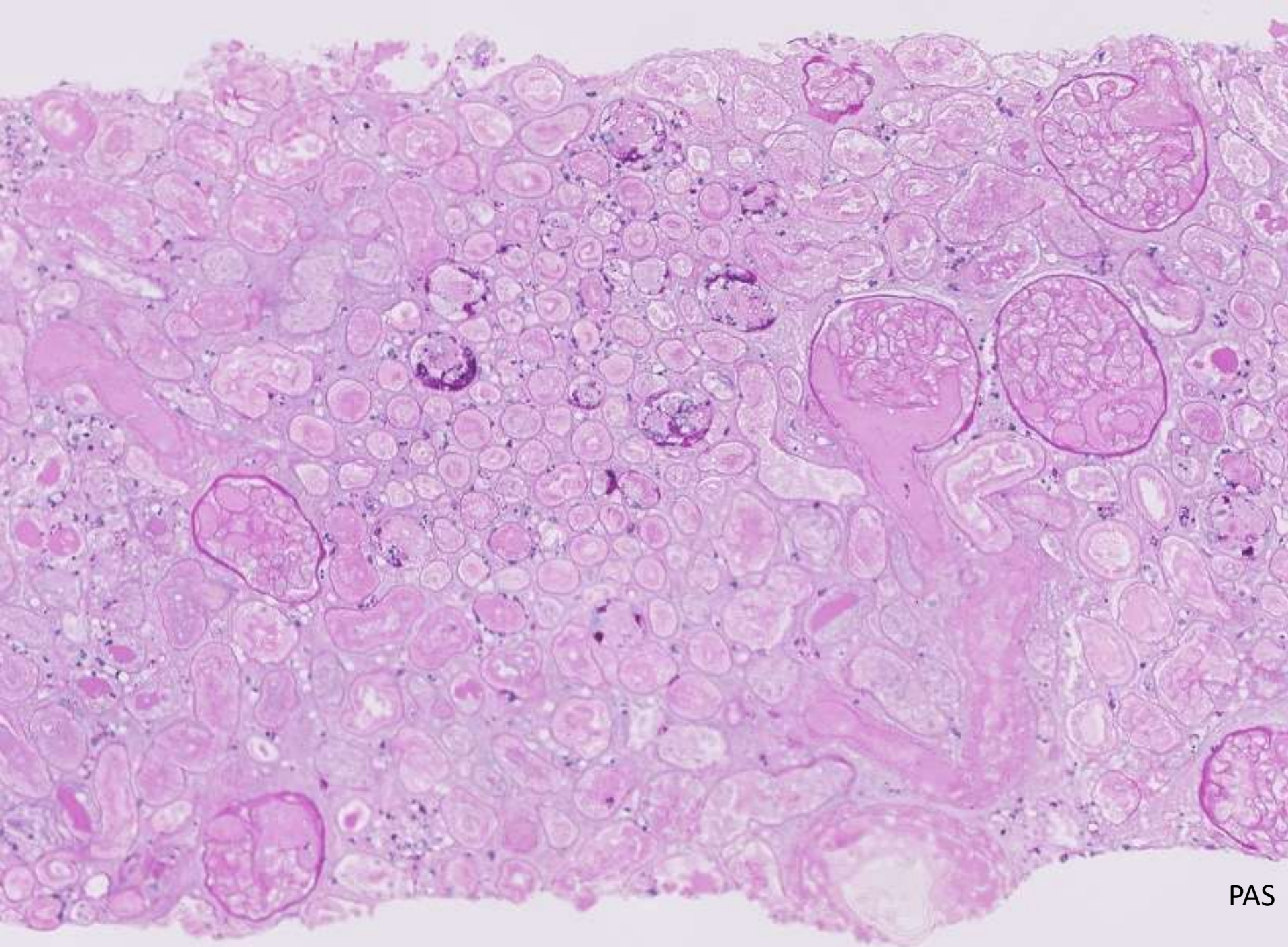
Trichrome



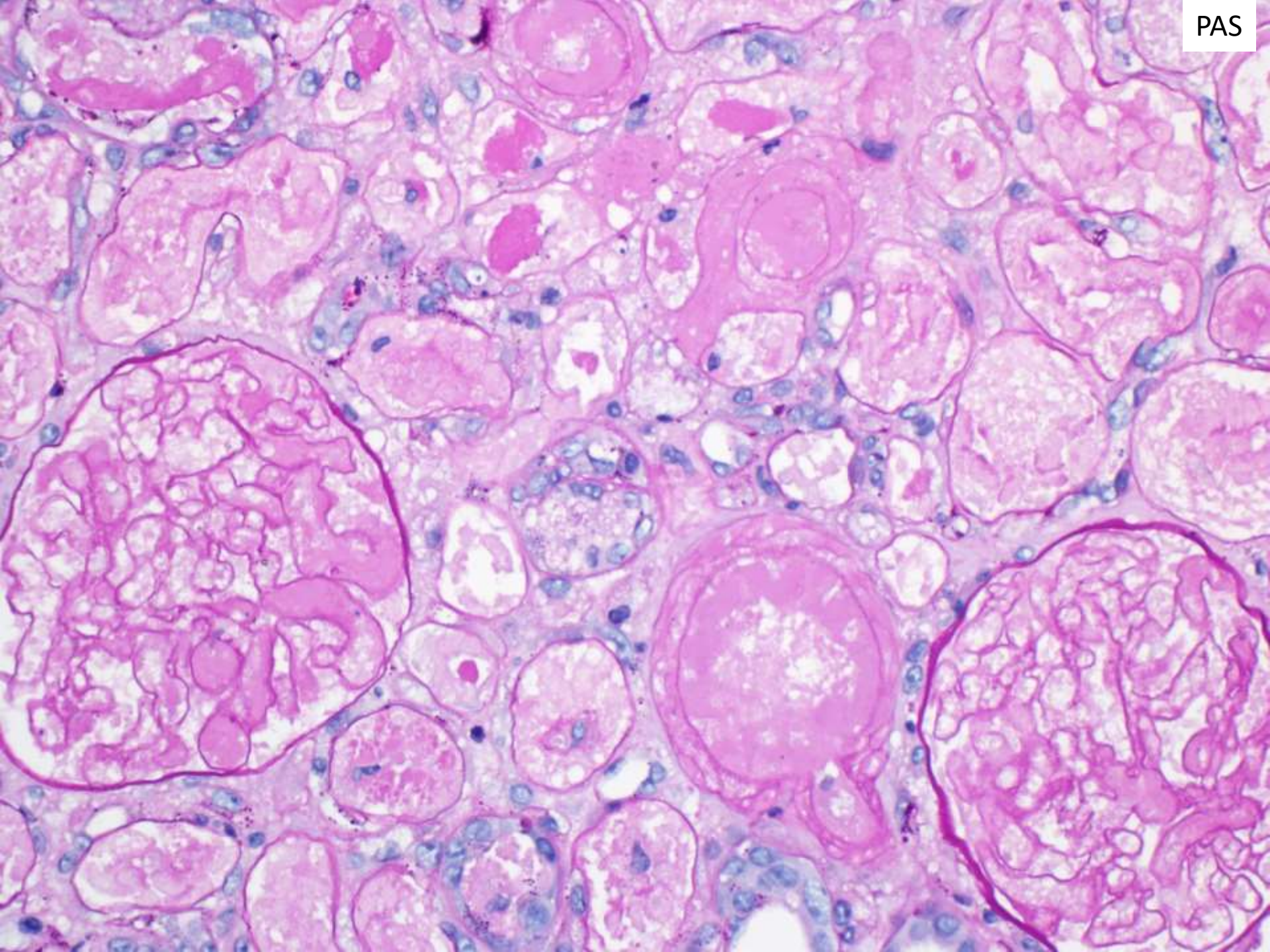
PAS

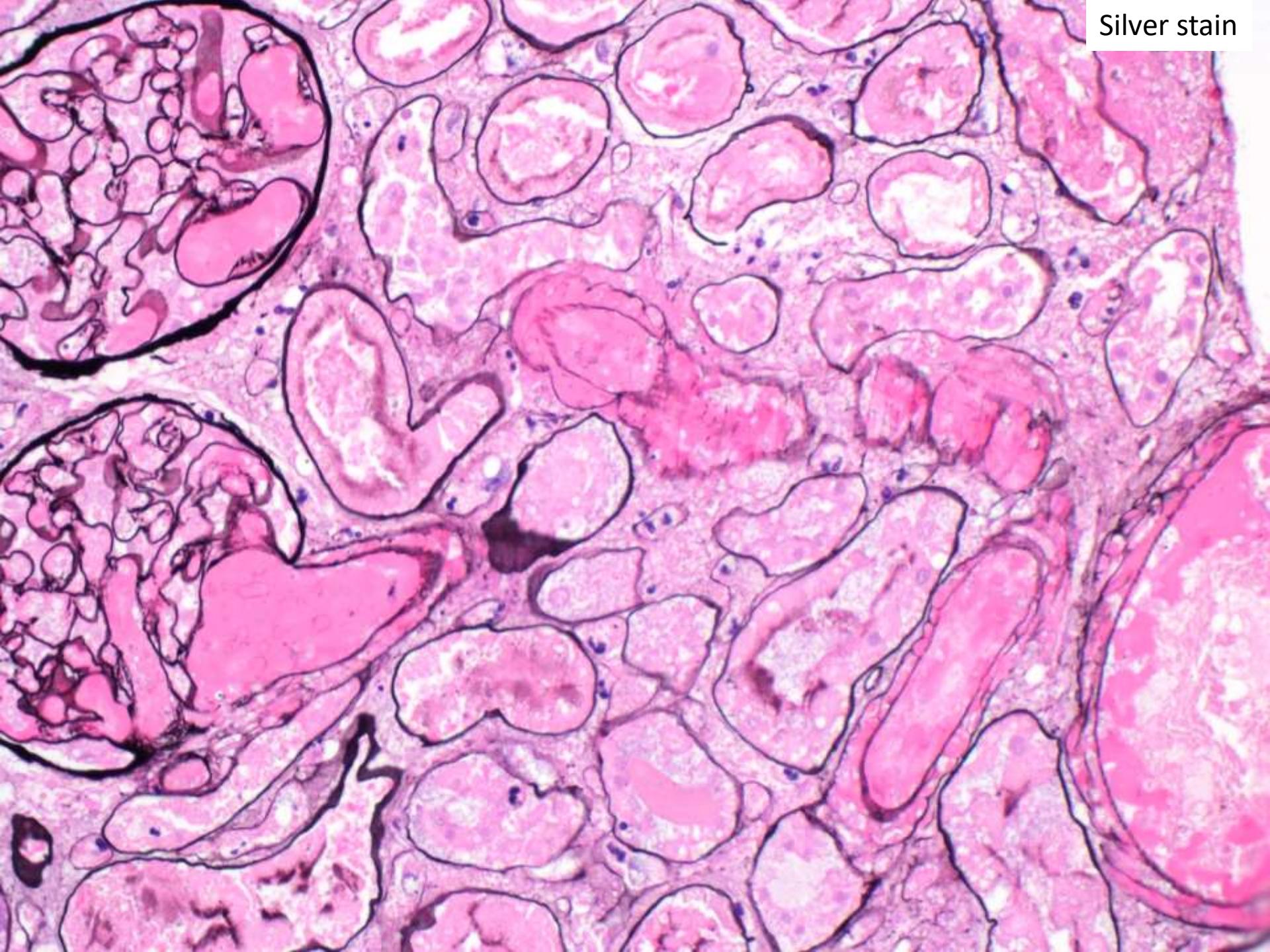


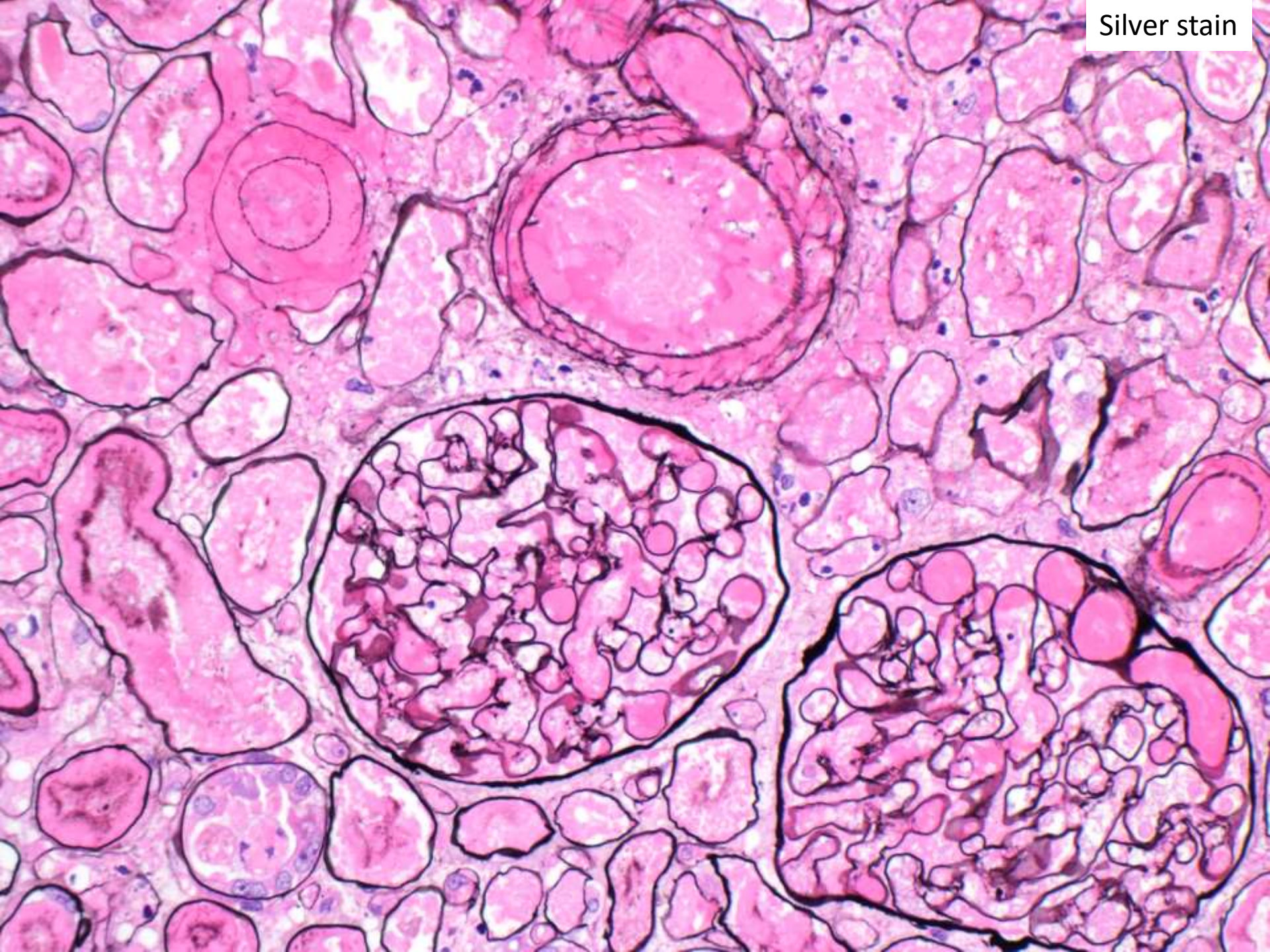
Trichrome



PAS







21-0707

David Bingham; Stanford

50-year-old F with liver mass.

