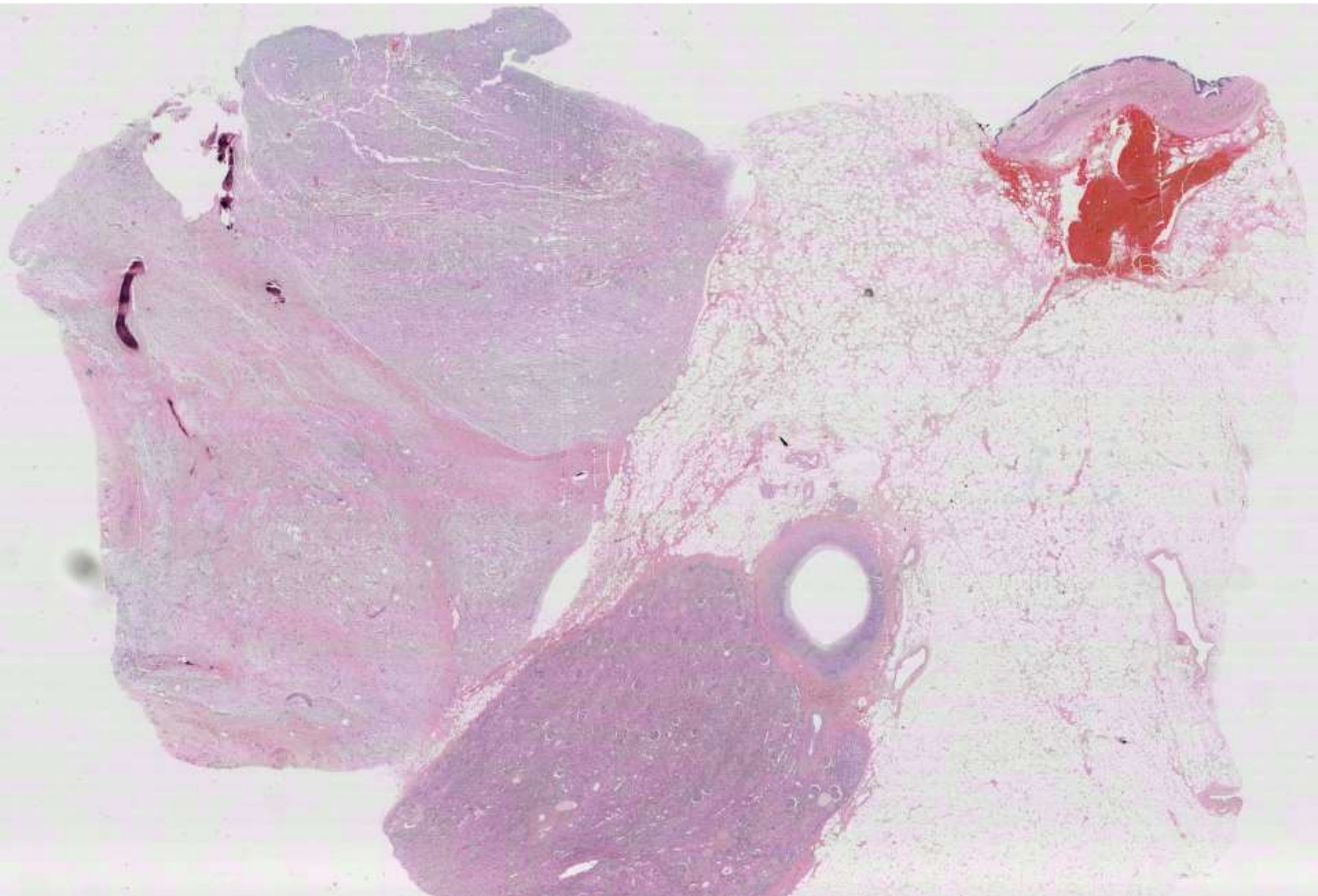
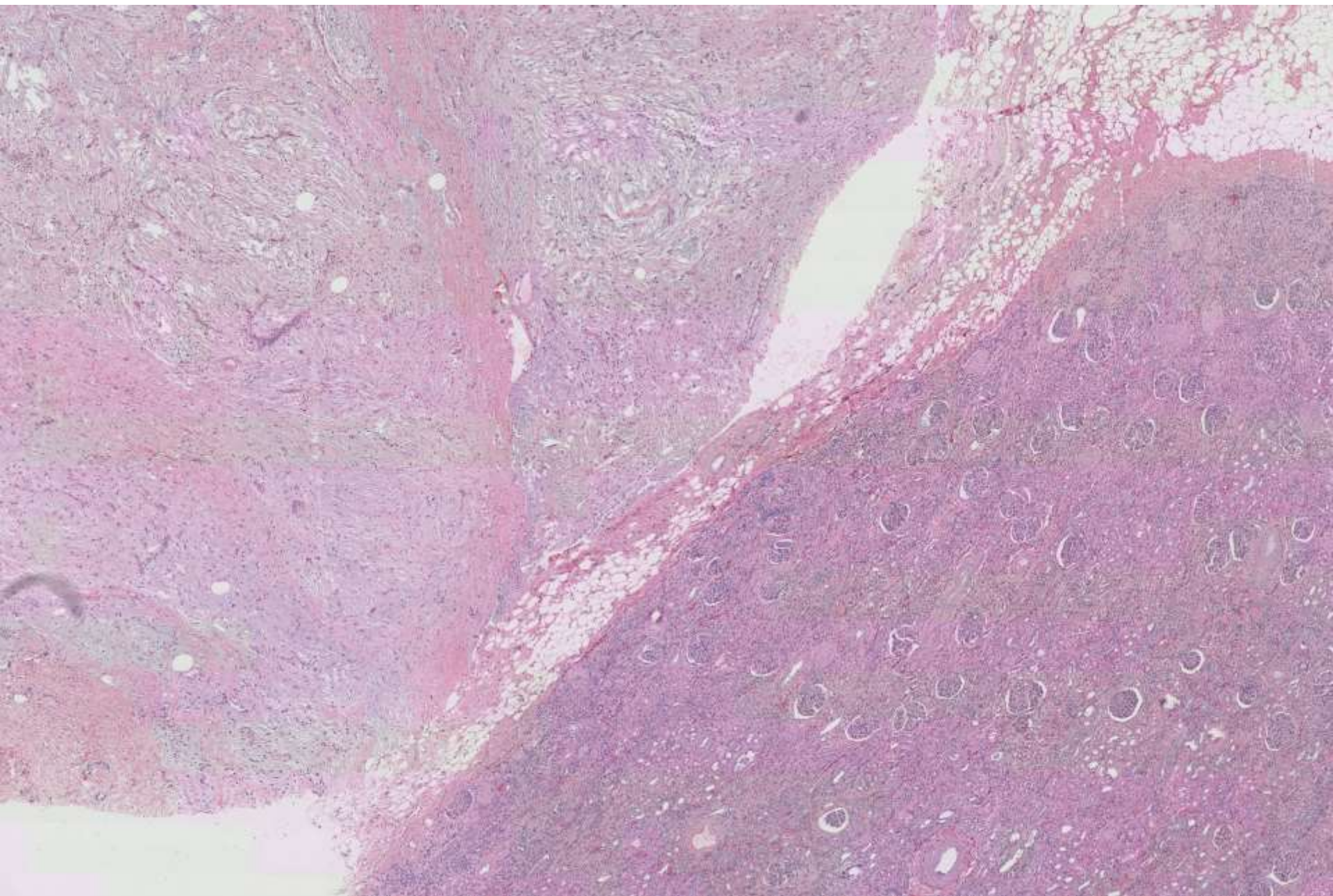


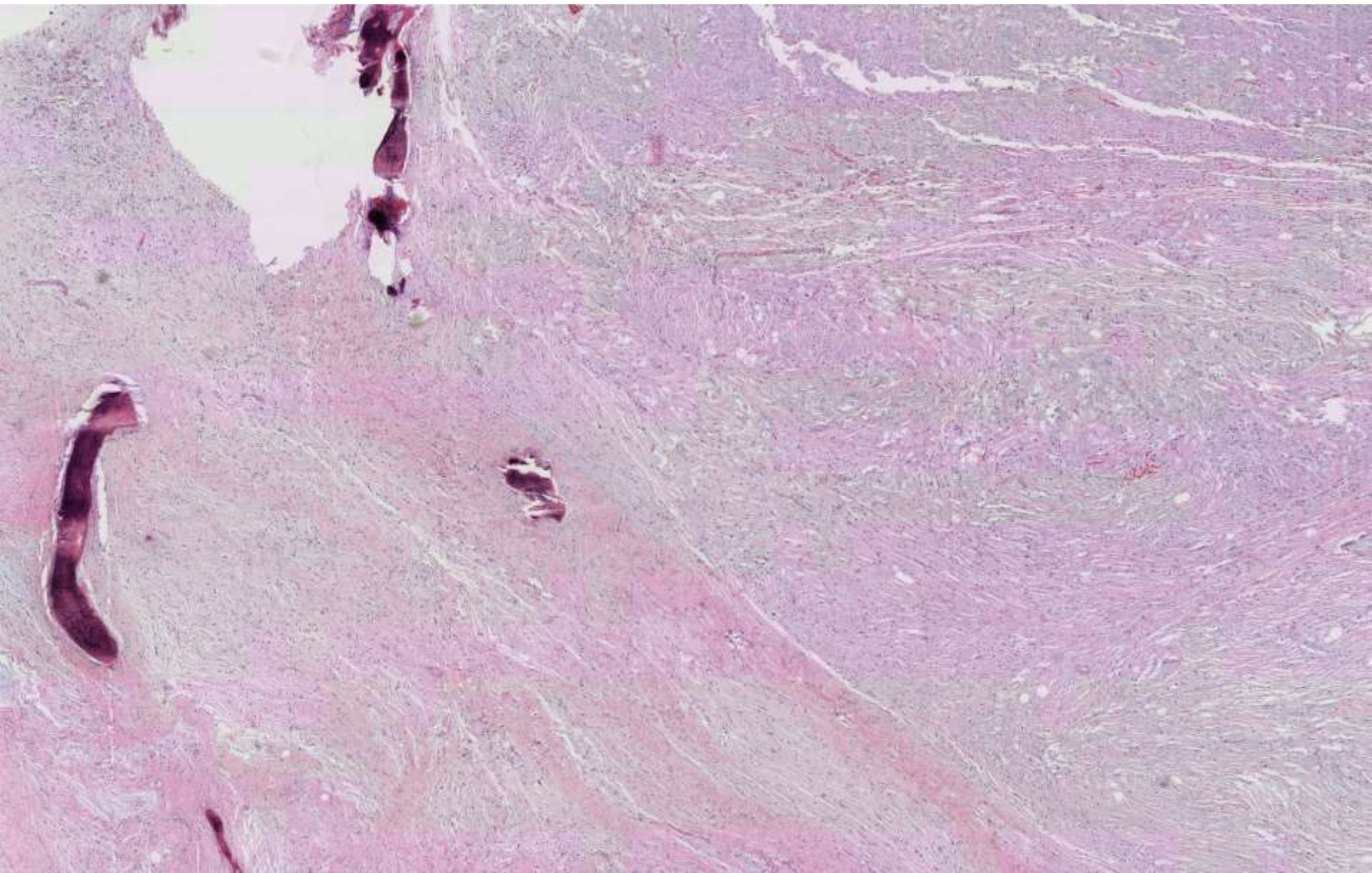
19-0801
(scanned slide available)

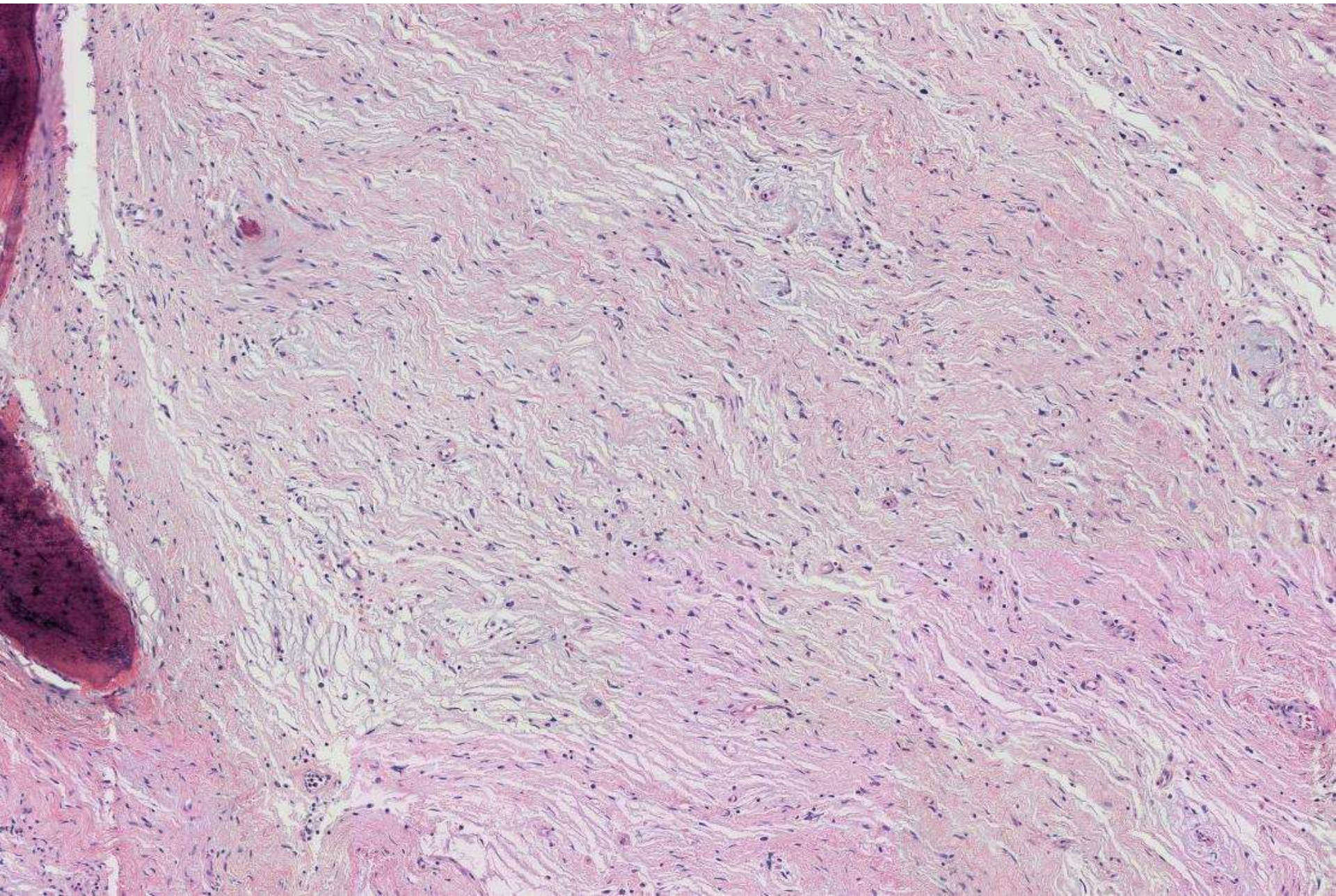
Emily Chan, UCSF

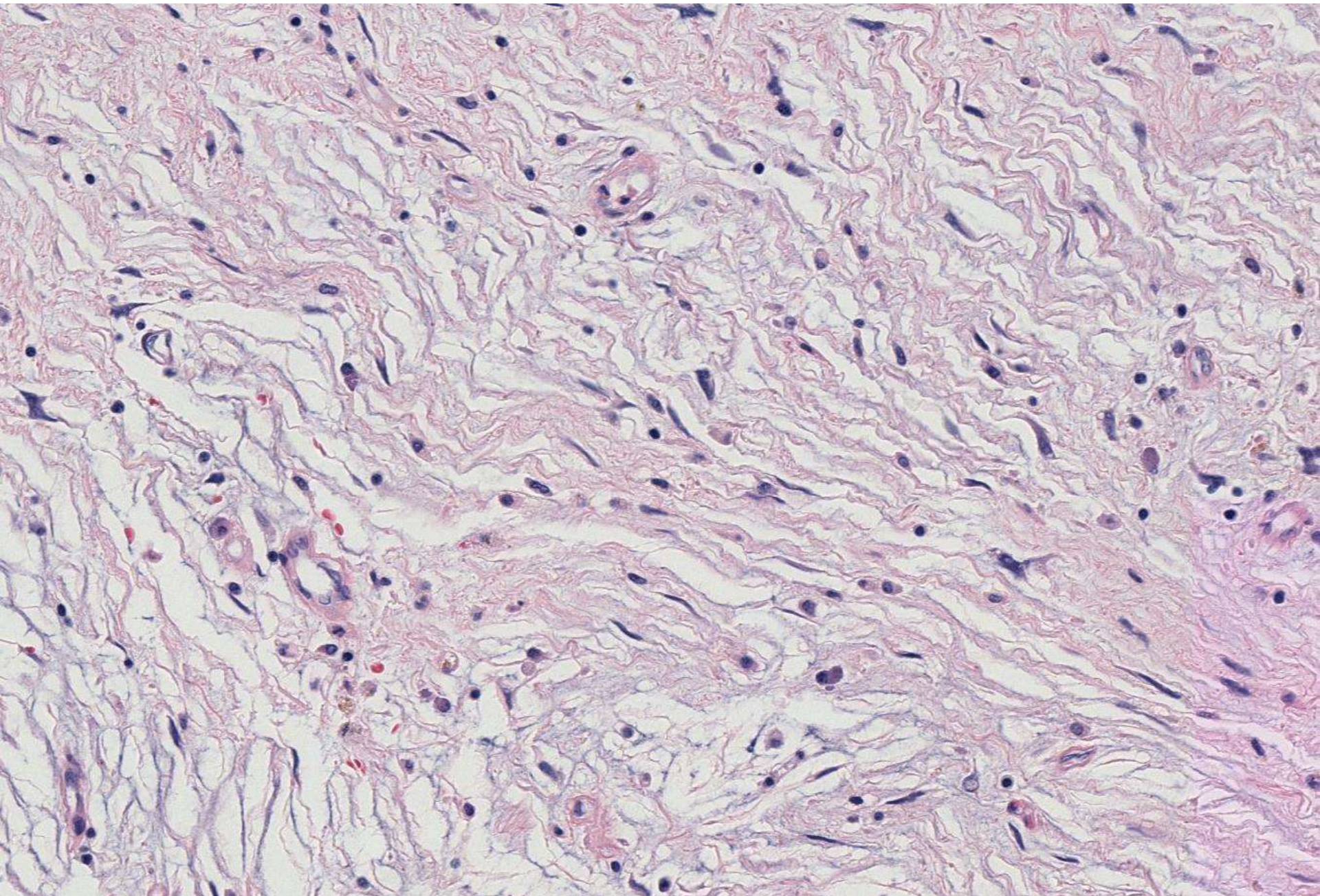
57-year-old man with 5.2cm left
upper pole/para-pelvic renal mass.

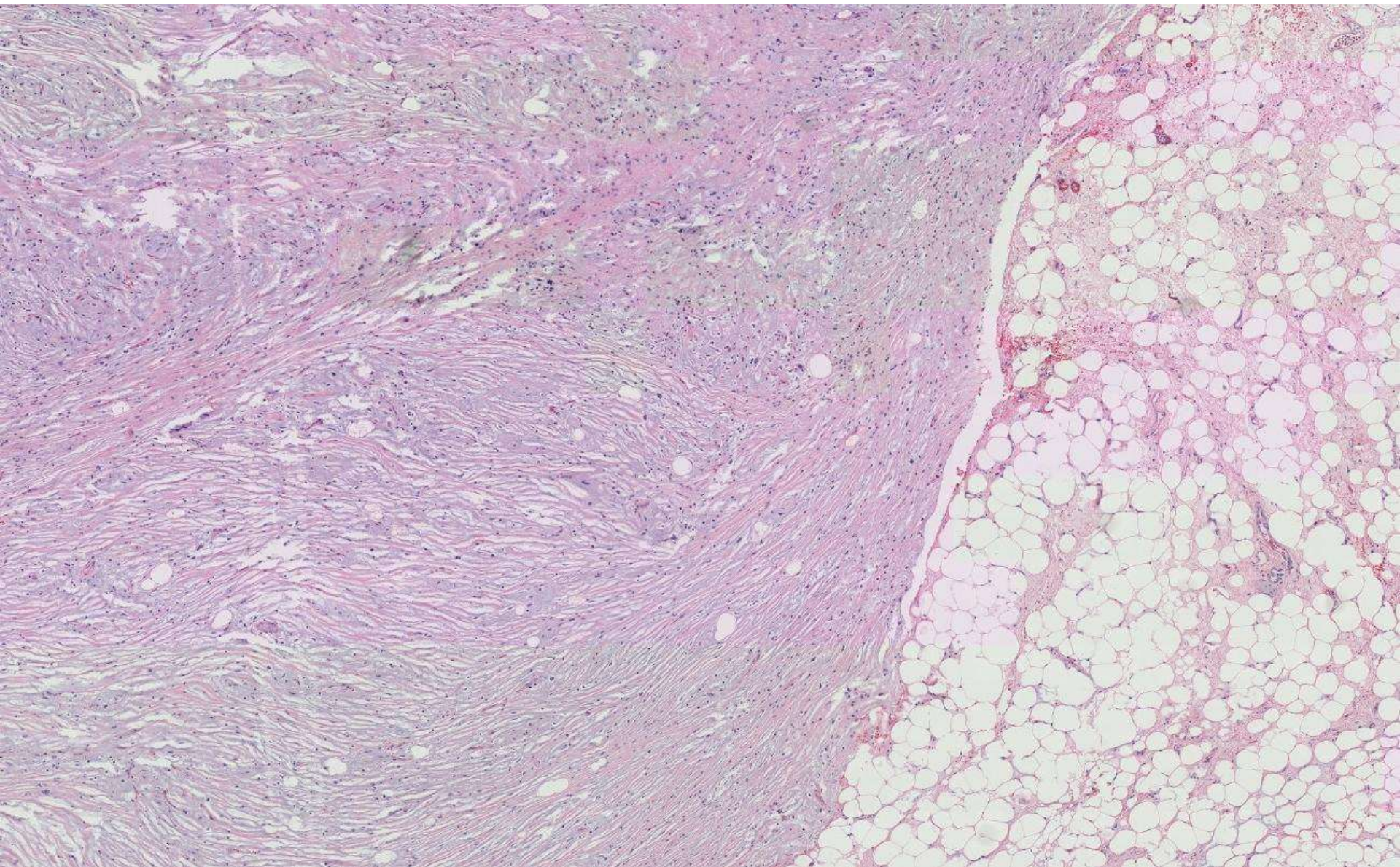


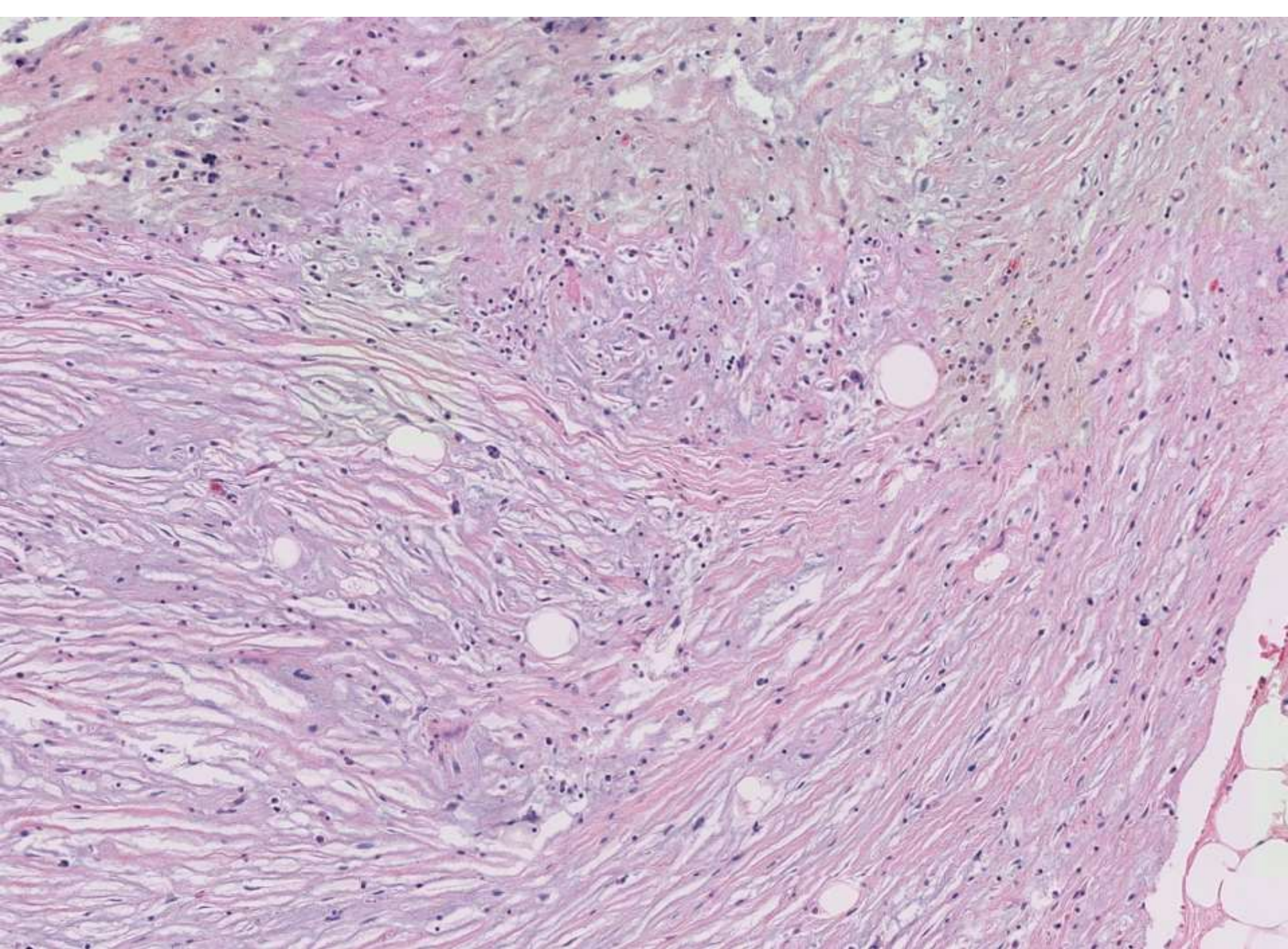


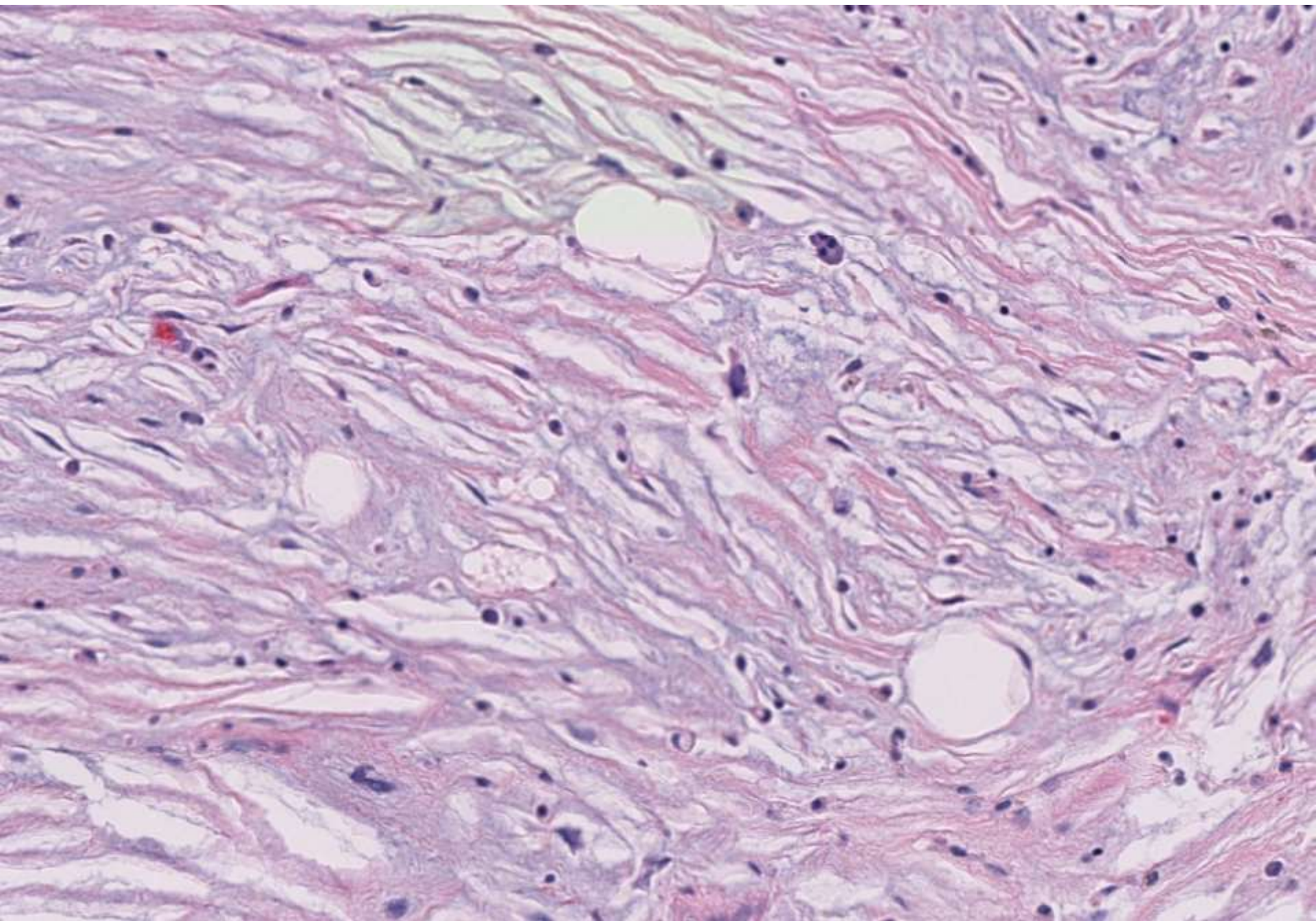












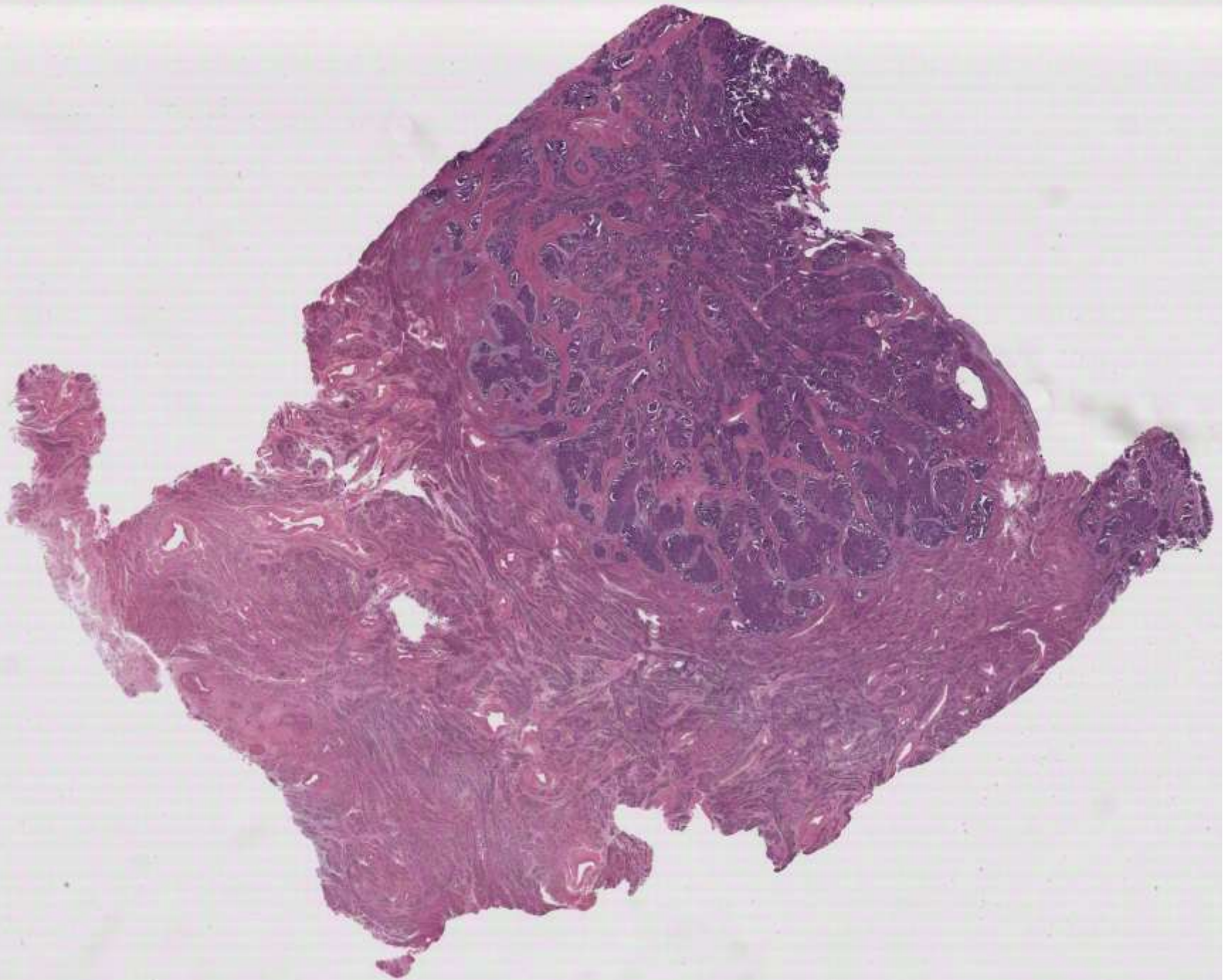


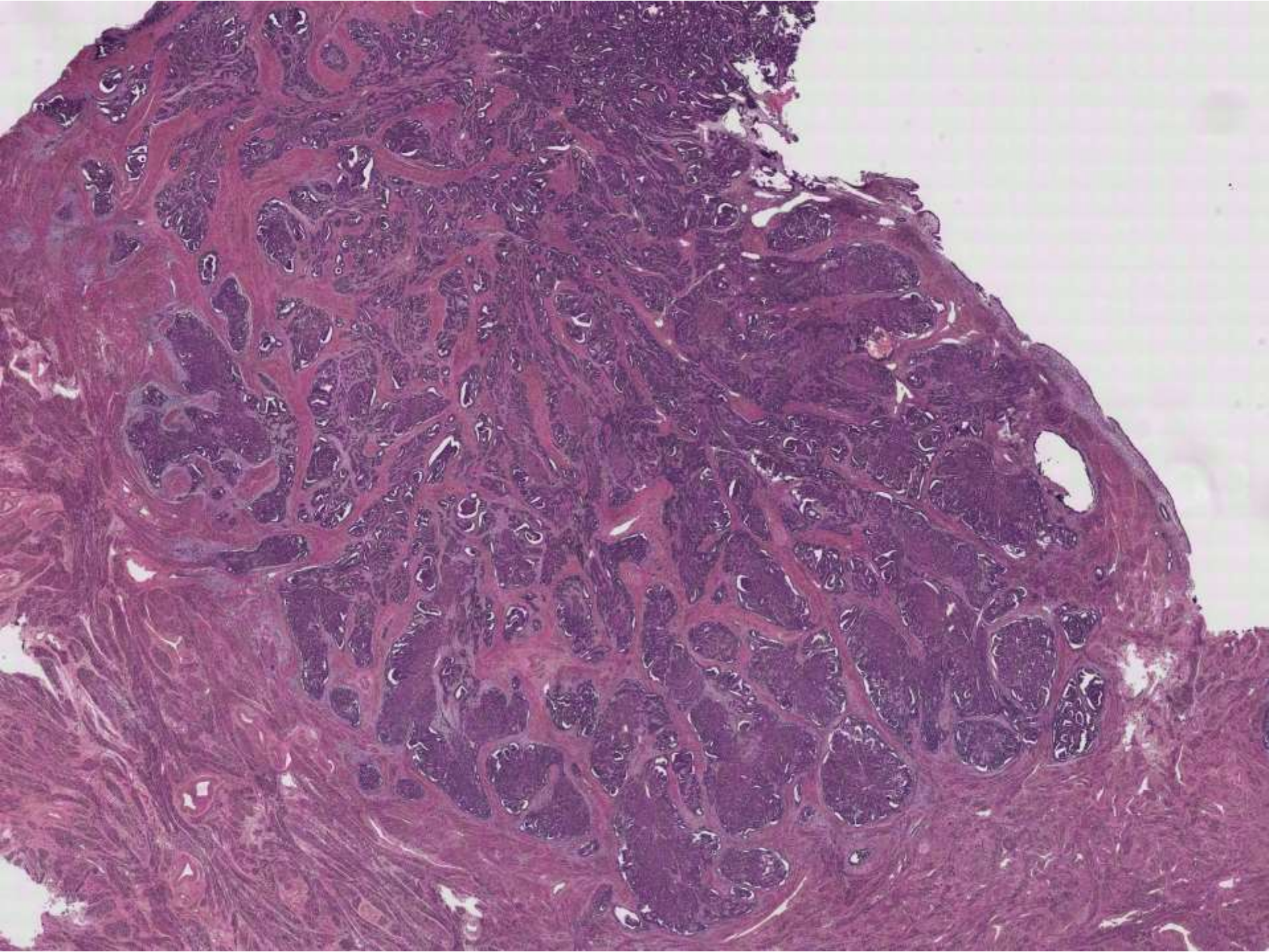
19-0802

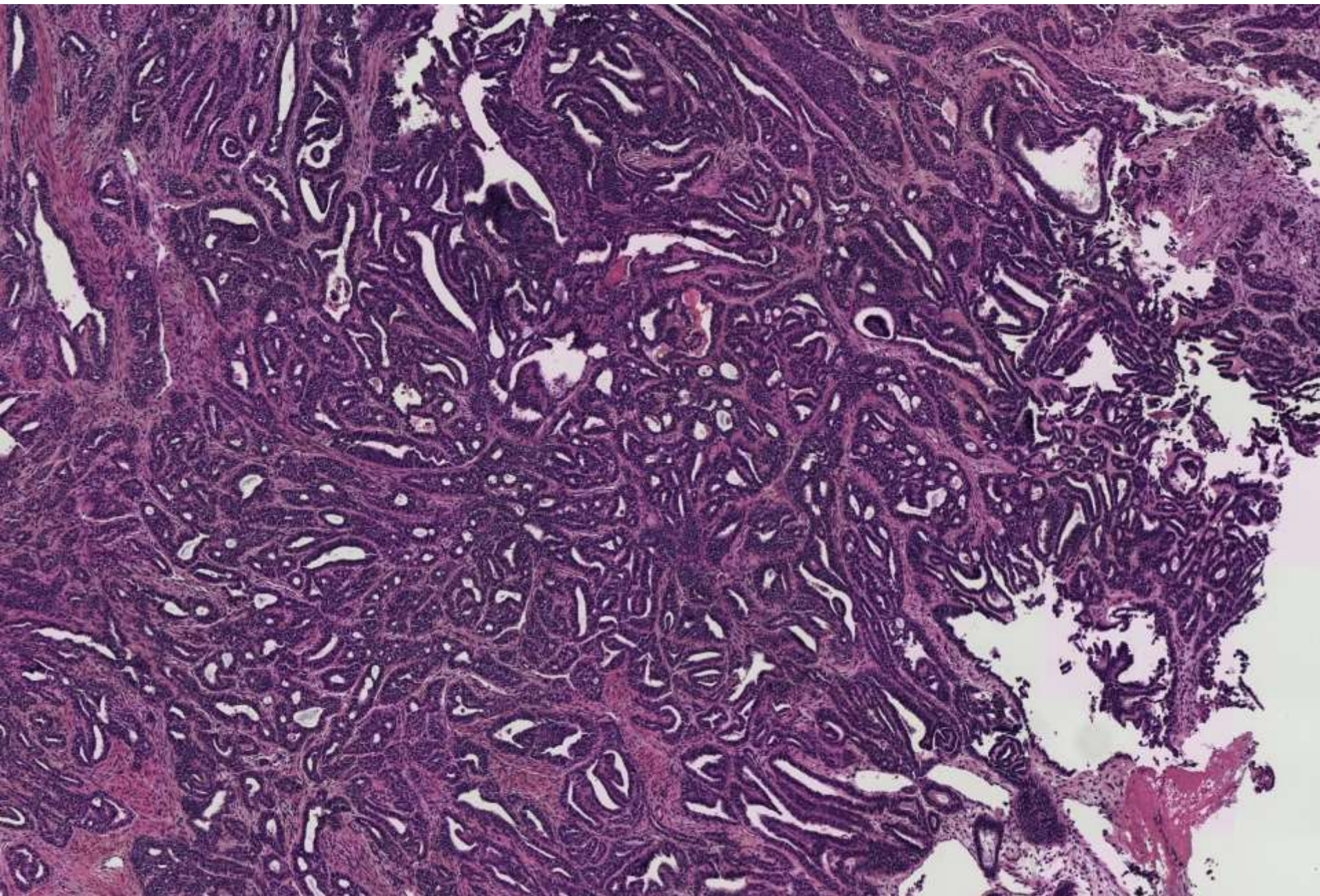
(scanned slide available)

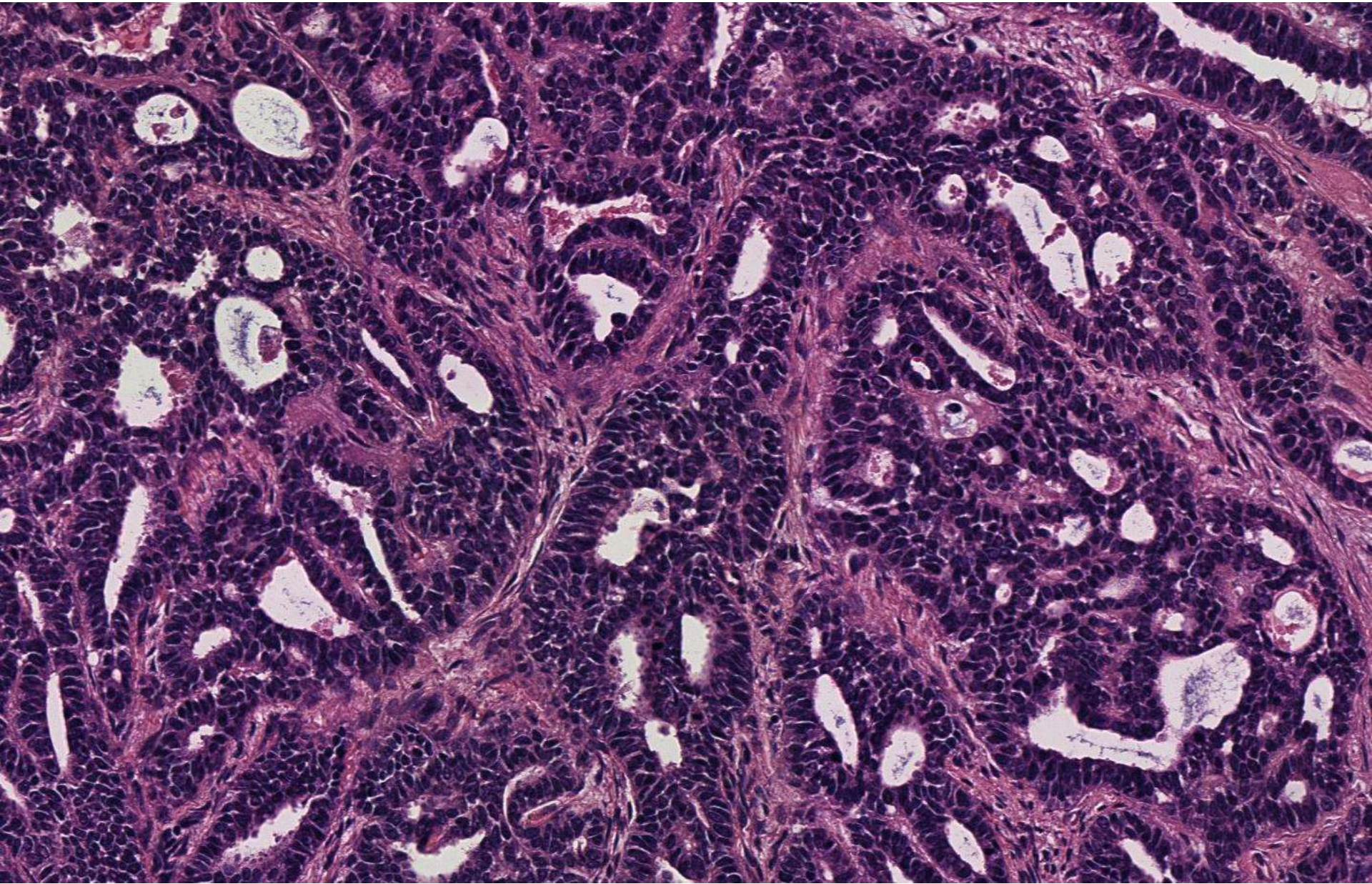
Ankur Sangoi, El Camino Hospital

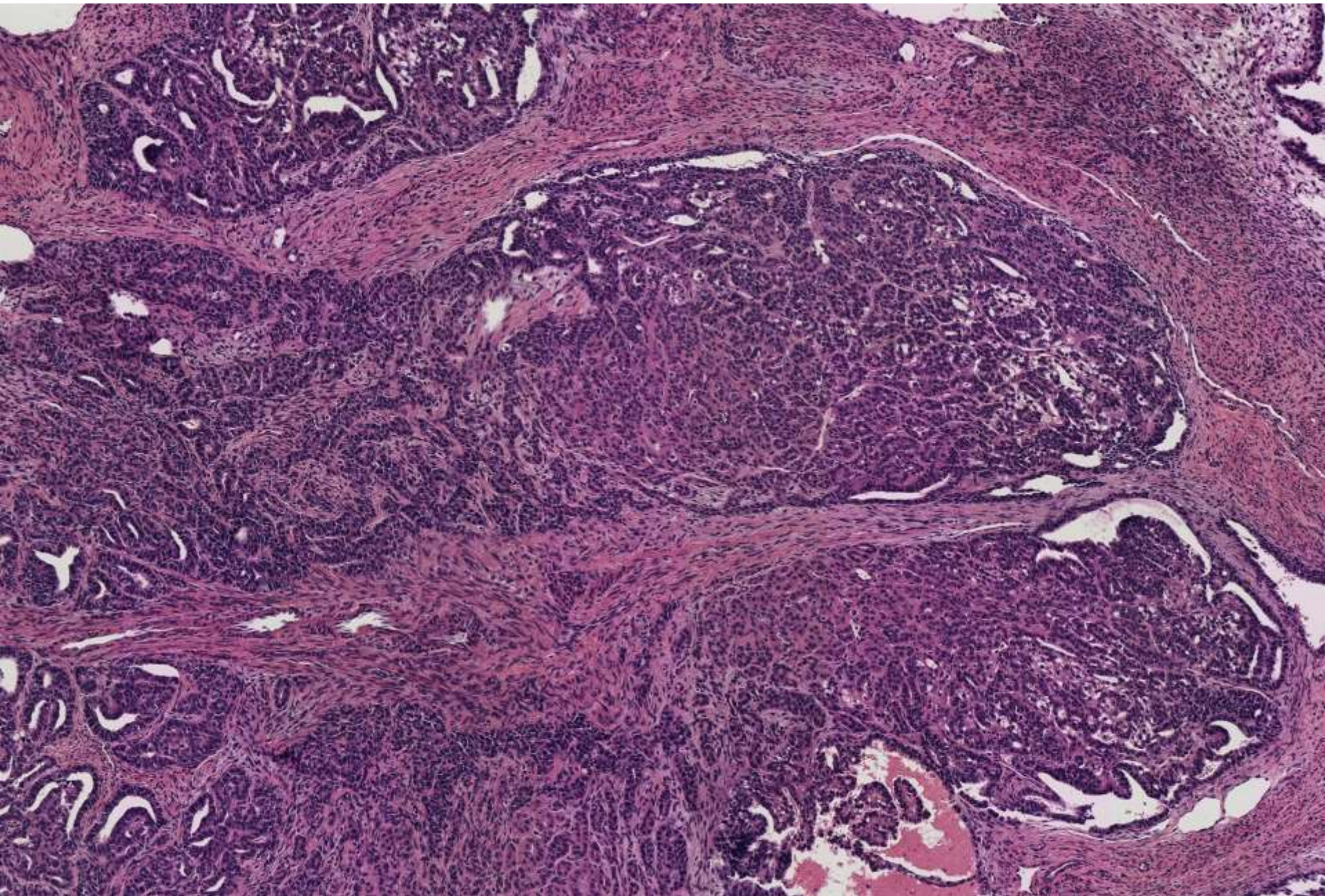
54-year-old woman with endometrial
mass. TAH performed.

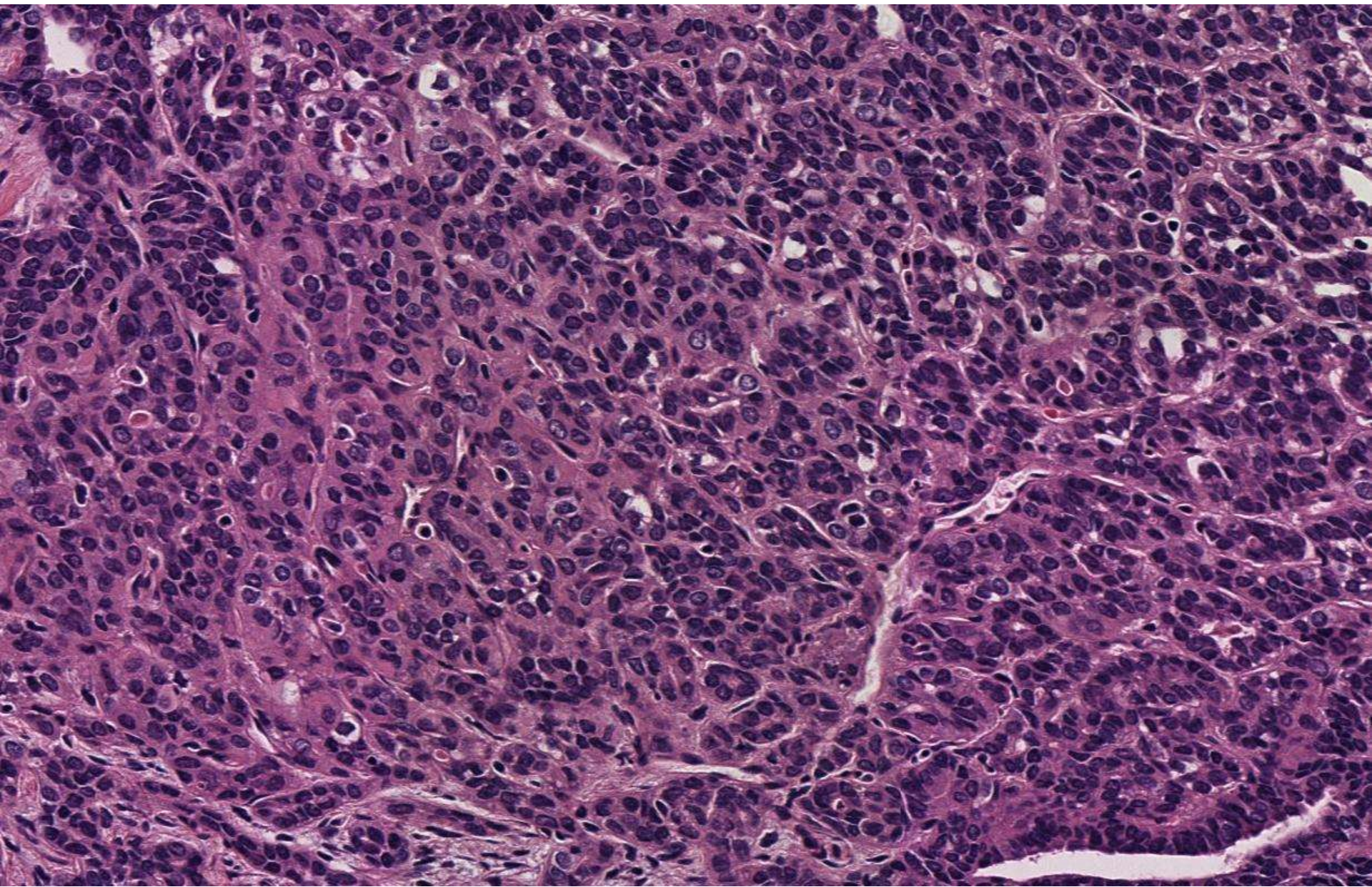


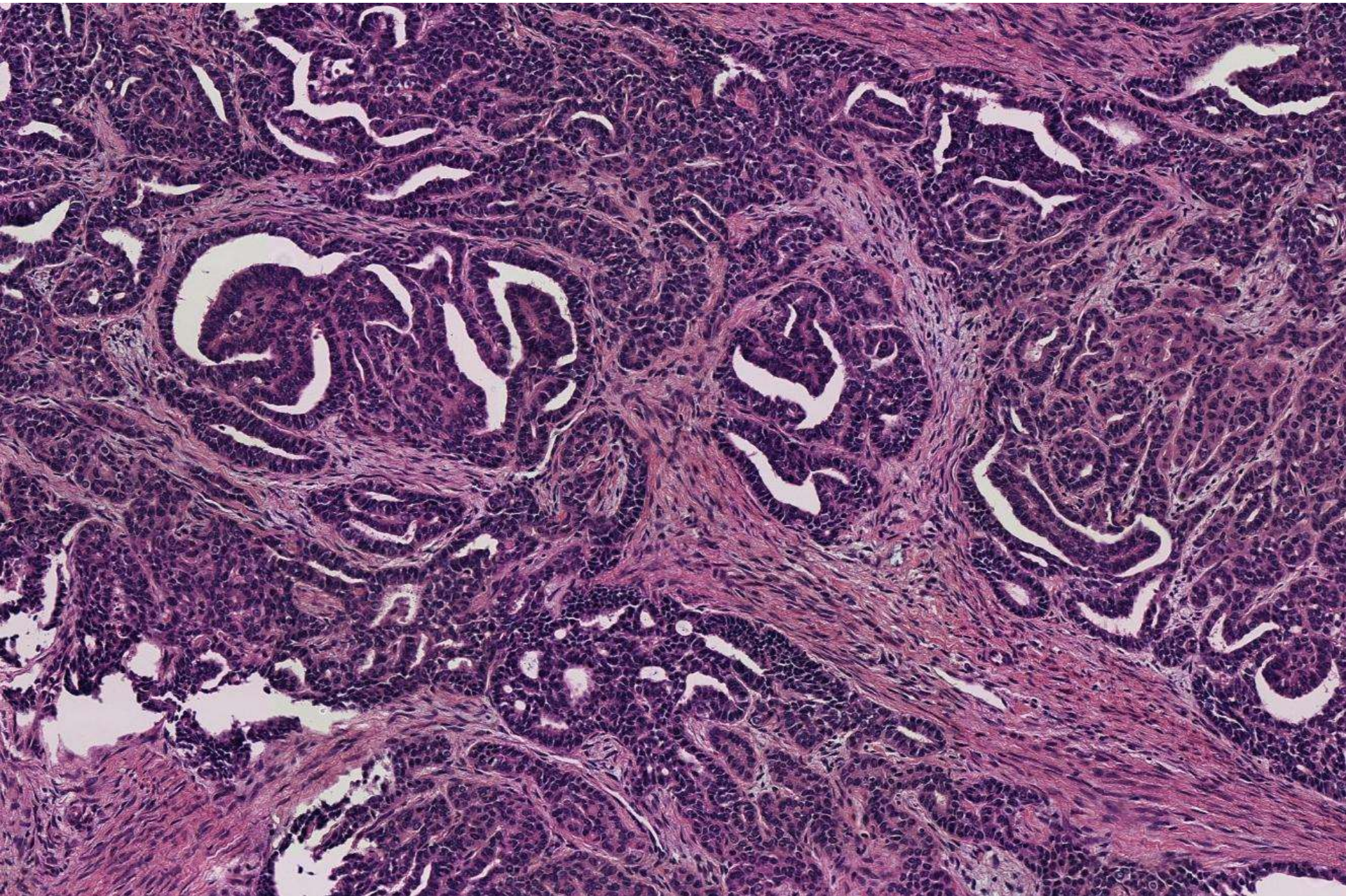


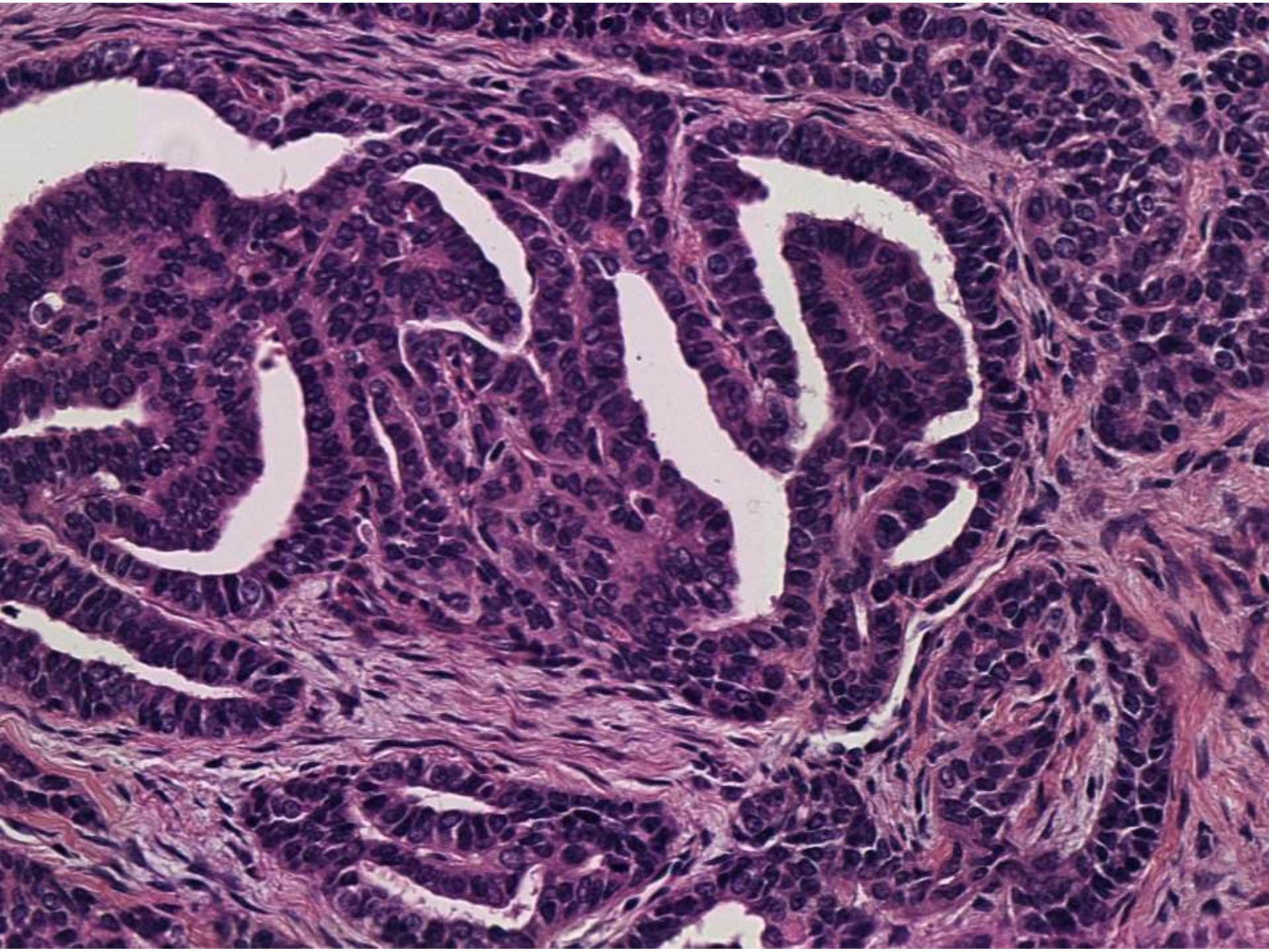


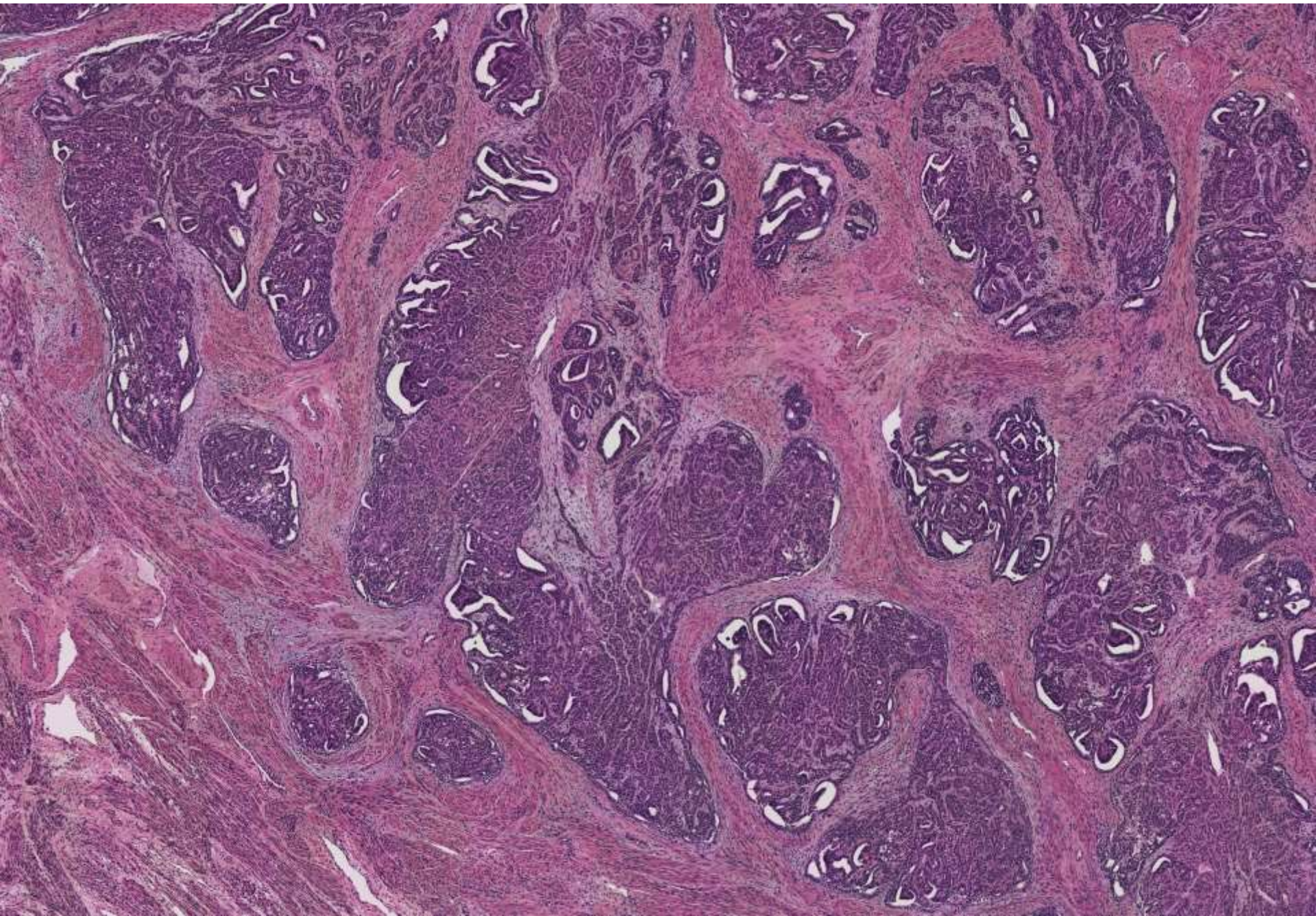


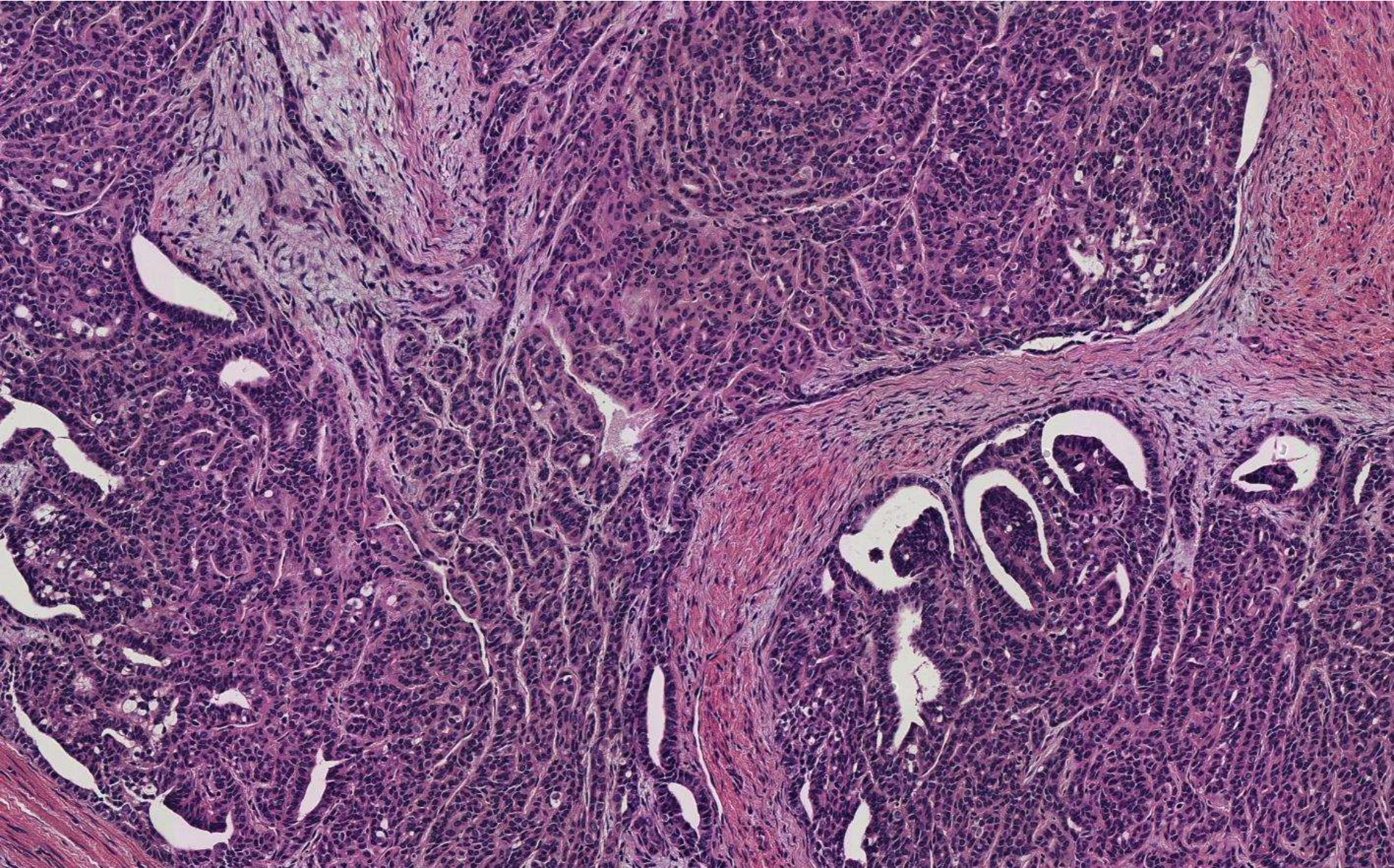


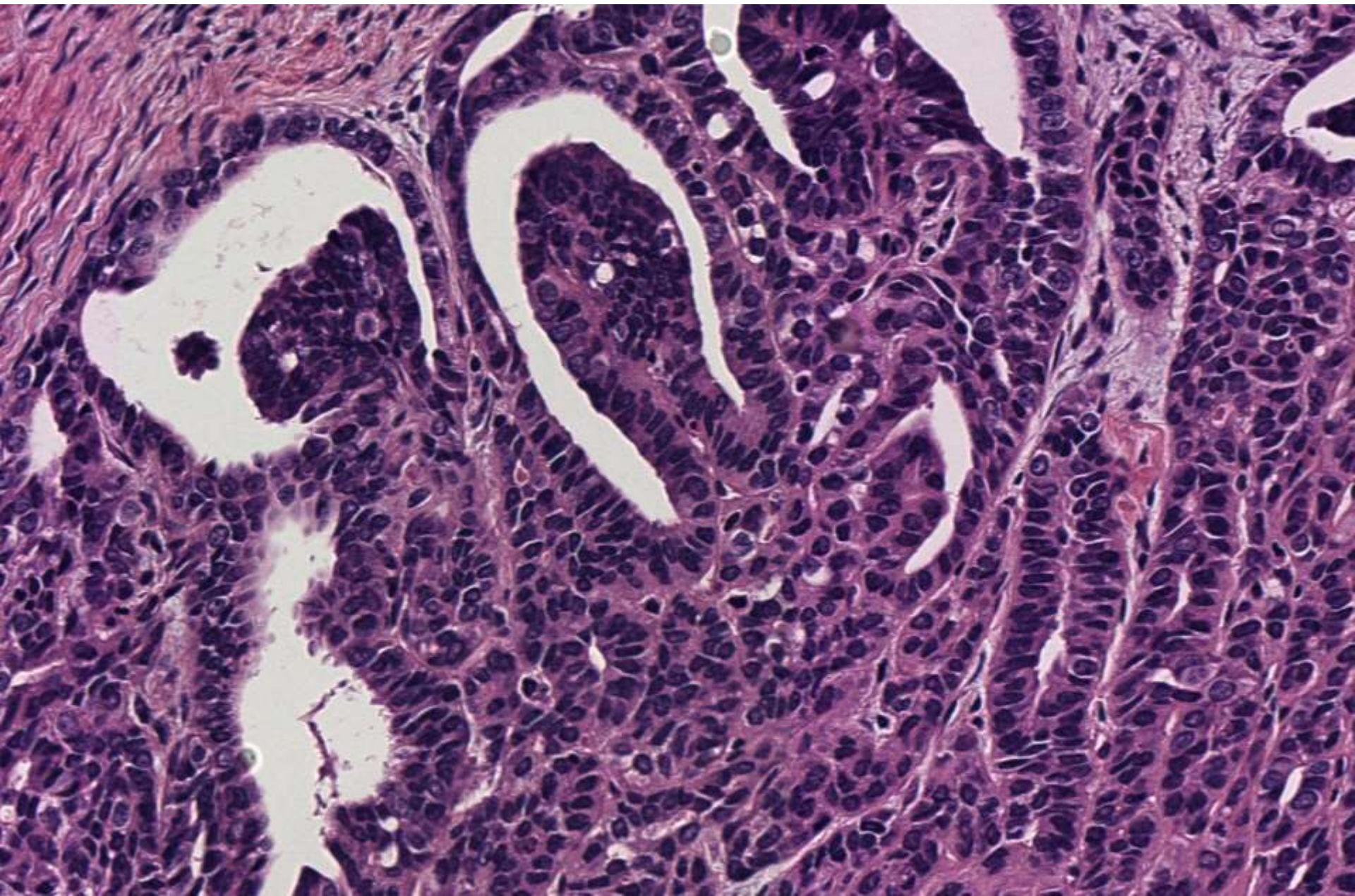


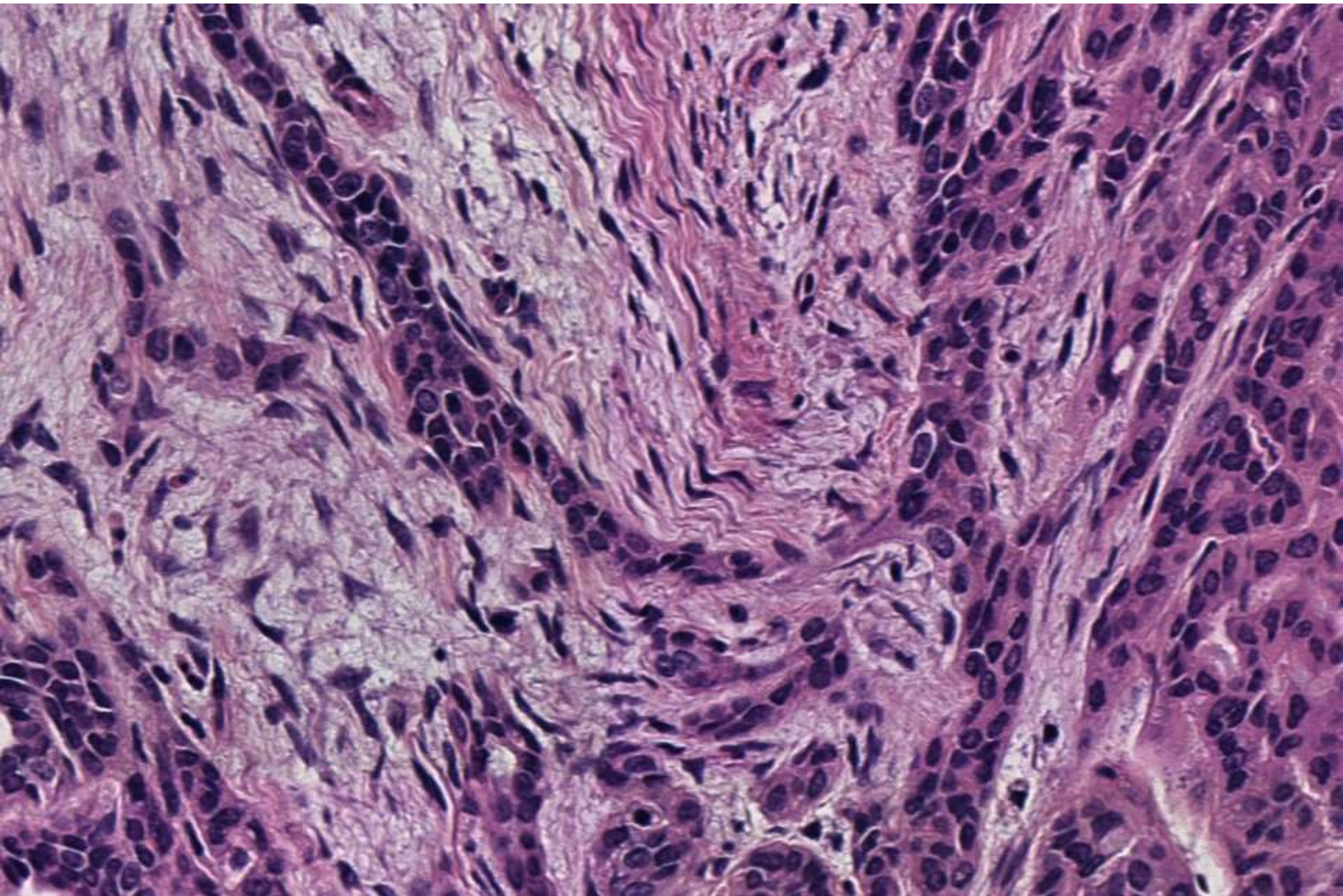












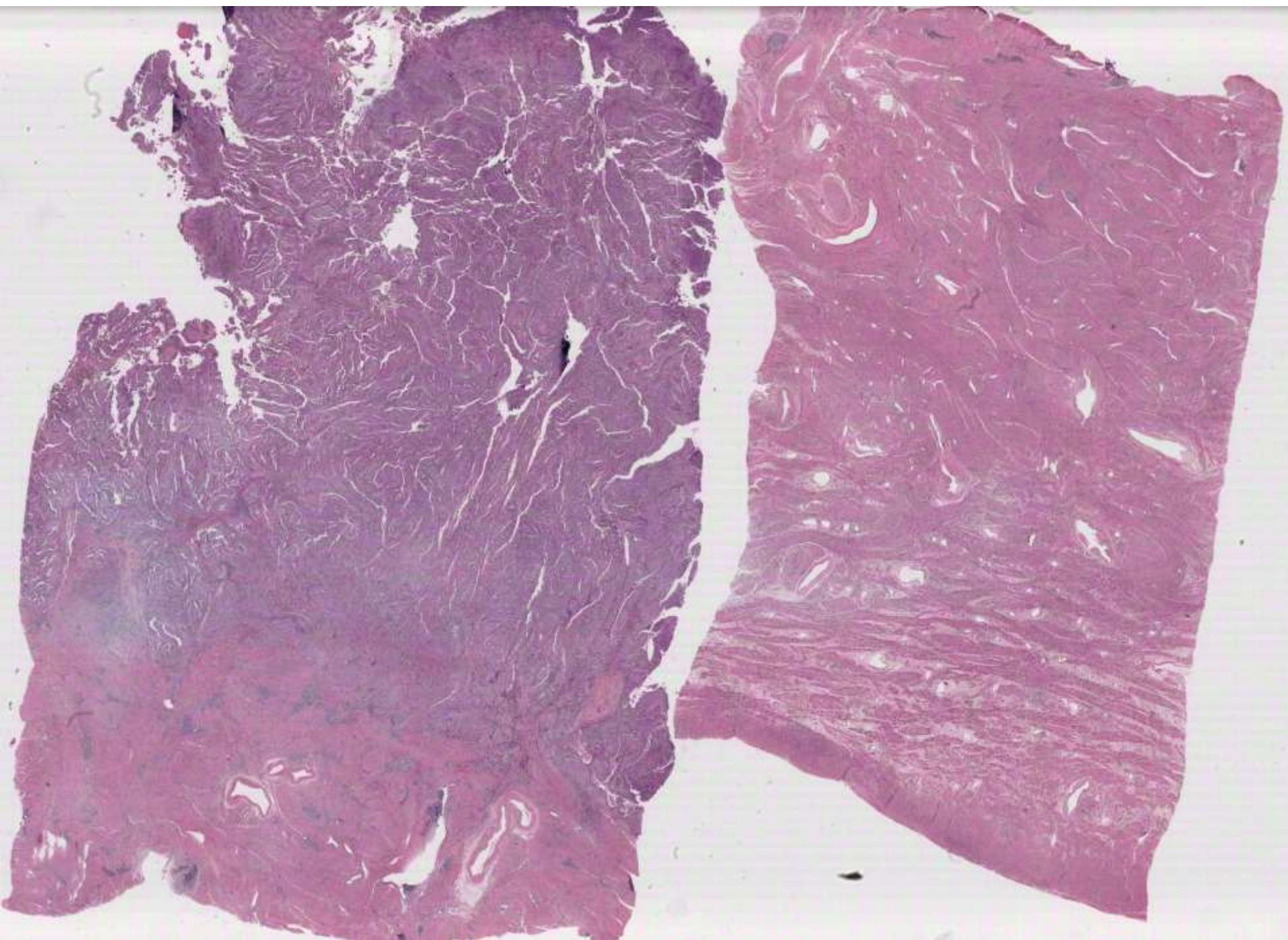


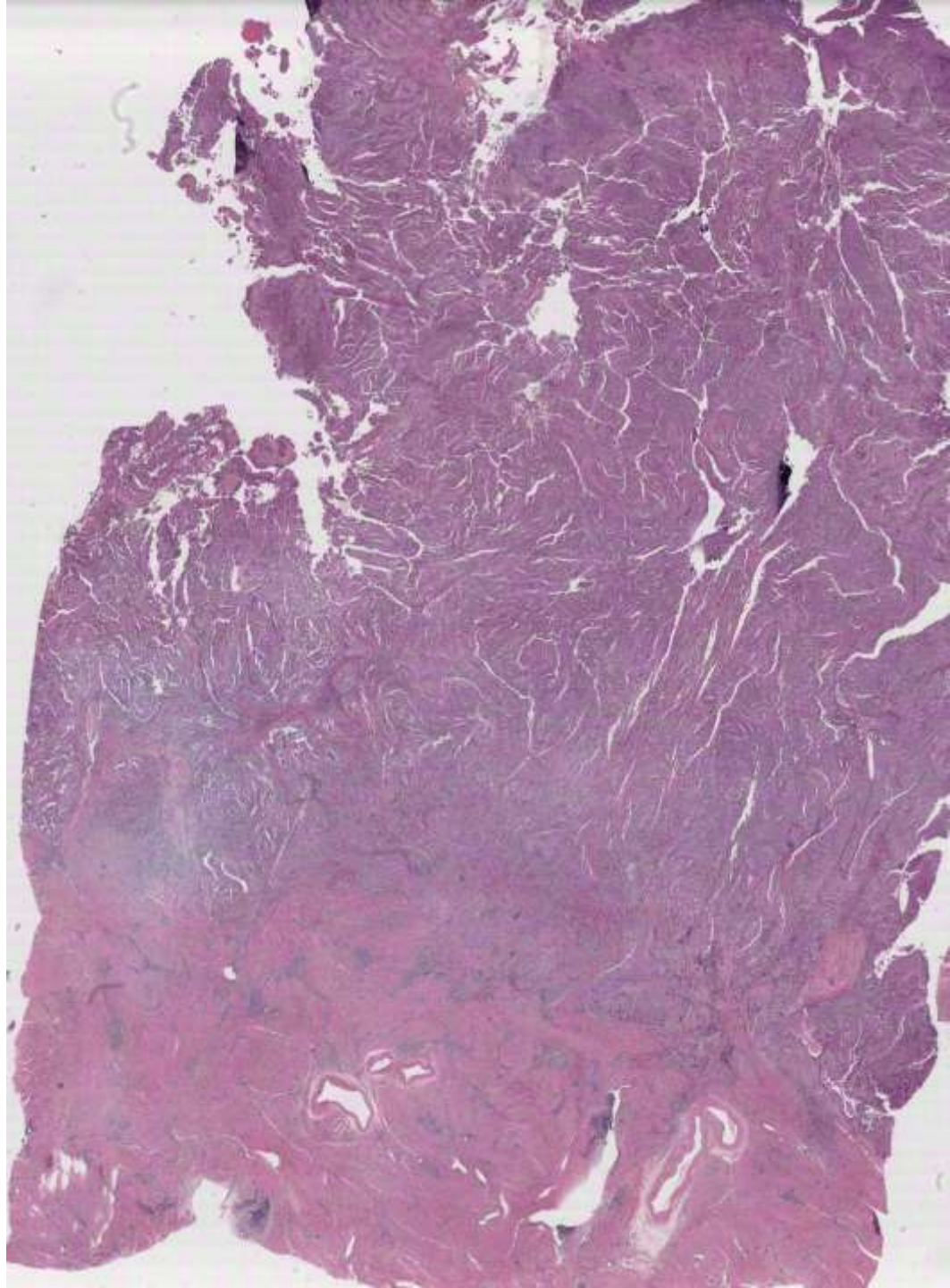
19-0803

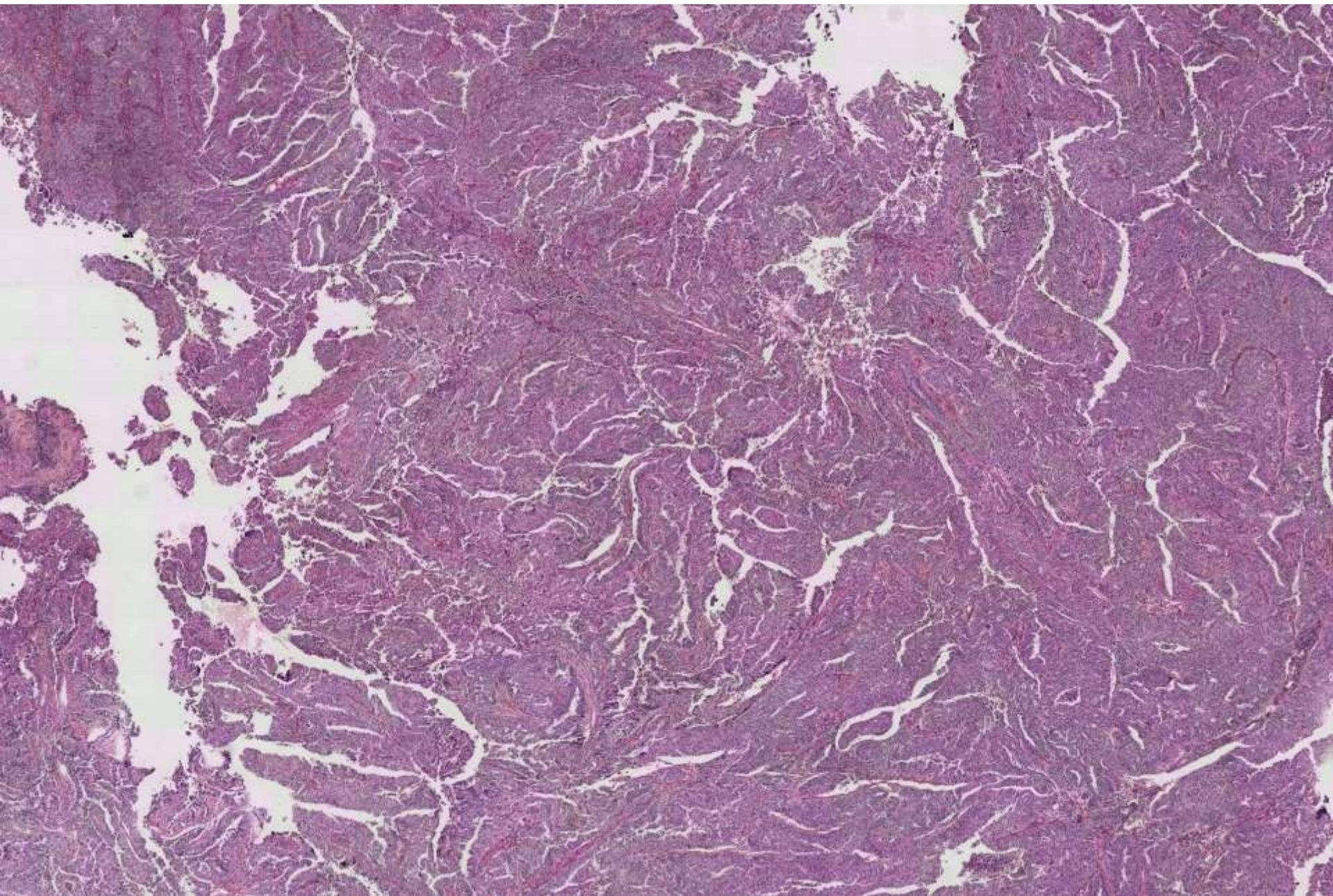
(scanned slide available)

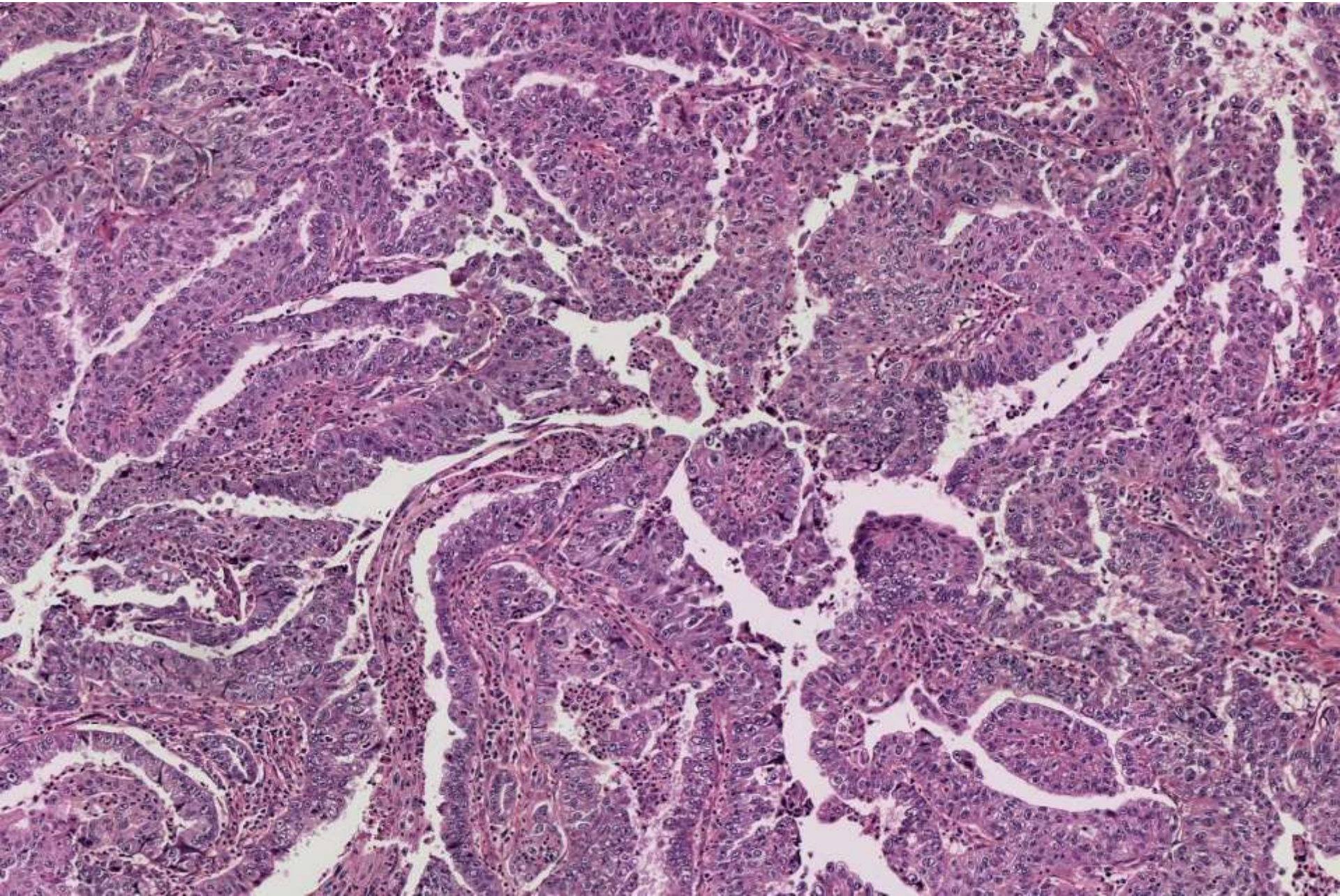
Ankur Sangoi, El Camino Hospital

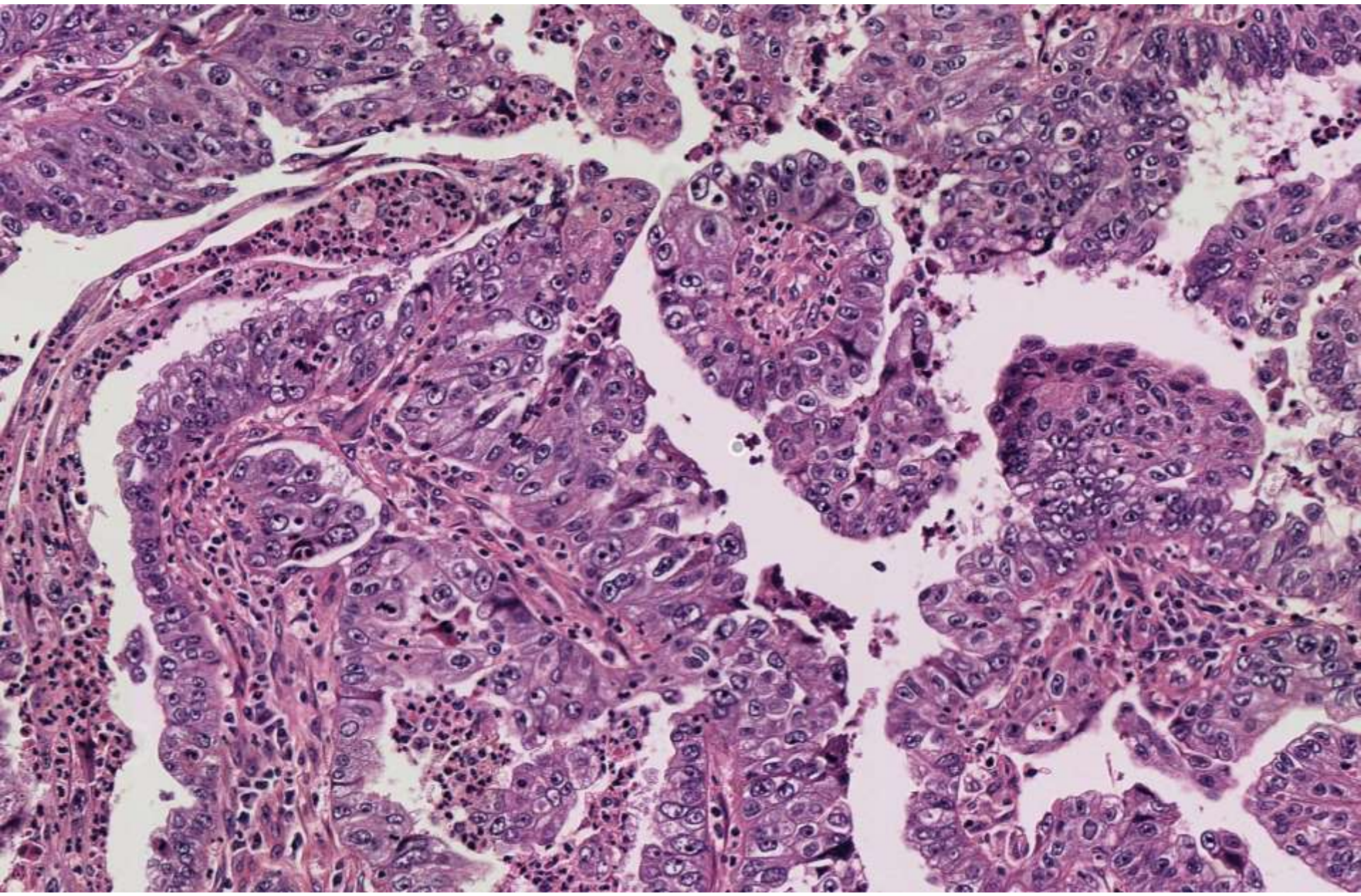
(Different!) 54-year-old woman with
endometrial mass. TAH performed.

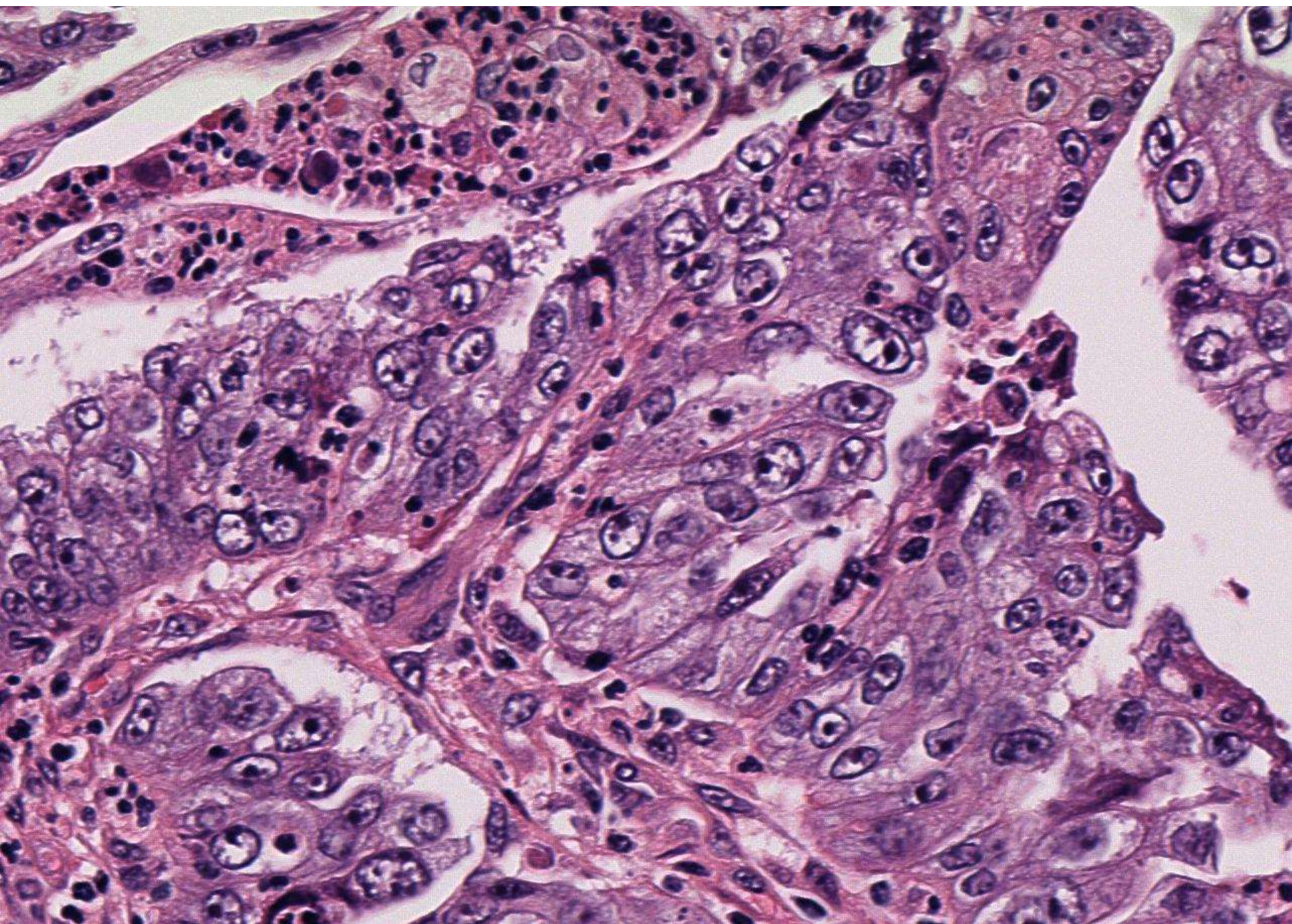


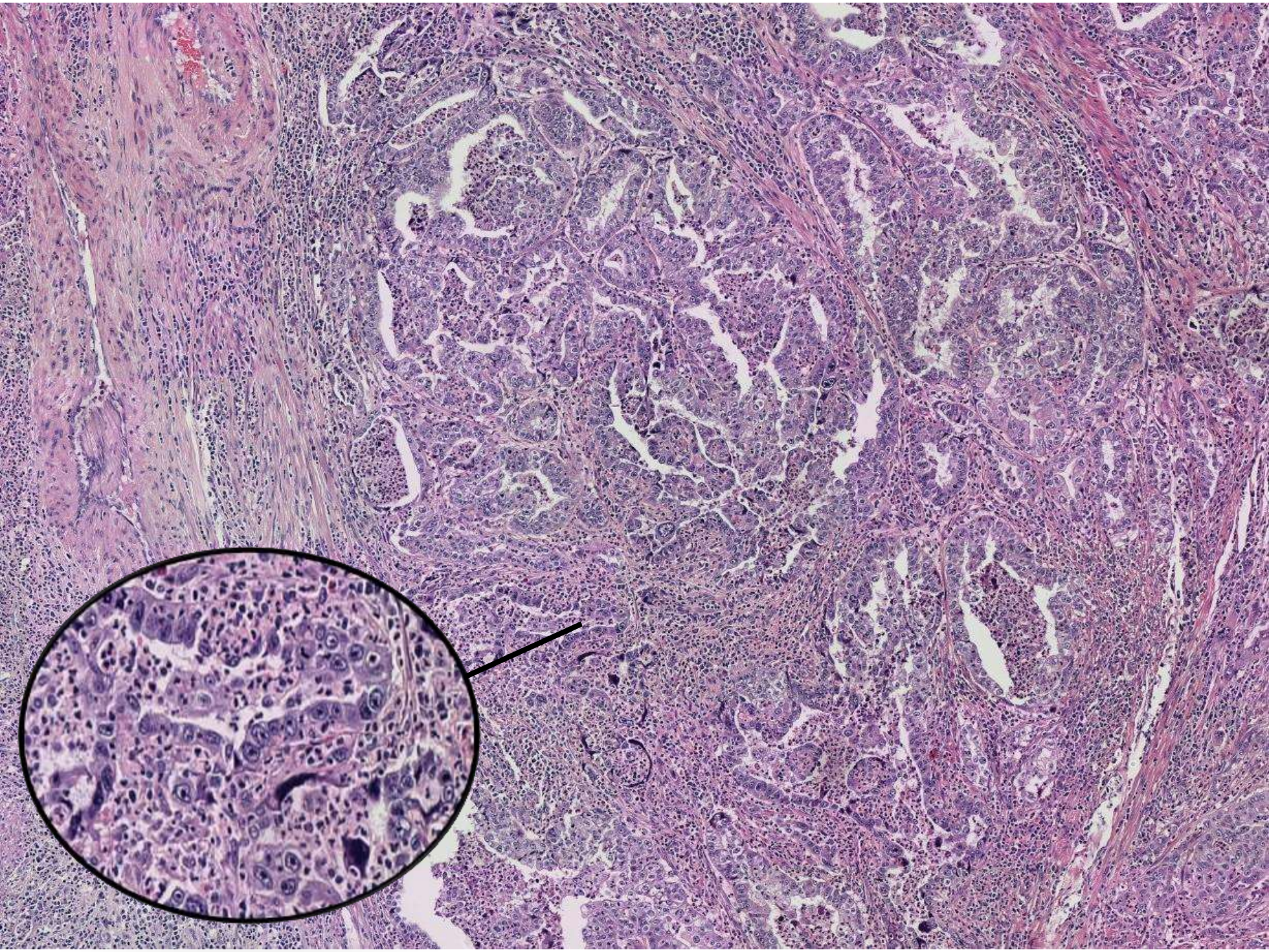


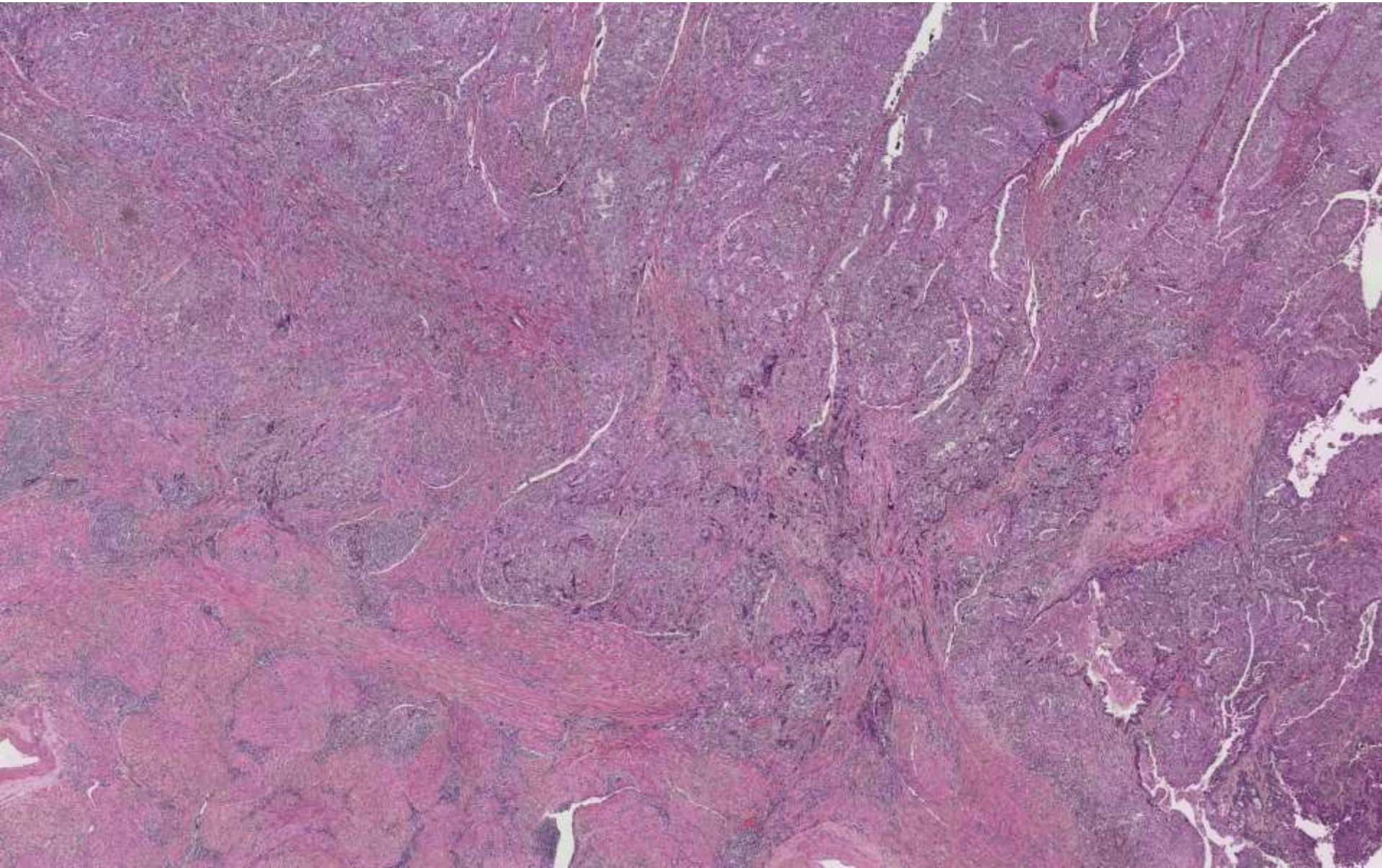


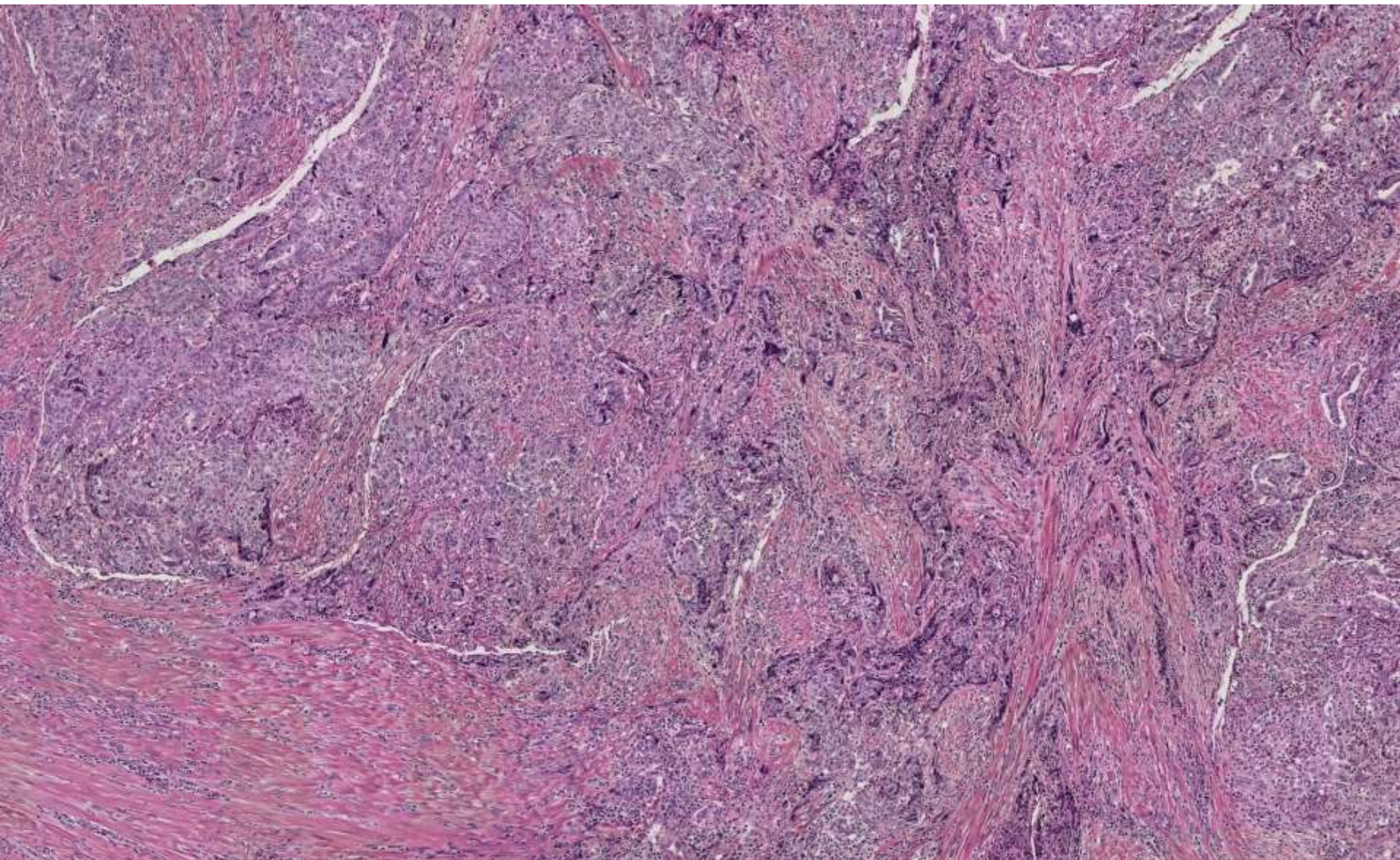


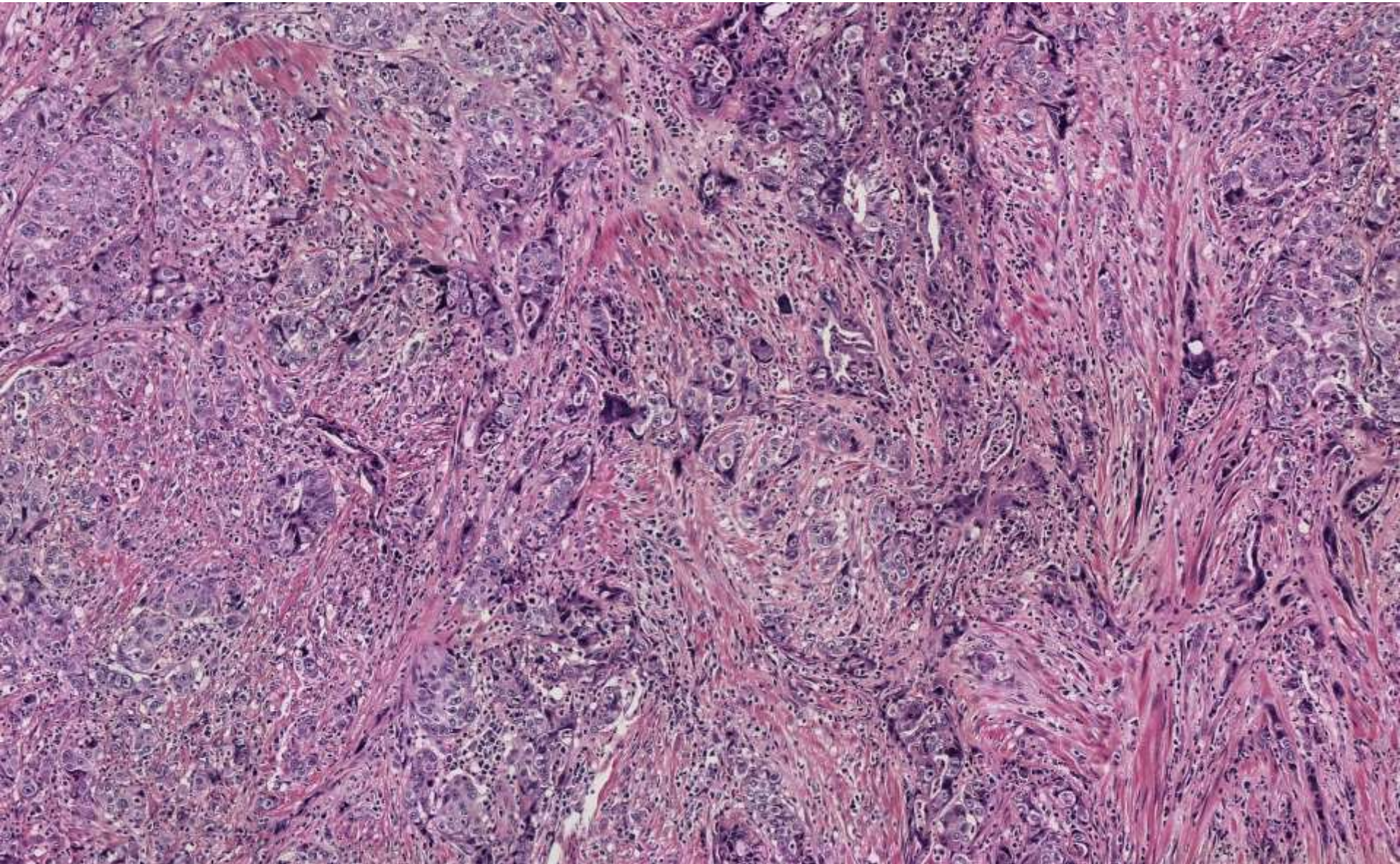


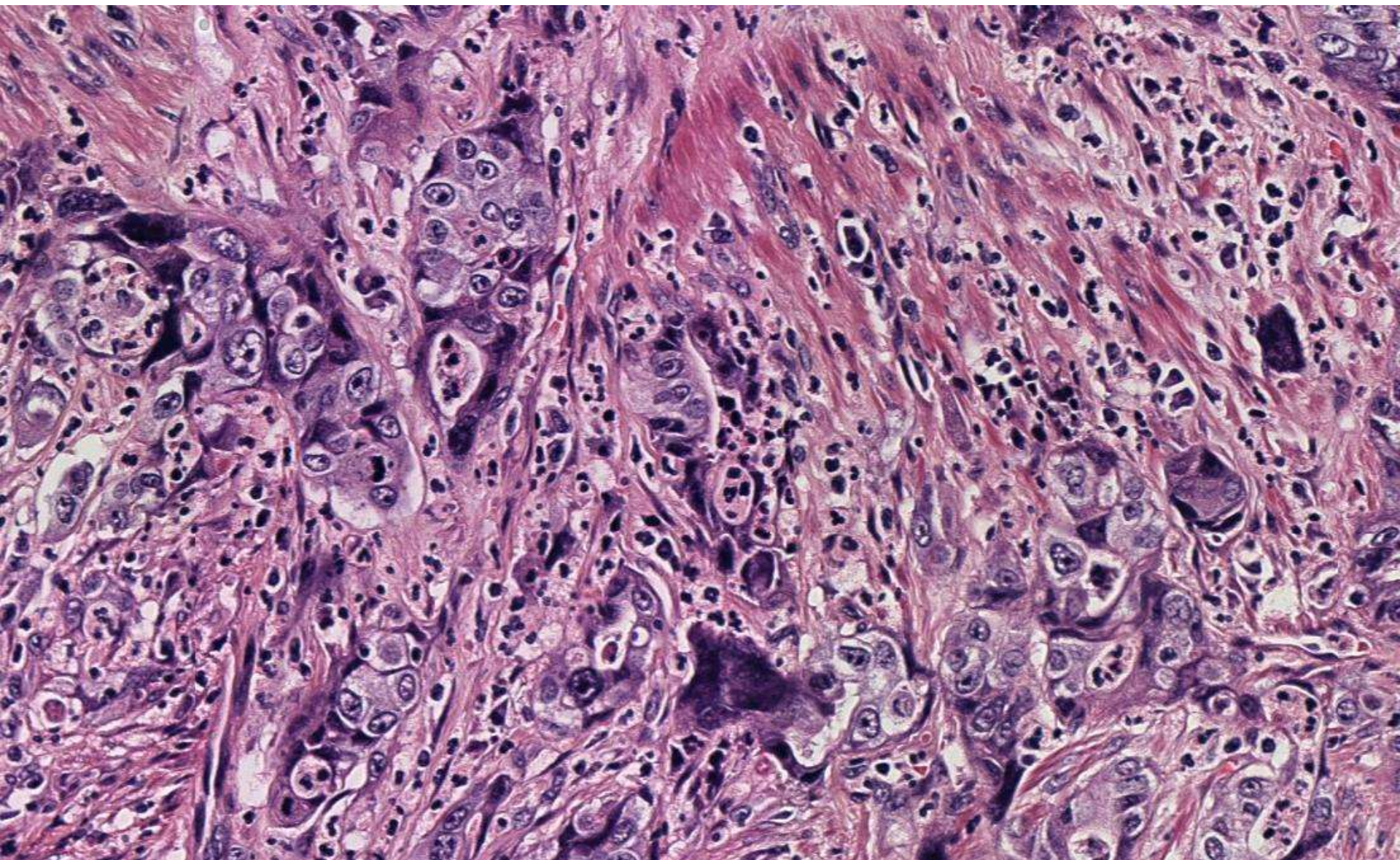


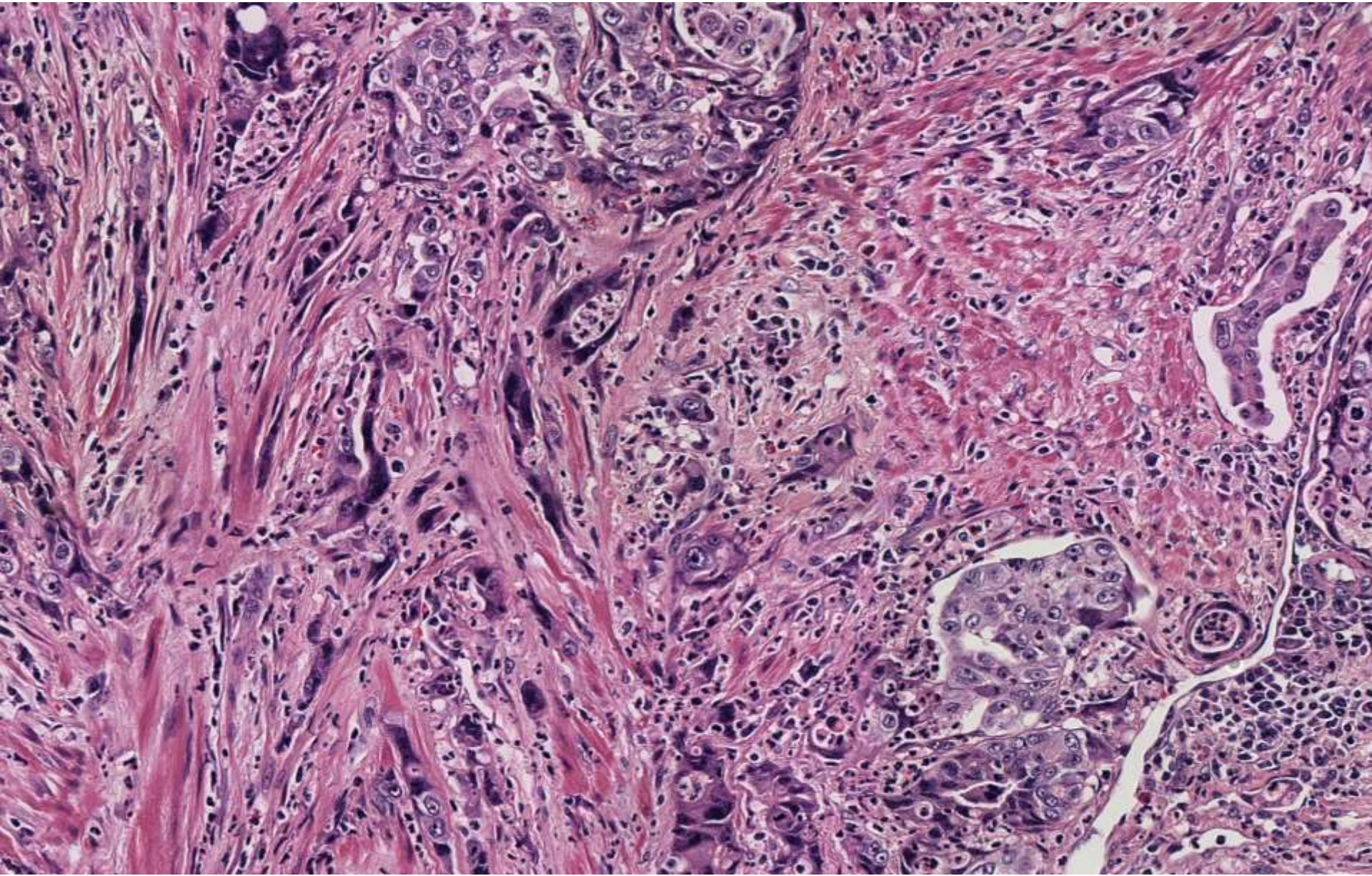












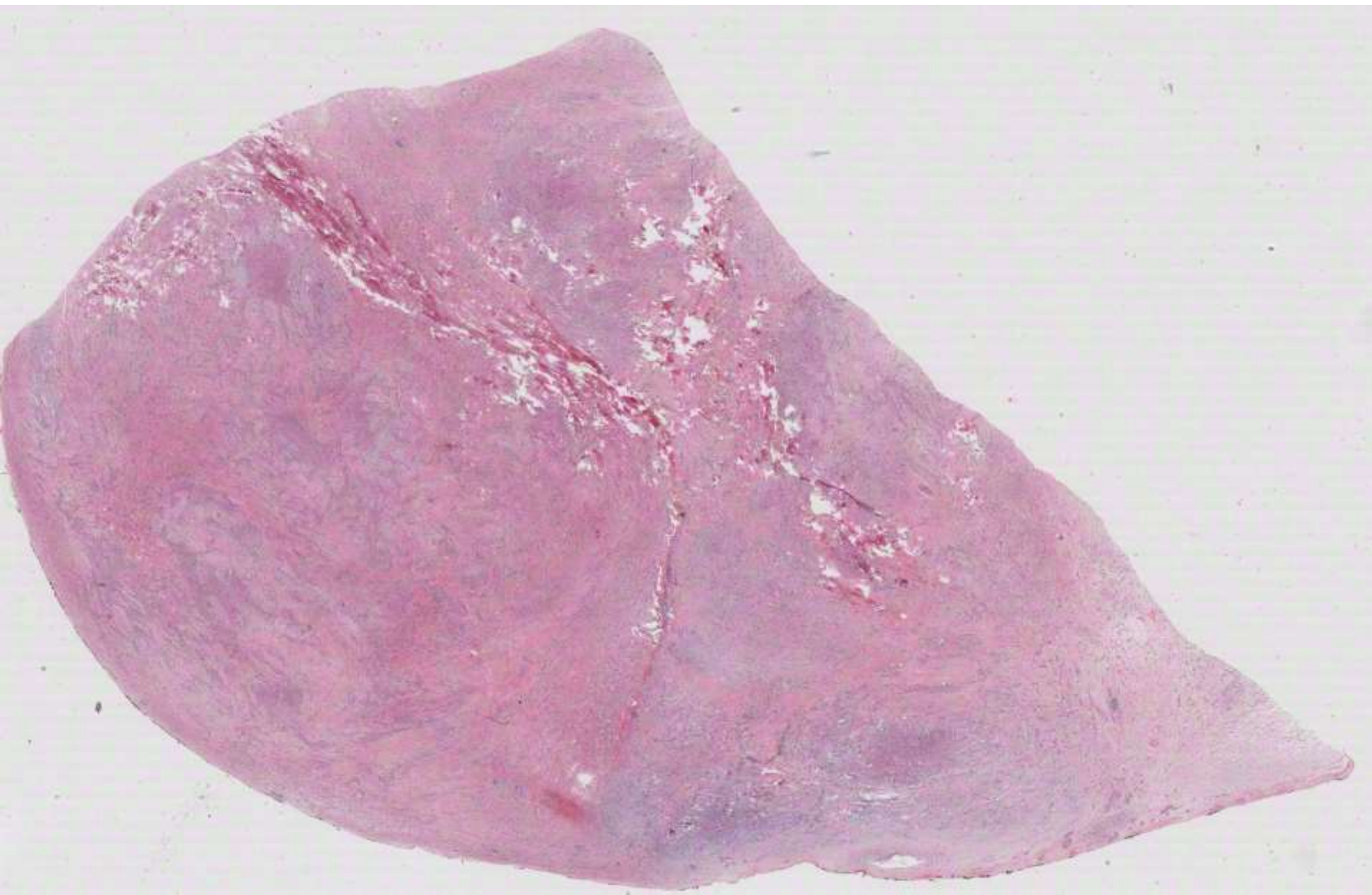


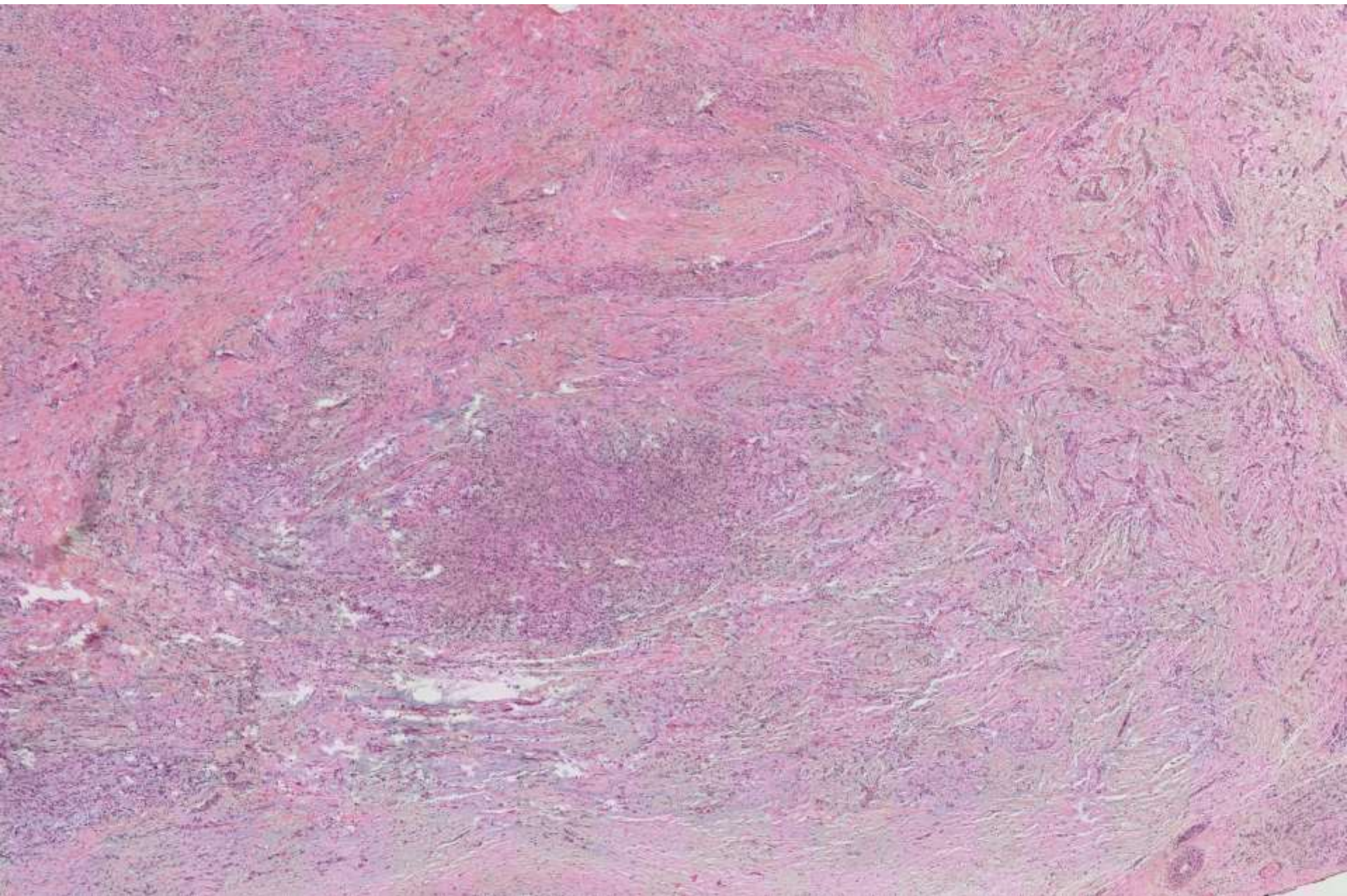
19-0804

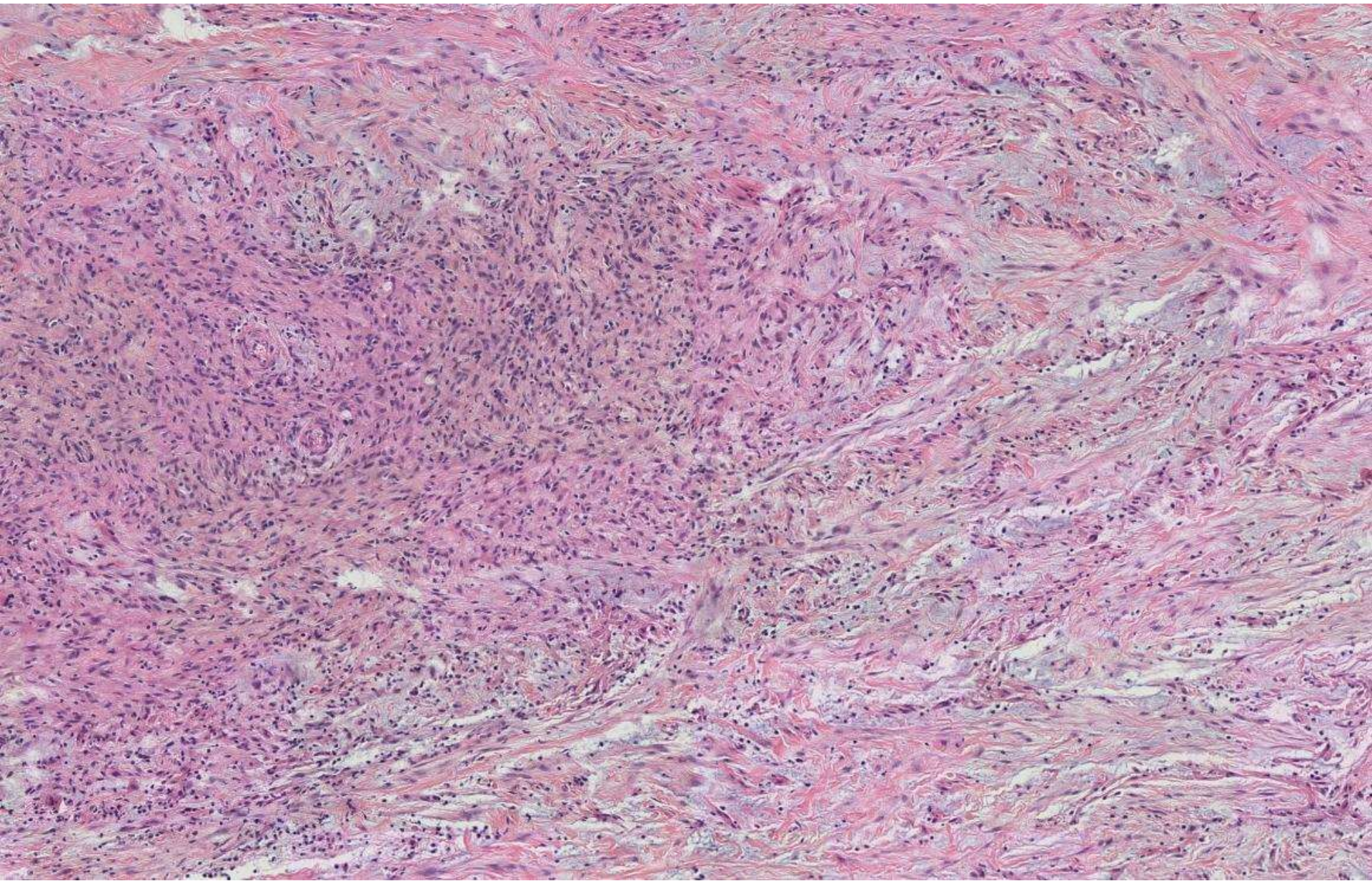
(scanned slide available)

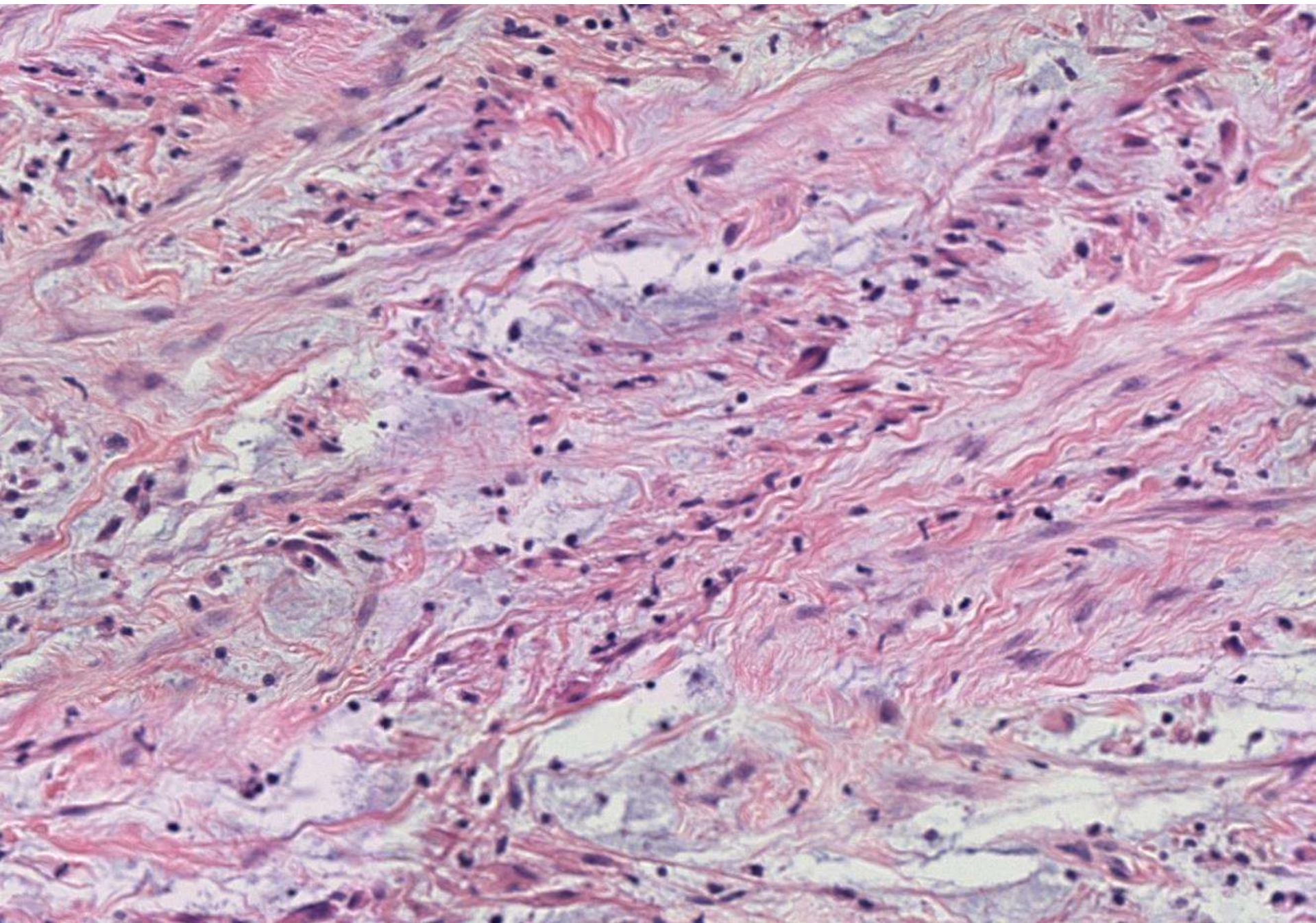
Nicole Croom/Karuna Garg; UCSF

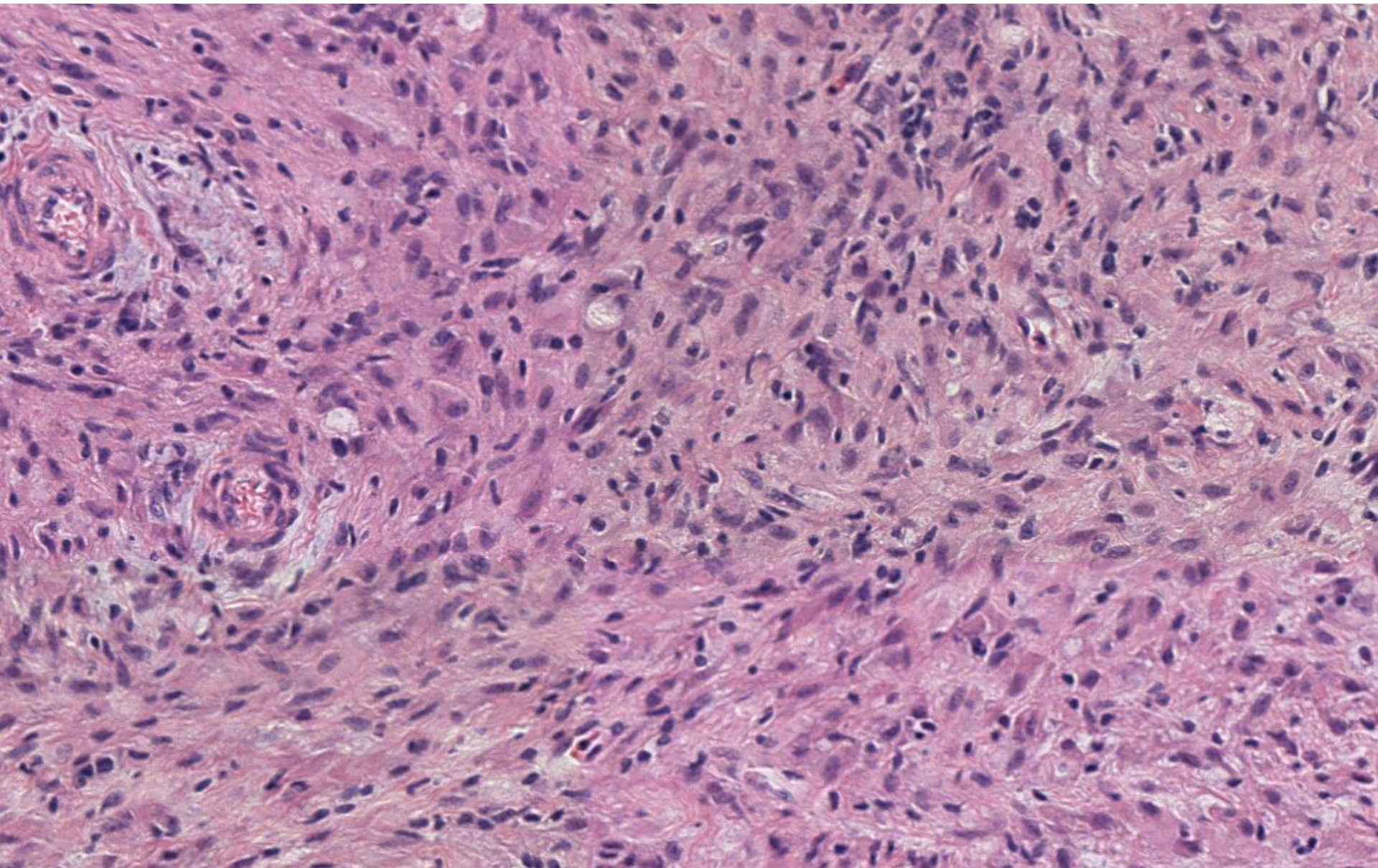
10-year-old girl with h/o immature pelvic teratoma s/p resection now with 7cm Pouch of Douglas mass.

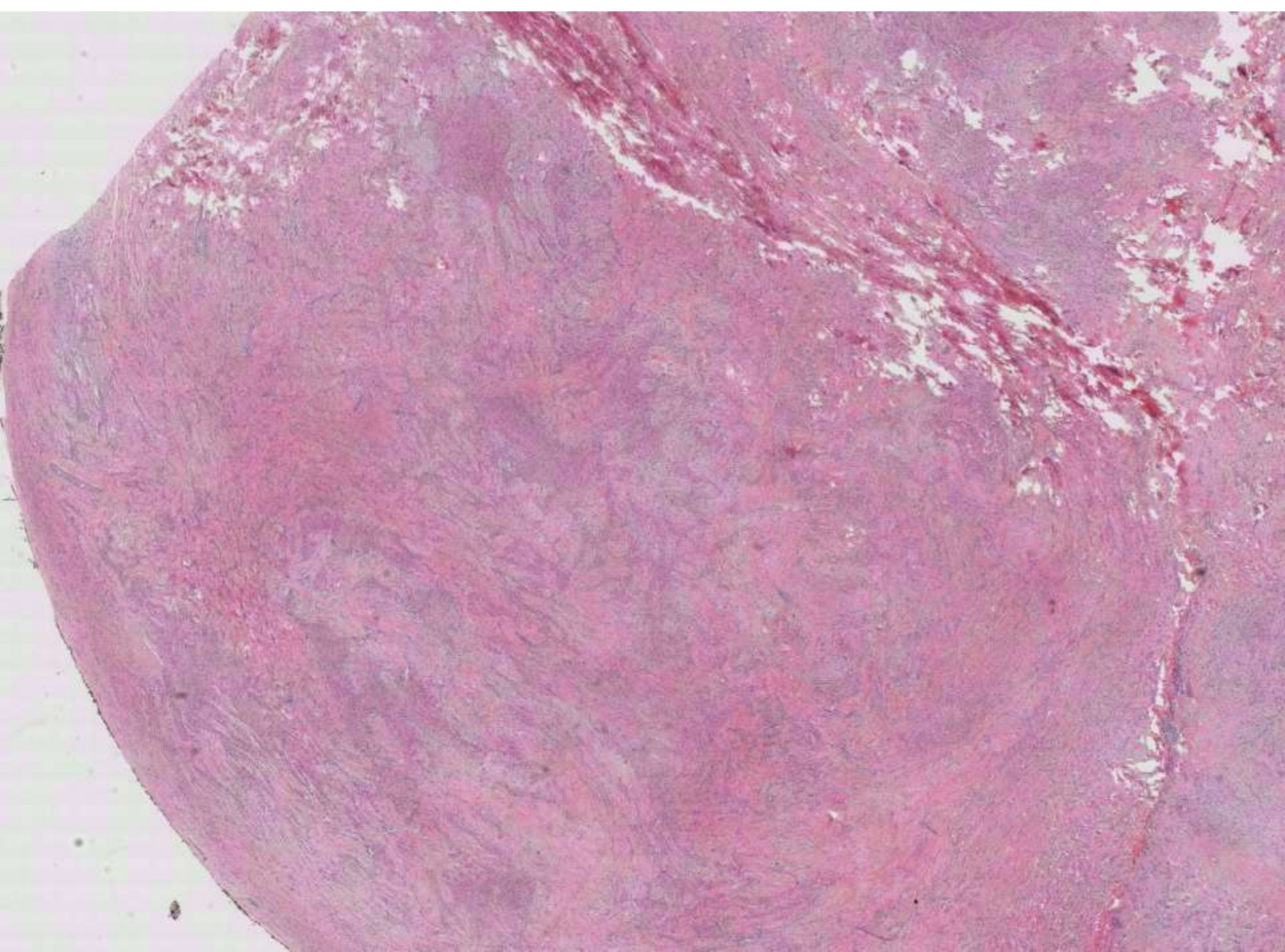


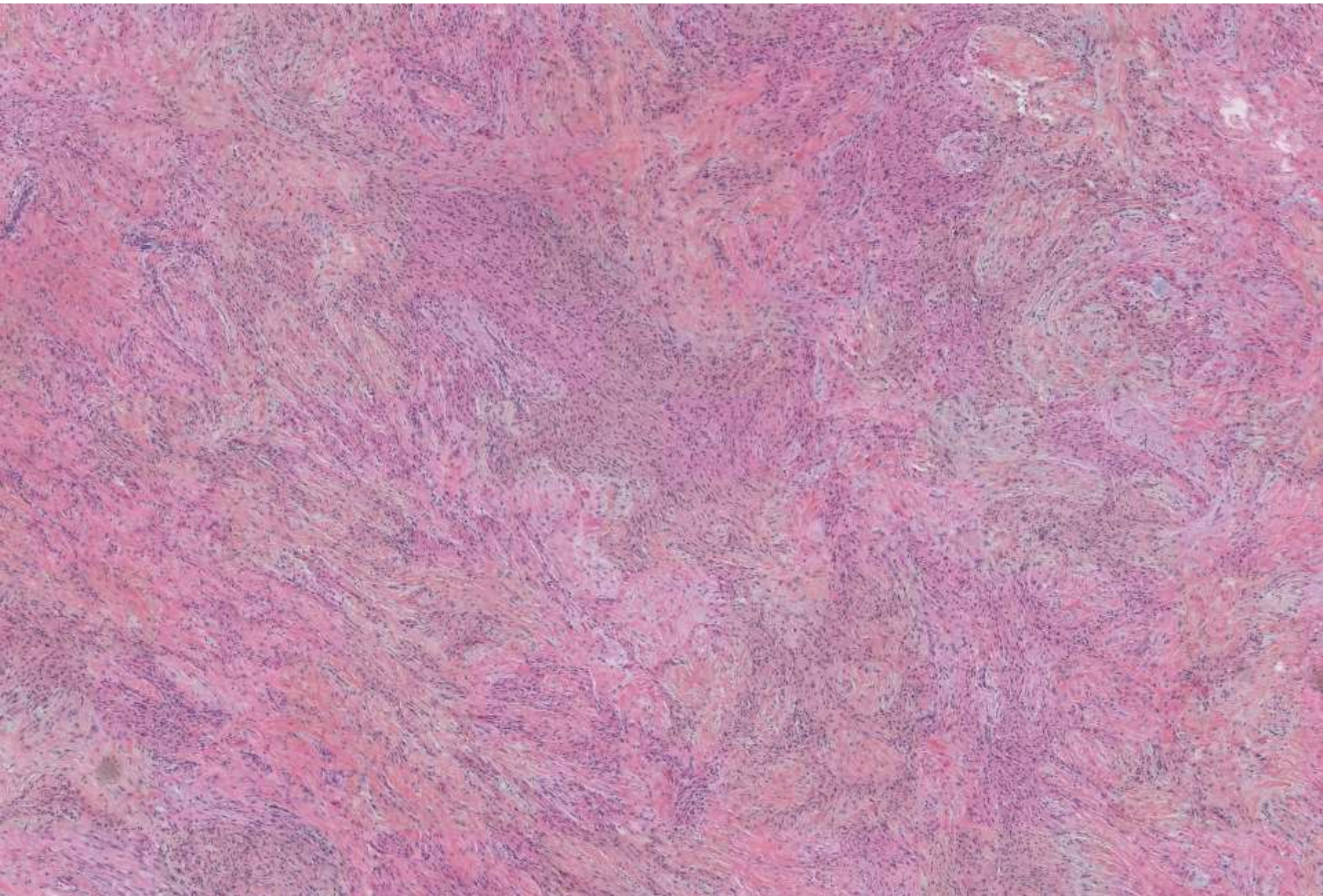


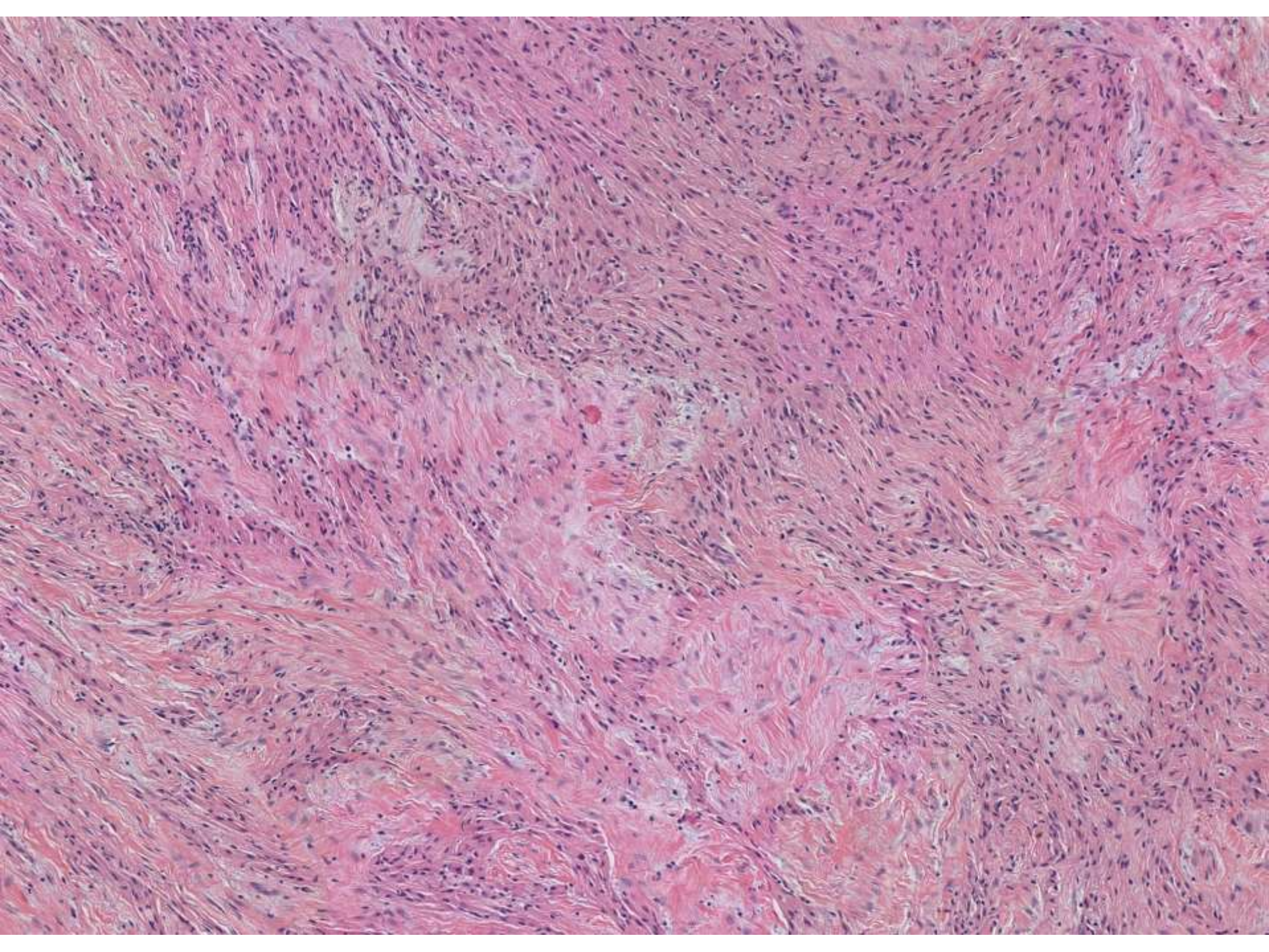


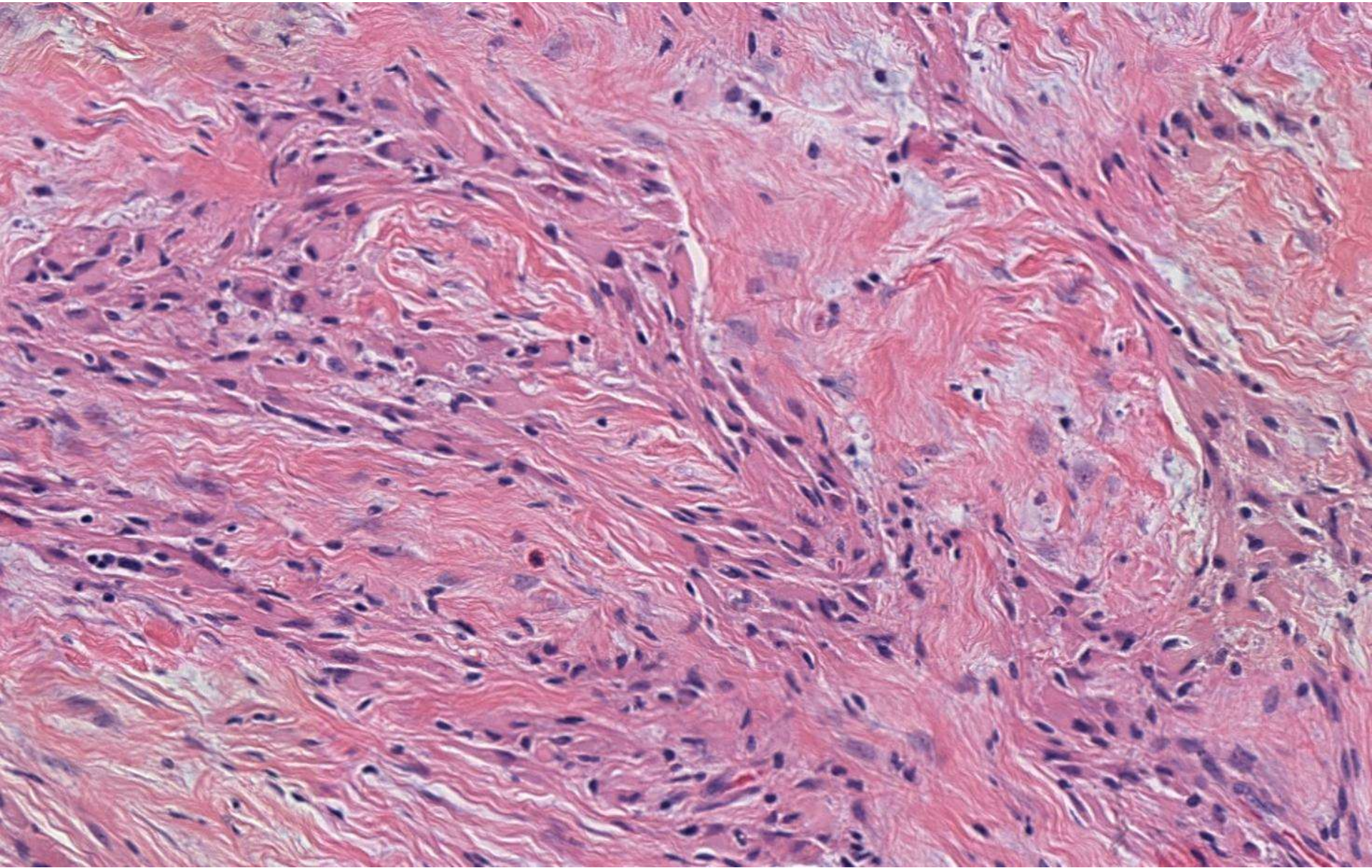














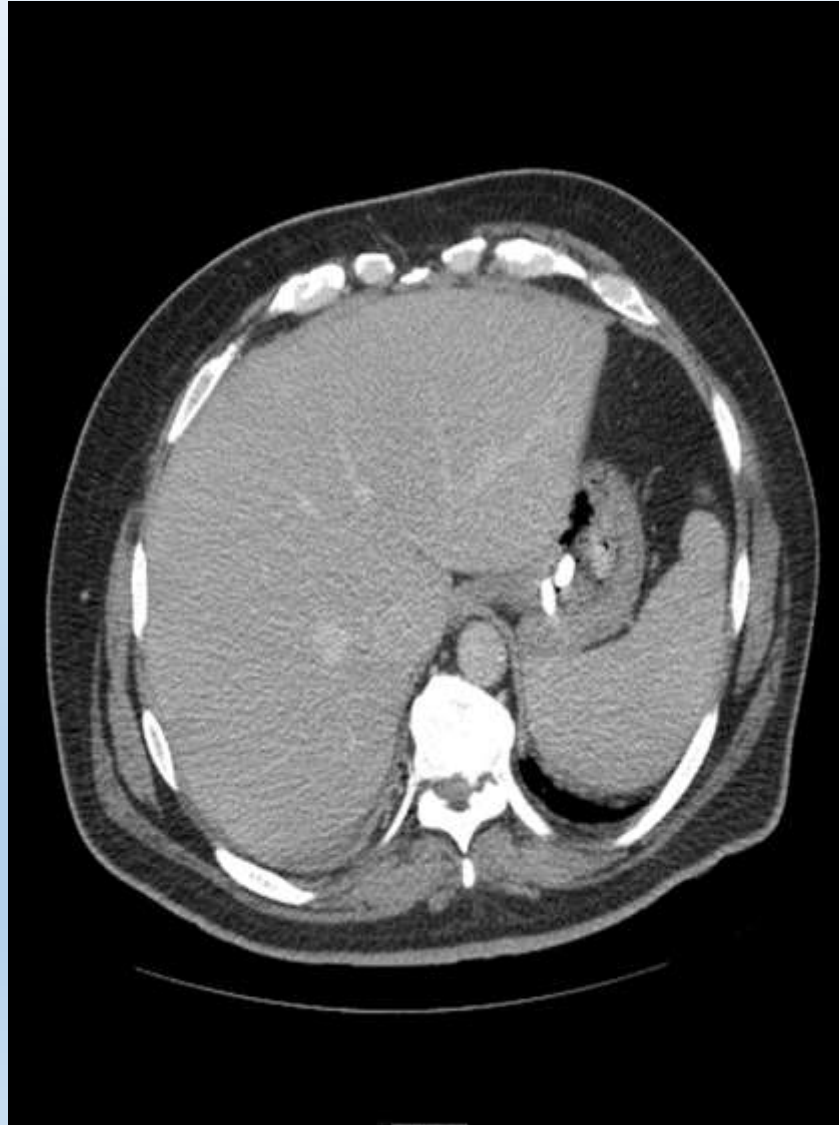19-0805

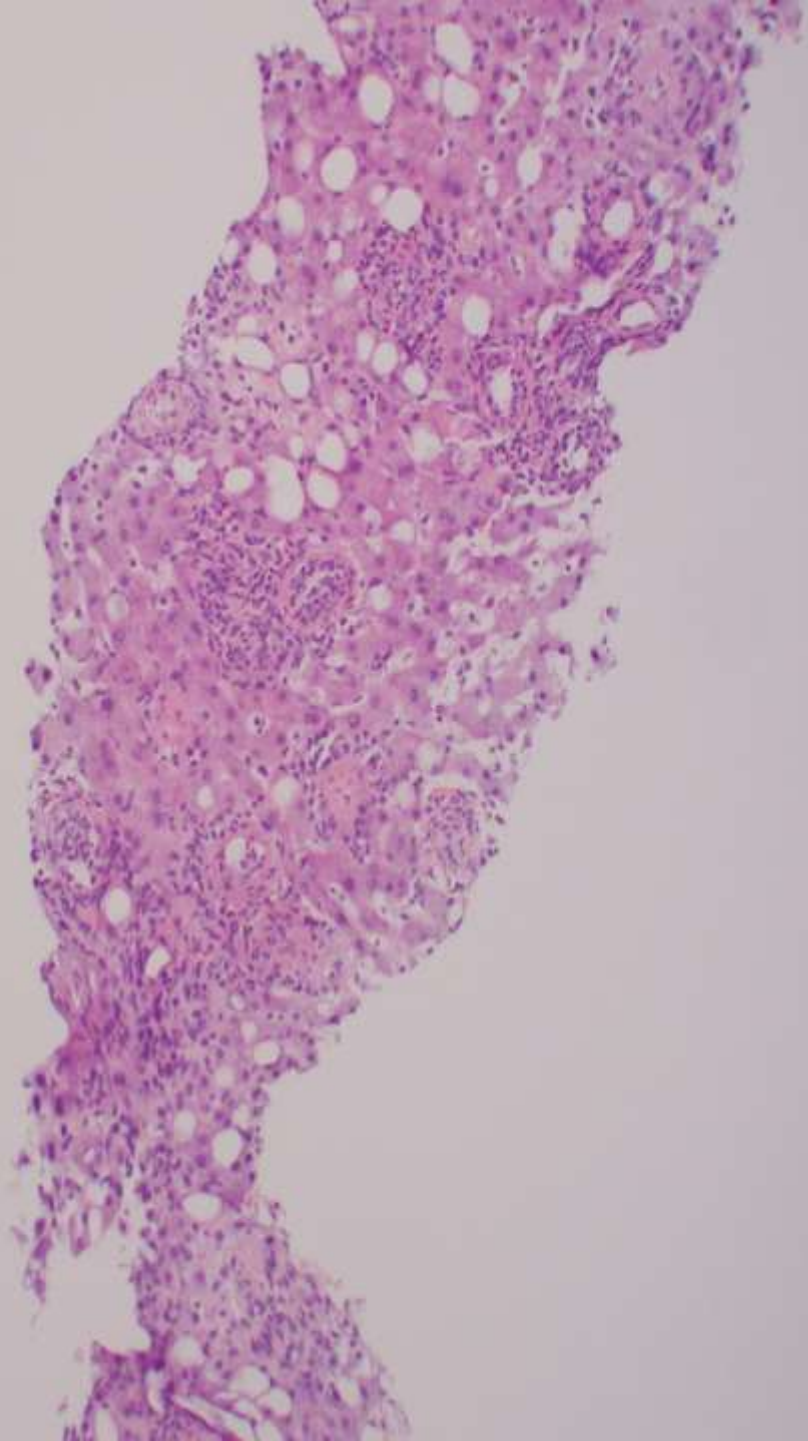
(scanned slide available)

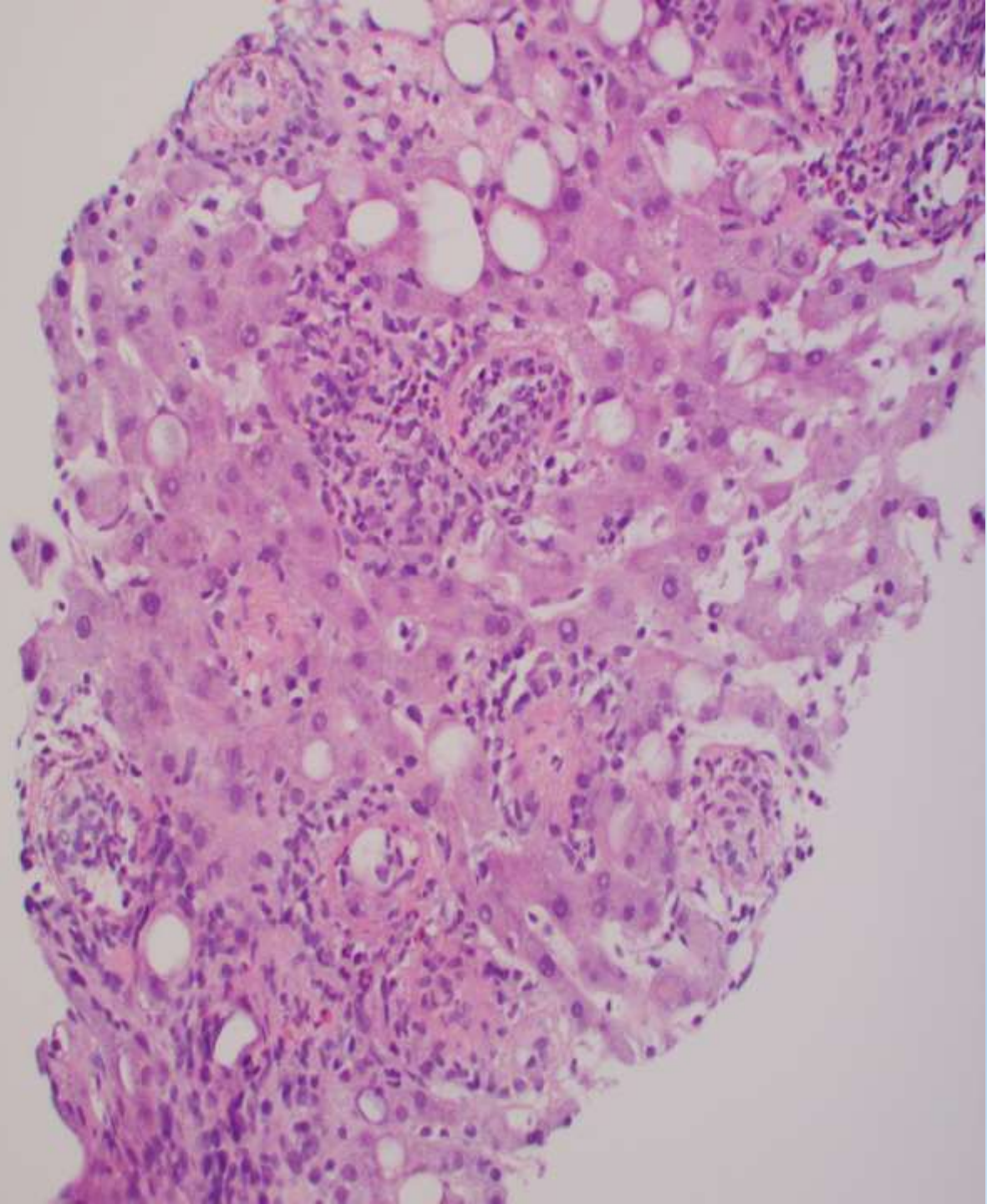
Sava Grujic; Kaiser San Jose

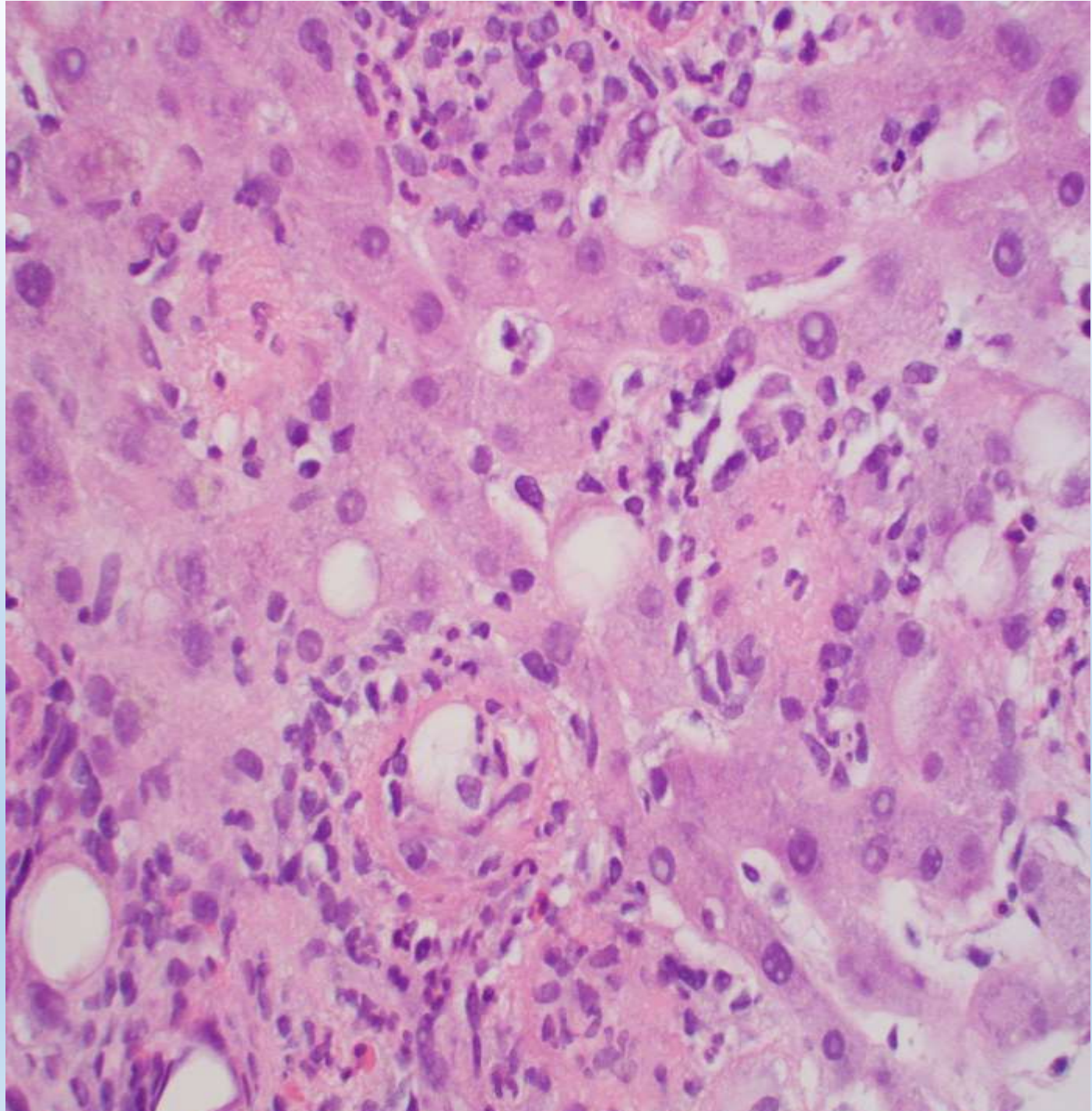
48-year-old man with fever and
hepatosplenomegaly. Liver biopsy submitted.

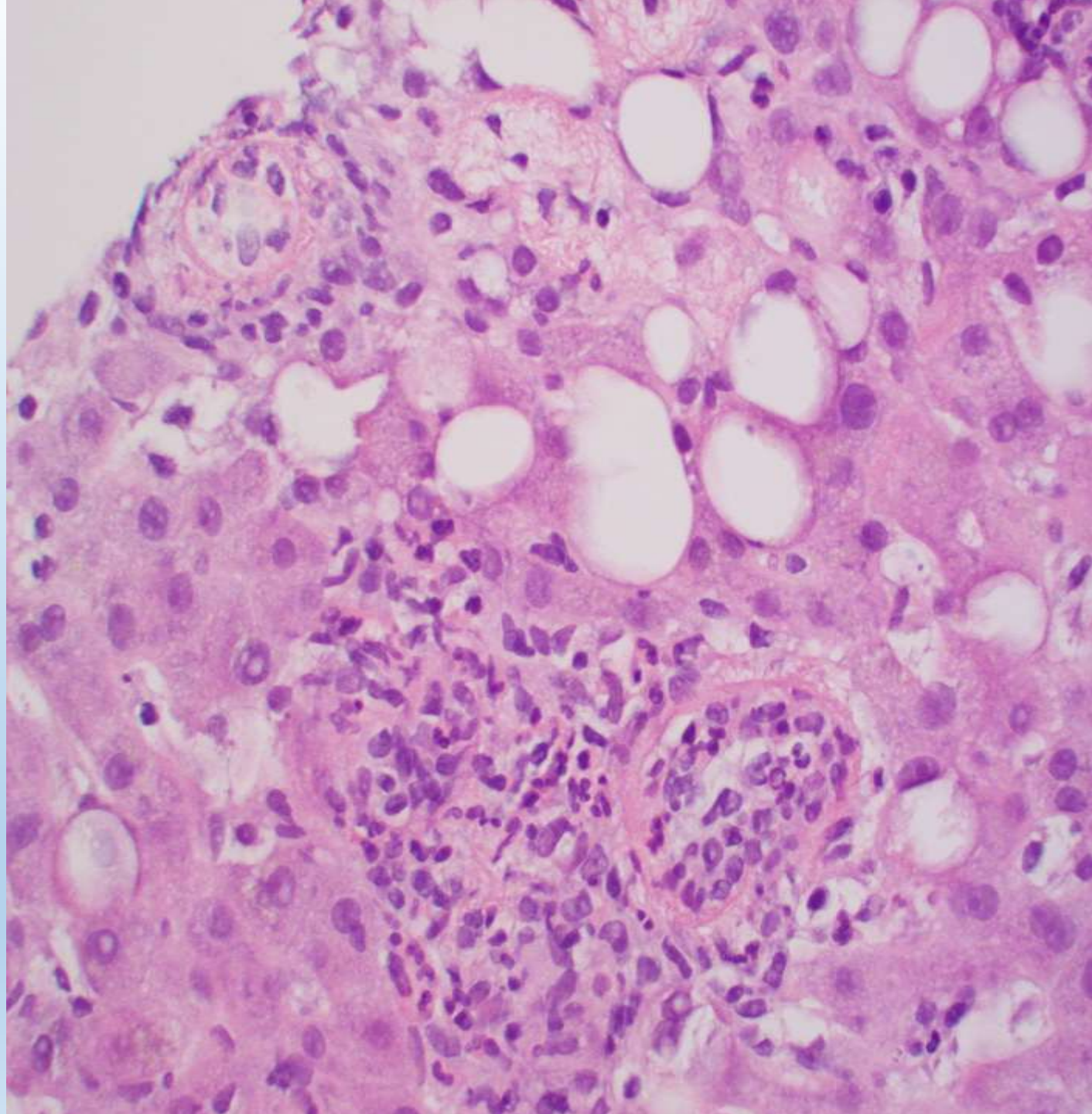
48 y/o male with fever and hepatosplenomegaly
Initial serology was nonconclusive, liver bx was
performed









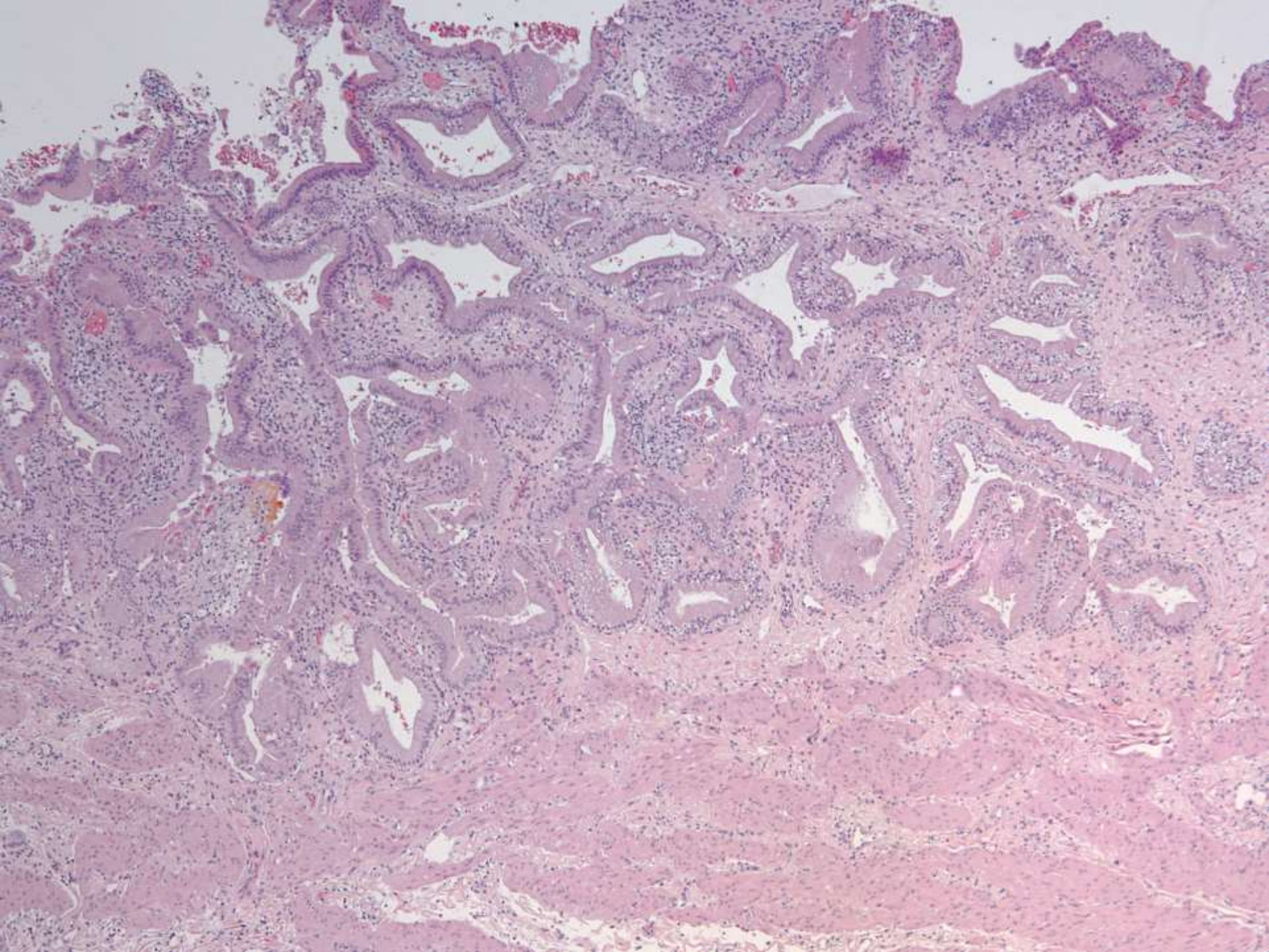


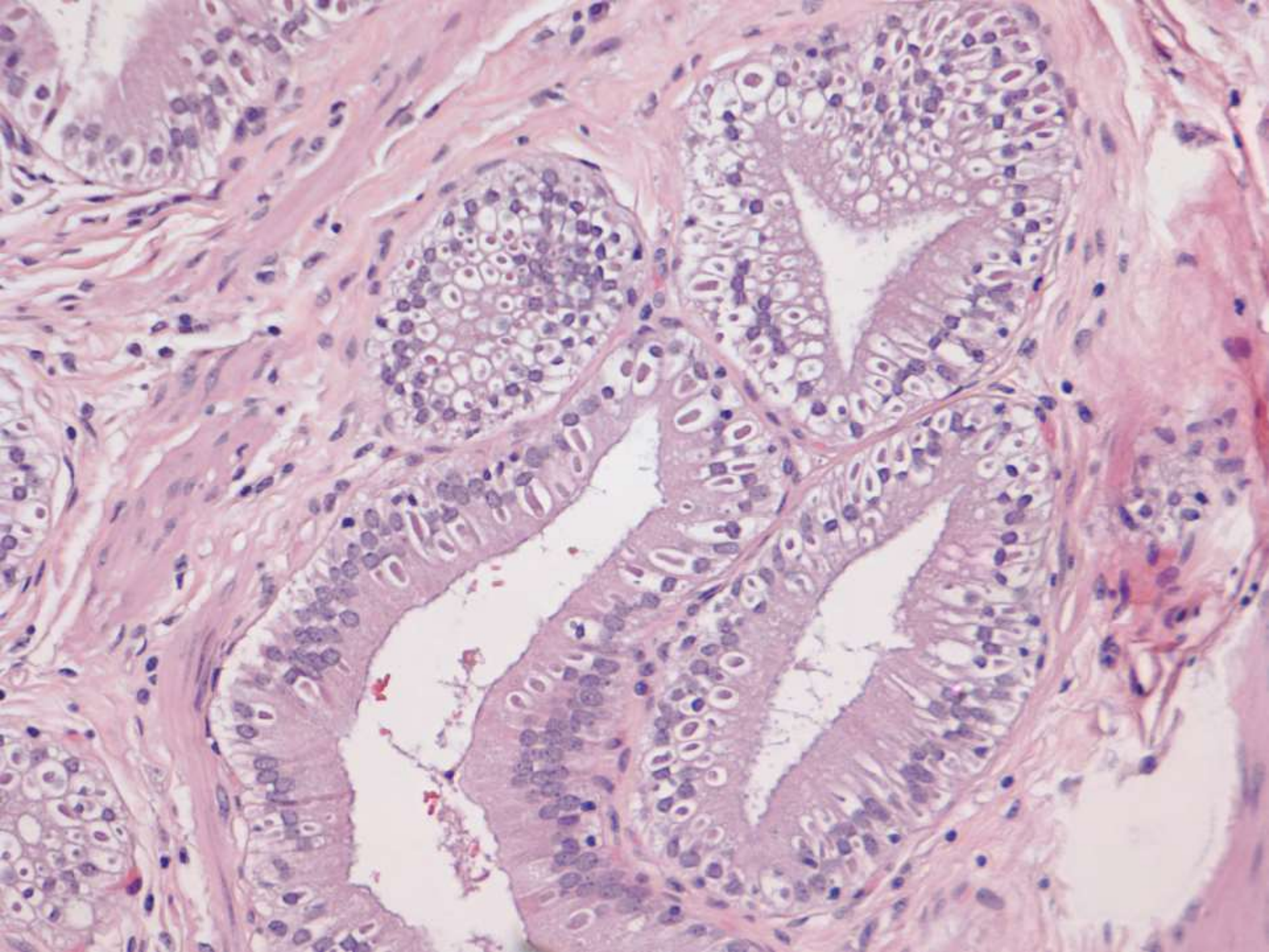


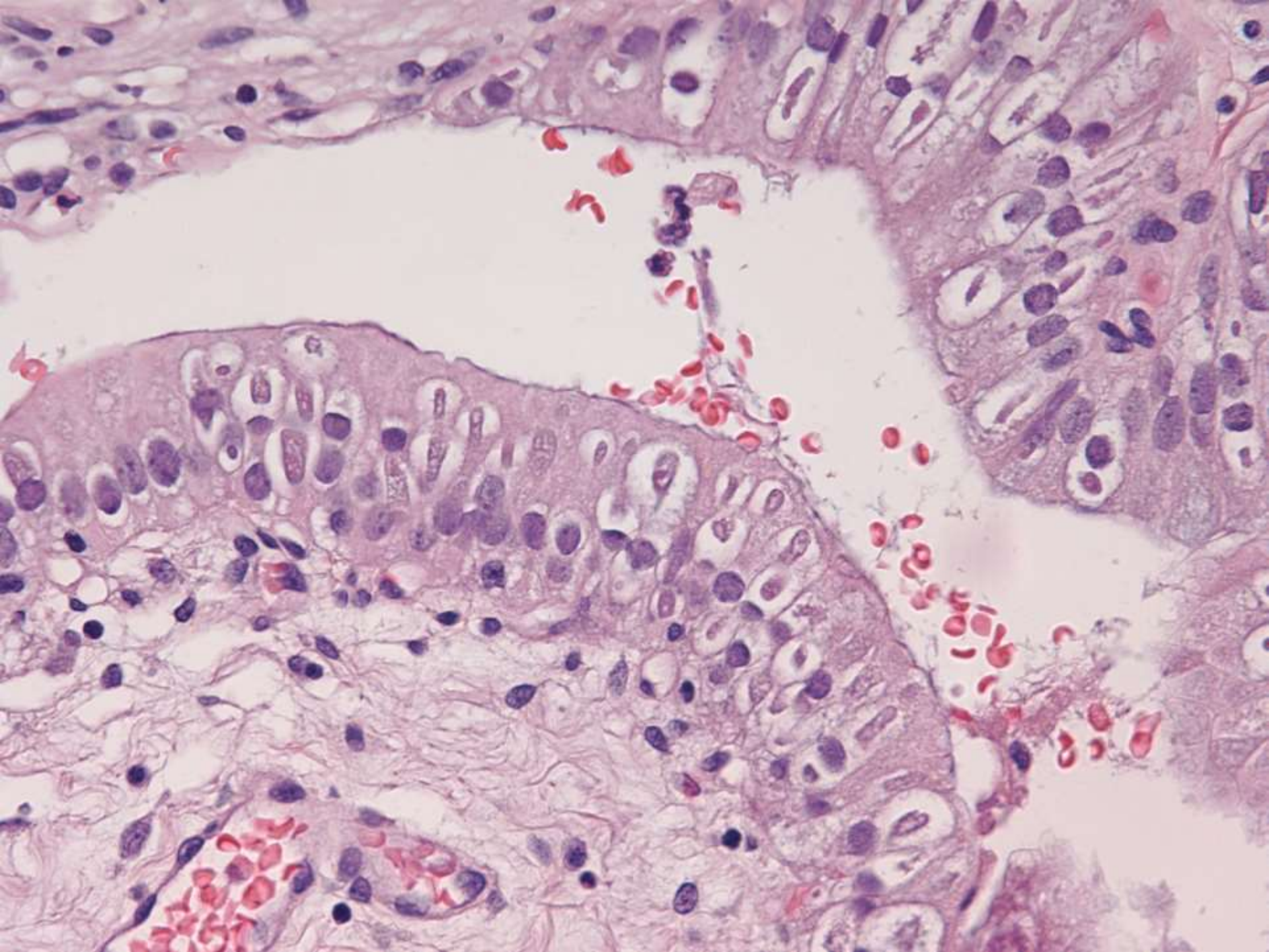
19-0806

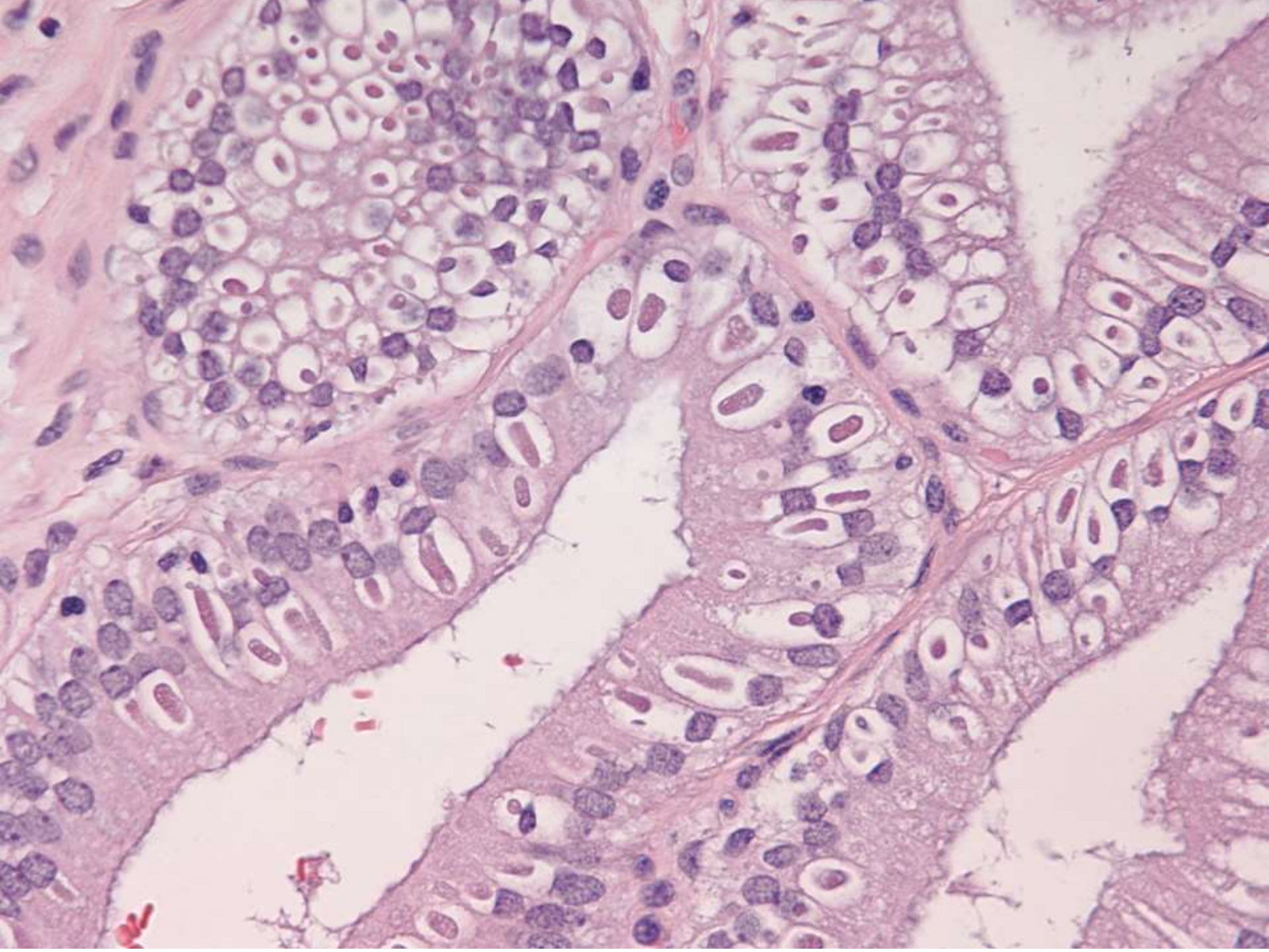
Greg Charville; Stanford

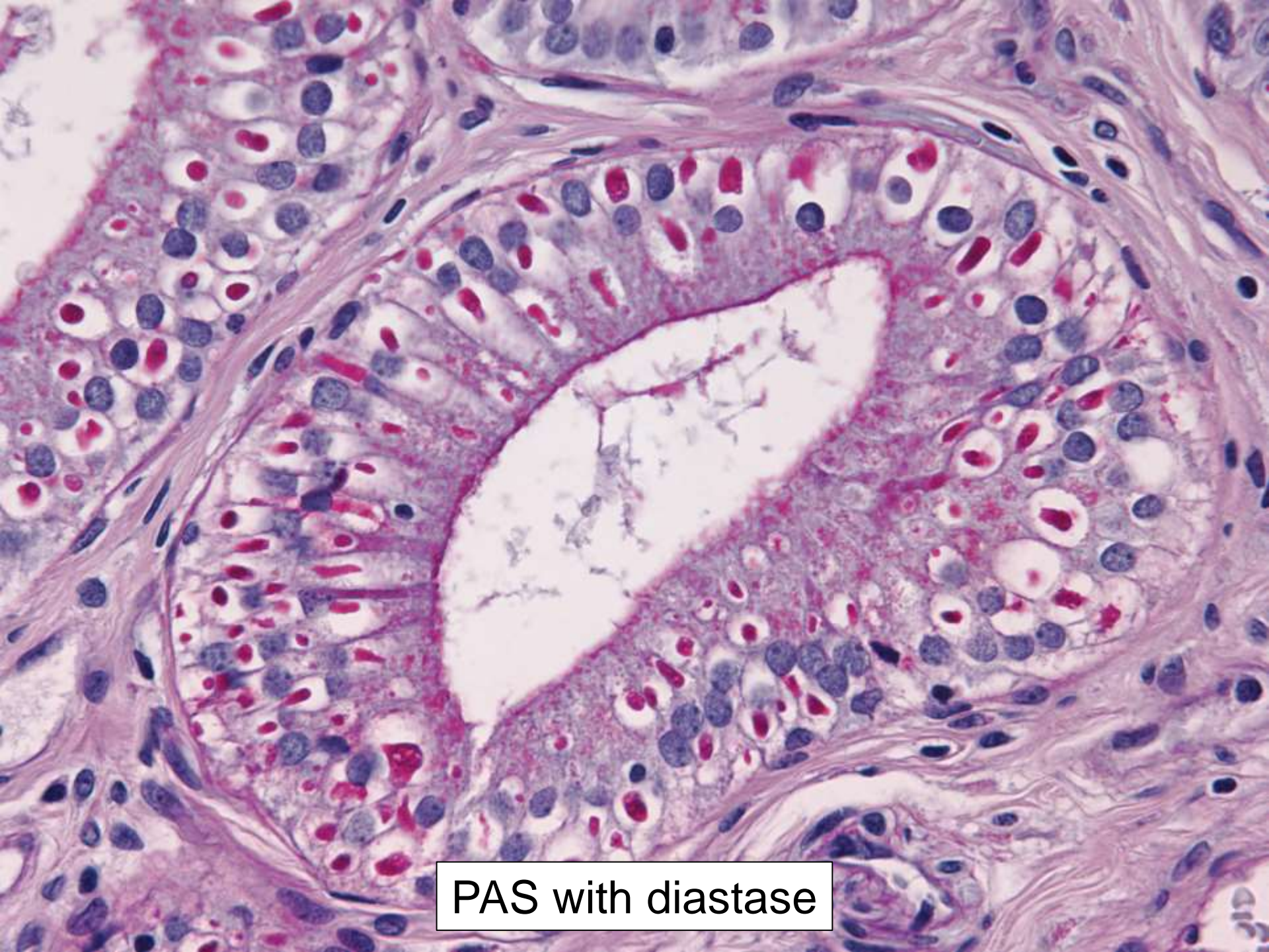
71-year-old undergoing liver transplant for Hepatitis C cirrhosis complicated by HCC. Persistent diarrhea developed 6 days post-transplant. Donor gallbladder specimen submitted.











PAS with diastase



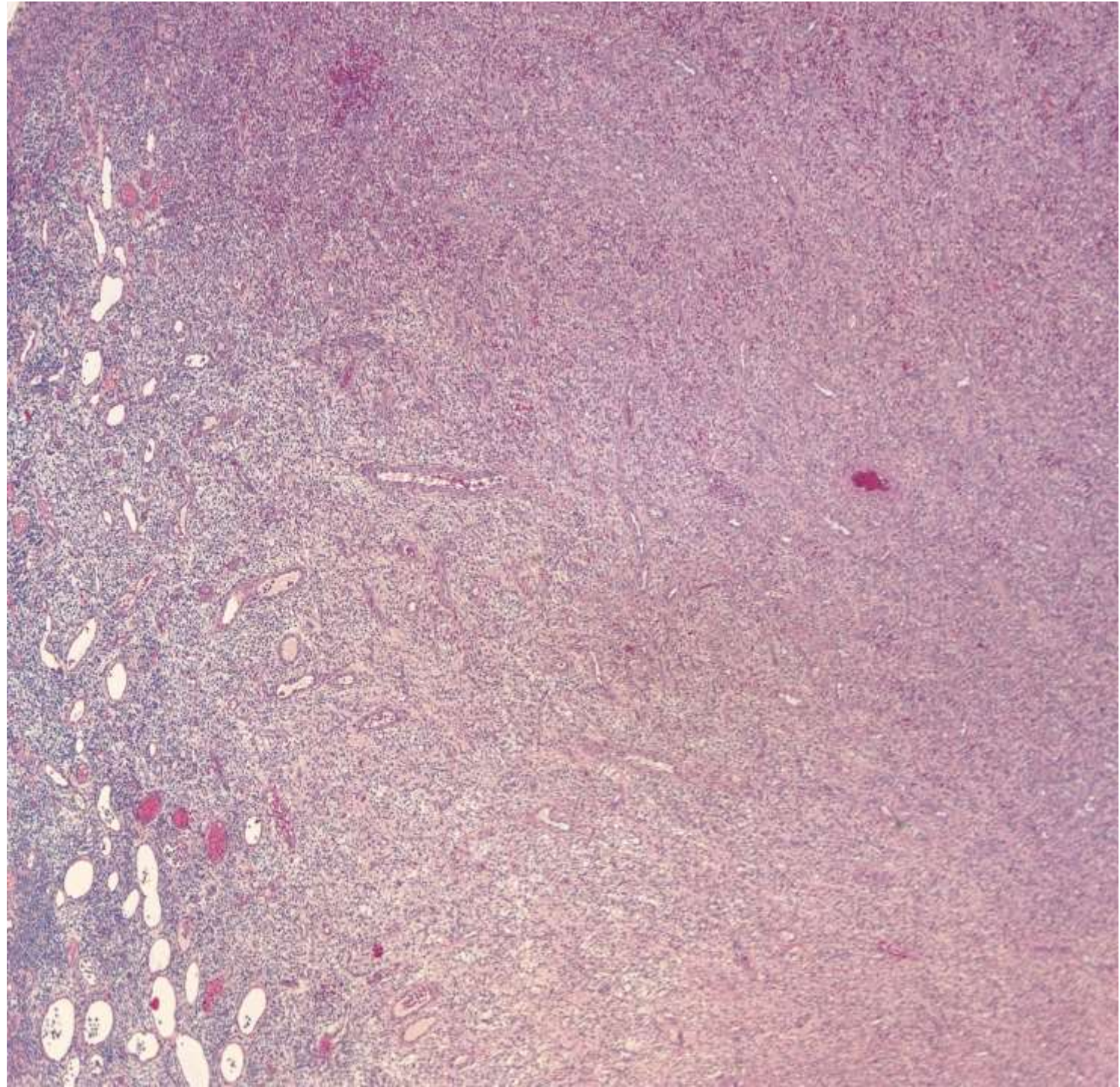
19-0807

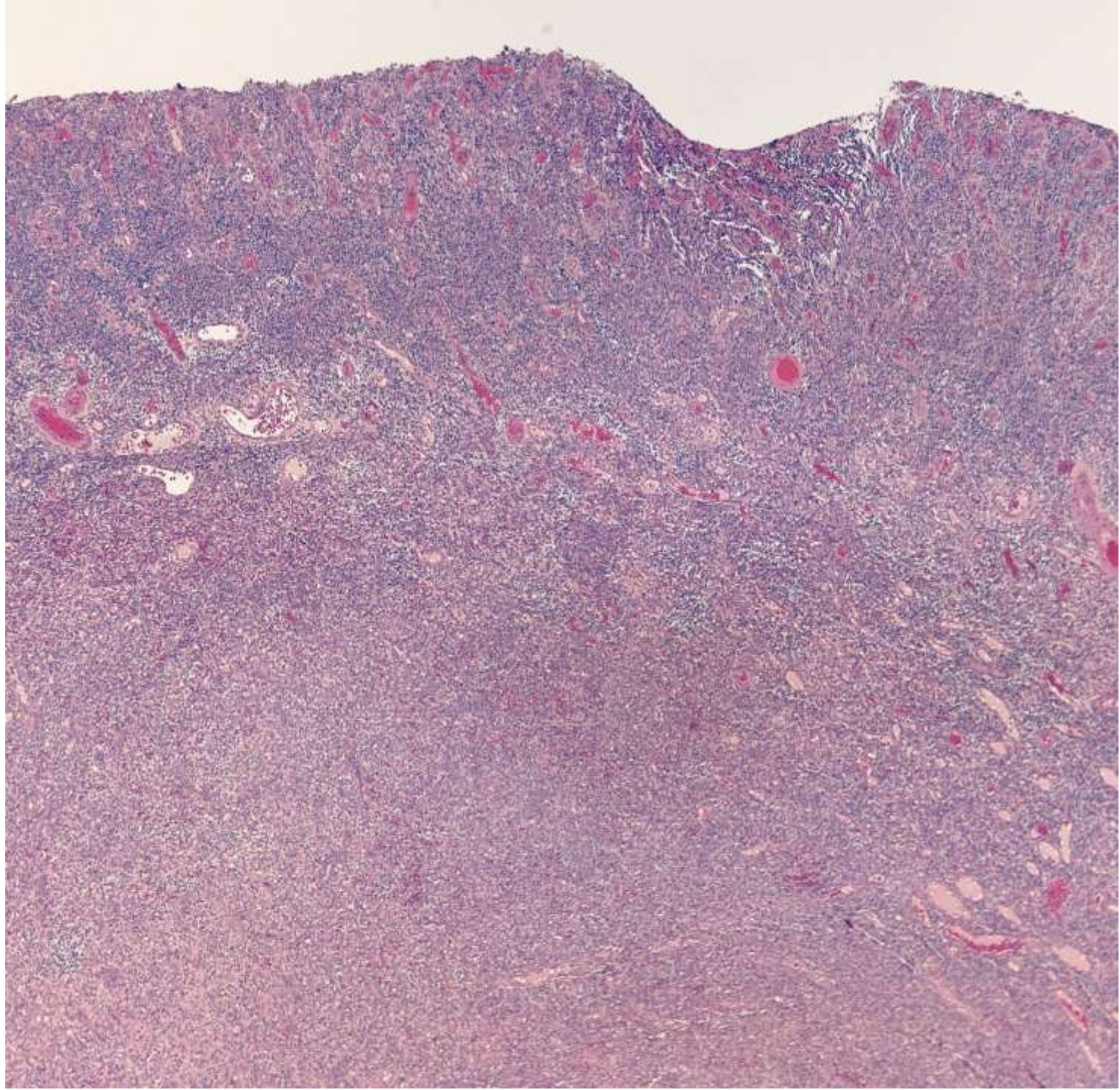
Shyam Raghavan/Greg Charville;
Stanford

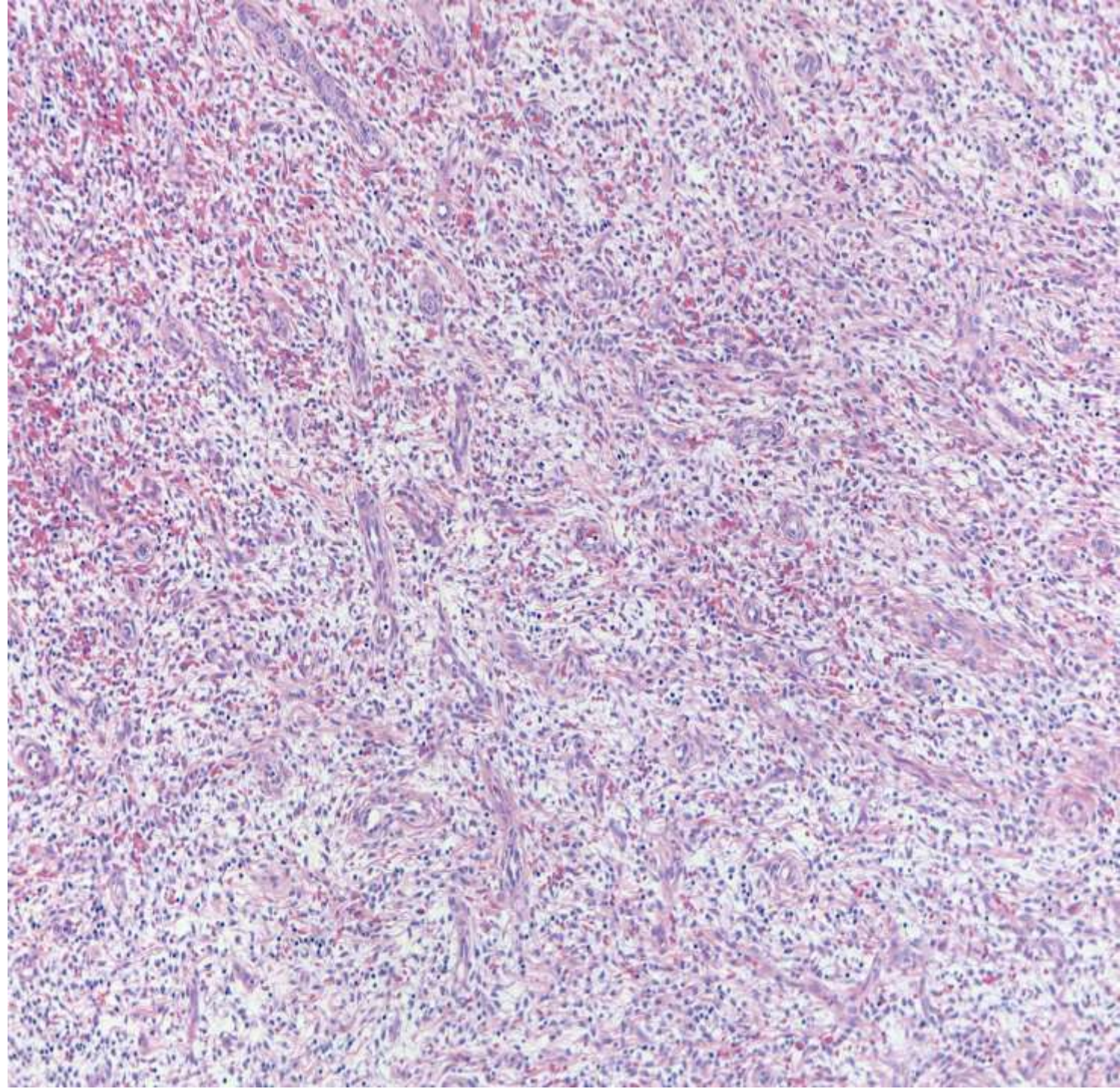
68-year-old woman with sessile sigmoid
colon mass.

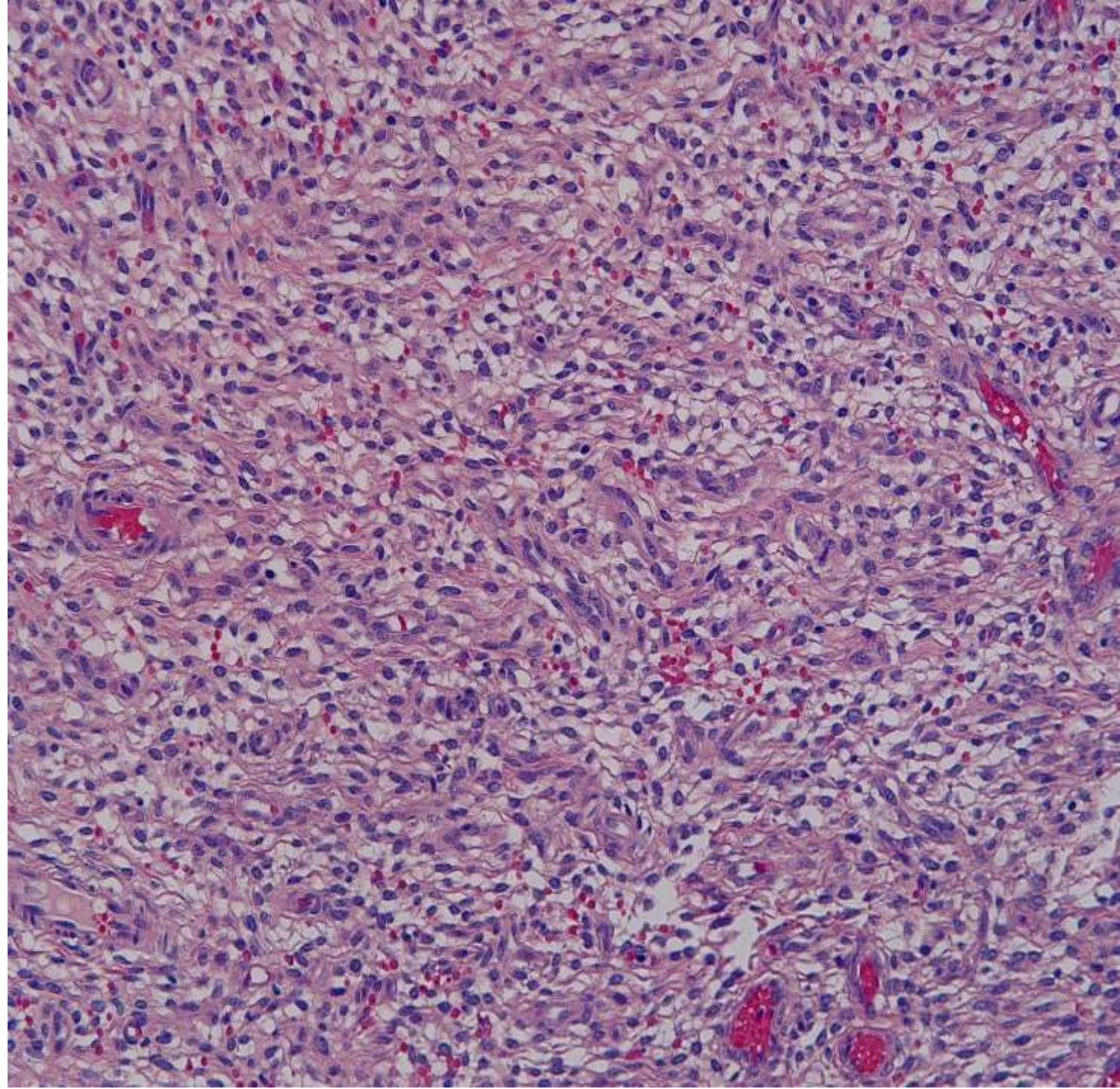
Clinical History

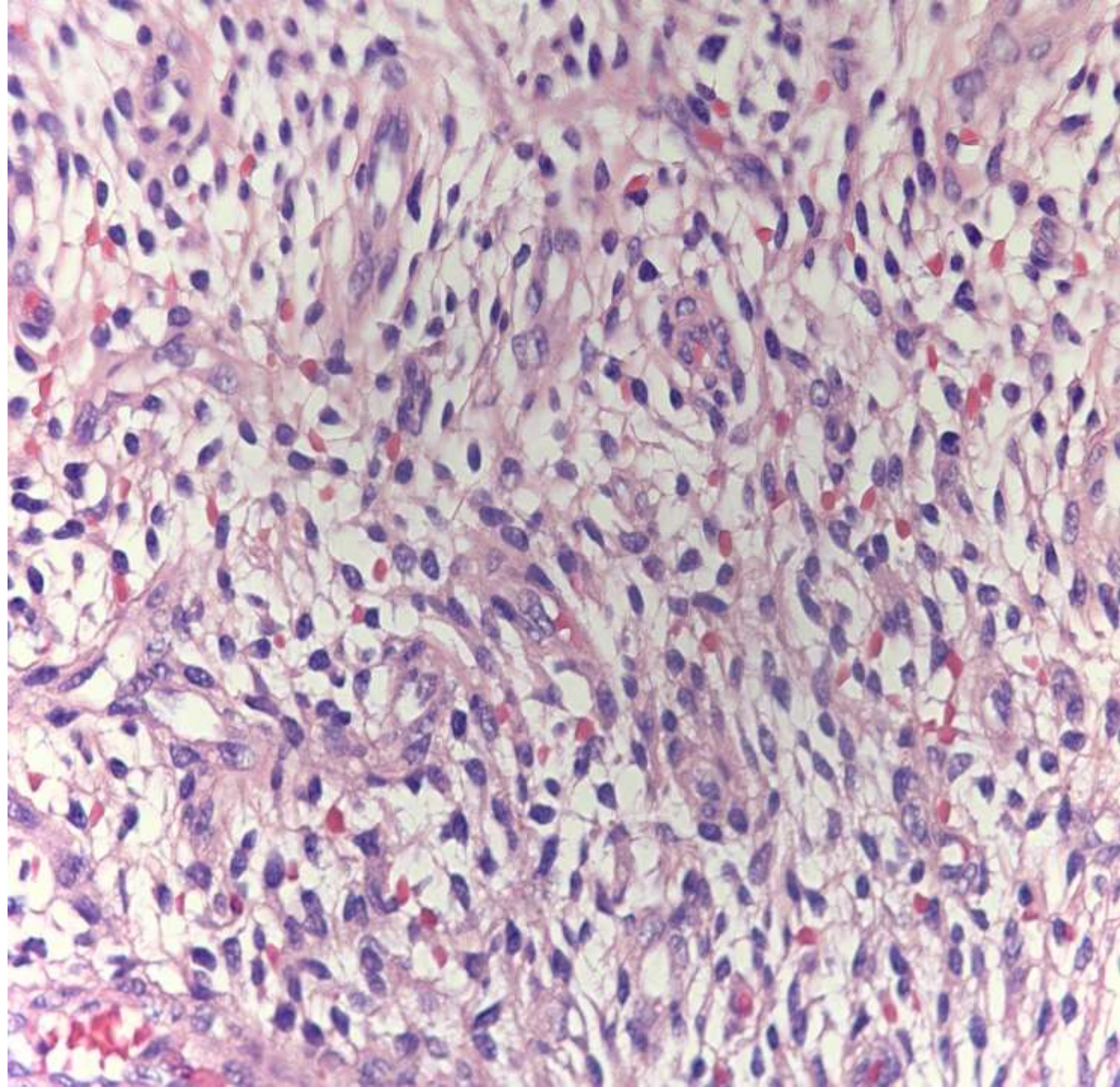
- 68 year old female with a rectosigmoid mass, identified on routine screening colonoscopy
- No relevant PMH, PSH, Meds
- Endoscopically appeared a sessile broad based partially ulcerated mass

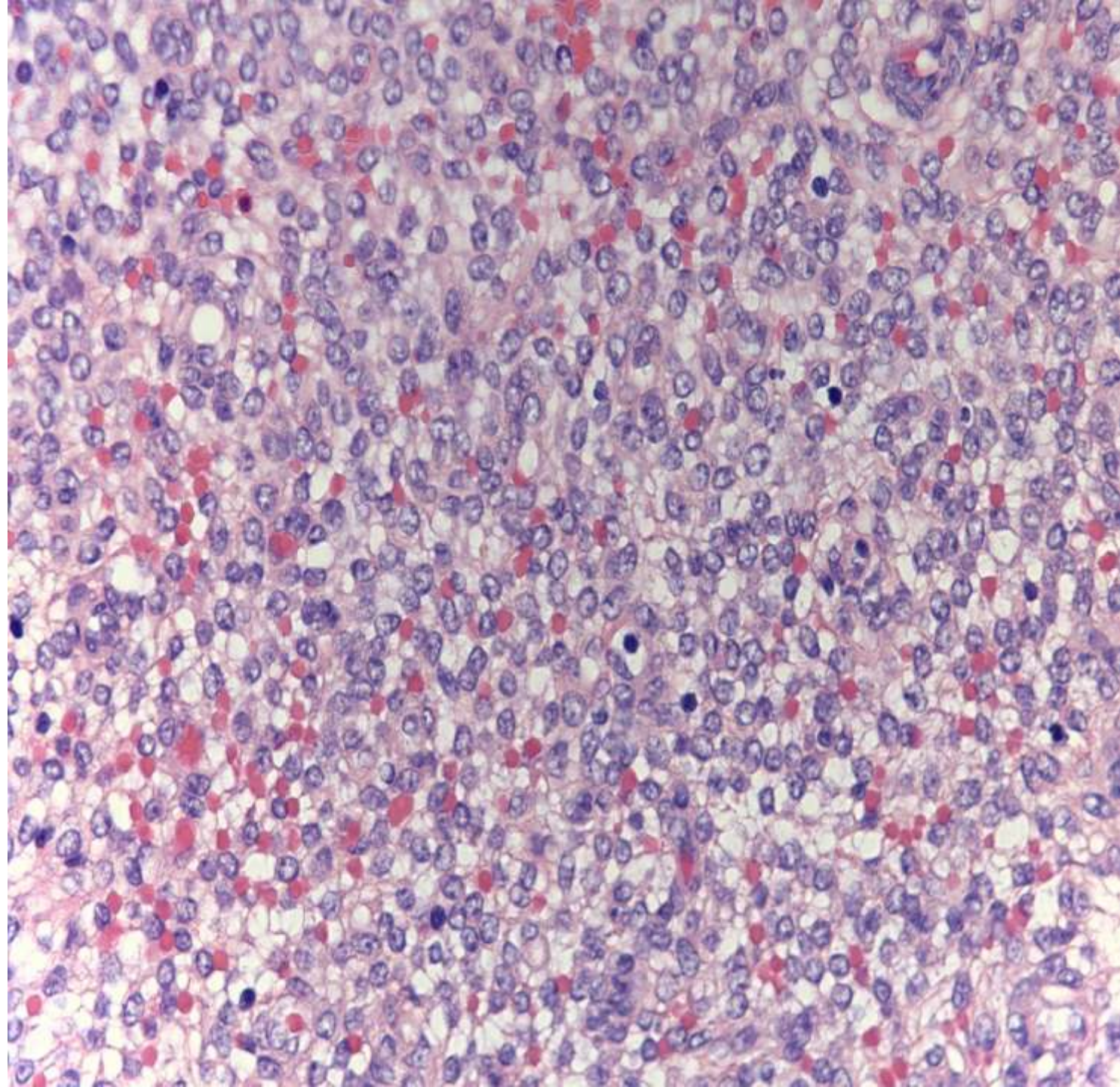


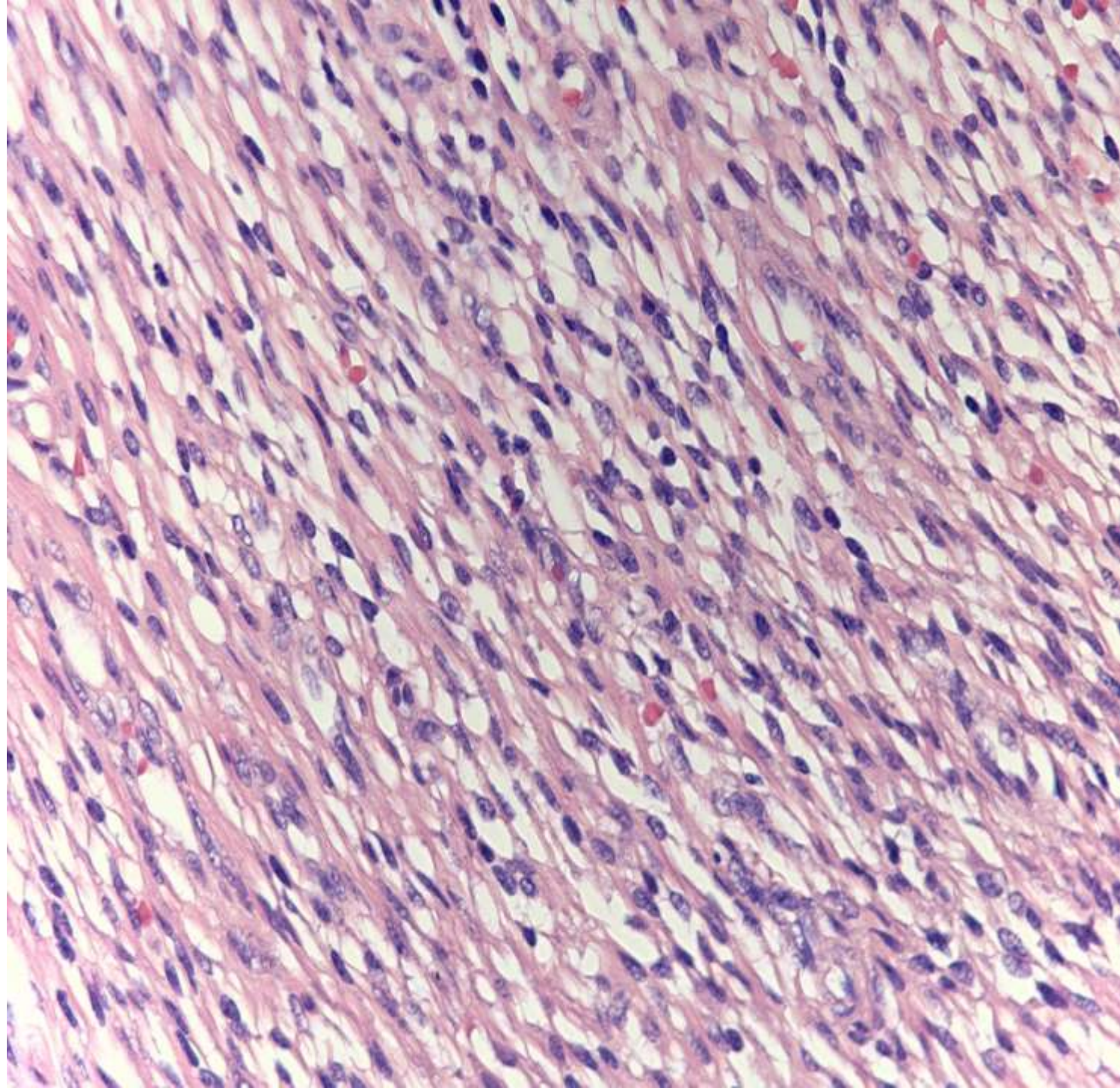










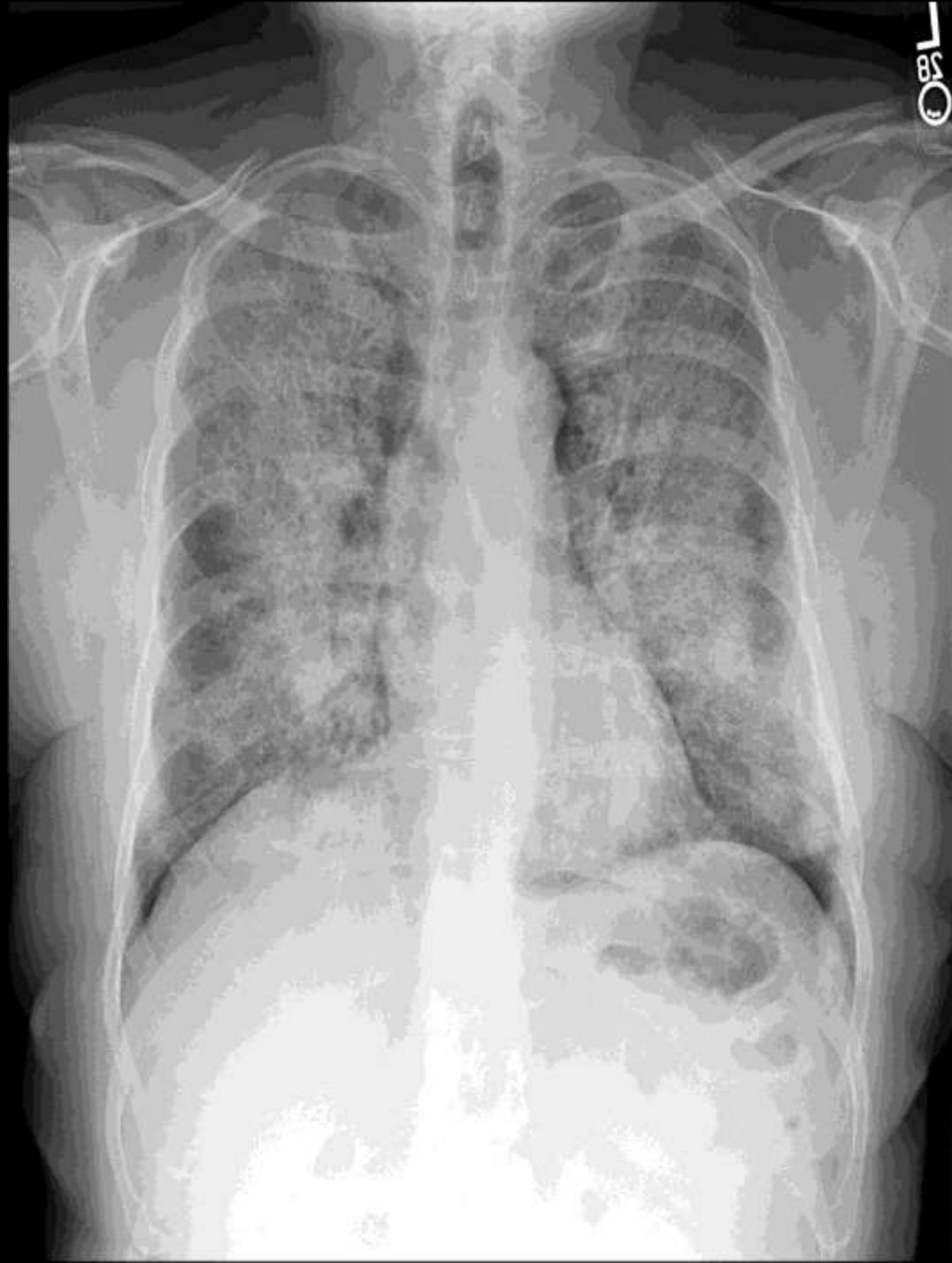

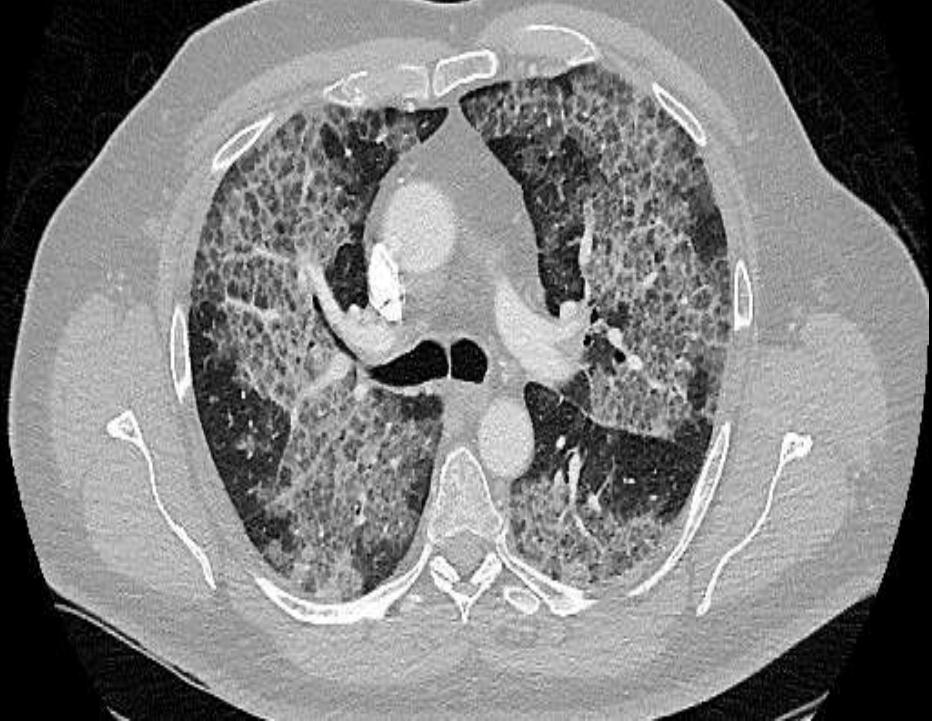
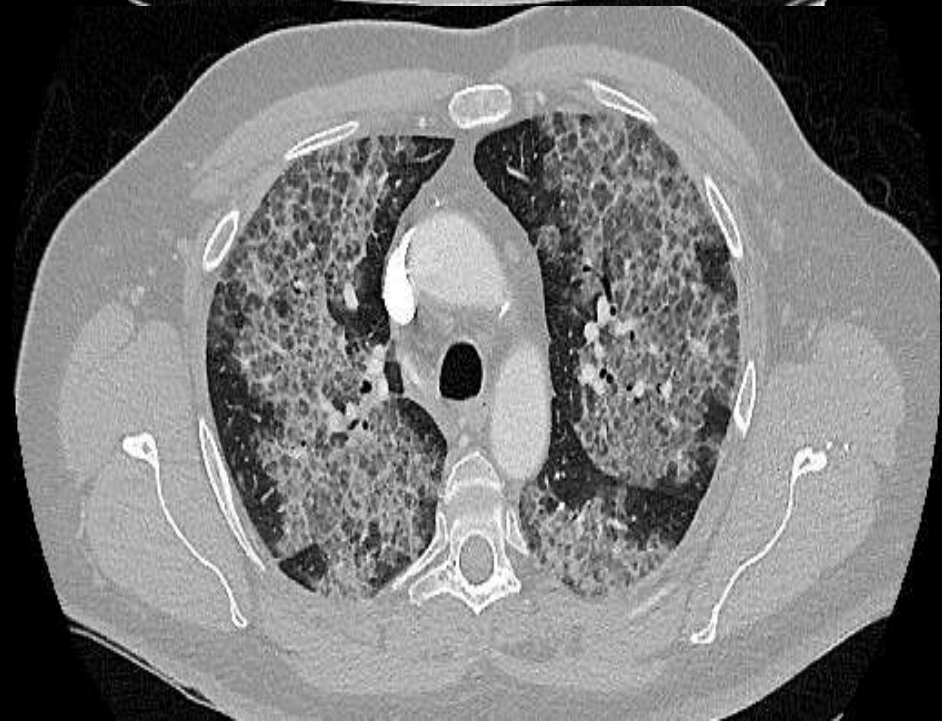
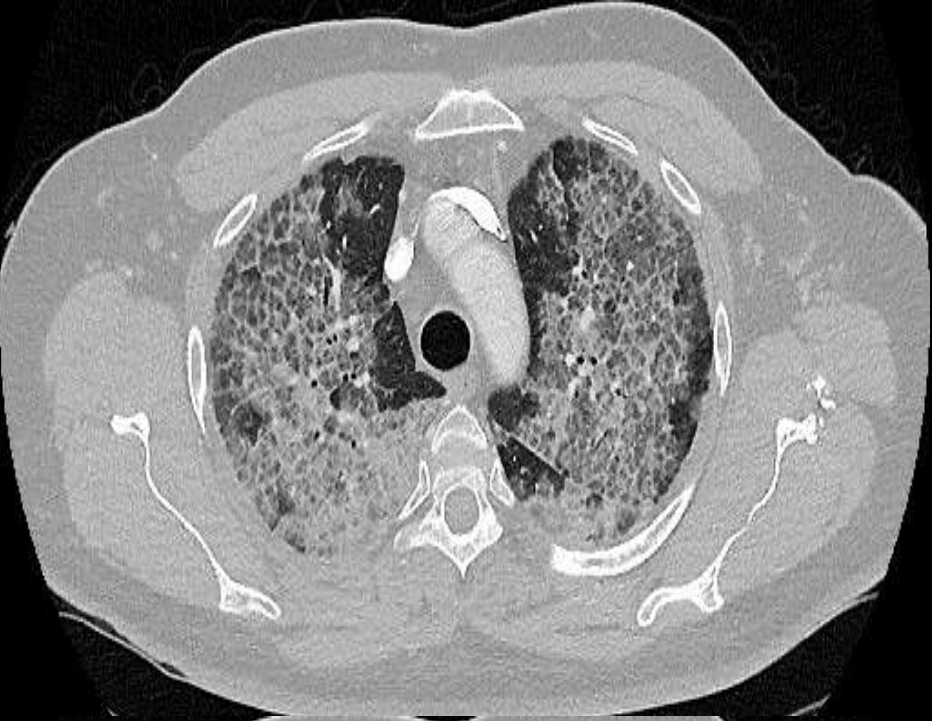
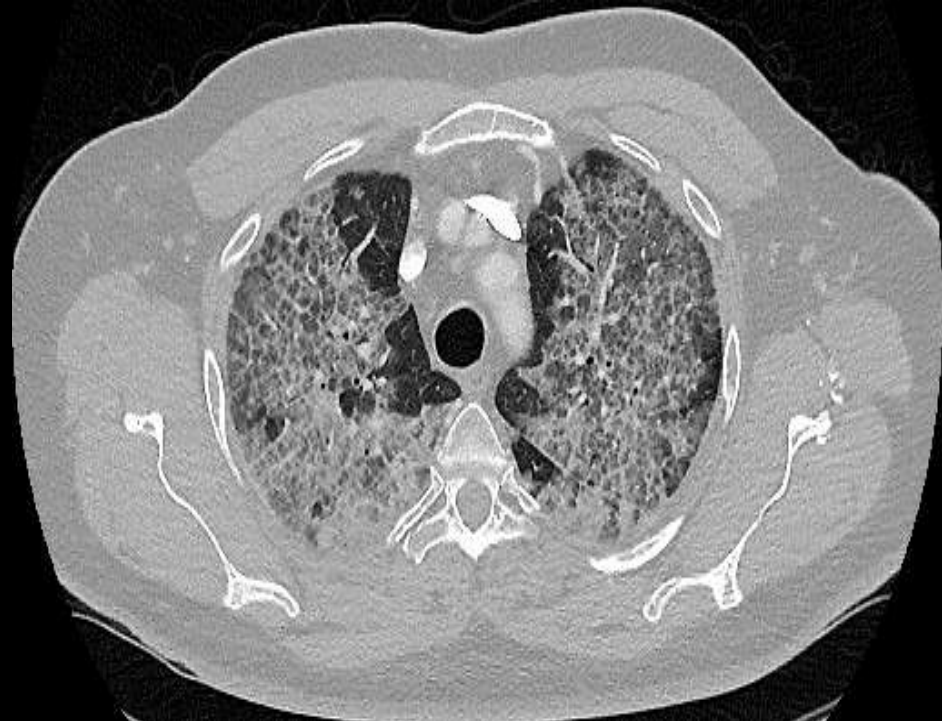


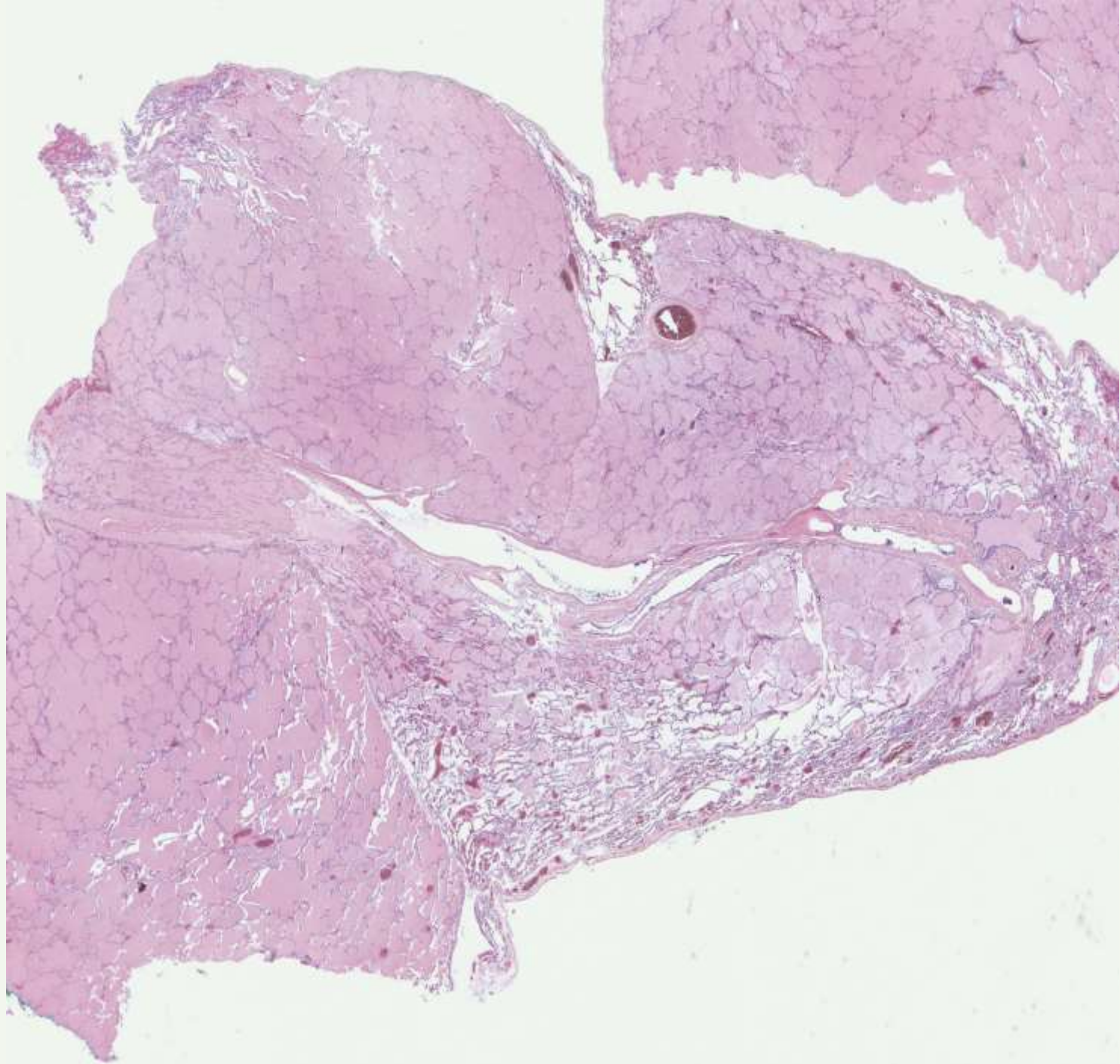
19-0808

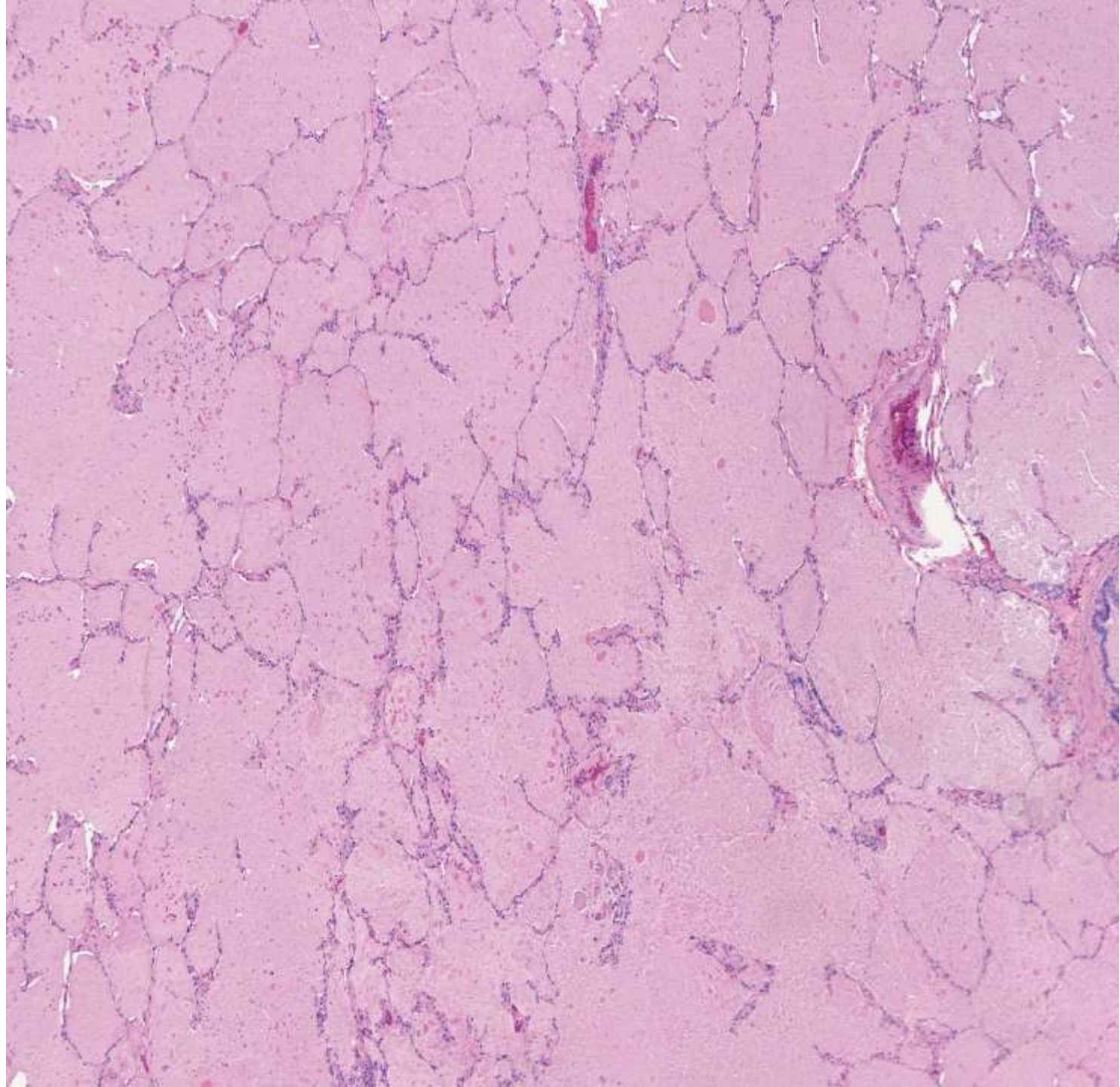
Kevin Kolahi/Kristin Jensen/Christine
Louie; VA Hospital Palo Alto

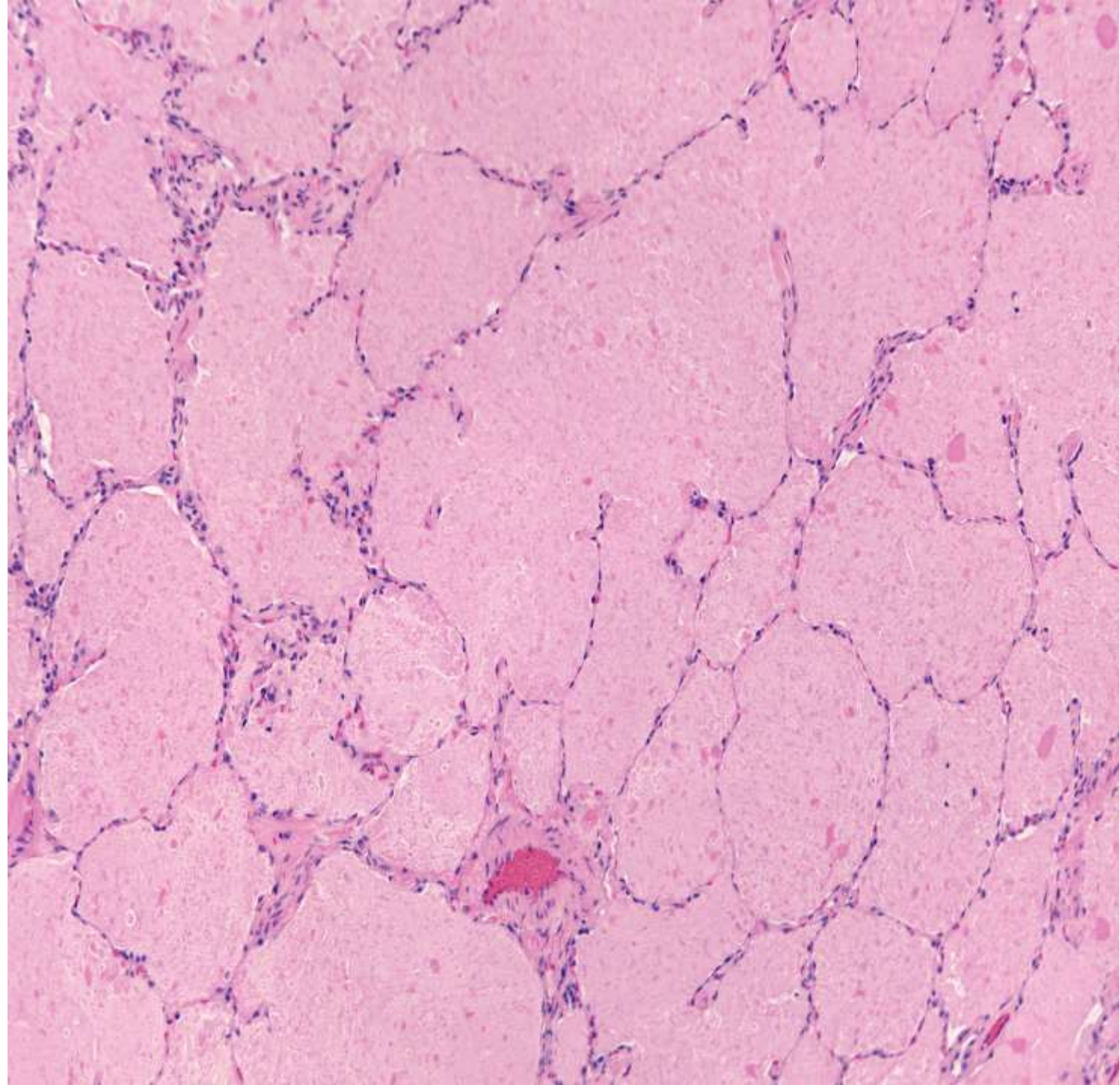
65-year-old with slowly progressive dyspnea on
exertion and bilateral lung opacities discovered on
chest CT.













19-0809

Romain Cayrol/Don Born; Stanford

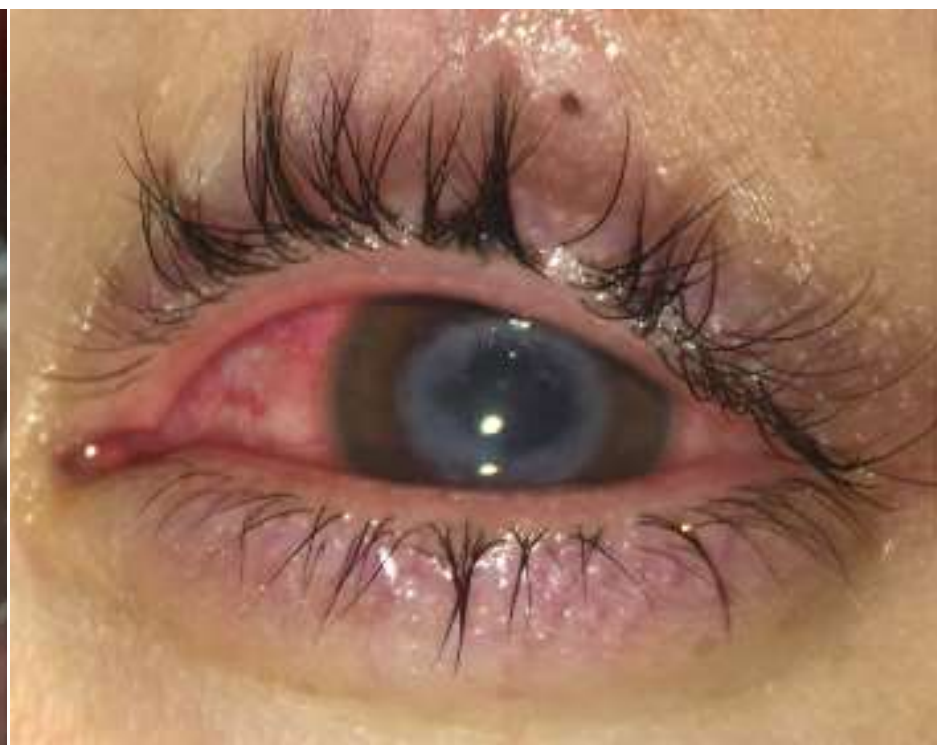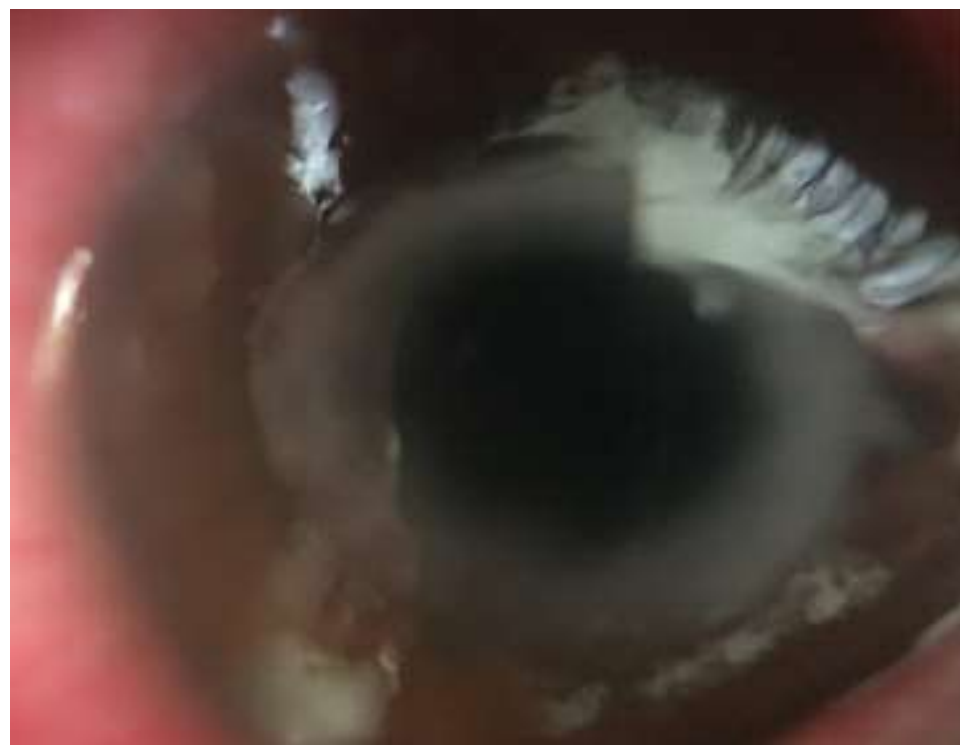25-year-old female presents with acute pain
and redness in left eye.

Clinical History

- 25-year-old female with acute (24-48h) worsening left eye pain, redness and discharge
- In January she developed pain and redness in her left eye, the clinical examination showed a Wessly immune ring
- The clinical diagnosis was herpes keratitis and she started Zylet (loteprednol/tobramycin), difluprednate, topical ganciclovir, besifloxacin, fluoromethalone and valacyclovir
- The symptoms improved at the time, no cultures were taken
- Worked on a farm from November through February
 - Chickens, pigs, goats, one alpaca, and in close proximity to the farm's well system
- She wears glasses and used to wear rigid gas permeable lenses, but stopped wearing them in December due to irritation

Clinical Examination

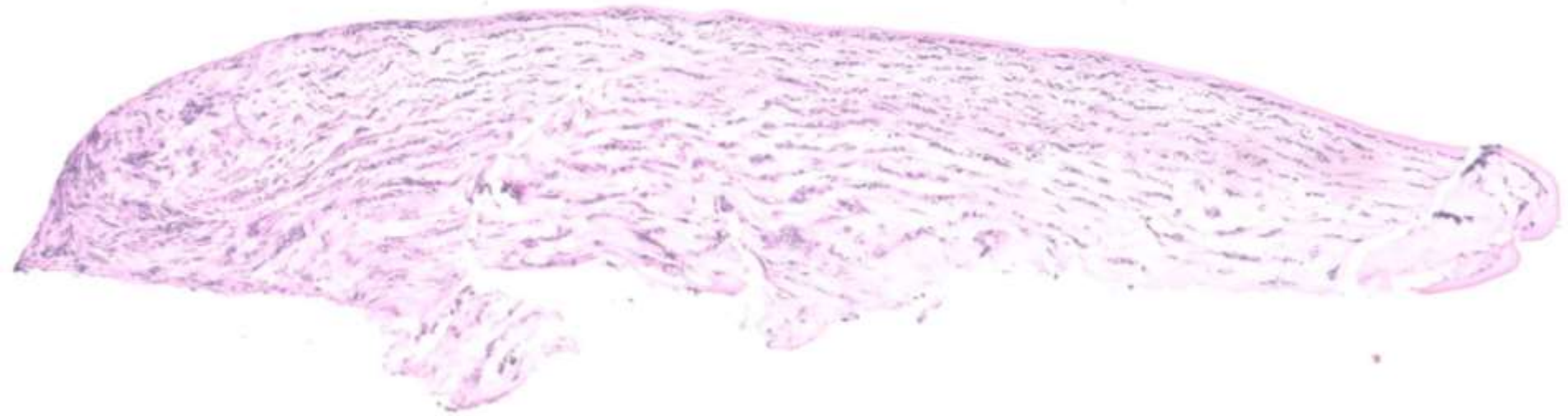
- Corneal haze, small epithelial ulcerations, anterior corneal stroma white ring infiltrate

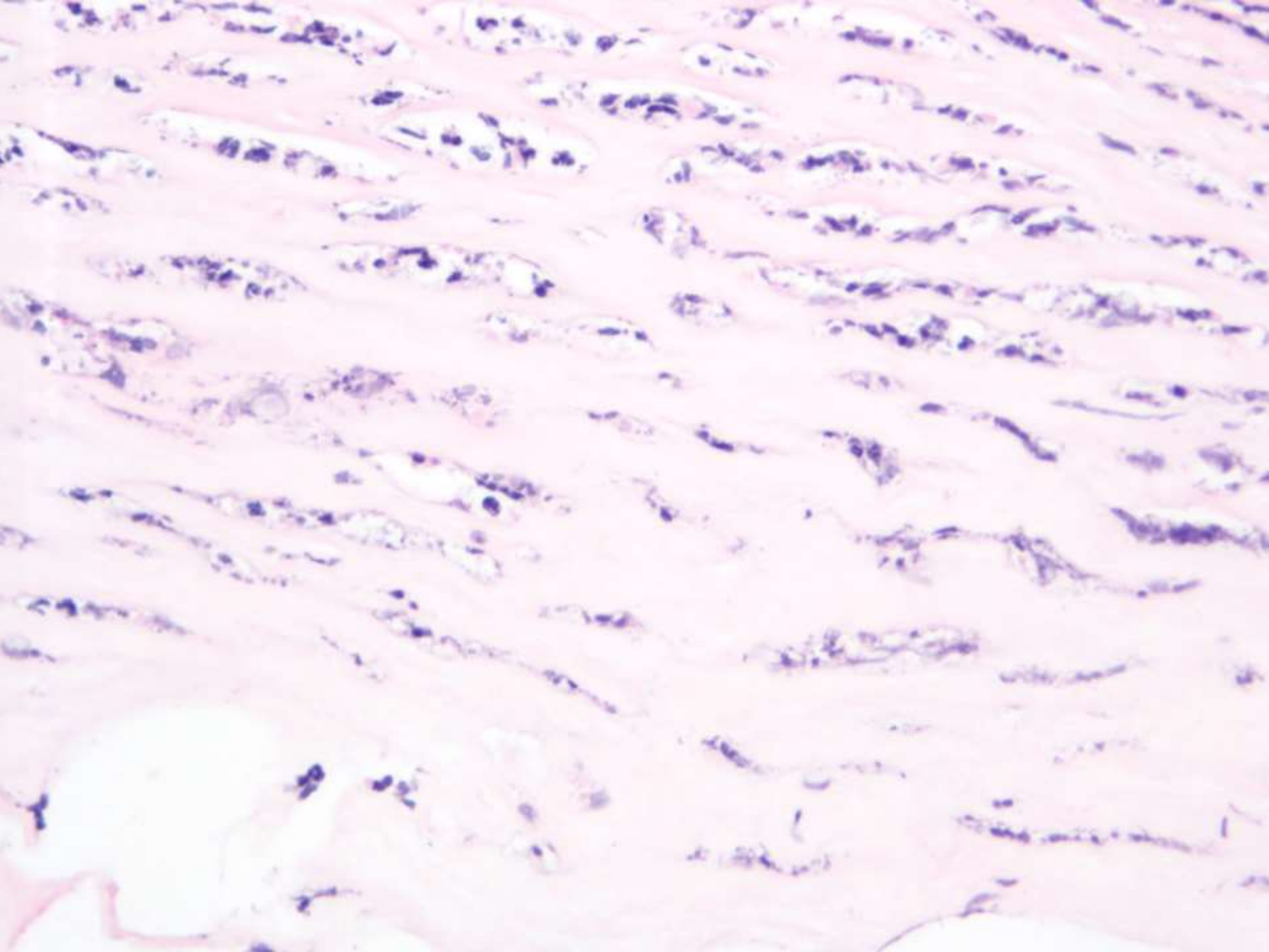


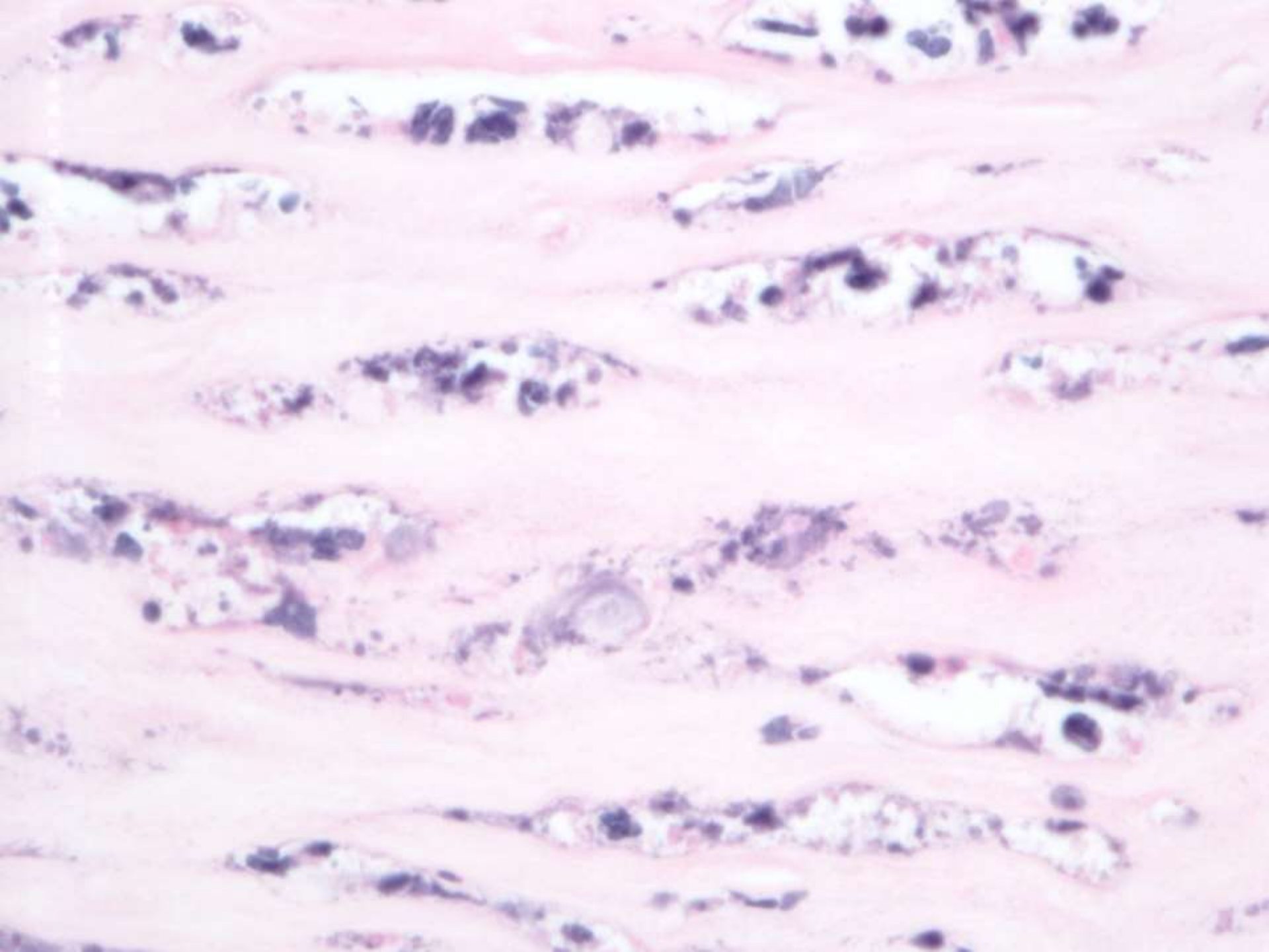
Gross Description

- A. EYE, LEFT CORNEA, BIOPSY
 - 0.2 x 0.1 x 0.1 cm pale white fragment

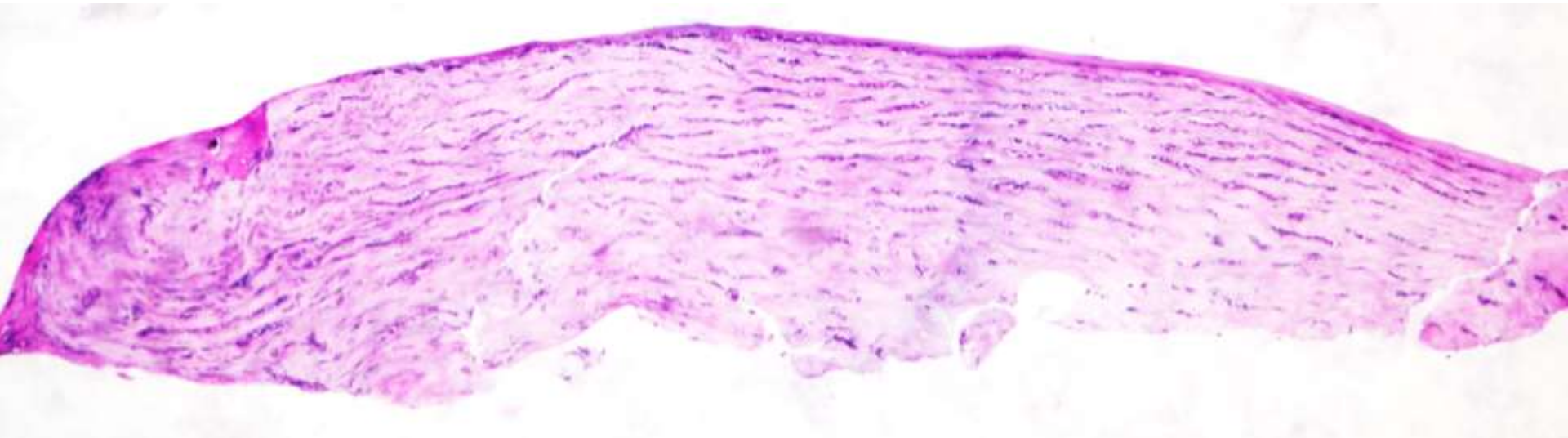
H&E

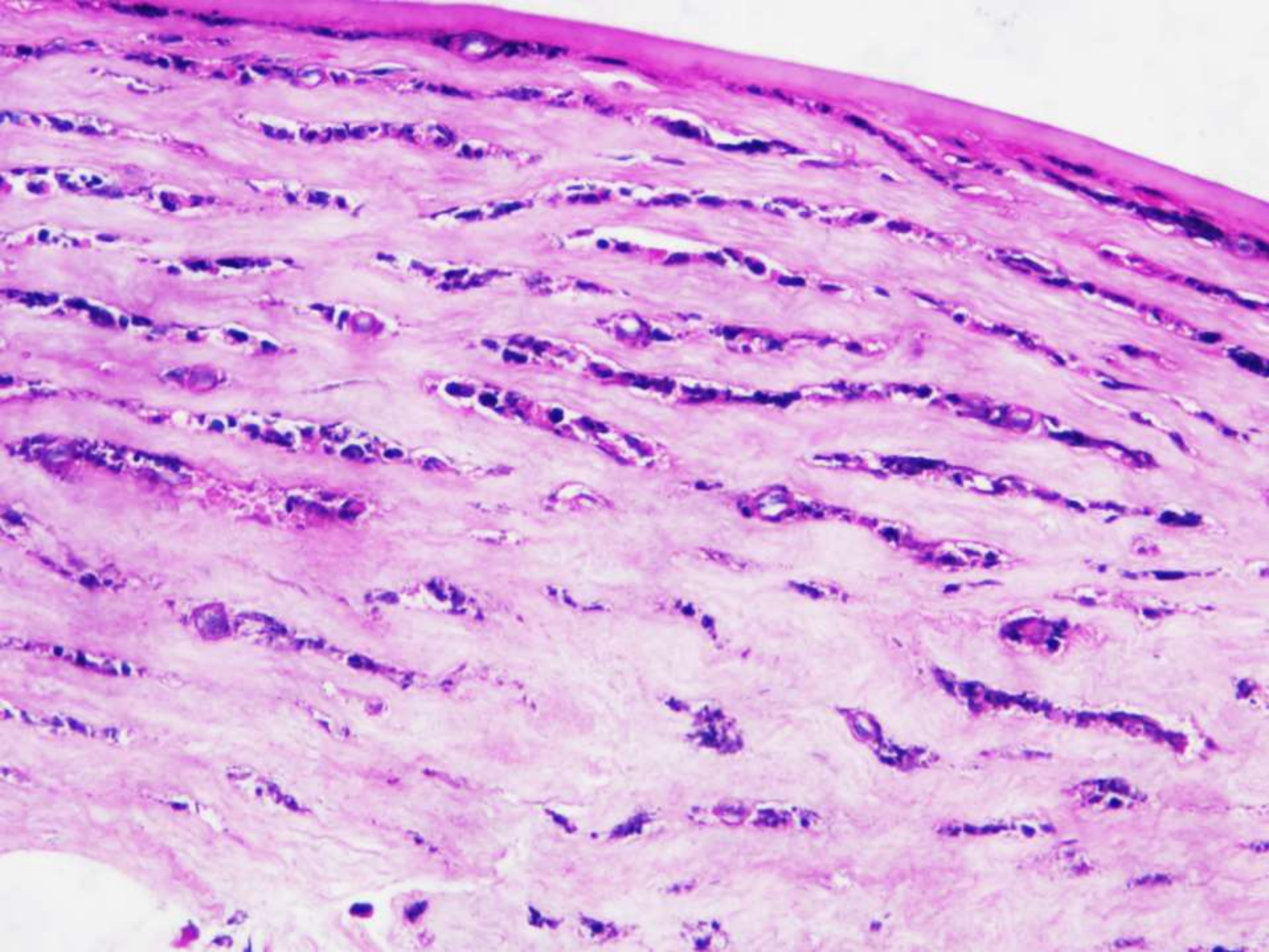


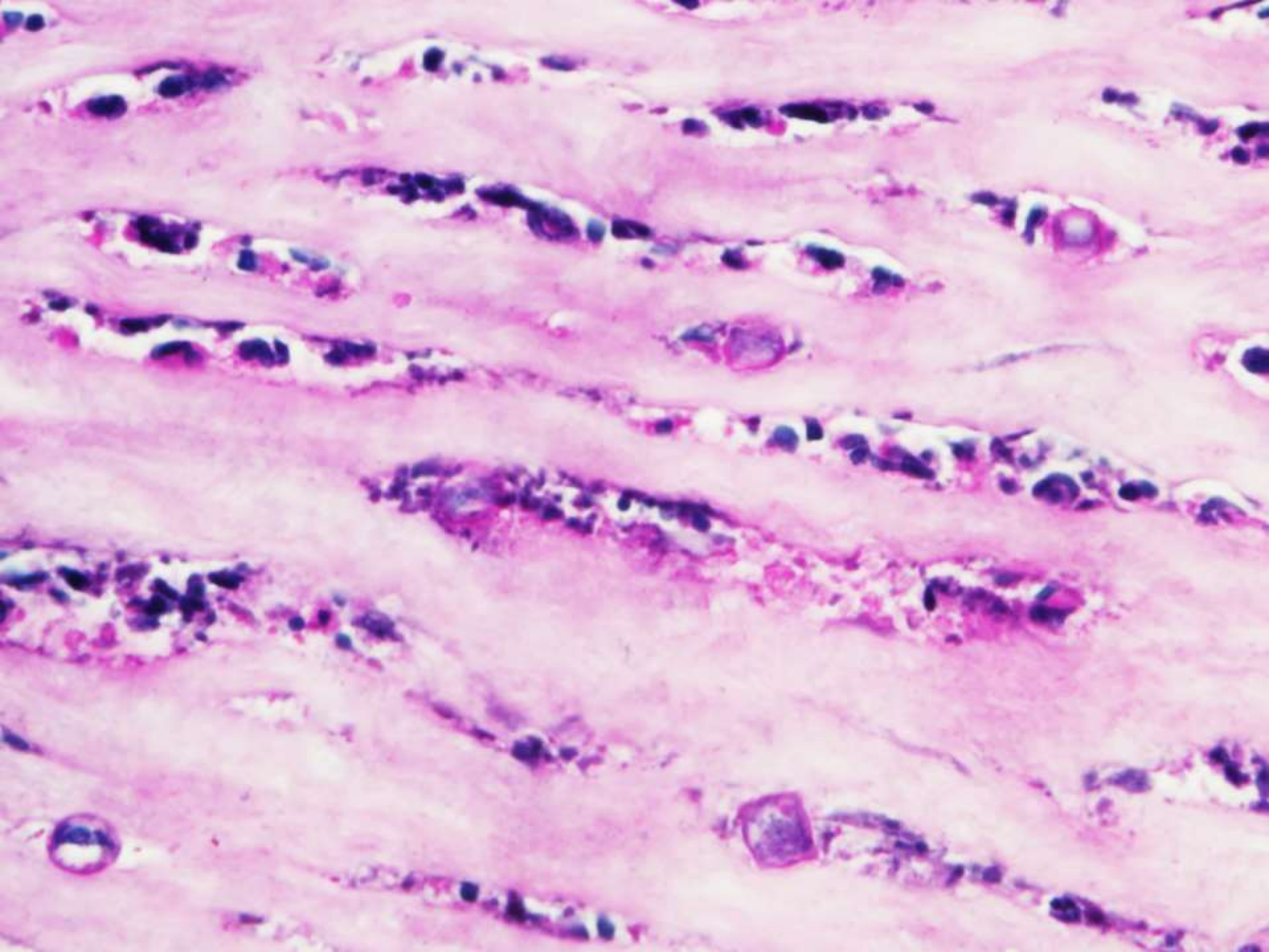





PASD








GMS









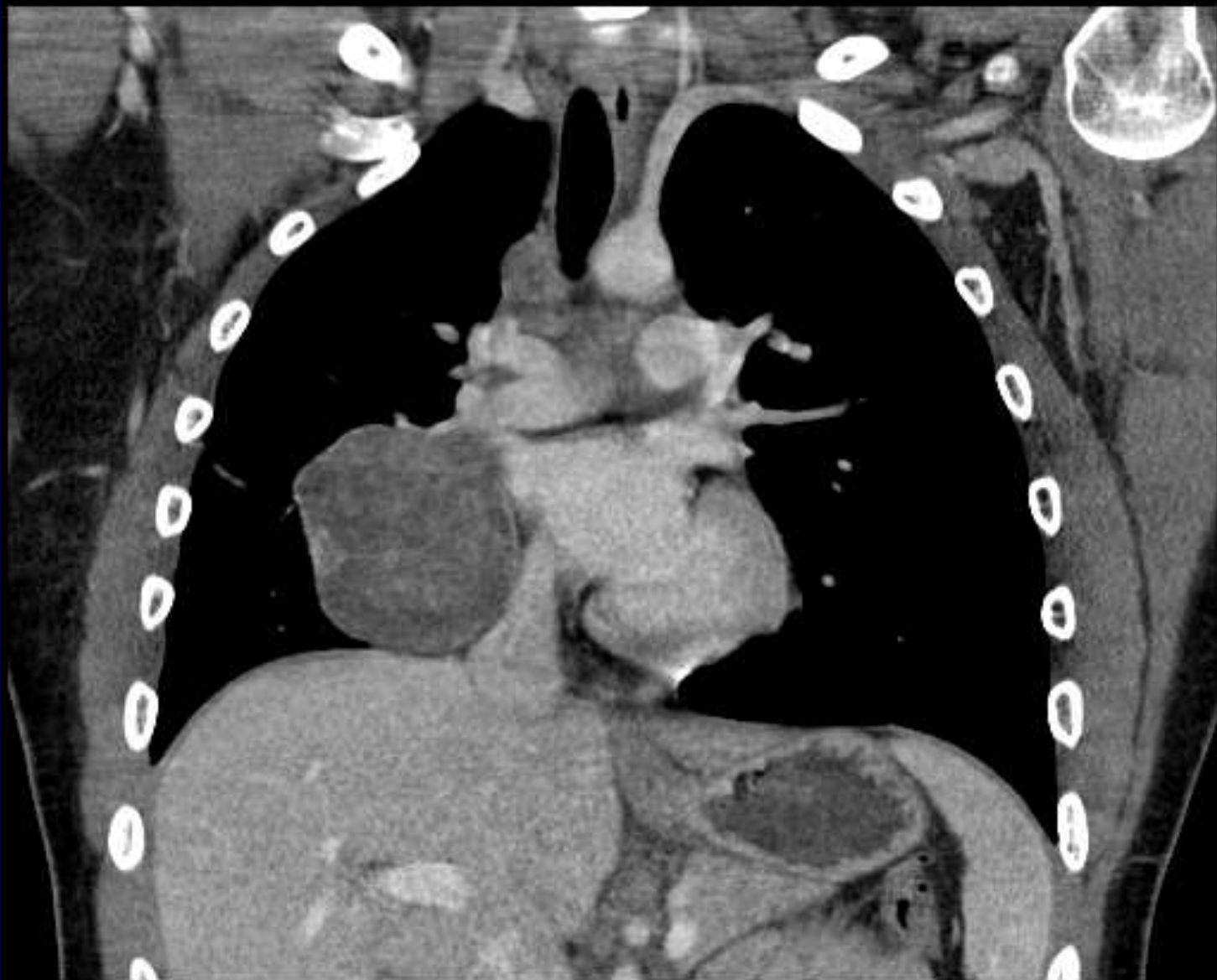
19-0810

Liping Song; Kaiser Permanente Oakland Medical Center

16-year-old female with a history of mild asthma, evaluated for abnormal chest imaging for cough, chest discomfort, and SOB.. She is from California but lived in Arizona for 1.5 years. Chest X-ray showed right lung mass. CT showed 6.3cm right lung mass with large subcarinal adenopathy. Clinically concern for Coccidioides infection, she was started on fluconazole. Over the past week she has continued to have chest discomfort and required norco administration.

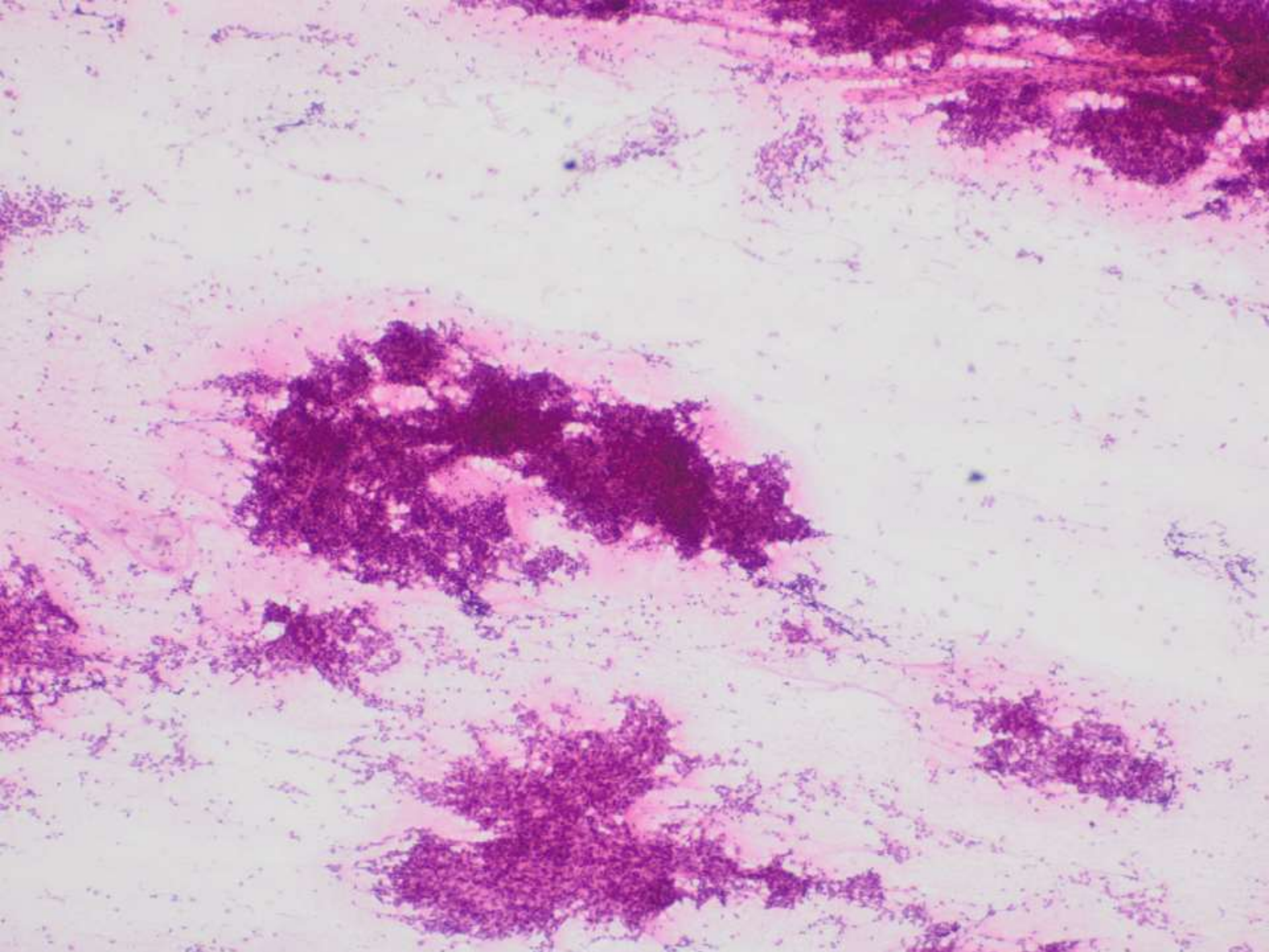
After hour frozen call

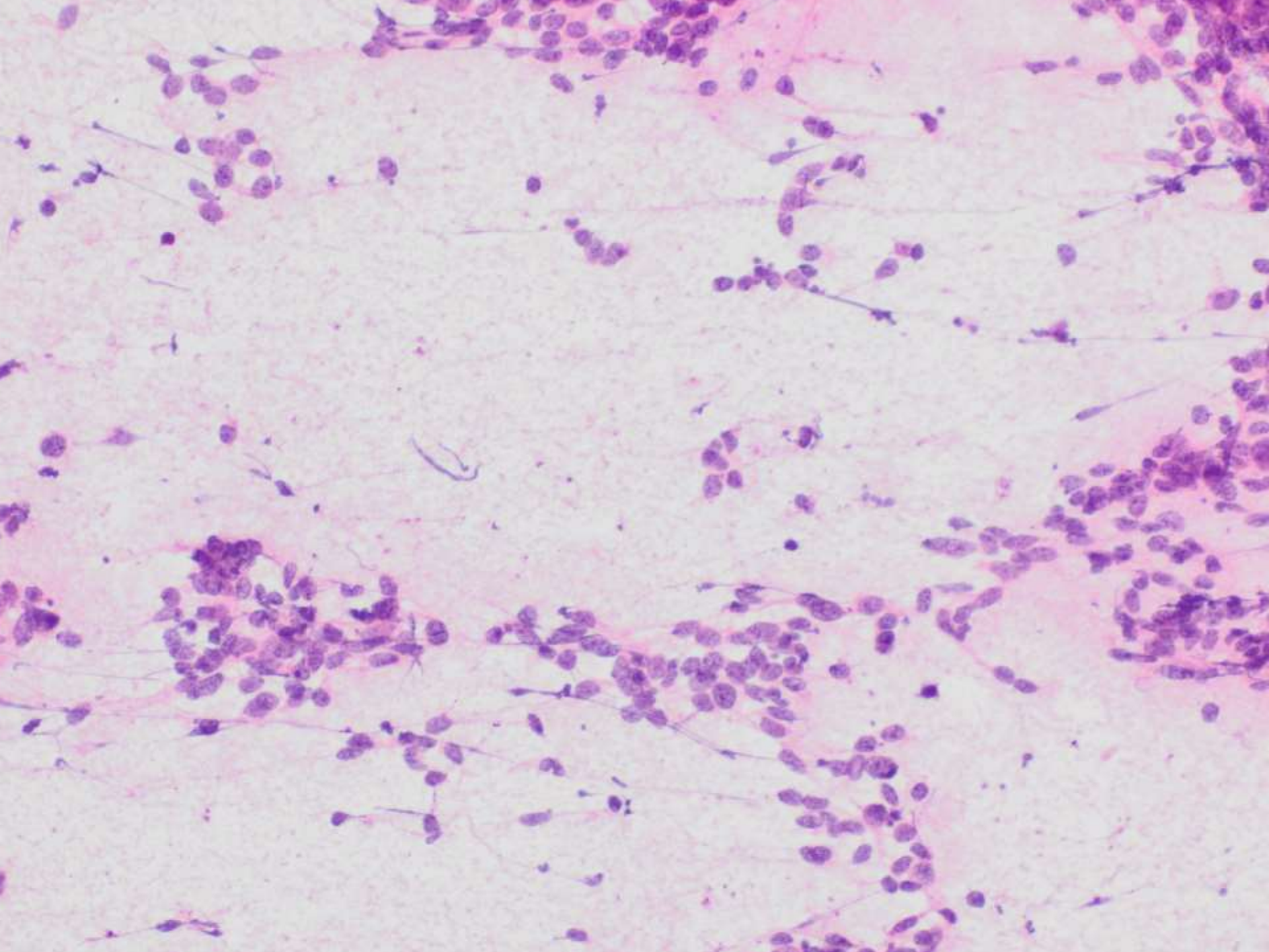
16 year old girl clinically concern for coccidioides infection (lived in Arizona for 1.5 years). she was started on fluconazole. Over the past week she has continued to have chest discomfort and is requiring norco administration

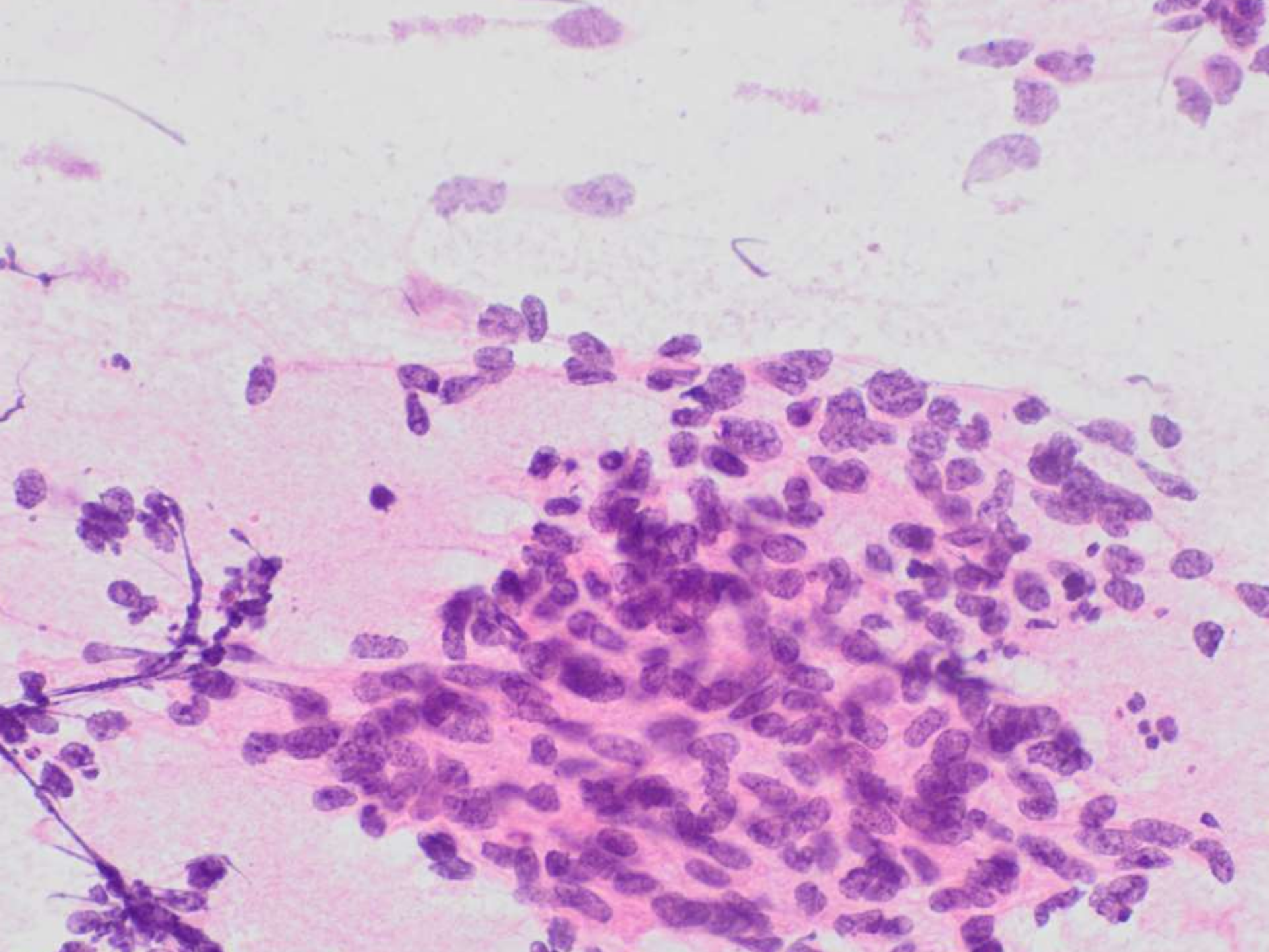


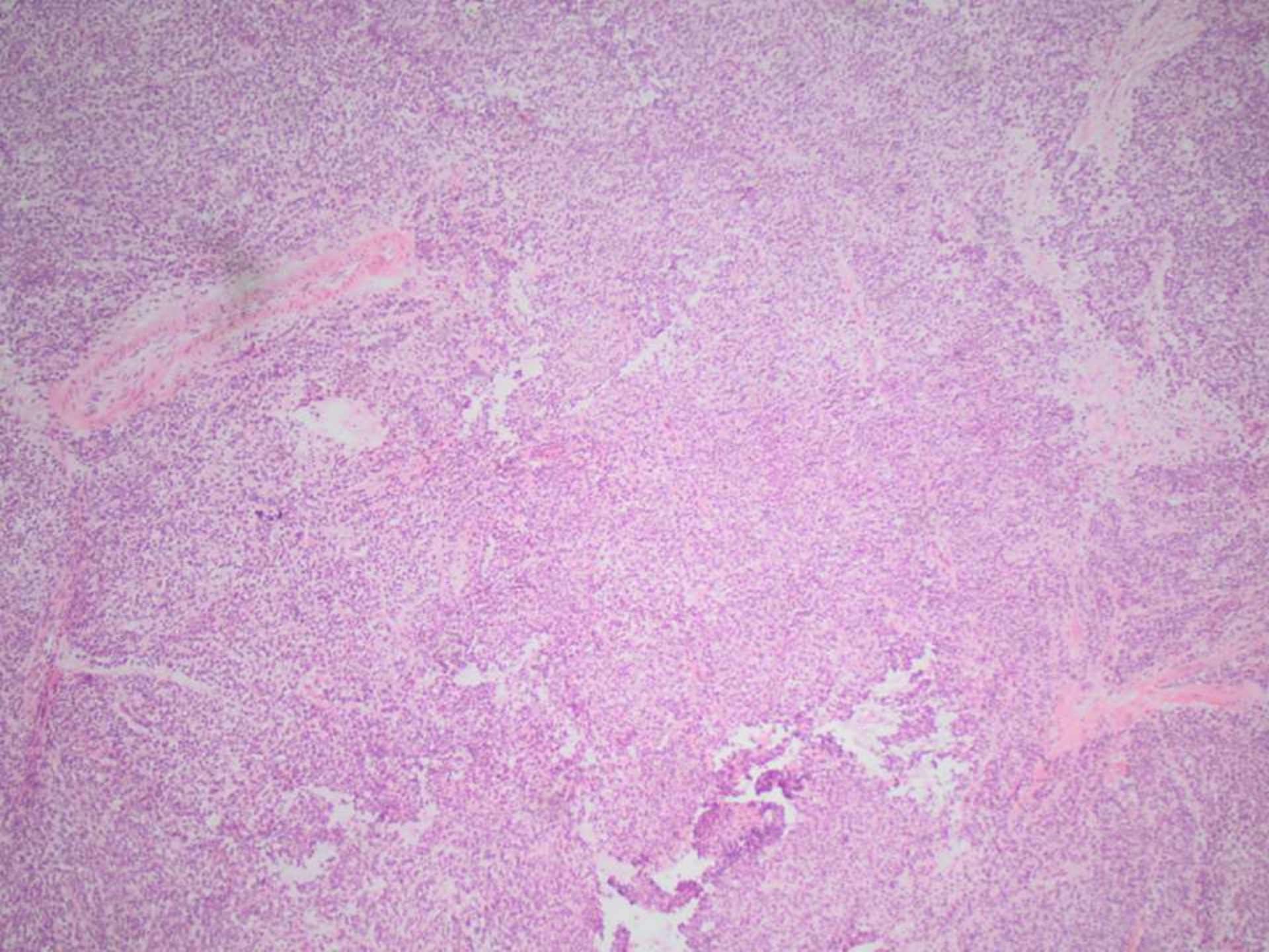
CT report

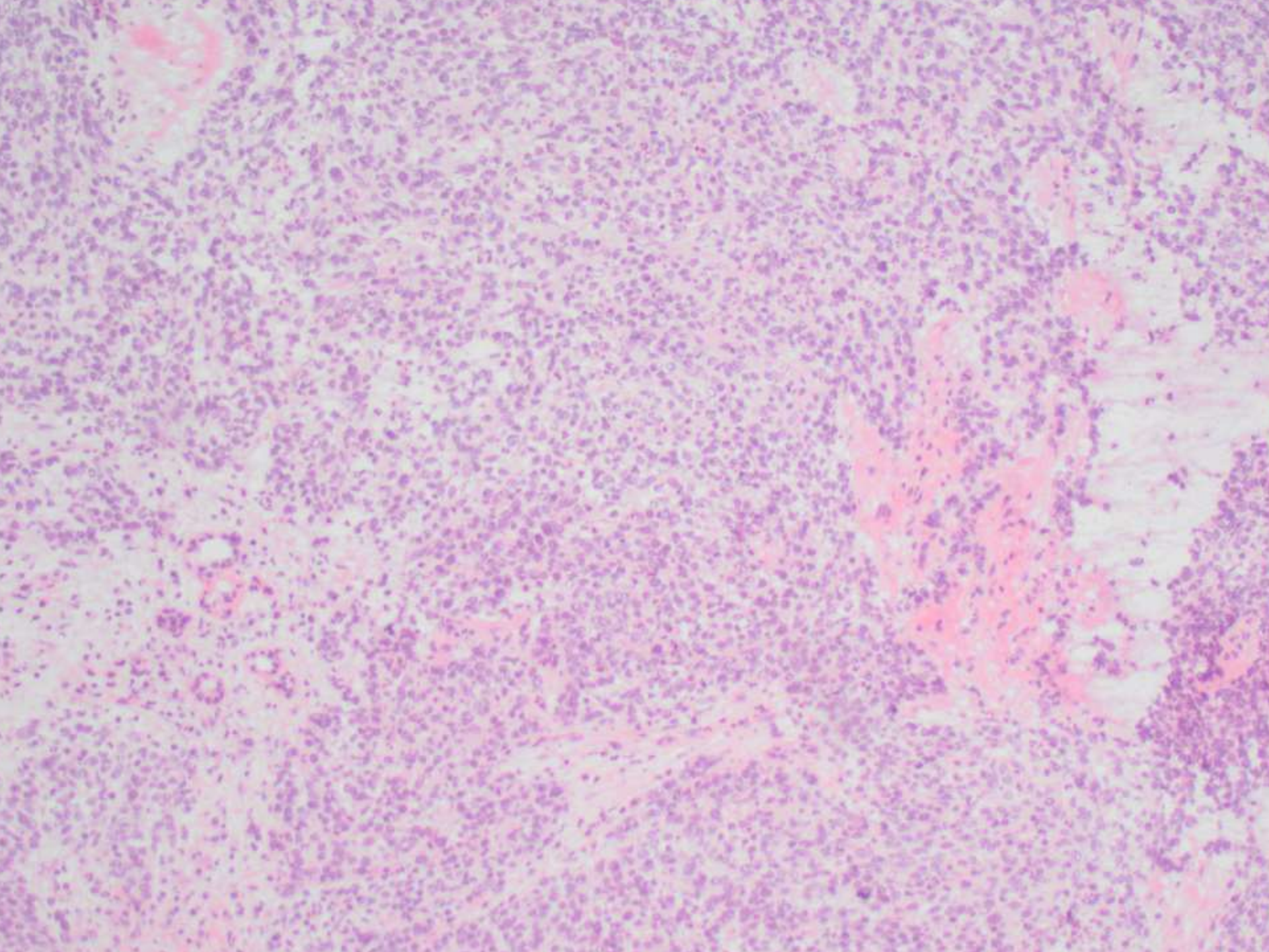
- 11/19/18 CT Large (6.3 cm) masslike right infrahilar lung consolidation with mediastinal adenopathy, including large subcarinal adenopathy. There is obstruction of the right middle lobe bronchus with some right middle lobe consolidation, likely post compressive atelectasis. Given the predominantly hypodense appearance, an **atypical infectious process** (i.e. coccidiomycosis though TB or other atypical infections can also be considered) is favored. A true neoplastic mass seems less likely, though is difficult to exclude. Possibly infectious or inflammatory pulmonary nodule(s).

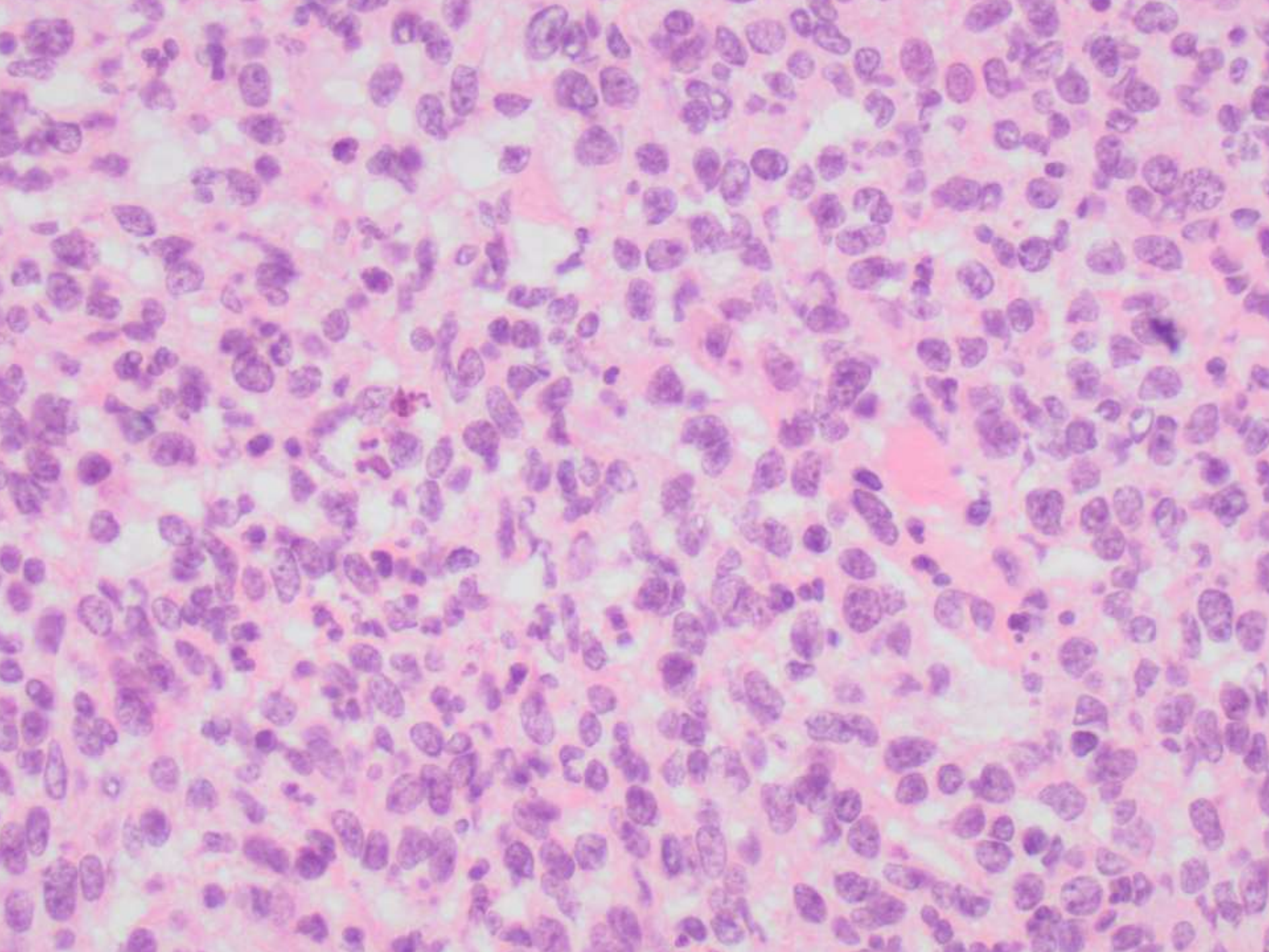












PERMANENT

