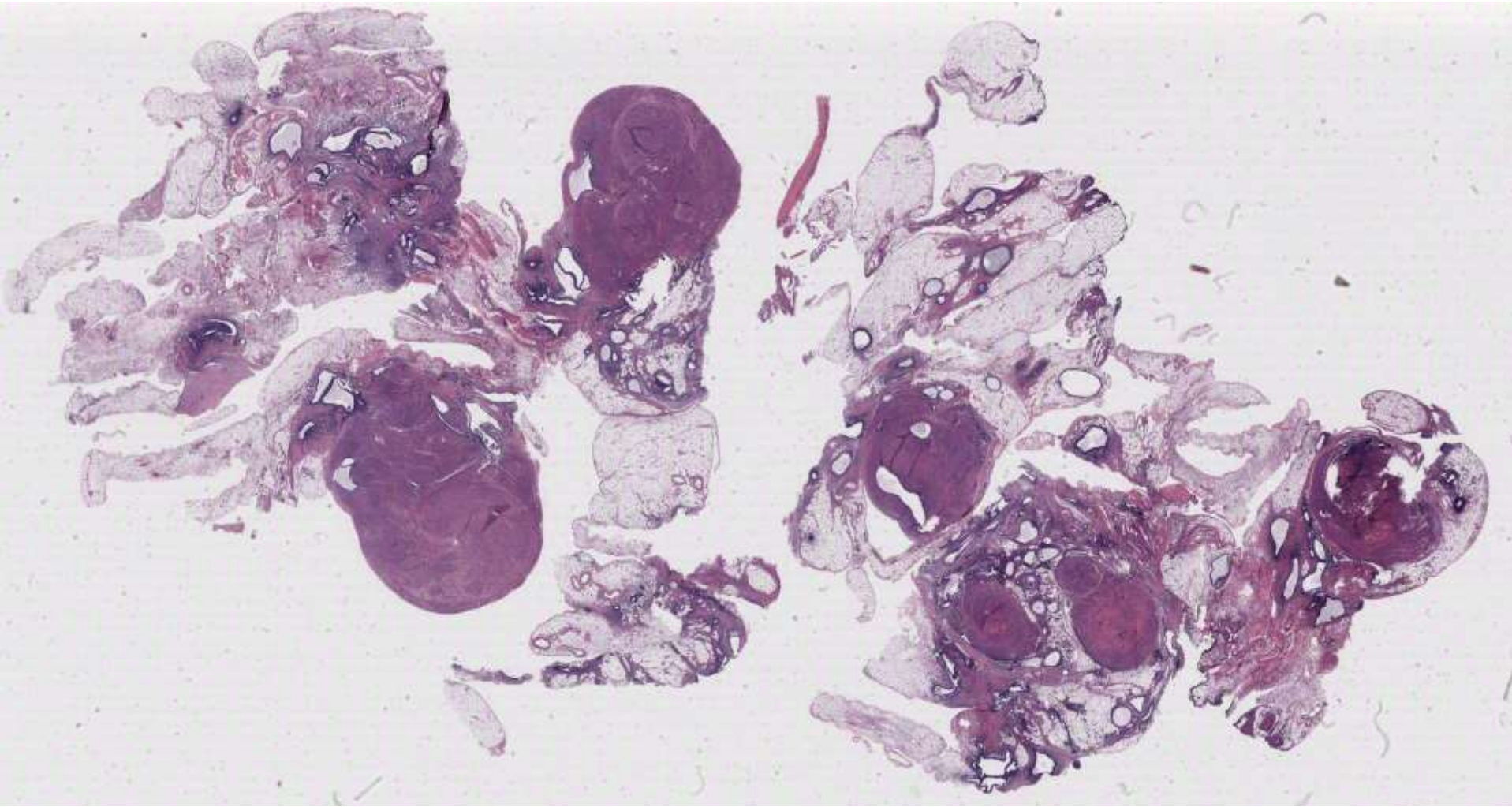


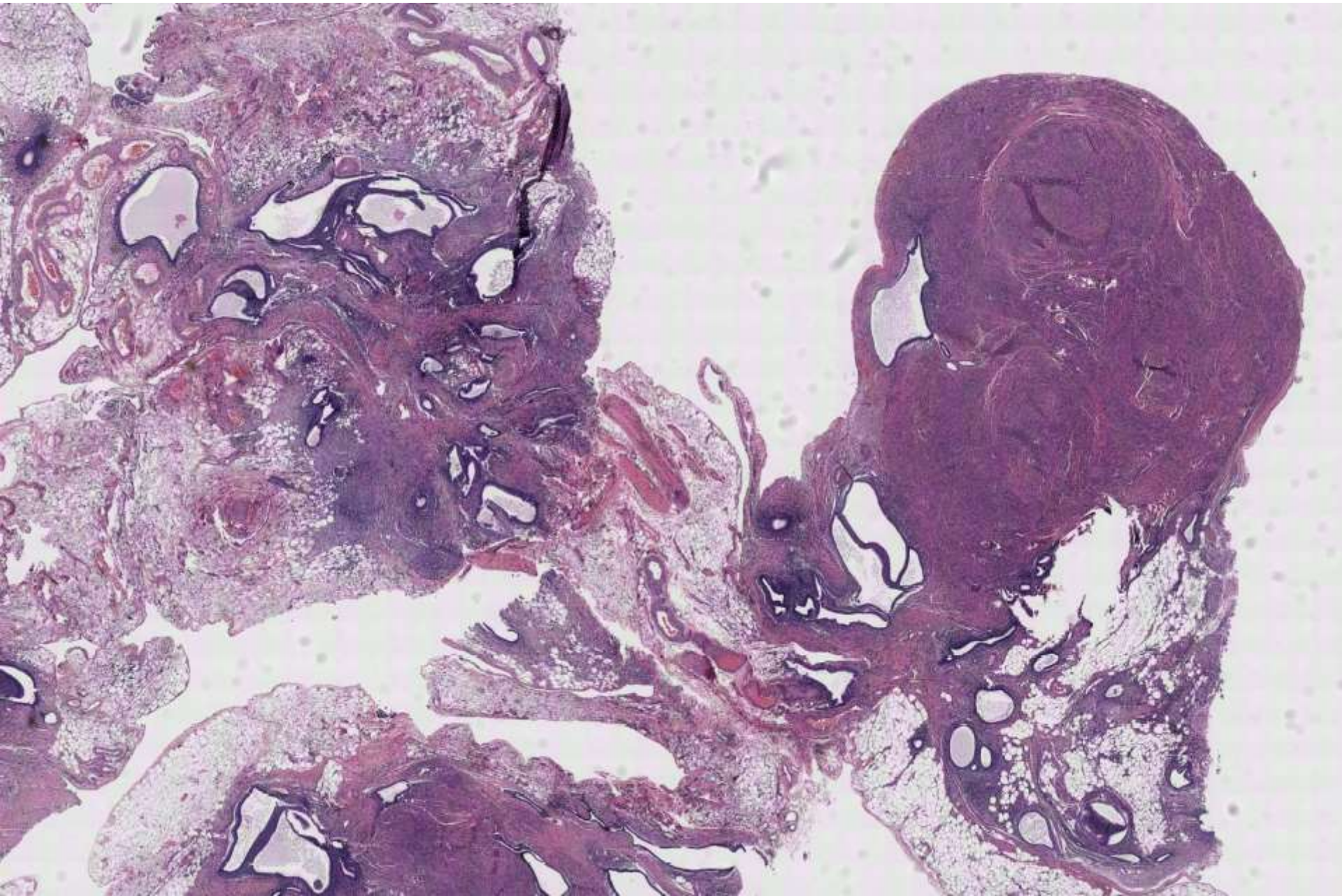
# 19-0701

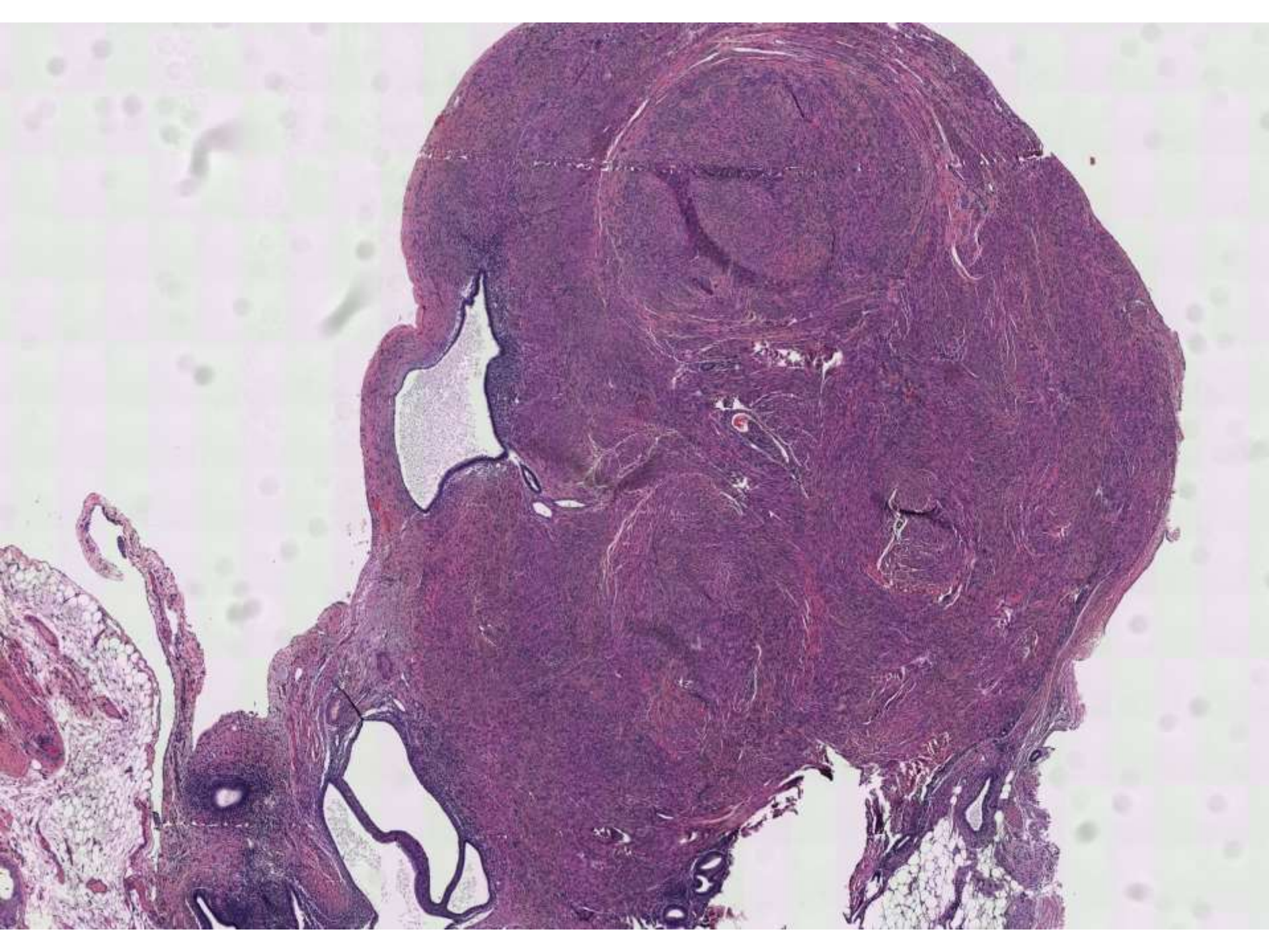
(scanned slide avail)

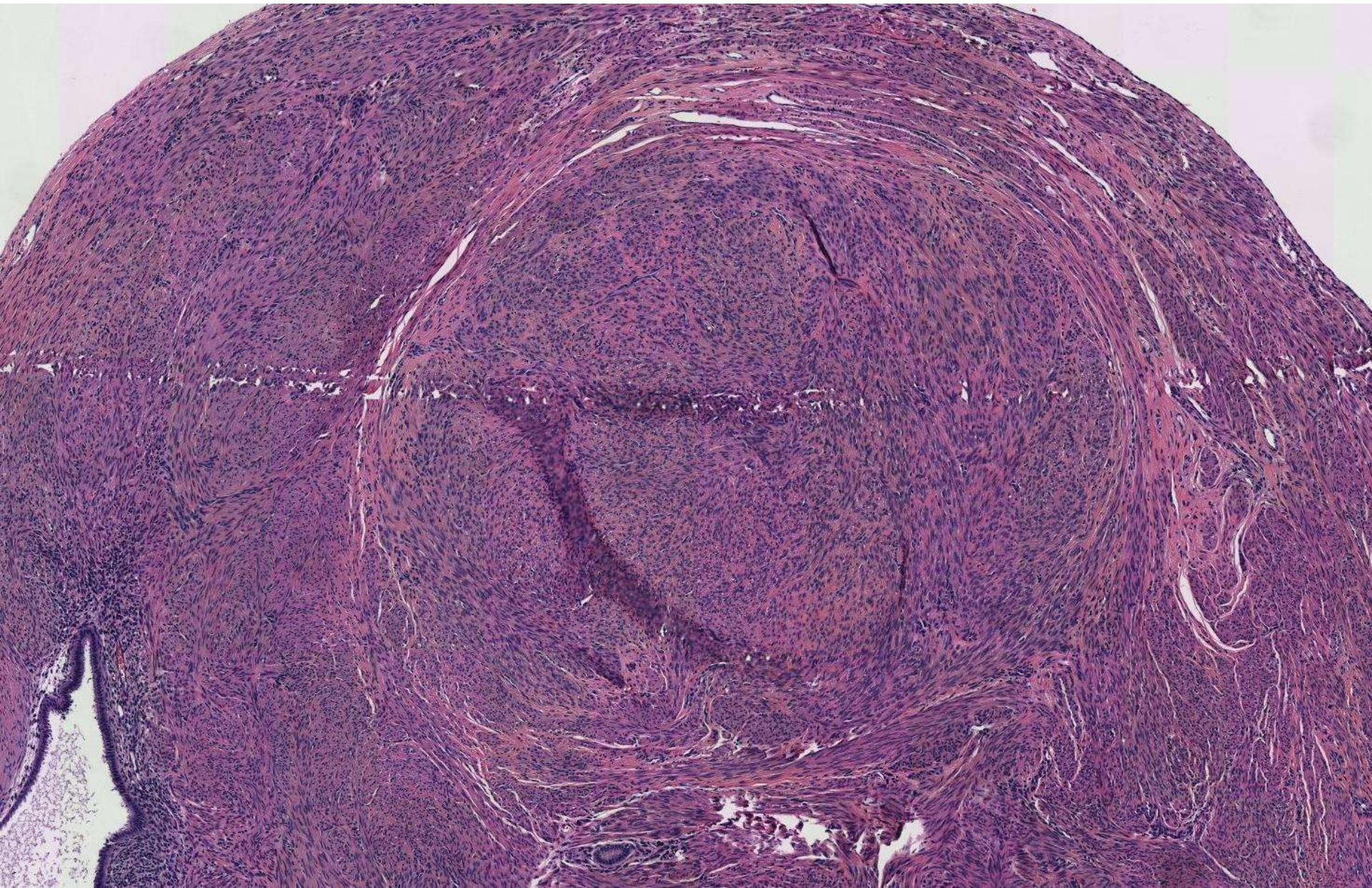
**Mahendra Ranchod; Good  
Samaritan Hospital**

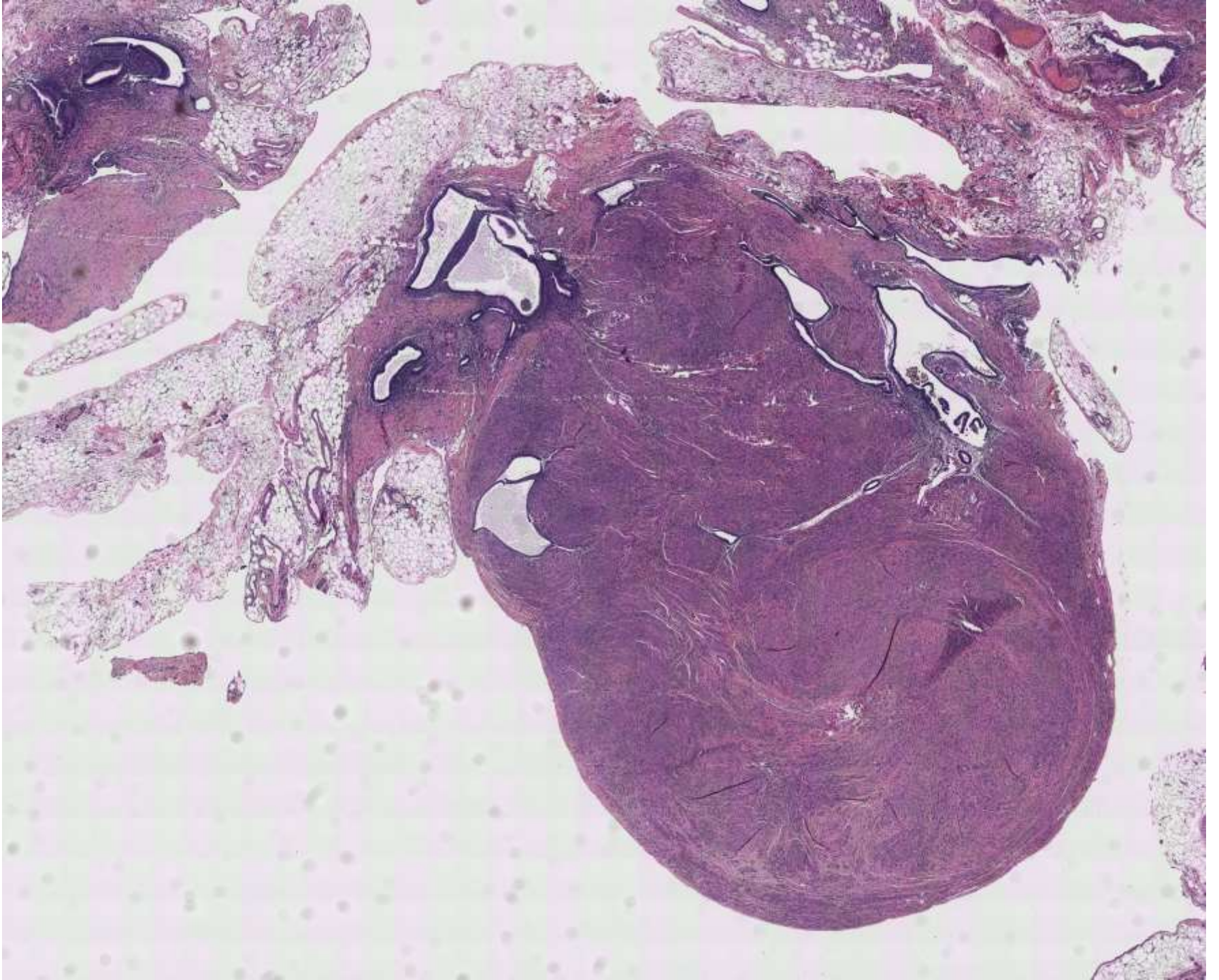
37-year-old woman with endometriosis was found to have 3 firm nodules in the omentum, largest 8mm in maximum dimension.

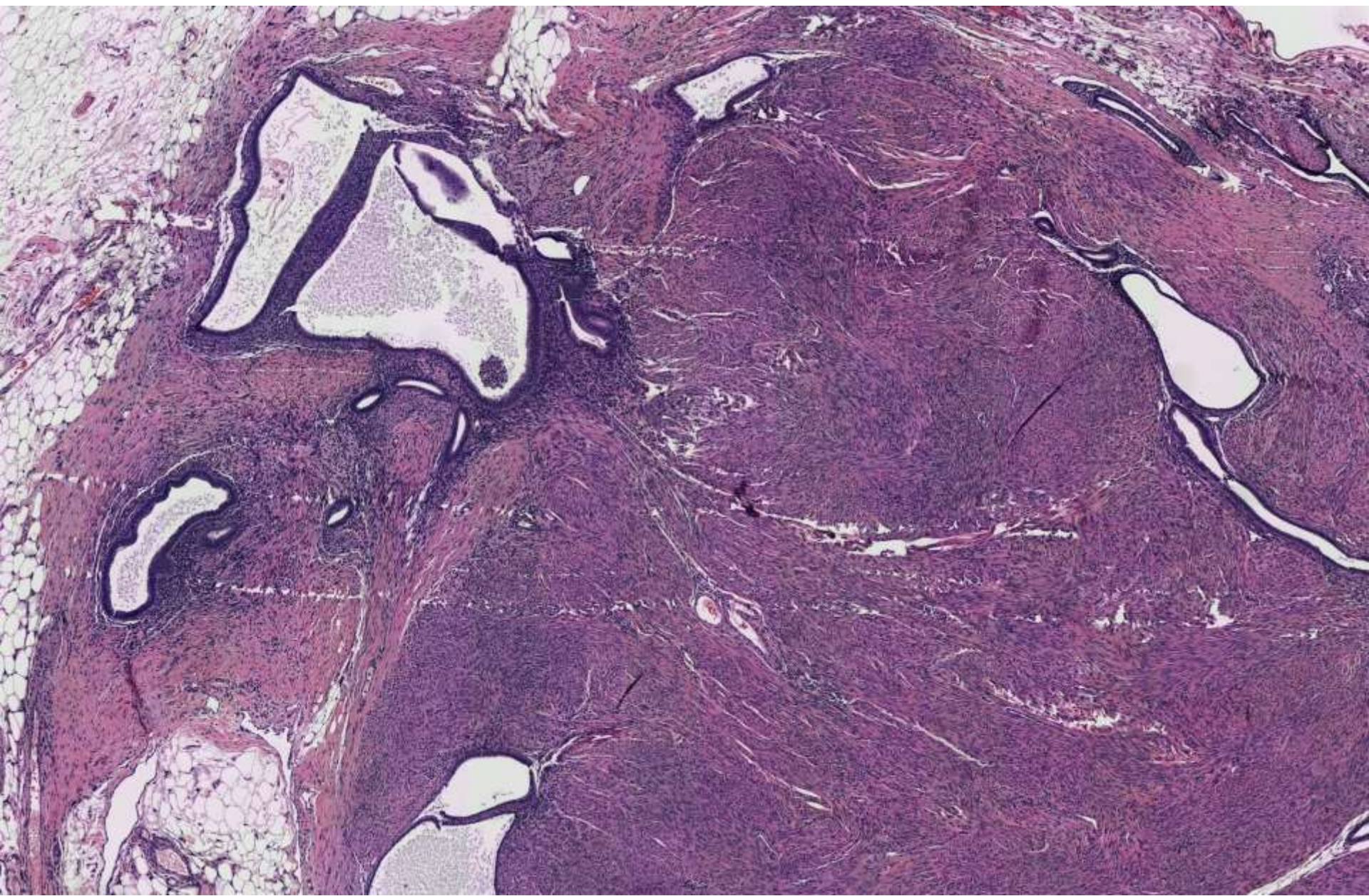


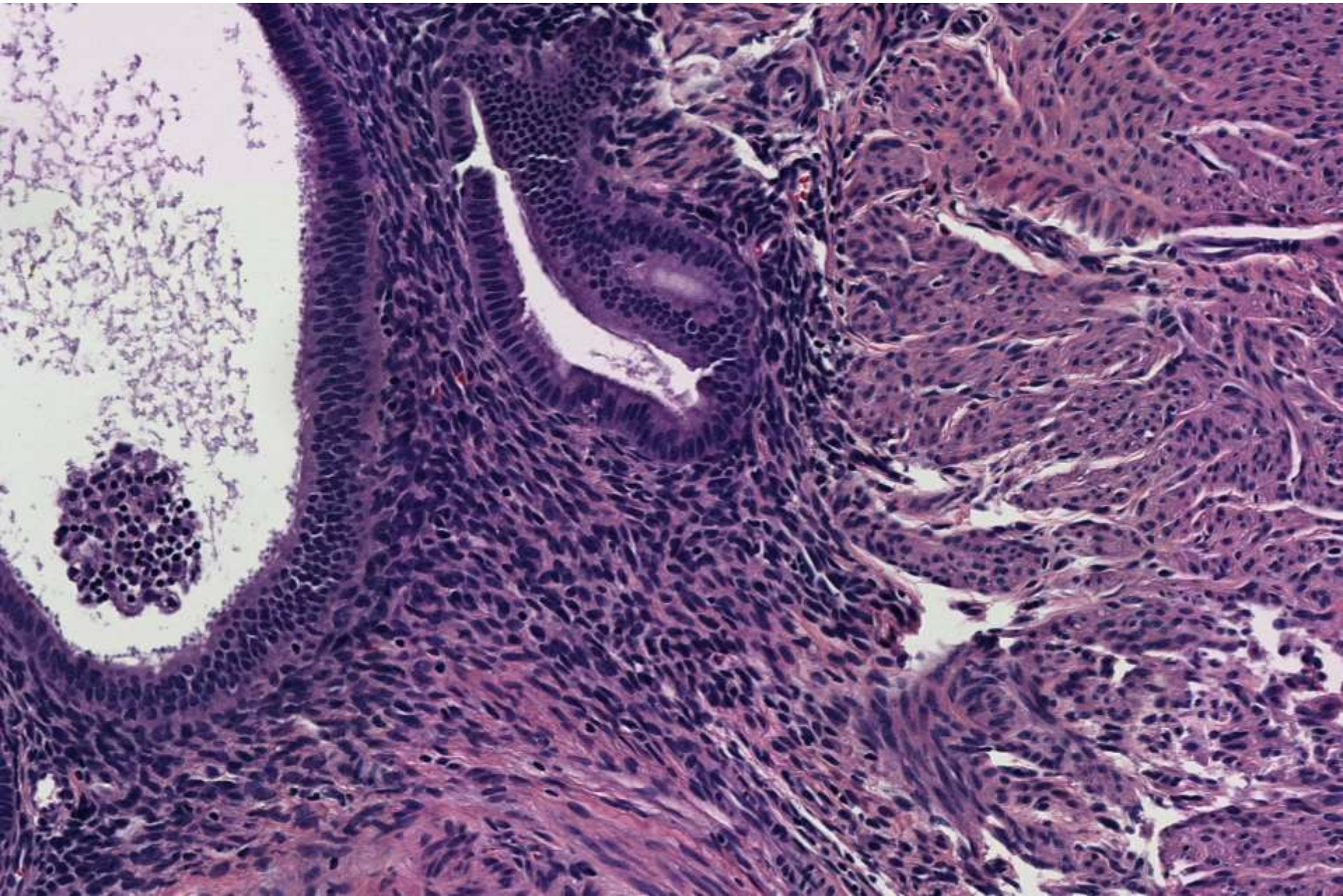




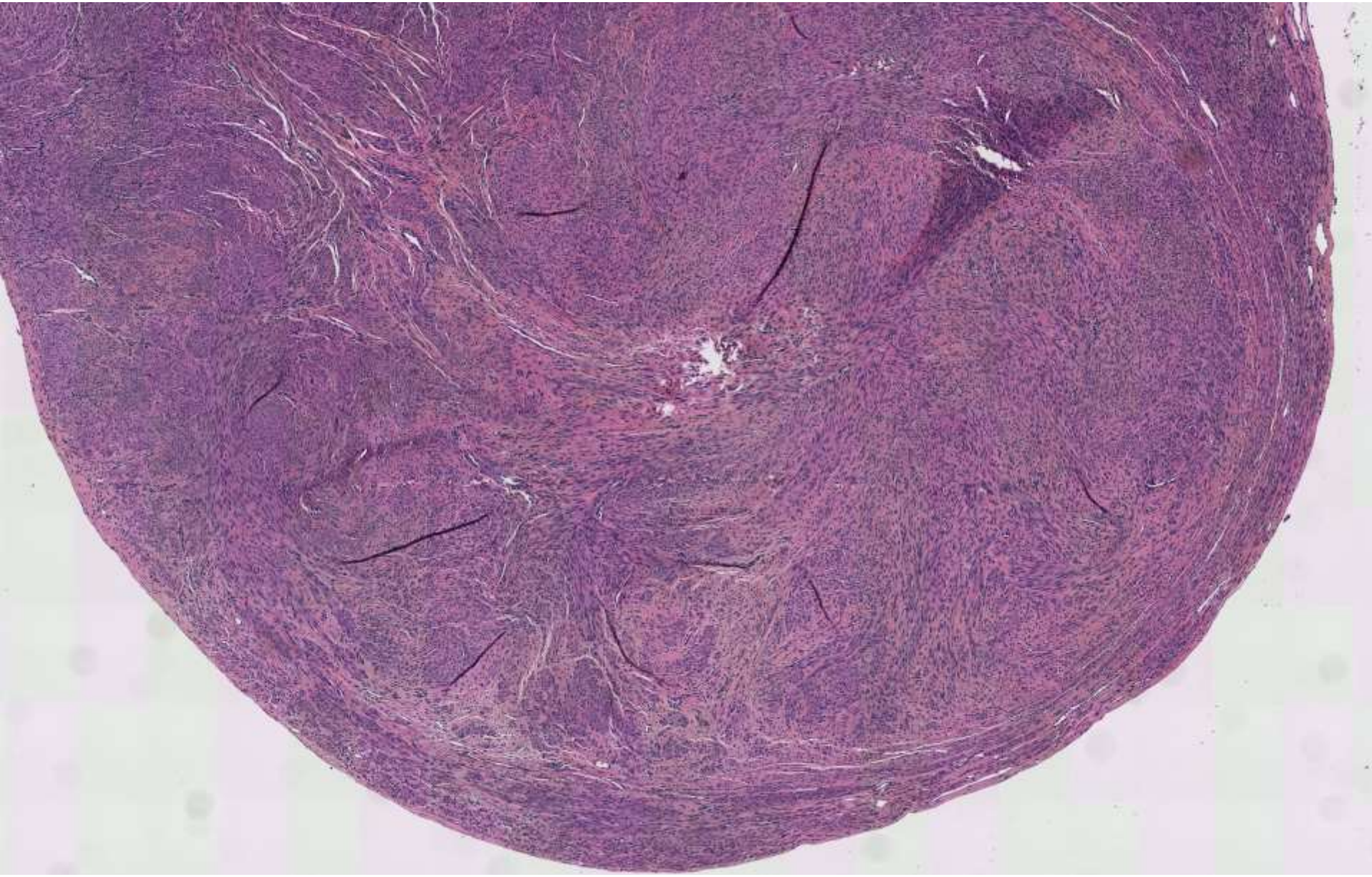


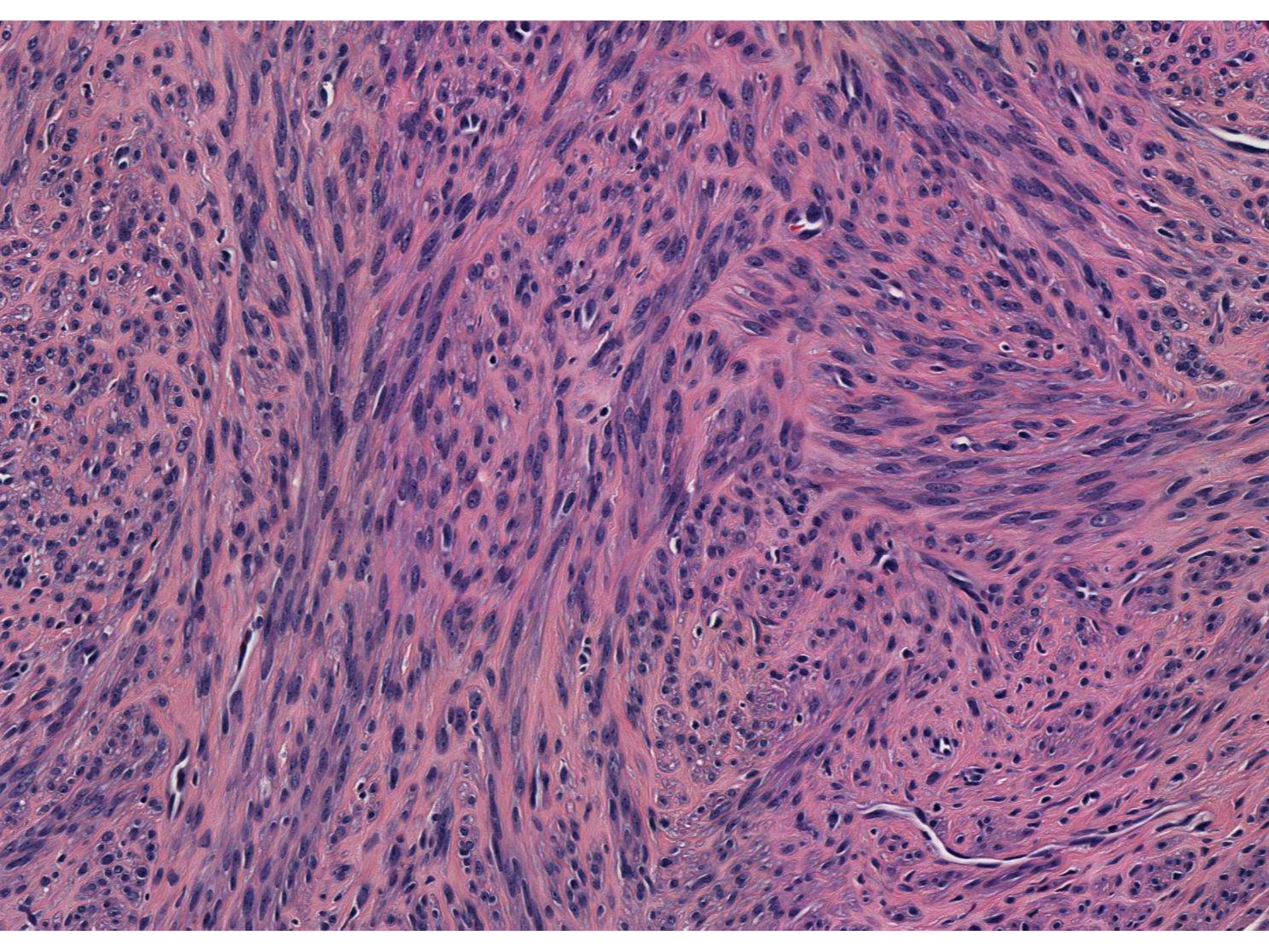










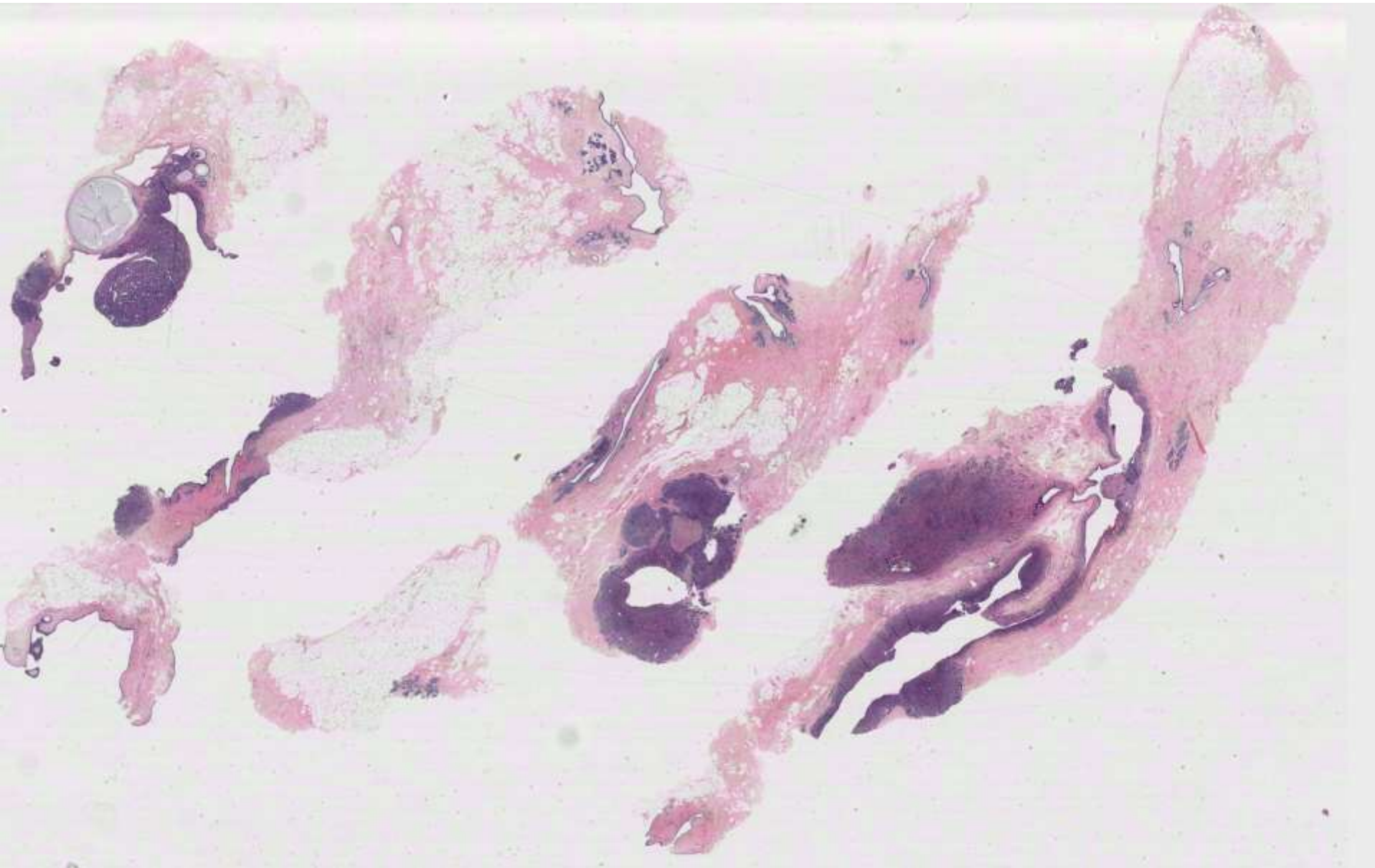


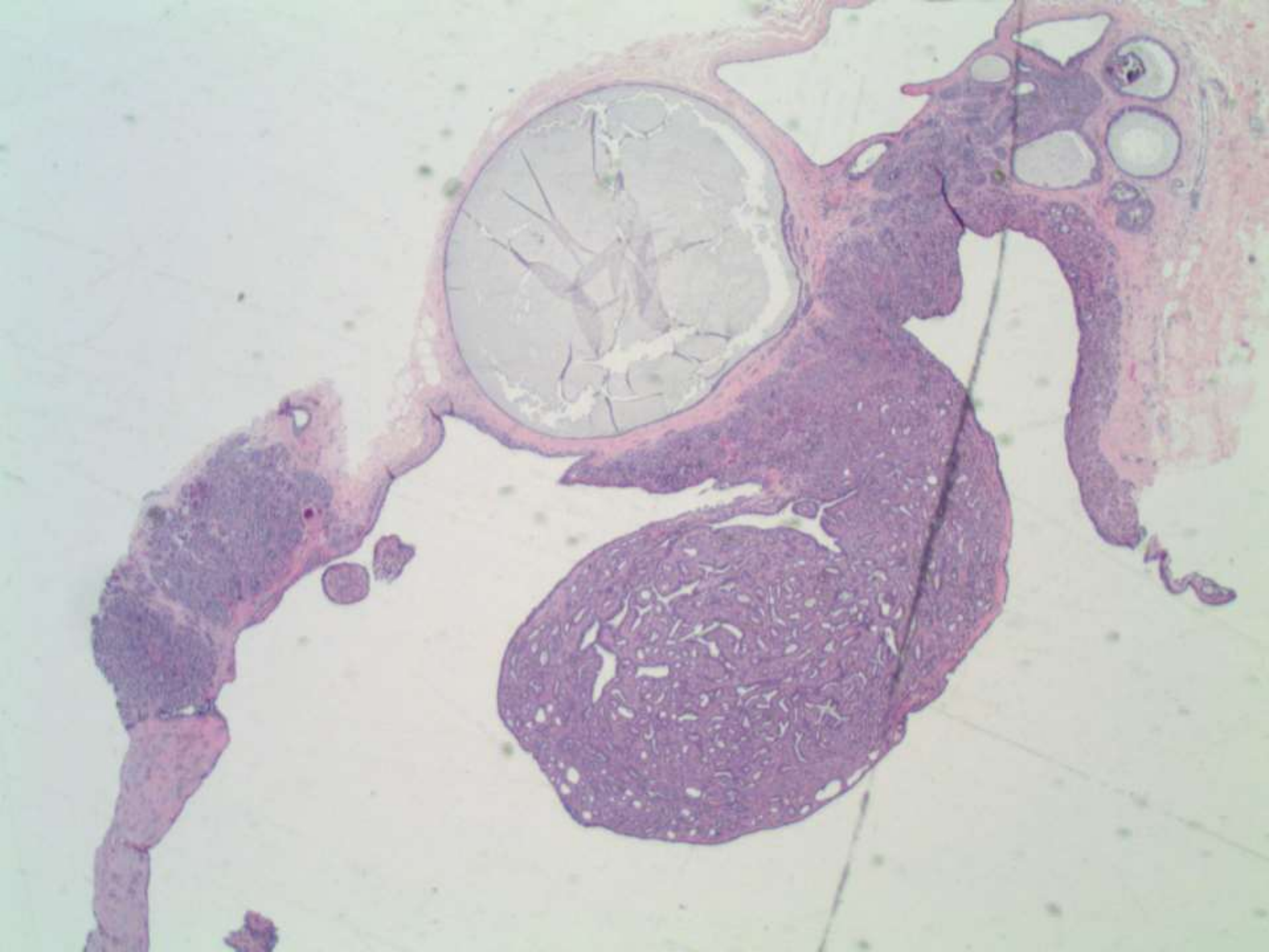# 19-0702

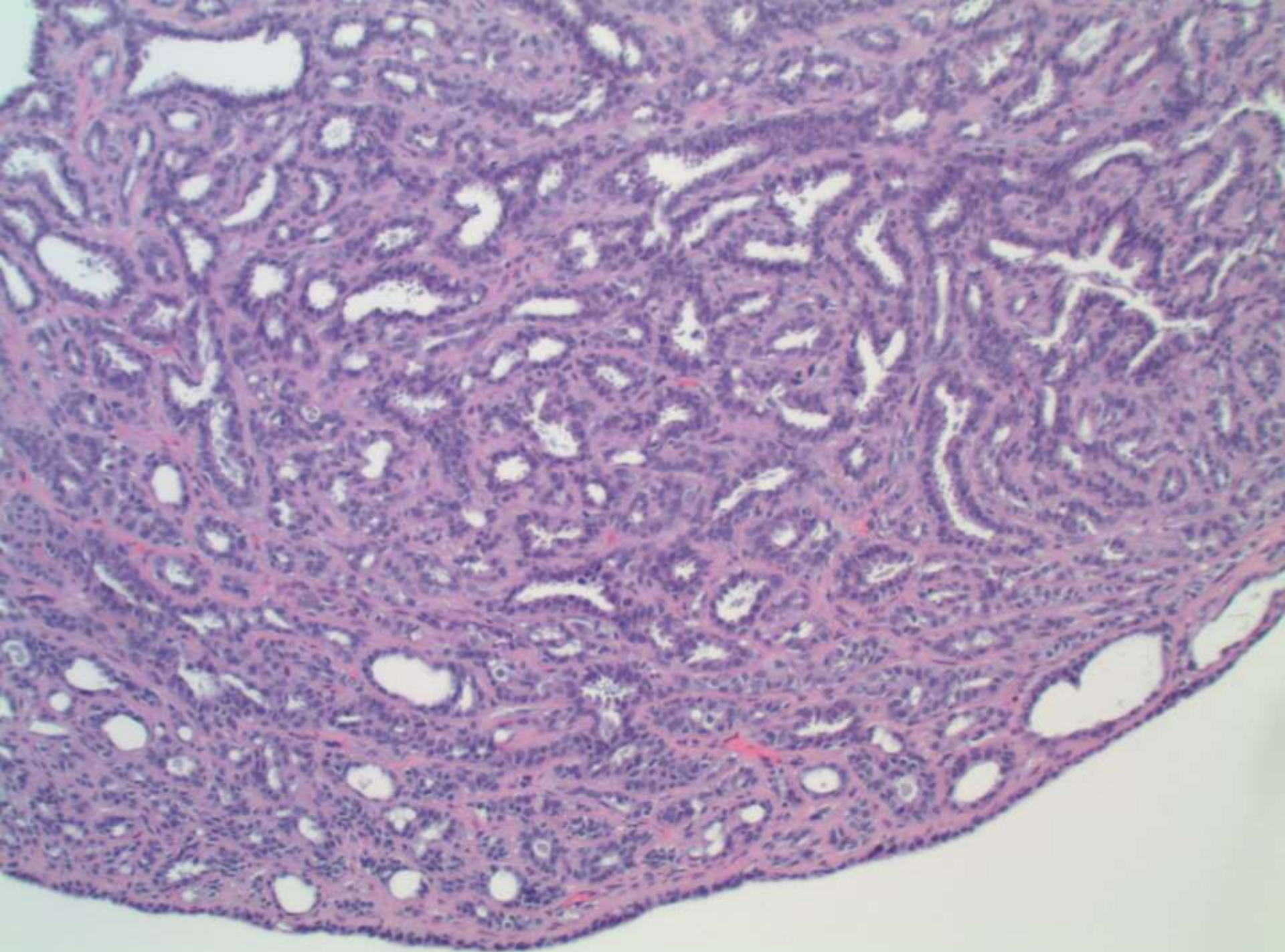
(scanned slide avail)

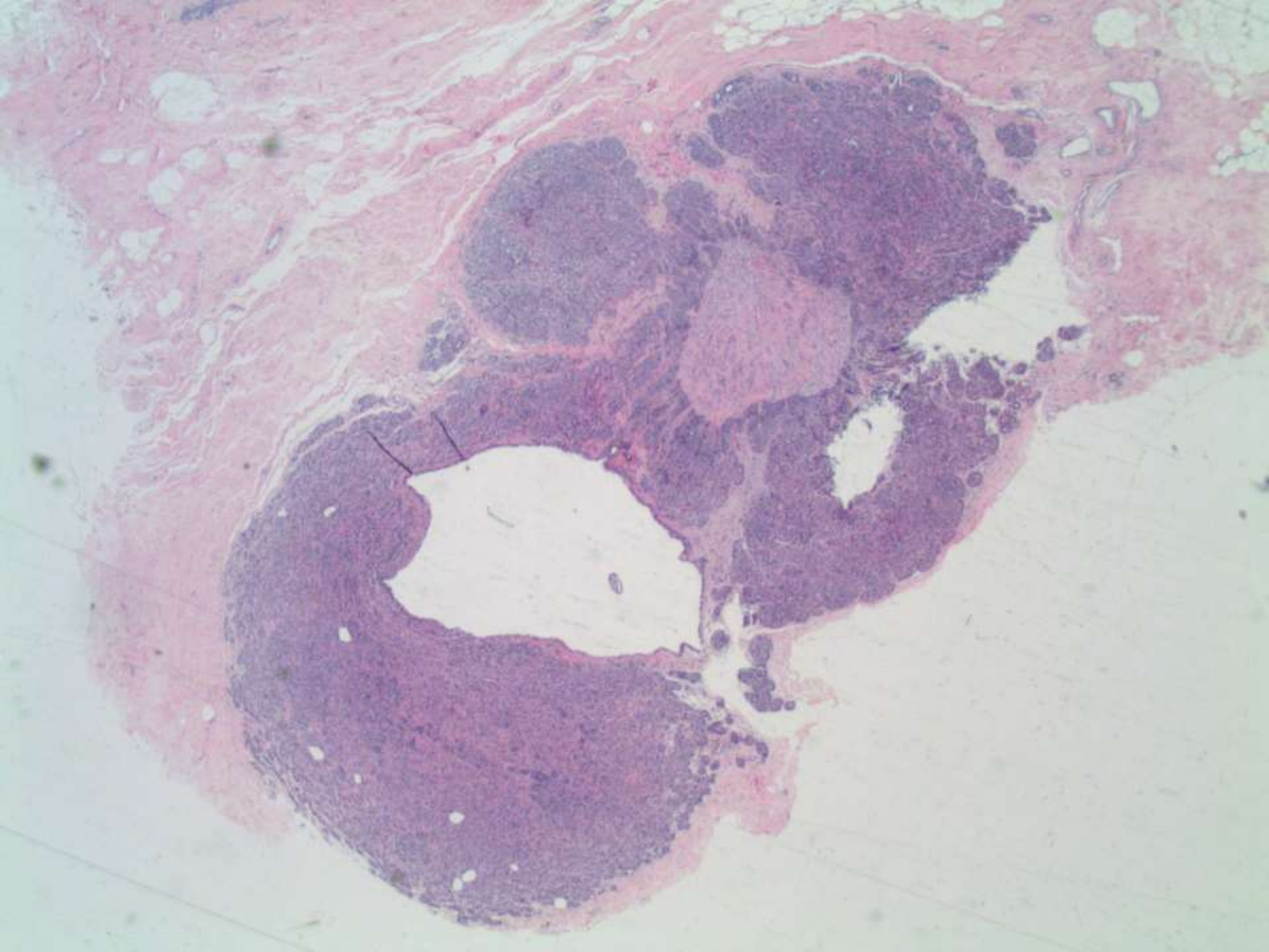
Megan Troxell; Stanford

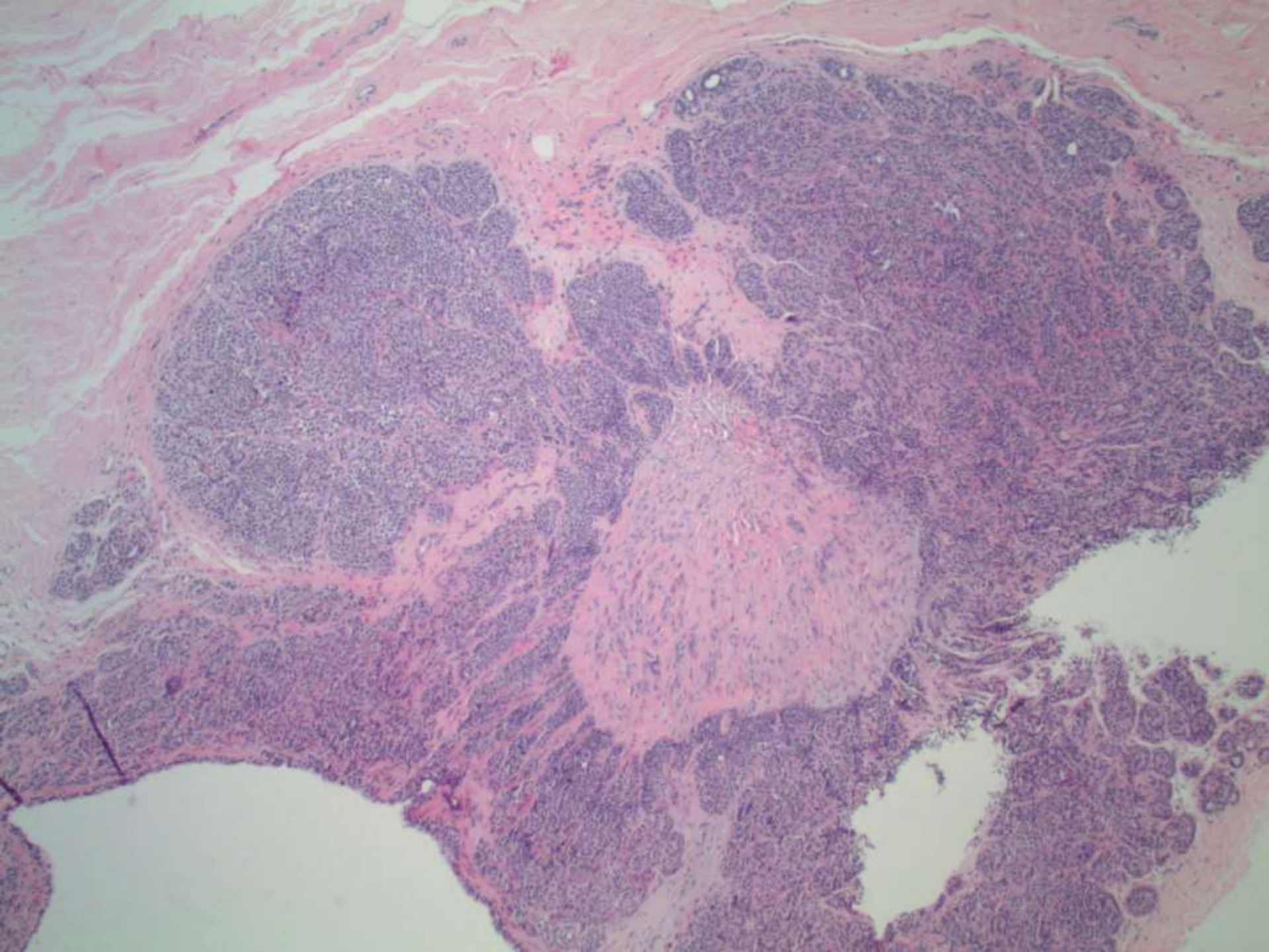
46-year-old woman with h/o  
contralateral breast cancer. Now with  
left breast mass noted on MRI and  
ultrasound.



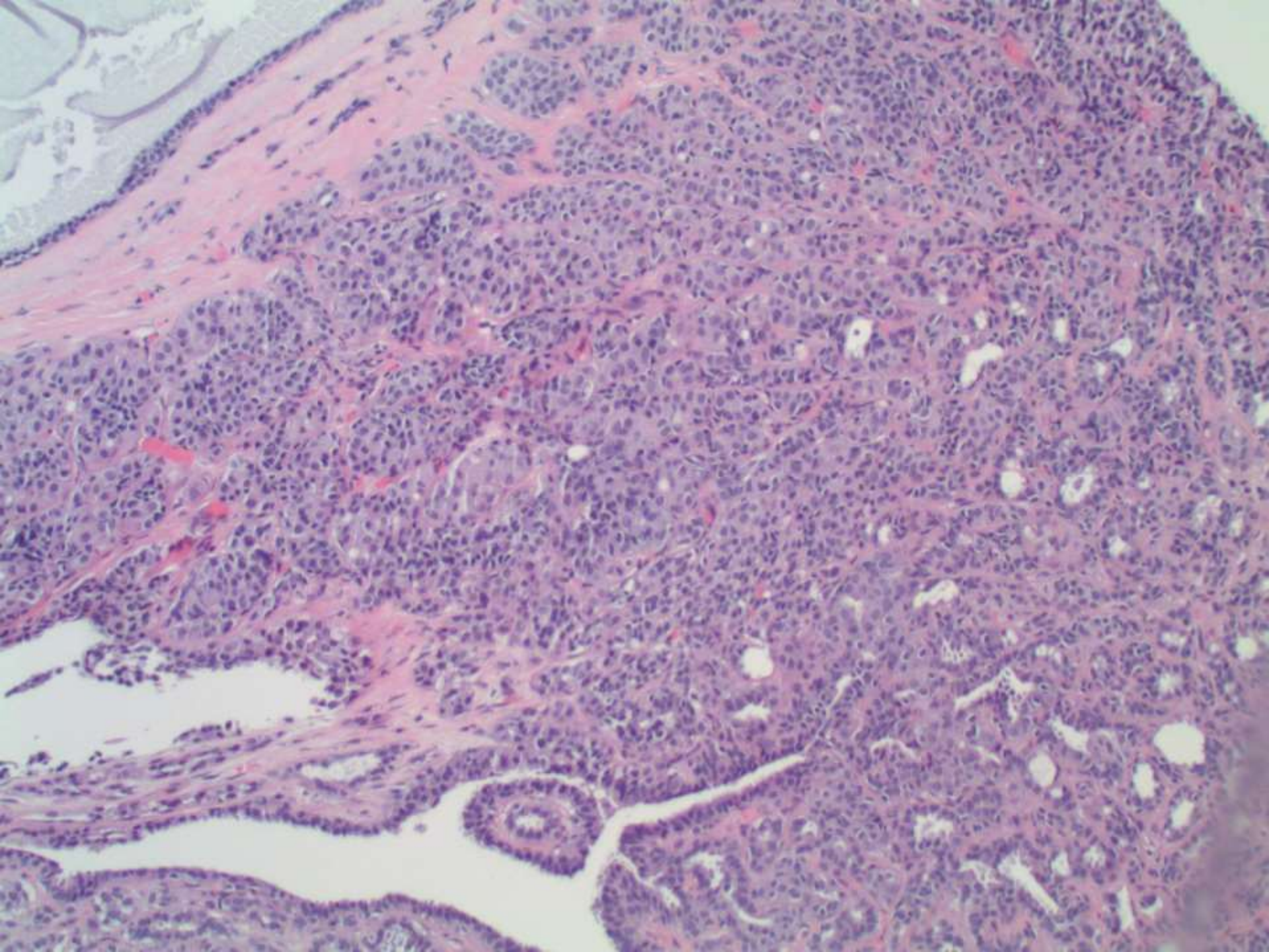


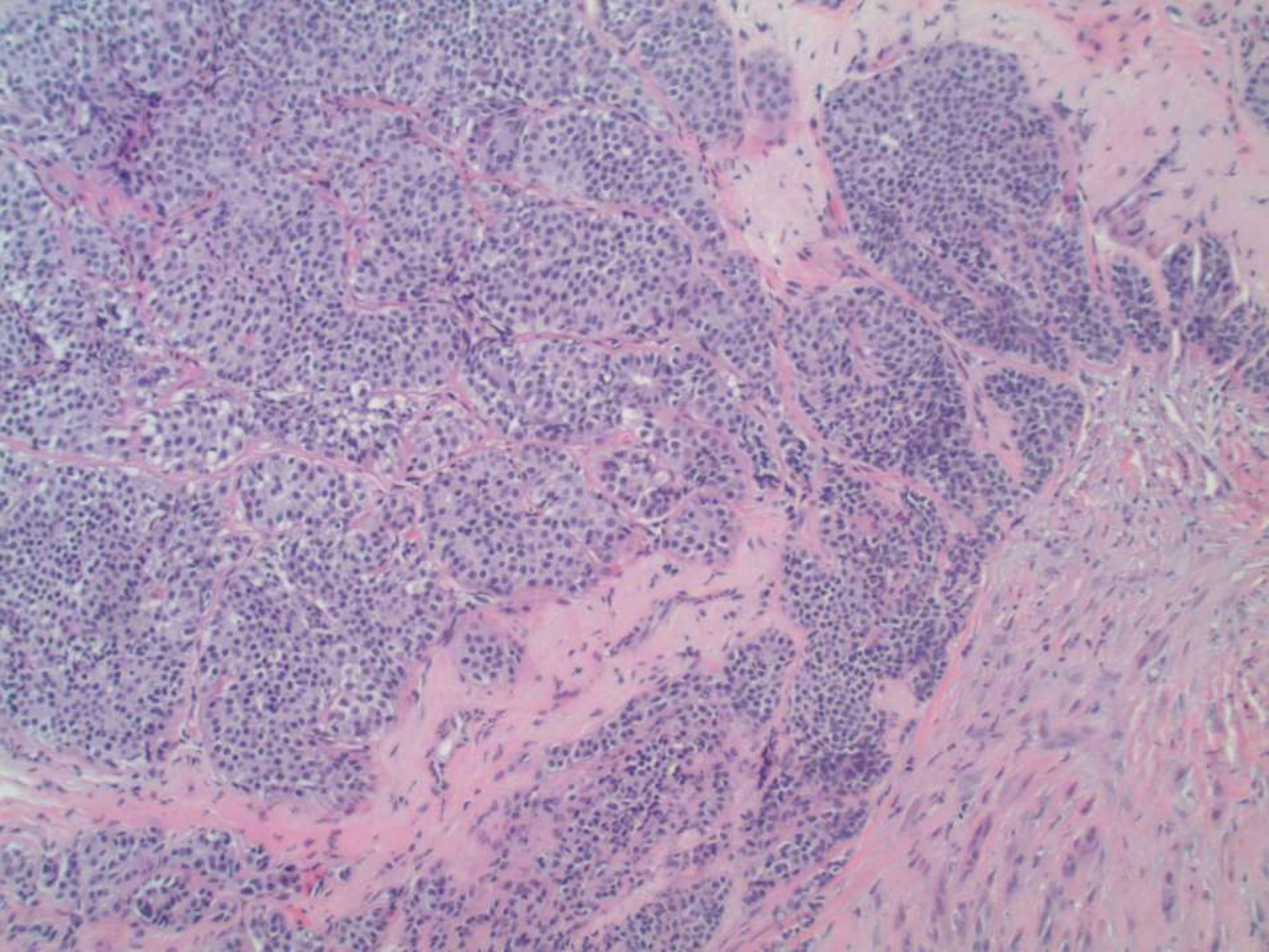


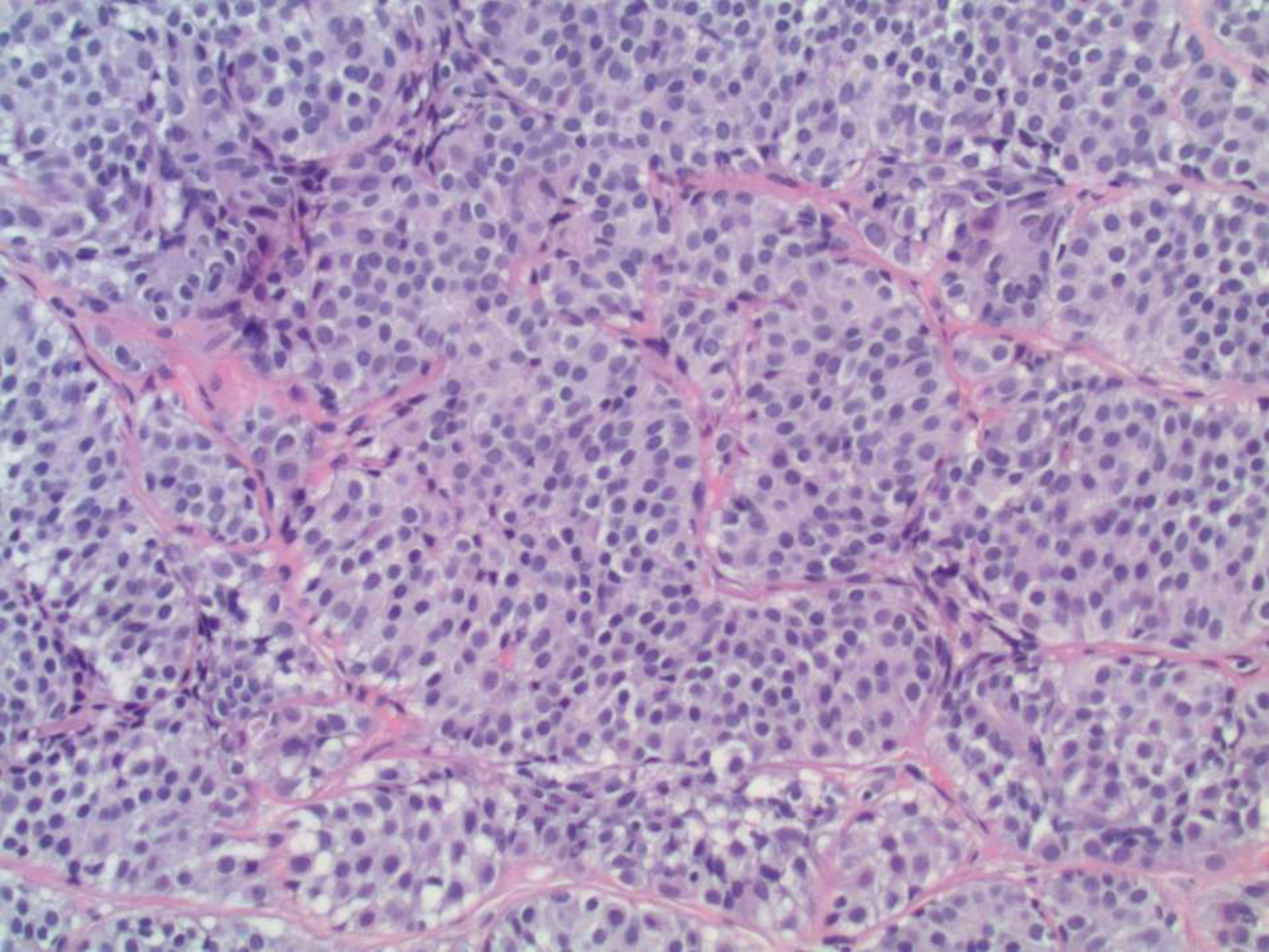


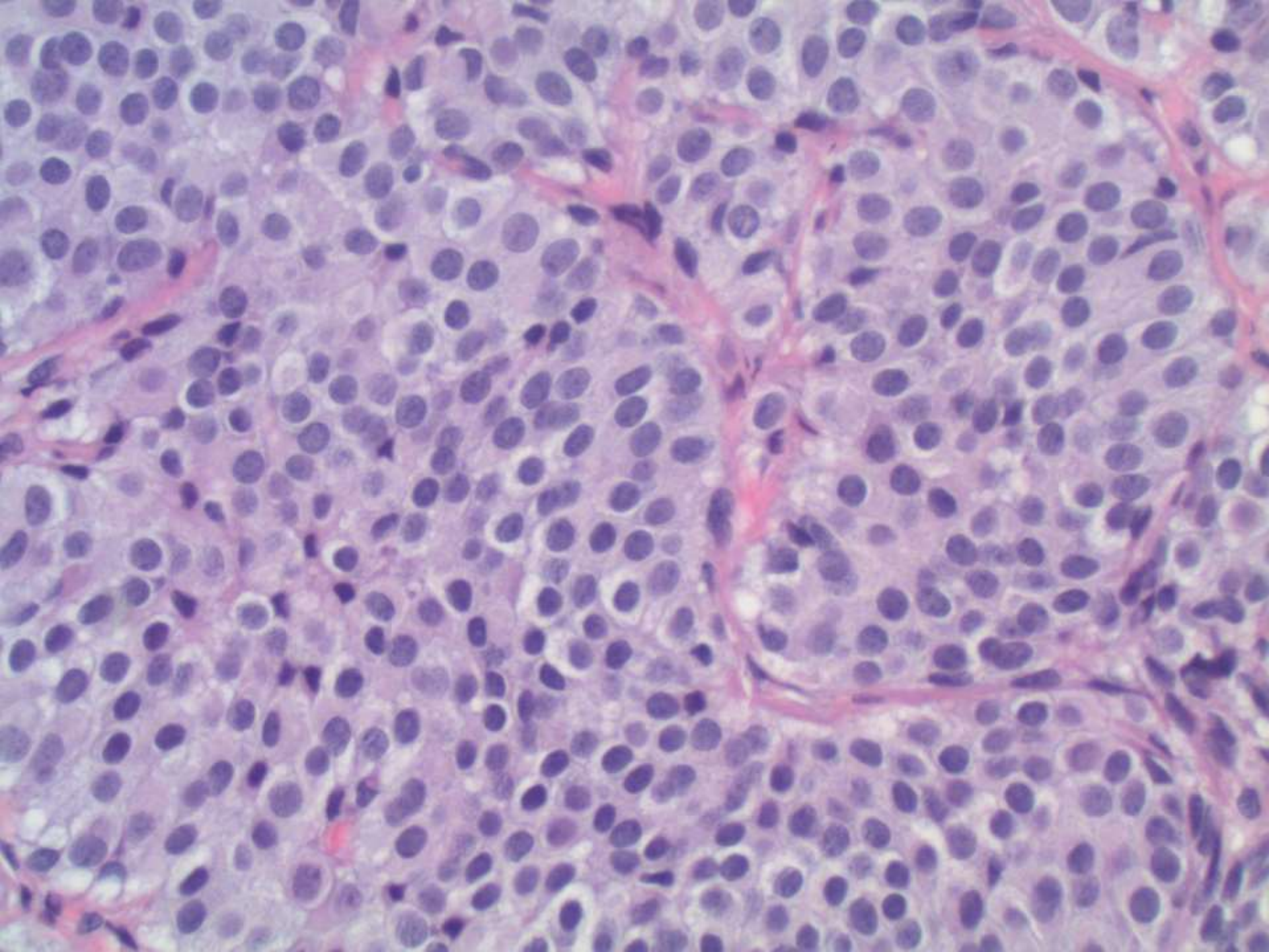


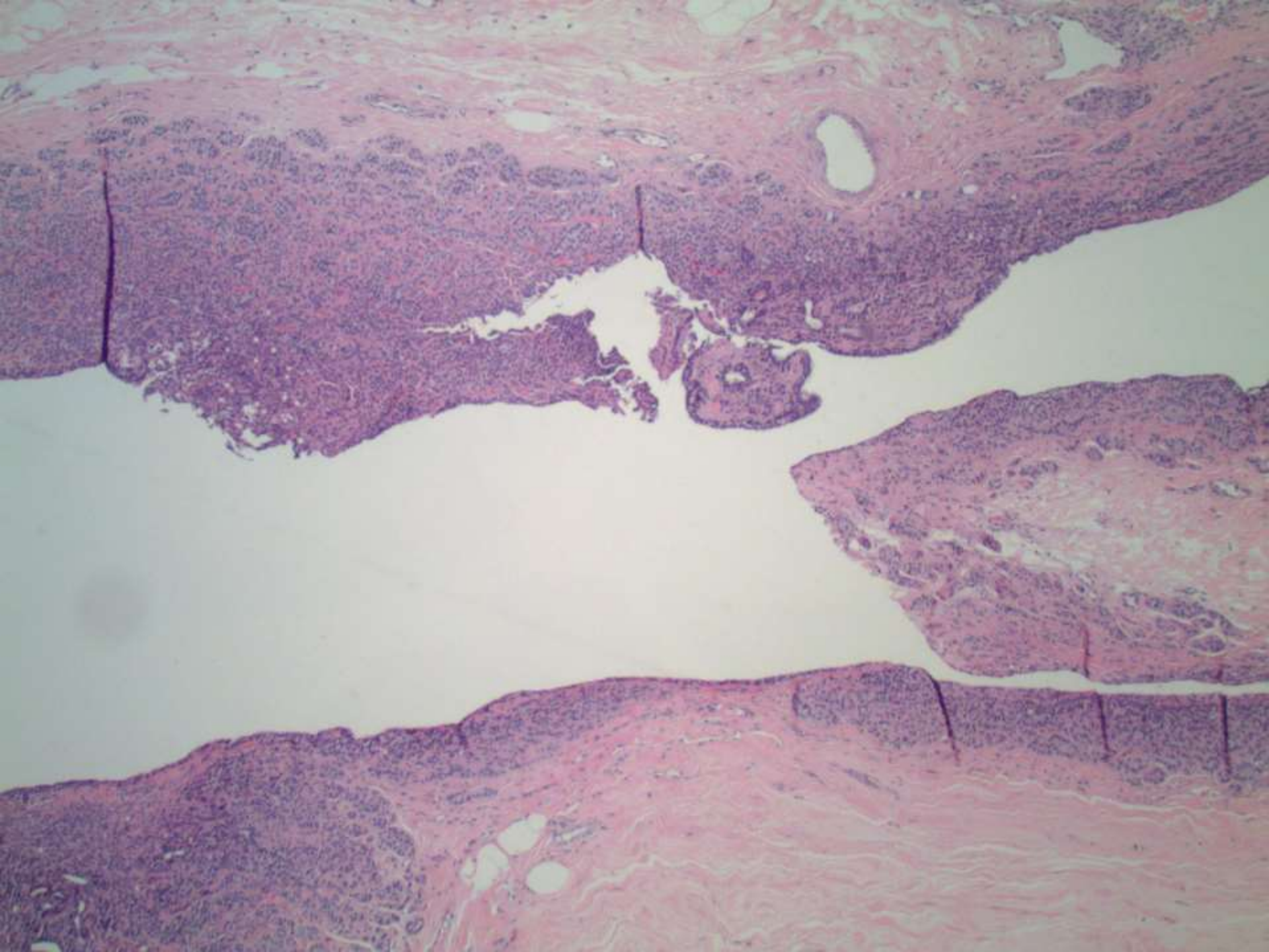


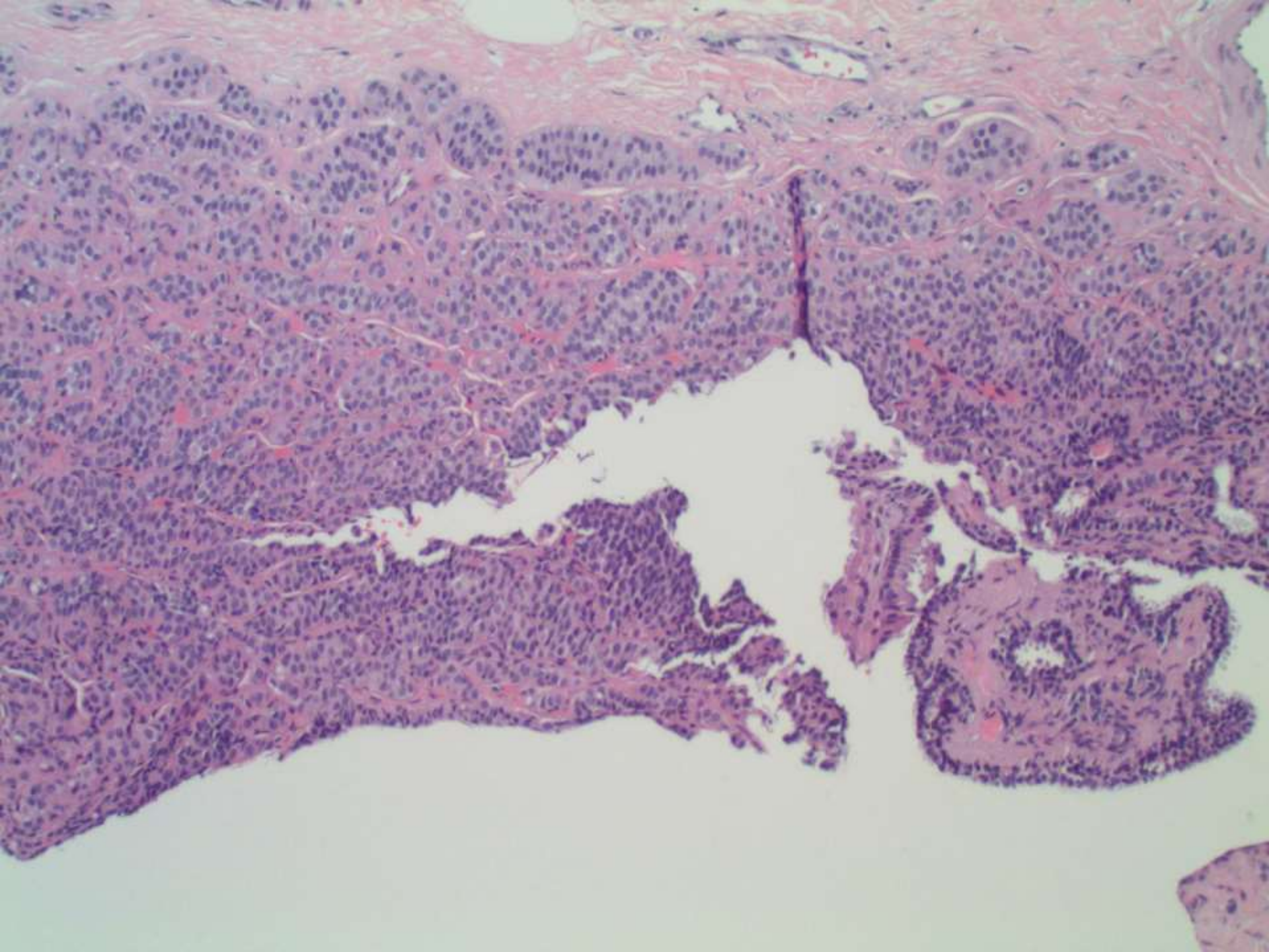


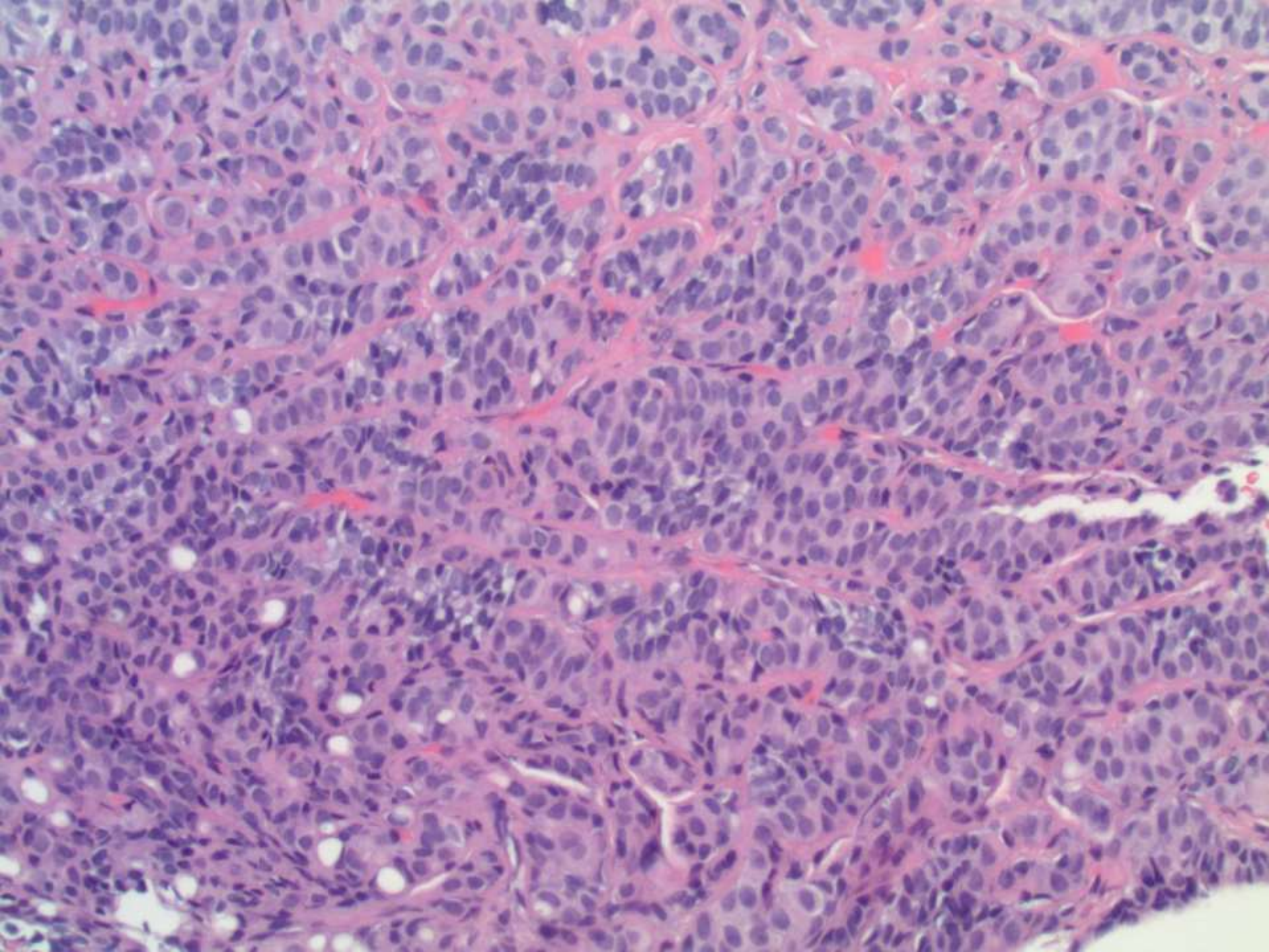


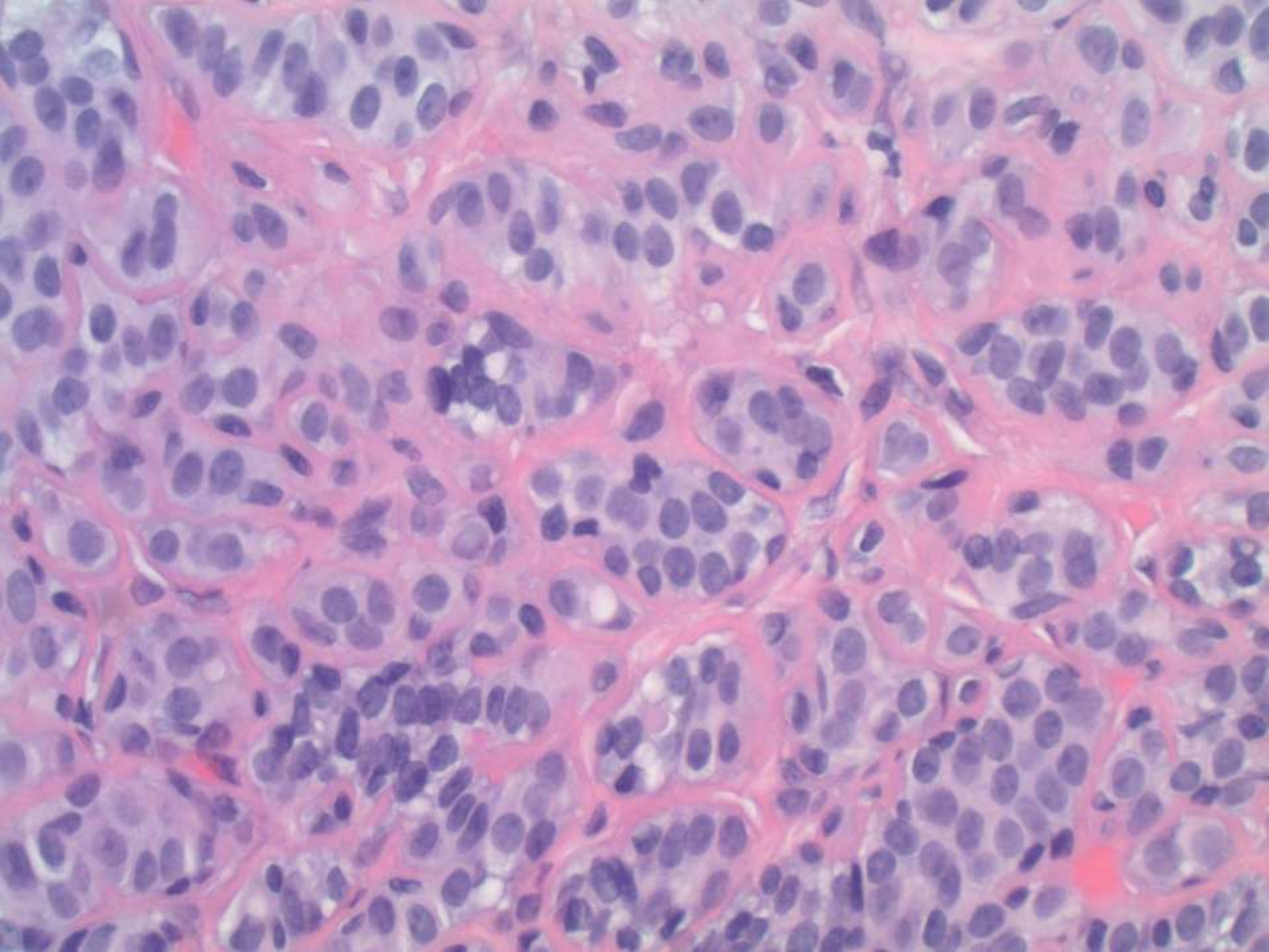




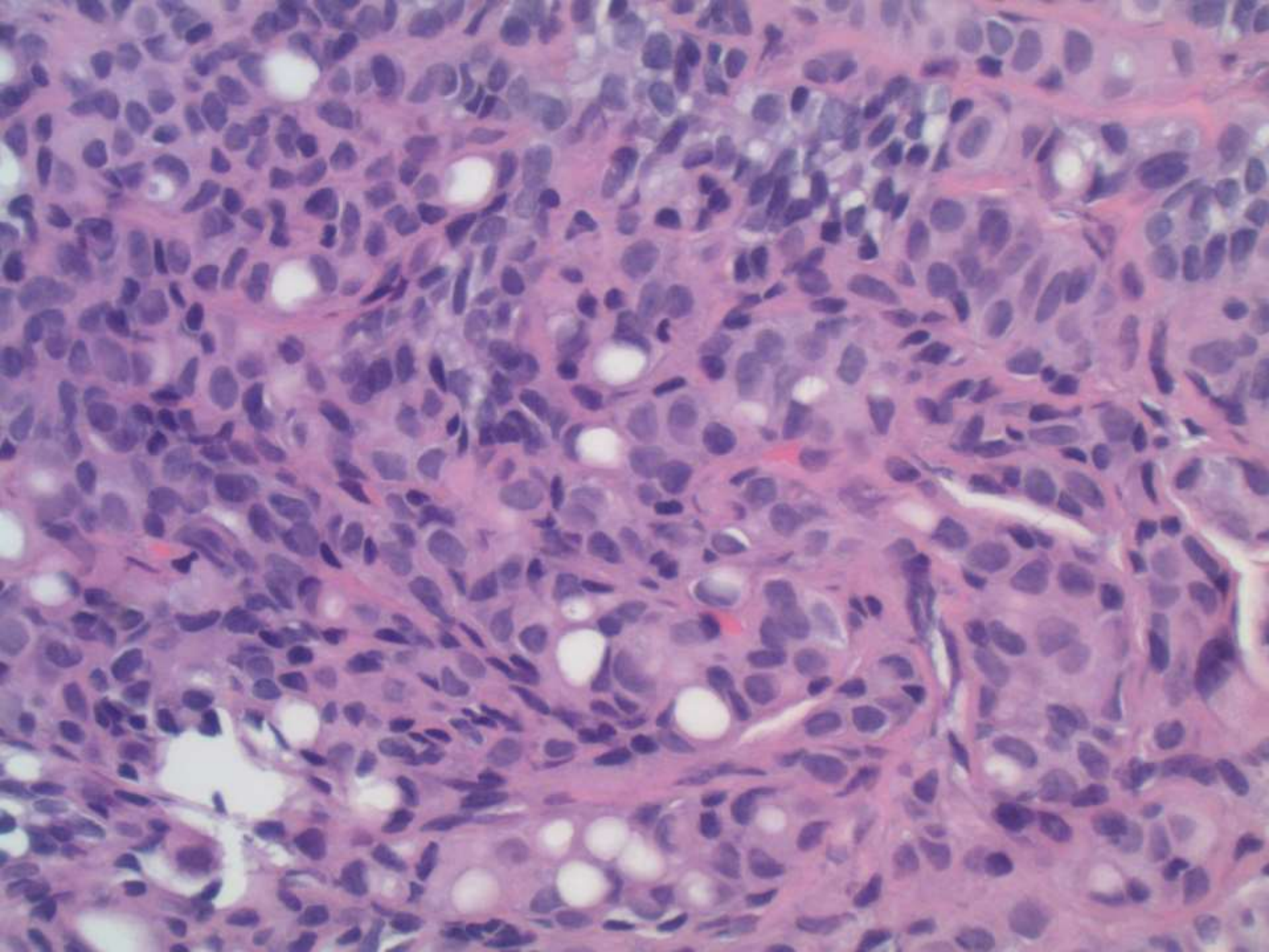


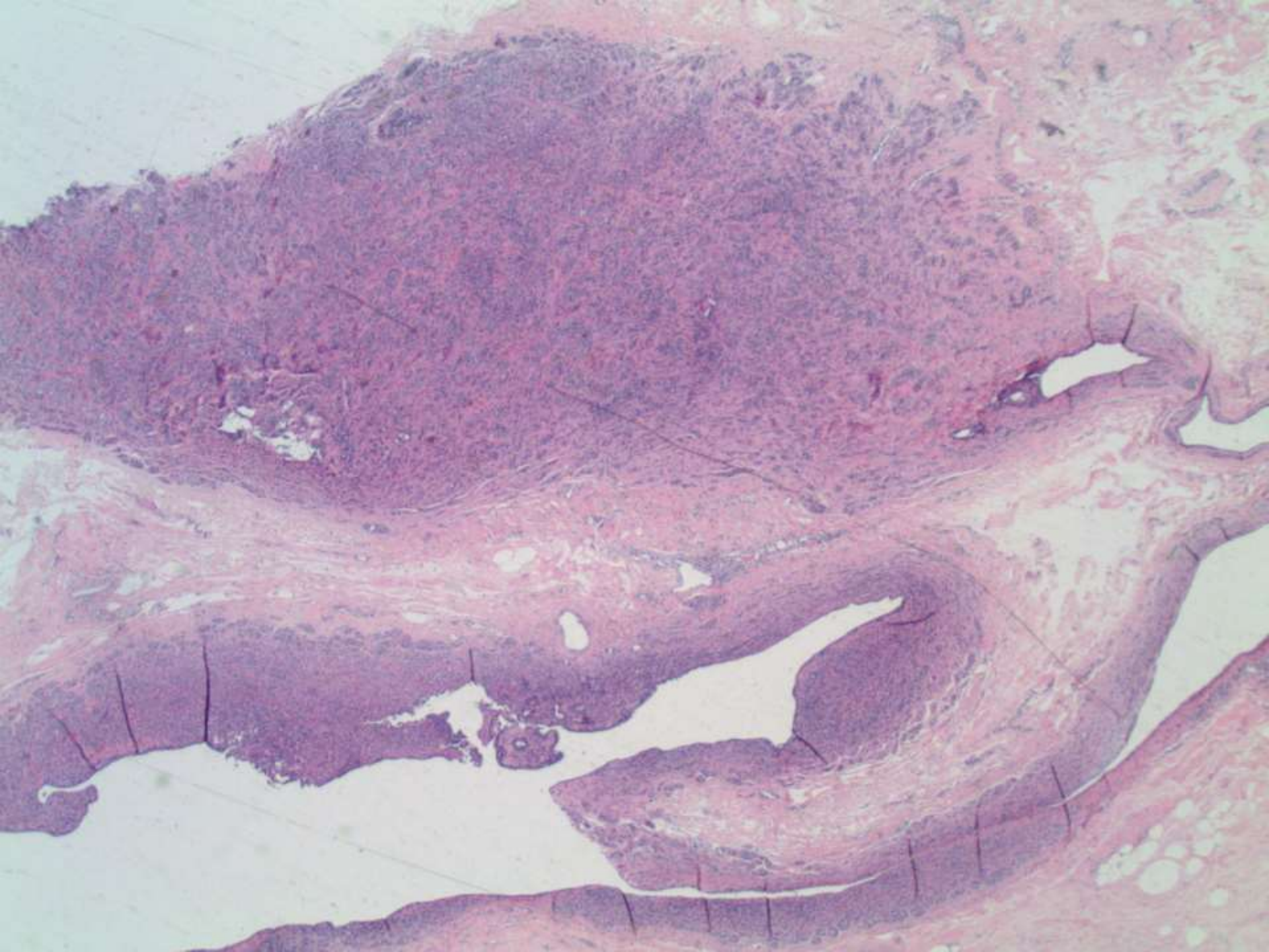


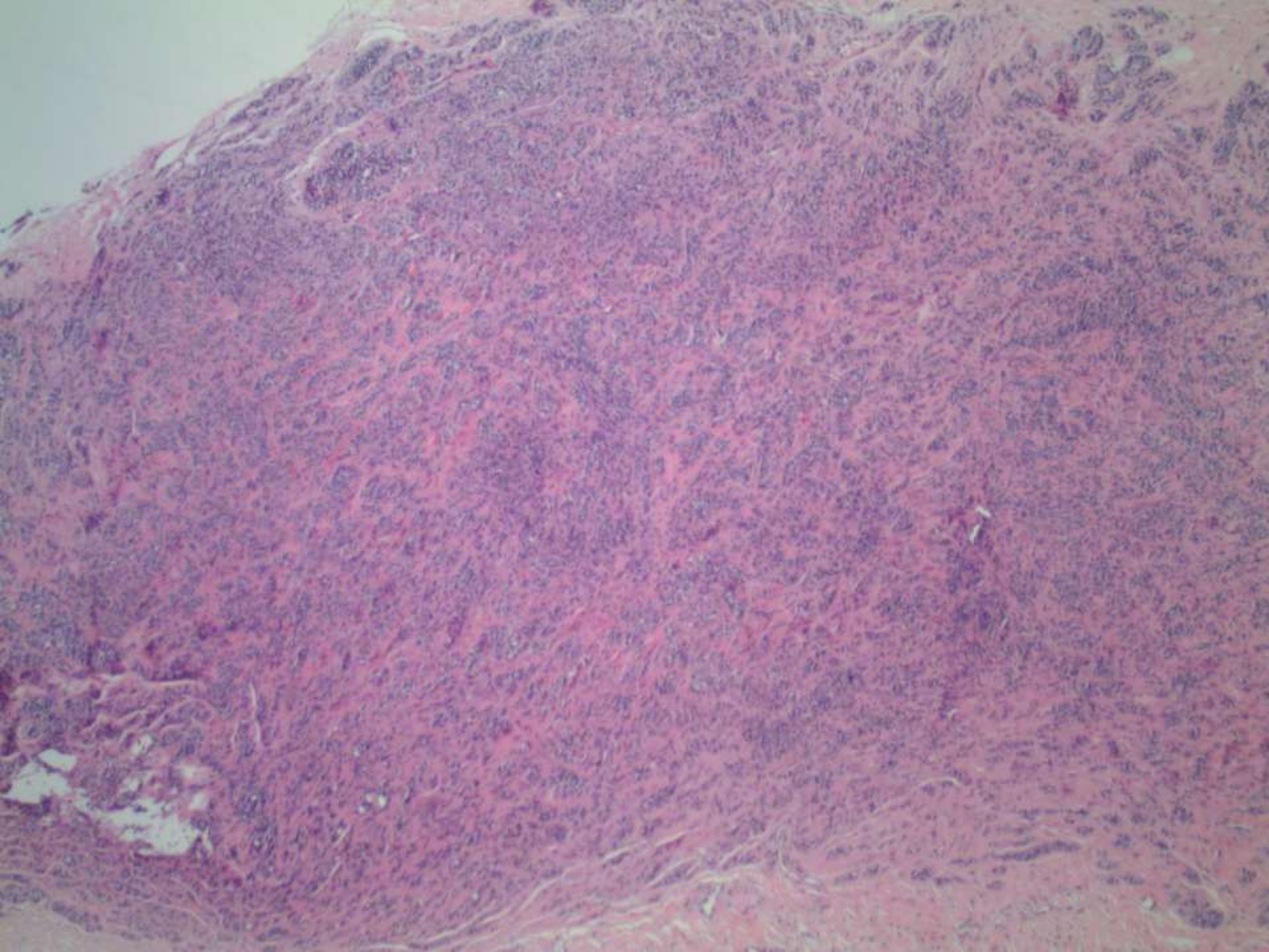


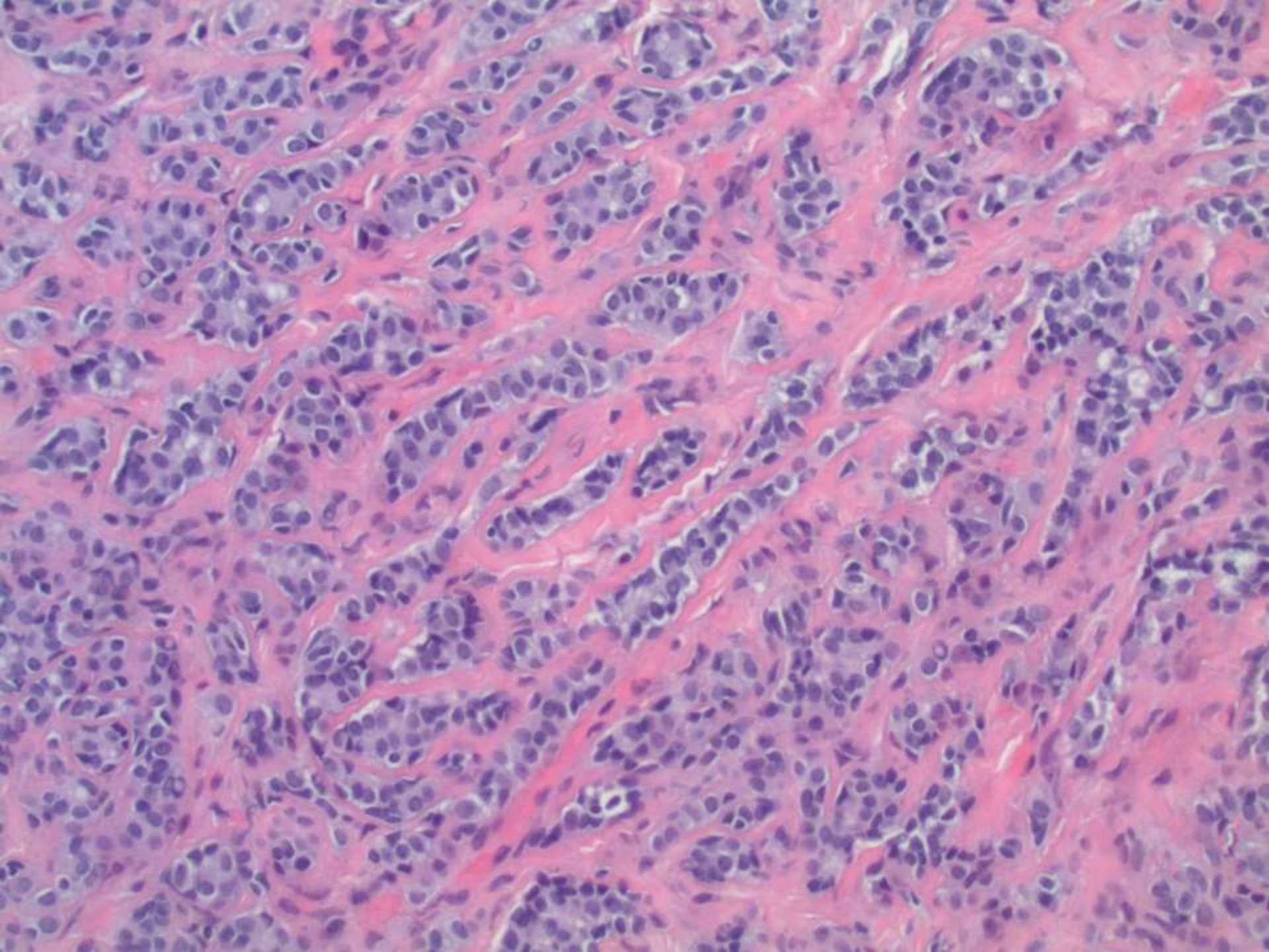


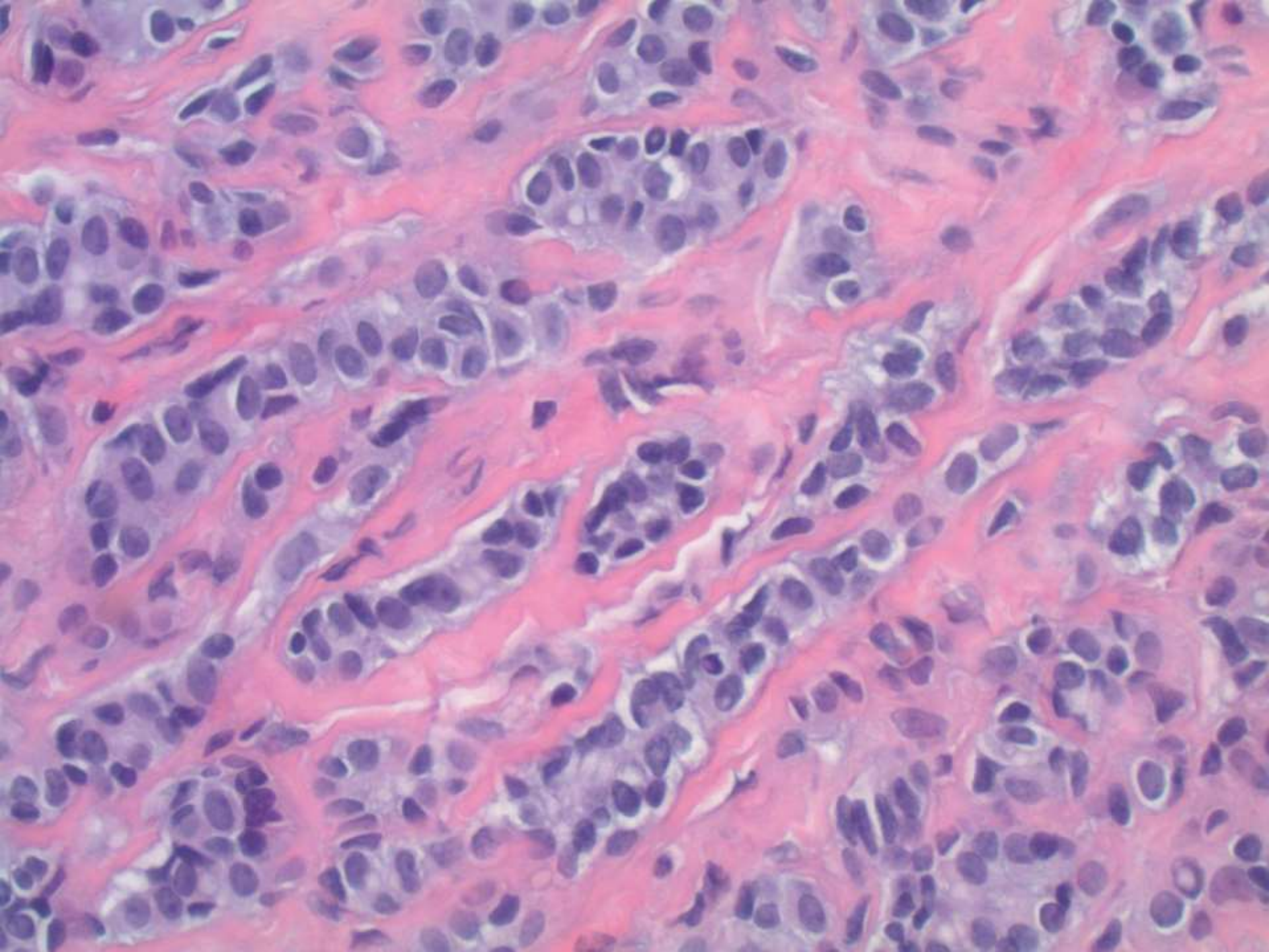










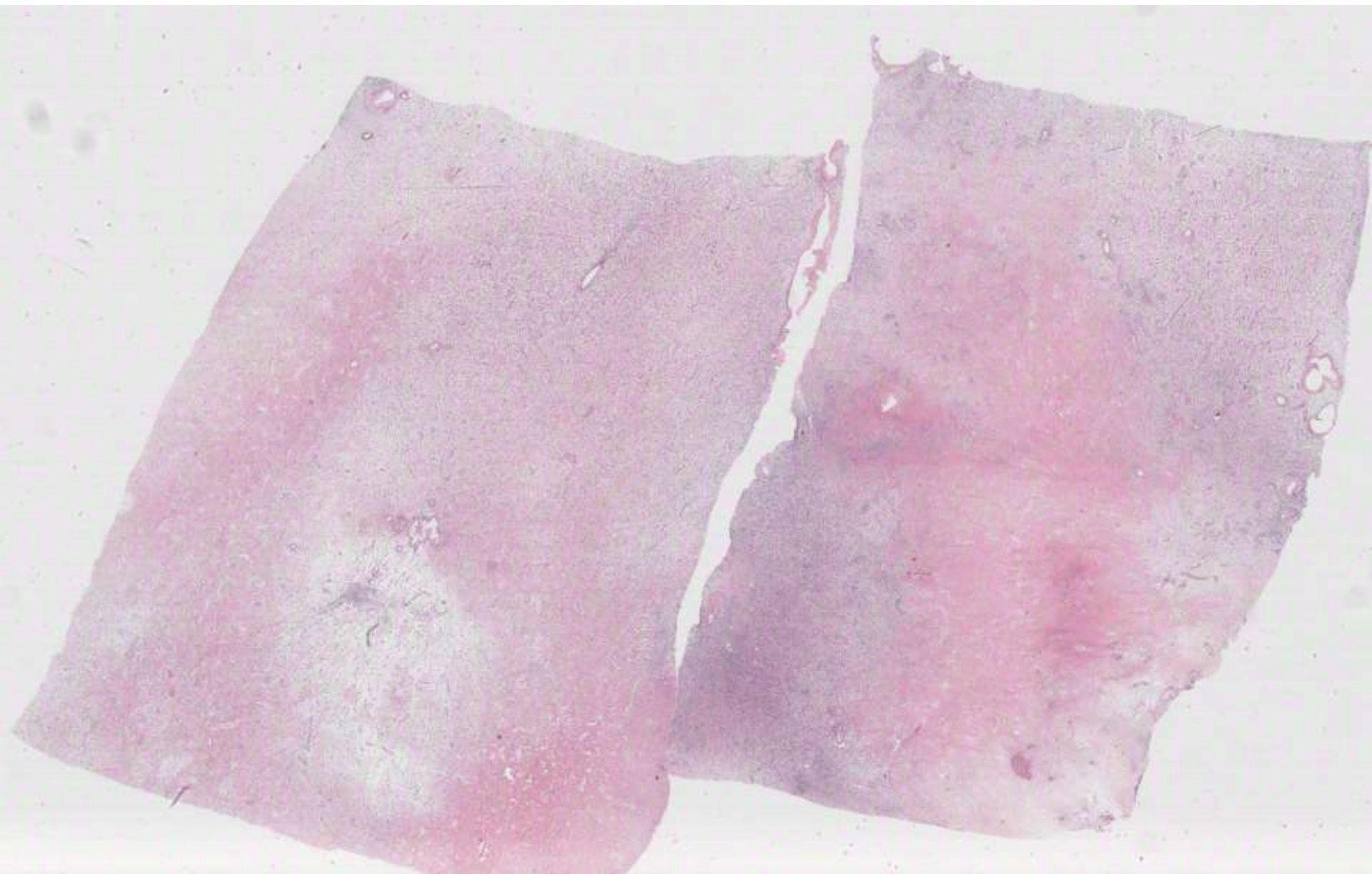

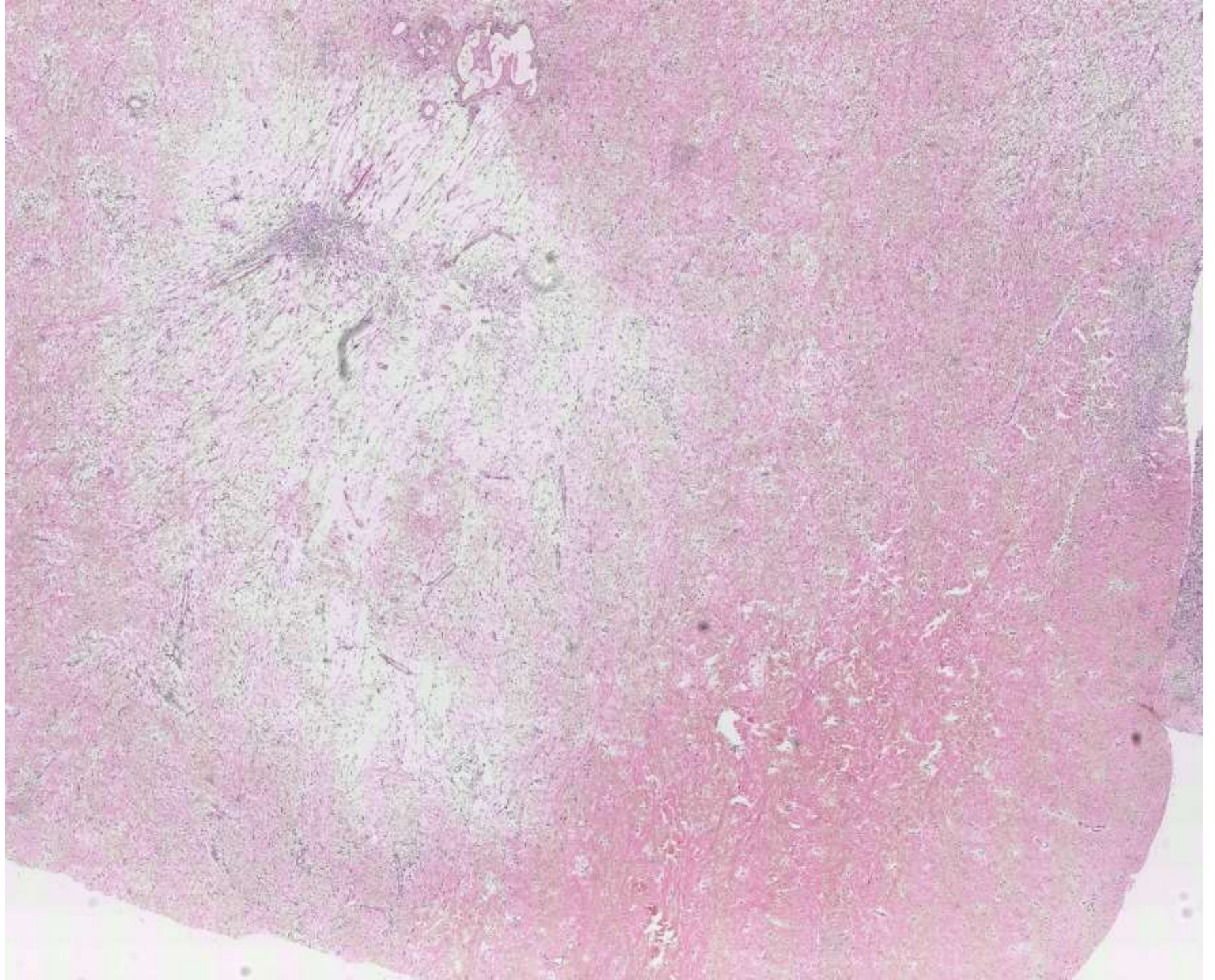
# 19-0703

(scanned slide avail)

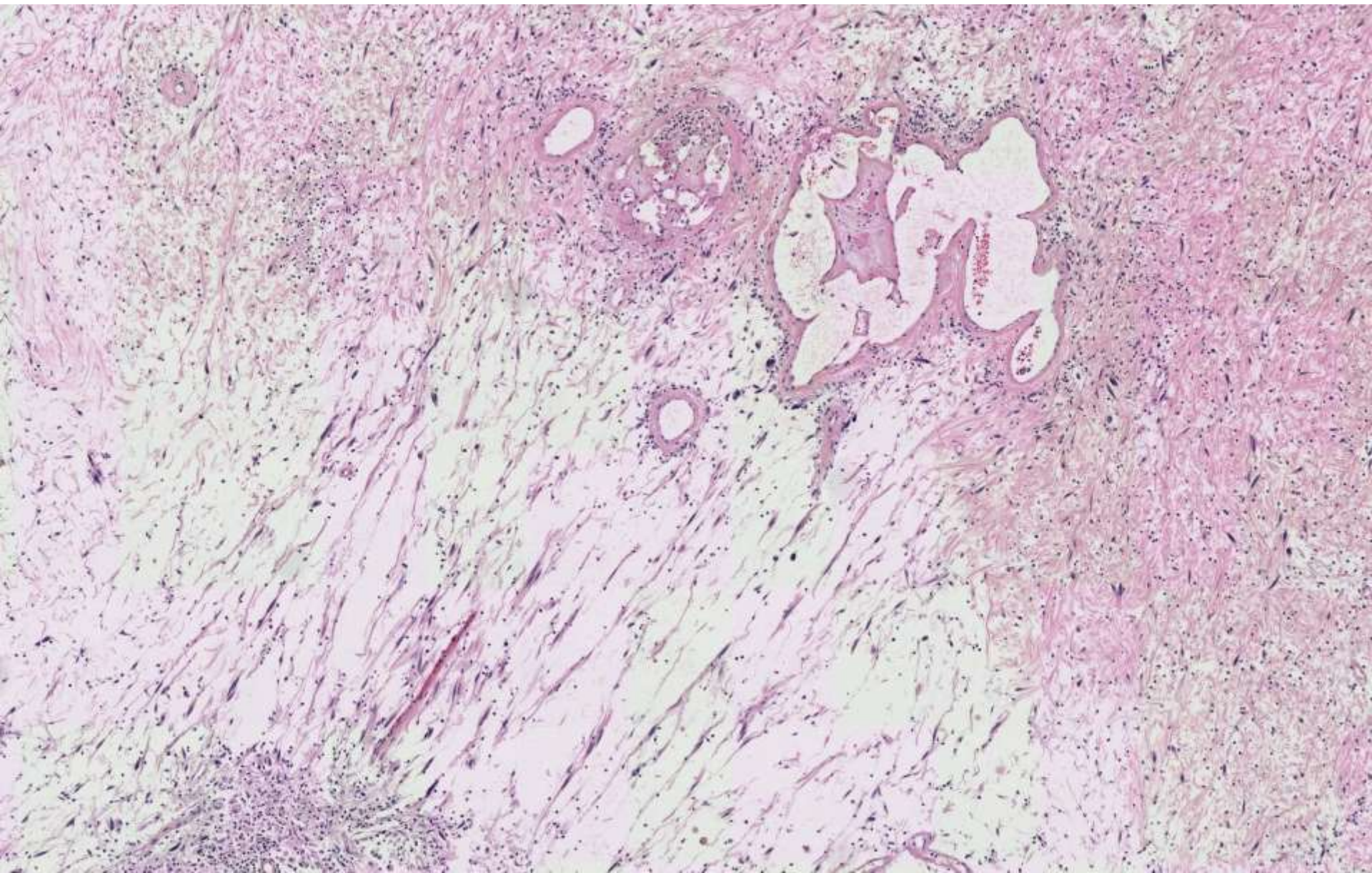
**Balaram Puligandla; Kaiser Oakland**

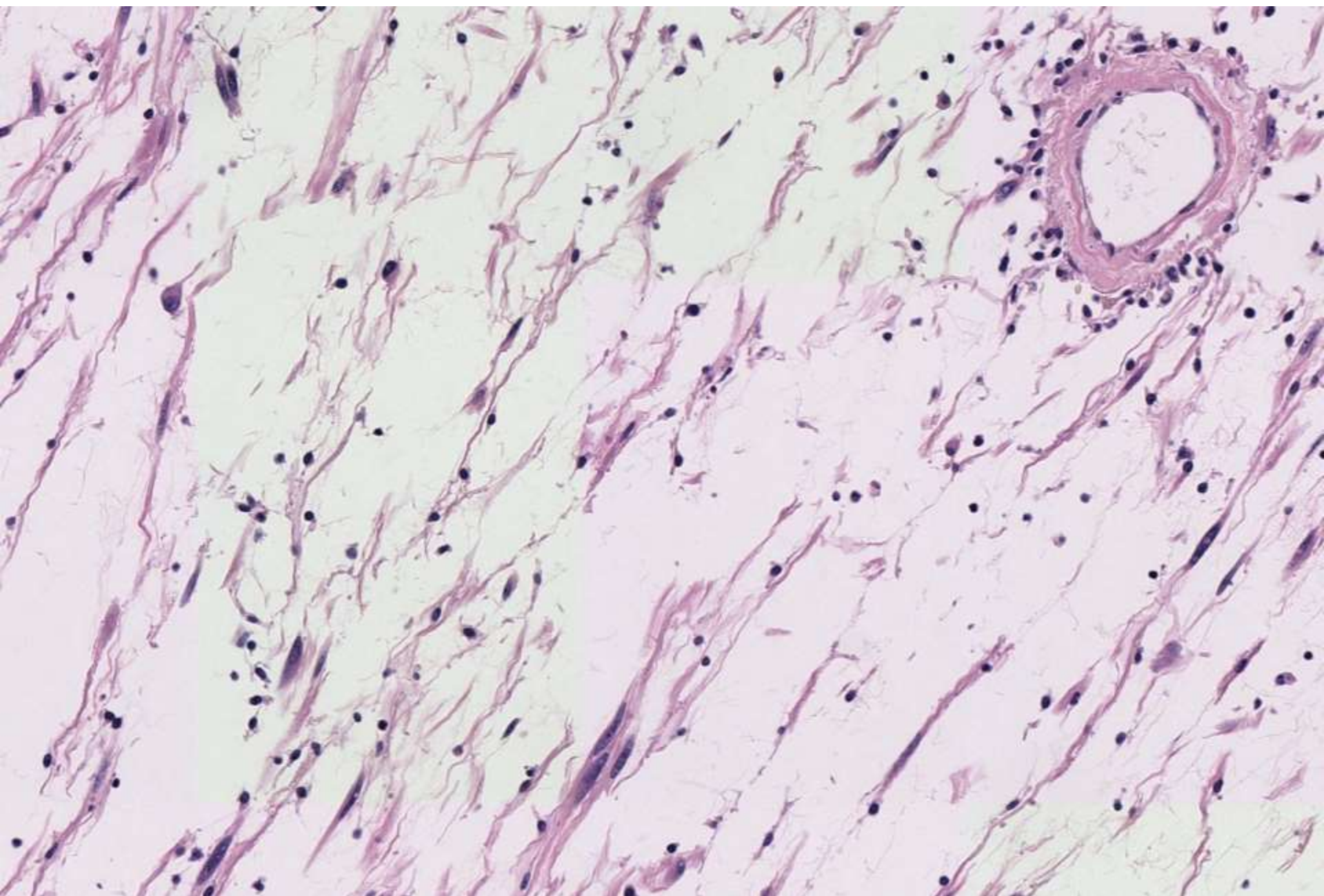
62-year-old woman with h/o breast cancer in 1994, s/p mastectomy, chemo/radiation now with a large left pleural/chest wall mass.

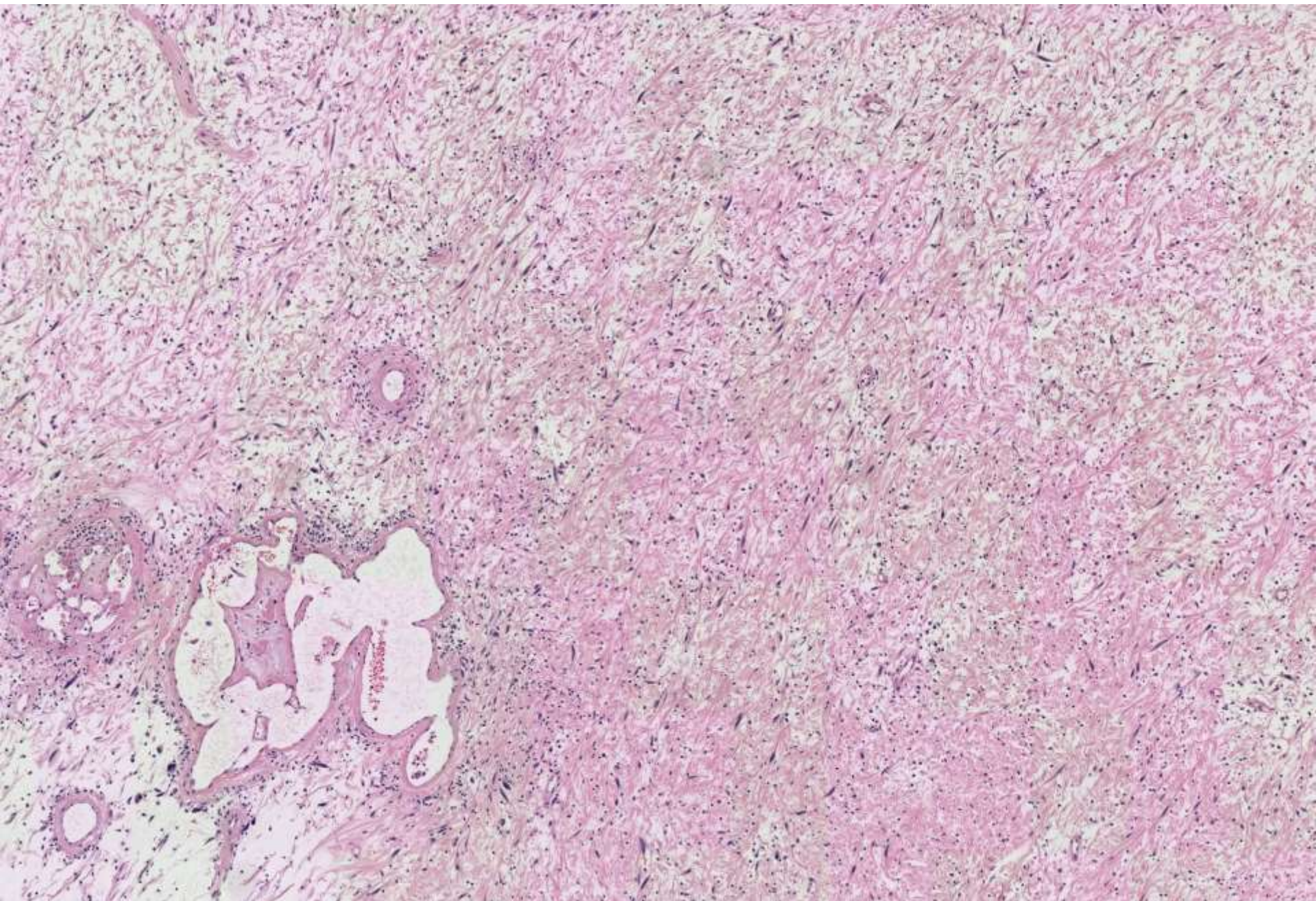


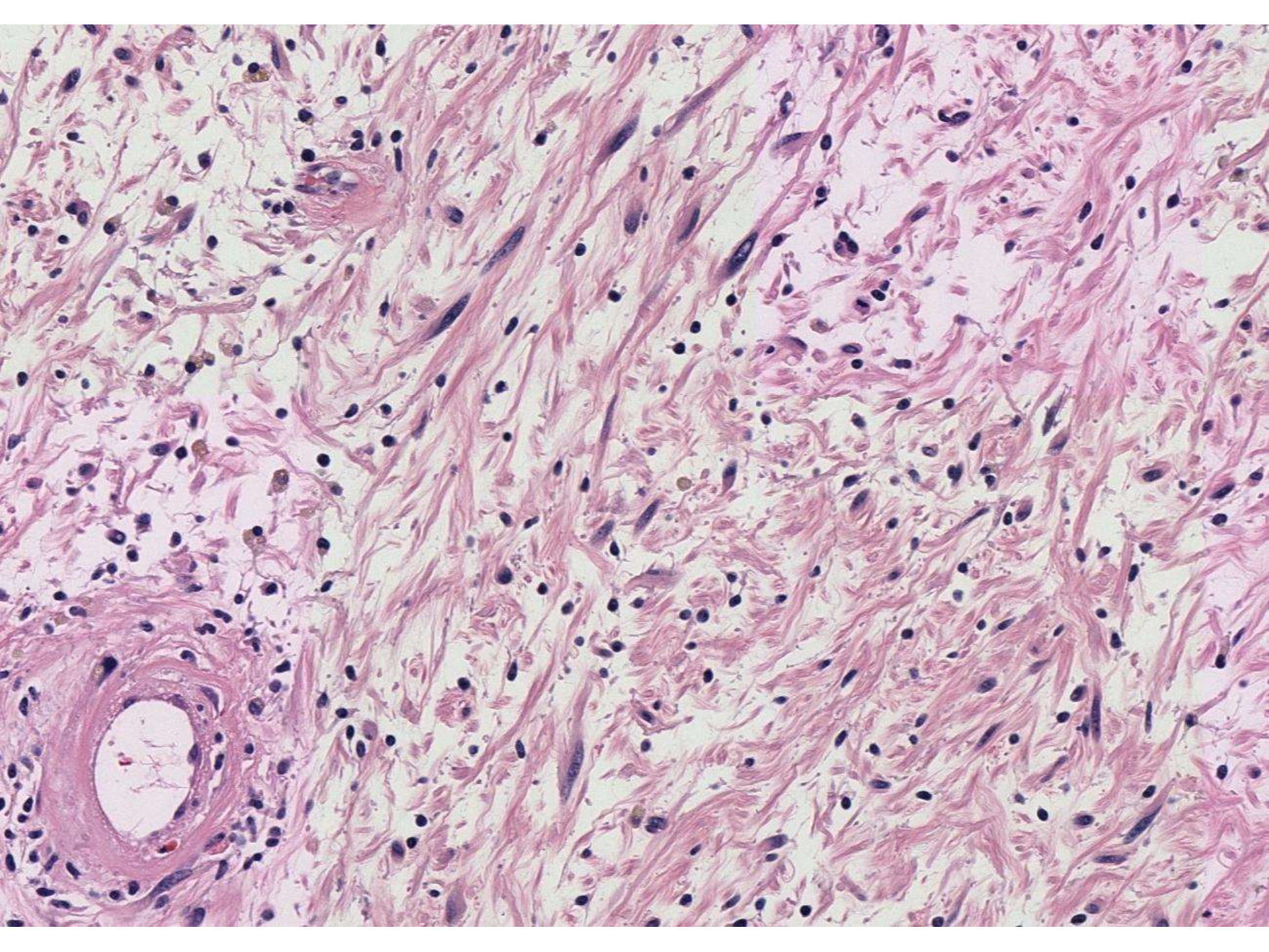


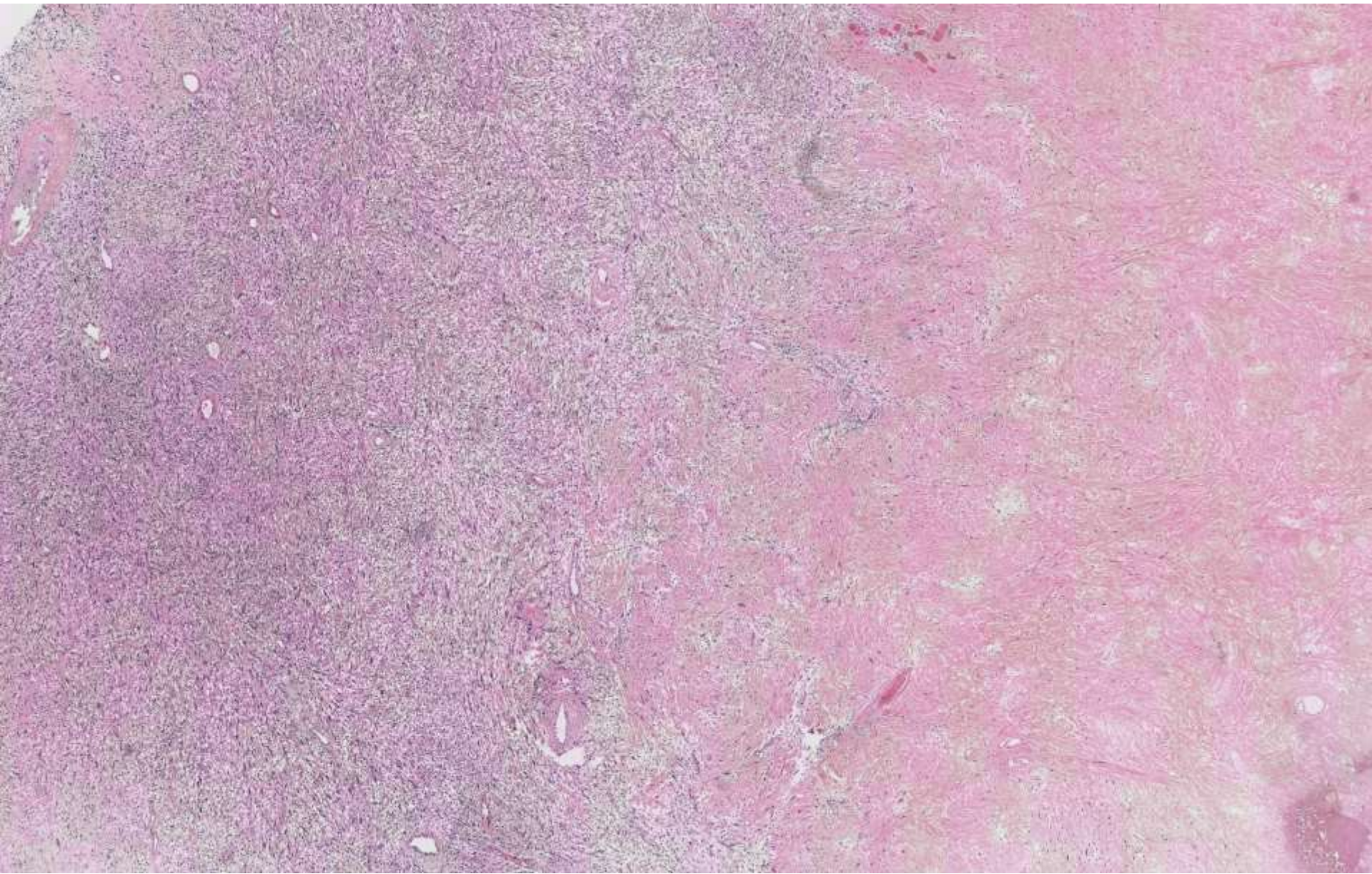


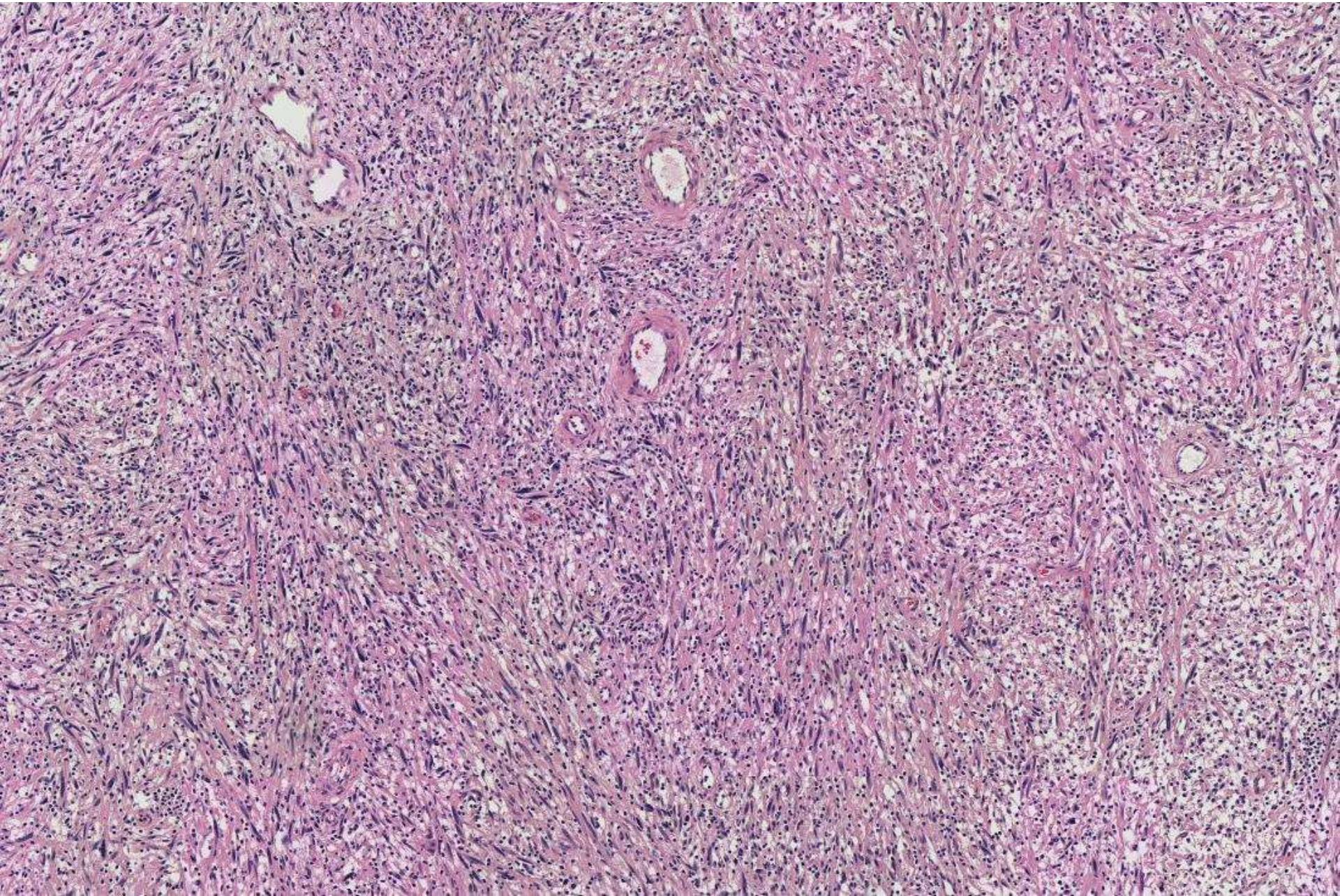


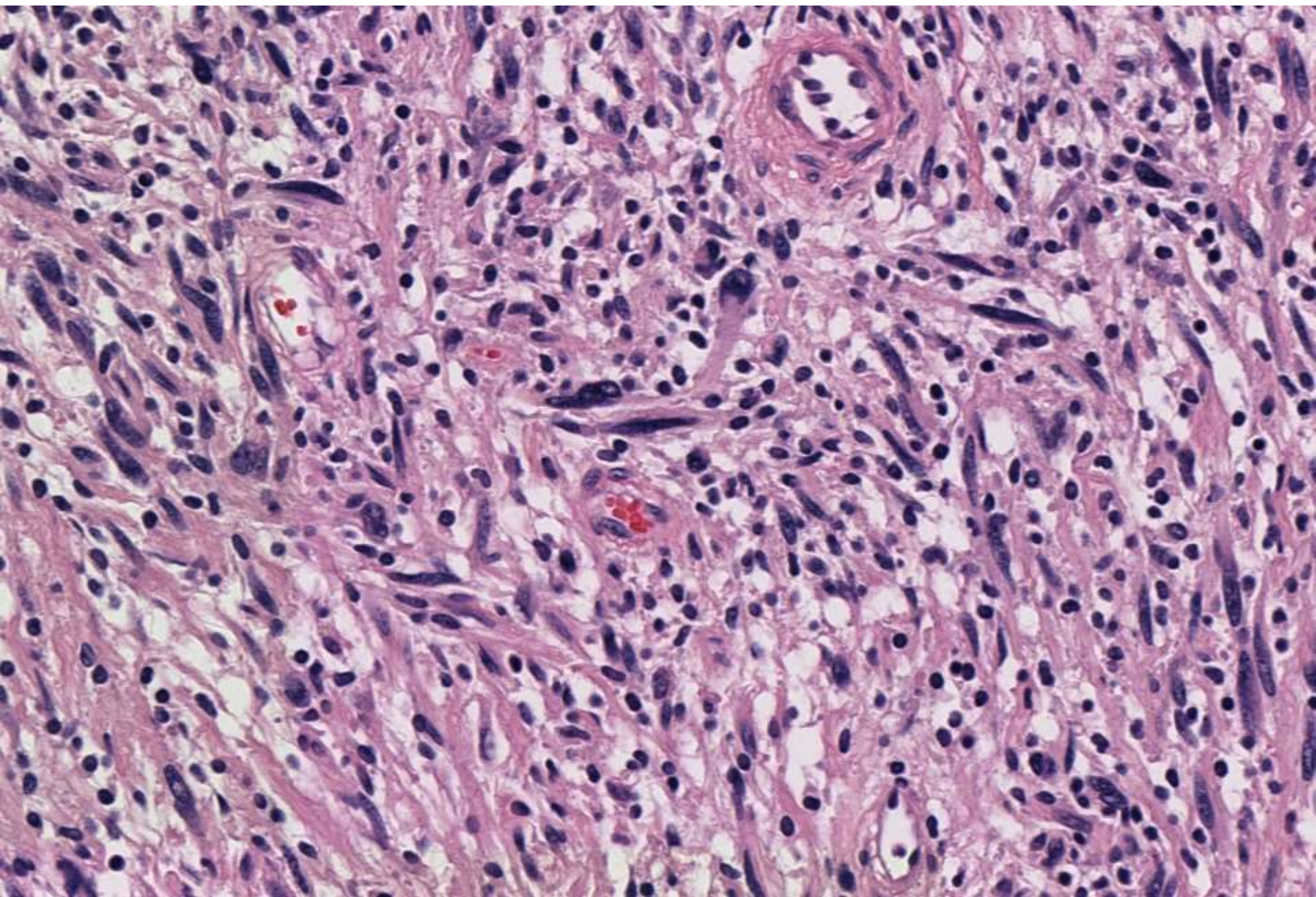


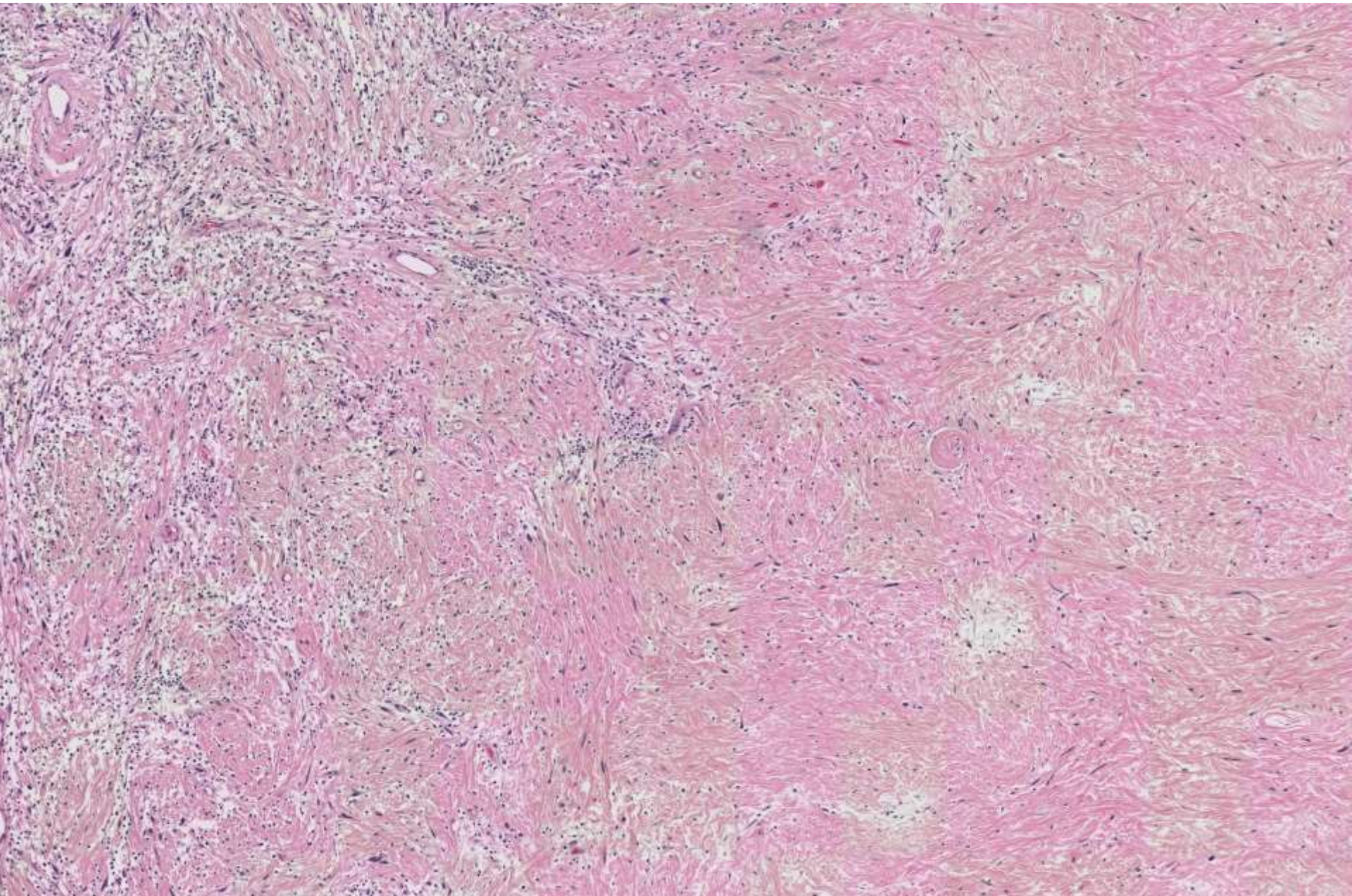




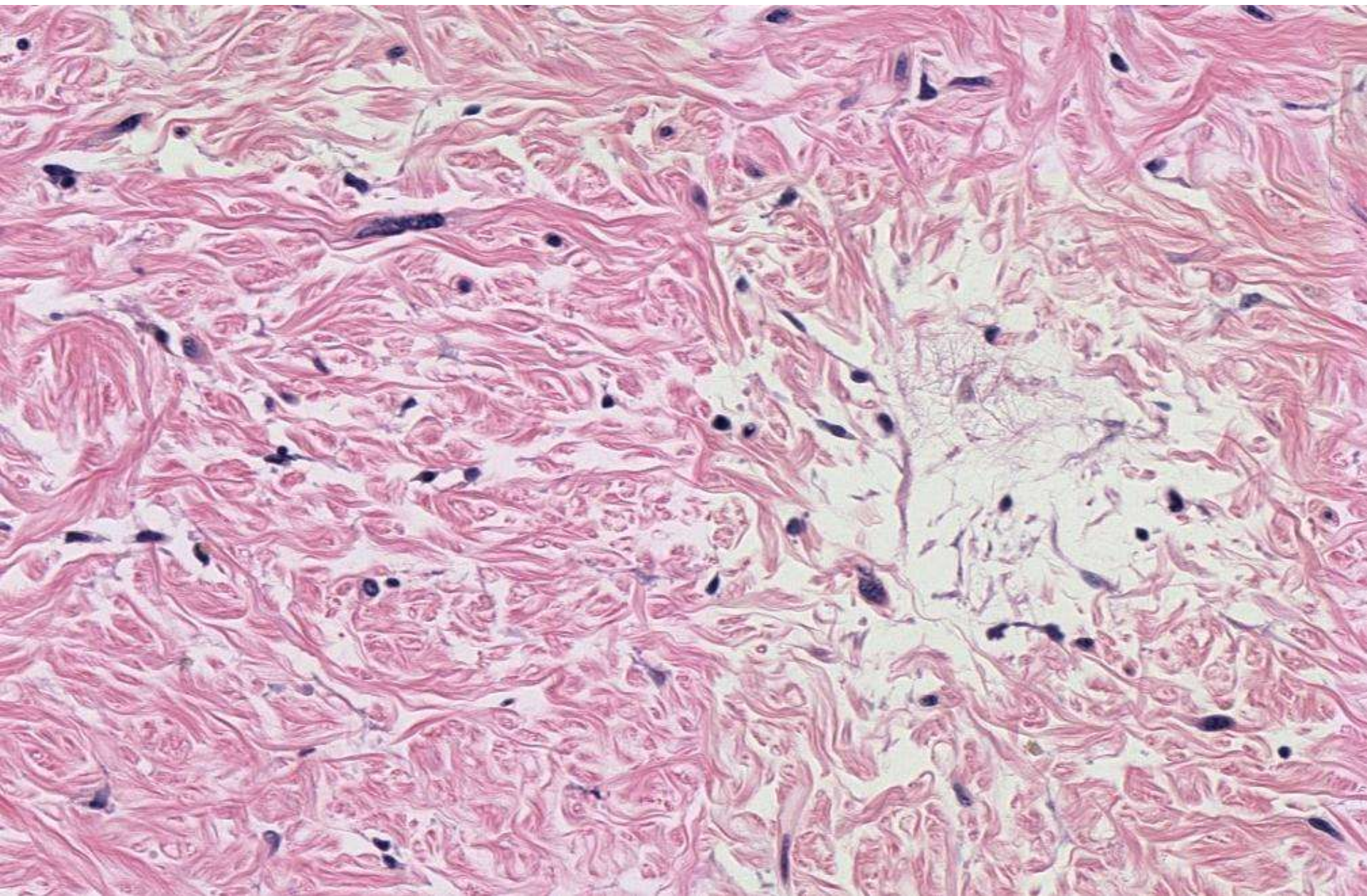


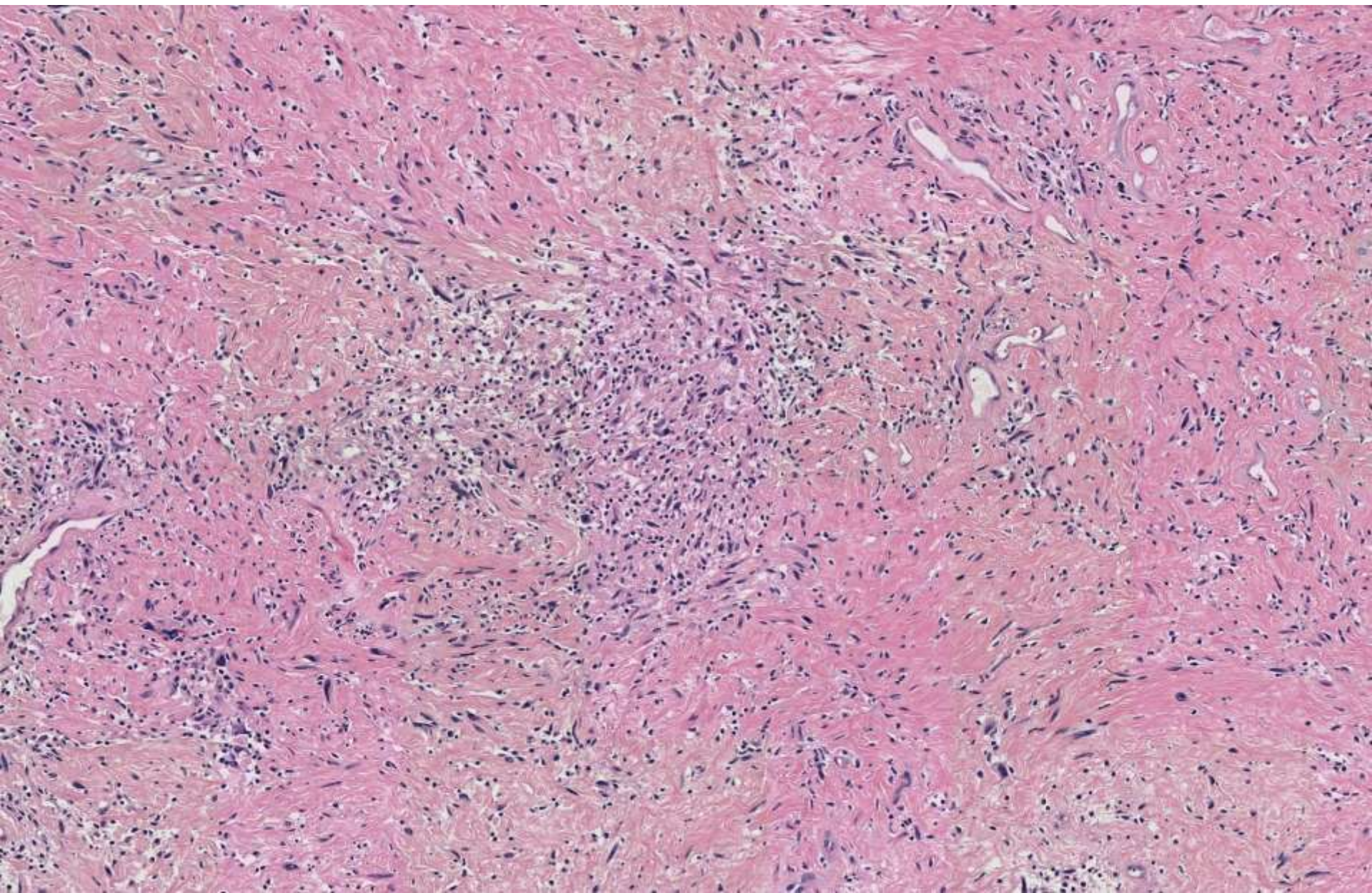










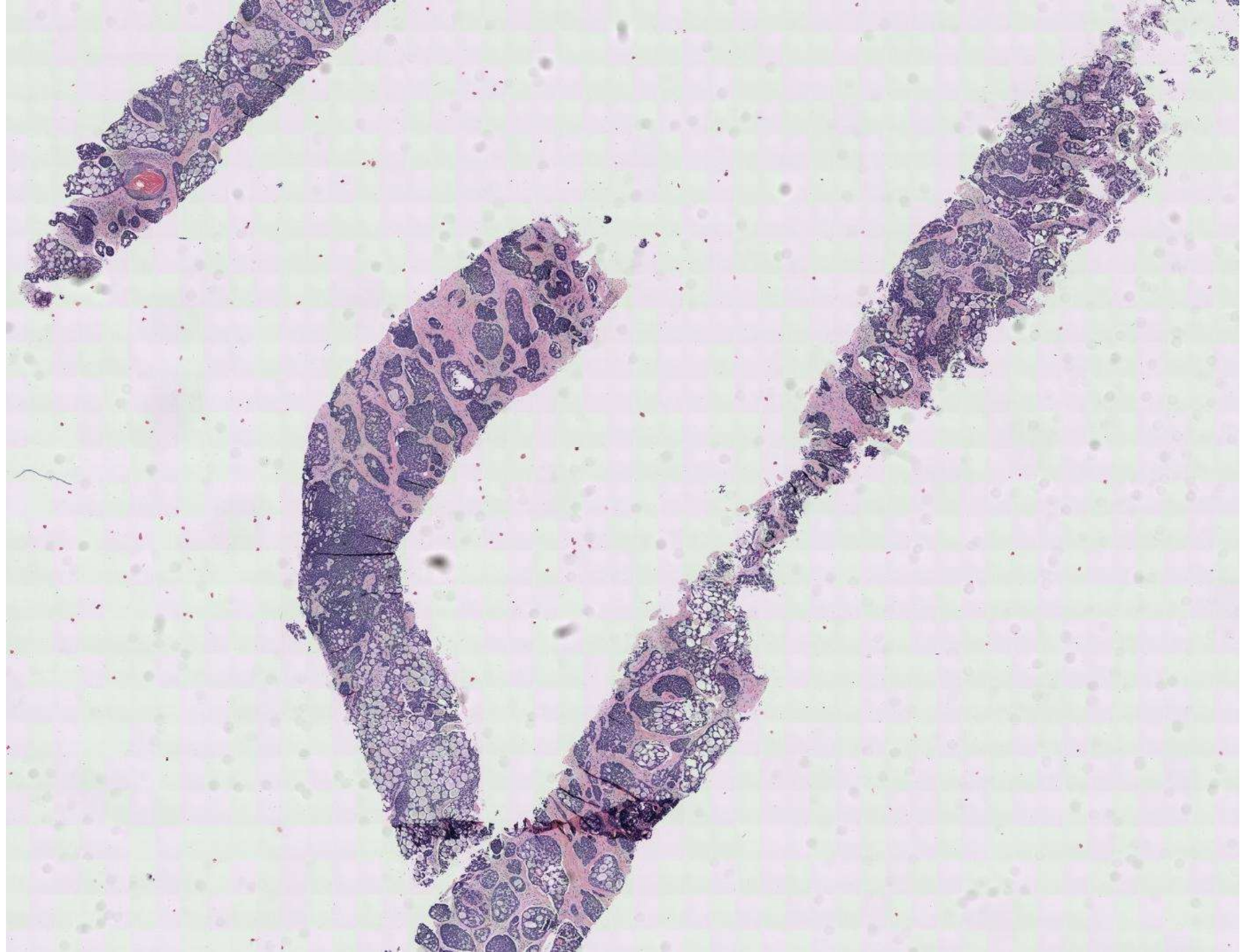


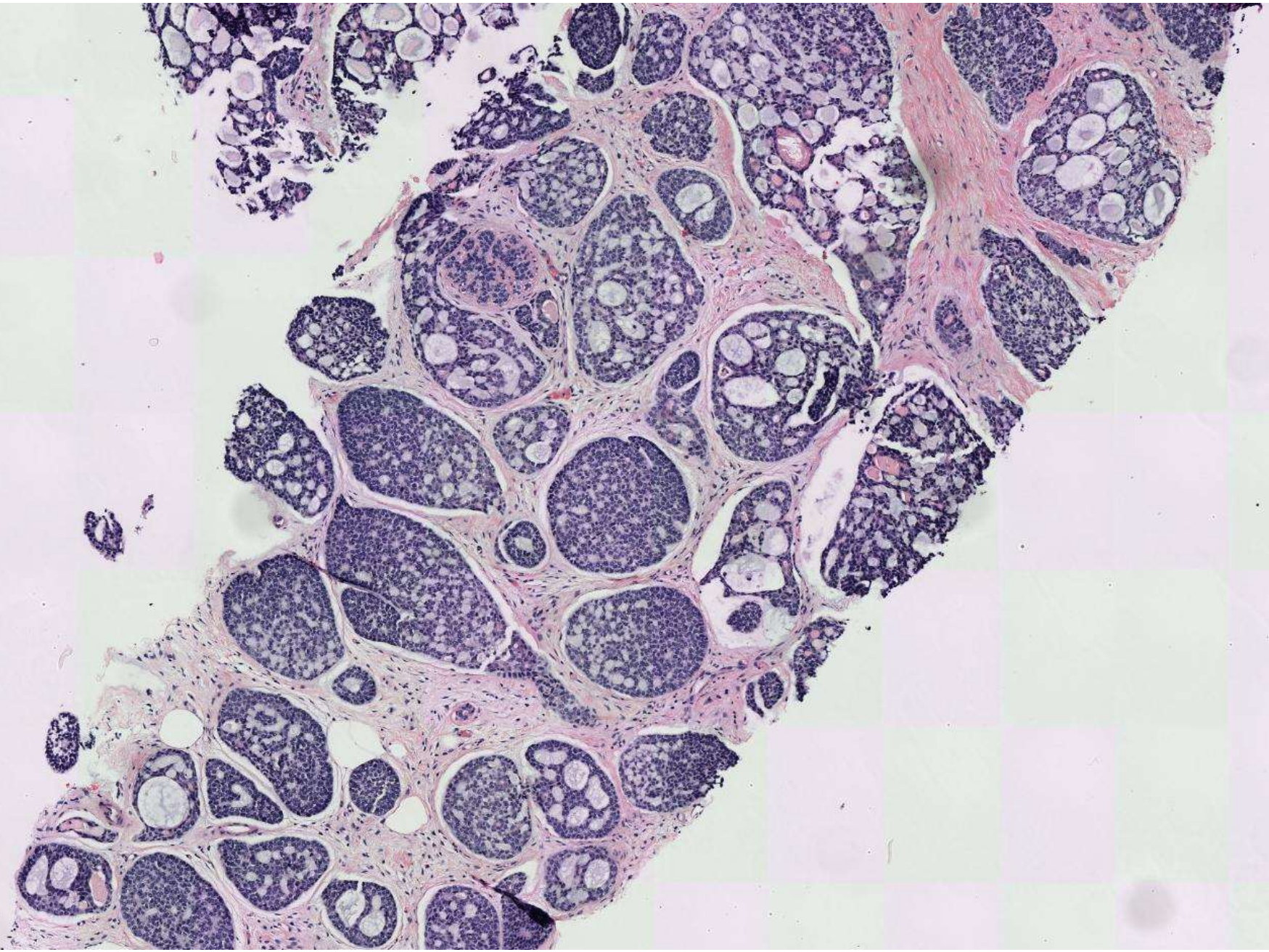
# 19-0704

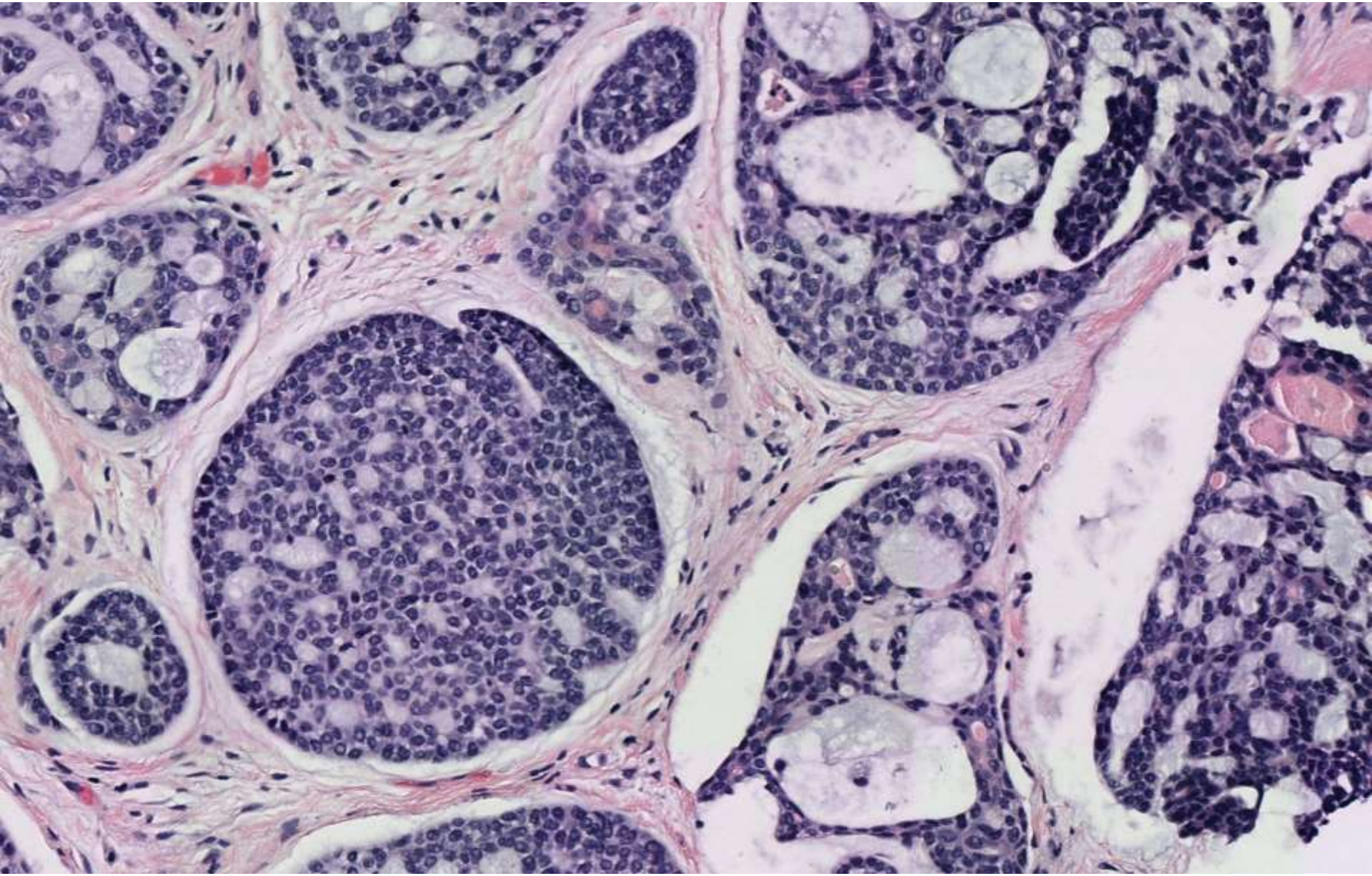
(scanned slide avail)

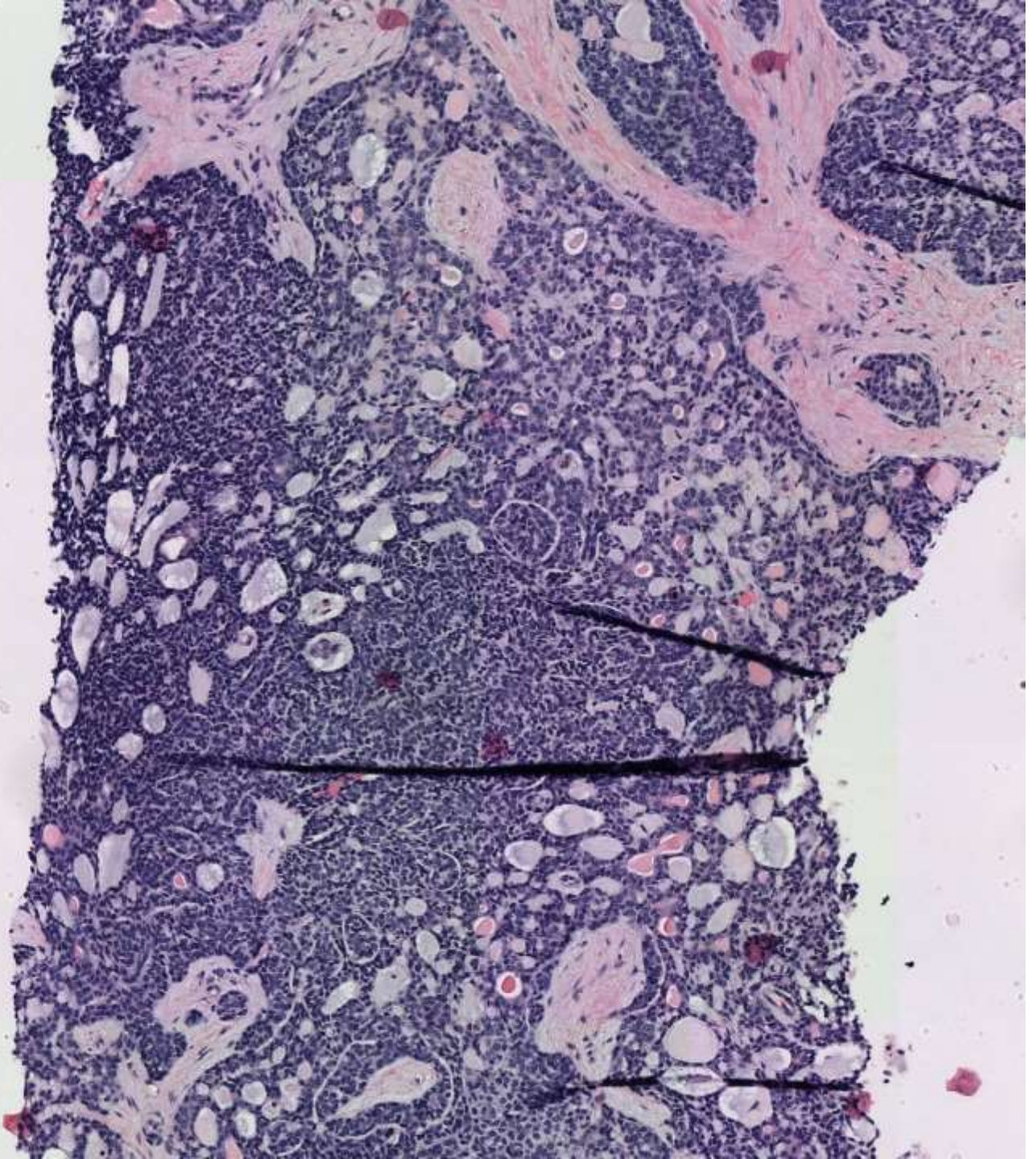Keith Duncan; Mills-Peninsula

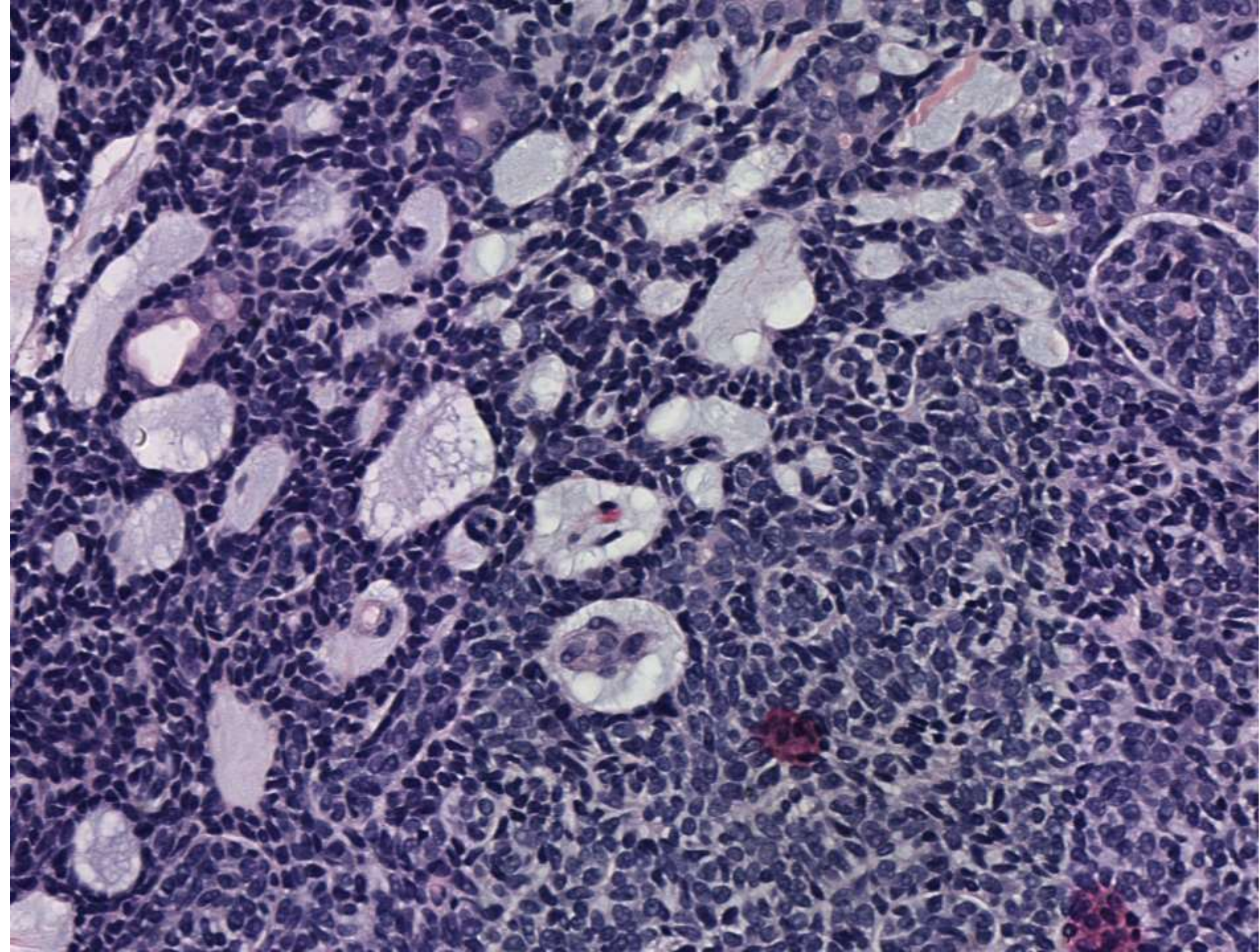
71-year-old female with solid breast  
mass, biopsied.



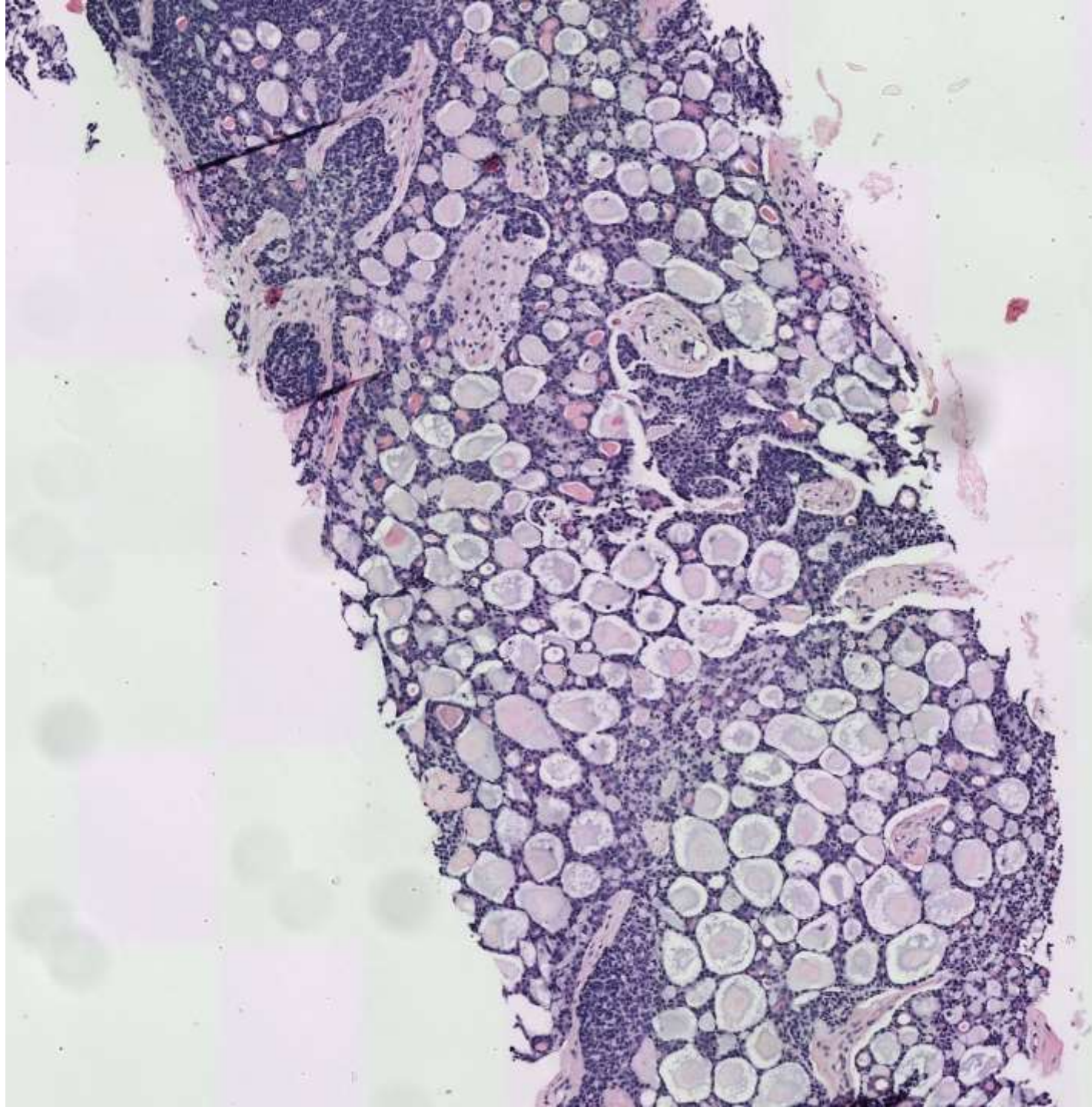


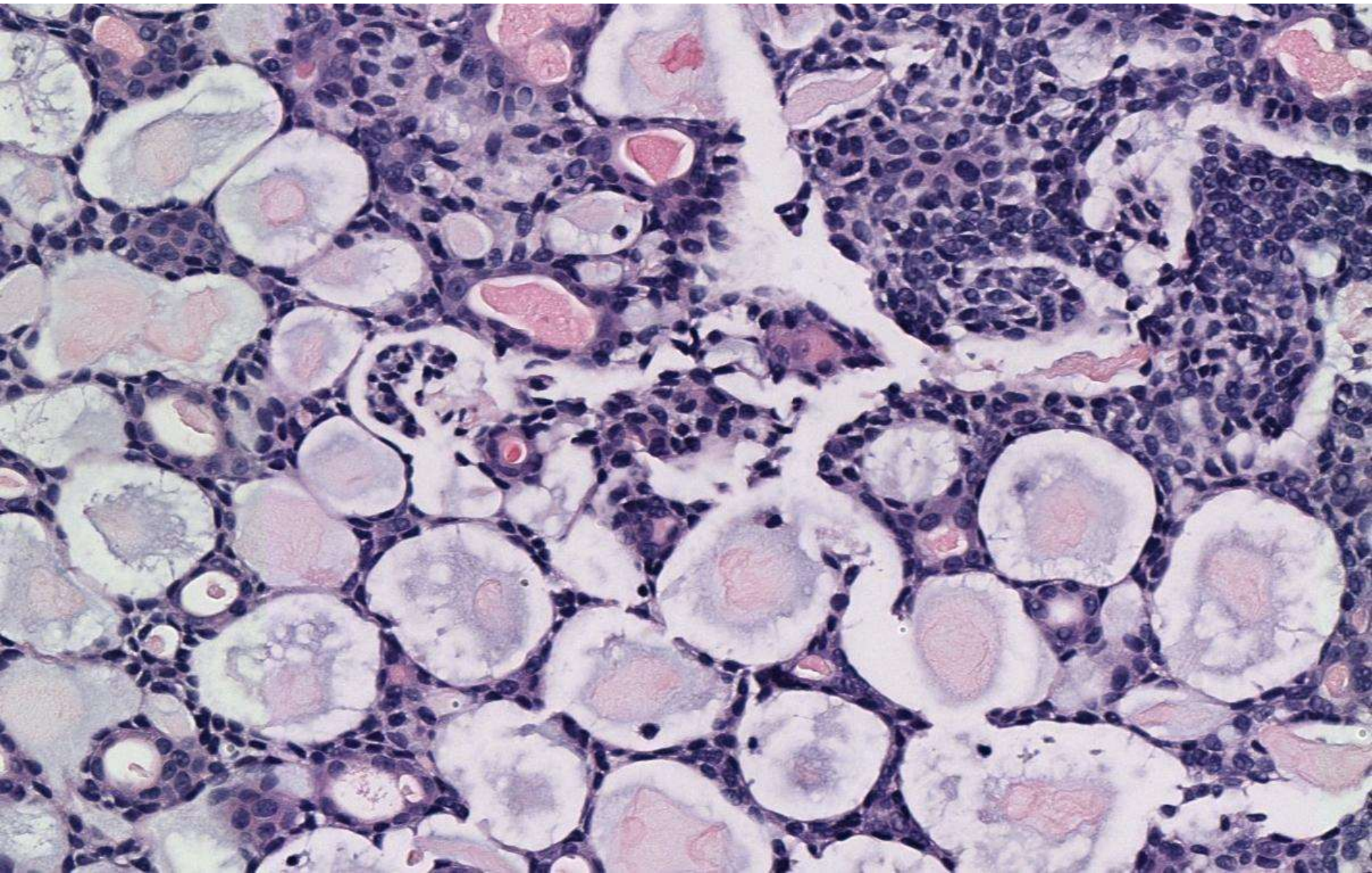








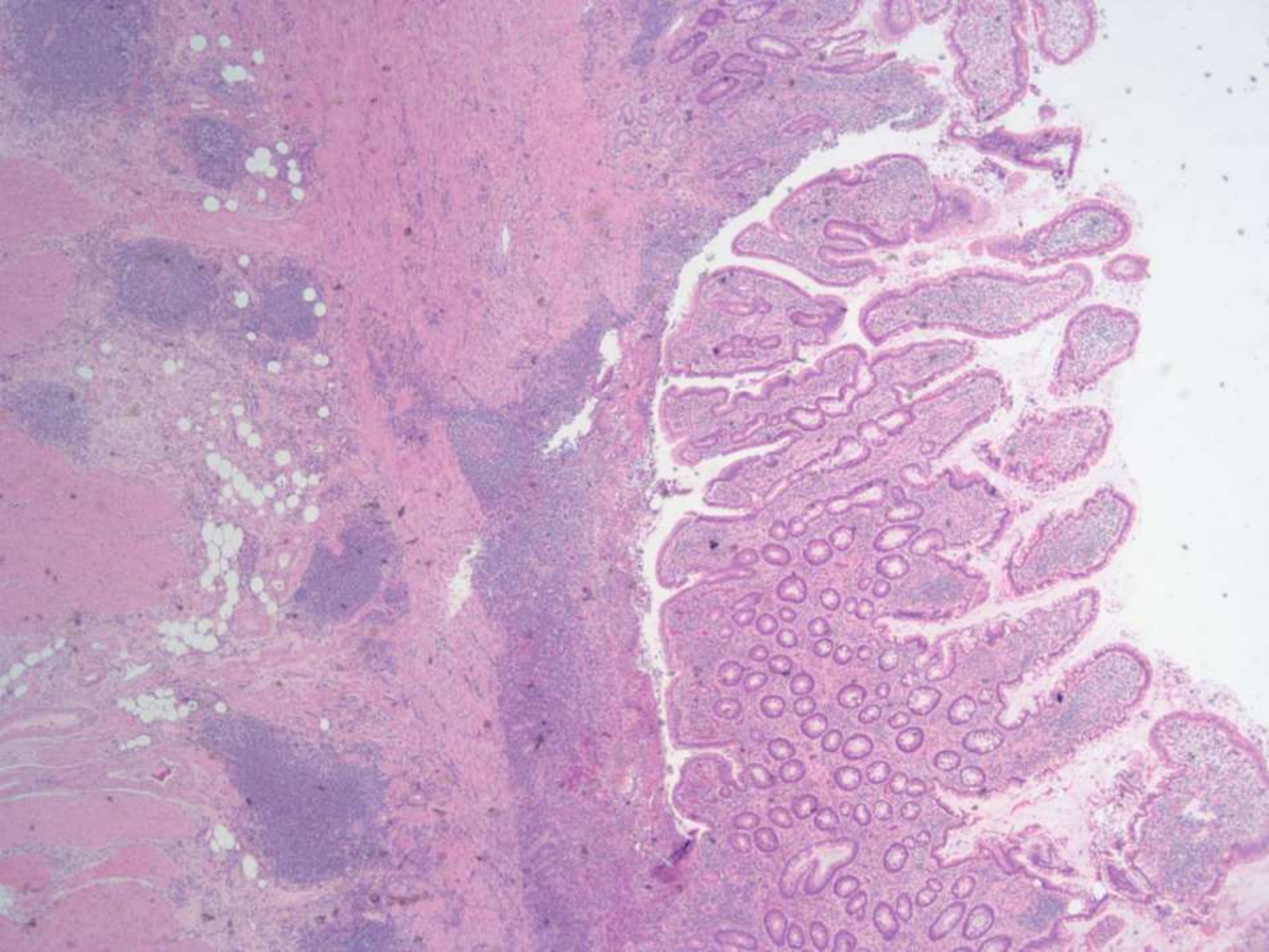


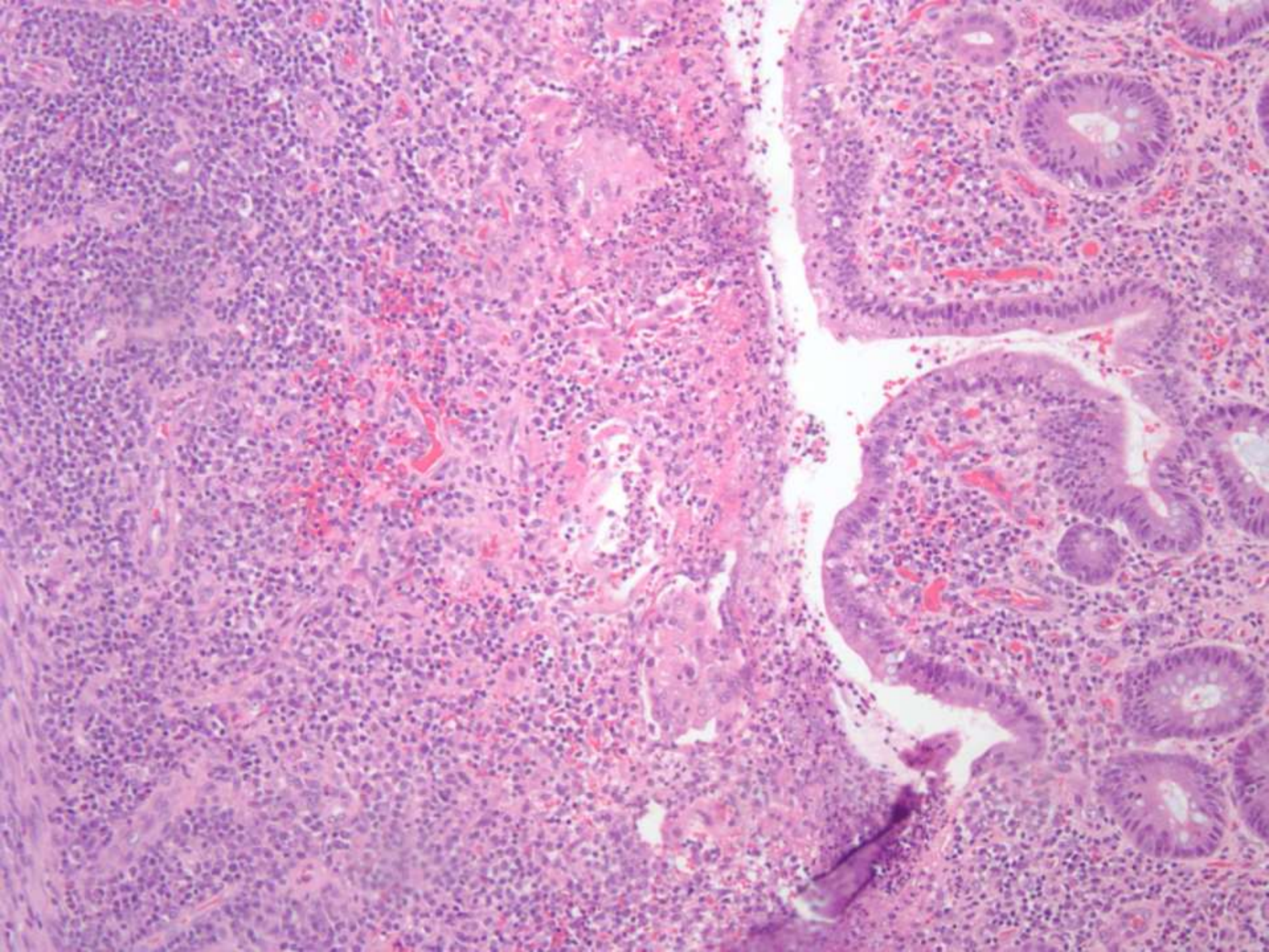


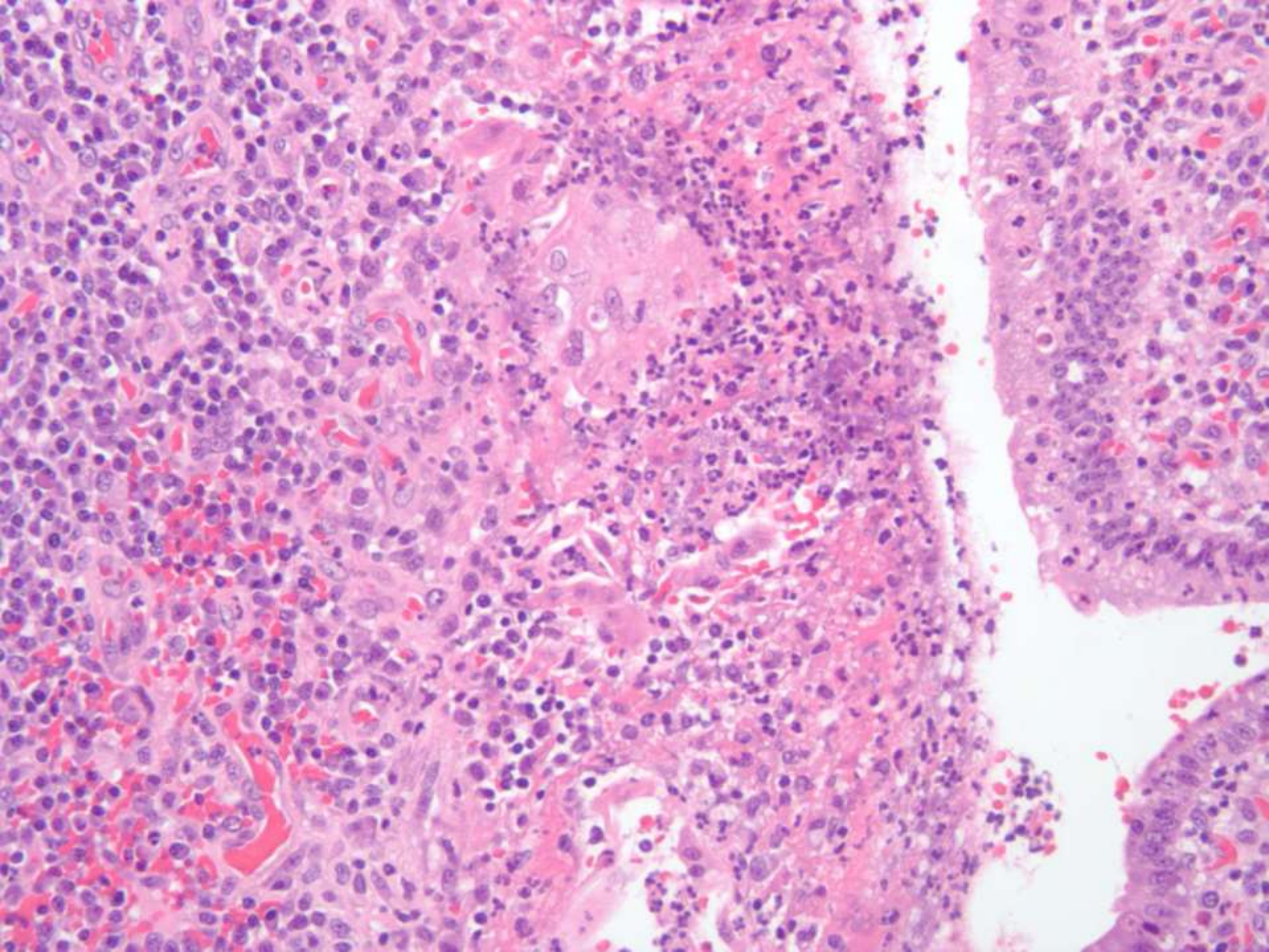
# 19-0705

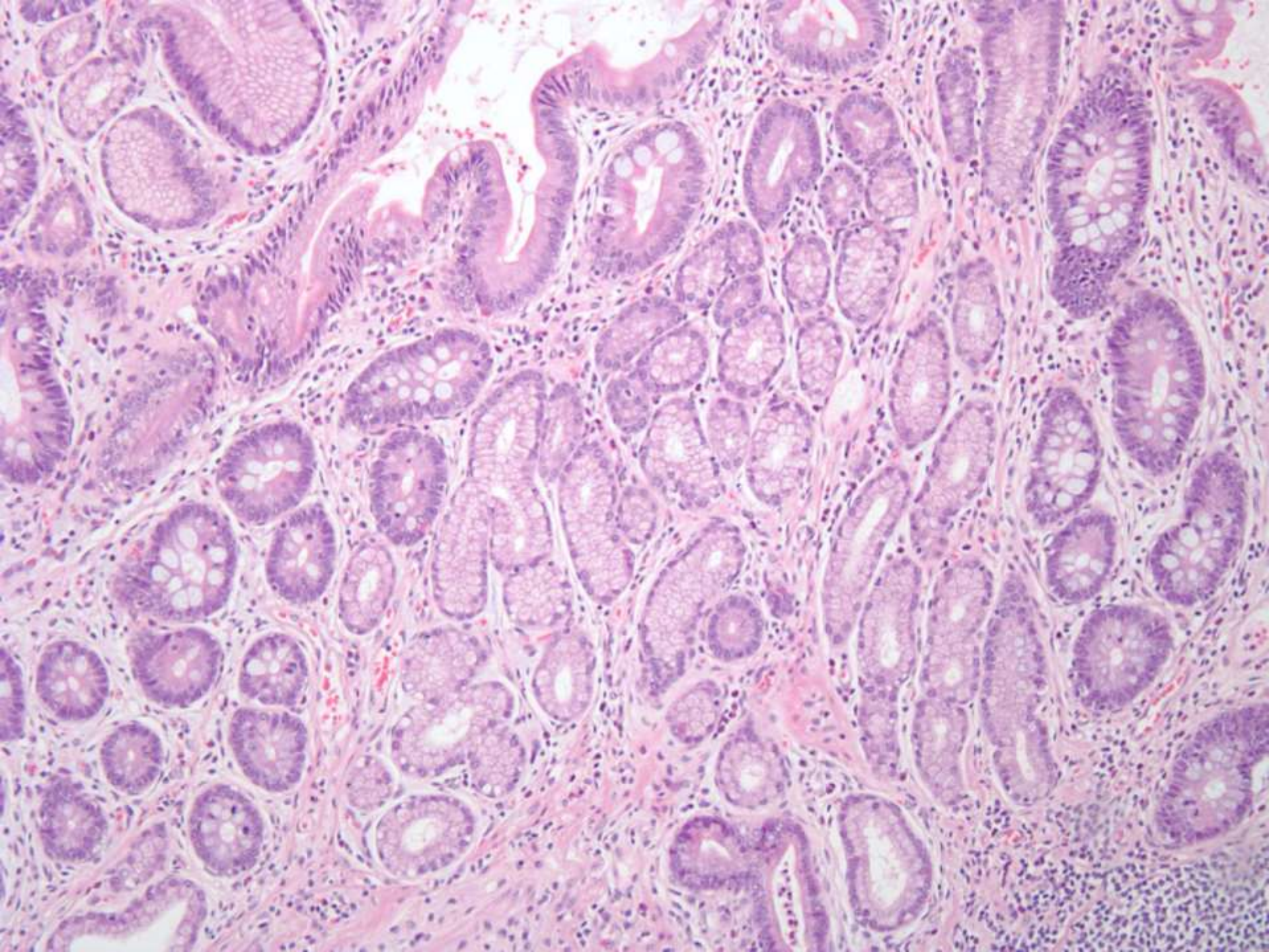
Charles Lombard; El Camino Hospital

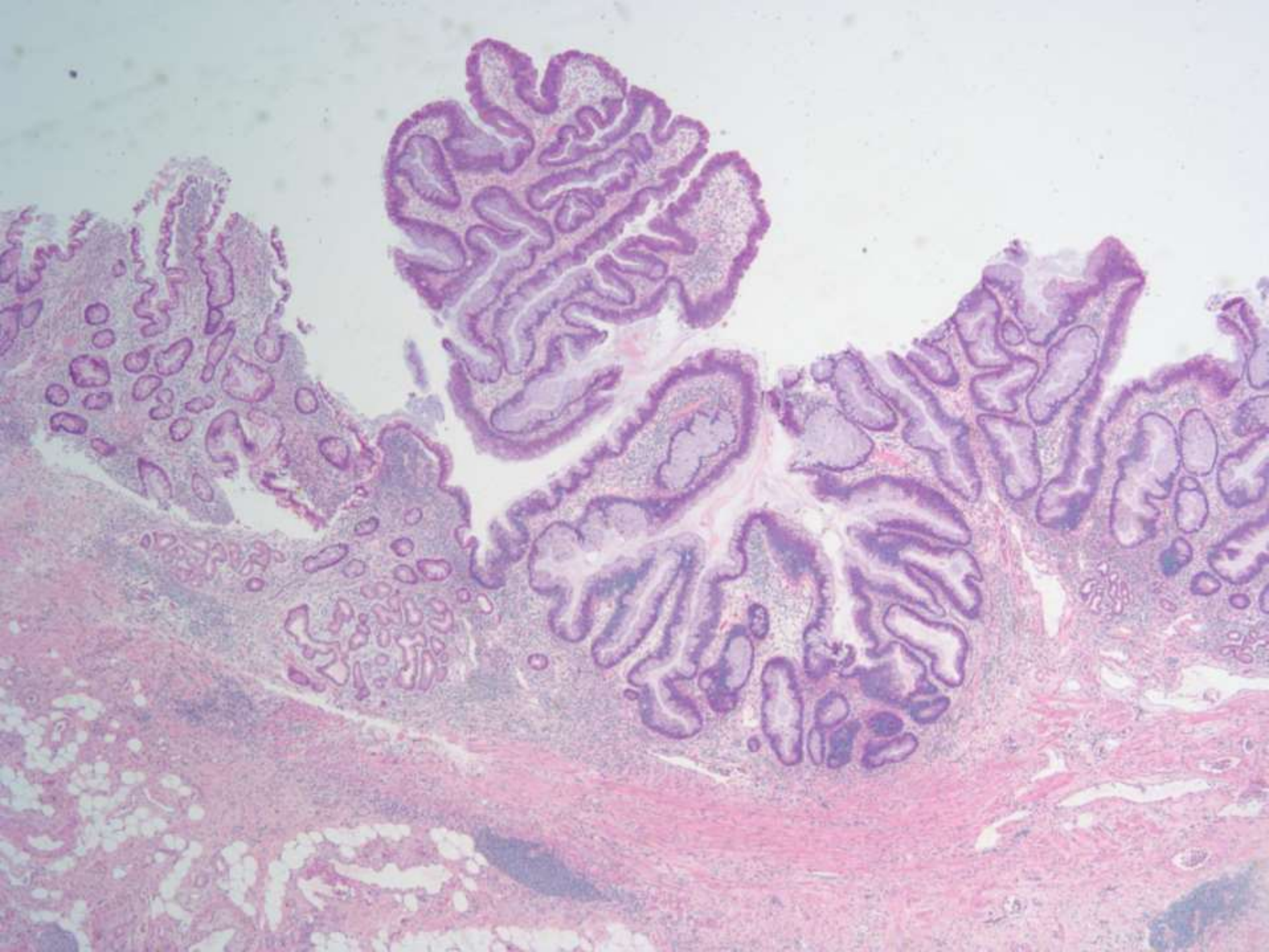
69-year-old woman undergoes  
ileocolonic resection for obstruction.



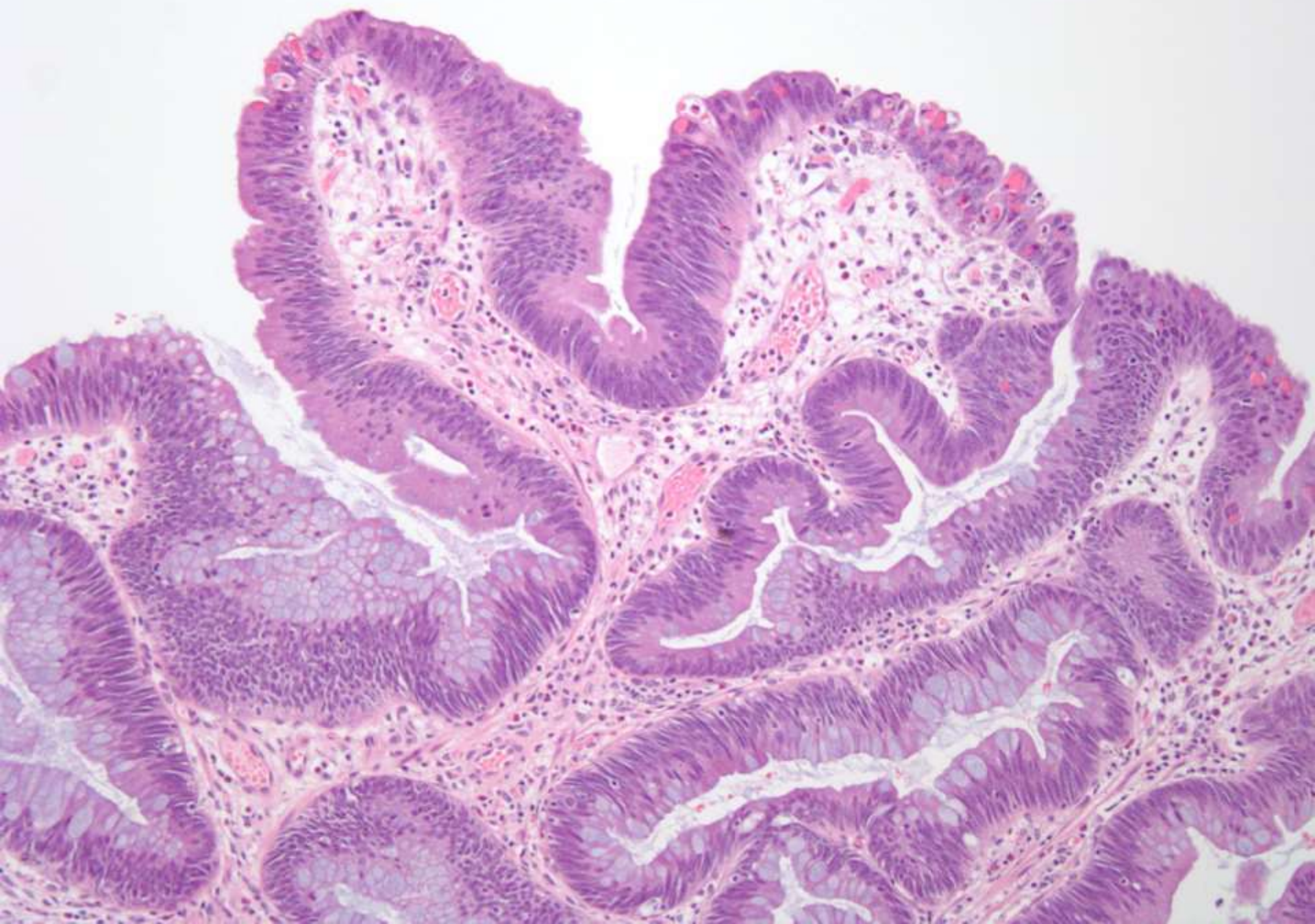


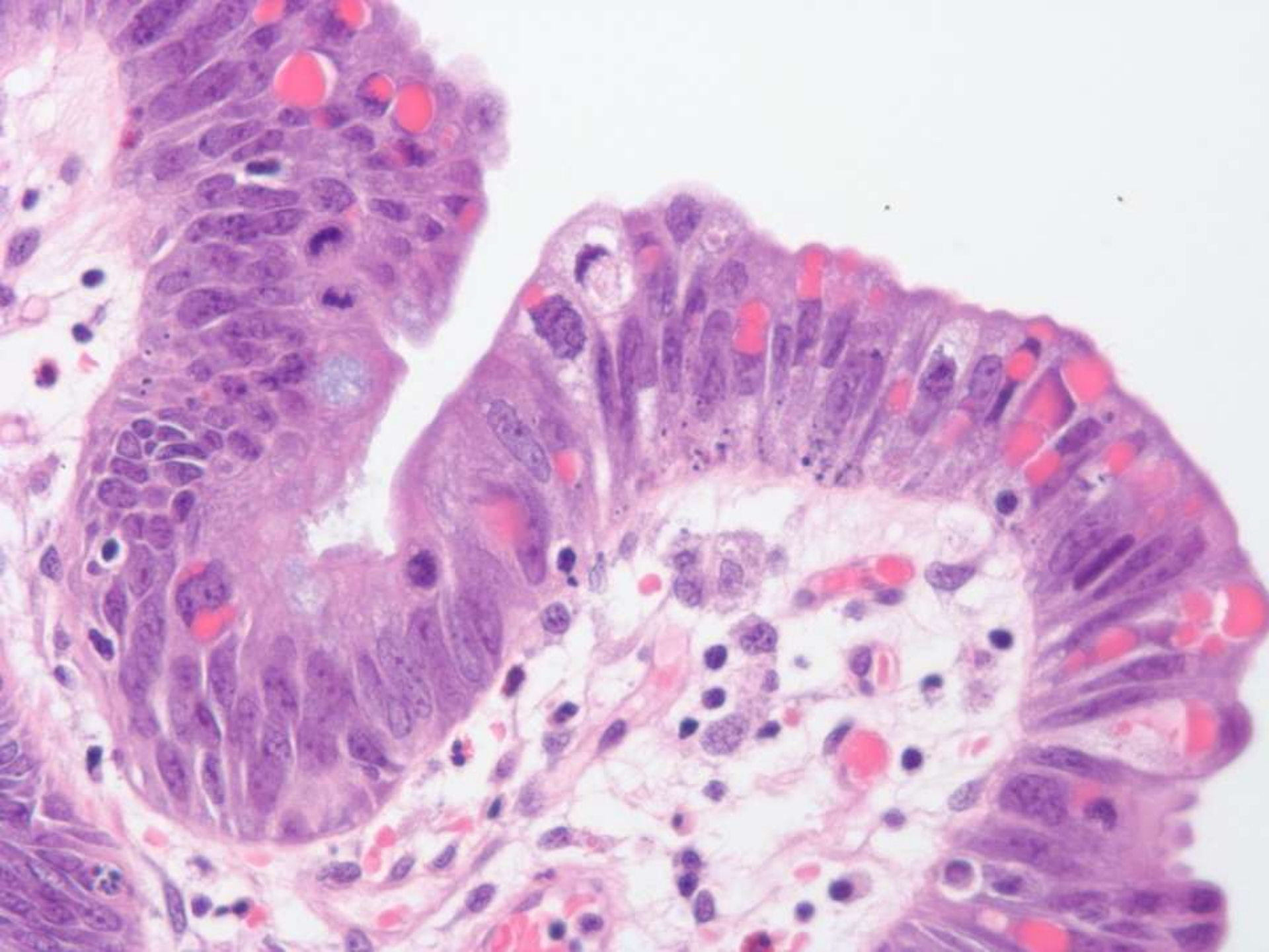


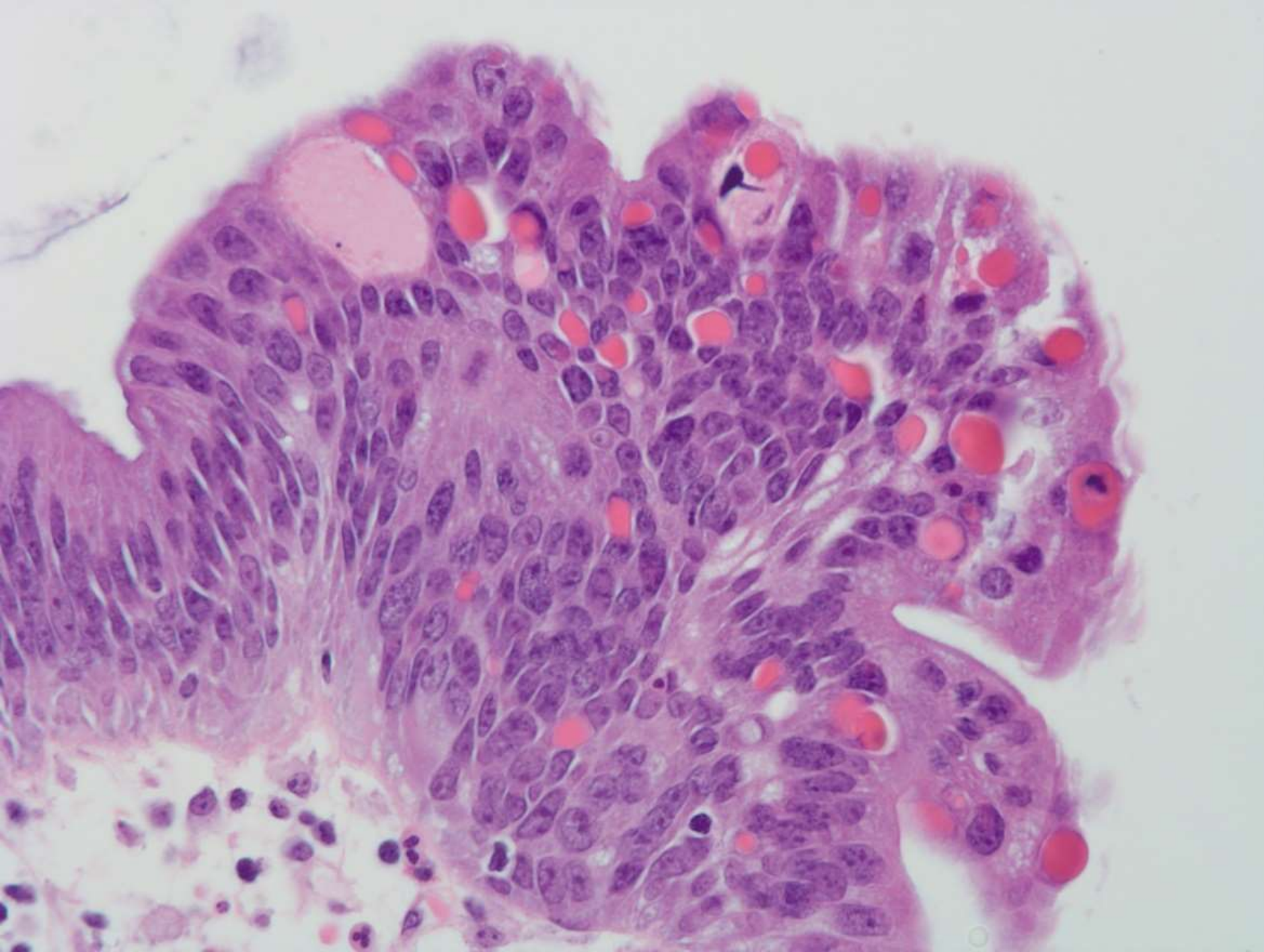




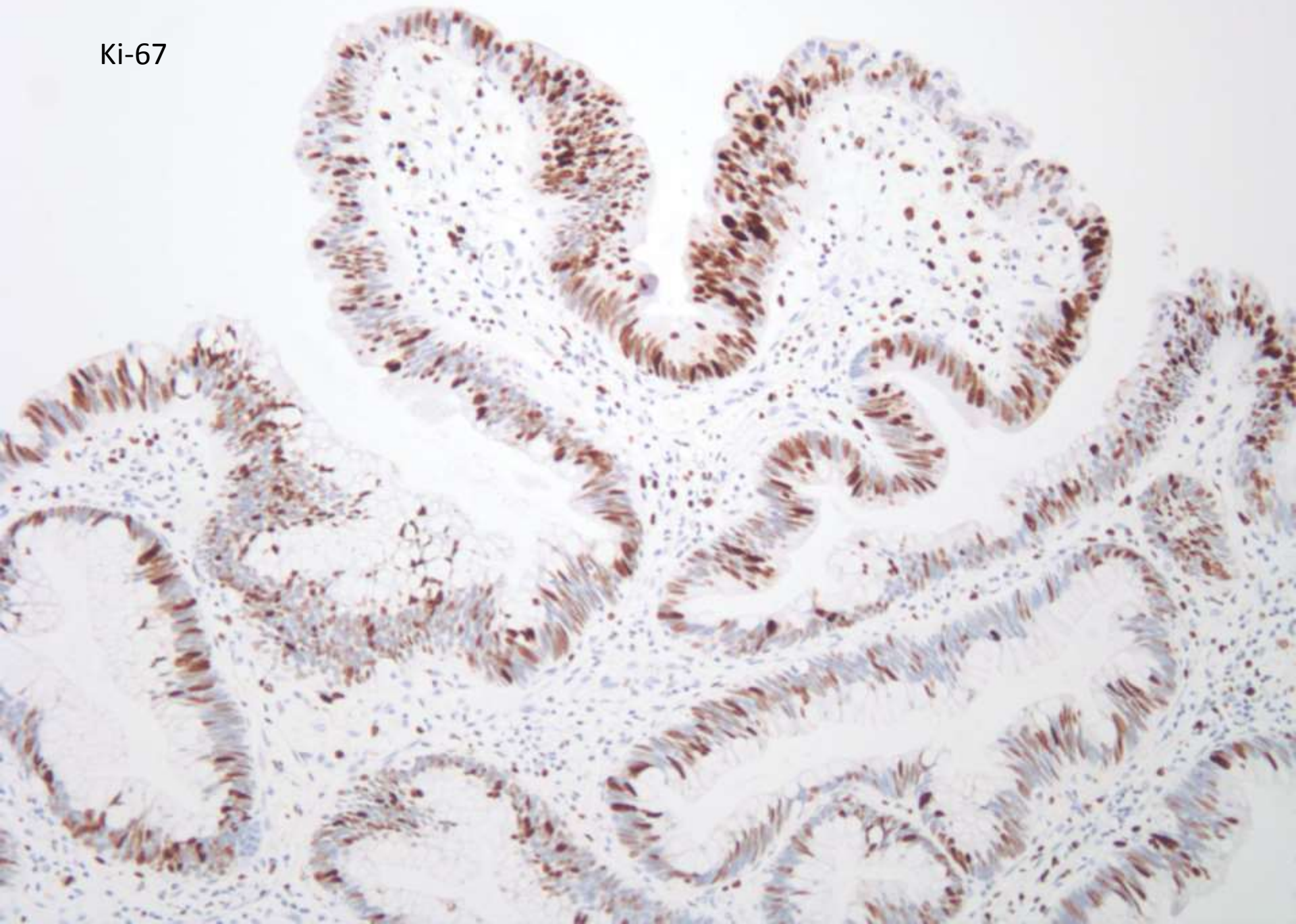








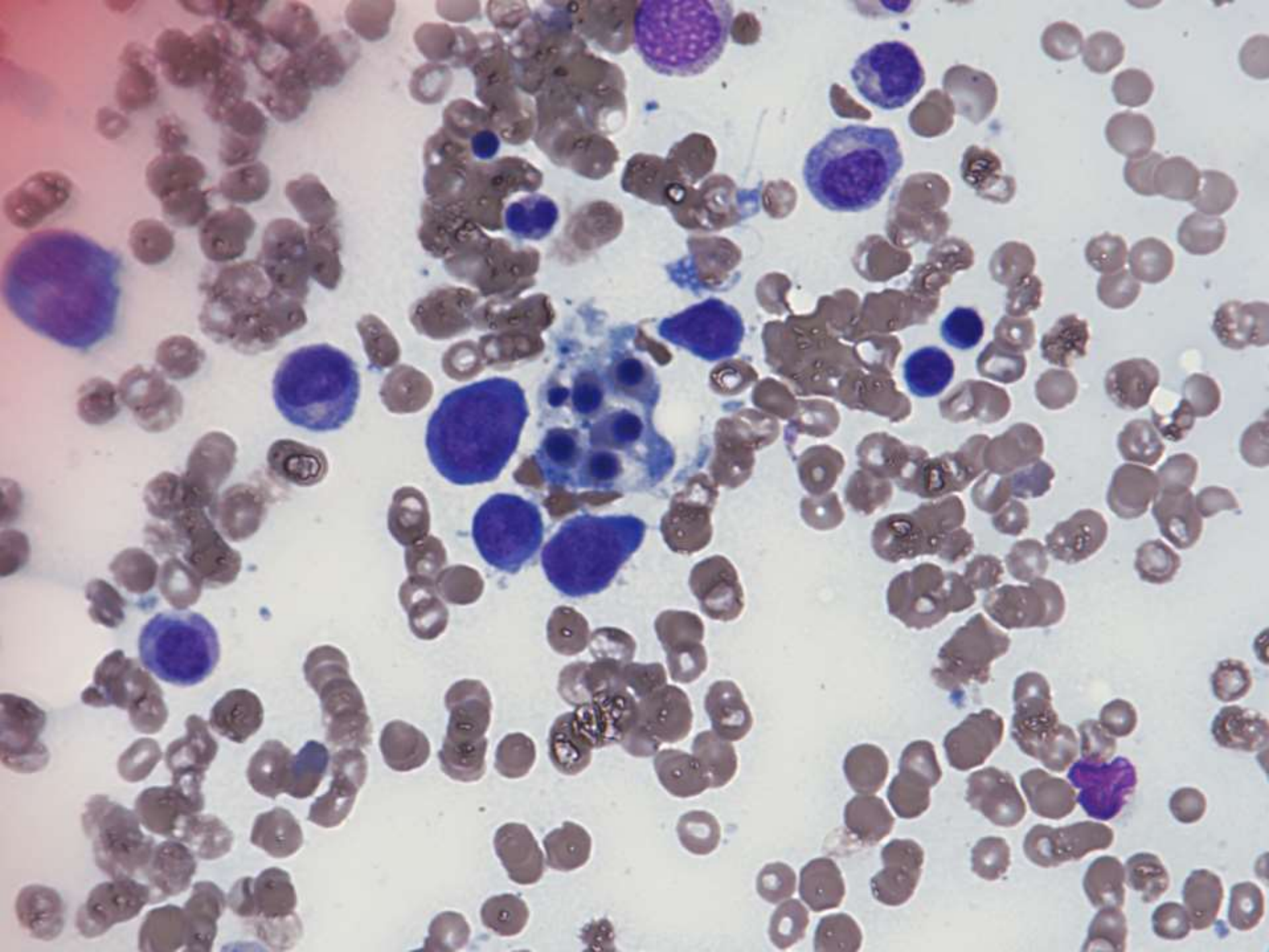
Ki-67

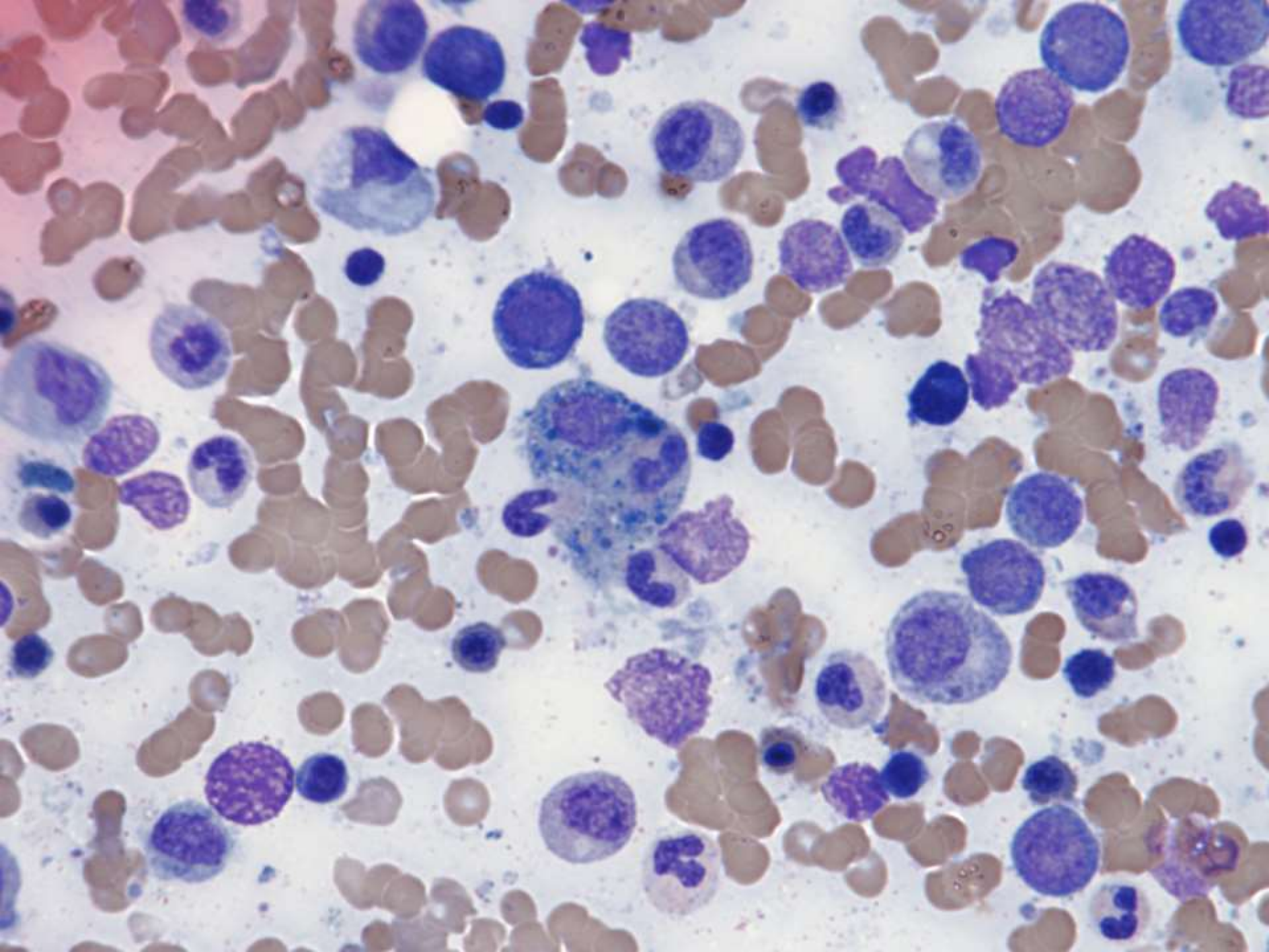


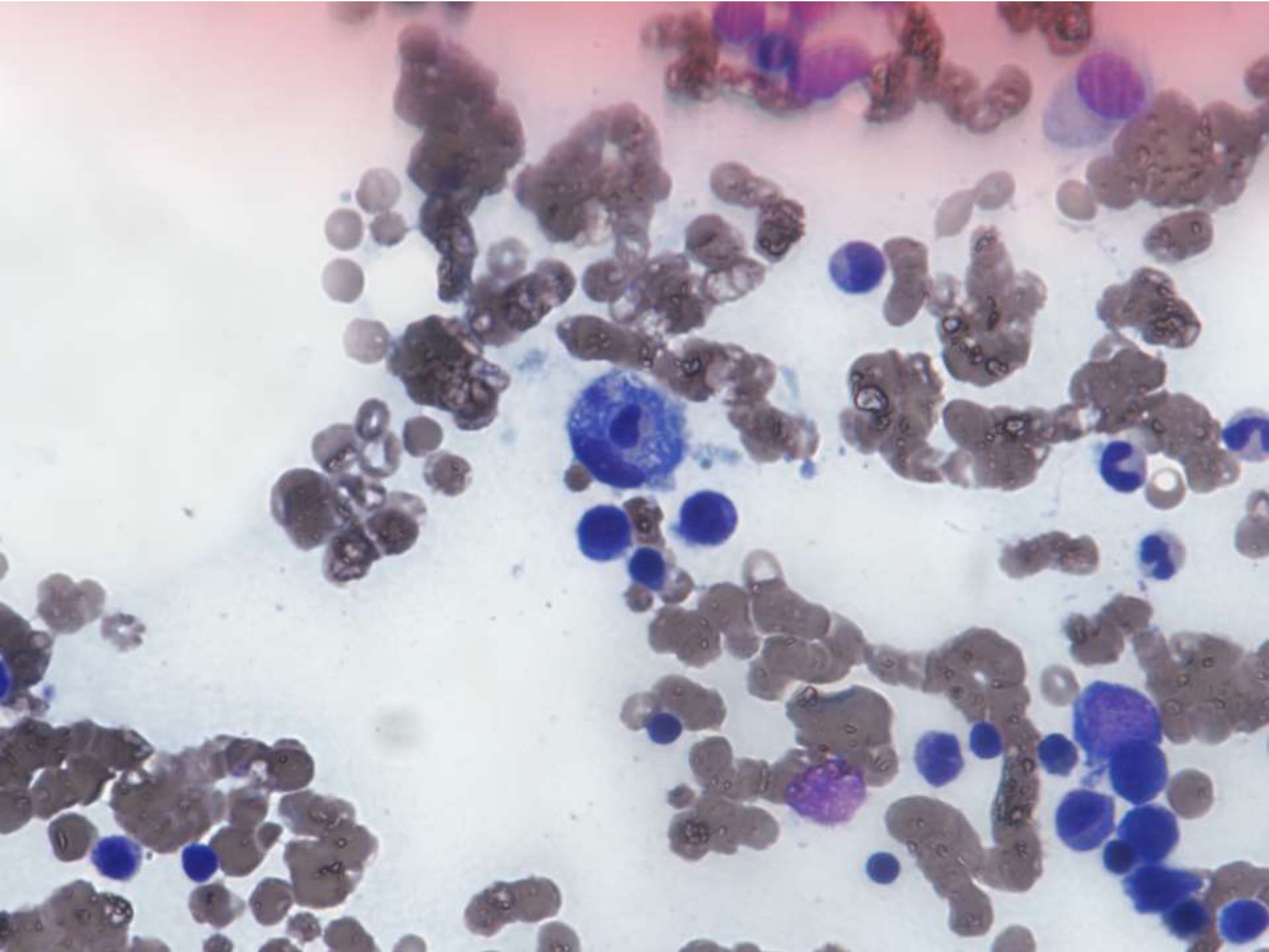
# 19-0706

Sebastian Fernandez-Pol/Dita  
Gratzinger; Stanford

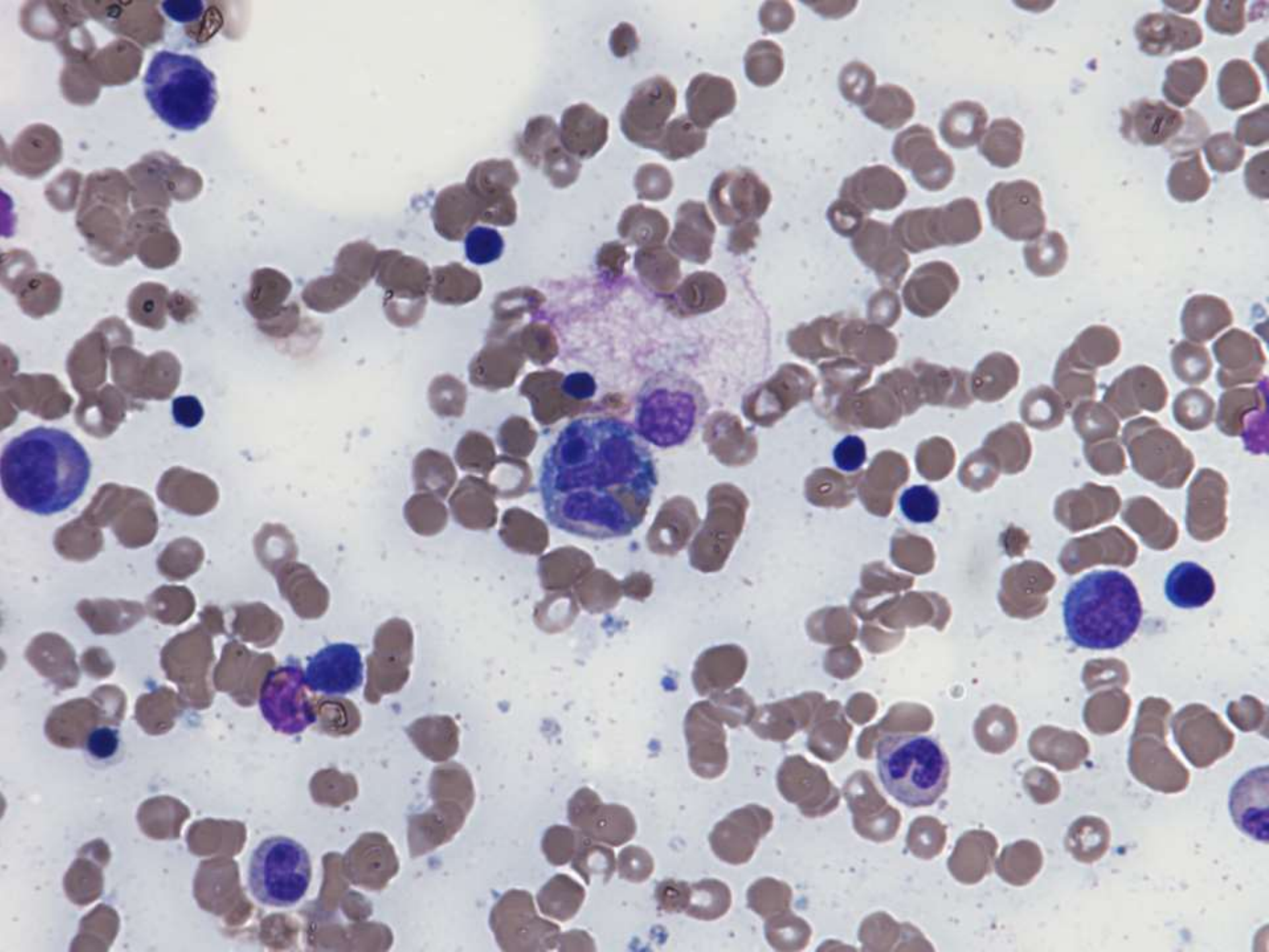
40-year-old man with no significant  
past medical history undergoes bone  
marrow biopsy.

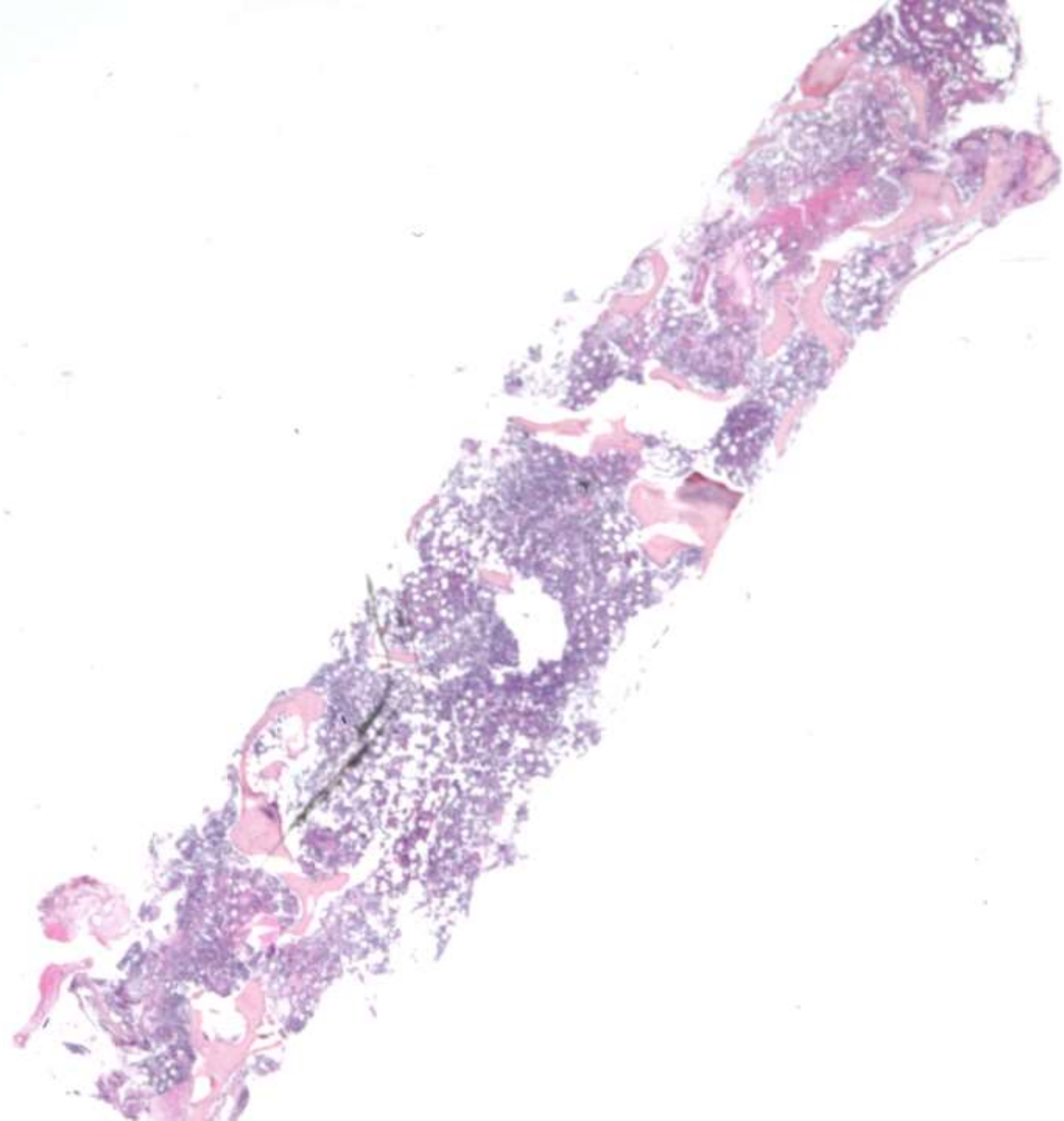


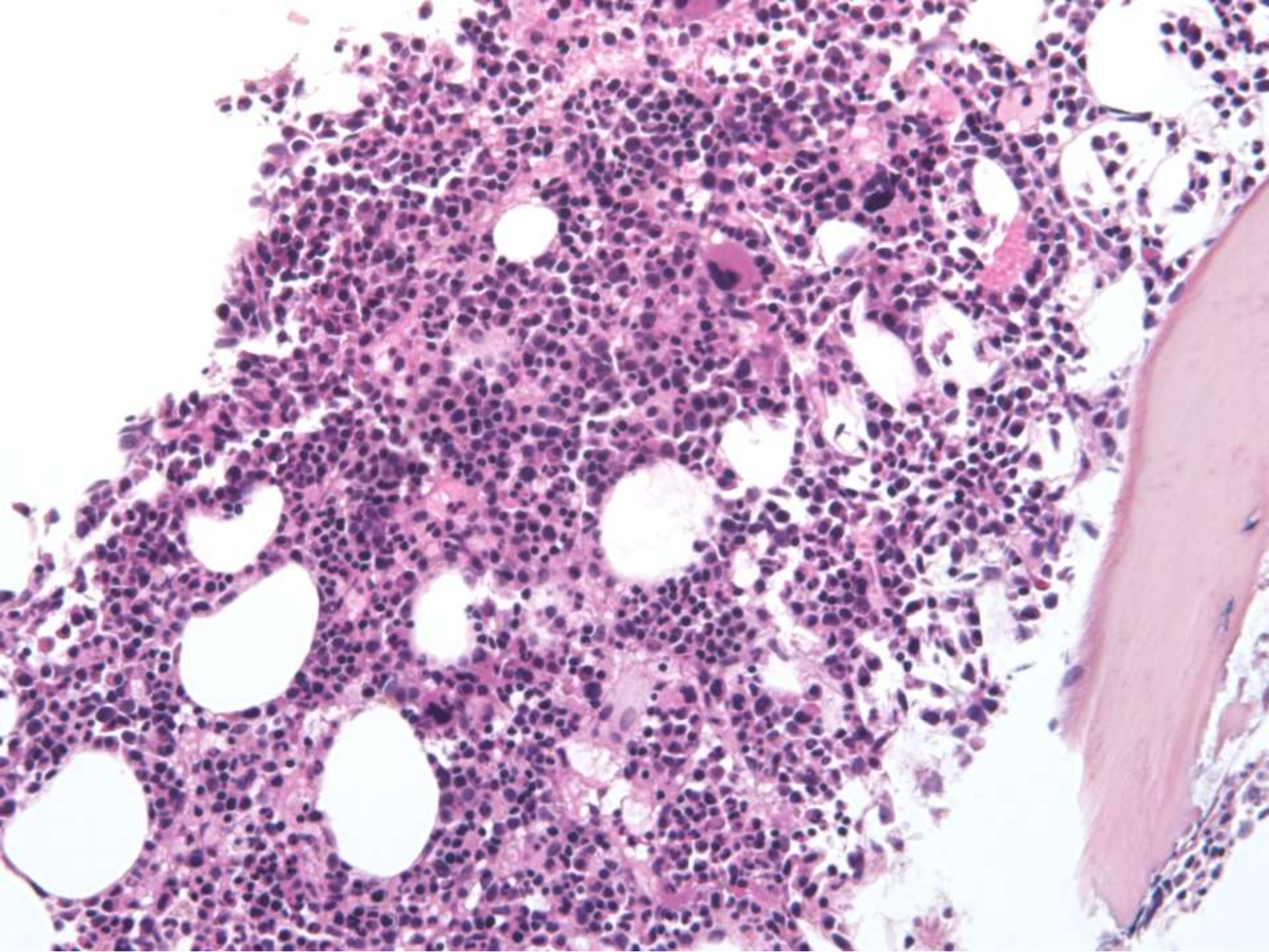


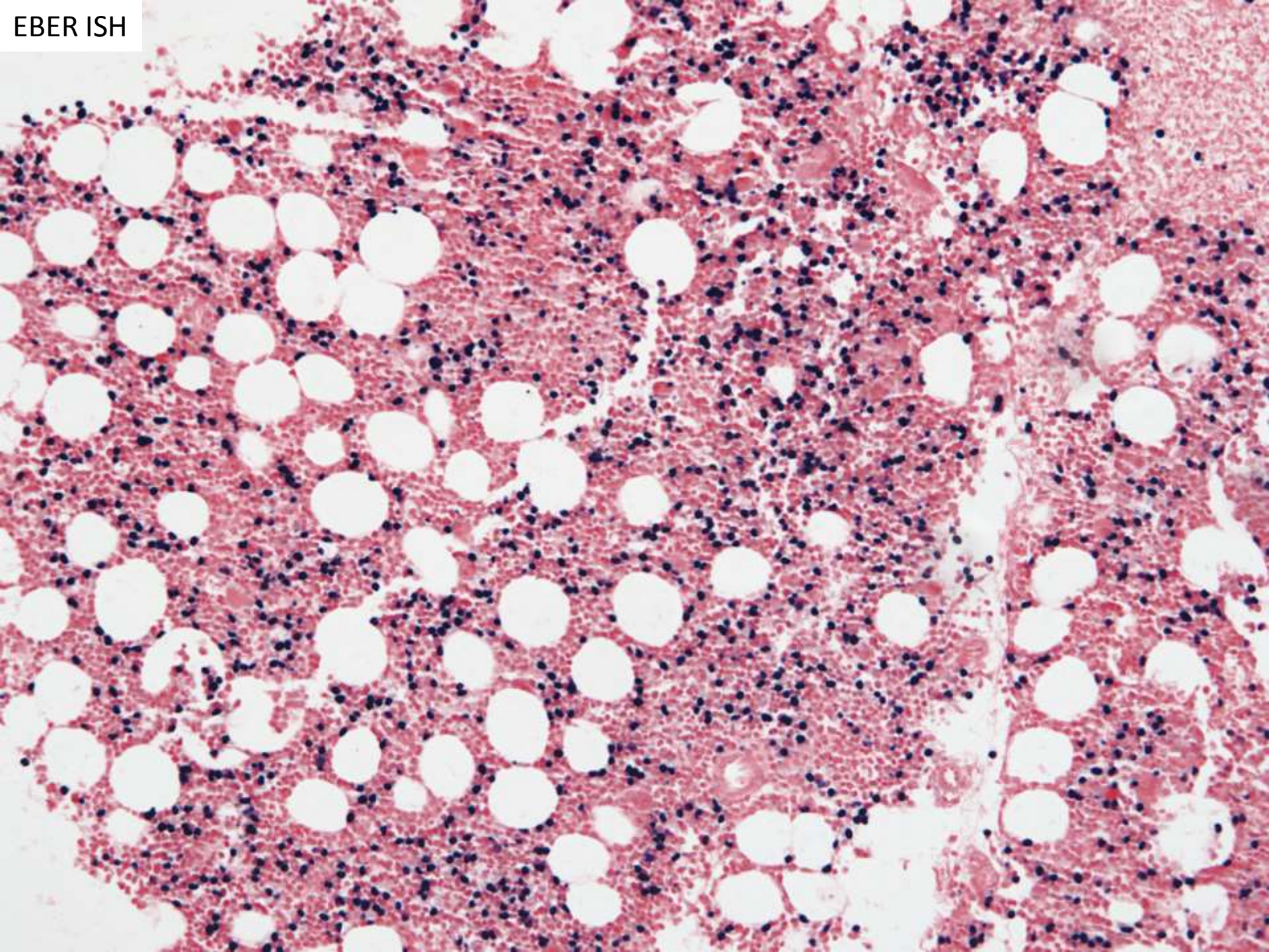






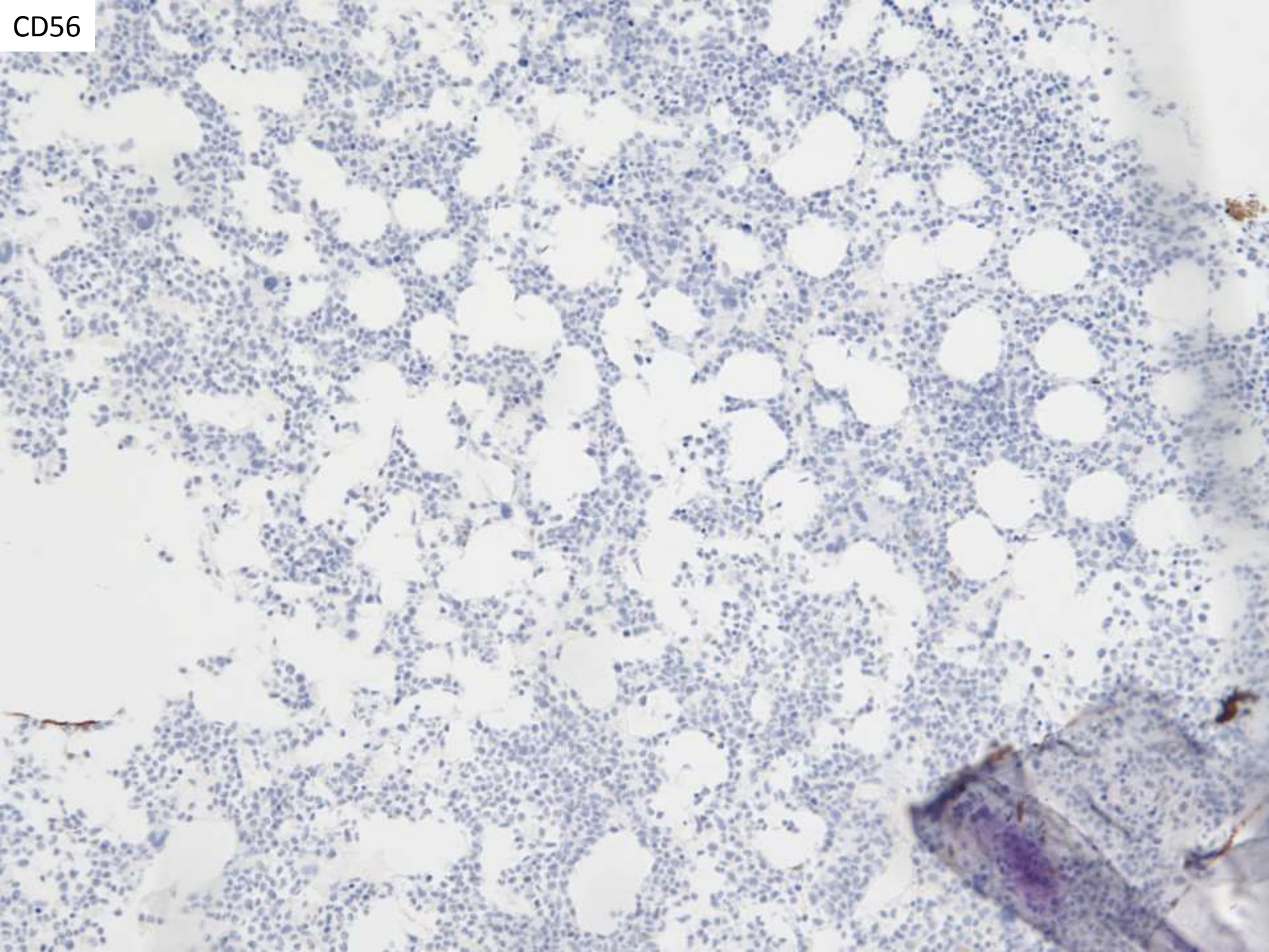




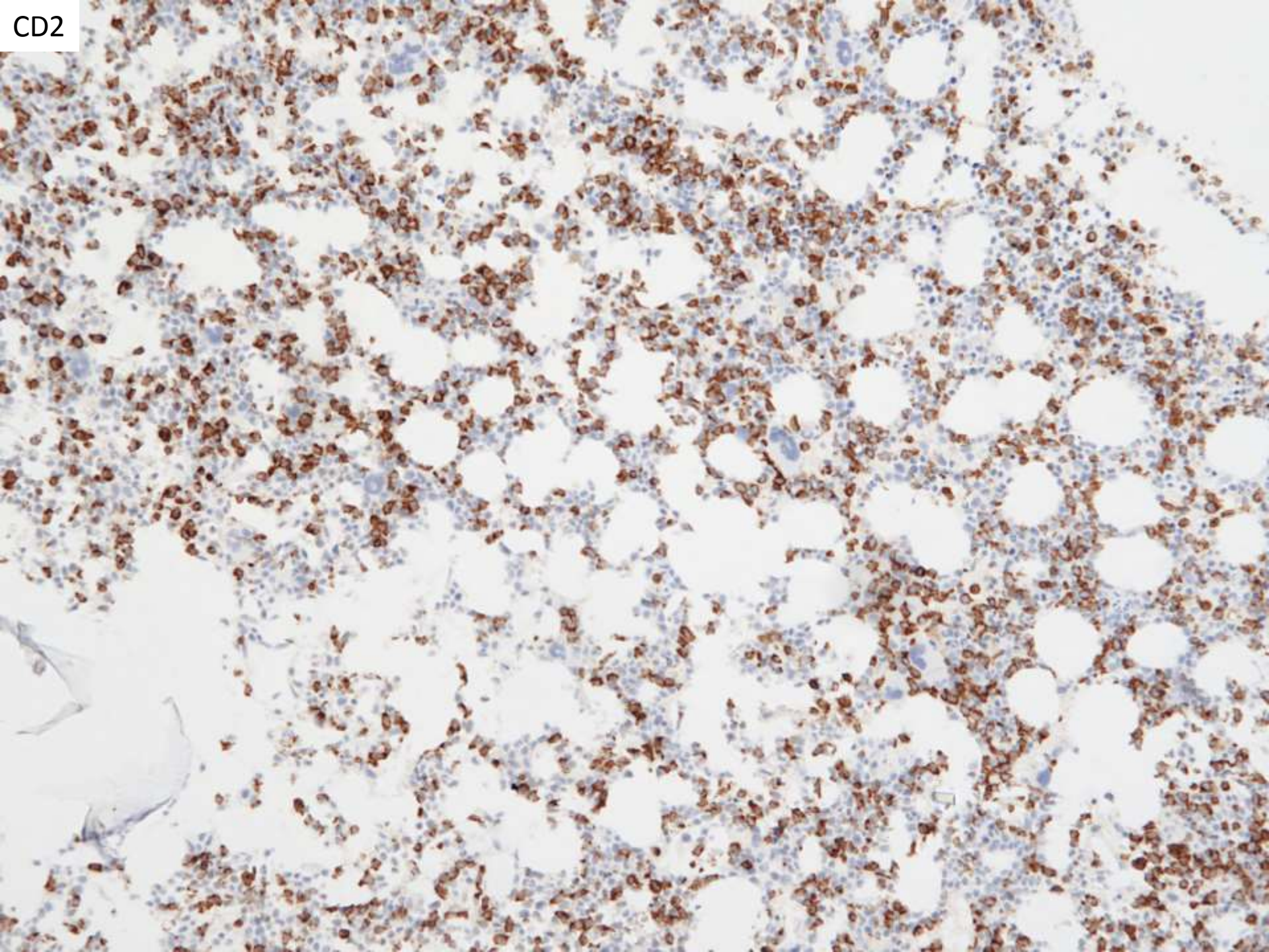


EBER ISH

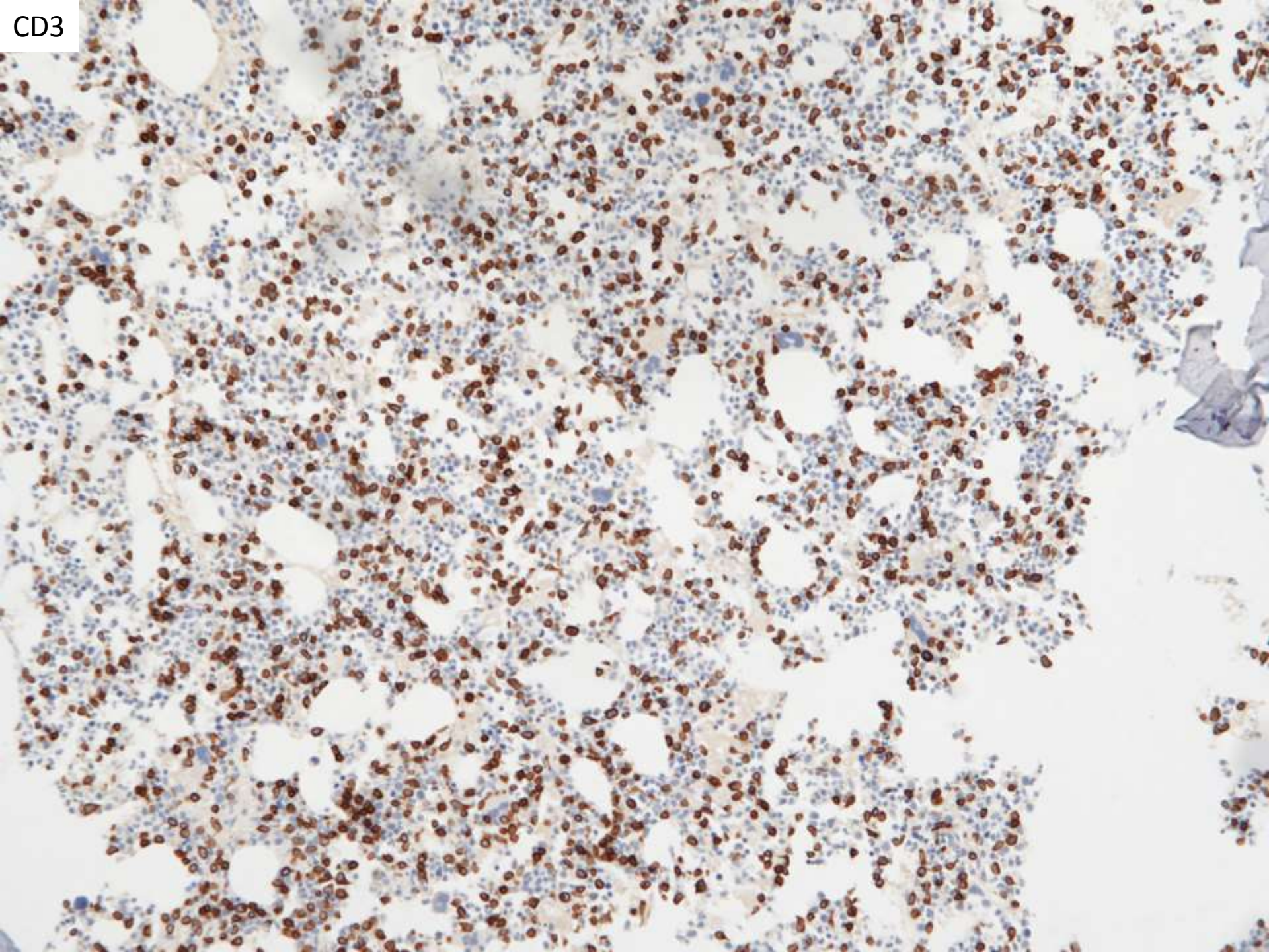
CD56



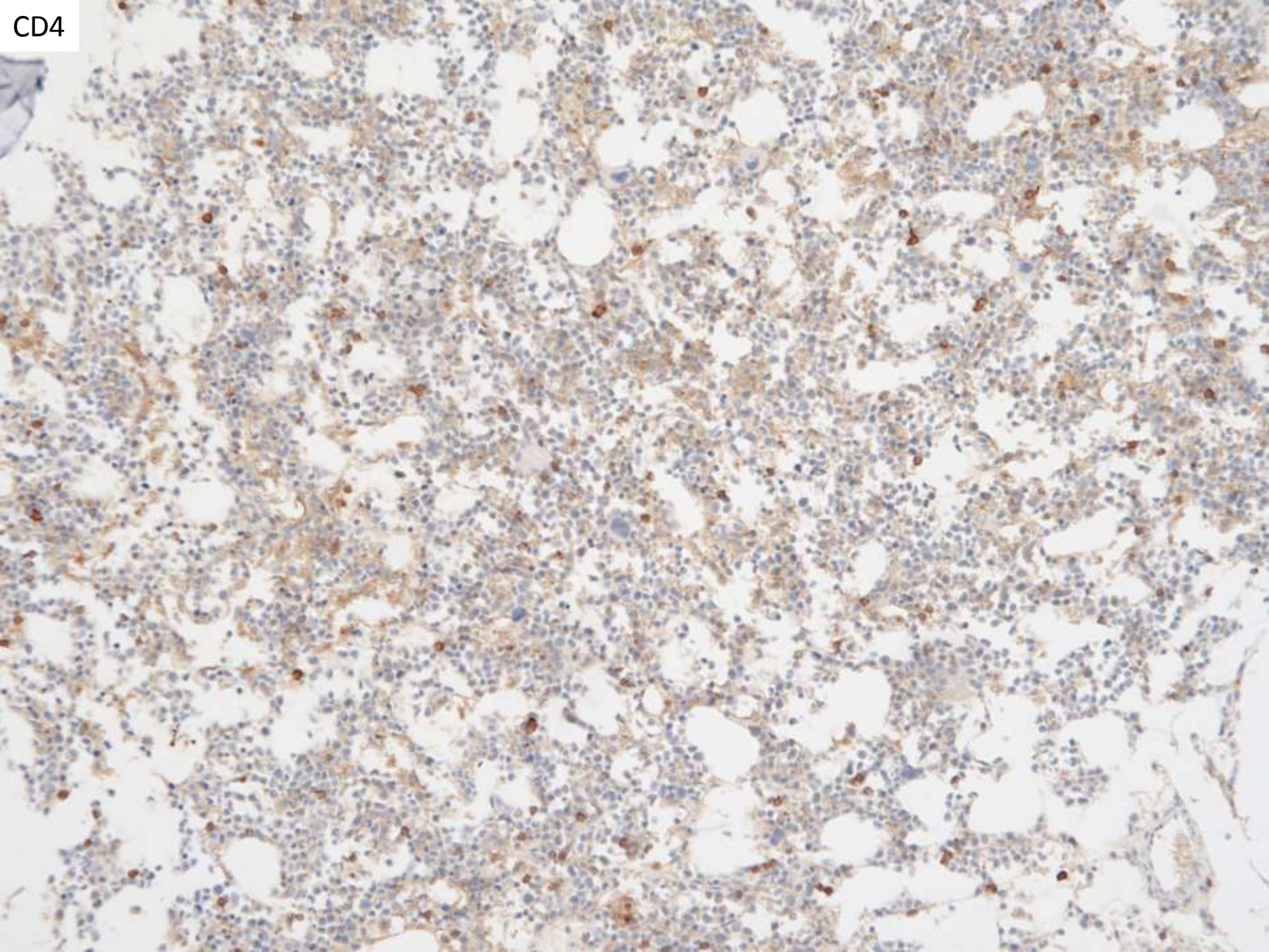
CD2



CD3

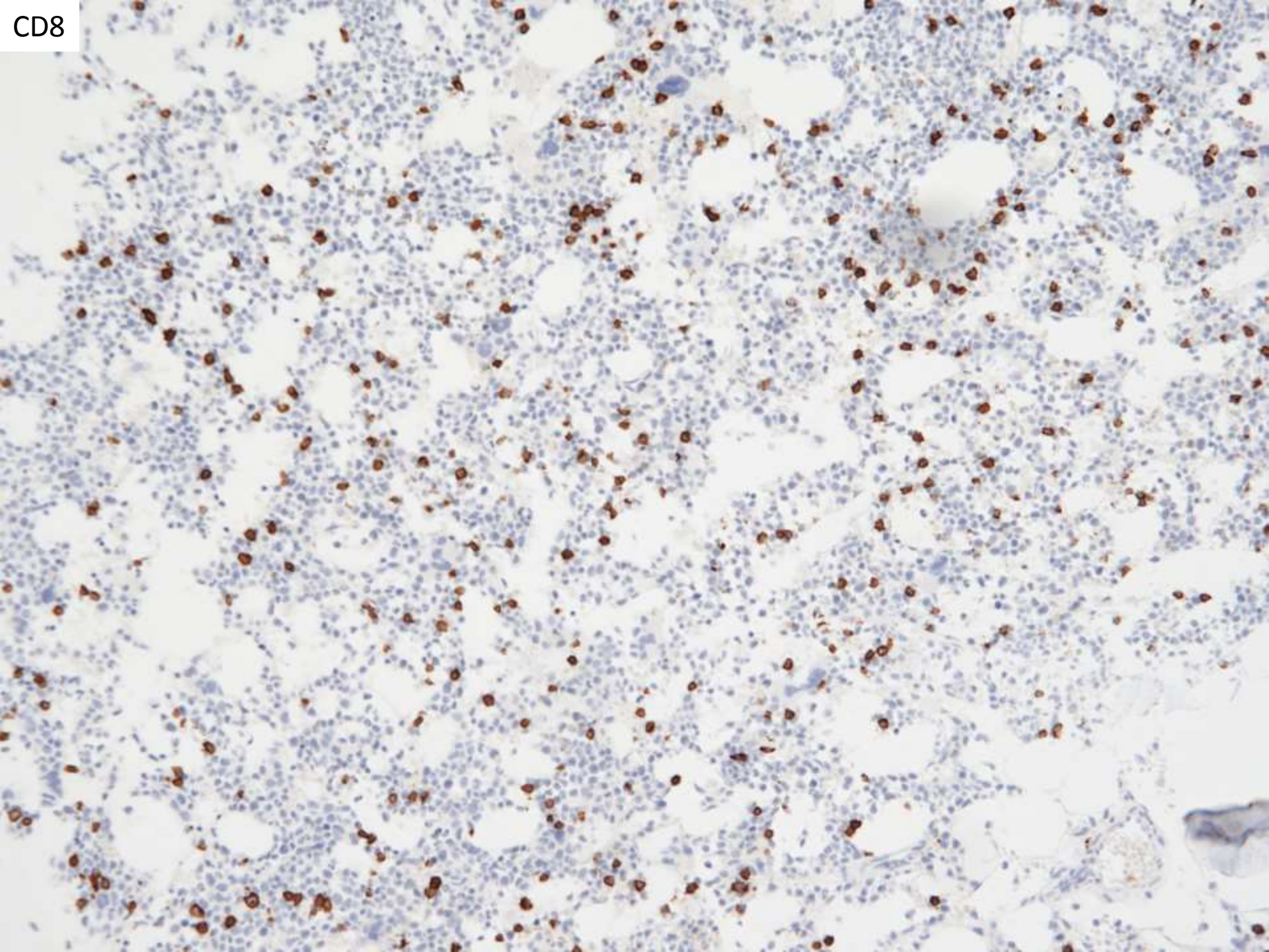


CD4

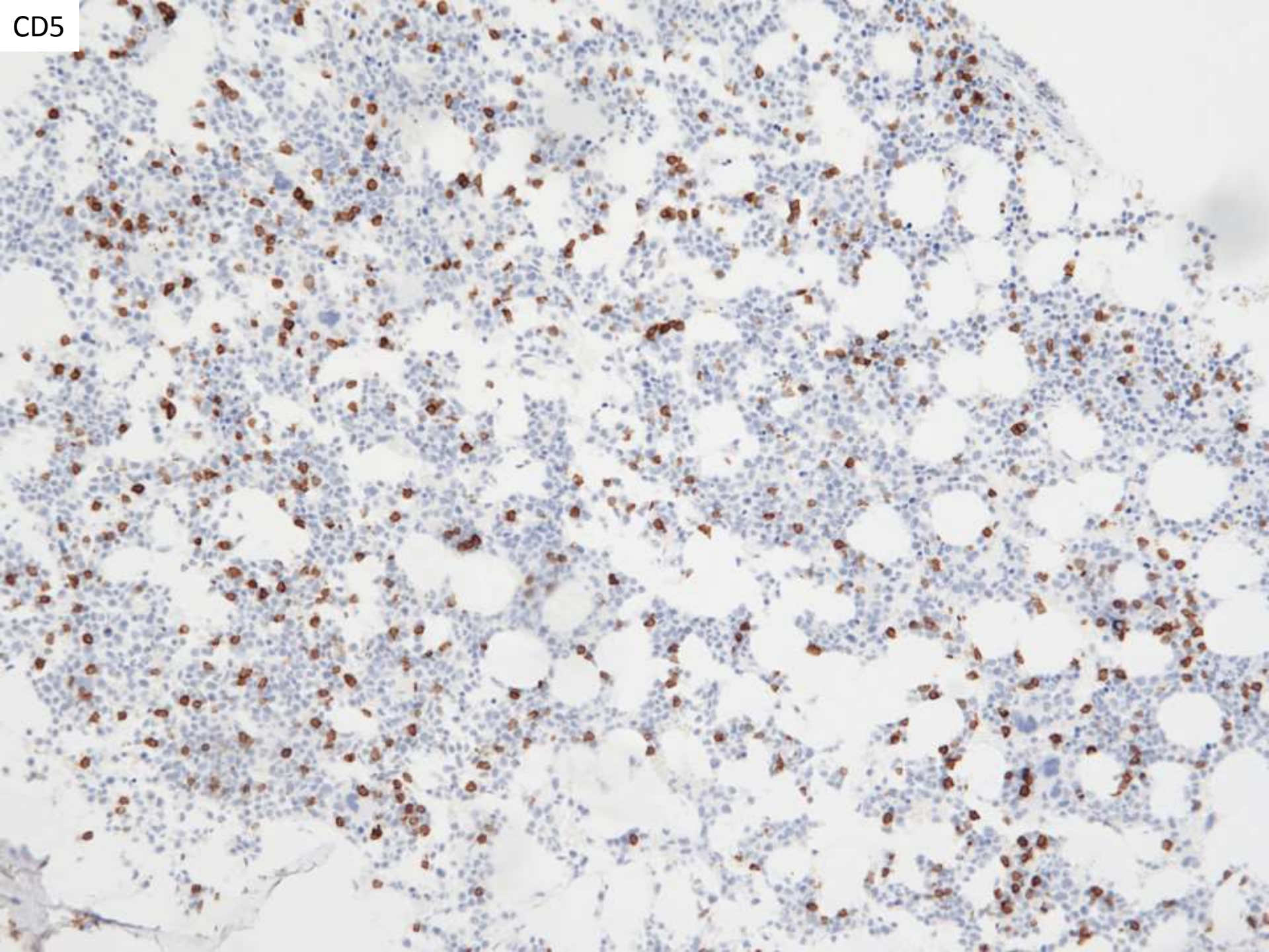


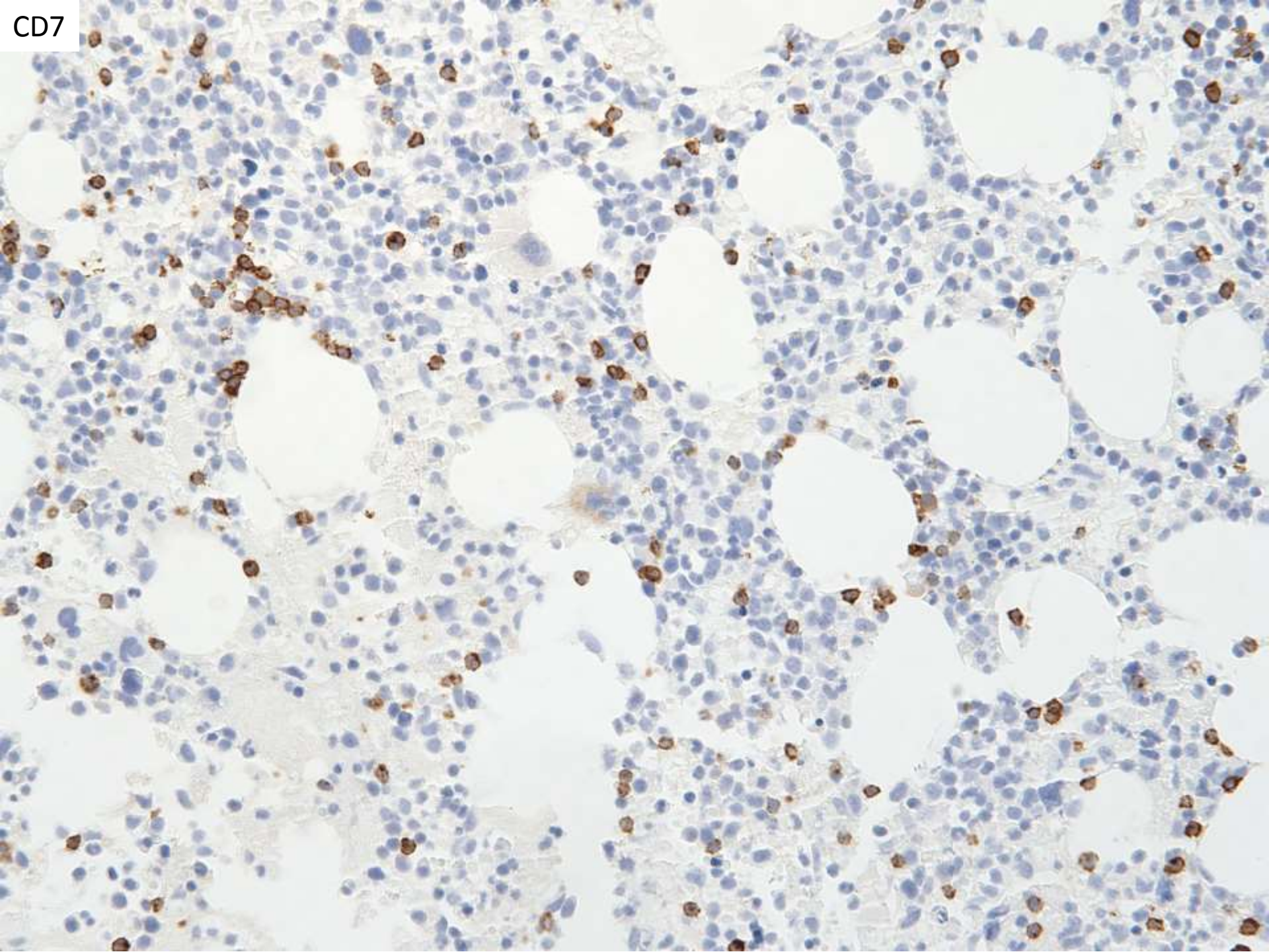


CD8



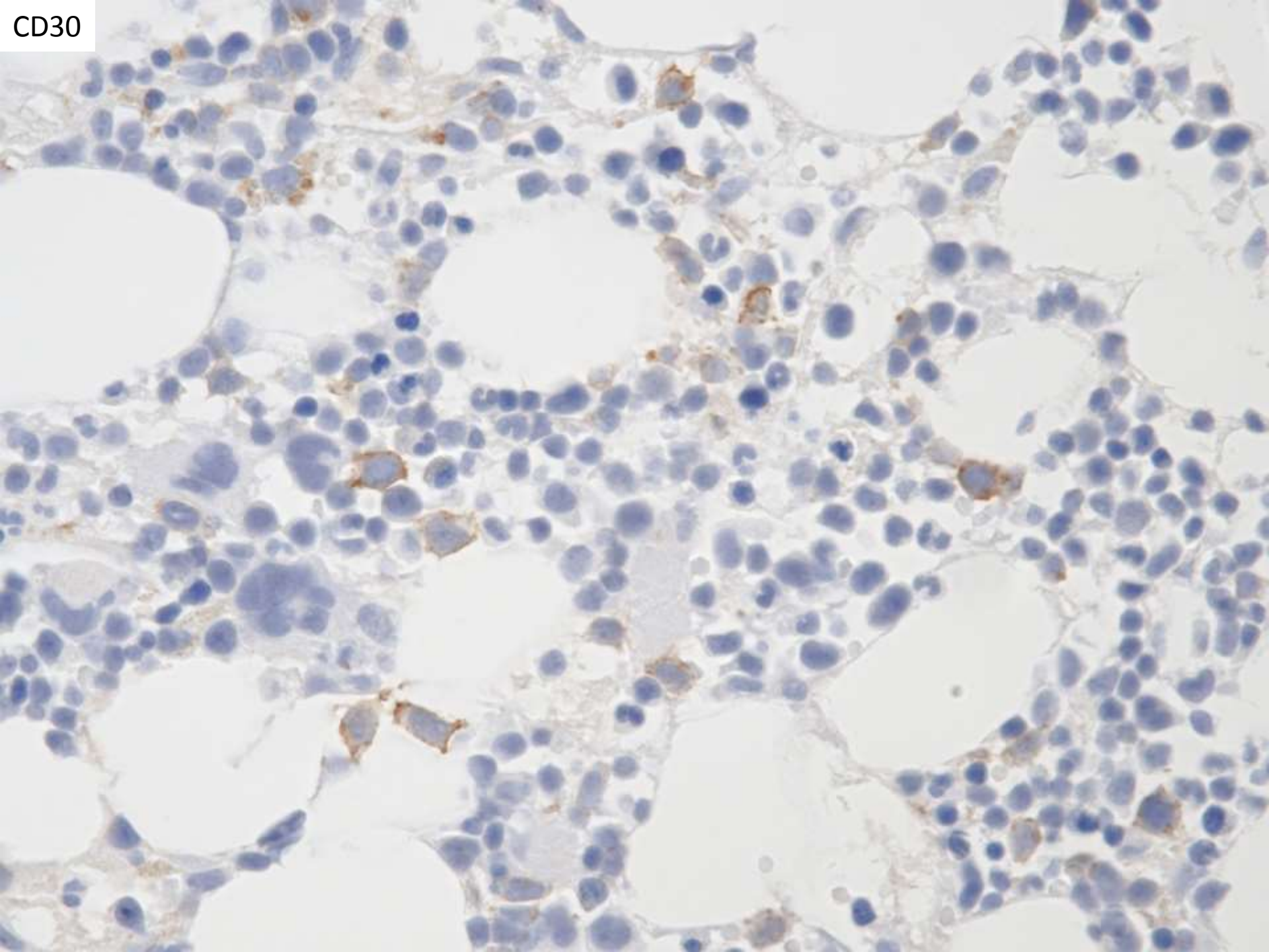
CD5

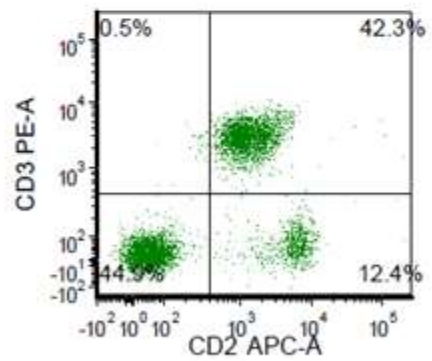
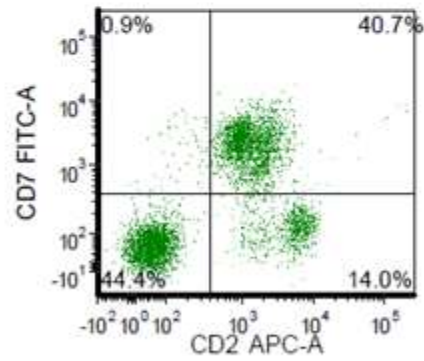
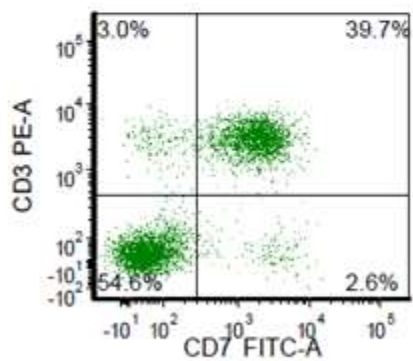
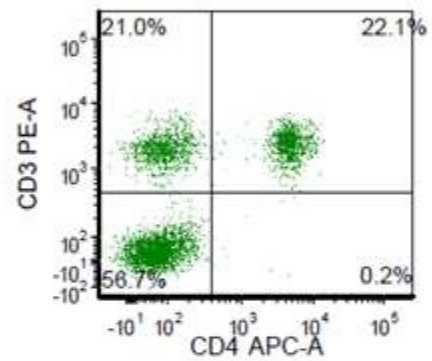
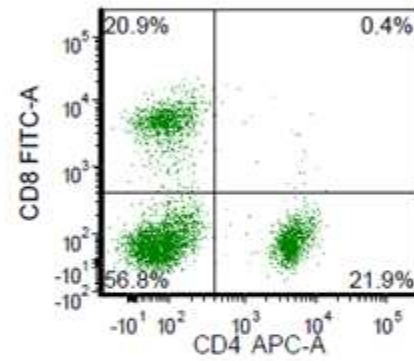
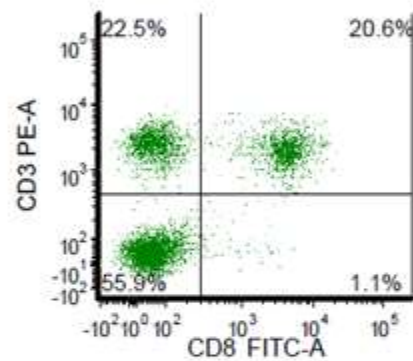
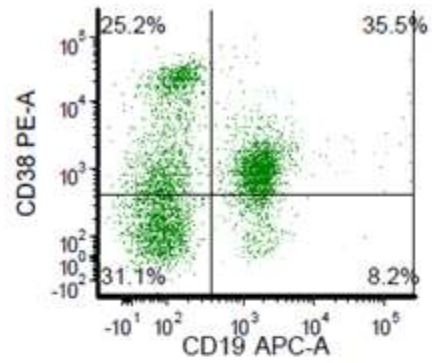
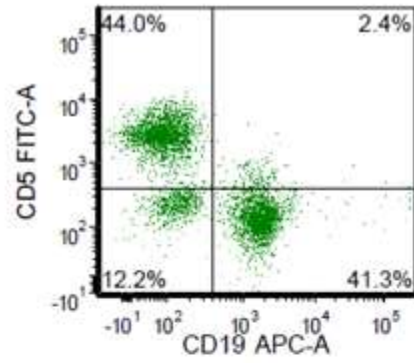
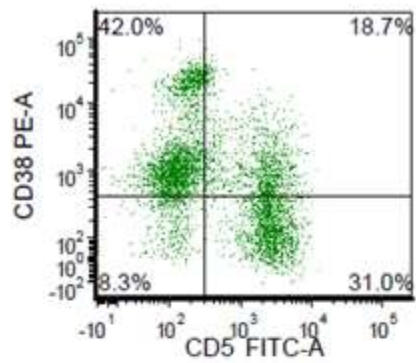
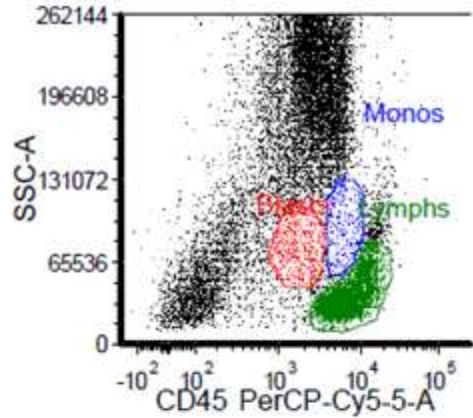


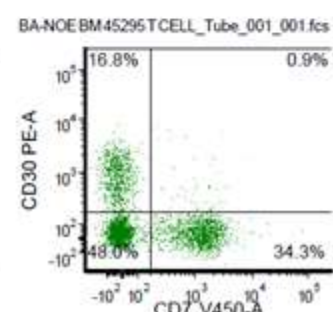
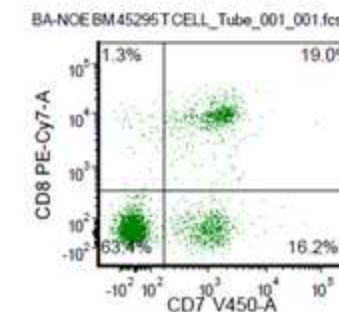
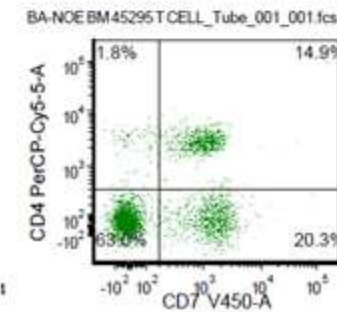
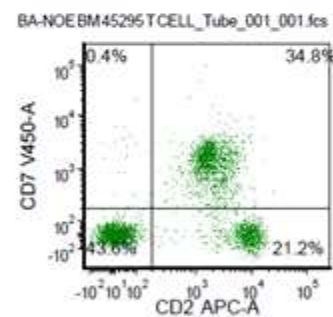
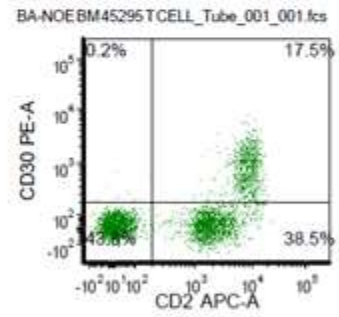
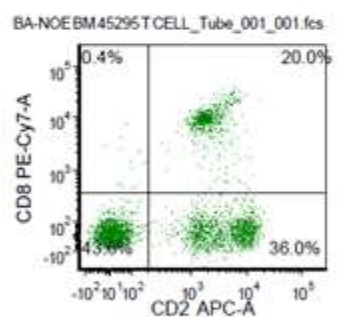
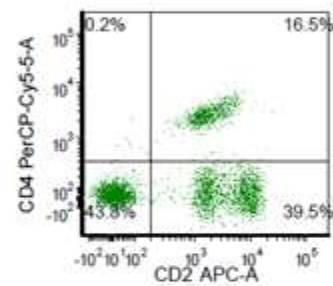
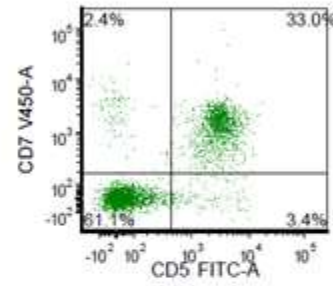
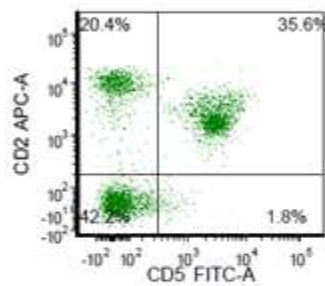
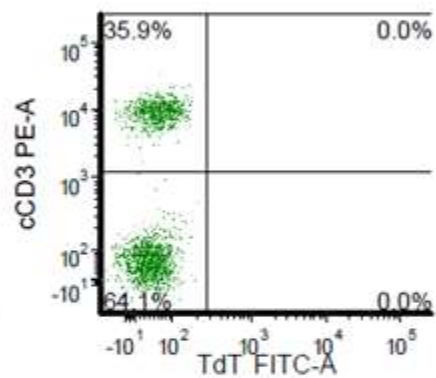
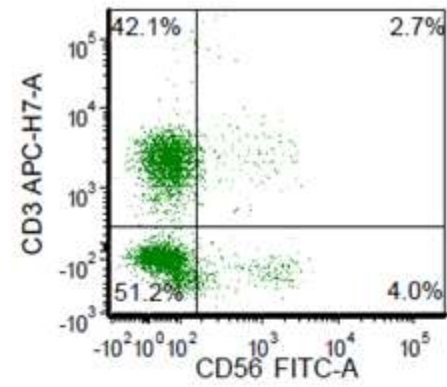
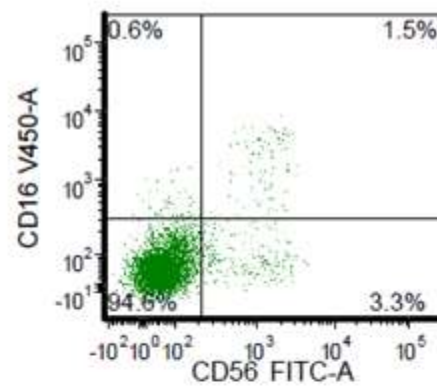
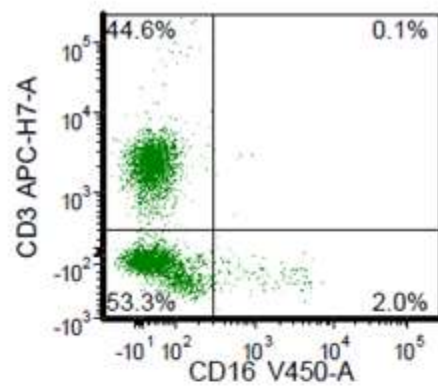
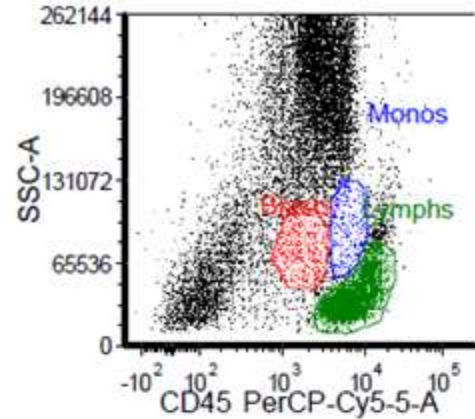


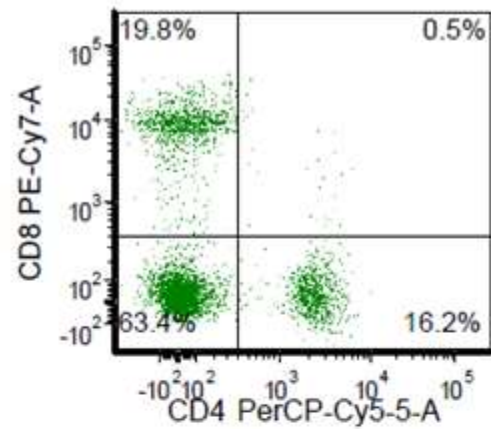
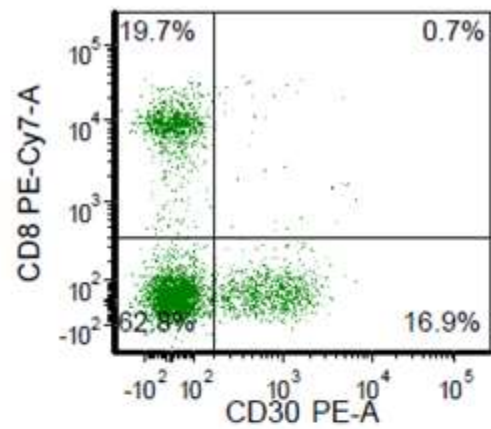
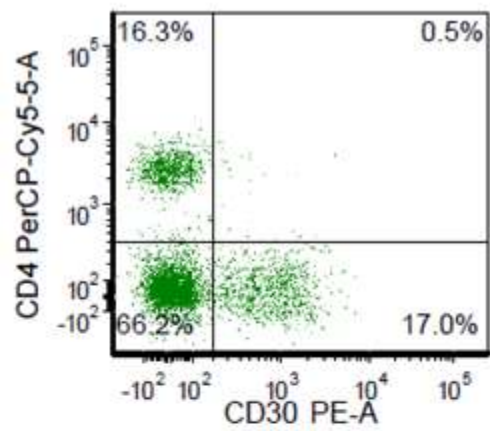
CD7

CD30









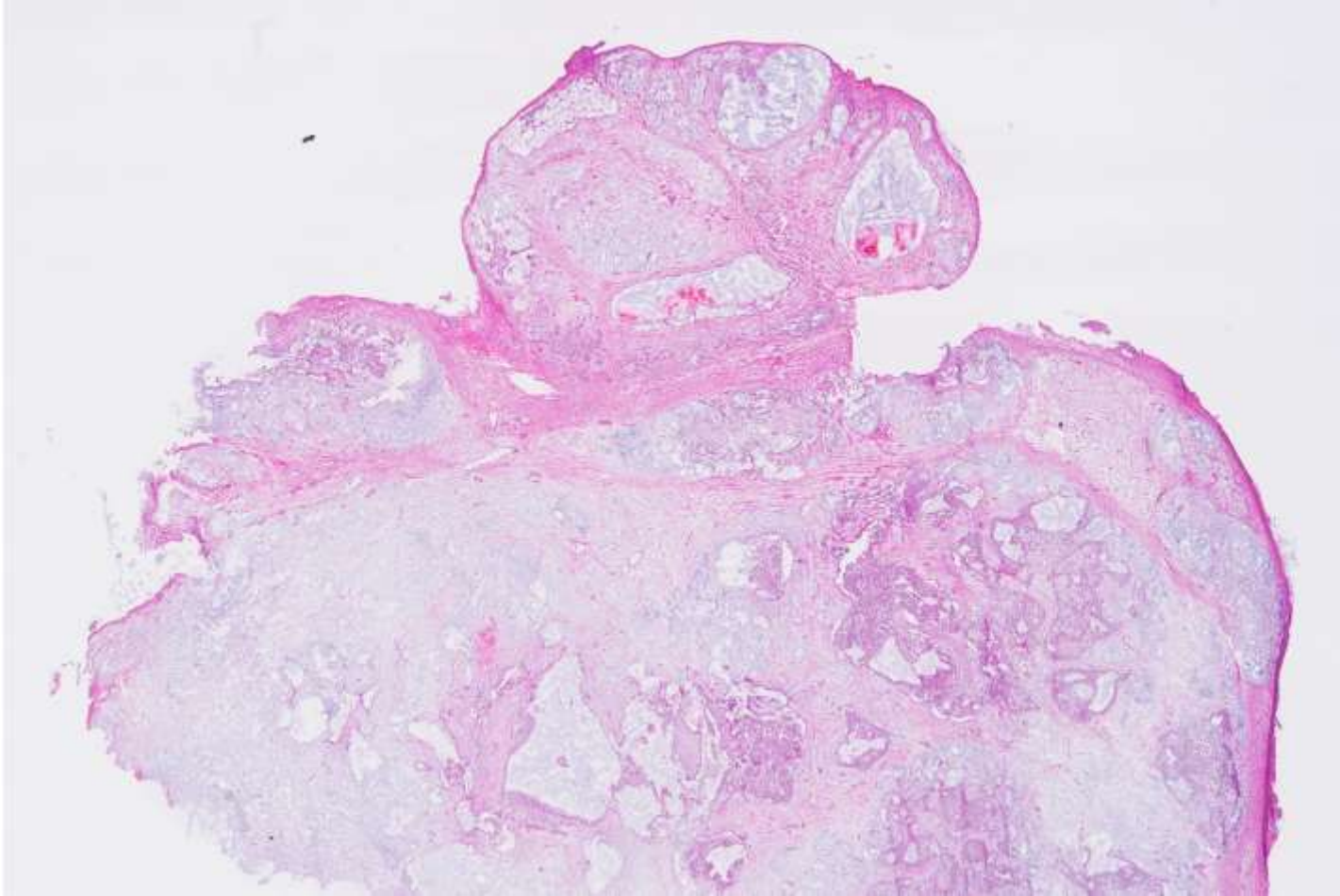
# 19-0707

Nicholas Ladwig/Charles Zaloudek;  
UCSF

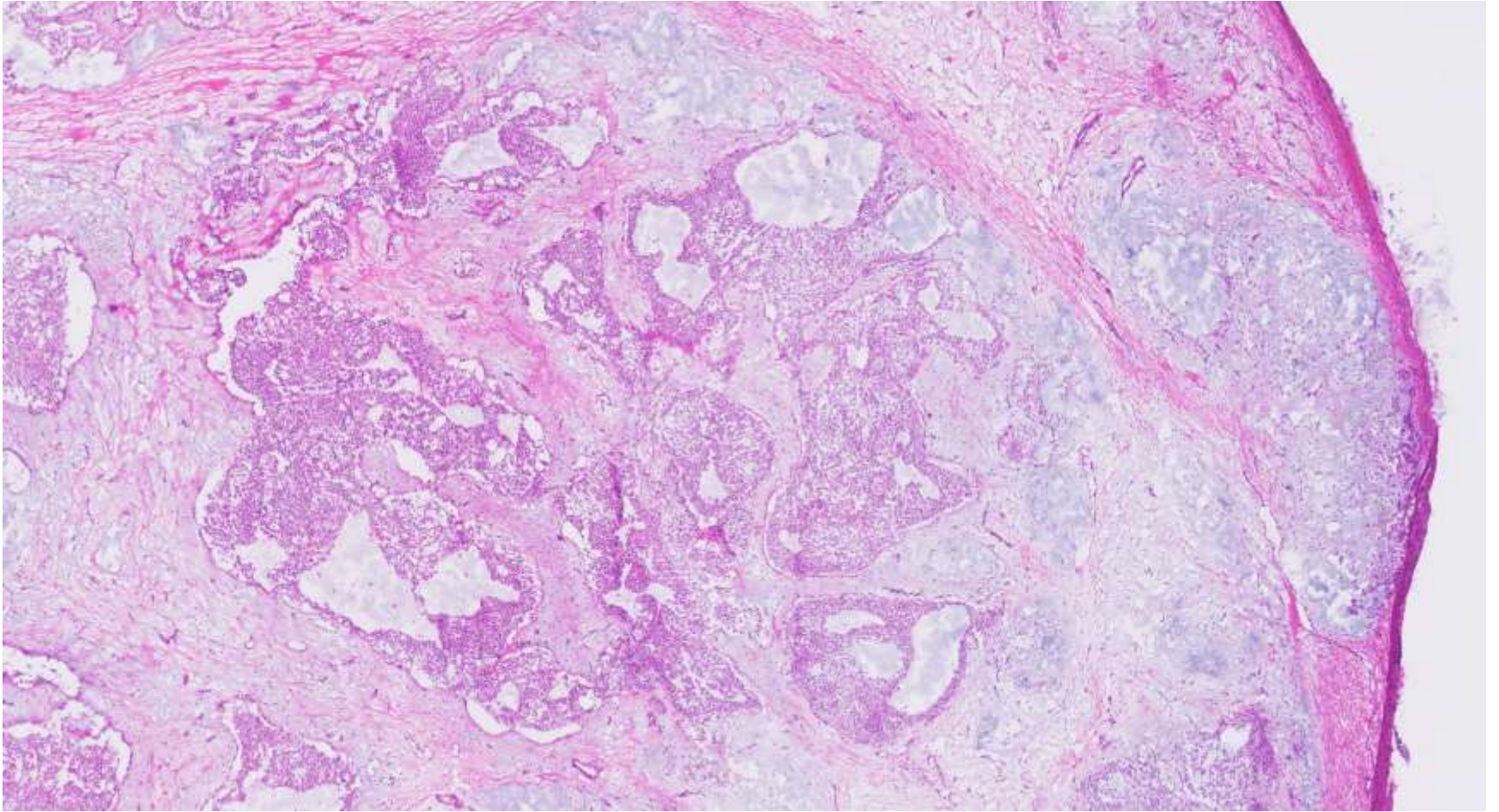
5-day-old newborn male undergoes orchiectomy for suspected testicular torsion. Intraoperative evaluation revealed 1.5cm testicular mass, specimen sent for frozen section. Labs sent at time of frozen section:  
AFP 15,418 ug/L, HCG 2IU/L.



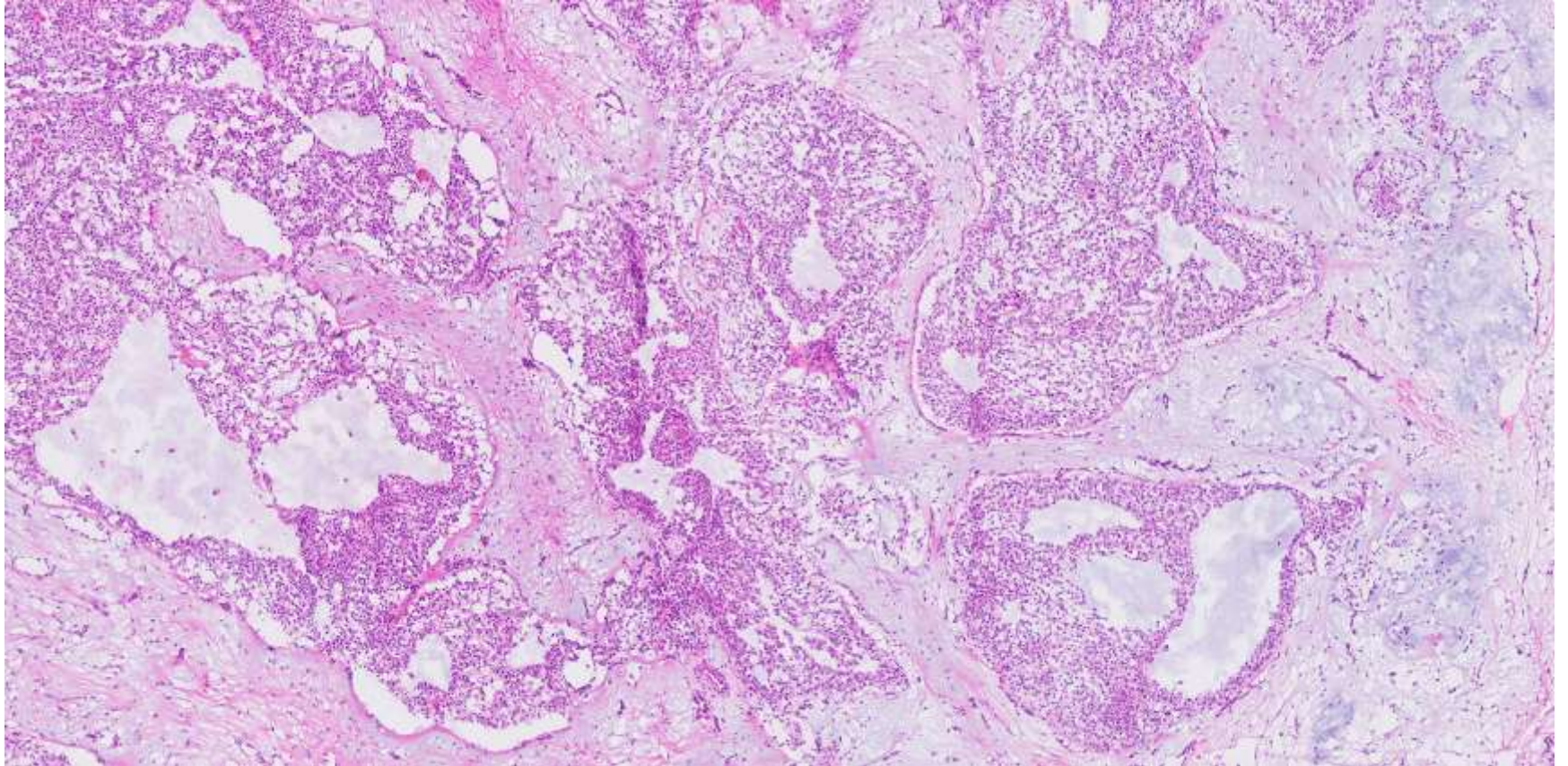
1x



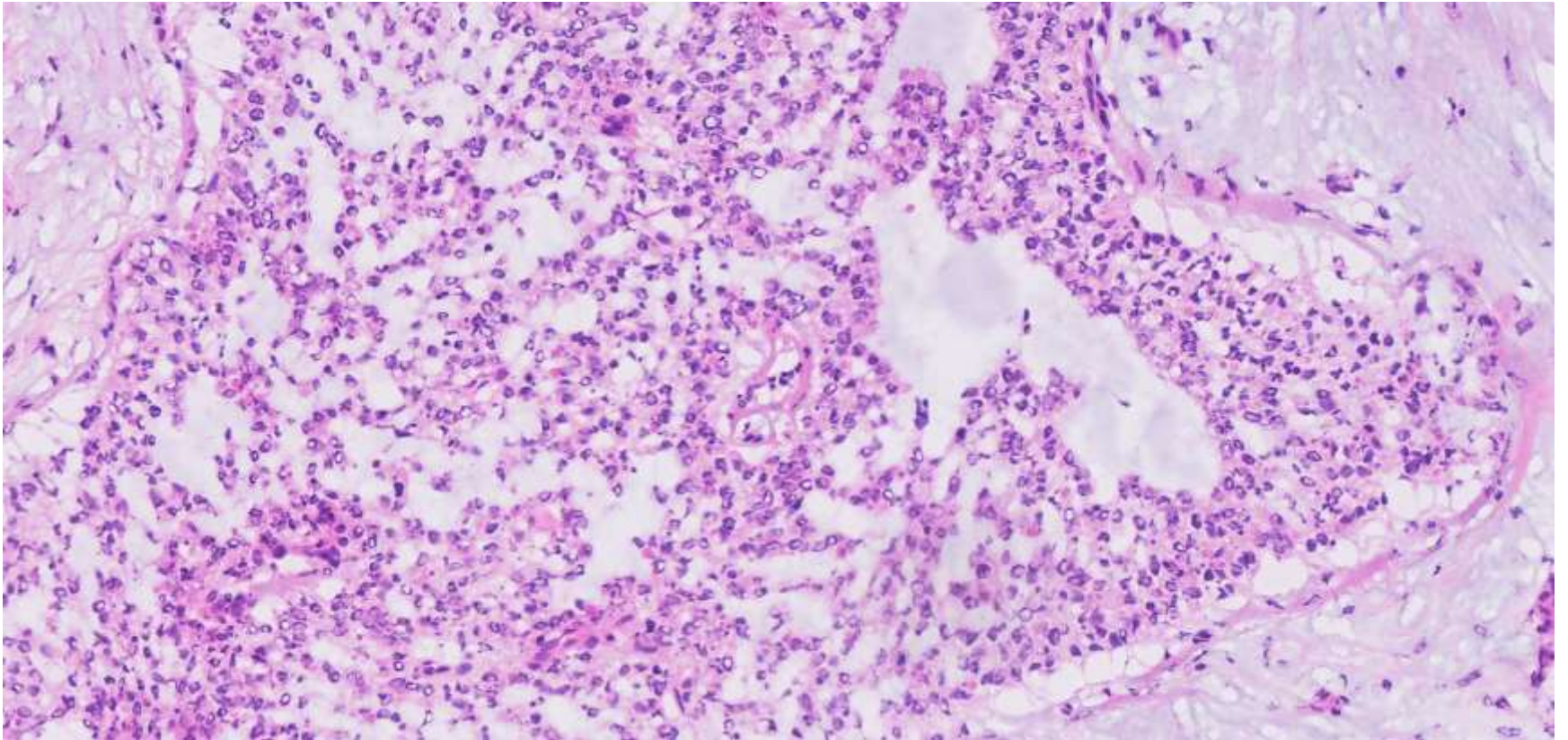
2x



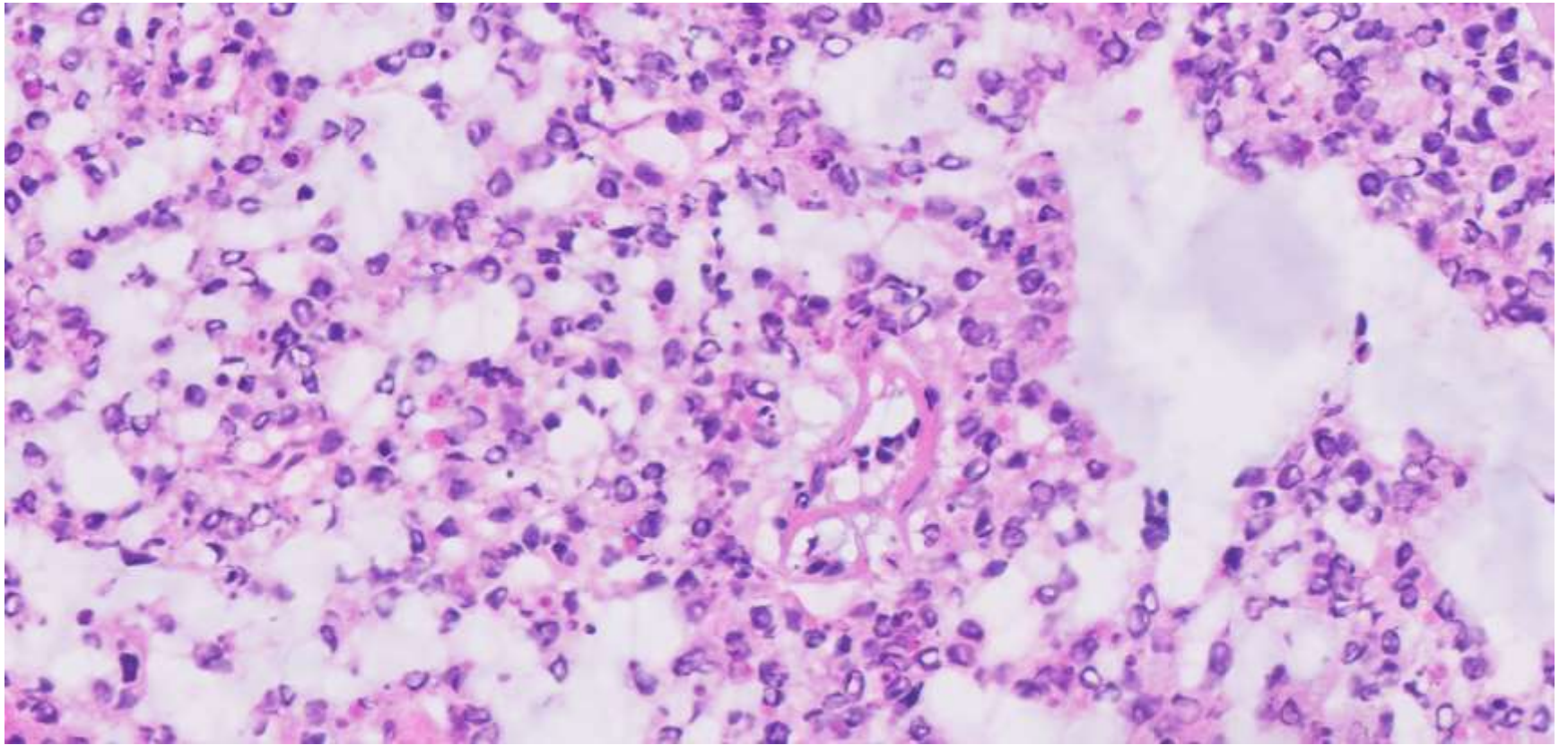
5x



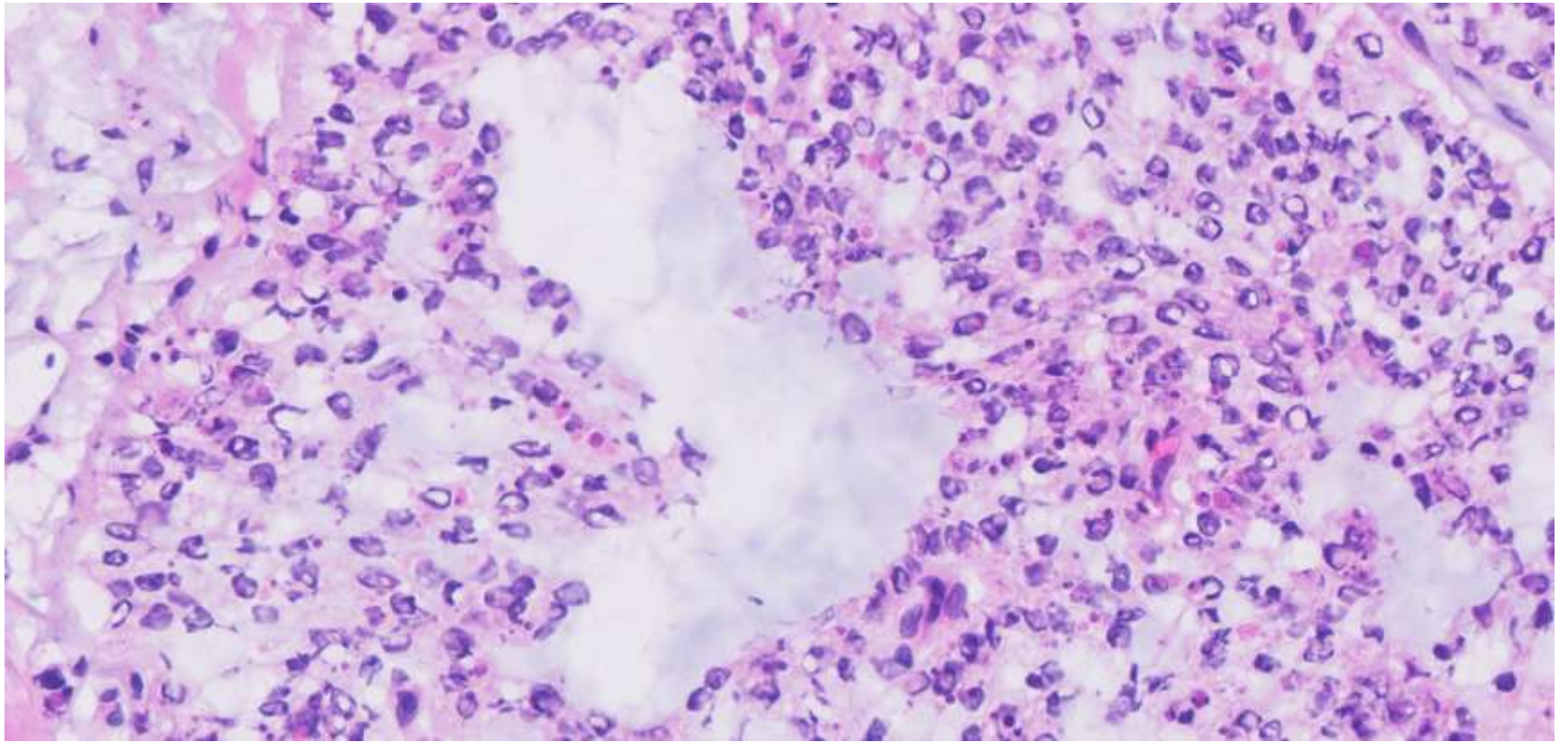
20x



40x



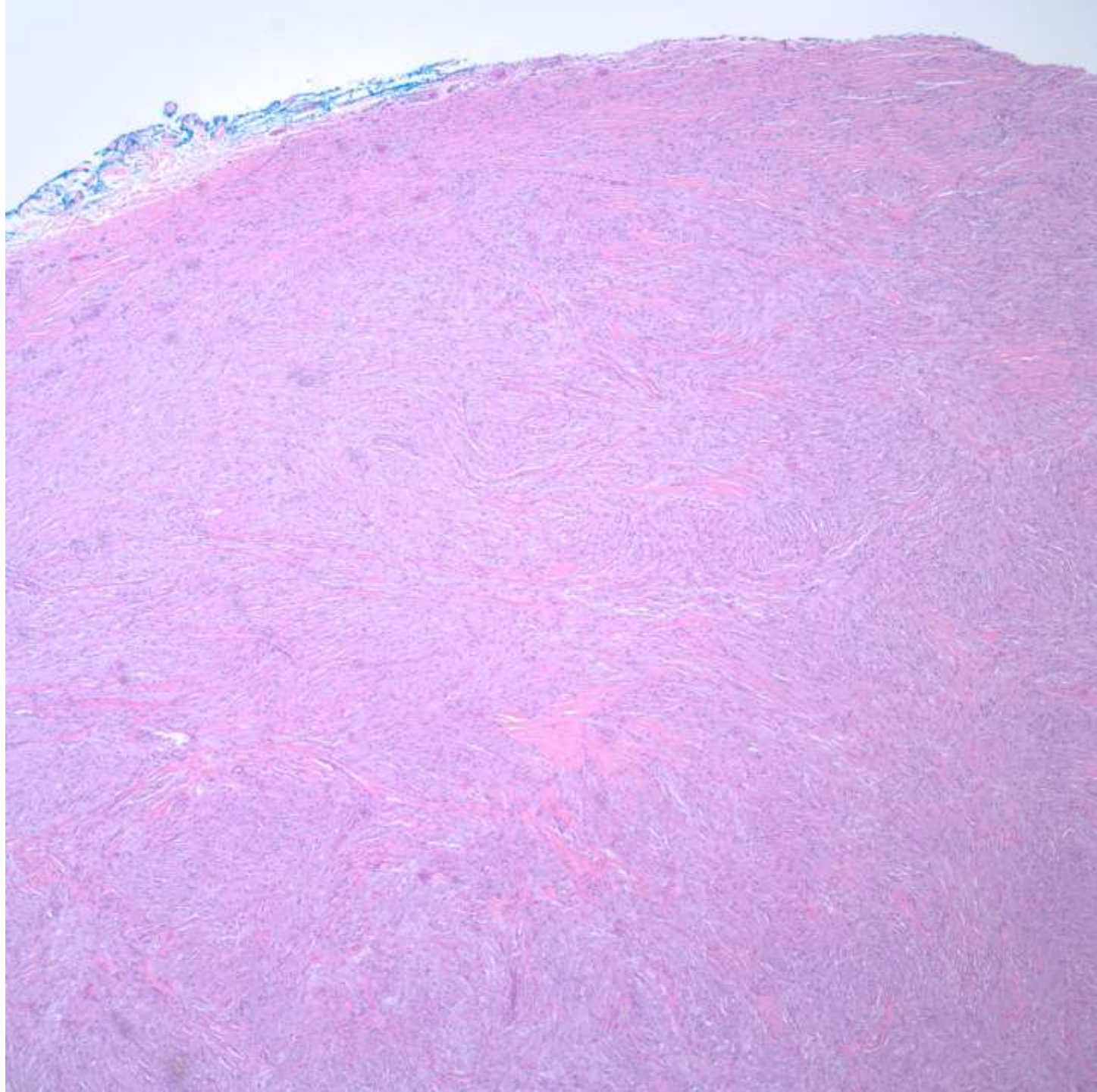
40x #2



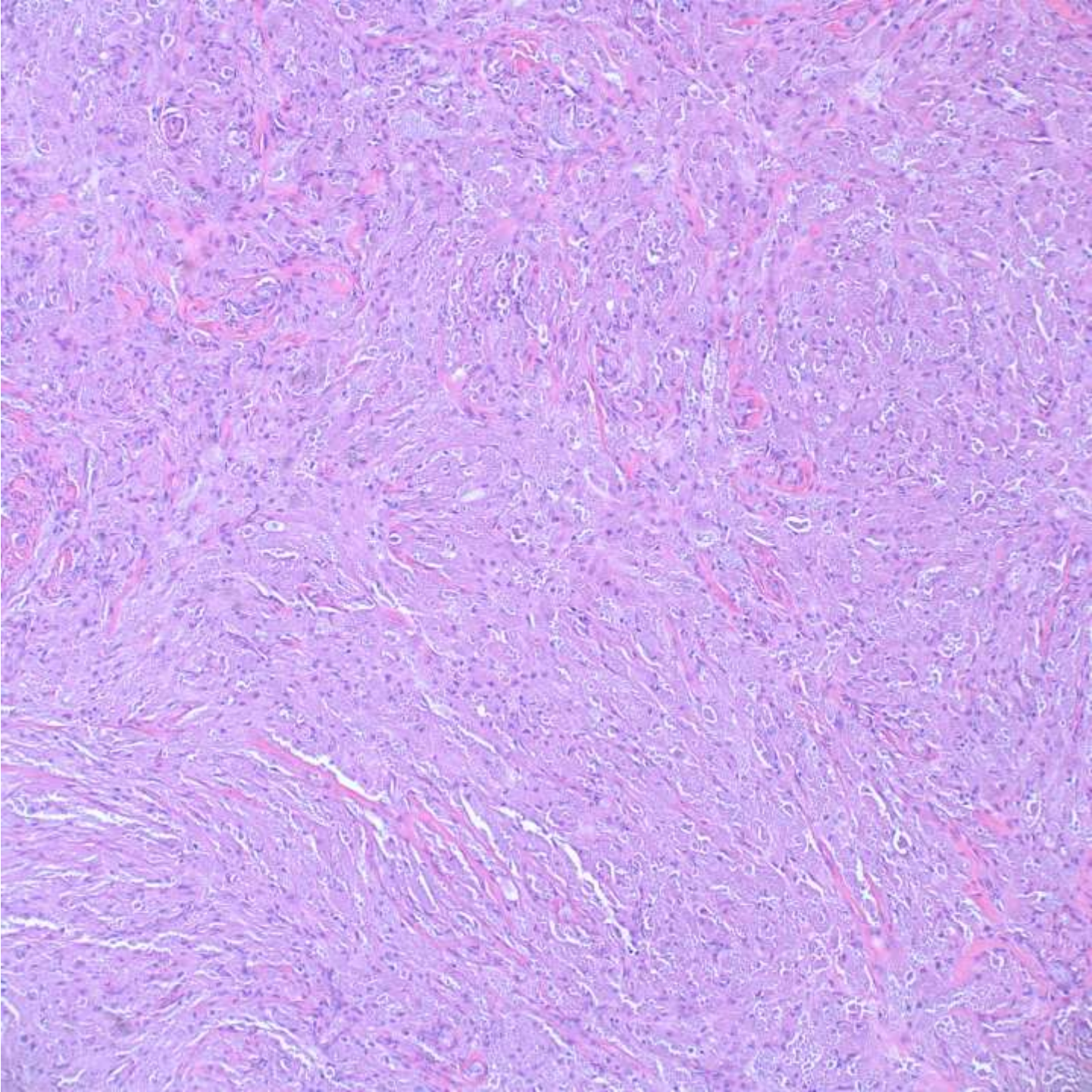
# 19-0708

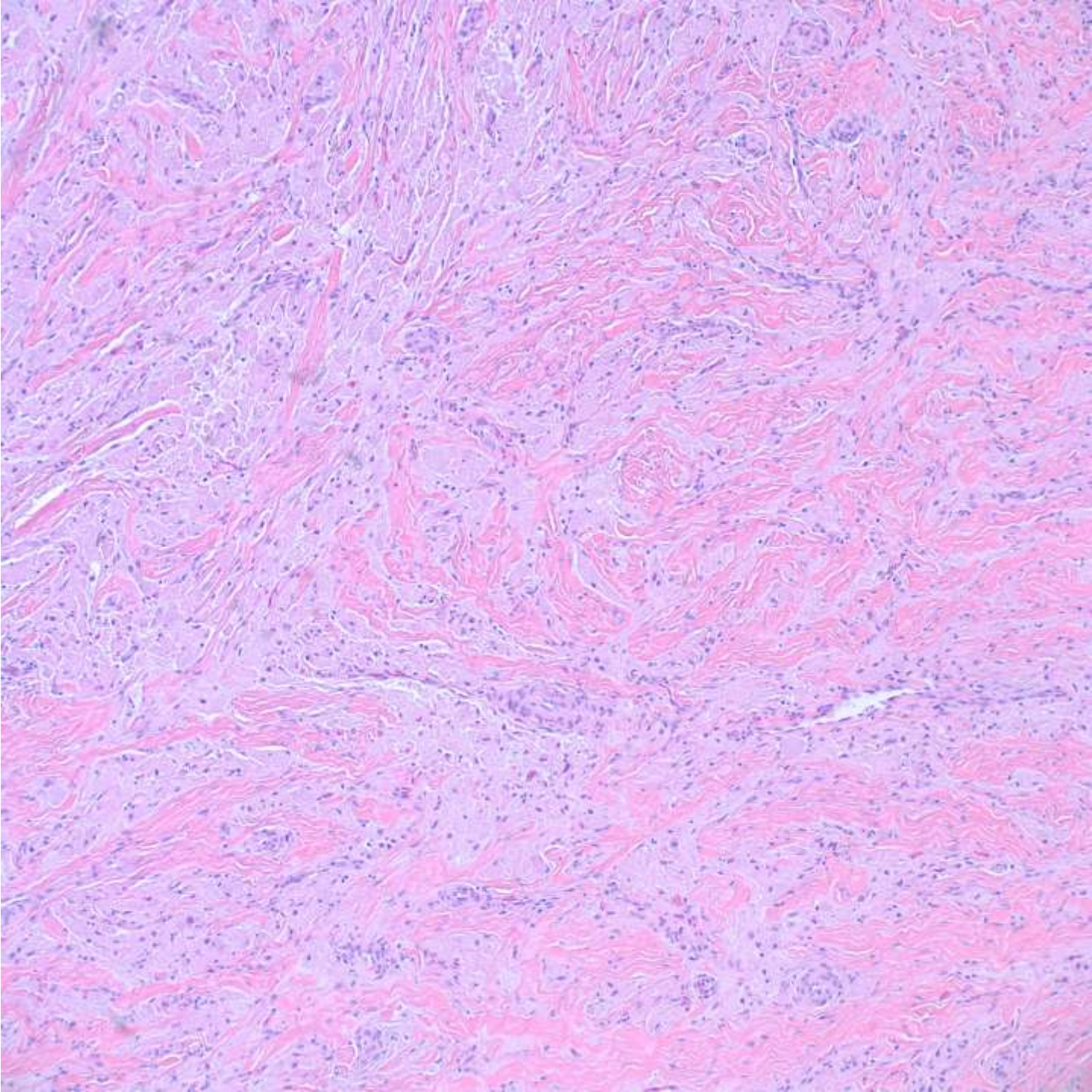
Dennis Adams/Brooke Howitt;  
Stanford

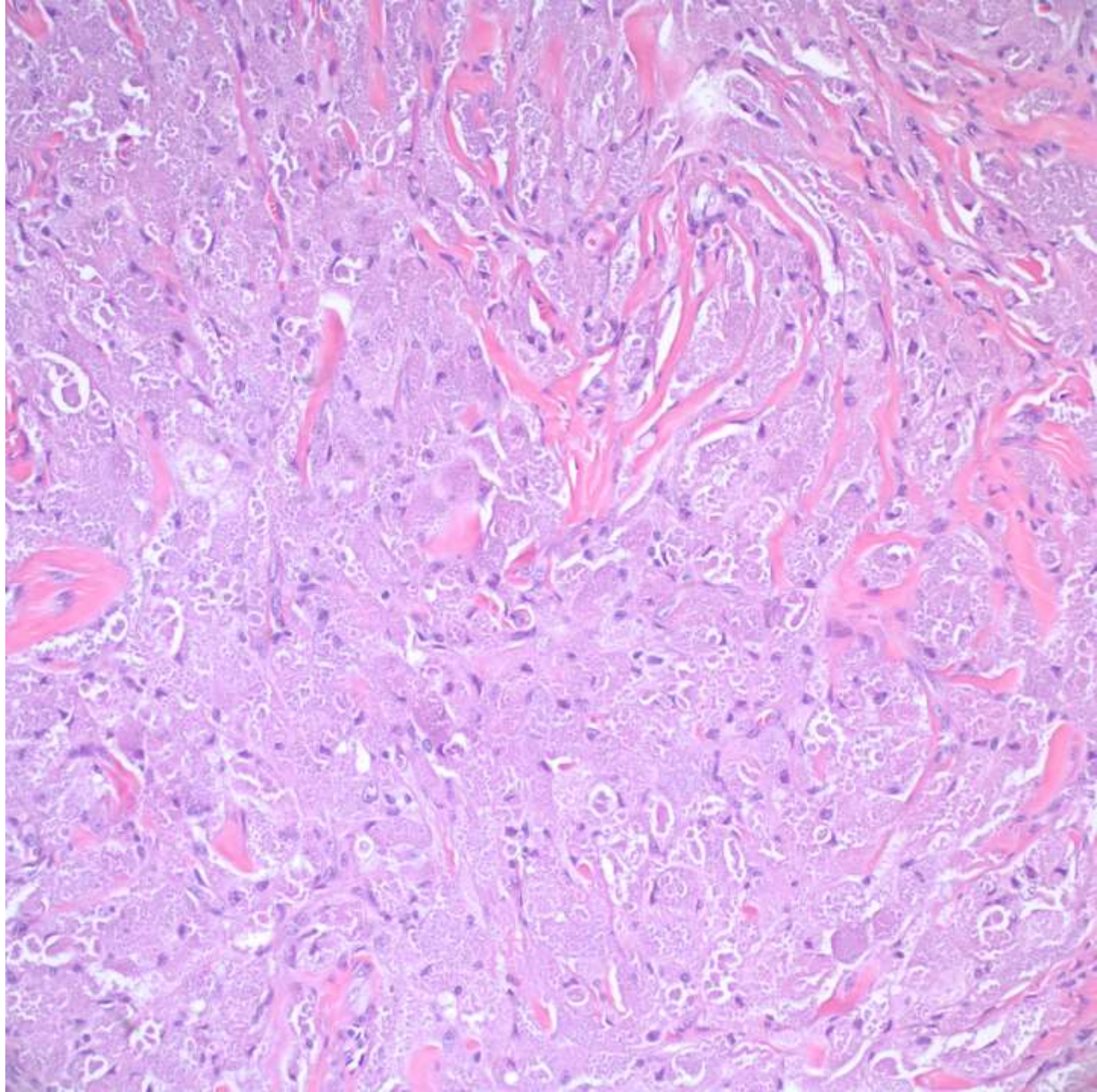
23-year-old woman with a left mid  
clavicle soft tissue mass excision.

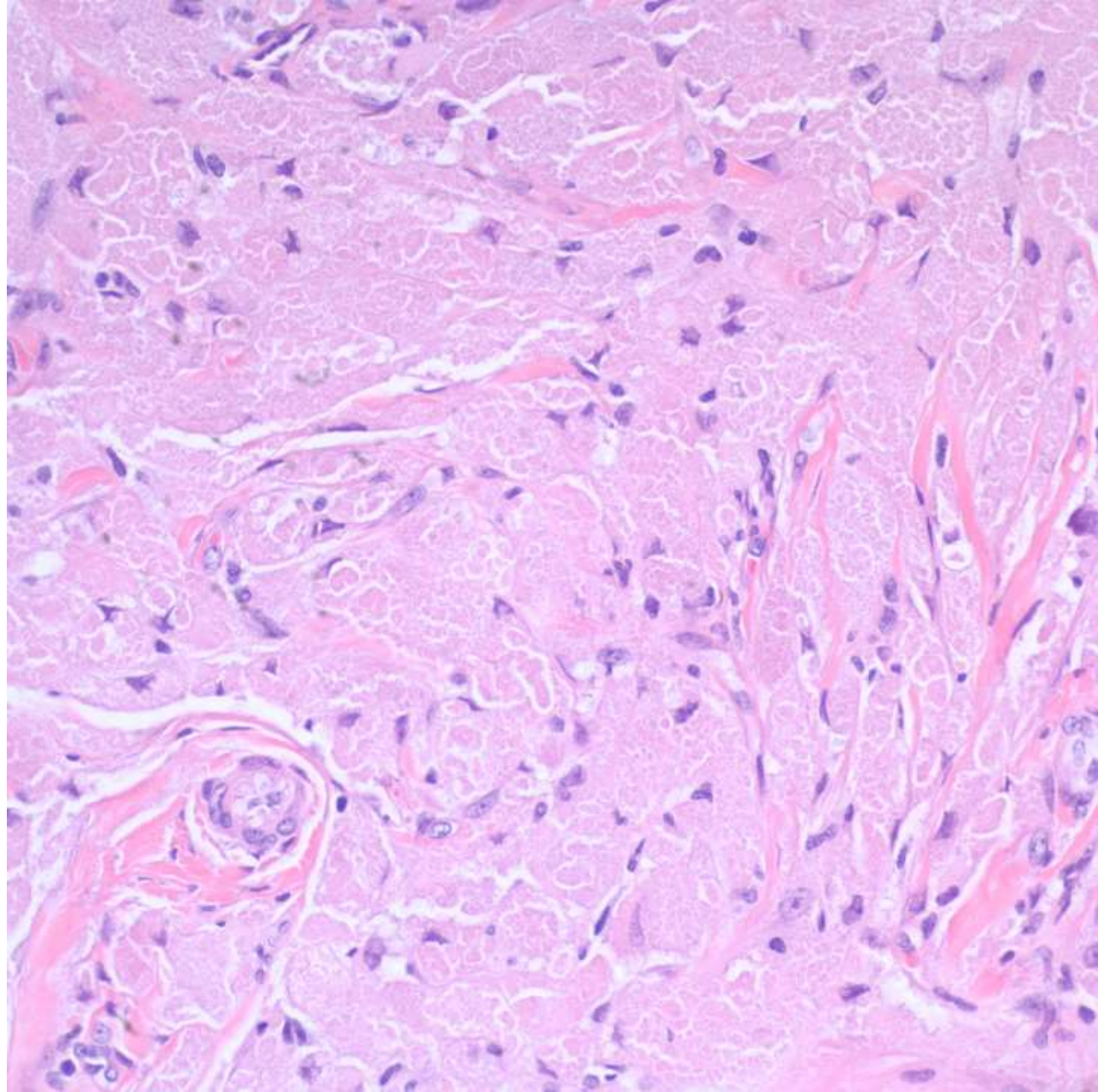




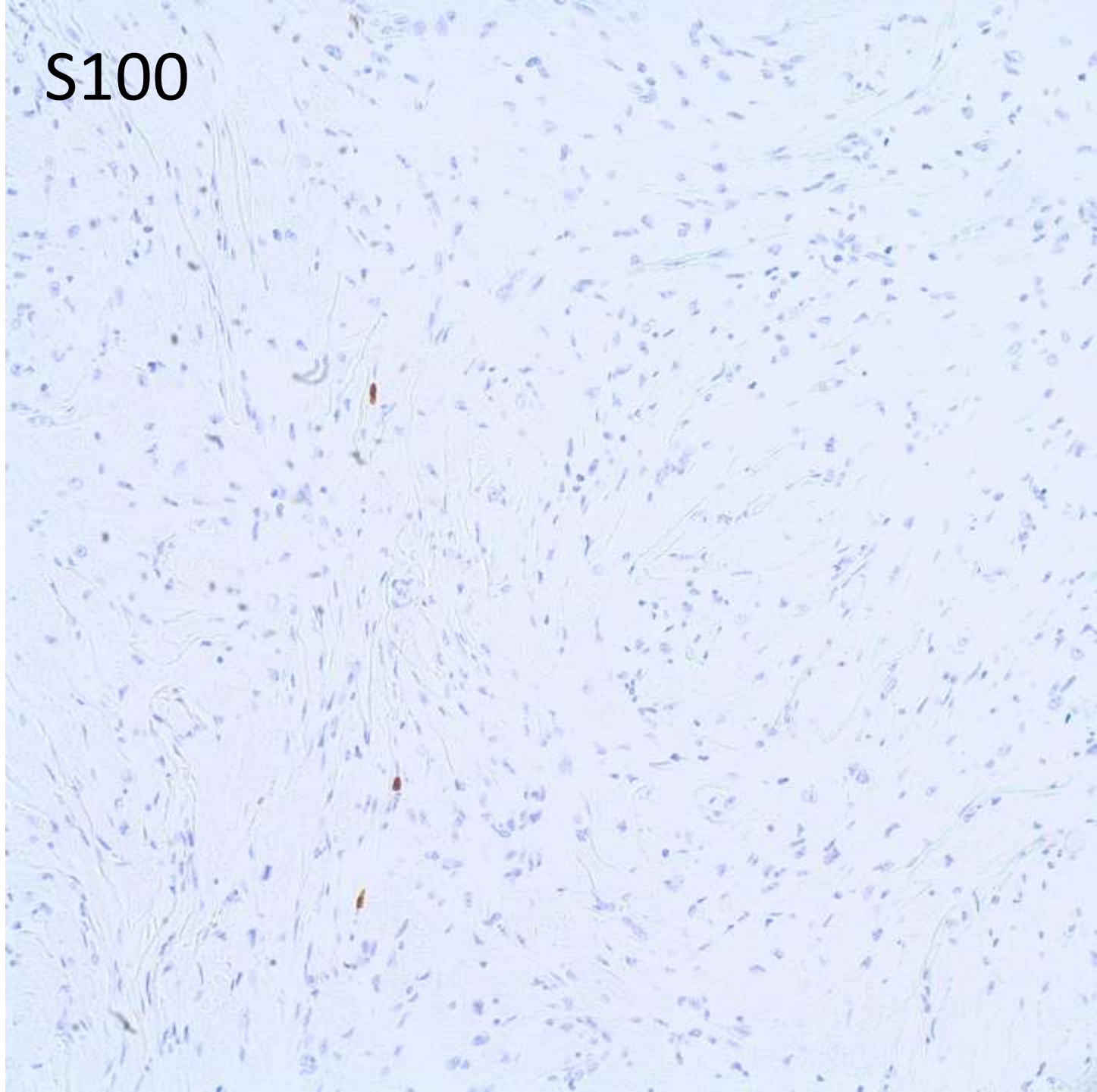








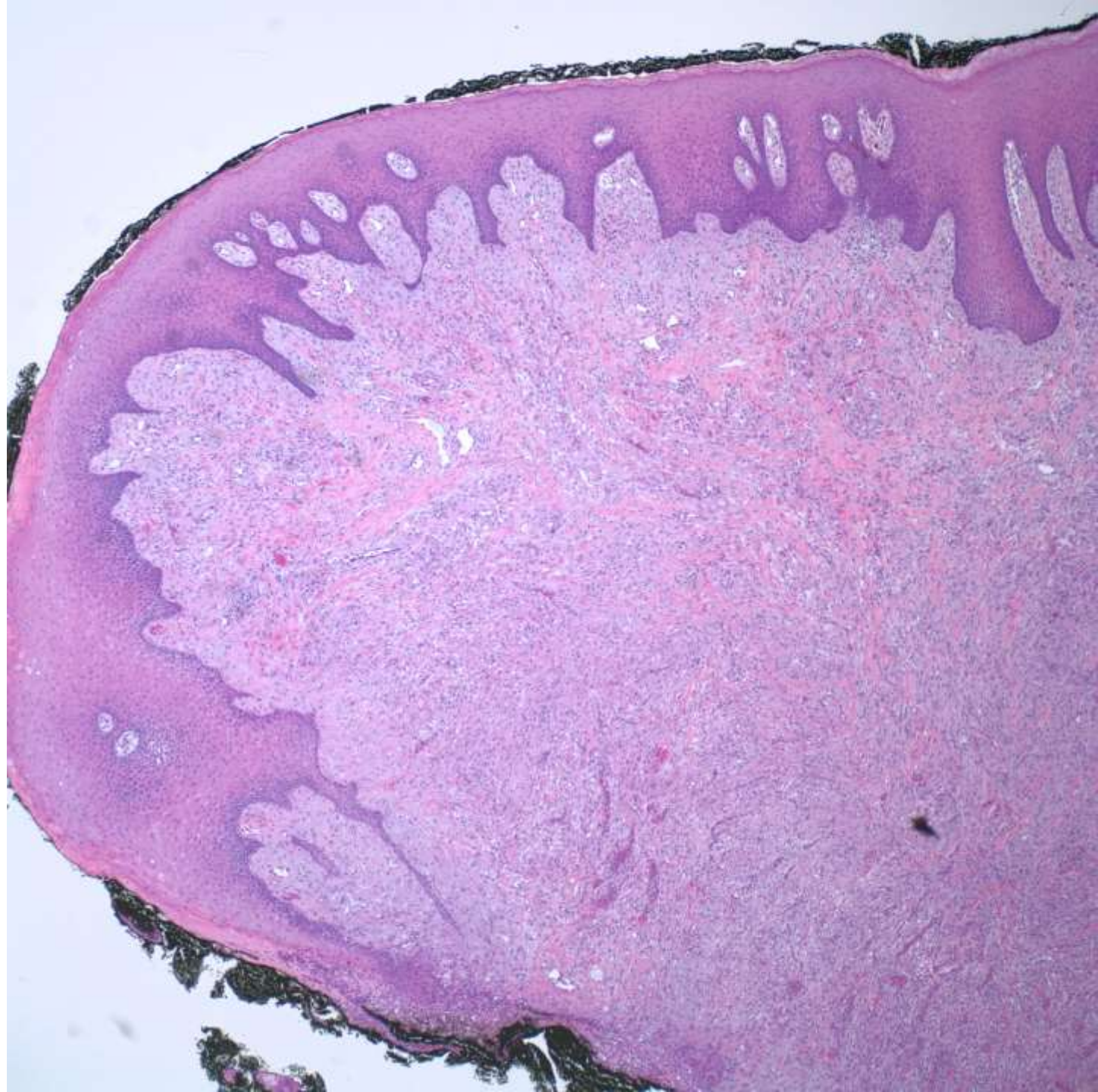
S100

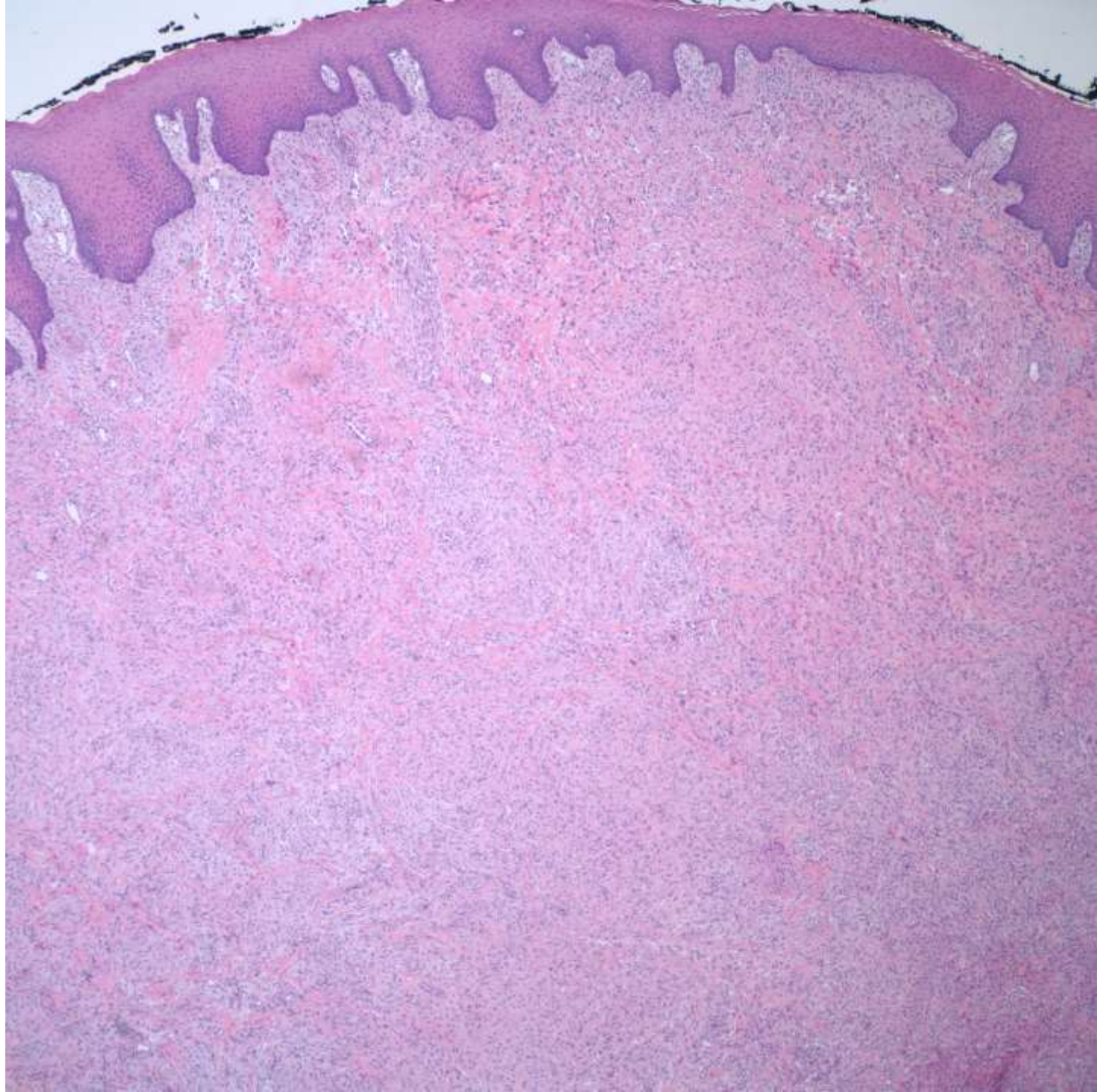


# 19-0709

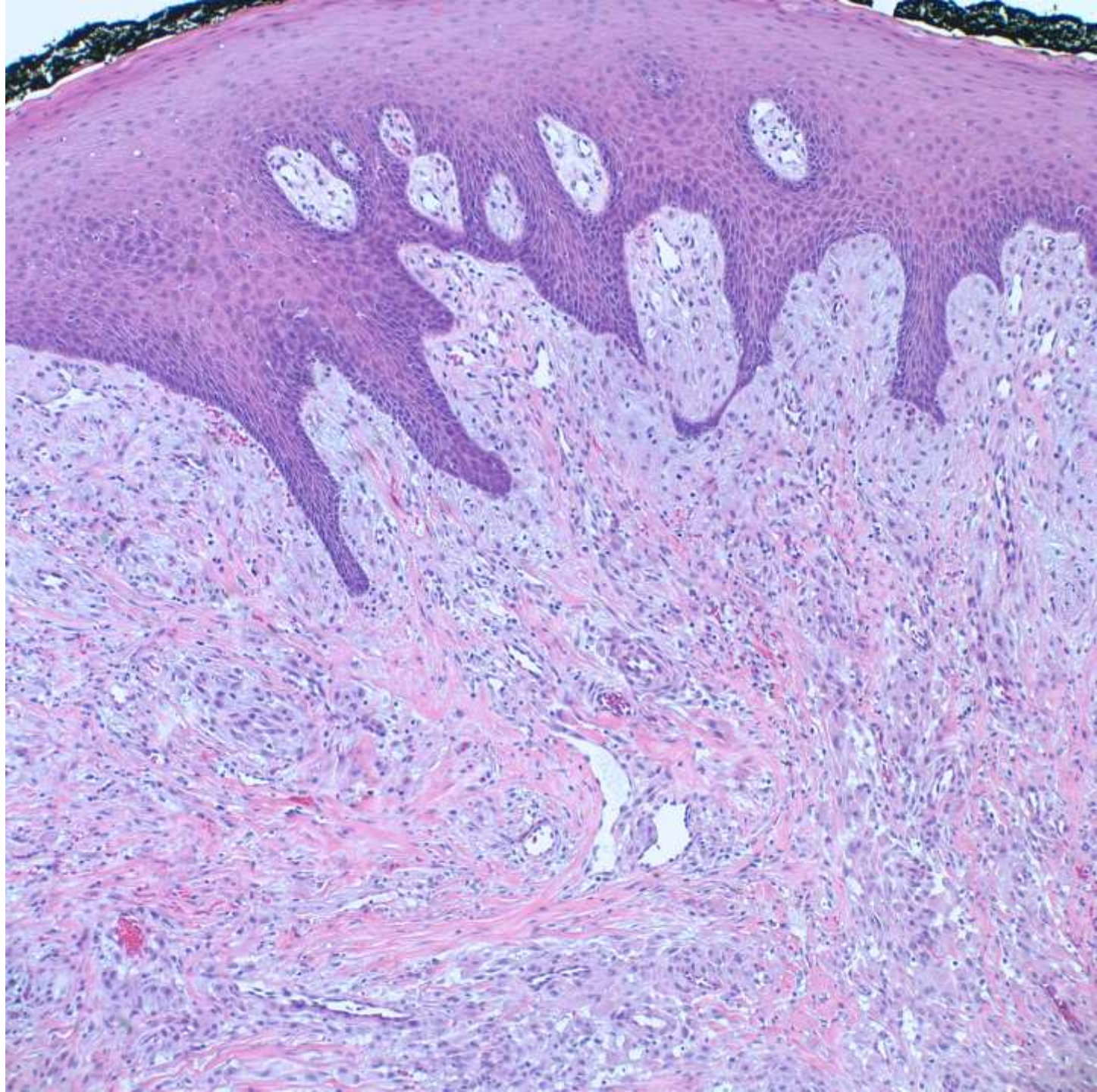
Dennis Adams/Gerald Berry;  
Stanford

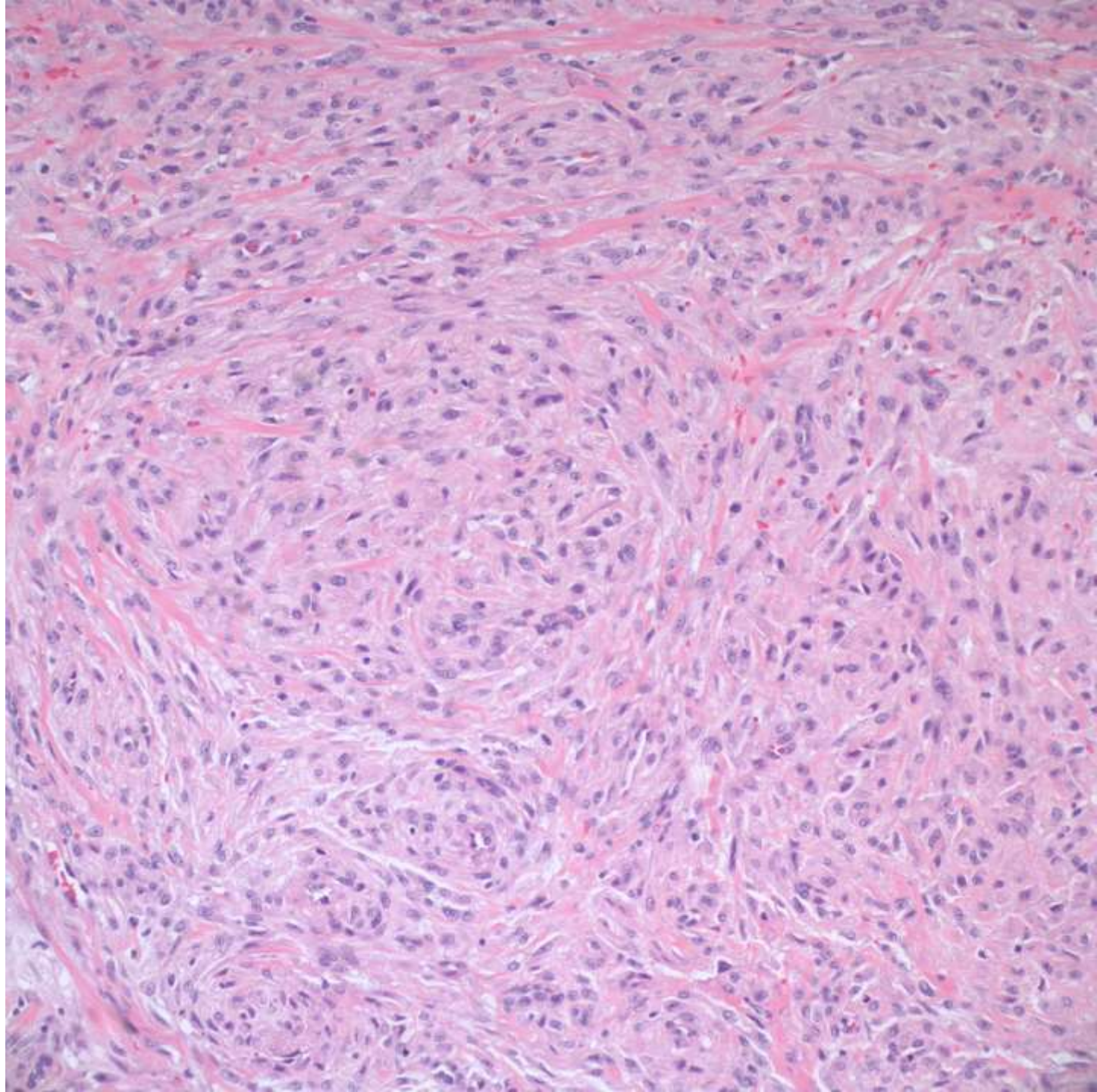
16-month-old male with was  
incidentally found to have a tongue  
lesion of unknown duration.

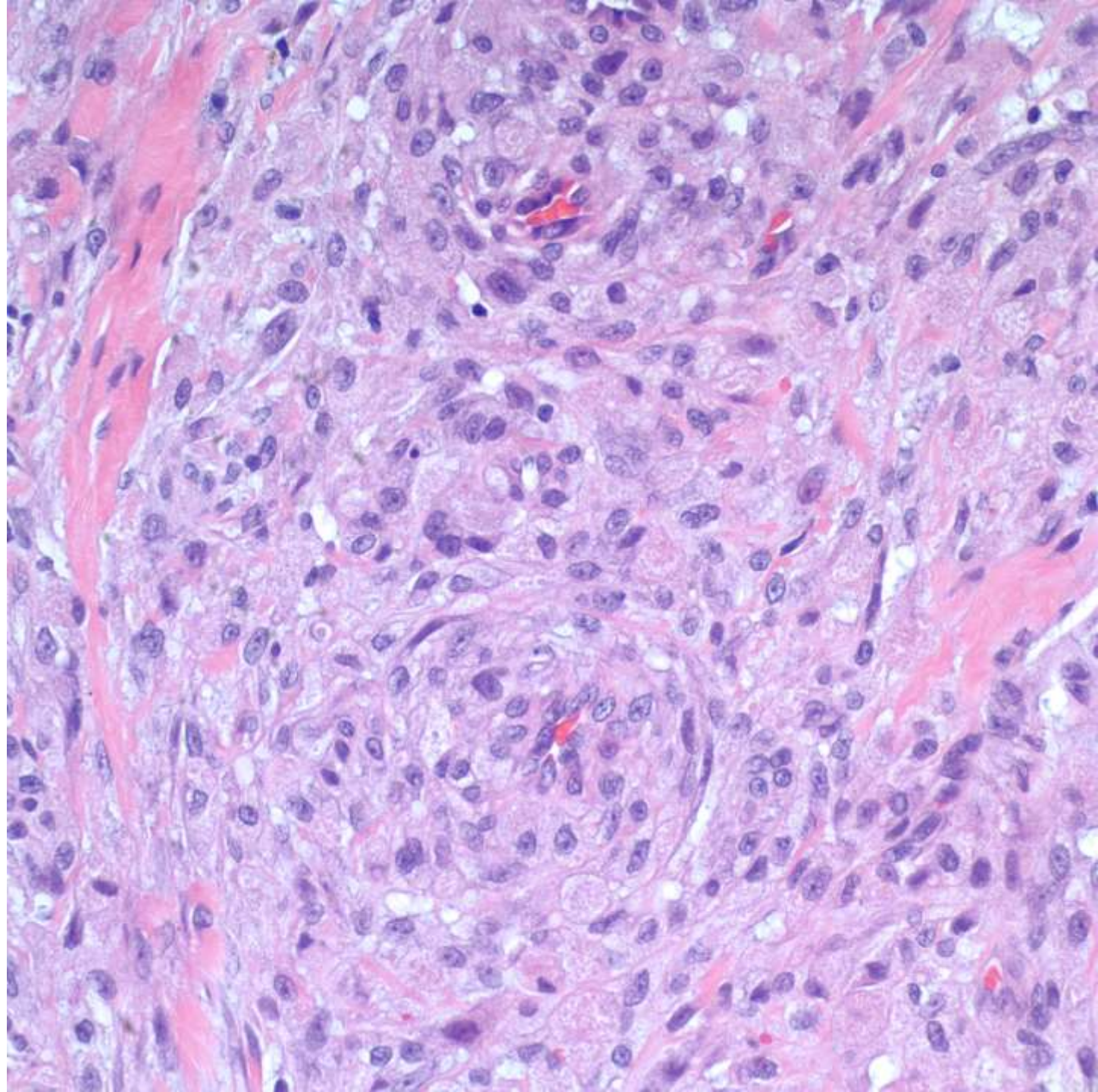












# 19-0710

Hannes Vogel; Stanford

64-year-old male with pituitary  
tumor.

