South Bay Pathology Society
October 2025 Web cases

Disclosures
October 6, 2025

Dr. Brooke Howitt has disclosed active financial relationships with Leica (educational honoraria), Abbvie (consultant), Santa Ana Bio (stock options) and Cartography Biosciences (consultant and stock options). Dr. G. Charville has disclosed an active financial relationship with Cartography Biosciences (consultant). South Bay Pathology Society has determined that none of these relationships are relevant to the clinical diagnostic cases being discussed. The activity planners and faculty listed below have no relevant financial relationship(s) to disclose with ineligible companies whose primary business is producing, marketing, selling, re-selling, or distributing healthcare products used by or on patients.

Presenters/Faculty:
Armen Kharar jian, MD
Tanya Ponnatt, MD
Anjanaa Vijayanarayanan, MD
Emily Chan, MD
Eric Ollila, MD
Haijuan Gao, MD
Maggie Lam, MD
Nivaz Brar, MD
John Higgins, MD

Activity Planners/Moderator:
Kristin Jensen, MD
Megan Troxell, MD, PhD
Dave Bingham, MD

25-1001

Armen Kharar jian, MD, MBA; Kaiser Walnut Creek

Young male with left cervical neck mass

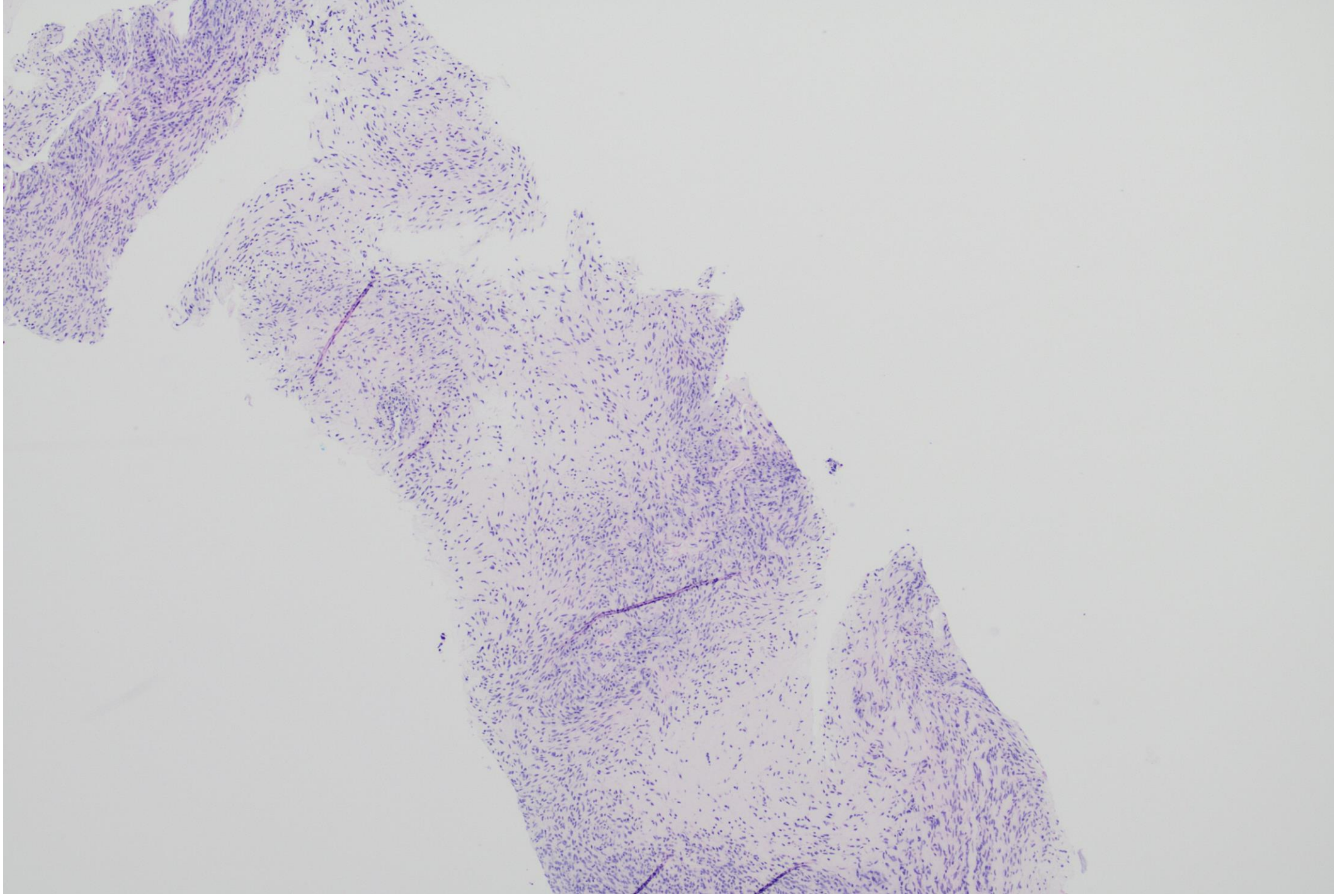

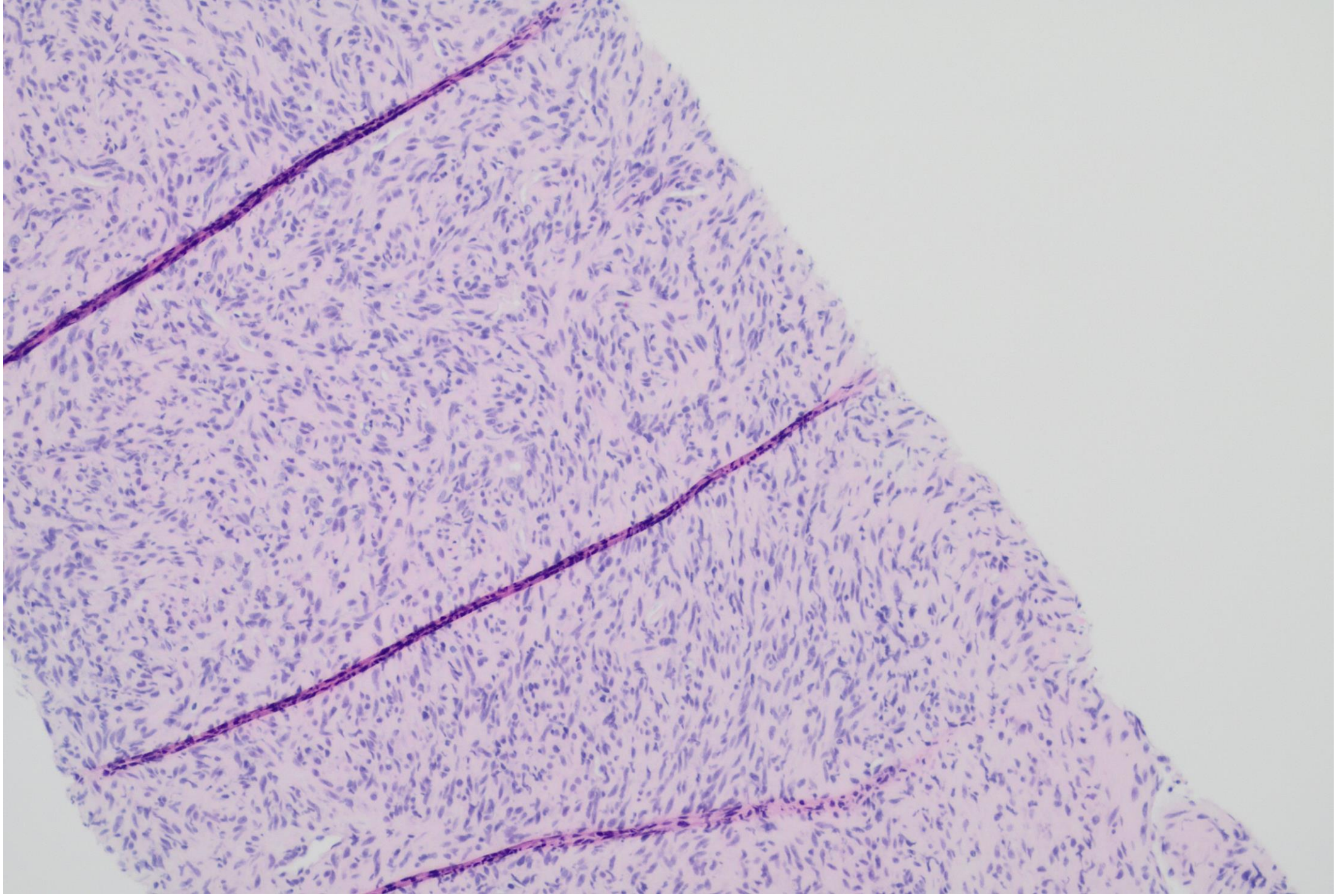

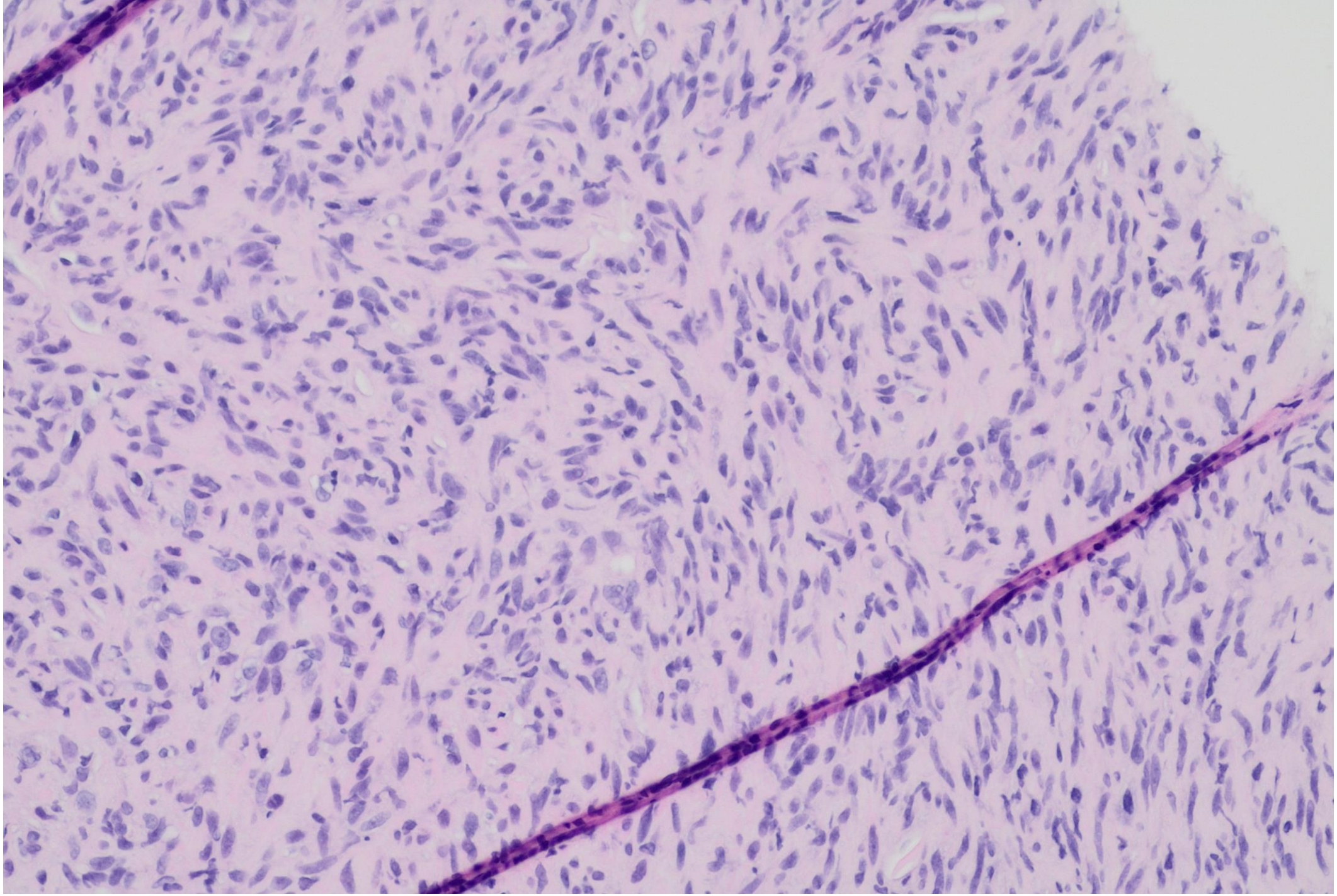

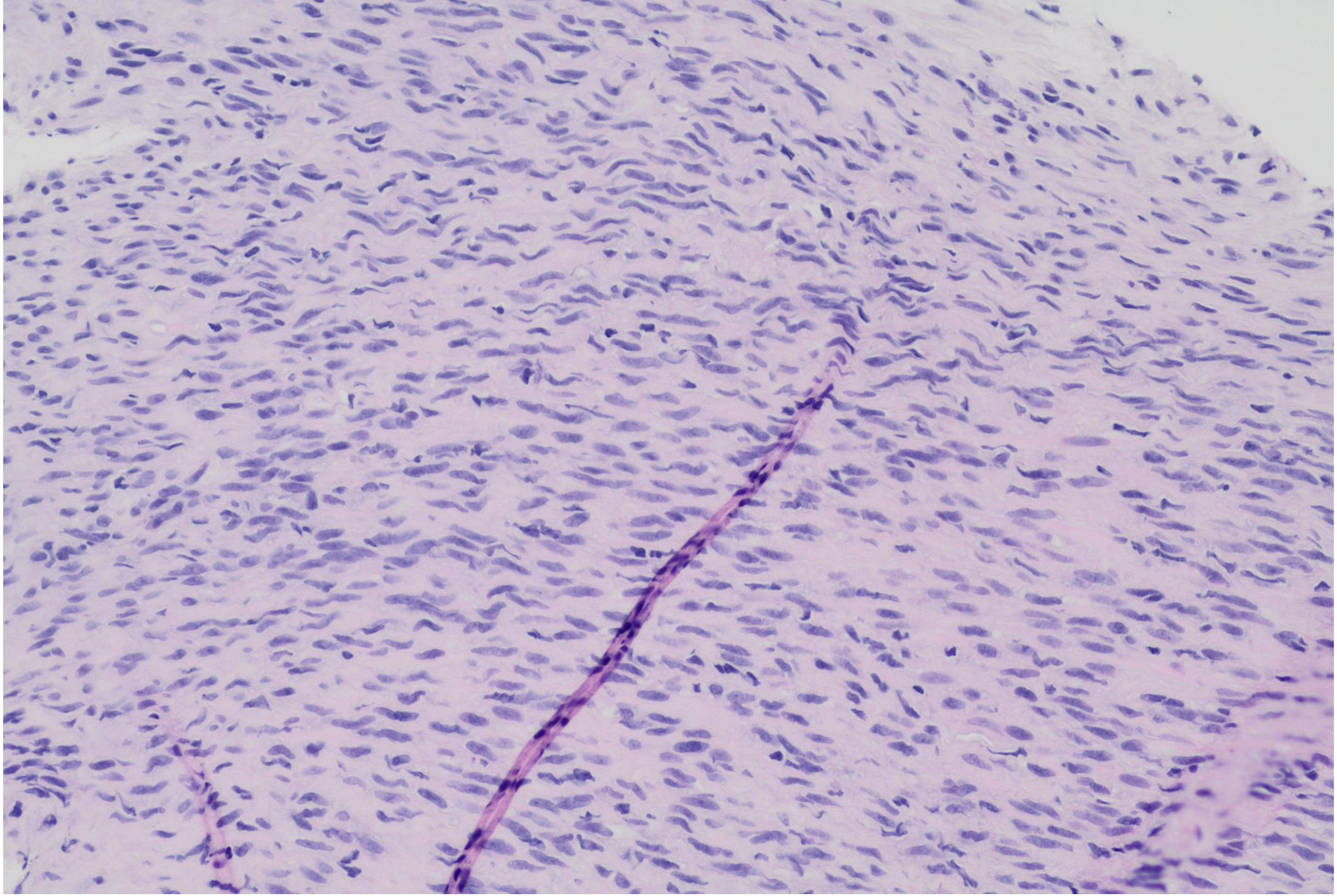

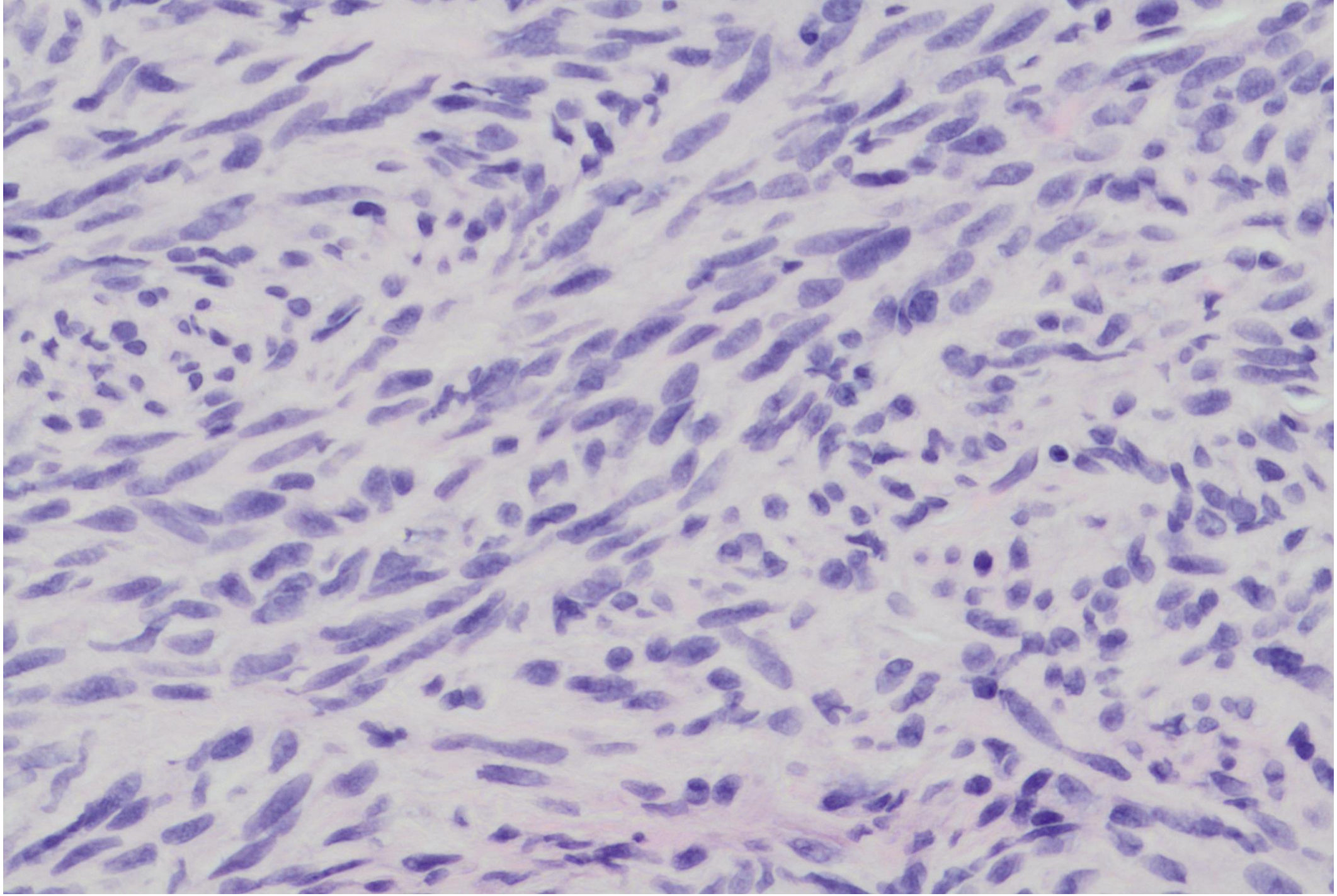

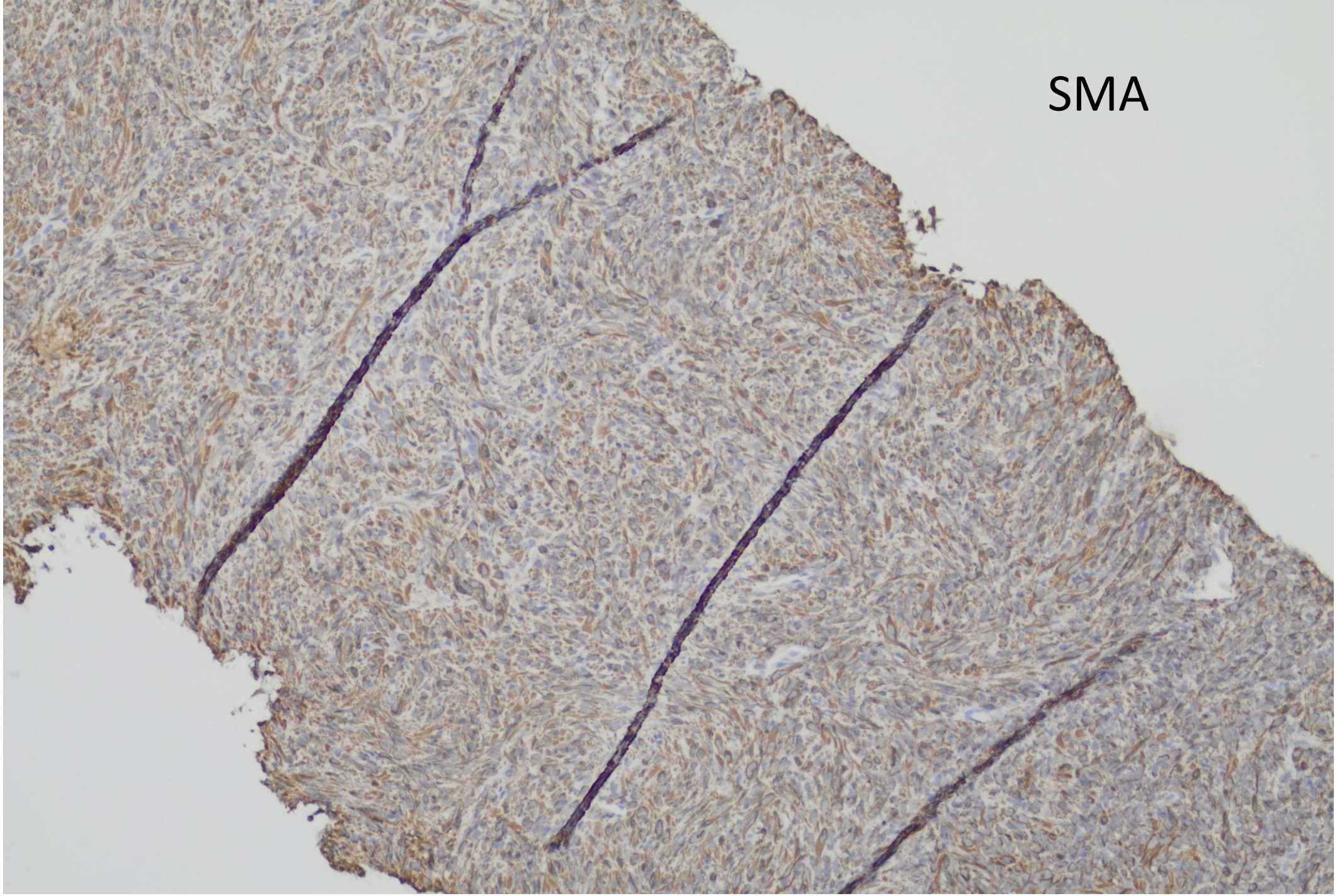
SMA

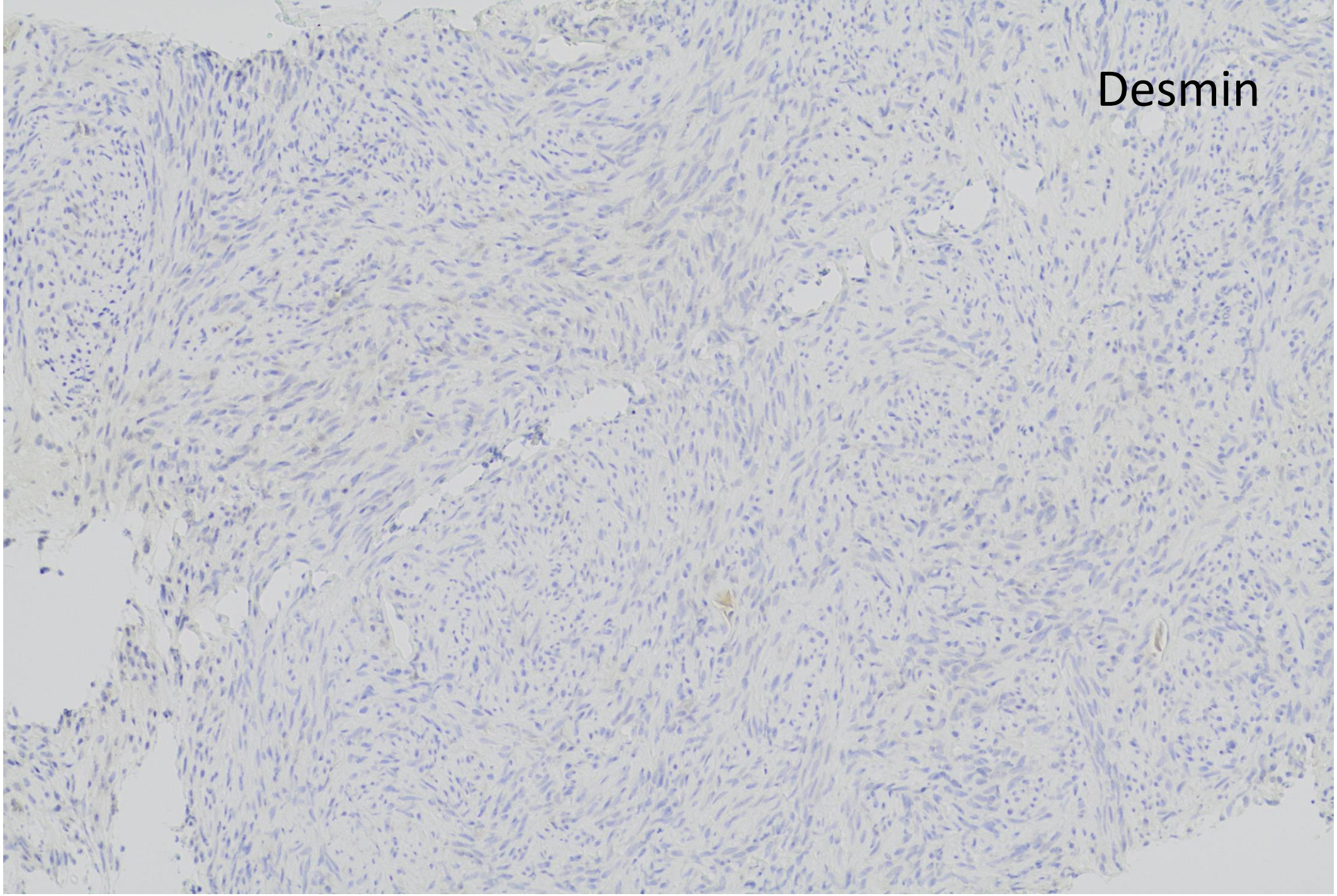
Desmin

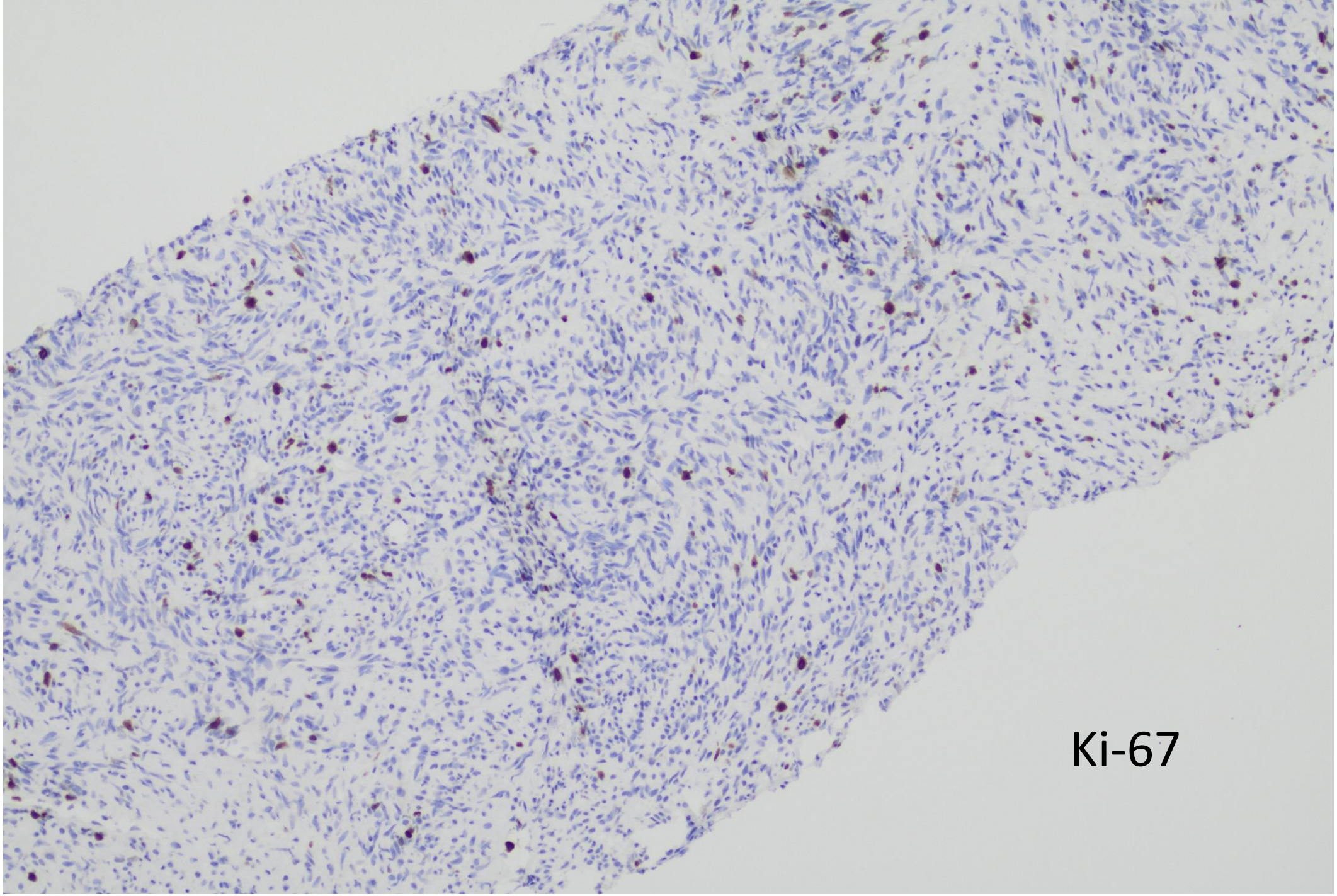
Ki-67

Other Negative Stains

- Pancytokeratin
- EMA
- S100
- SOX10
- MelanA
- STAT6
- Wild Type p53

DIAGNOSIS?

CARIS LIFE SCIENCES

Pathogen Identification

EBV	10,991,846	Positive	≥100,000 Reads

Epstein-Barr virus (EBV) detection by Whole Exome Sequencing (WES) Methods:
The DNA of EBV must be detected for a tumor to be considered positive for EBV. This EBV-detection assay determines EBV-status using WES to enumerate the number of sequencing reads specific to EBV. EBV is commonly found in gastric/esophageal junction carcinomas (EJC) and nasopharyngeal carcinoma (NPC) of the head and neck.

EBV-positive gastric/EJC and NPC tumors exhibit molecular hallmarks of potential sensitivity to cancer immunotherapy: EBV-positivity has been associated with partial responses to immunotherapy in gastric/EJC cancer, and define an undifferentiated subtype with superior prognosis and an immune-dense microenvironment in NPC.

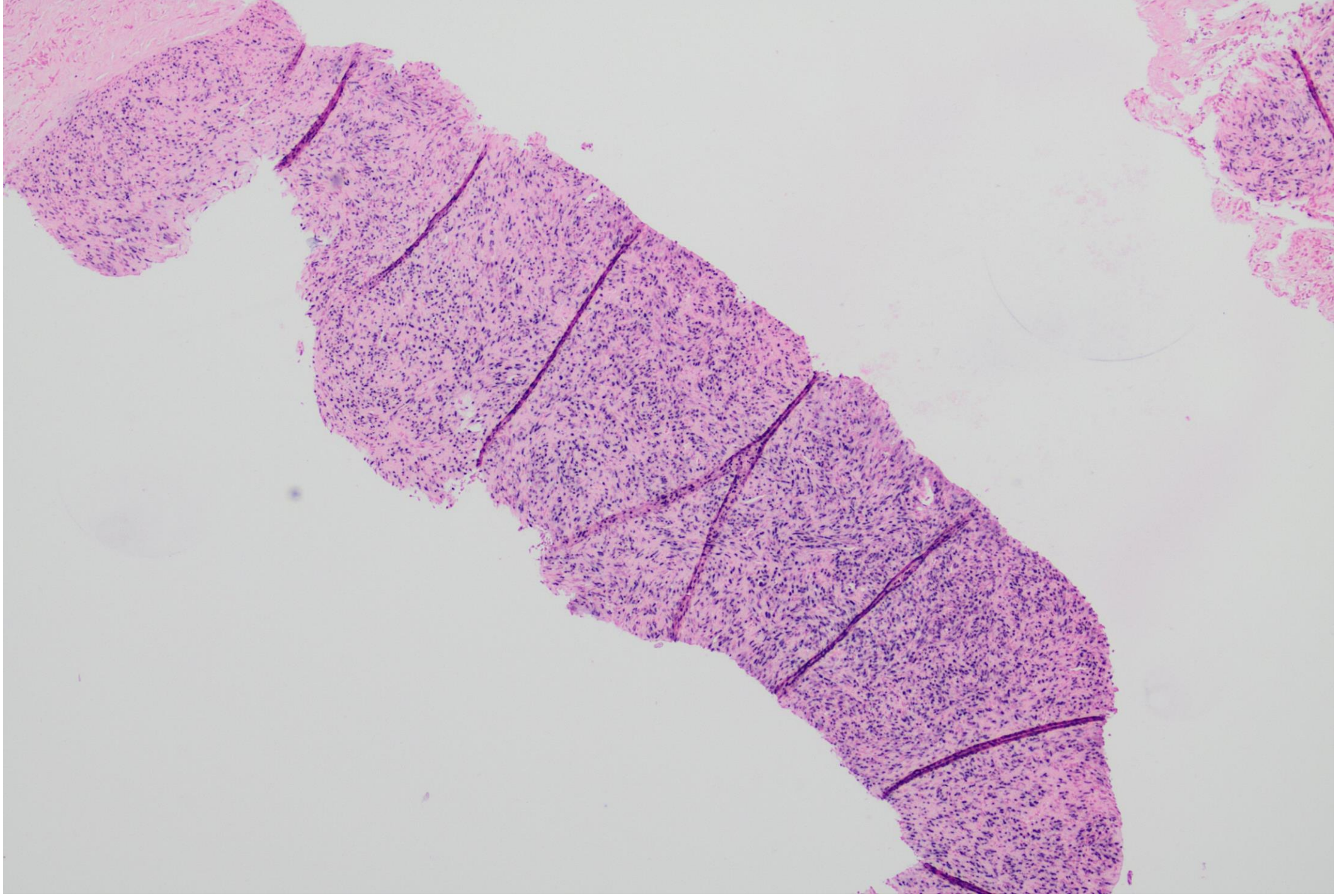

Thoughts?

EBV Associated Smooth Muscle Tumor

- Neoplasm with smooth muscle differentiation
- Patients have a clinical history of immunosuppression
- Wide age range with slight female predominance
- Most common clinical settings
  - HIV/AIDS
  - Post-transplant
  - Congenital or primary immunodeficiency (least common)
- Can occur anywhere in the body

EBV Associated Smooth Muscle Tumor

- Pathogenesis
  - Infection and transformation of smooth muscle cells by EBV
- Histology
  - Fascicular arrangement of well-differentiated smooth muscle cells
  - Vesicular nuclei with small nucleoli
  - Lack of nuclear pleomorphism
  - Low mitotic rate

EBV Associated Smooth Muscle Tumor

- Prognosis
  - Most do not metastasize
  - Adverse prognosis mostly related to comorbidities of immunosuppression
- Treatment
  - Surgery or reduced immunosuppression

25-1002

Tanya Ponnatt, Anjanaa Vijayanarayanan; UCSF

65-year-old, otherwise healthy man with diffuse lymphadenopathy and multiple radiolucent bone lesions.

<u>CBC:</u>

- Hgb: 10 g/dL
- WBC: 61.6 x 10E9/L
- Absolute lymphocyte: 50.9 x 10E9/L
- Platelets: 68 x 10E9/L

Lymph node biopsy

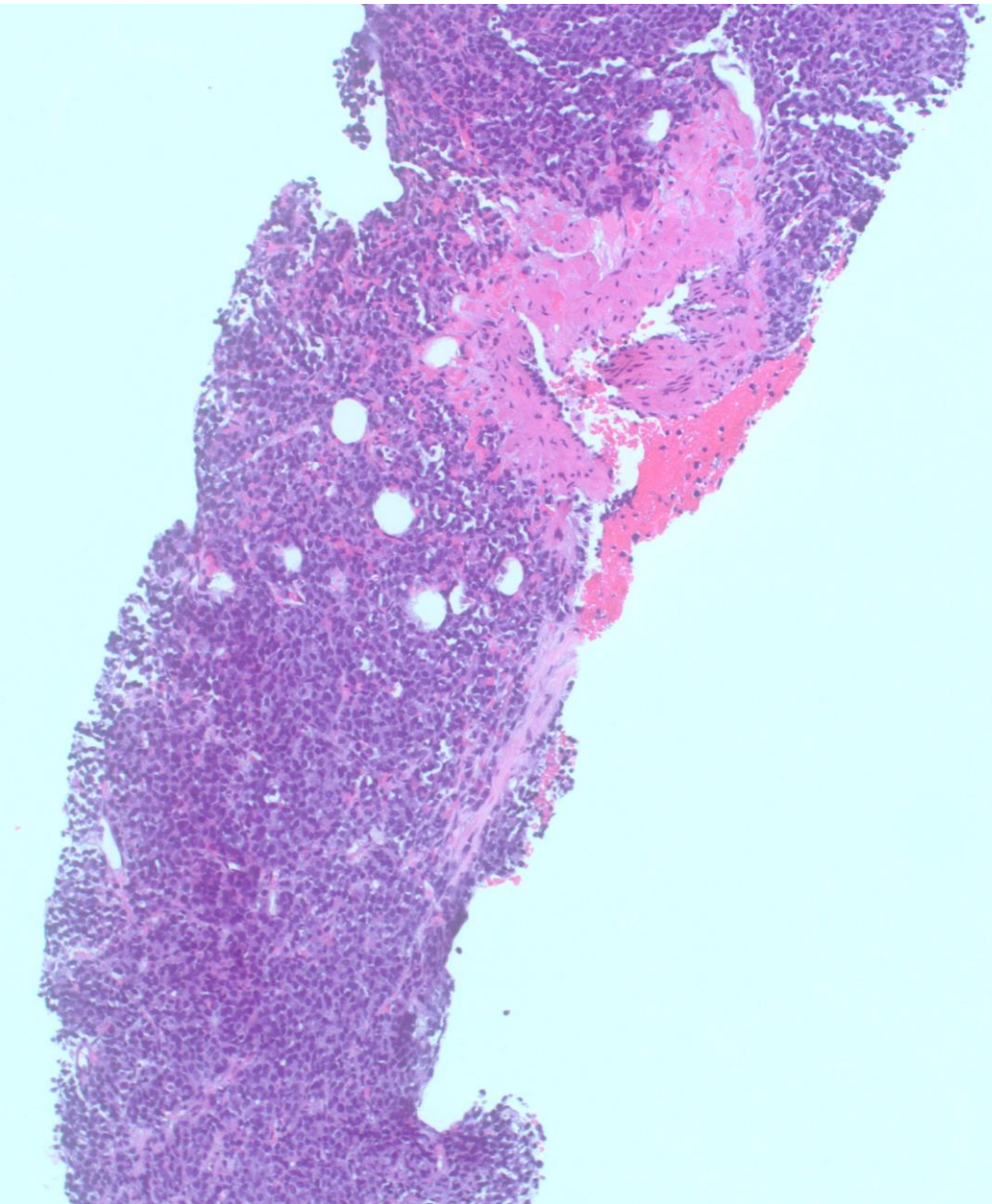

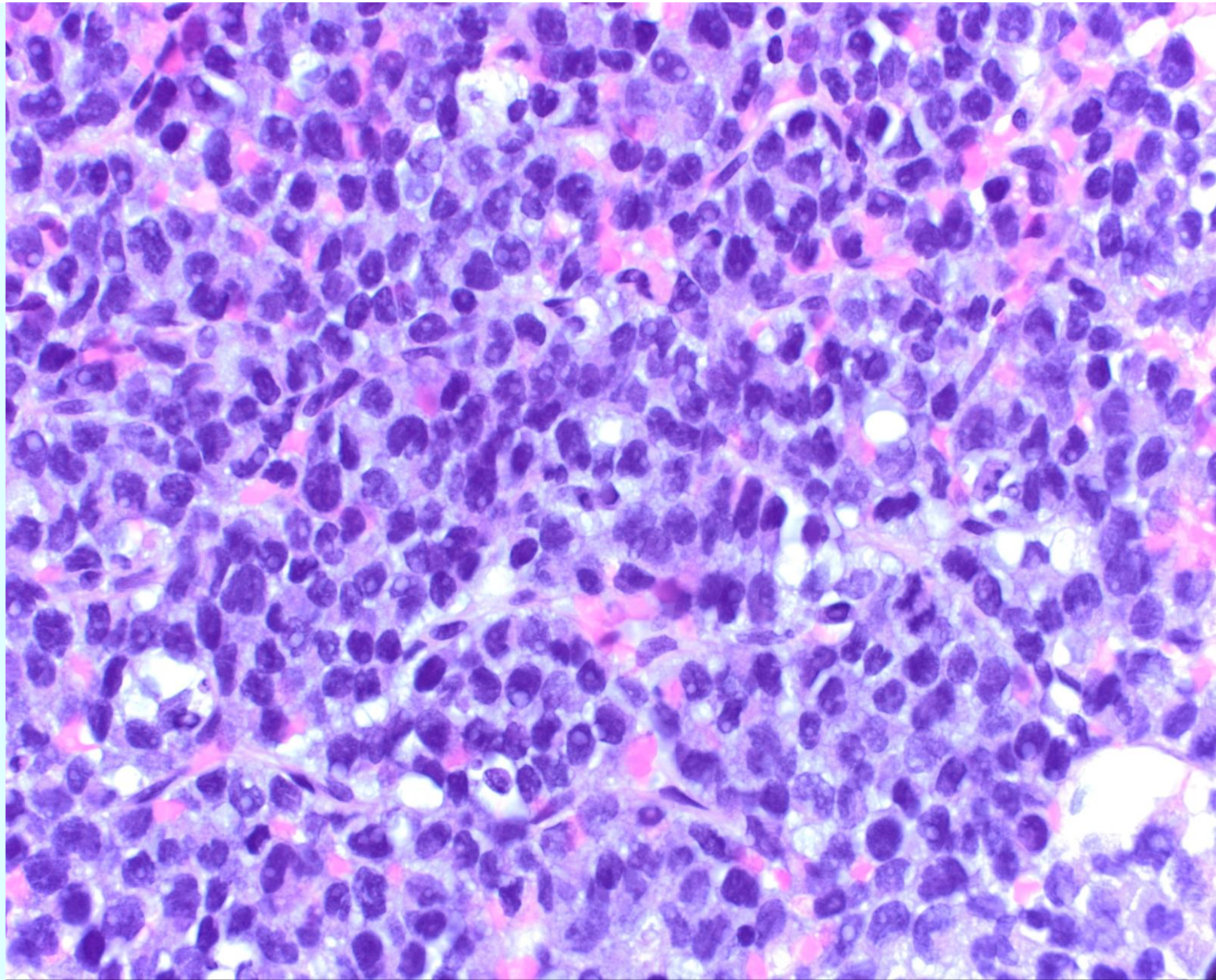

Blood

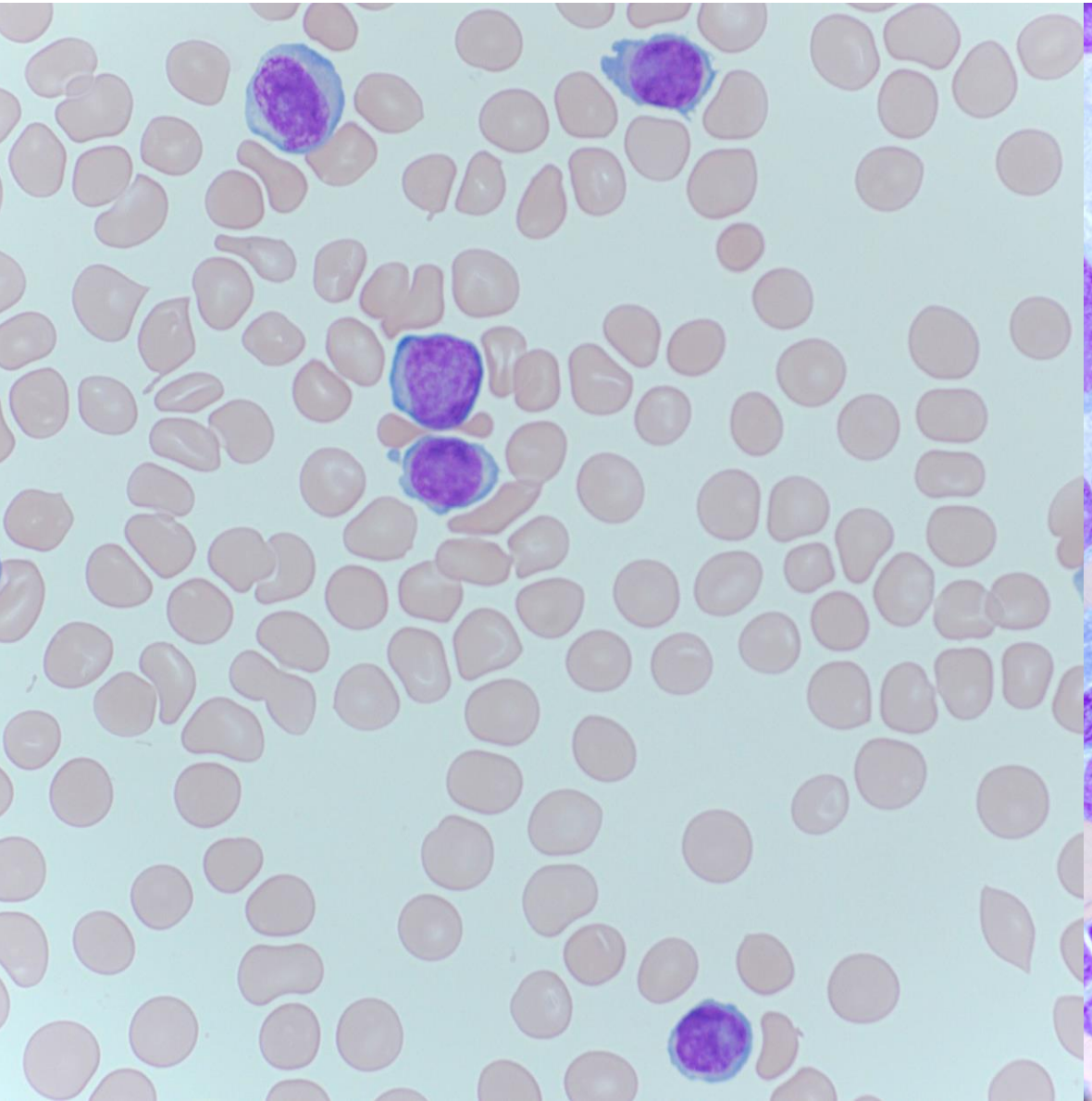

Bone marrow aspirate

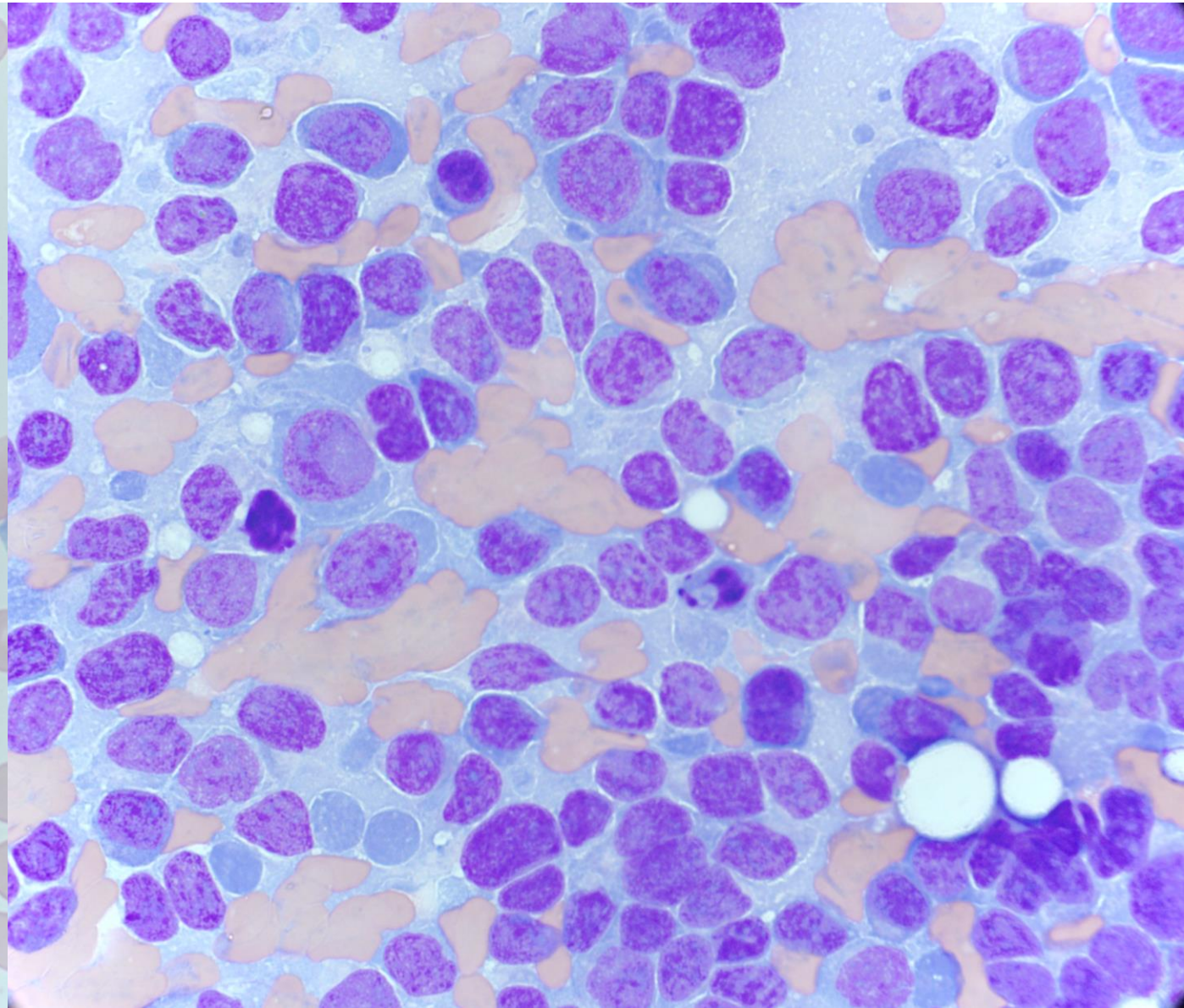


CD45

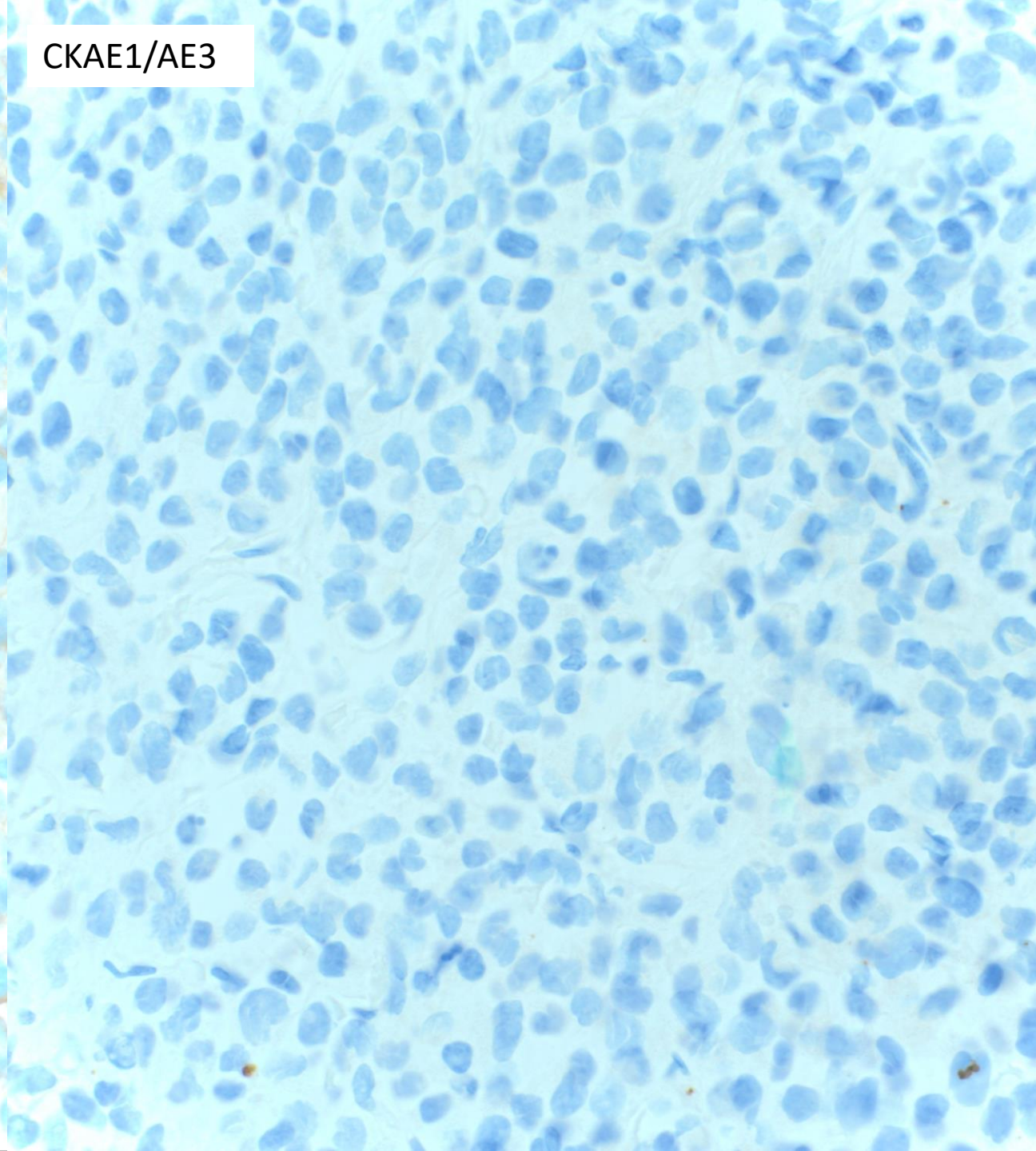
CKAE1/AE3

DIAGNOSIS?

Blood and bone marrow

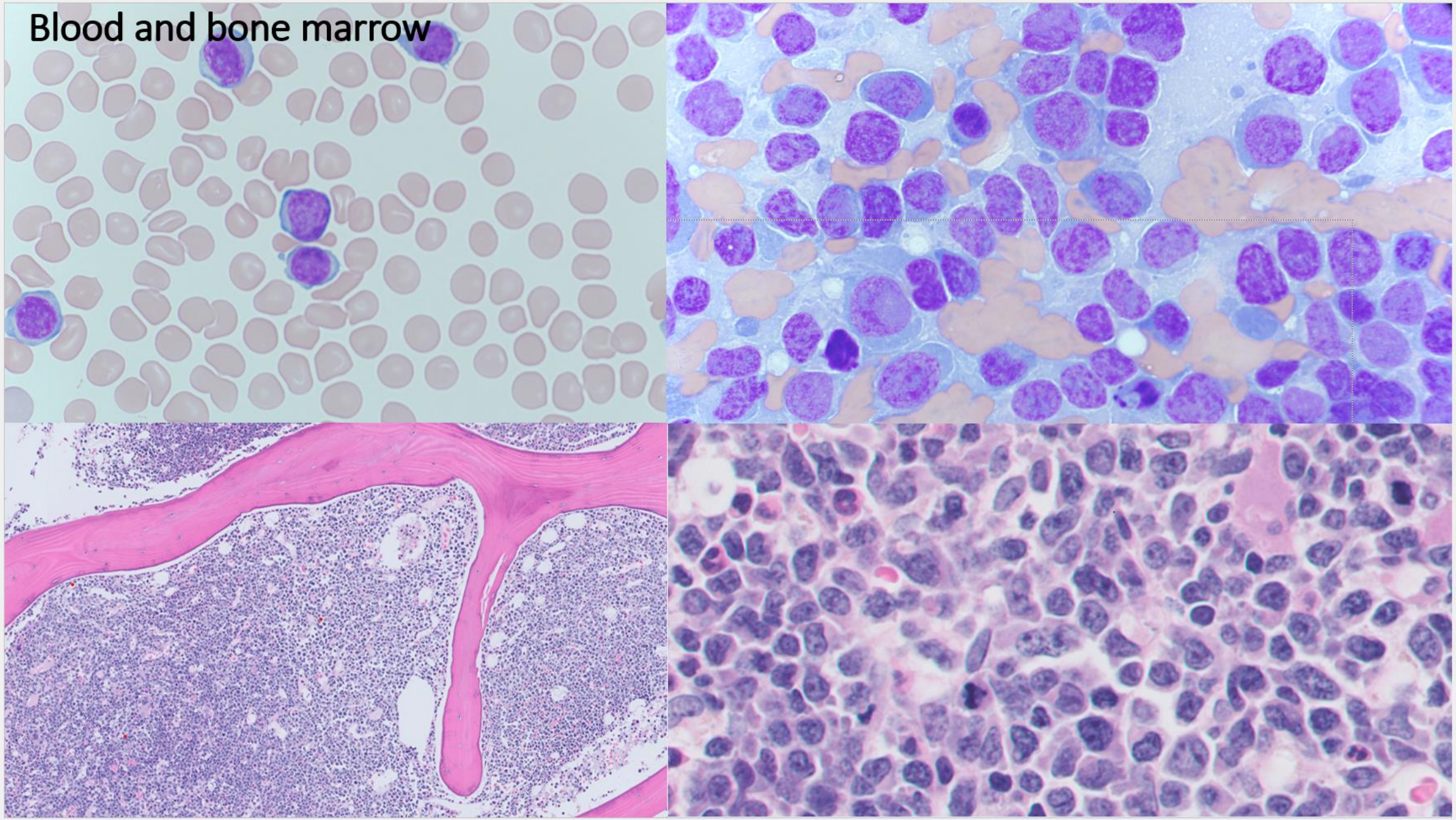

Retroperitoneal lymph node biopsy

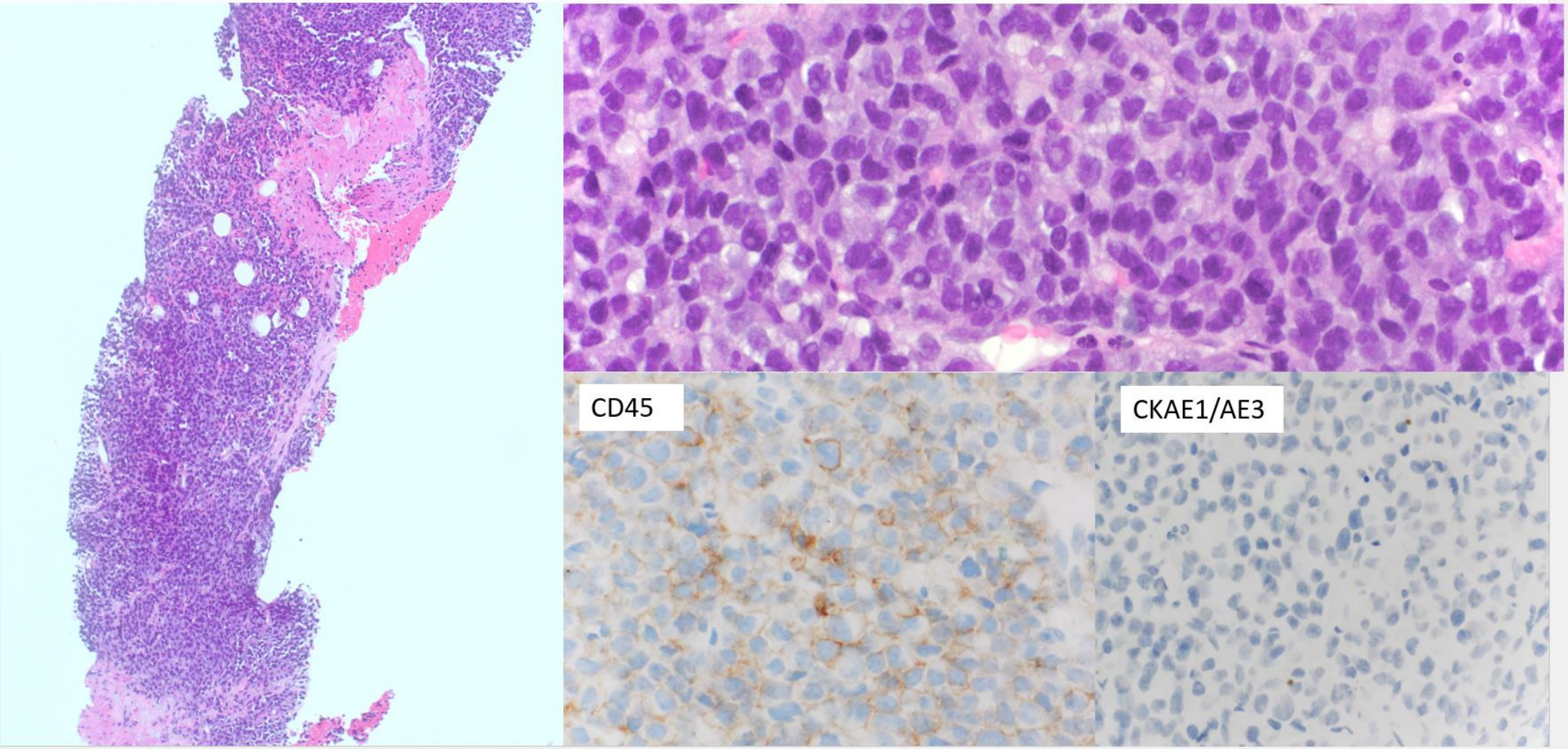

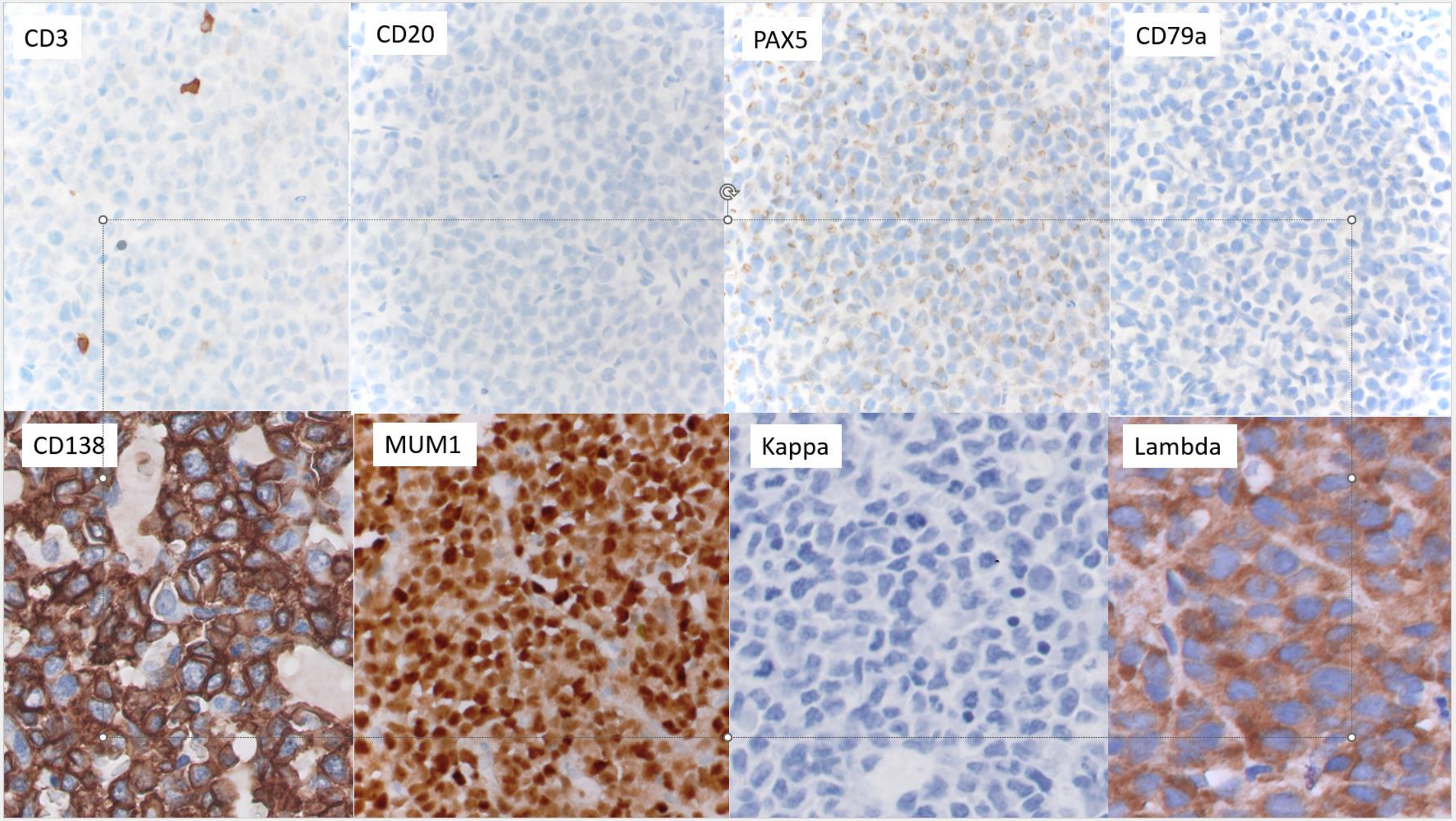
CD3
CD20
PAX5
CD79a
CD138
MUM1
Kappa
Lambda

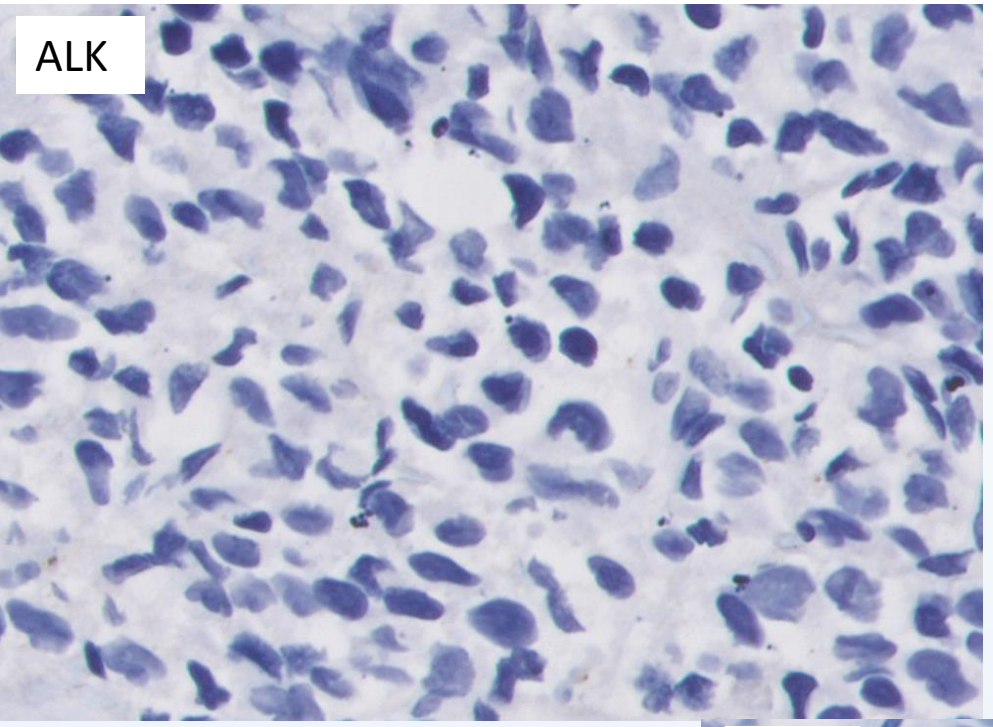
ALK

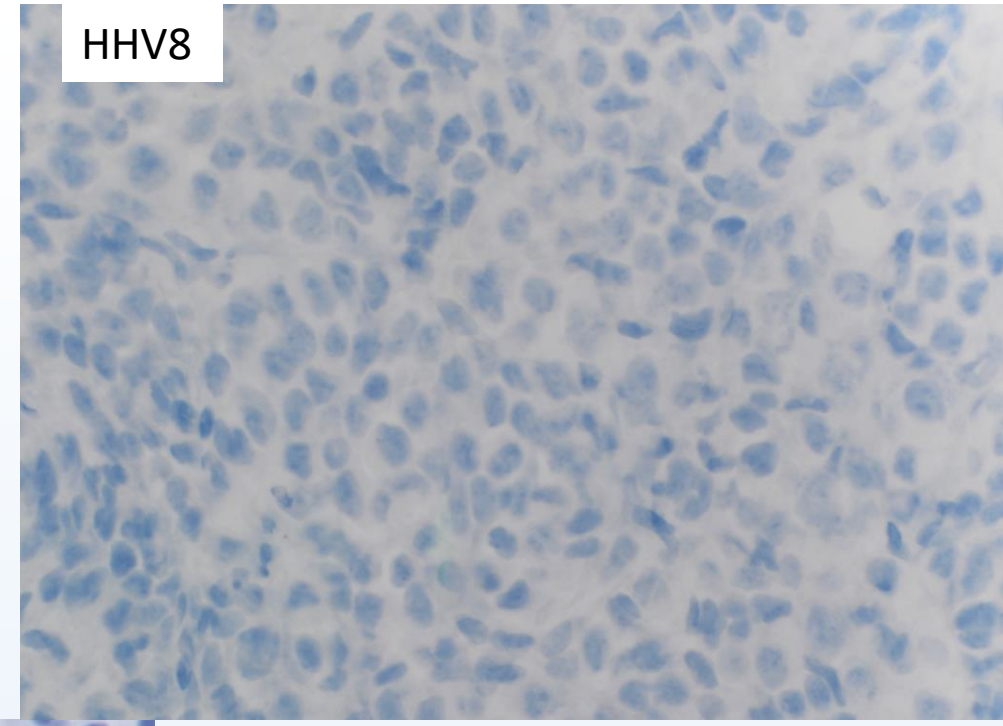
HHV8

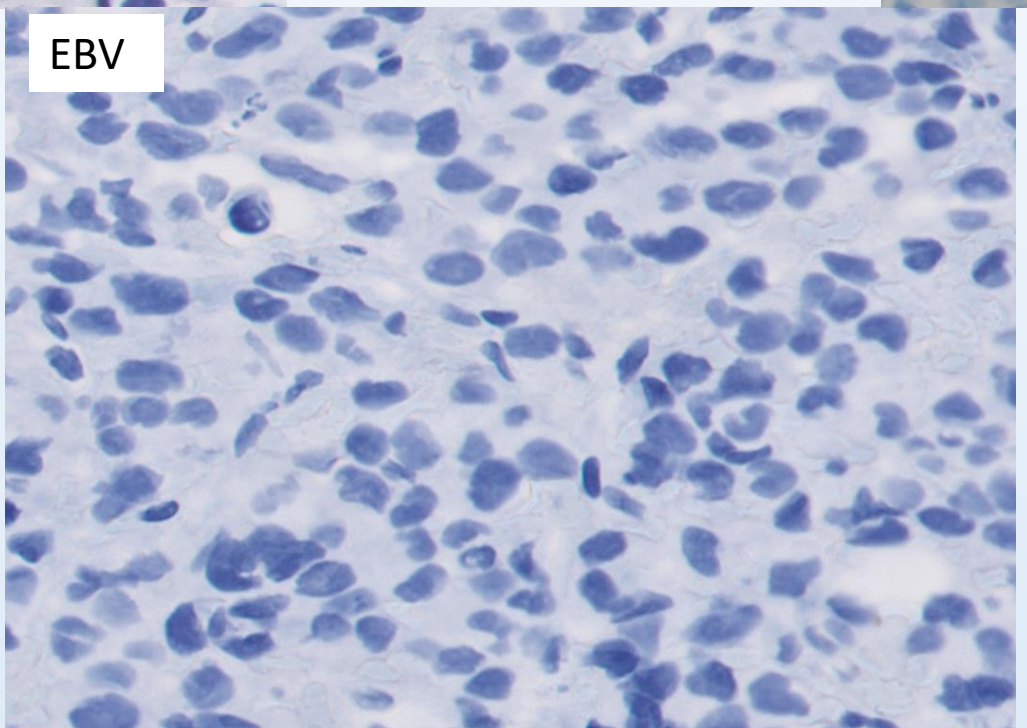
EBV

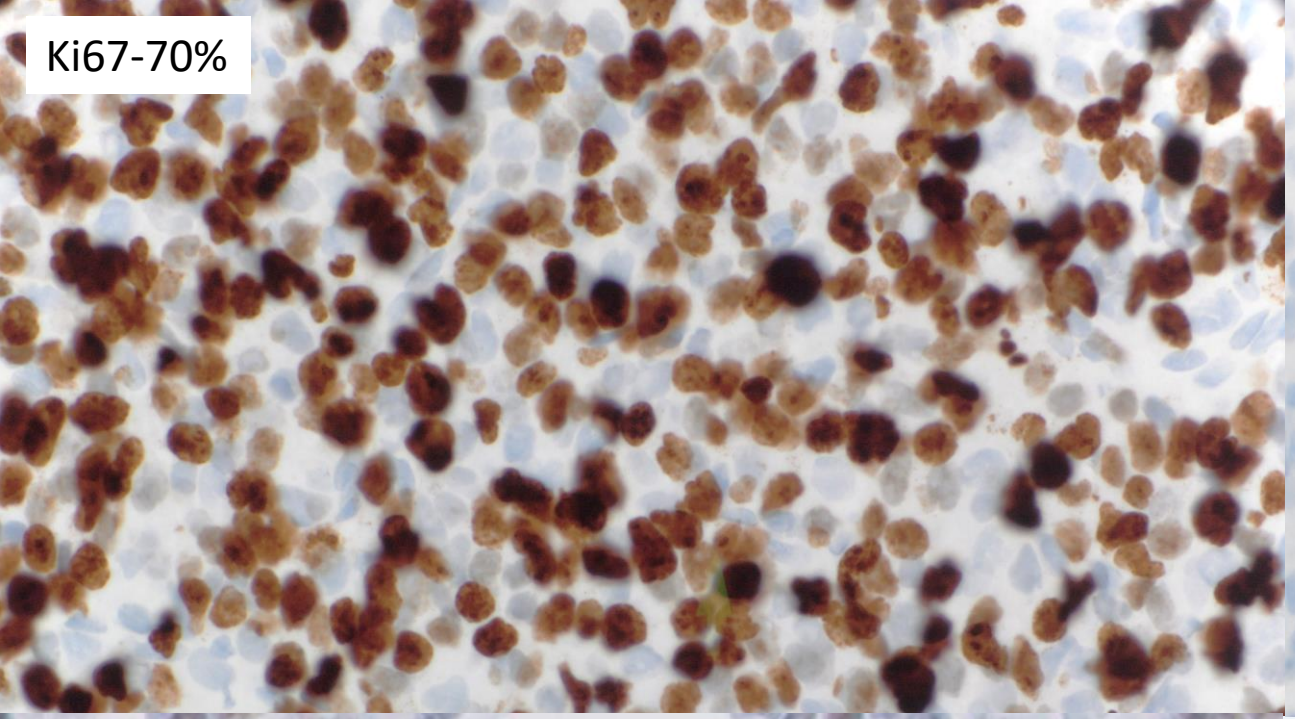
Ki67-70%

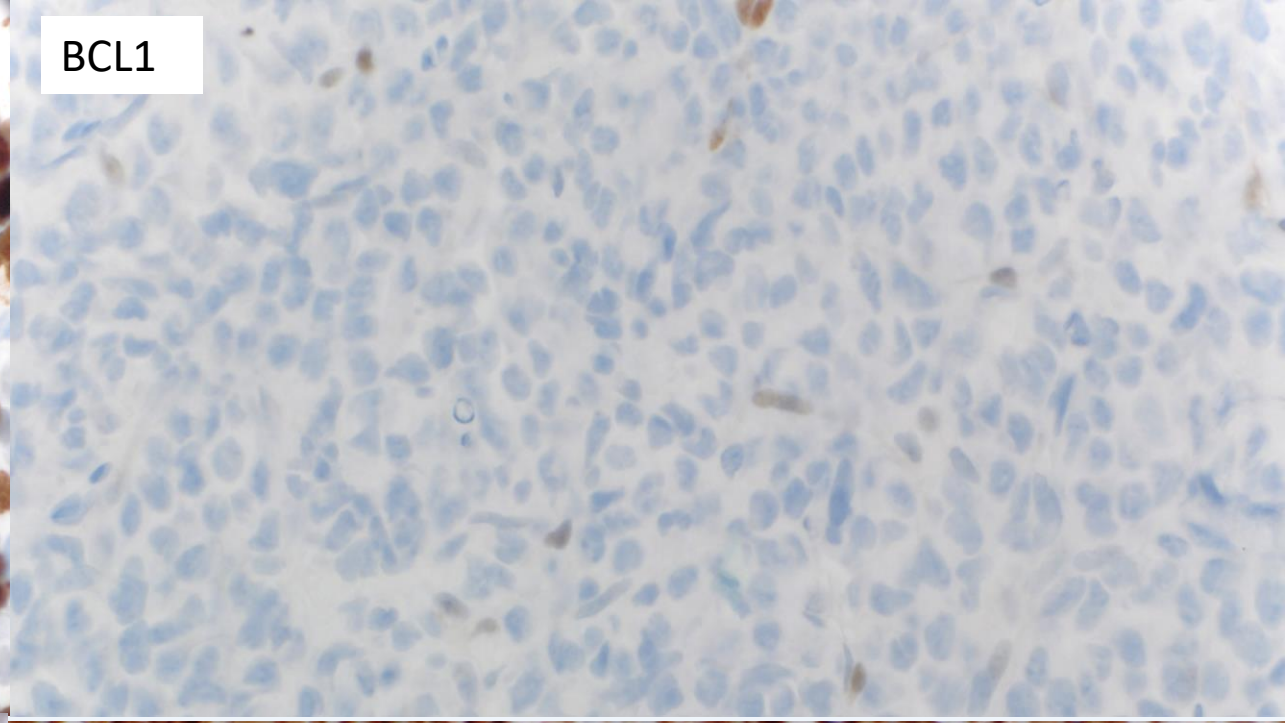
BCL1

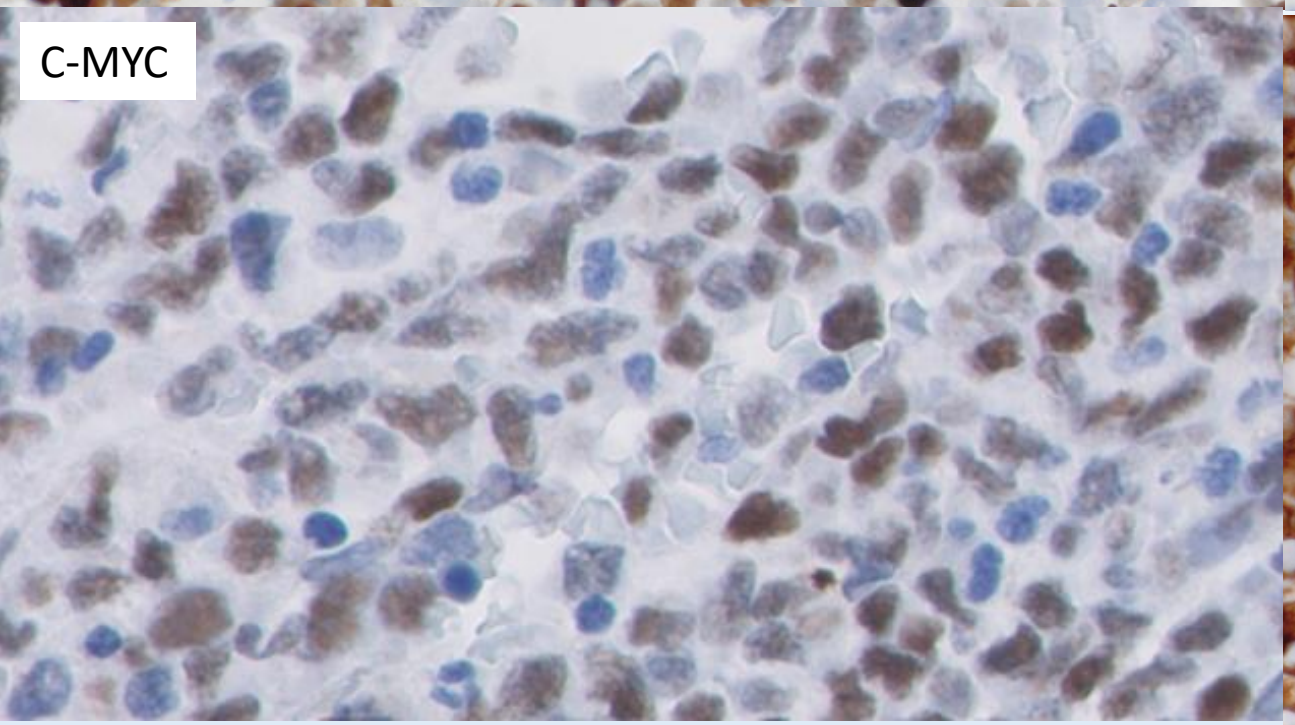
C-MYC

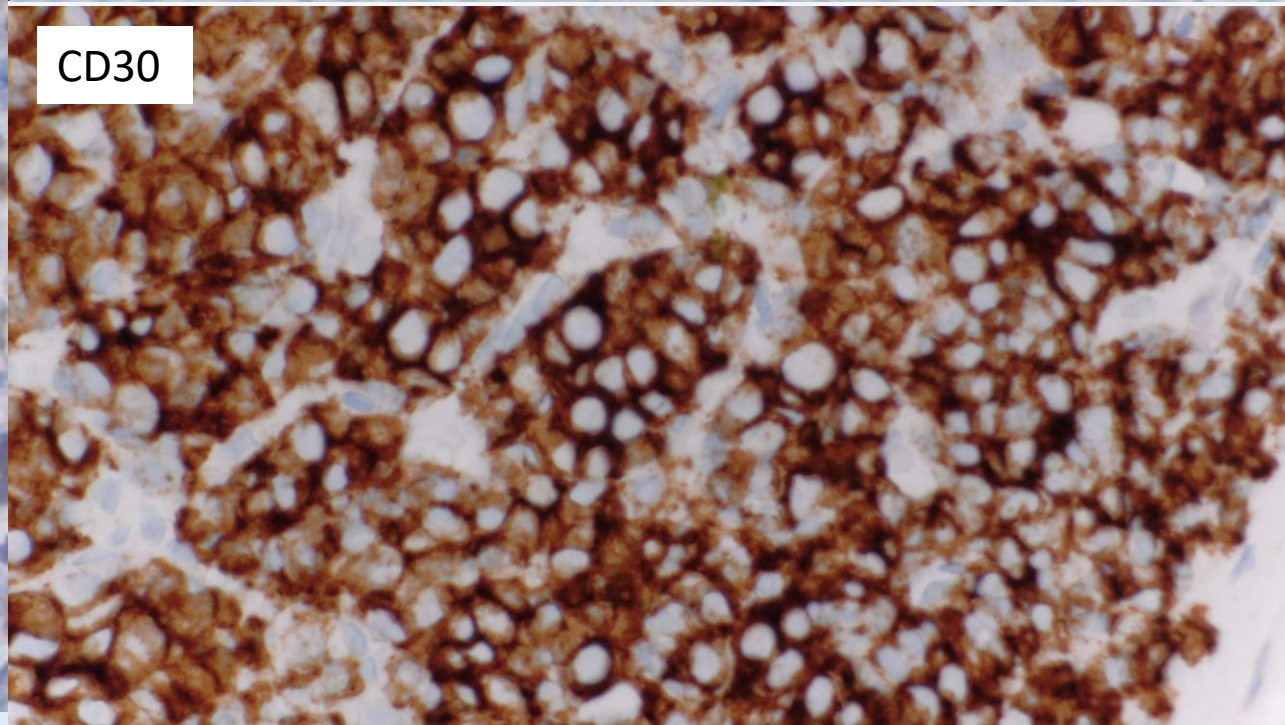
CD30

Differential Diagnosis

- **Plasma cell leukemia vs plasmablastic lymphoma with marrow involvement**

Ancillary tests

- Karyotype: 45~46,X,-Y,+1,add(1)(q12),add(6)(p11.2),-13,-14,-20,+3mar[3]/46,XY[5]
- <u>CD138 enriched MM FISH</u>
  - gain of 1q21 (CKS1B, 3 copies of 1q21)
  - loss of a chromosome 13
  - gain or rearrangement of 14q32 (IGH)
- <u>NGS</u>
  - Mutations in RAF1, KRAS, CDH2
  - IGH::IRF4 fusion mRNA - t(6;14)(p25;32)
  - Increased MAFB fusion mRNA - t(14;20)

- Additional Clinical history:SPEP - M protein (IgD heavy chain and free lambda light chain)

Final diagnosis

- Bone marrow biopsy:
  - Plasma cell leukemia with high grade cytological features

- Lymph node biopsy
  - Plasma cell neoplasm with anaplastic features

Cancers (Basel). 2025 Jun 9;17(12):1914. doi: 10.3390/cancers17121914

The Genetic and Epigenetic Alterations of Plasmablastic Lymphoma: A Narrative Review

Michele Bibas [1,*], Andrea Antinori [2], Valentina Mazzotta [3], Teresa Marafioti [4,5], Jorge J Castillo [6,7]

Clinical Feature	Plasmablastic Lymphoma	Myeloma
Typical Age Group	Middle-aged to older adults; common in HIV+ patients	Older adults (median ~65–70 years)
Immune Status	Often immunocompromised (HIV/AIDS, post-transplant)	Generally immunocompetent
Site of Involvement	Extranodal (oral cavity, GI tract, lymph nodes, skin)	Bone marrow; bone lesions, extramedullary involvement
Symptoms	Rapidly growing mass, B symptoms, cytopenias	CRAB
Course	Aggressive, rapidly progressive	Chronic but progressive
Response to Therapy	Poor response to conventional CHOP or EPHOC; high relapse	Responds to new Drugs and Therapies
Prognosis	Poor (<1 year in advanced cases)	Variable; improved with modern therapy
Diagnostic Challenges	Mimics myeloma (sometimes on morphology and immunophenotype); usually lacks marrow CRAB features	Mimics PBL morphologically and on immunophenotype; systemic/marrow involvement

Plasmablastic lymphoma	Myeloma
MYC rearrangements (50–60%) with frequent partner: IgL/IgH TP53 mutations (30–50%) PRDM1/BLIMP1 loss.	Hyperdiploidy (50%) IgH translocations (t(11;14), t(4;14), t(6;14), t(14;16)) Del(17p) (high-risk) Rare MYC rearrangements MYC upregulation via secondary mechanisms
Gain of ch1q has been described	
Translocations commonly encountered in myeloma other than MYC rearrangements have not been described in PBL.	
STAT3 (30%) KRAS/NRAS SOCS1 TET2 CARD11	KRAS/NRAS (50%) BRAF (10–15%) TP53 (10%) FAM46C

Haematologica. 2021 May 6;106(10):2682–2693. doi: 10.3324/haematol.2020.271957

MAPK and JAK-STAT pathways dysregulation in plasmablastic lymphoma

Joan Enric Ramis-Zaldivar [1,2,*], Blanca Gonzalez-Farre [1,2,*], Alina Nicolae [3], Svetlana Pack [3], Guillem Clot [1,2], Ferran Nadeu [1,2], Anja Mottok [4], Heike Horn [5,6,7], Joo Y Song [8], Kai Fu [9], George Wright [10], Randy D Gascoyne [4], Wing C Chan [8], David W Scott [4,11], Andrew L Feldman [12], Alexandra Valera [1], Anna Enjuanes [1,2], Rita M Braziel [13], Erlend B Smeland [14,15], Louis M Staudt [16], Andreas Rosenwald [17], Lisa M Rimsza [18], German Ott [5,6,7], Elaine S Jaffe [3], Itziar Salaverria [1,2,#], Elias Campo [1,2,19,#,✉]

25-1003

Emily Chan; Stanford

Mid-50s year old man with right testicular mass
LDH 228, AFP 6, bHCG <1

11
12
13
14

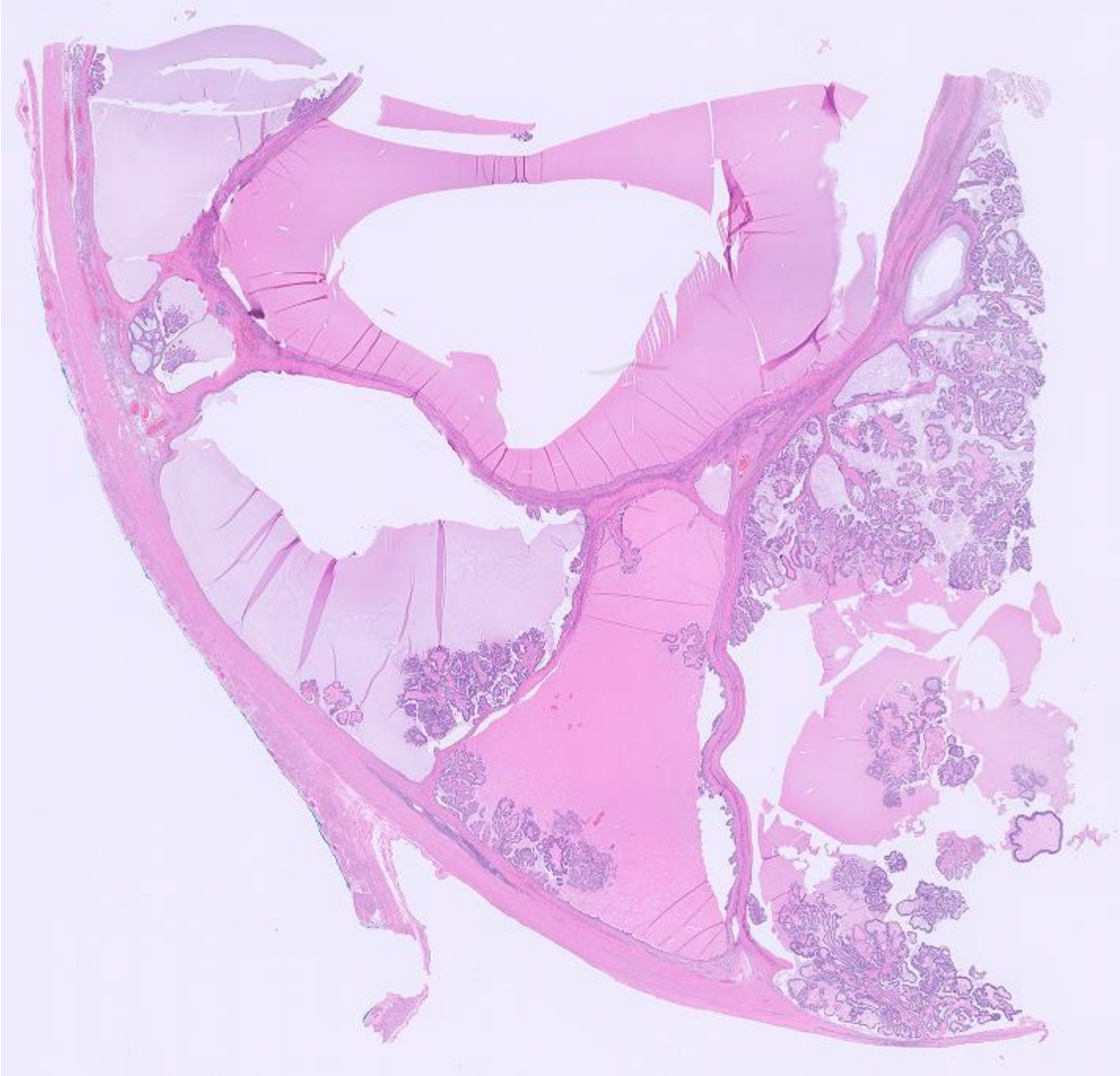

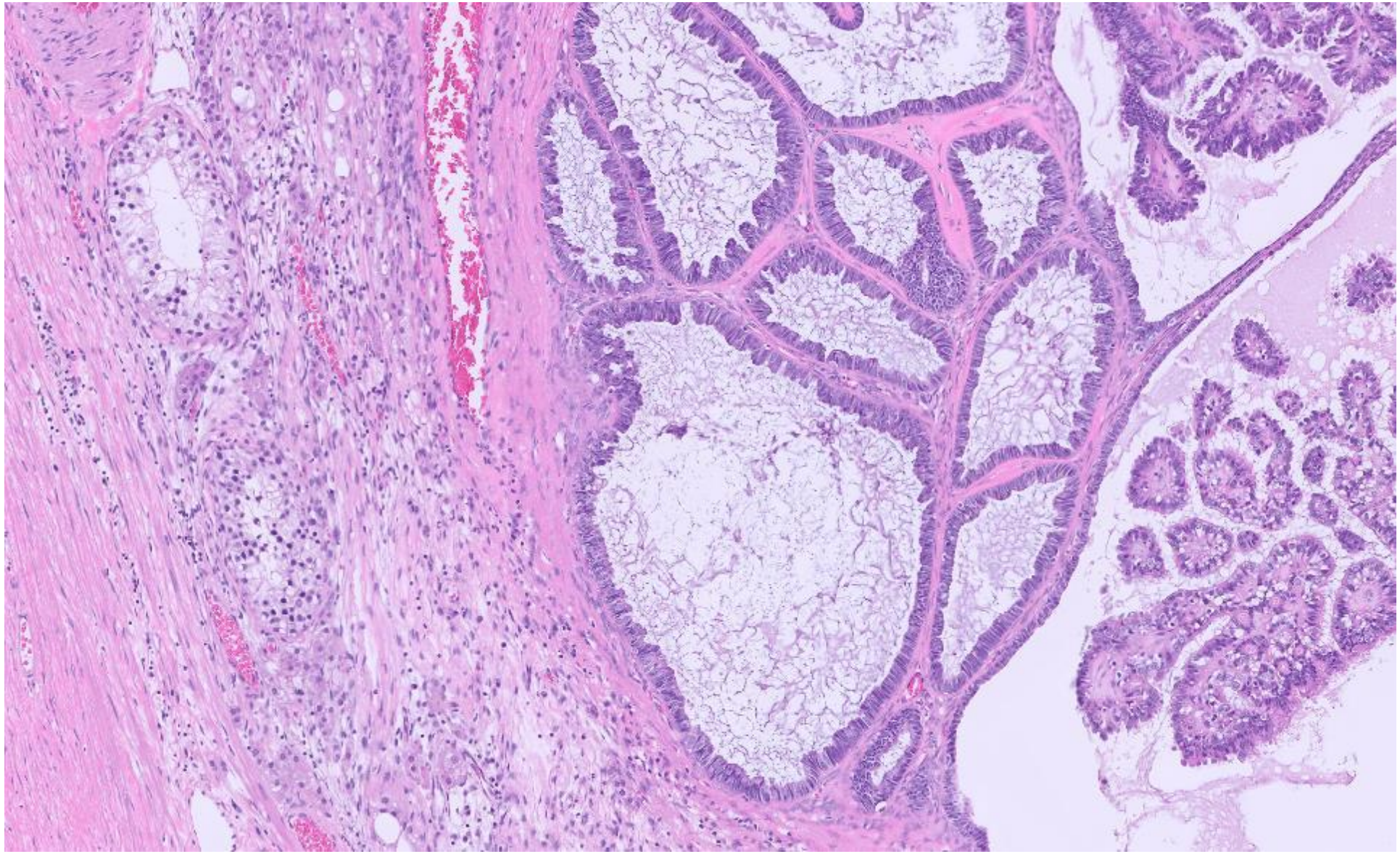

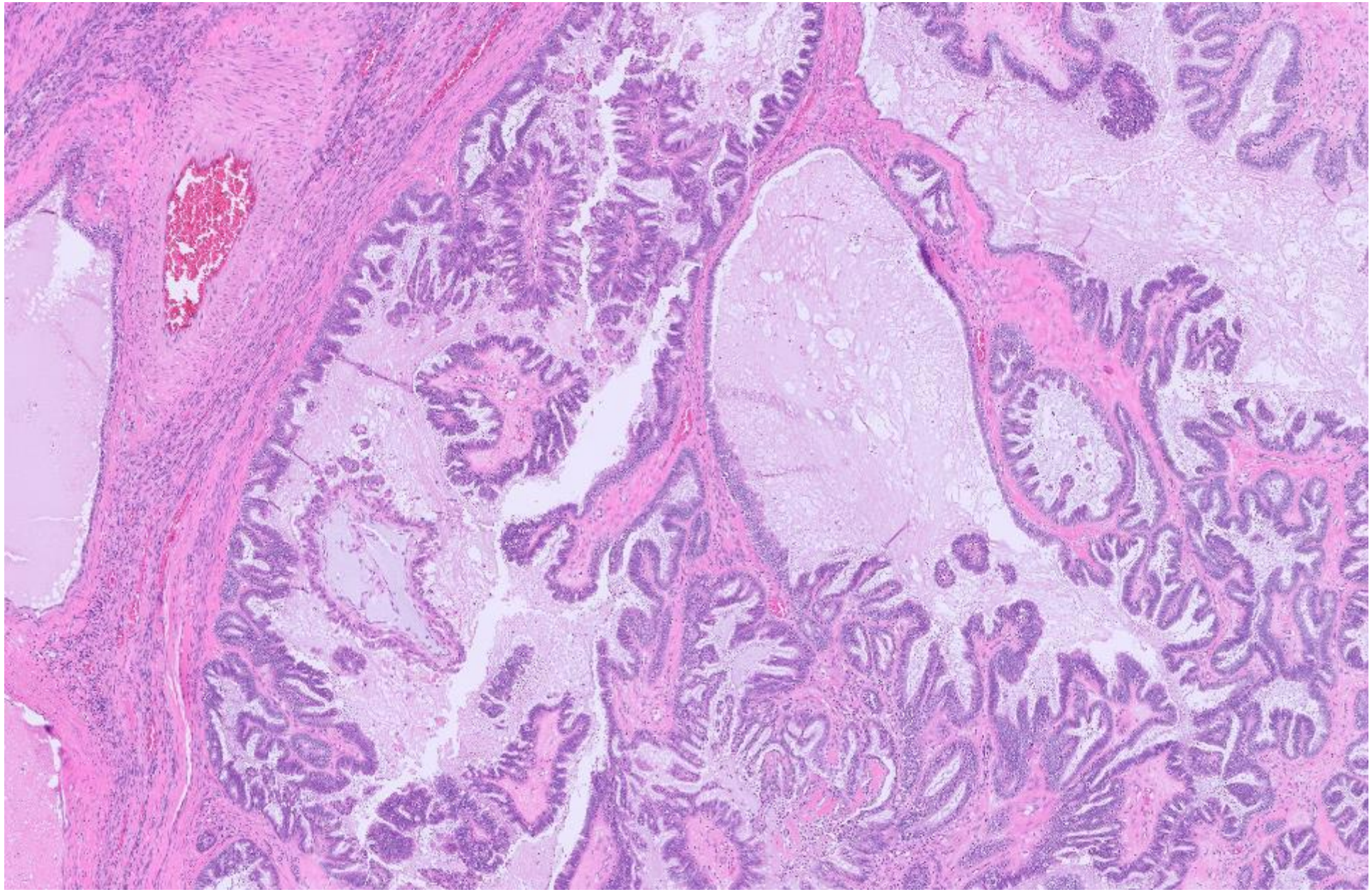

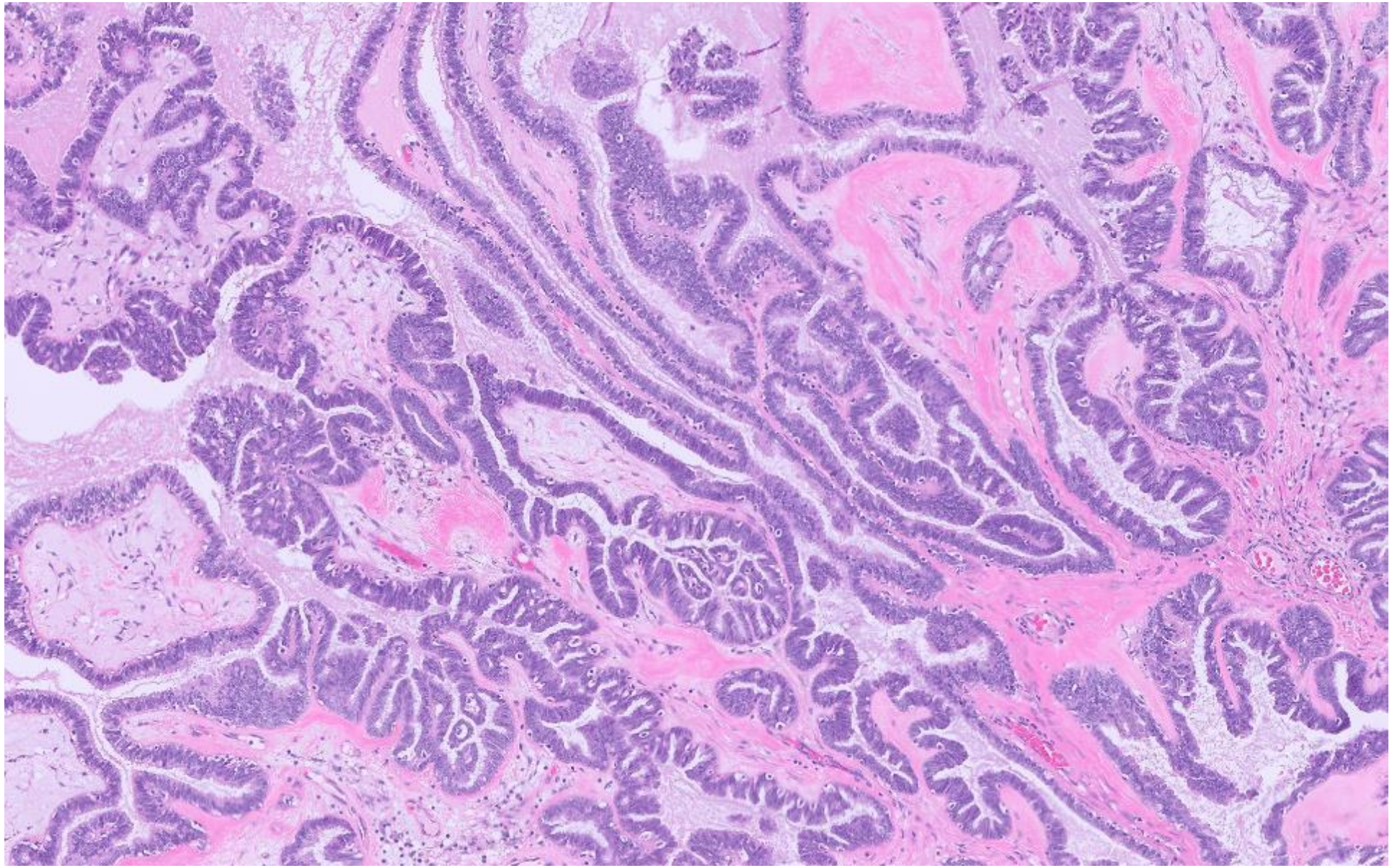

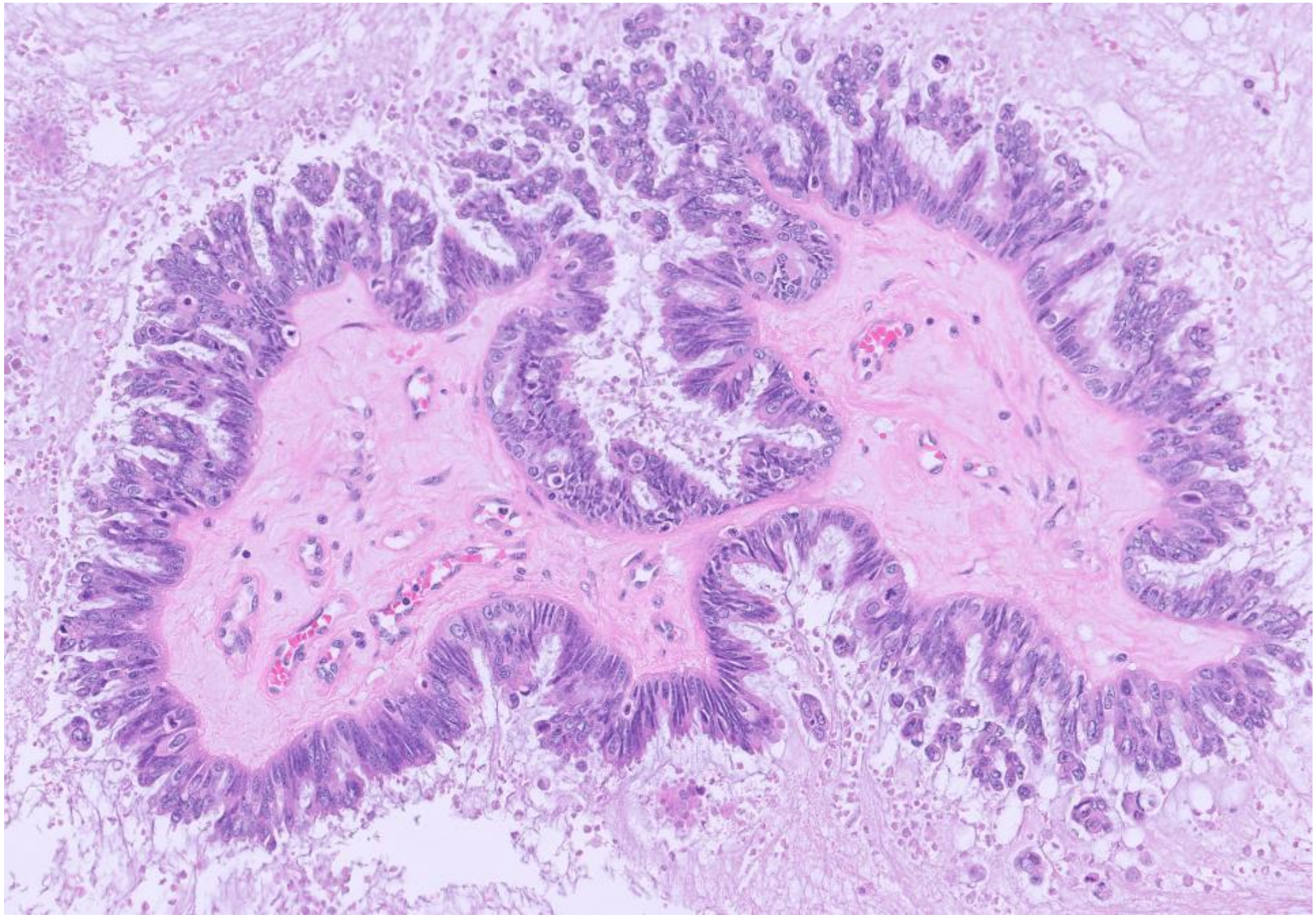

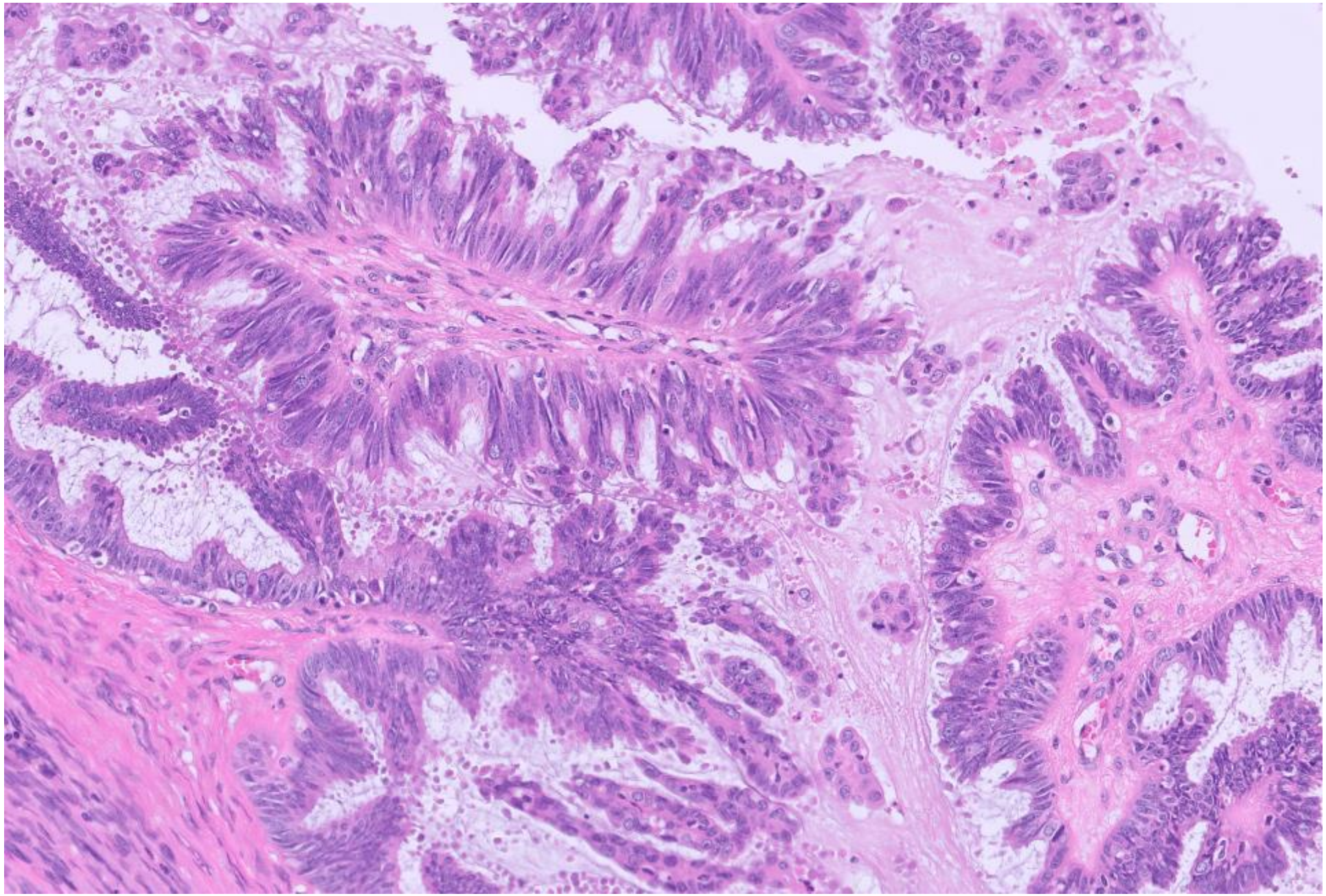

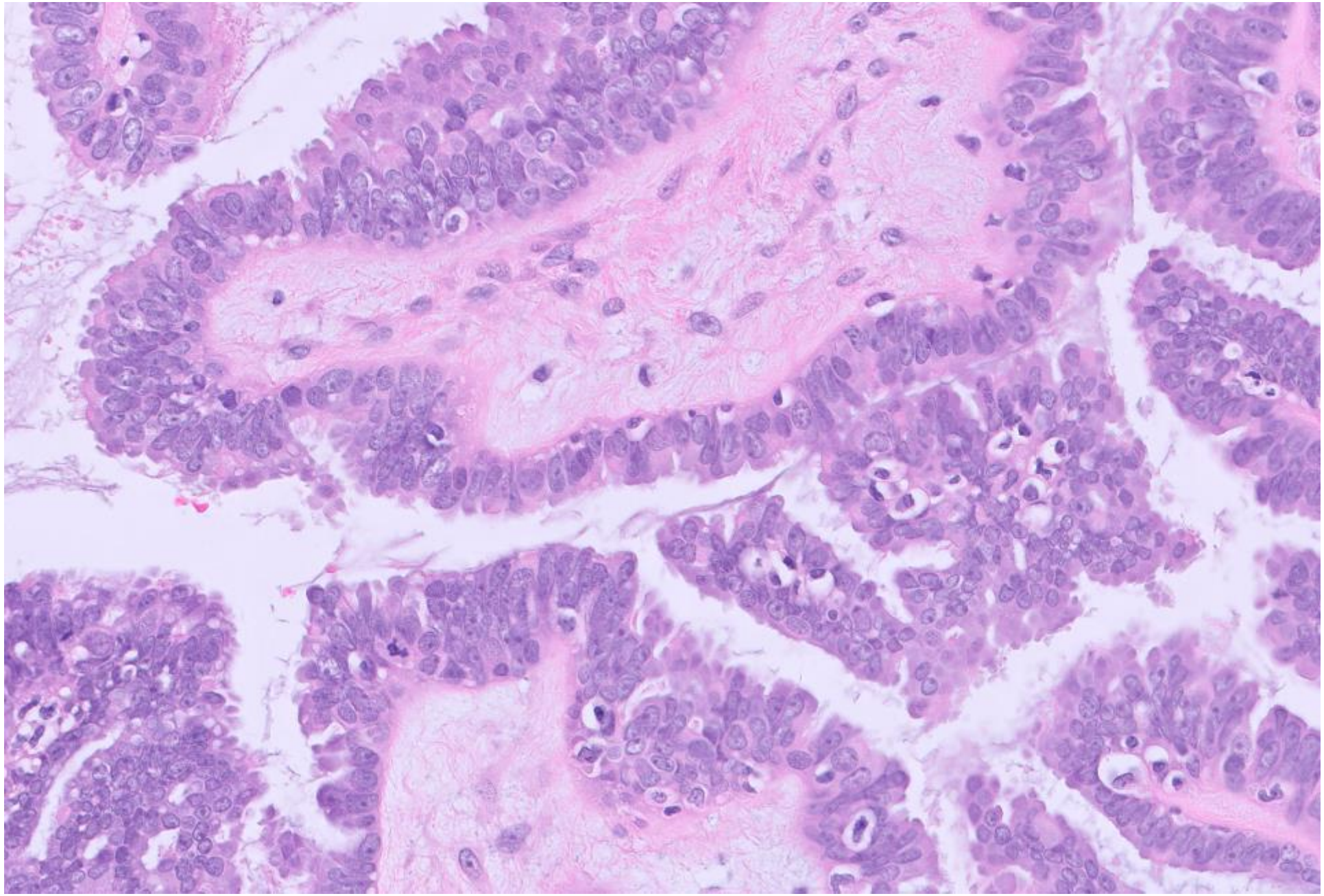

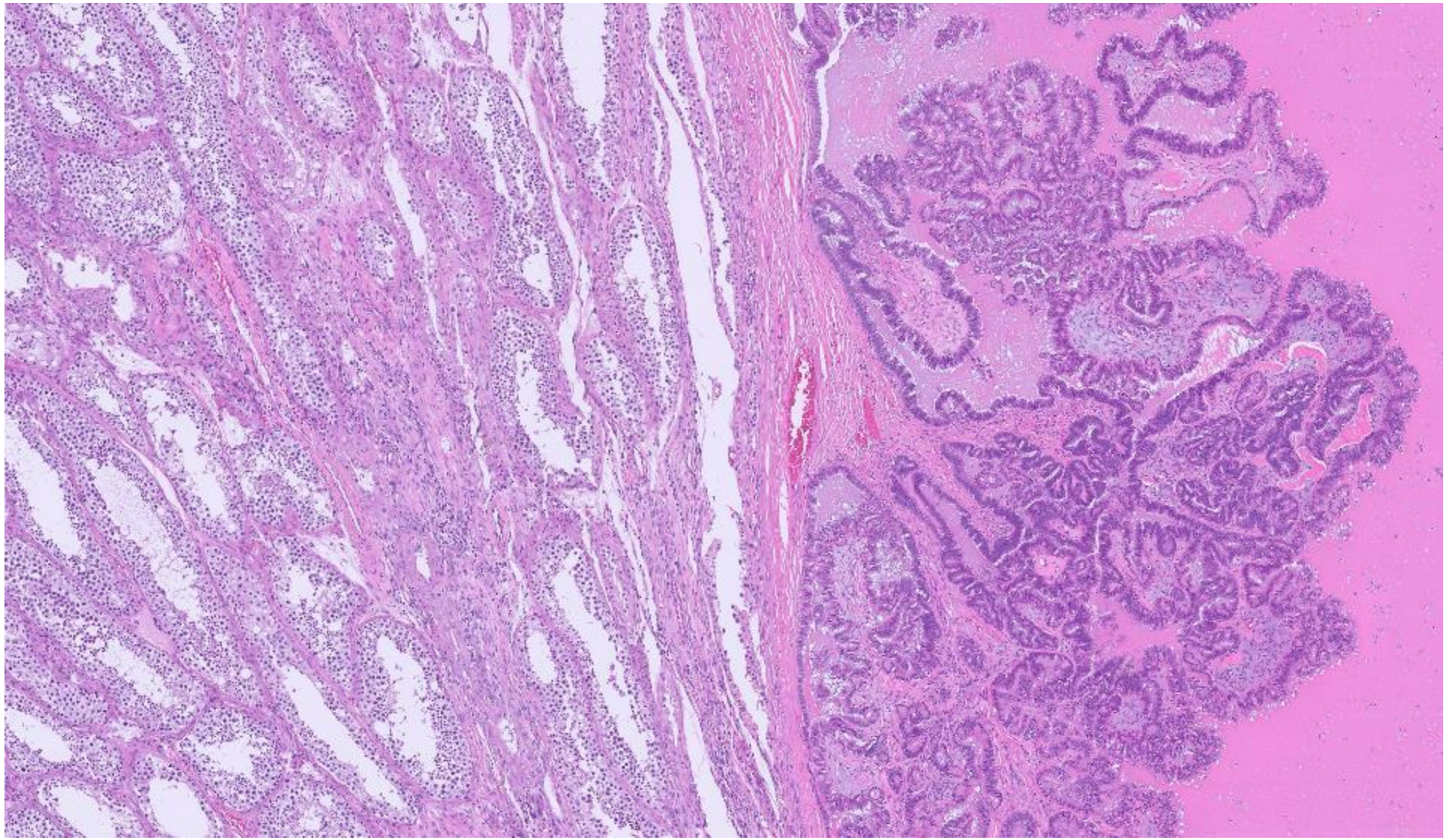

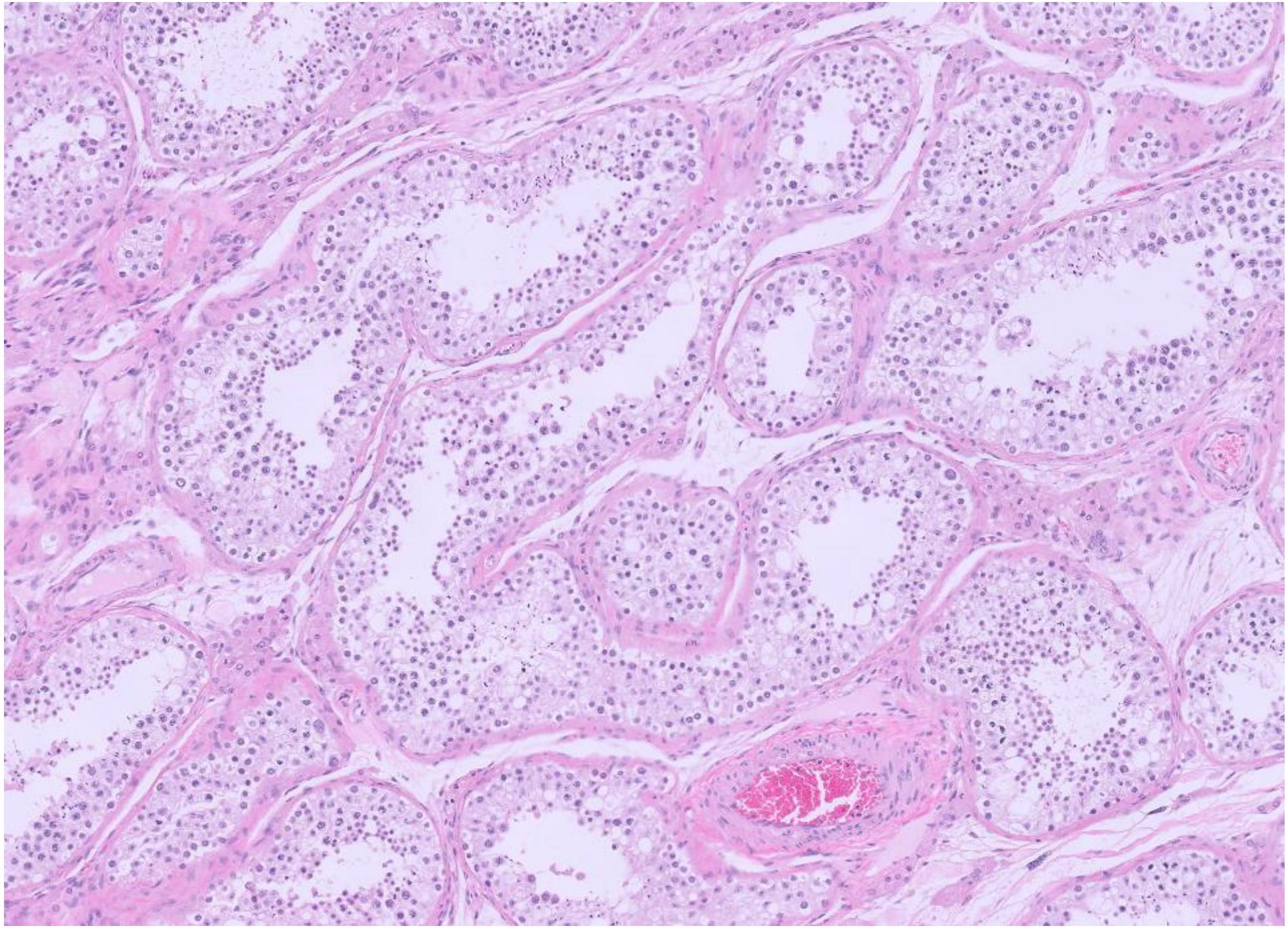

DIAGNOSIS?

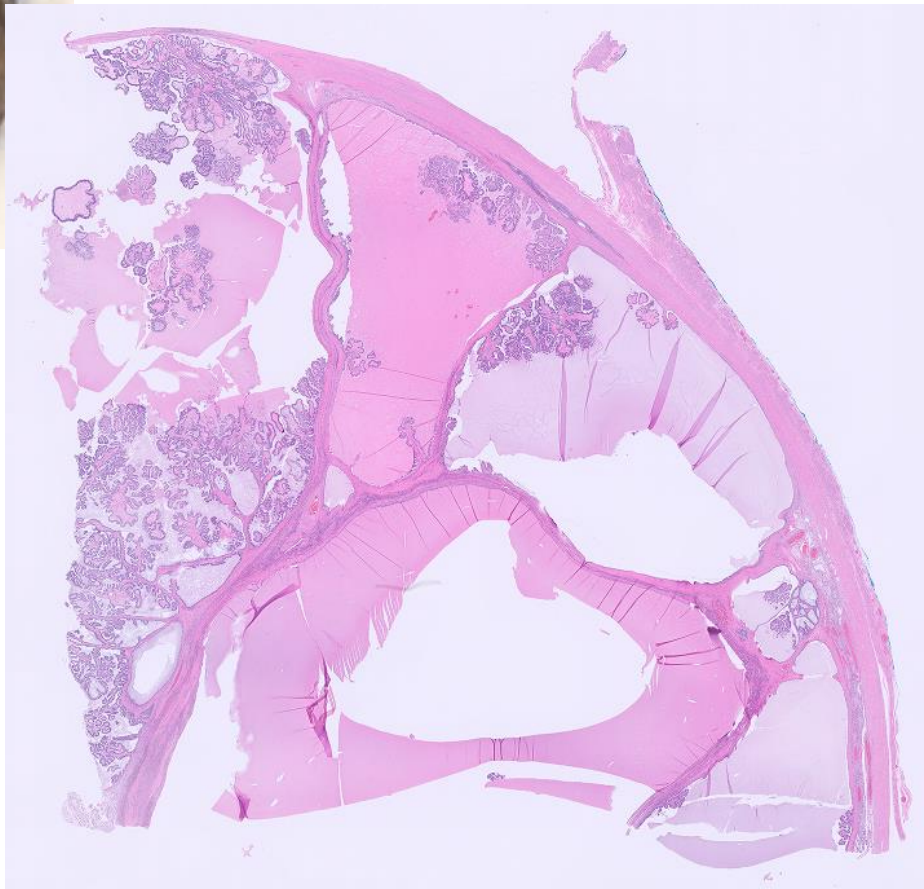

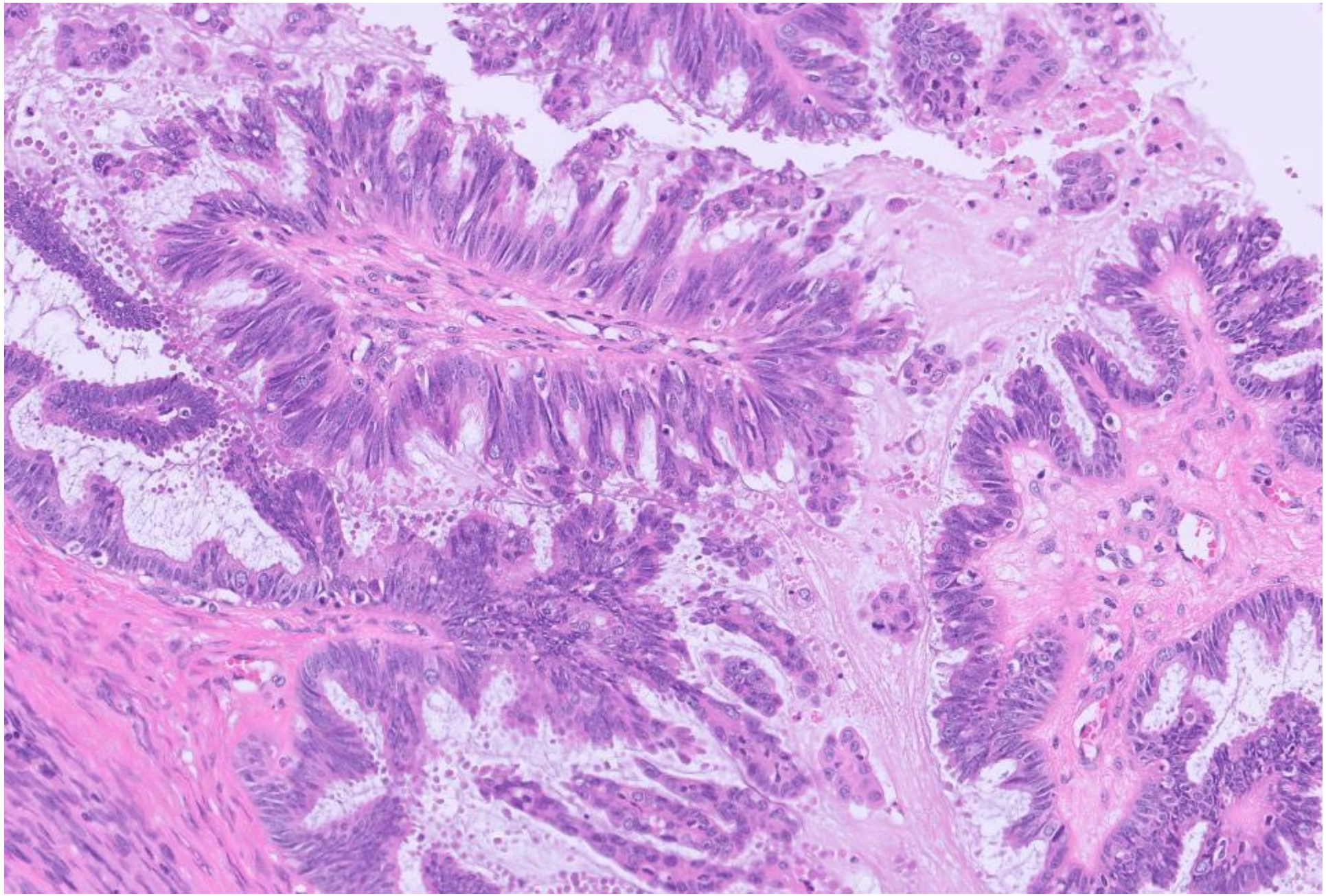

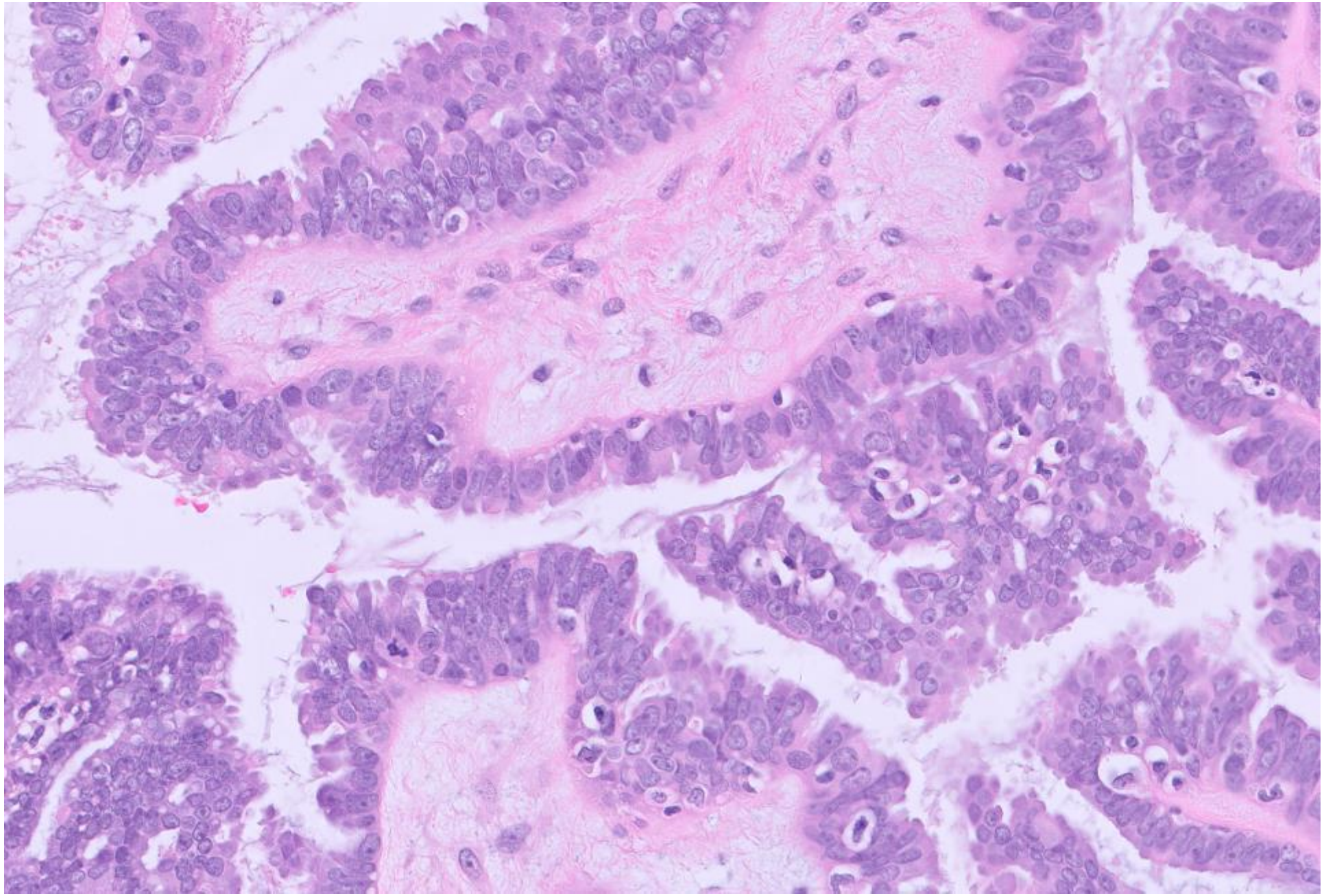

Differential diagnosis – Location!

- **Germ cell tumor** (yolk sac tumor, embryonal carcinoma, teratoma, secondary somatic malignancy)
- **Mesothelial tumor**
- **Rete testis adenocarcinoma**
- **Müllerian type tumor** (serous borderline tumor, high-grade/low-grade serous carcinoma, endometrioid adenocarcinoma, clear cell carcinoma)
- Metastatic adenocarcinoma

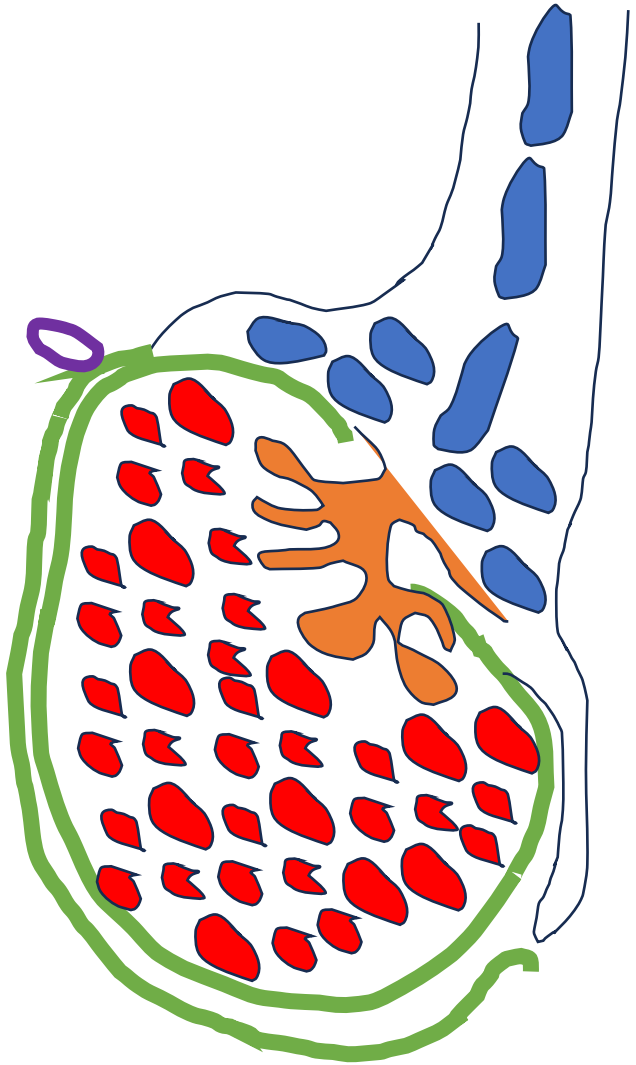

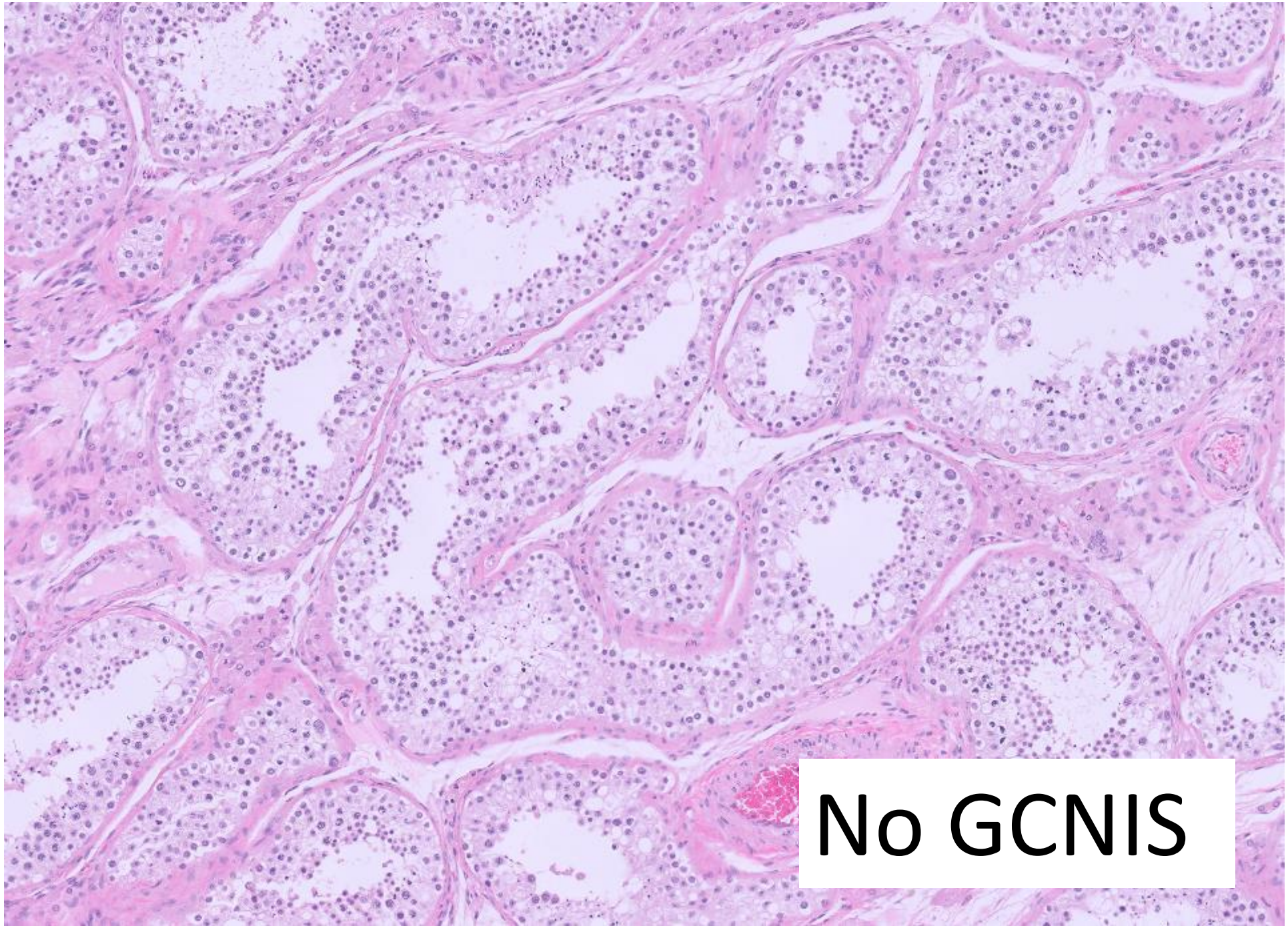
No GCNIS

Confined to testis and far from rete testis and tunica

IPOX

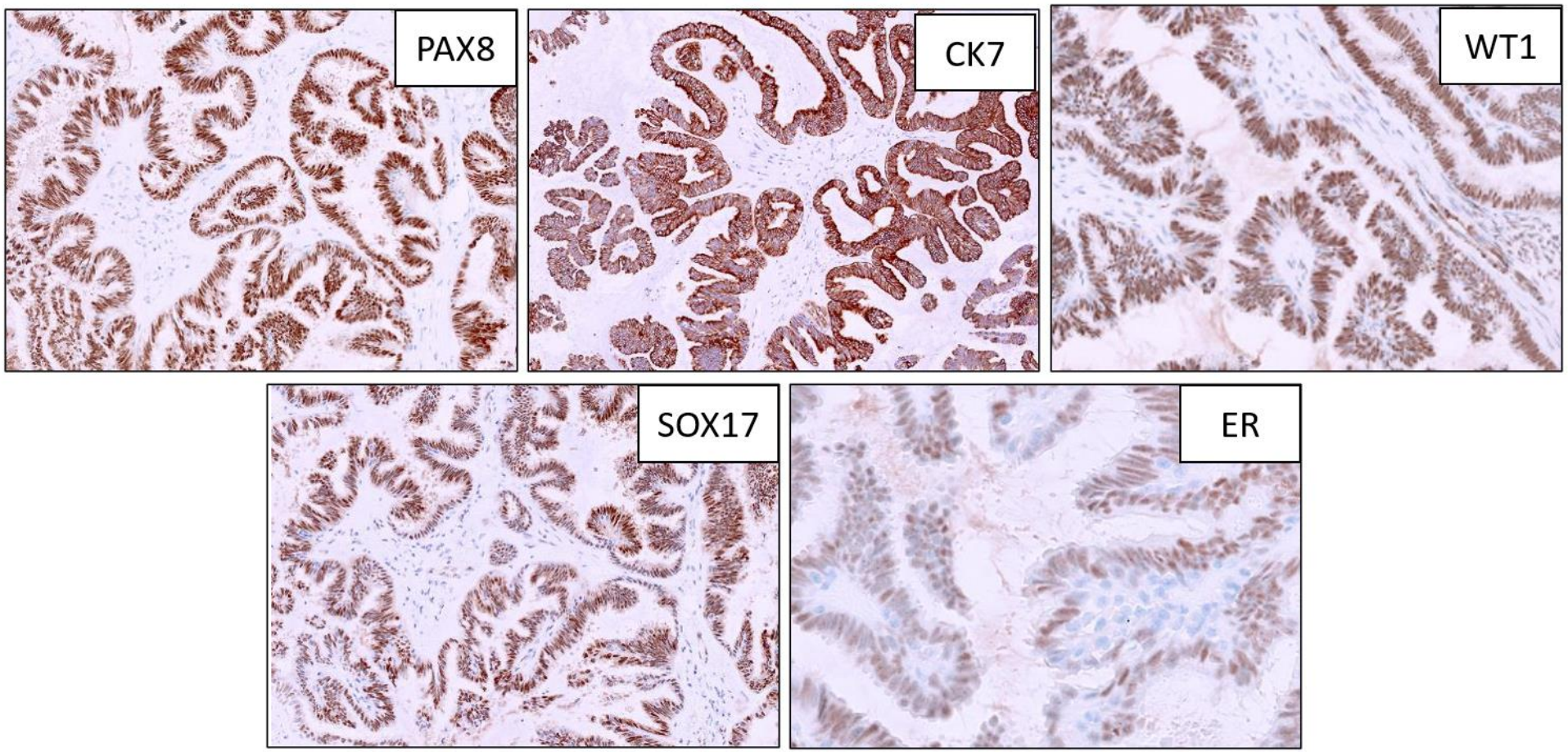

Negative stains: SALL4, OCT4, SOX2, Glypican3, CK20, CDX2, P53, NKX3.1, TTF1

Diagnosis:

Serous borderline tumor

(Müllerian type tumor of the testis)

Serous borderline tumors (SBT) of the testis and paratestis

- Rare
- Identical to ovarian serous borderline tumors
  - Müllerian serous epithelium lining papillae with hierarchical branching pattern
- Indolent behavior when pure
- Subset can develop autoimplants, microinvasion, low-grade serous carcinoma, high-grade serous carcinoma
- Relevant IPOX in morphologic Ddx: PAX8, WT1, ER/PR, D2-40, calretinin, P53

Am J Surg Pathol. 2025 Jun 13. doi: 10.1097/PAS.0000000000002439. Online ahead of print.

Serous Borderline Tumors of the Testis and Paratestis: A Clinicopathologic Study of 19 Tumors Emphasizing Morphologic Spectrum and Clinical Outcome

Ali Shahabi [1], Aleksei Konstantinov [2], Jesse K McKenney [1], Jason Lane [1], Chia-Sui Kao [1], Sean R Williamson [1], Reza Alaghehbandan [1], Liang Cheng [3], Ankur R Sangoi [4], Emily Chan [4], Kristine M Cornejo [5], Christopher G Przybycin [1]

Affiliations + expand

PMID: 40511957 DOI: 10.1097/PAS.0000000000002439

Am J Surg Pathol. 2025 Jun 13. doi: 10.1097/PAS.0000000000002439. Online ahead of print.

Serous Borderline Tumors of the Testis and Paratestis: A Clinicopathologic Study of 19 Tumors Emphasizing Morphologic Spectrum and Clinical Outcome

Ali Shahabi [1], Aleksei Konstantinov [2], Jesse K McKenney [1], Jason Lane [1], Chia-Sui Kao [1], Sean R Williamson [1], Reza Alaghehbandan [1], Liang Cheng [3], Ankur R Sangoi [4], Emily Chan [4], Kristine M Cornejo [5], Christopher G Przybycin [1]

Affiliations + expand

PMID: 40511957 DOI: 10.1097/PAS.0000000000002439

9 patients with pure SBT had no adverse outcomes

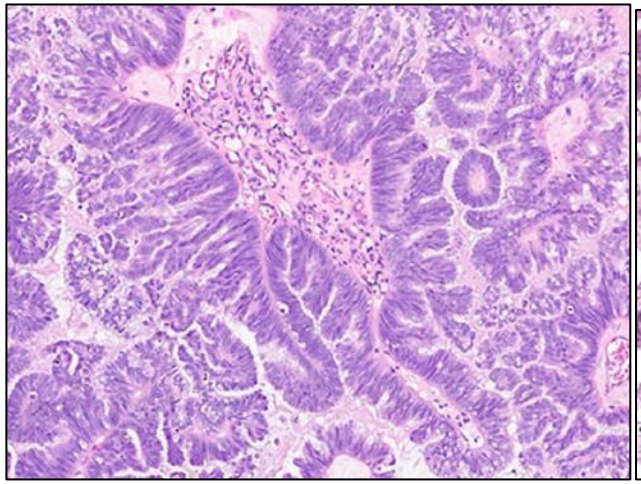

Micropapillary (6/19)

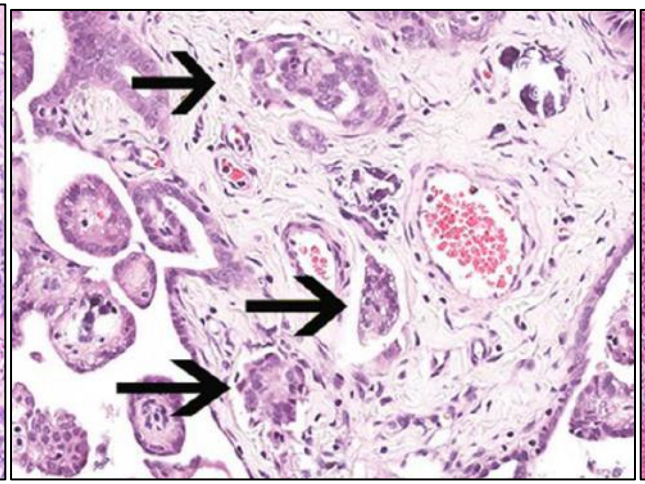

Microinvasion (4/19)

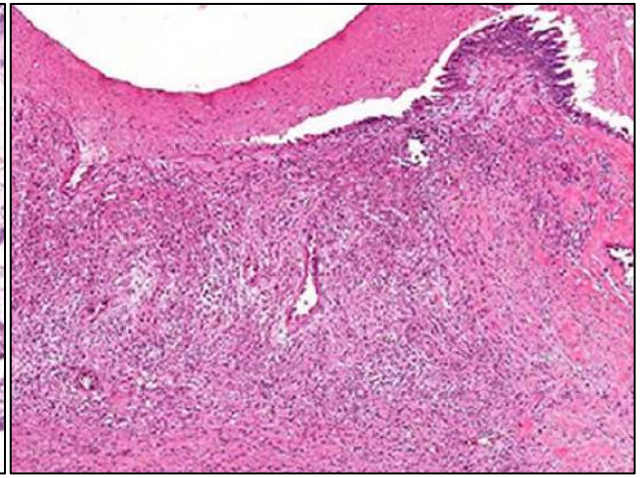

Autoimplants (5/19)

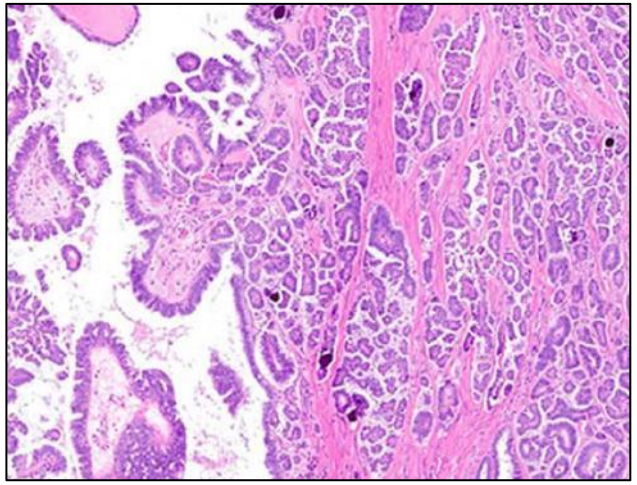

Low grade serous carcinoma (1/19)

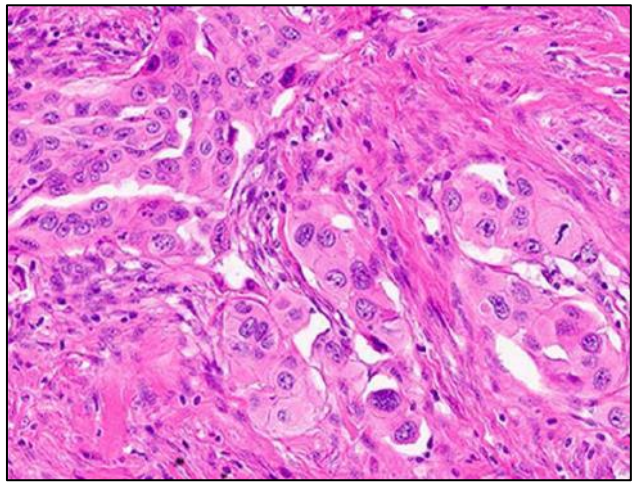

High grade serous carcinoma (1/19)

SBT presumed site of origin in testis: testicular appendage (appendix testis)

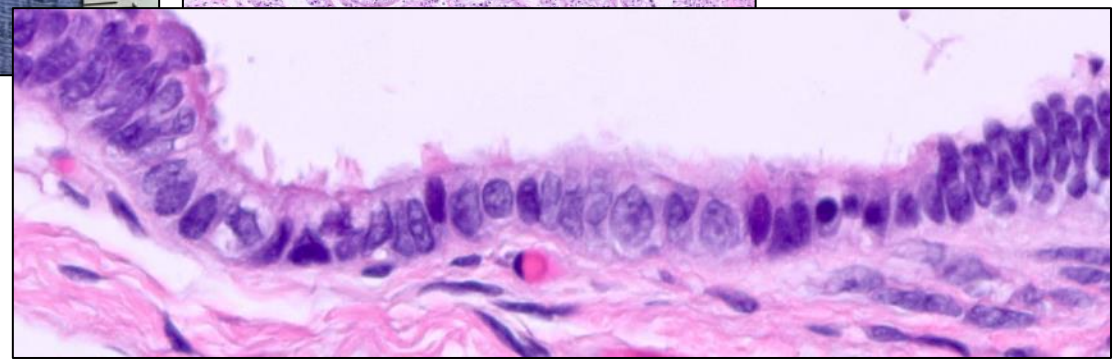

- Remnant of Müllerian duct
- Resembles fallopian tube epithelium with ciliated cells and secretory cells
- Can give rise to GYN type tumors in male testis

Images courtesy of Dr. A. Sangoi

Appl Immunohistochem Mol Morphol. 2016 Aug;24(7):e50-68. doi: 10.1097/PAI.0000000000000326.

Comprehensive Immunophenotypic Characterization of Adult and Fetal Testes, the Excretory Duct System, and Testicular and Epididymal Appendages

Martin J Magers [1], Aaron M Udager, Arul M Chinnaiyan, Diana French, Jeffrey L Myers, Jeffrey M Jentzen, Jonathan B McHugh, Amer Heider, Rohit Mehra

Affiliations + expand

PMID: 26867215 DOI: 10.1097/PAI.0000000000000326

	PAX8	WT1	CK7	CK20	CALR	AR	ER	PR
Rete testis	7/7	6/7	7/7	3/7	7/7	7/7	2/7	0/7
Testicular appendage	9/9	9/9	9/9	1/9	0/9	9/9	8/9	9/9
Tunica	0/7	7/7	6/7	0/7	7/7	0/7	0/7	0/7

Take home messages: serous borderline tumors of the testis and paratestis

- SBT are identical to ovarian serous borderline tumors
- Although rare, any GYN epithelial tumor can arise in the testis from Müllerian duct remnants (appendix testis), evaluate as you would a gyn tumor
- May have overlapping immuno features with rete testis adenocarcinoma and mesothelial tumors – use morphology, location and appropriate IPOX

25-1004

Eric Ollila; Stanford

77 yo F with a nasal cavity mass biopsy involving the nasal septum and cribriform plate

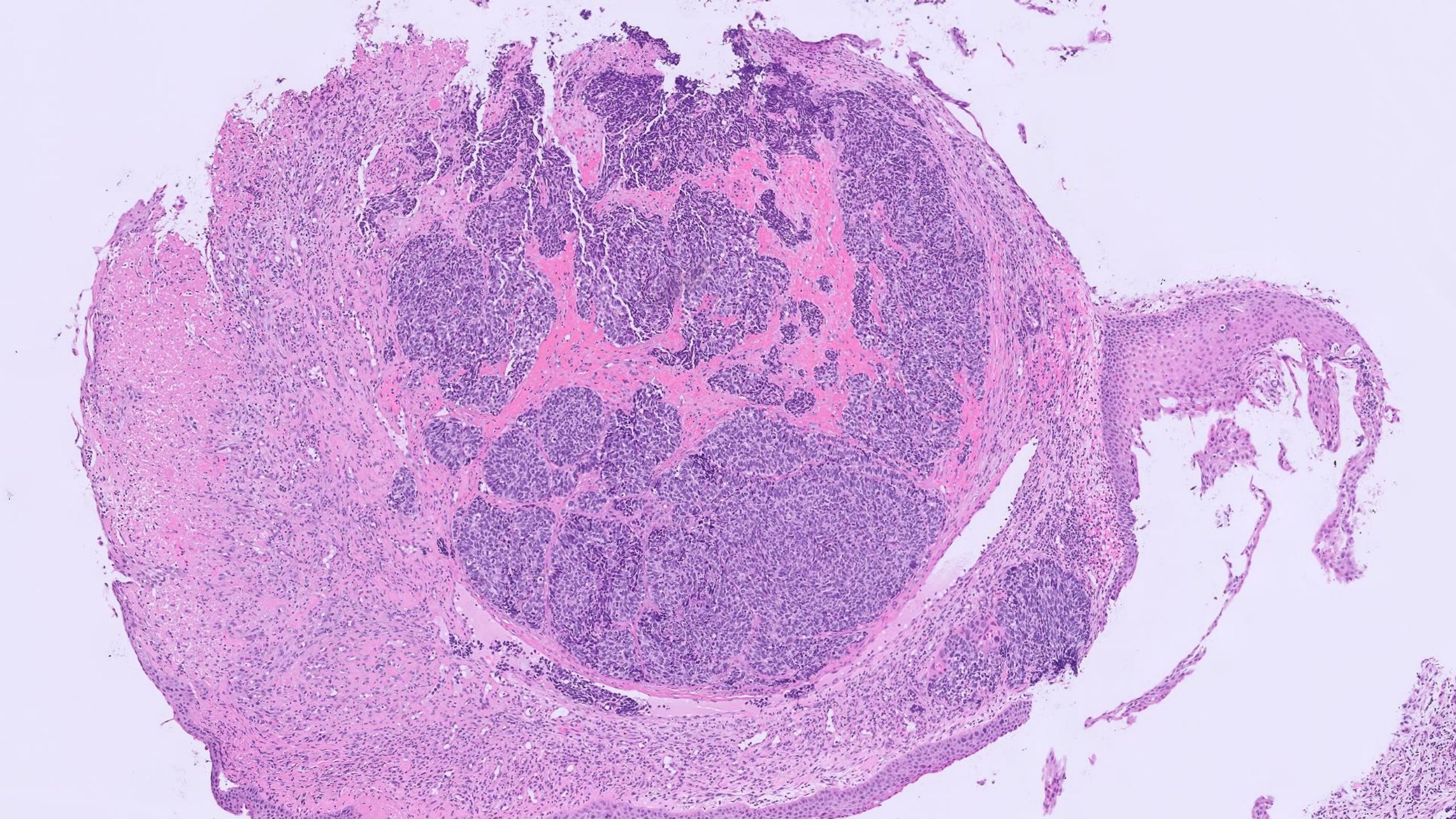

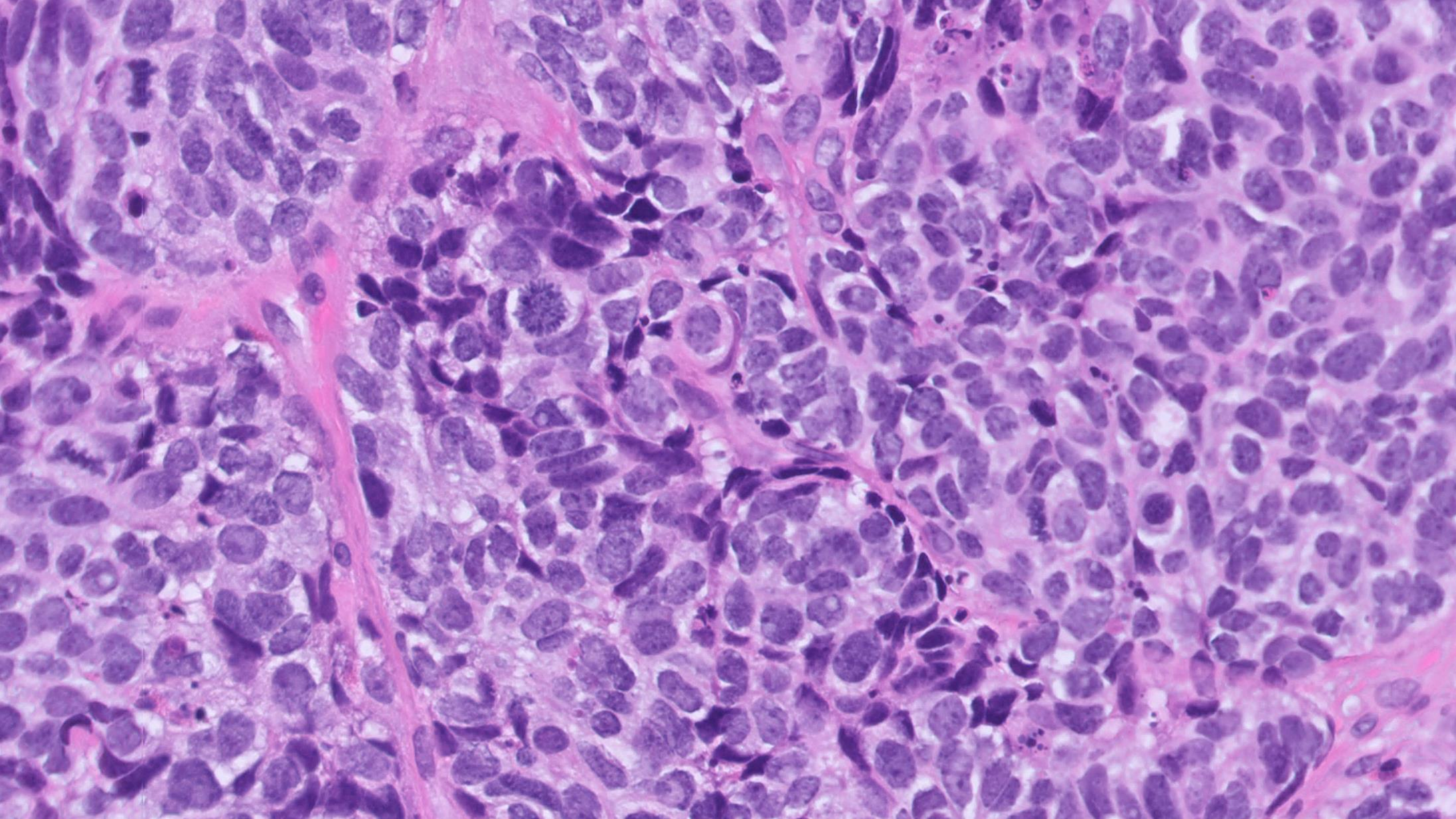

DIAGNOSIS?

Differential

- Squamous cell carcinoma
- Sinonasal undifferentiated carcinoma
  - Diagnosis of exclusion
  - Highly aggressive
- Olfactory neuroblastoma
  - Small round cells with neuropil, but may be high grade
  - Neuroendocrine (+) with S100 (+) sustentacular cells
  - Prognosis - Hyams grade
- Neuroendocrine carcinoma
  - Small cell
    - Nests/trabeculae, palisading, rosettes, necrosis
    - Stippled chromatin, inconspicuous nucleoli, frequent nuclear molding
    - >10 mitoses/2 mm
  - Large cell
    - Abundant eosinophilic cytoplasm, vesicular chromatin, course to speckled chromatin, and prominent nucleoli
    - Unclear prognosis

Differential

- SWI/SNF complex-deficient sinonasal carcinoma
  - Poorly differentiated to undifferentiated
  - Loss of SMARCB1 (INI1) or SMARCA4 (BRG)
  - Basaloid, plasmacytoid/rhabdoid, gland, yolk sac, undifferentiated resembling SNUC
  - No overt squamous cells
  - Focal/weak neuroendocrine (+)
  - HPV (-)
  - >50% die within 2 years

- HPV-related multiphenotypic sinonasal carcinoma
  - Basaloid with surface-derived and minor salivary gland–derived elements
  - Ductal and myoepithelial differentiation
  - Cribriform morphology
    - MYB IHC/ISH usually positive, but lacks *MYB* rearrangements
  - 1/3rd recur; regional spread rare

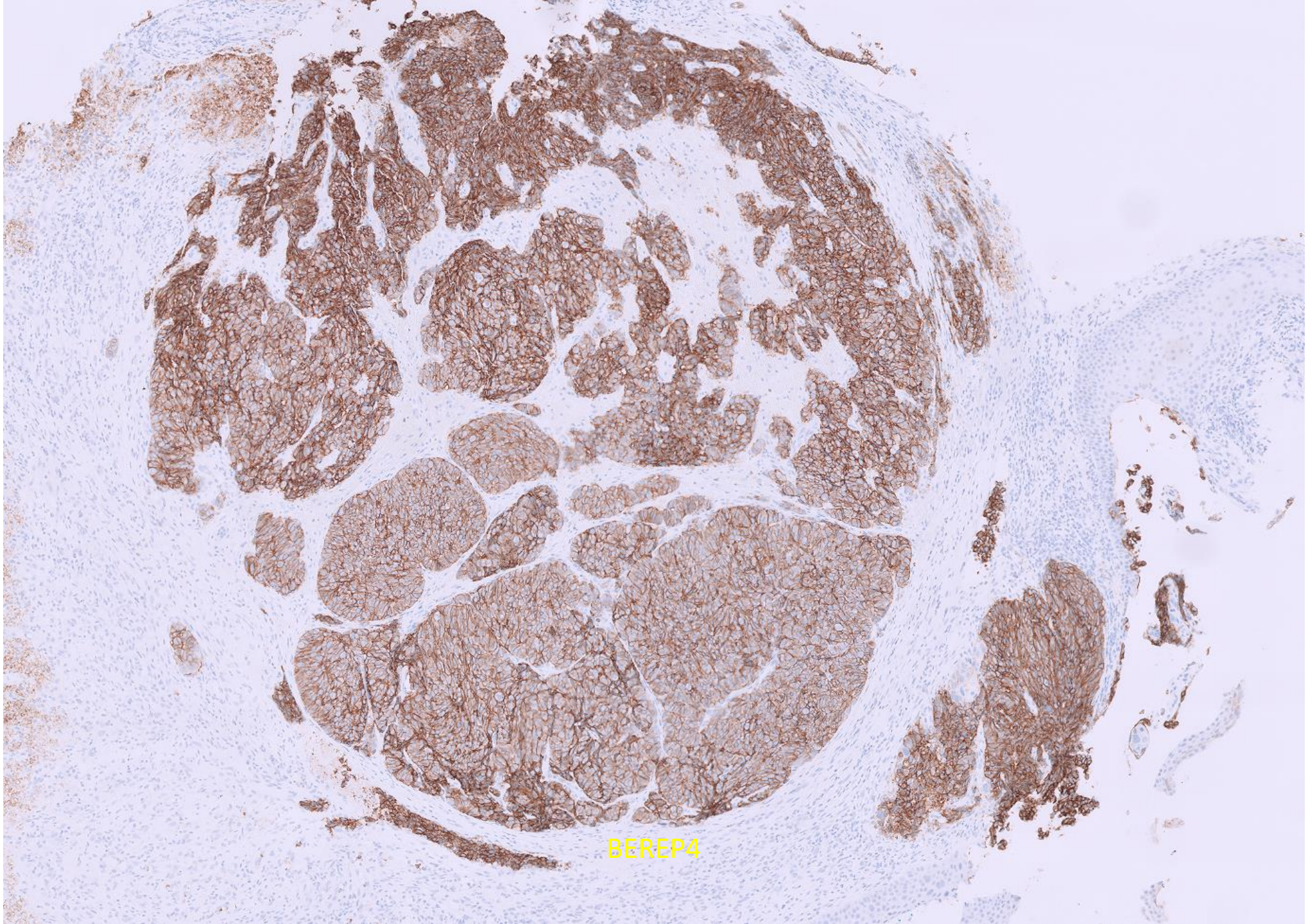
BEREP4

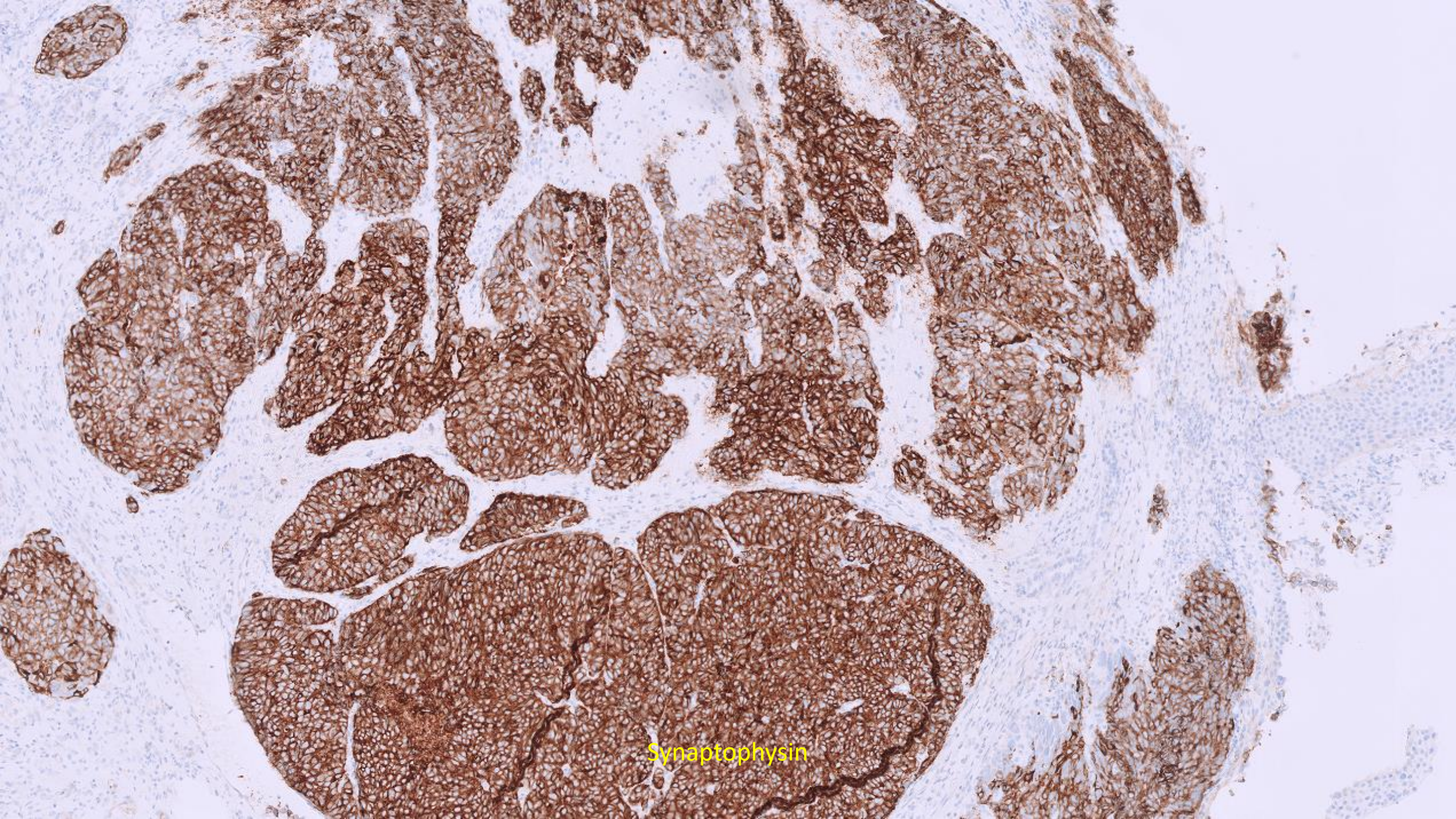
Synaptophysin

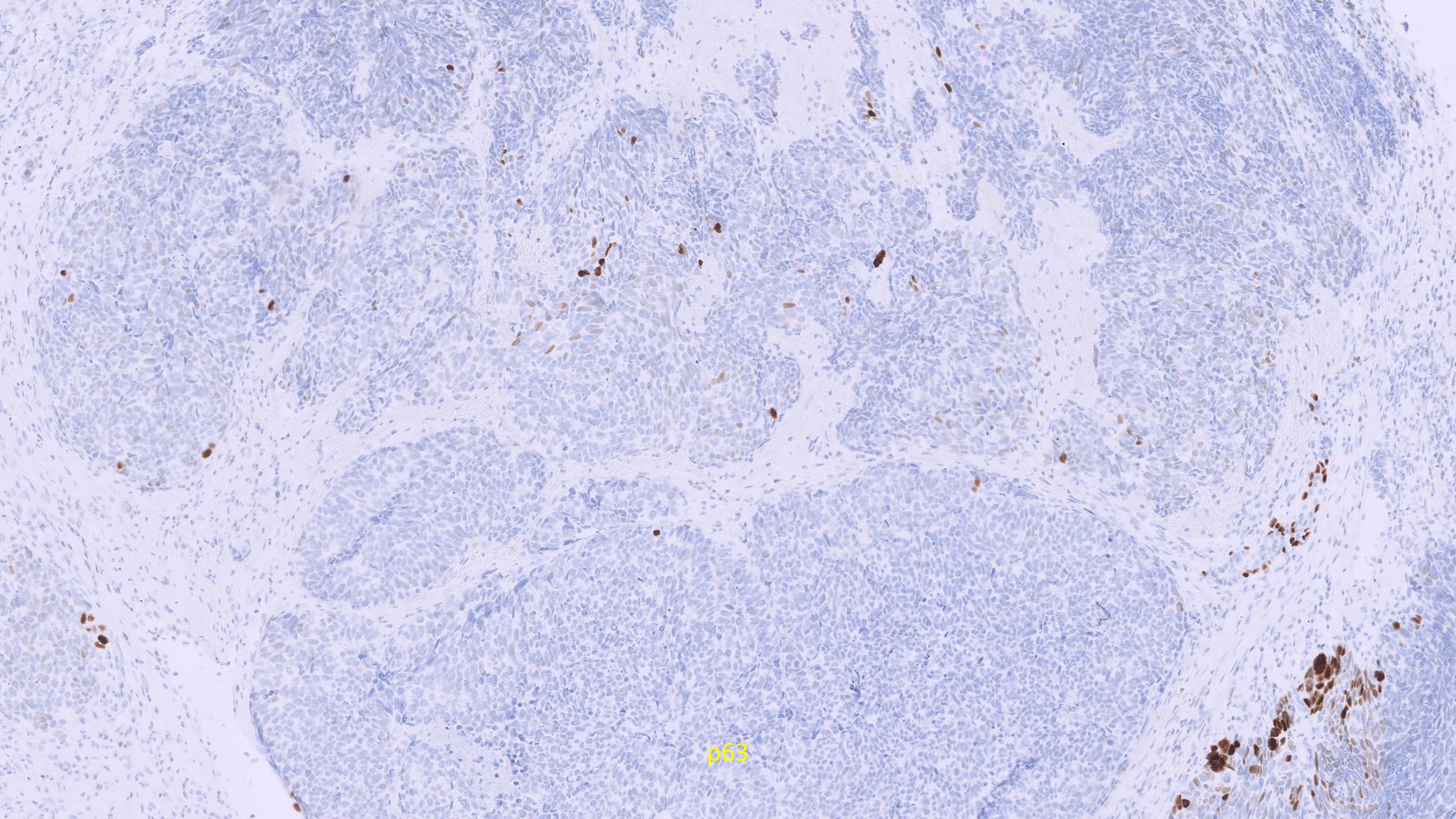
p63

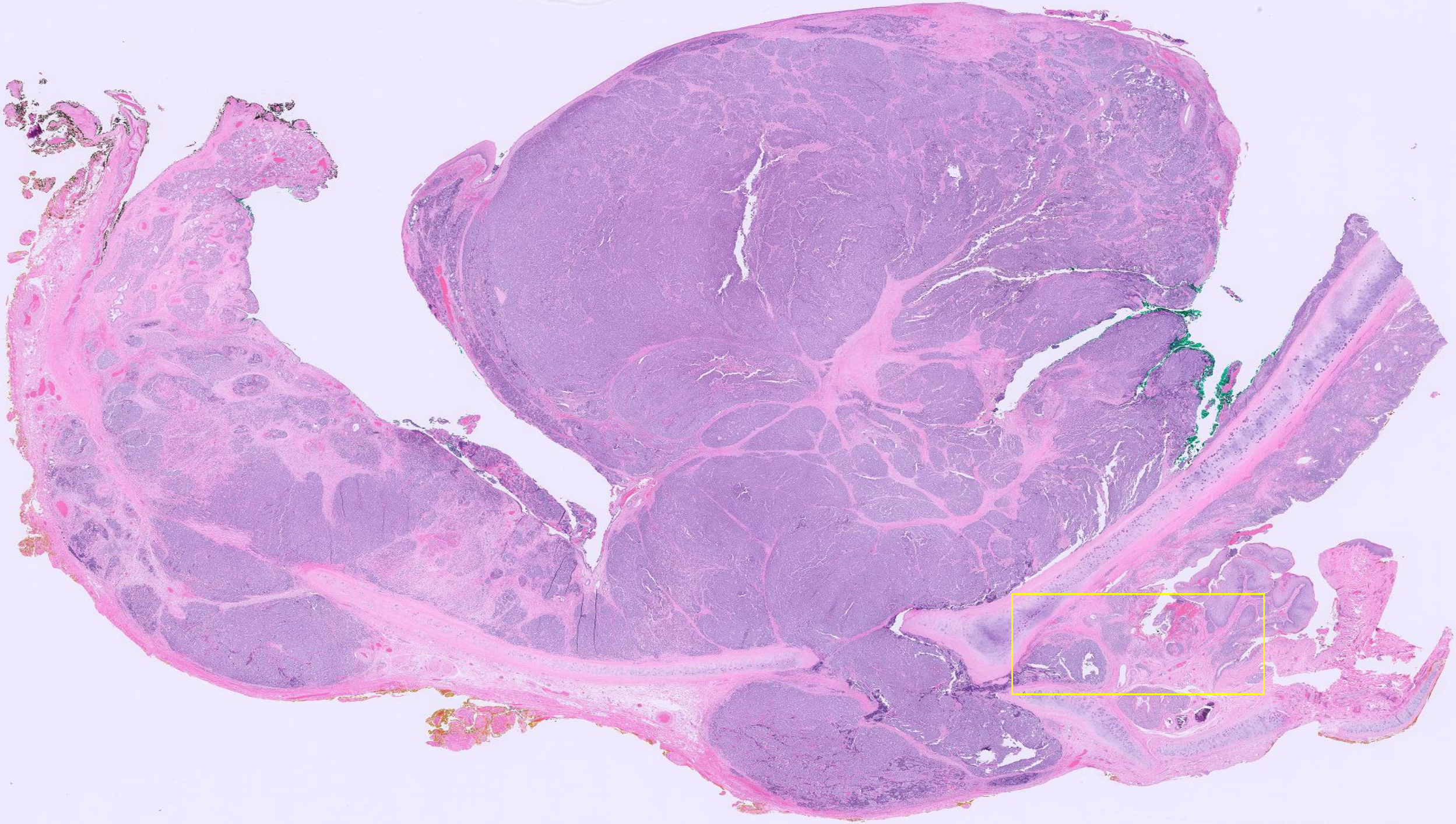

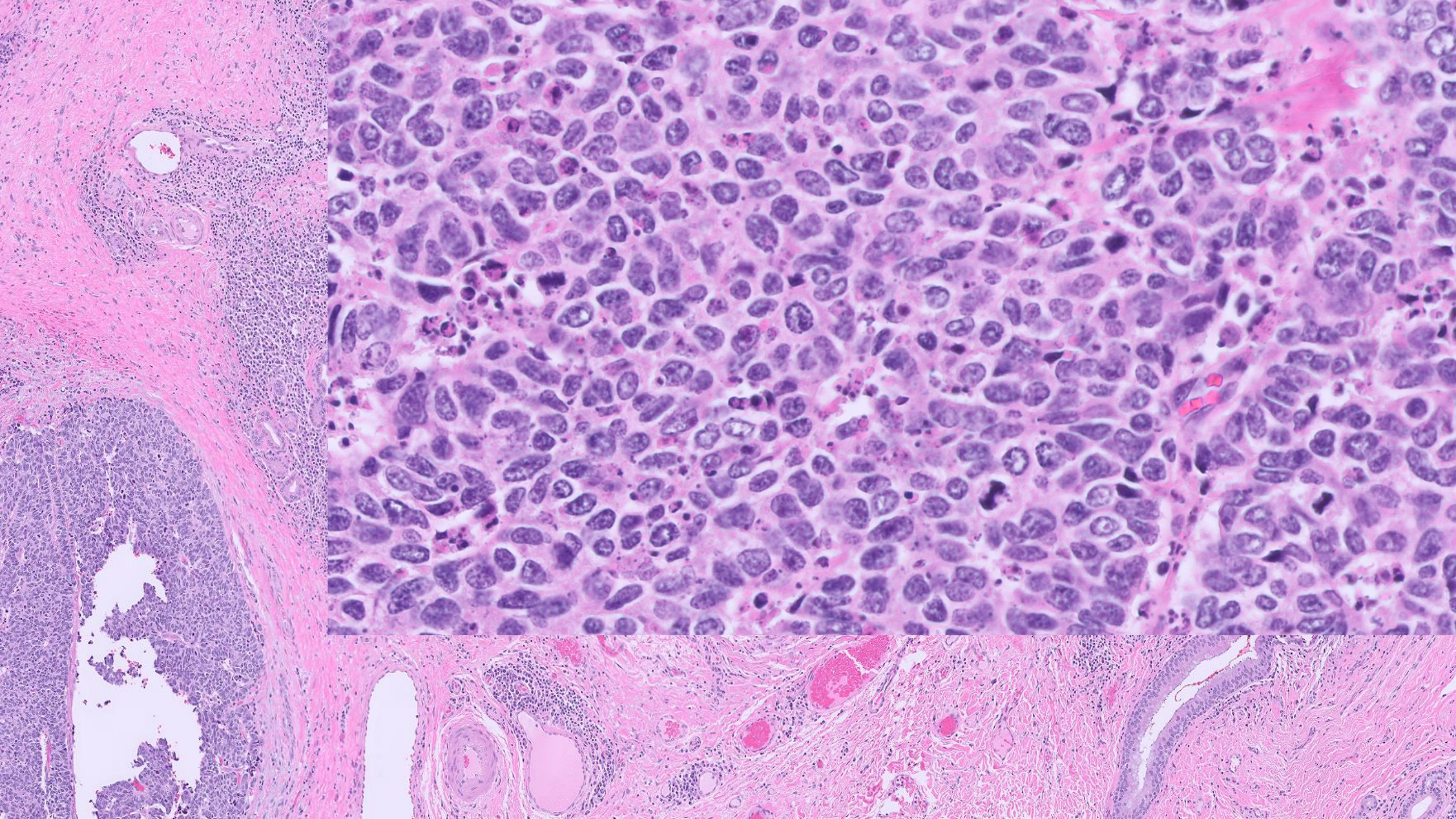

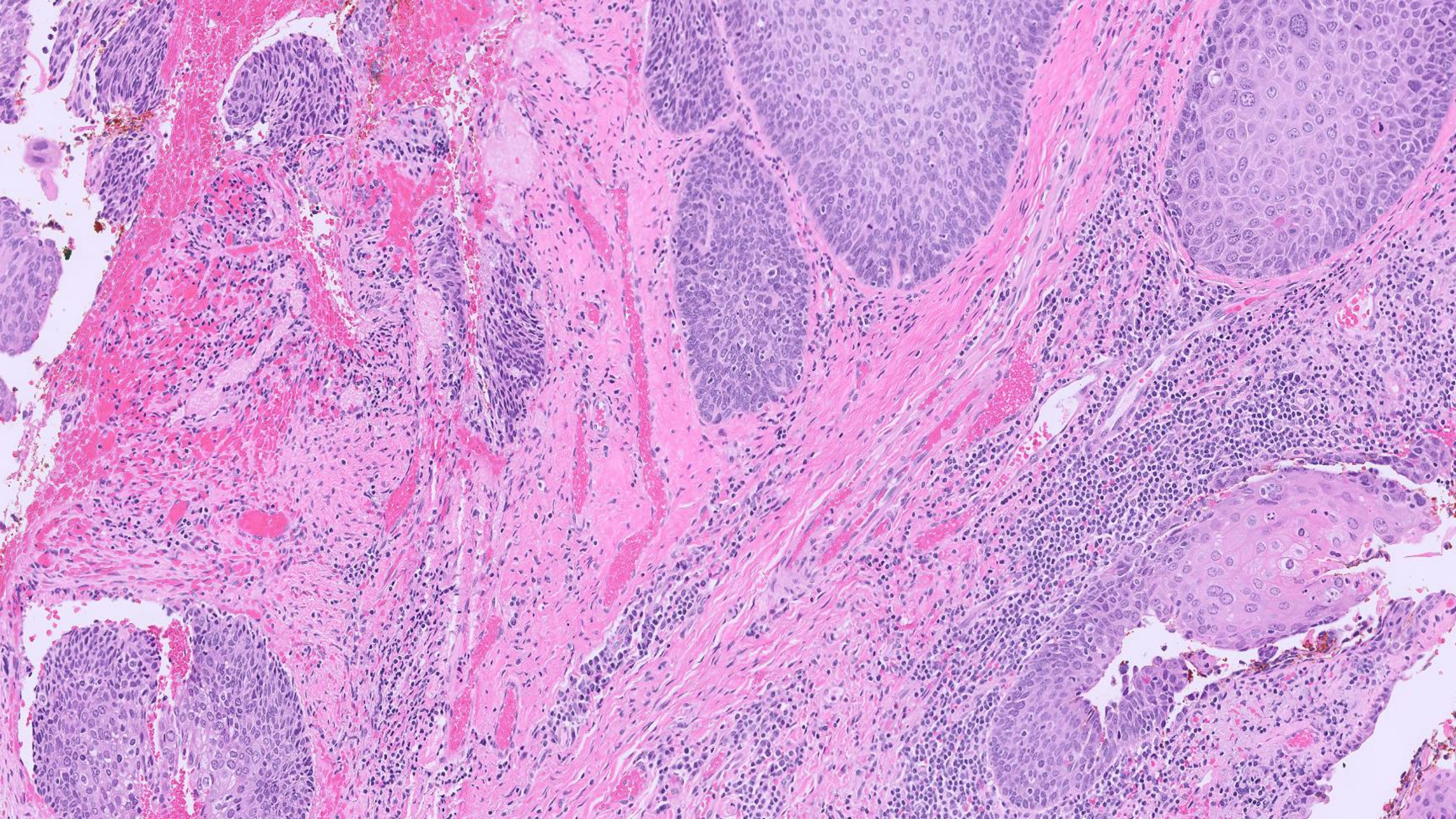

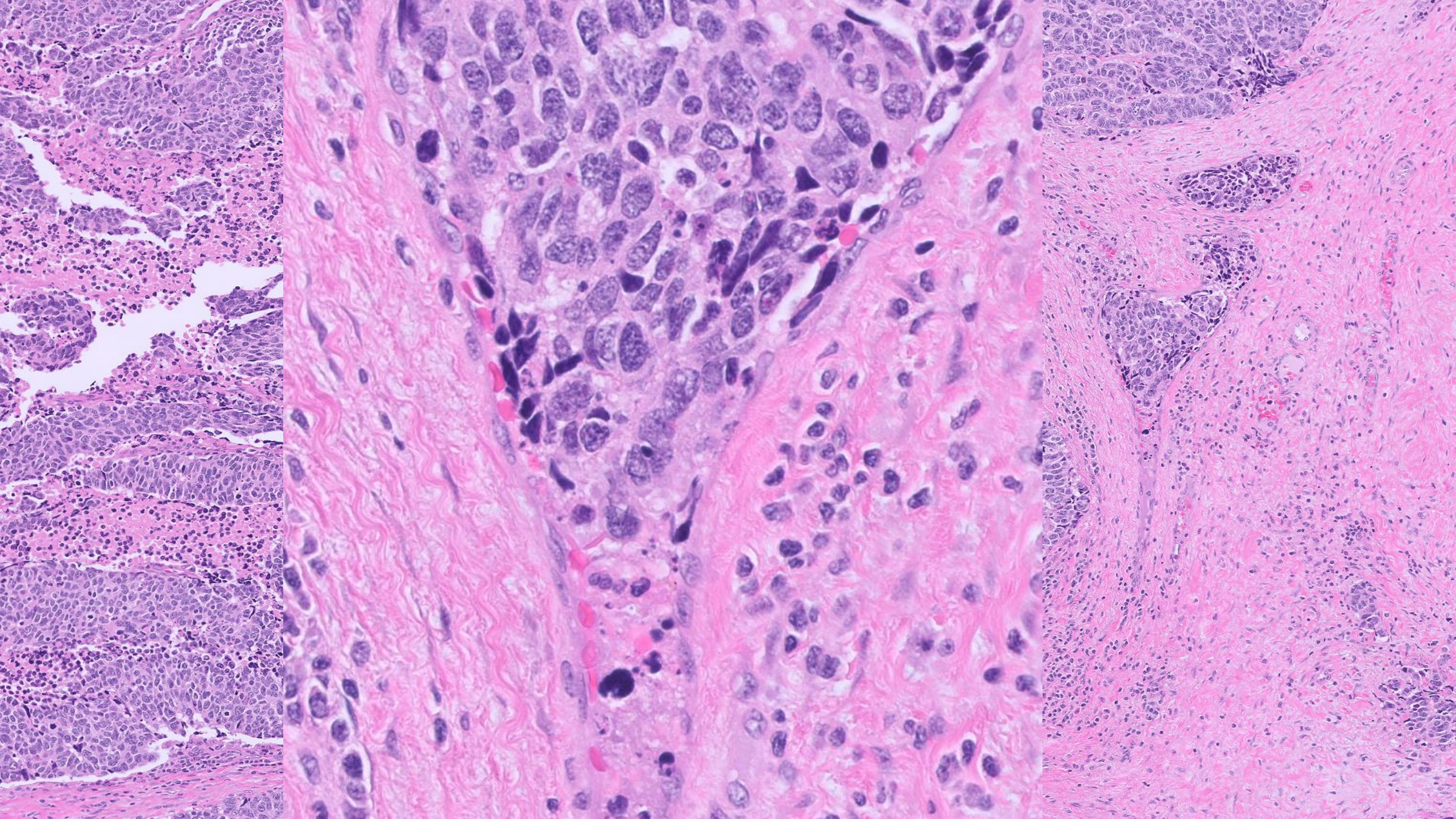

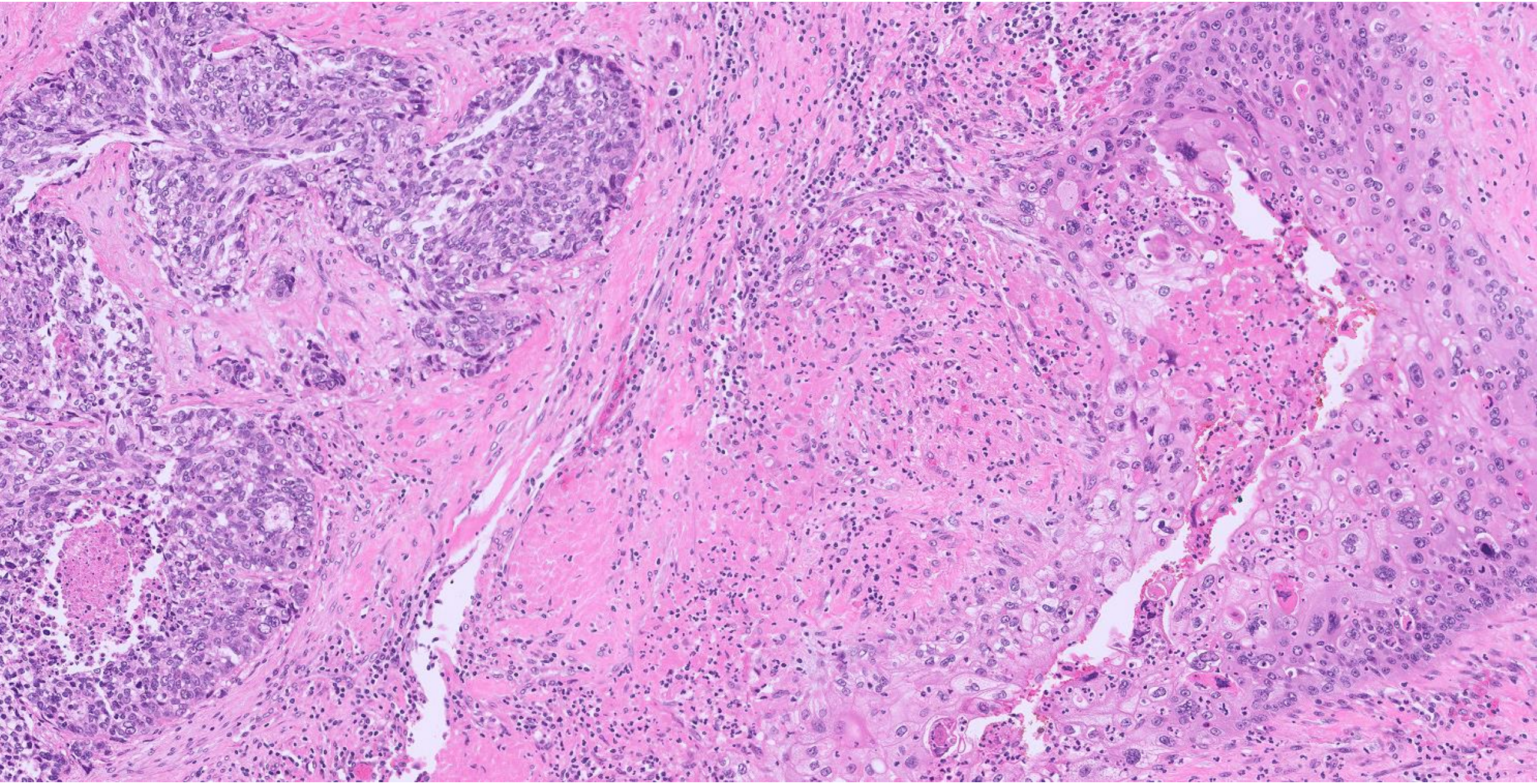

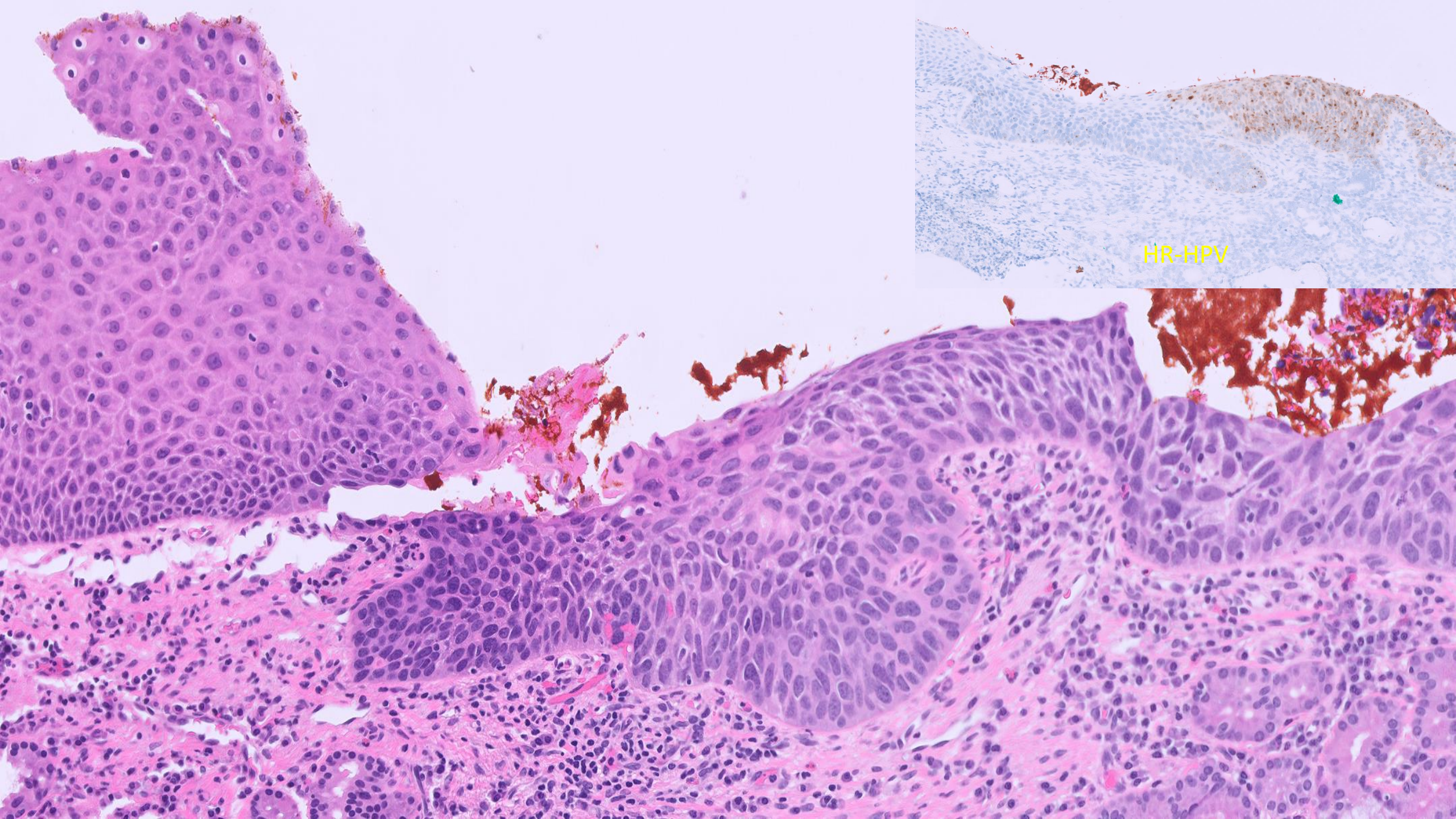
HR-HPV

HR-HPV

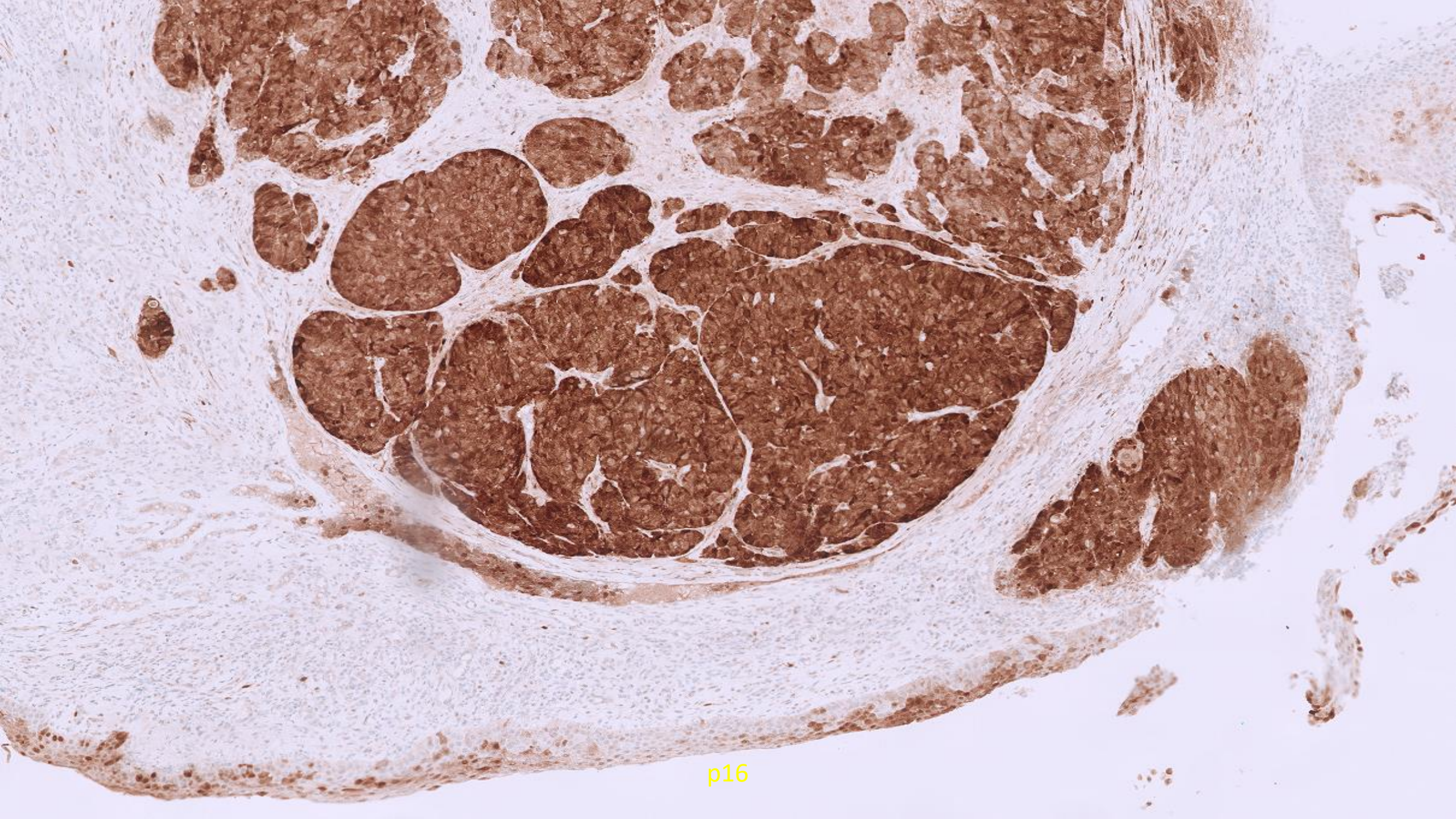
p16

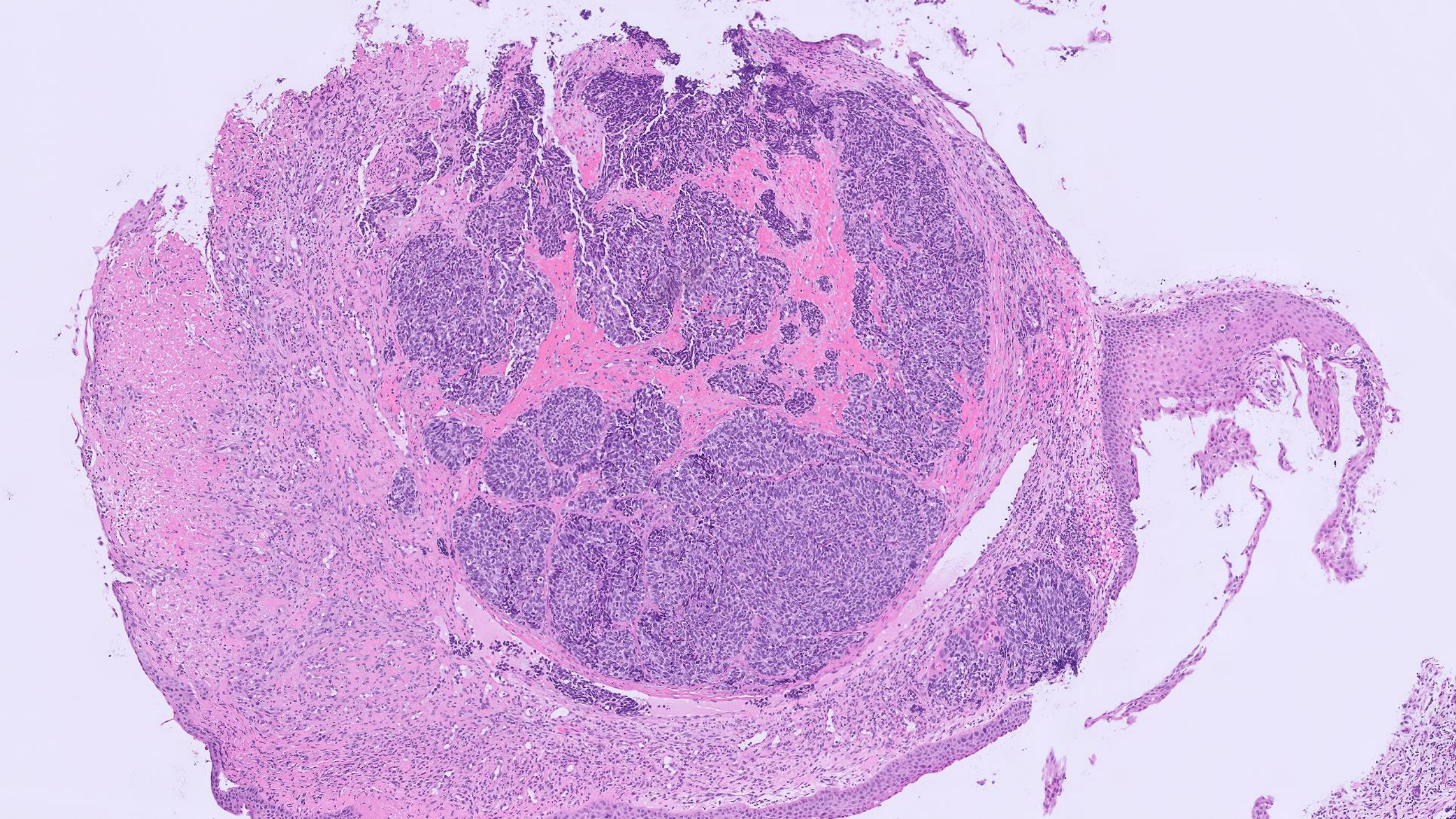

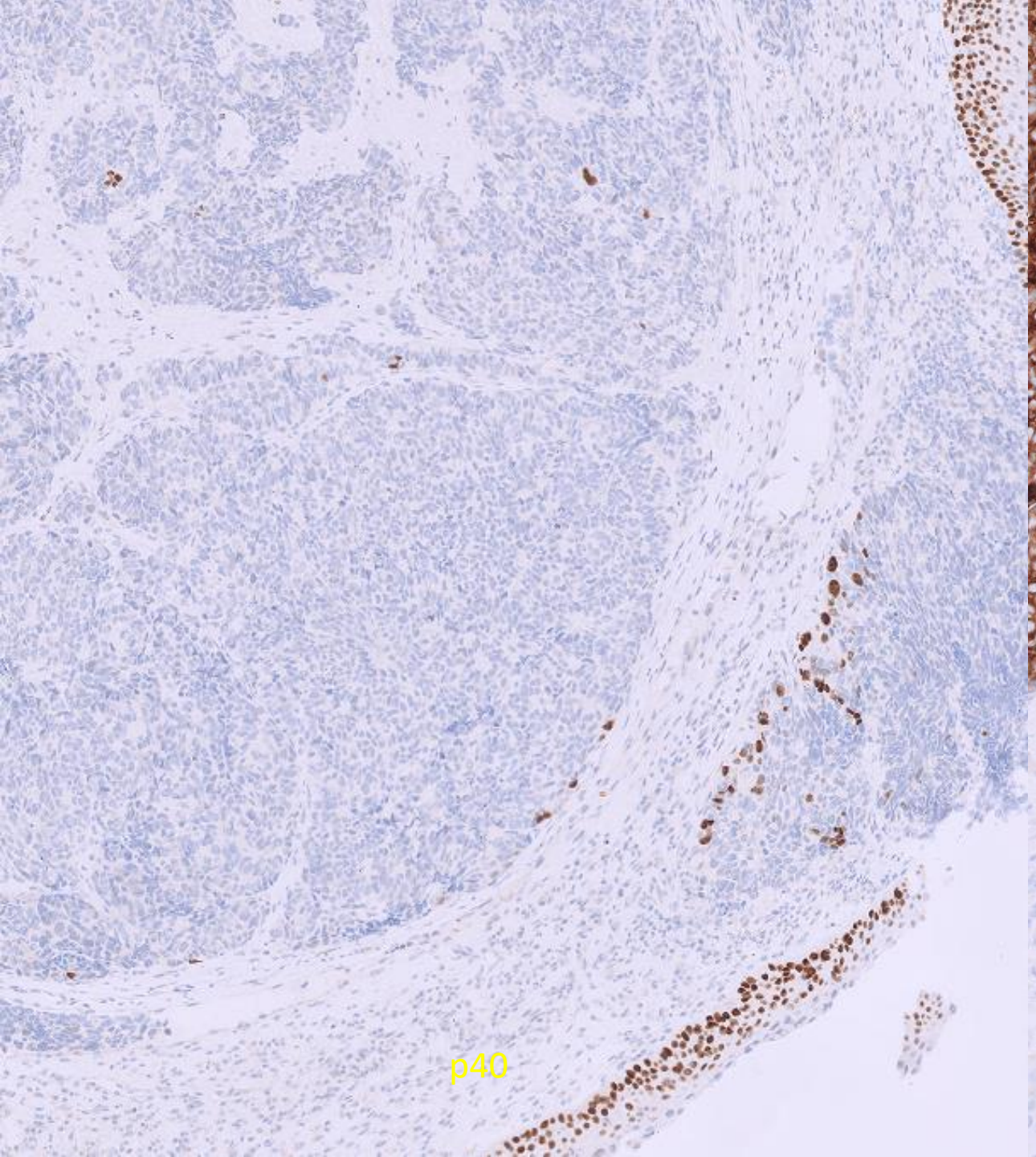
p40

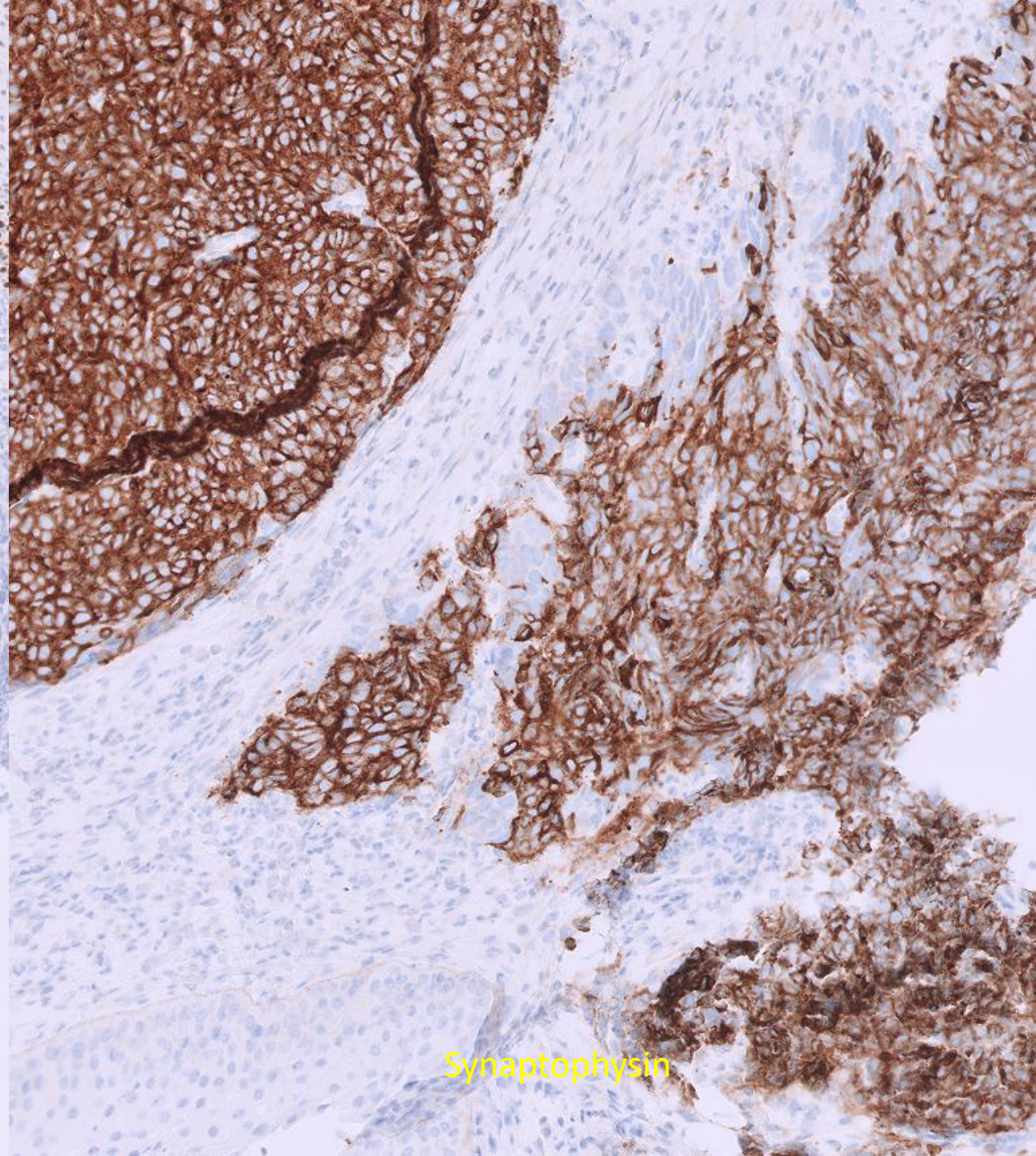
Synaptophysin

Final diagnosis

- HPV-related carcinoma with neuroendocrine and squamous differentiation

Comment: In the nasal septal mass resection, sections predominantly show large cell neuroendocrine carcinoma. There is a minor component of in situ and invasive keratinizing squamous cell carcinoma that is intimately associated with the neuroendocrine carcinoma. Both components are HPV positive, supporting a single tumor with divergent differentiation. The tumor is therefore best classified as an HPV-related carcinoma with neuroendocrine and squamous differentiation.

Follow up

- Adjuvant radiation due to pT3 disease (cribriform plate involvement)

25-1005

Greg Charville; Stanford

47-year-old male with pain in his thigh who was found to have a 10-cm mass

L
KMB
NWB

L
KMB
NWB

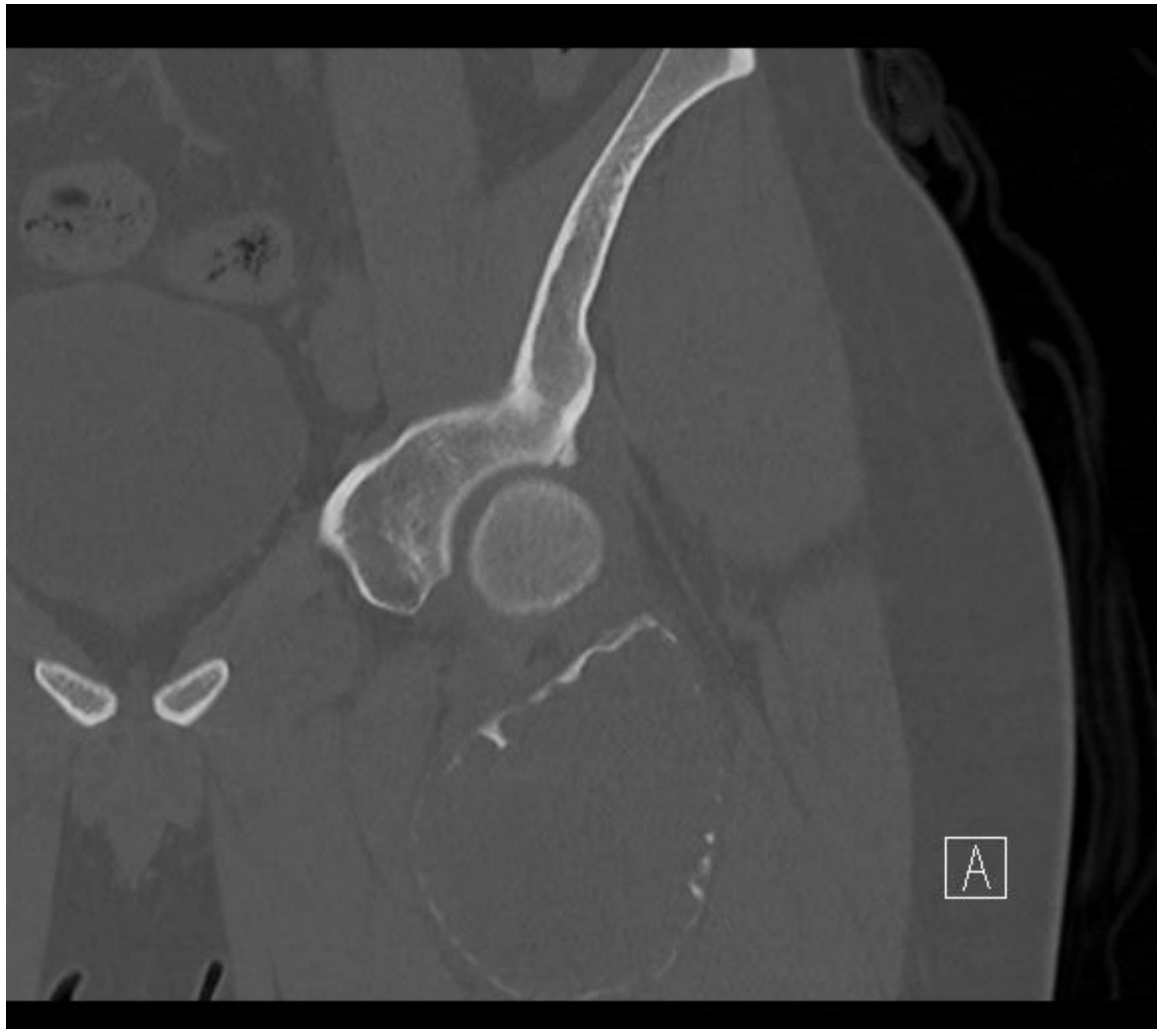
A

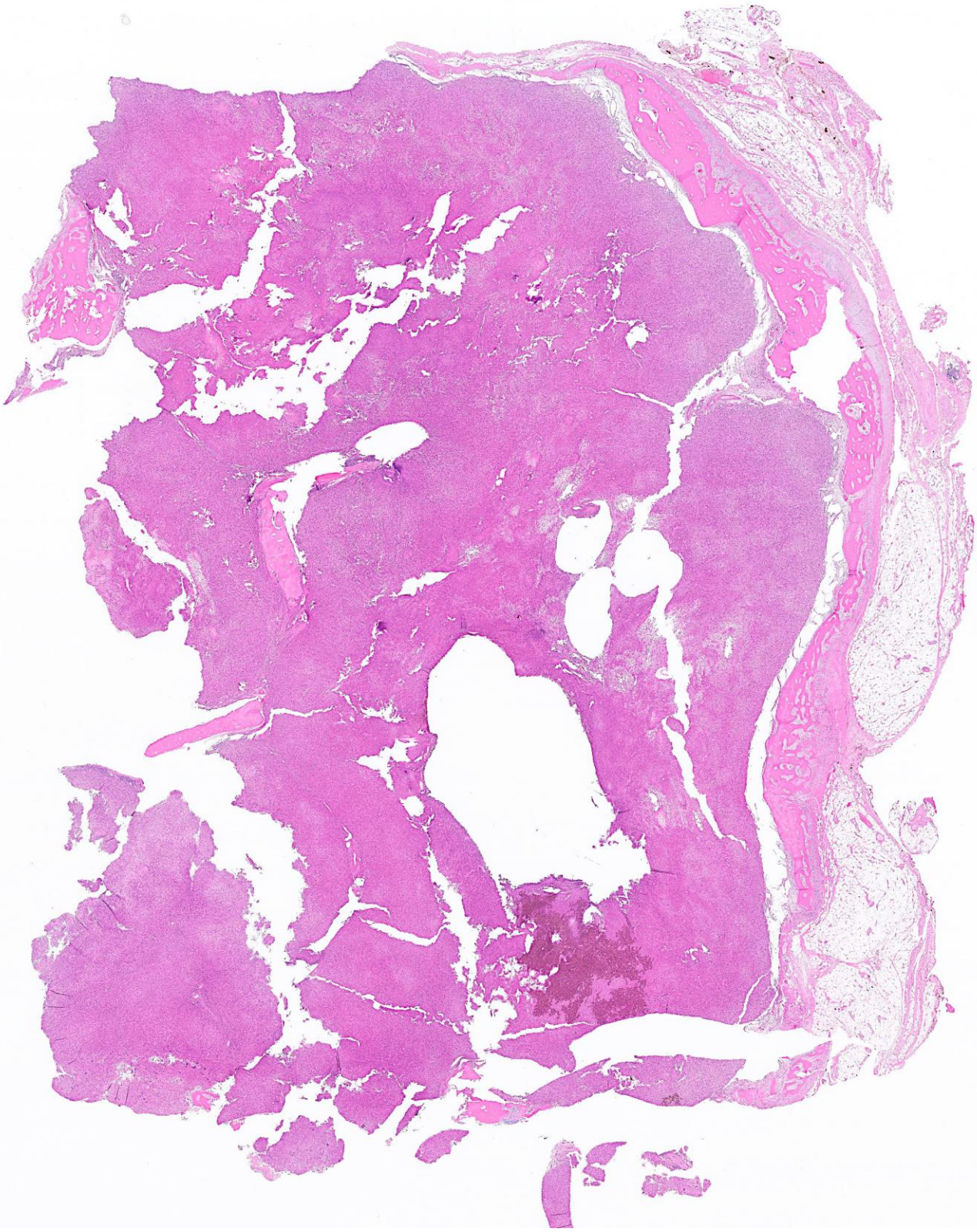

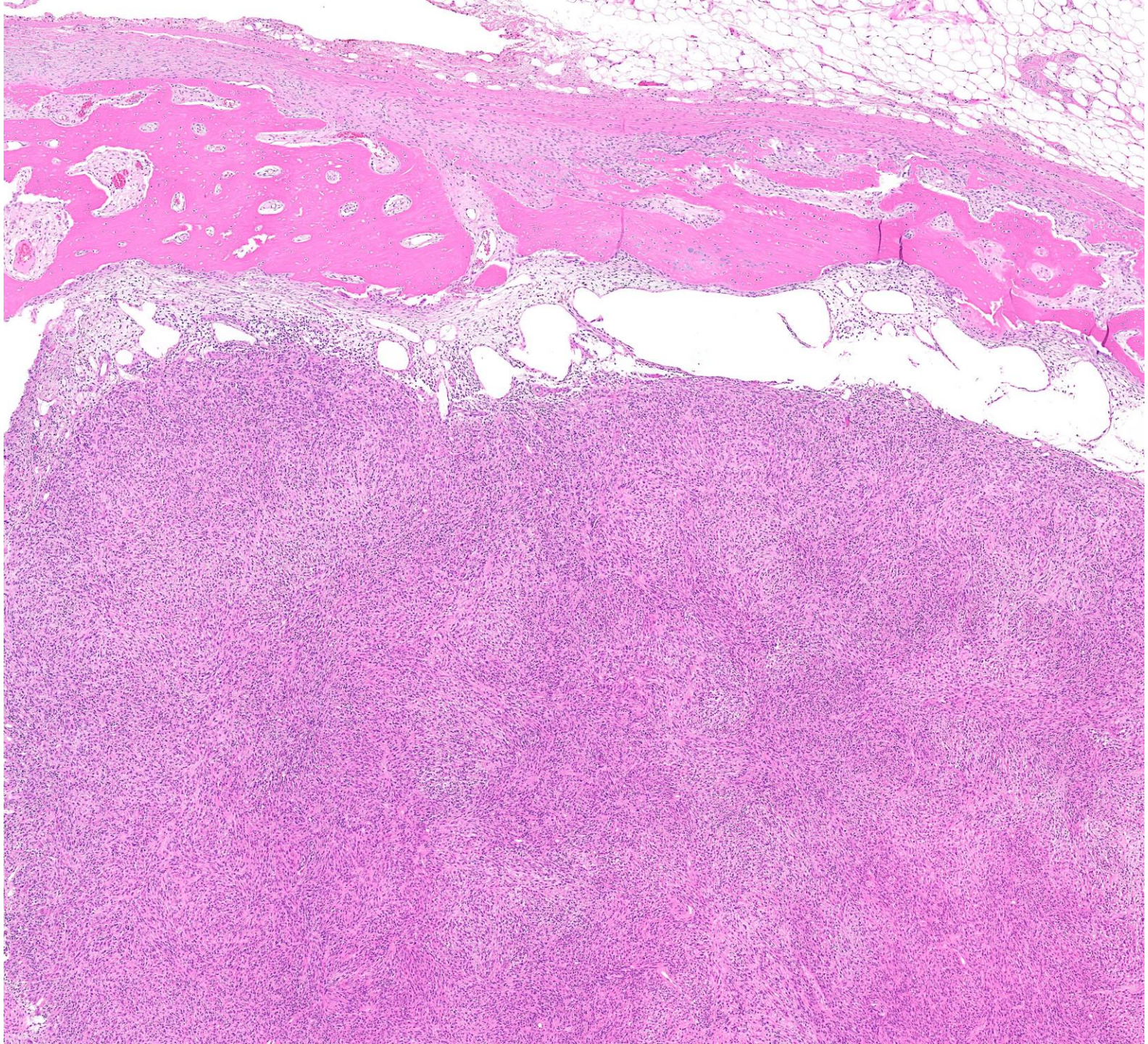

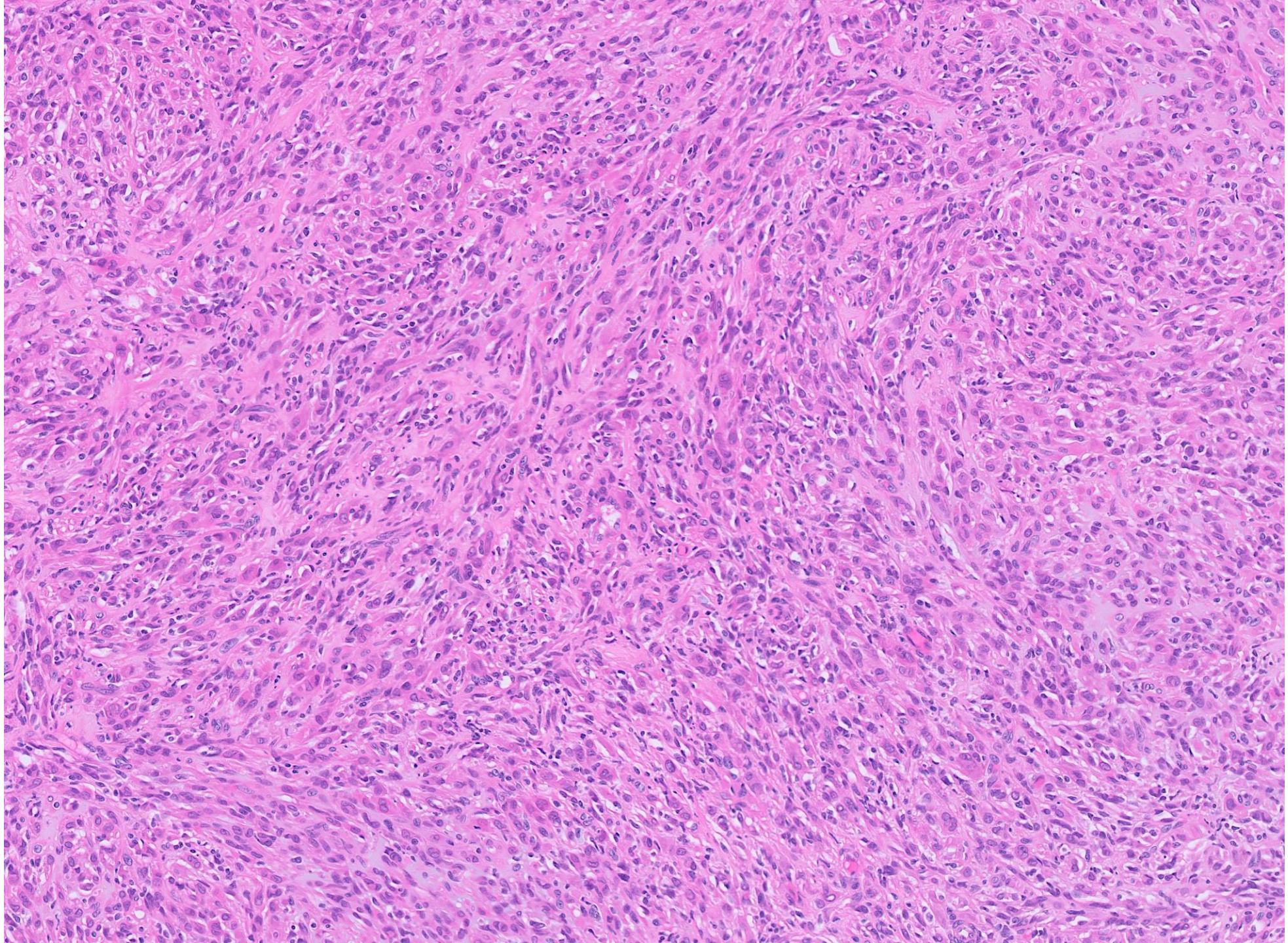

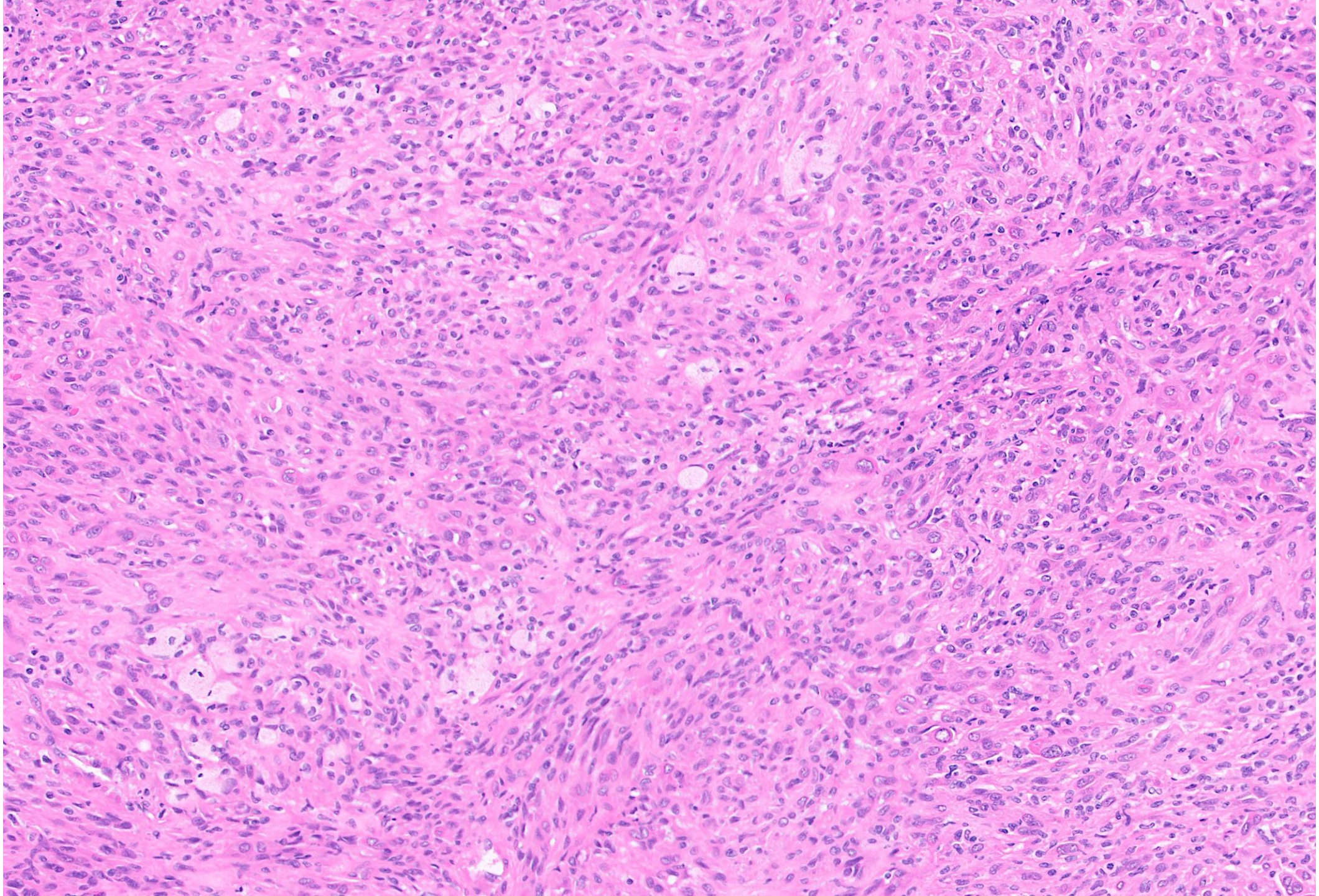

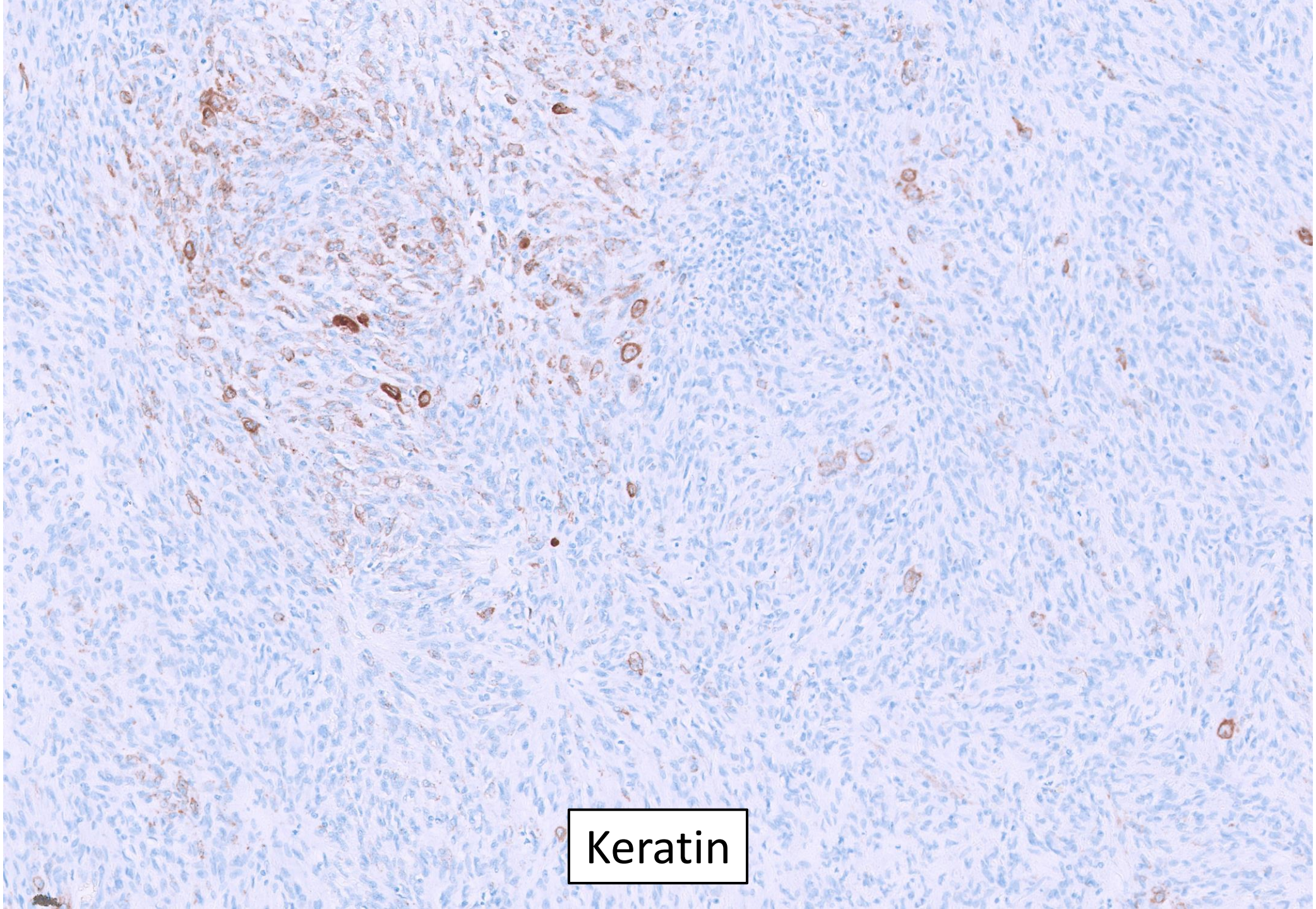
Keratin

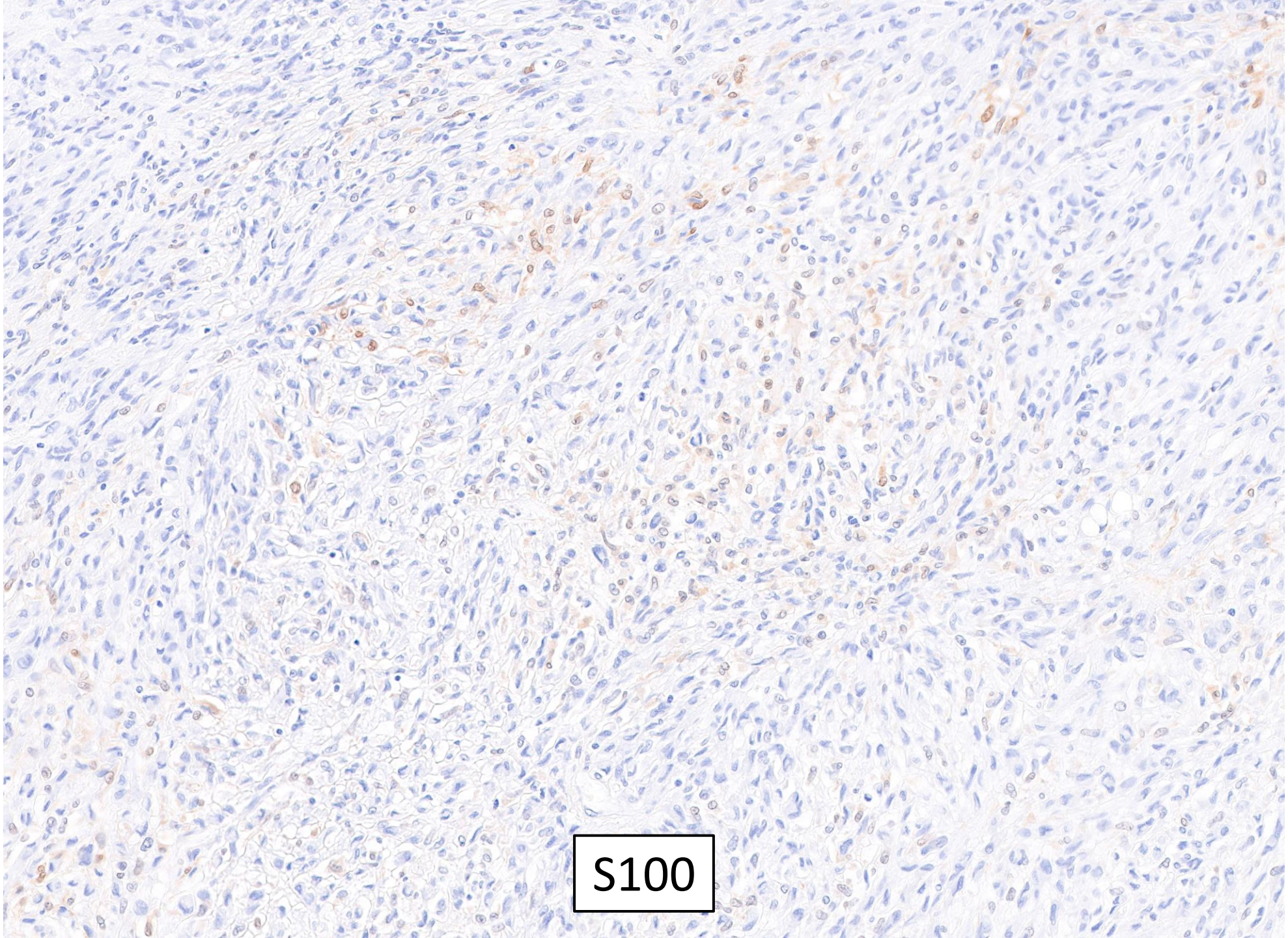
S100

DIAGNOSIS?

L
KMB
NWB

L
KMB
NWB

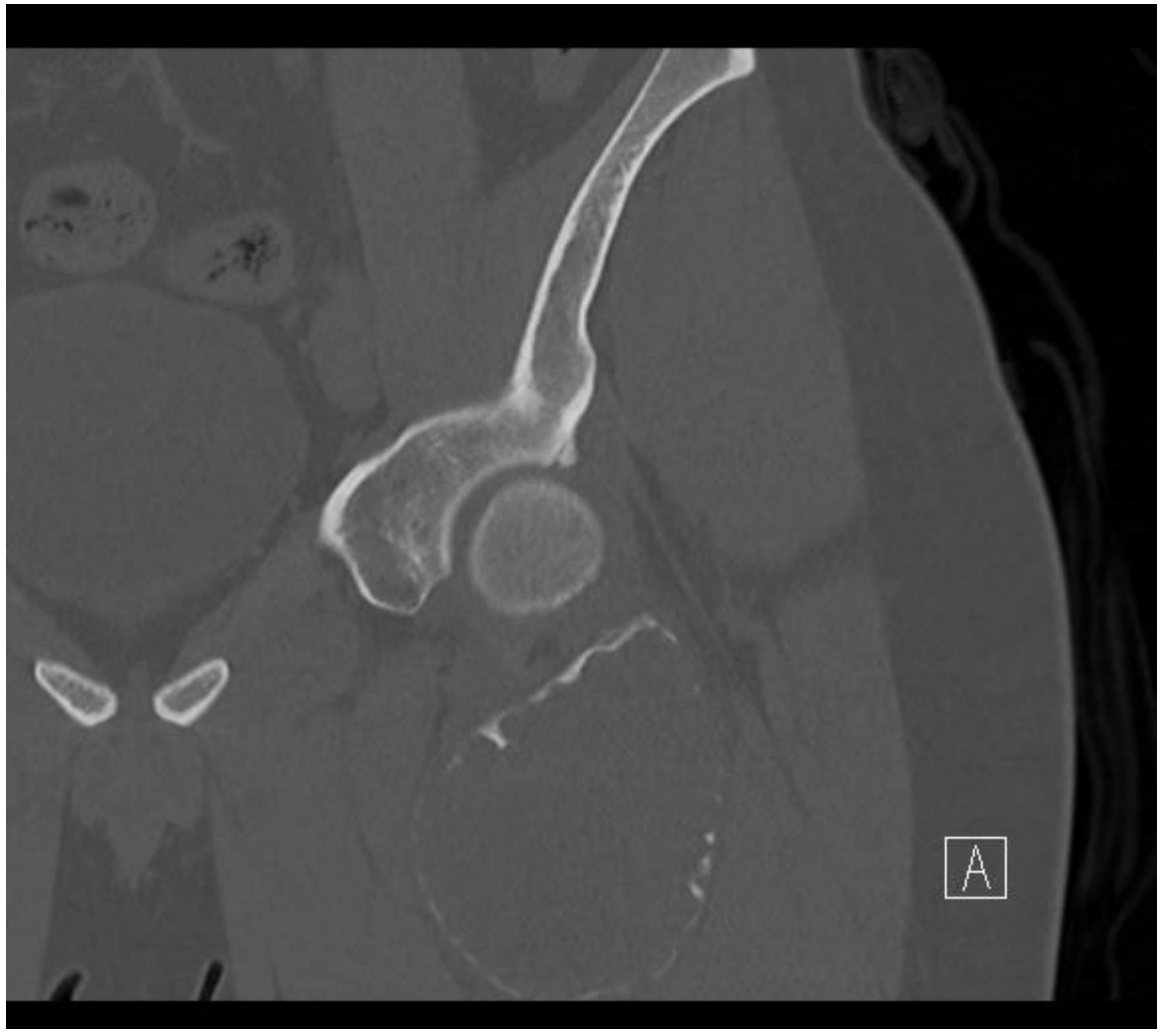
A

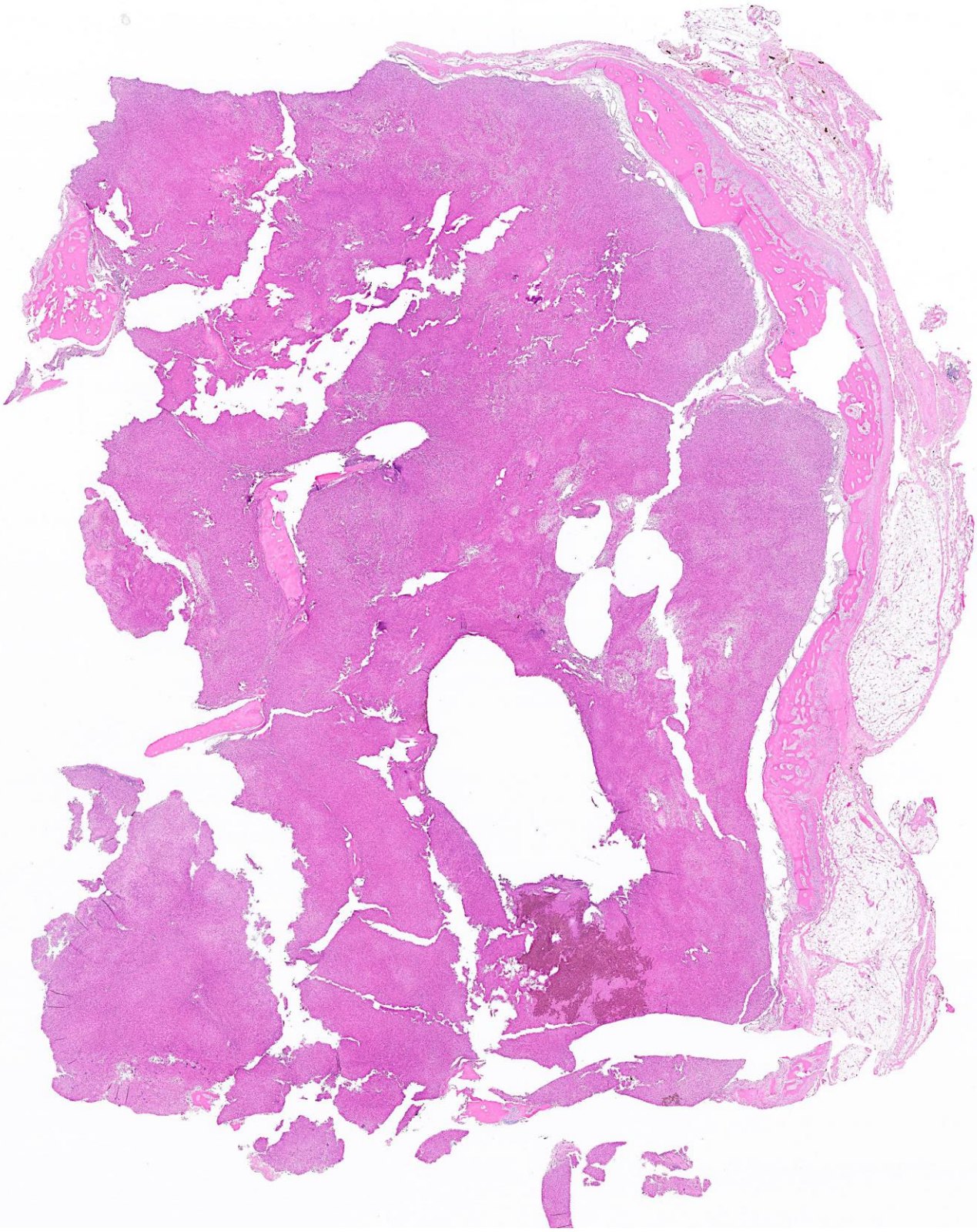

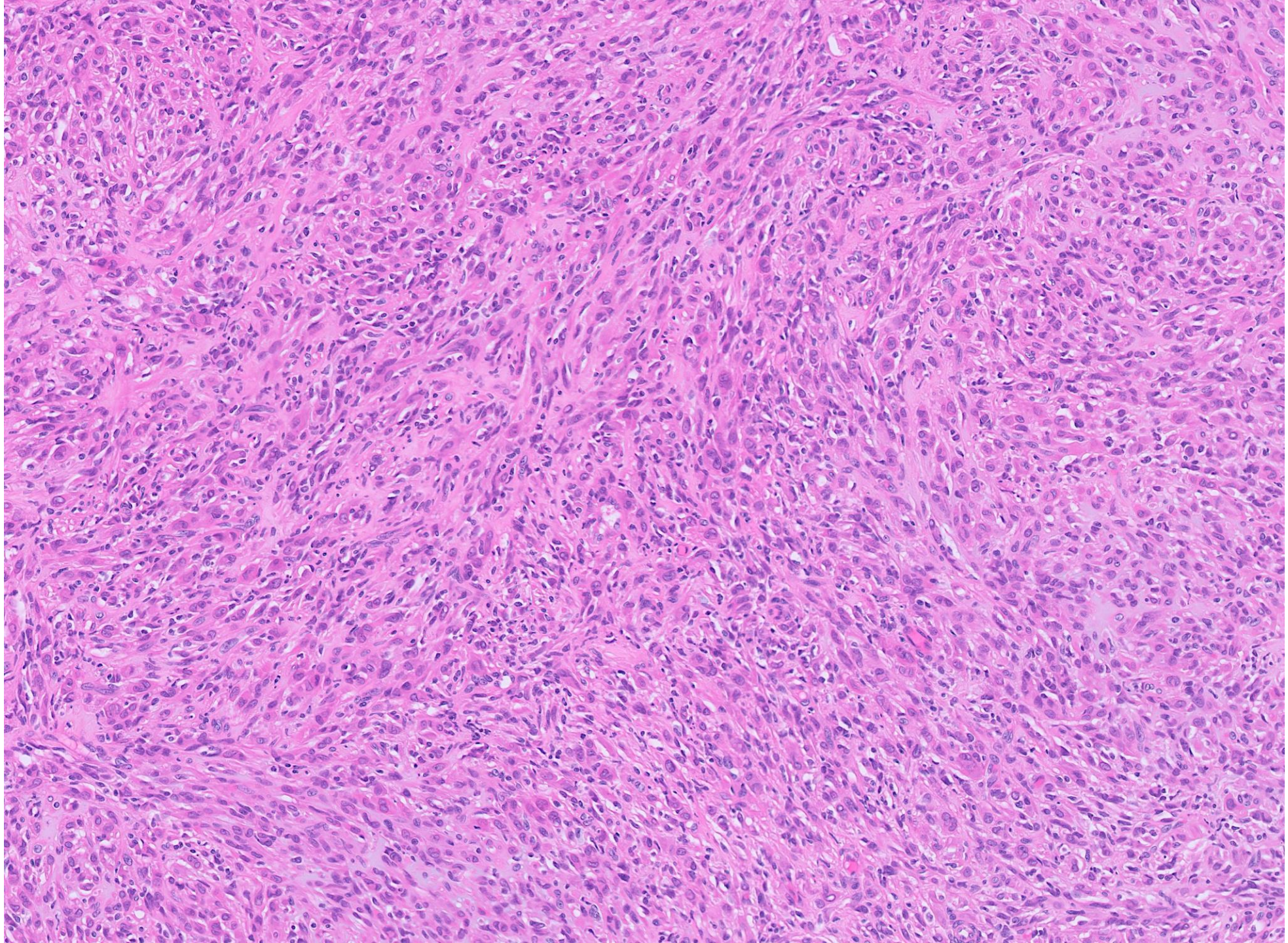

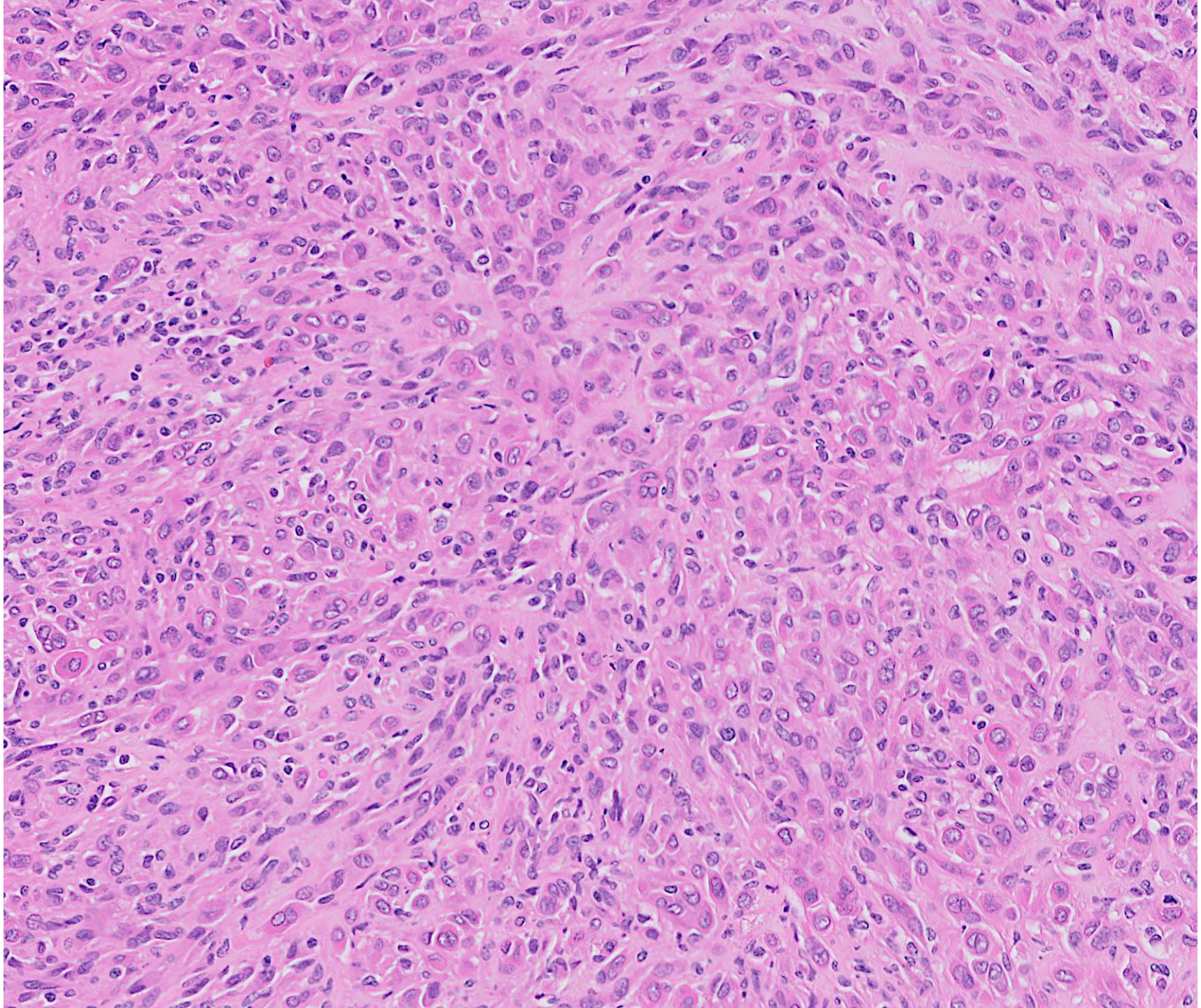

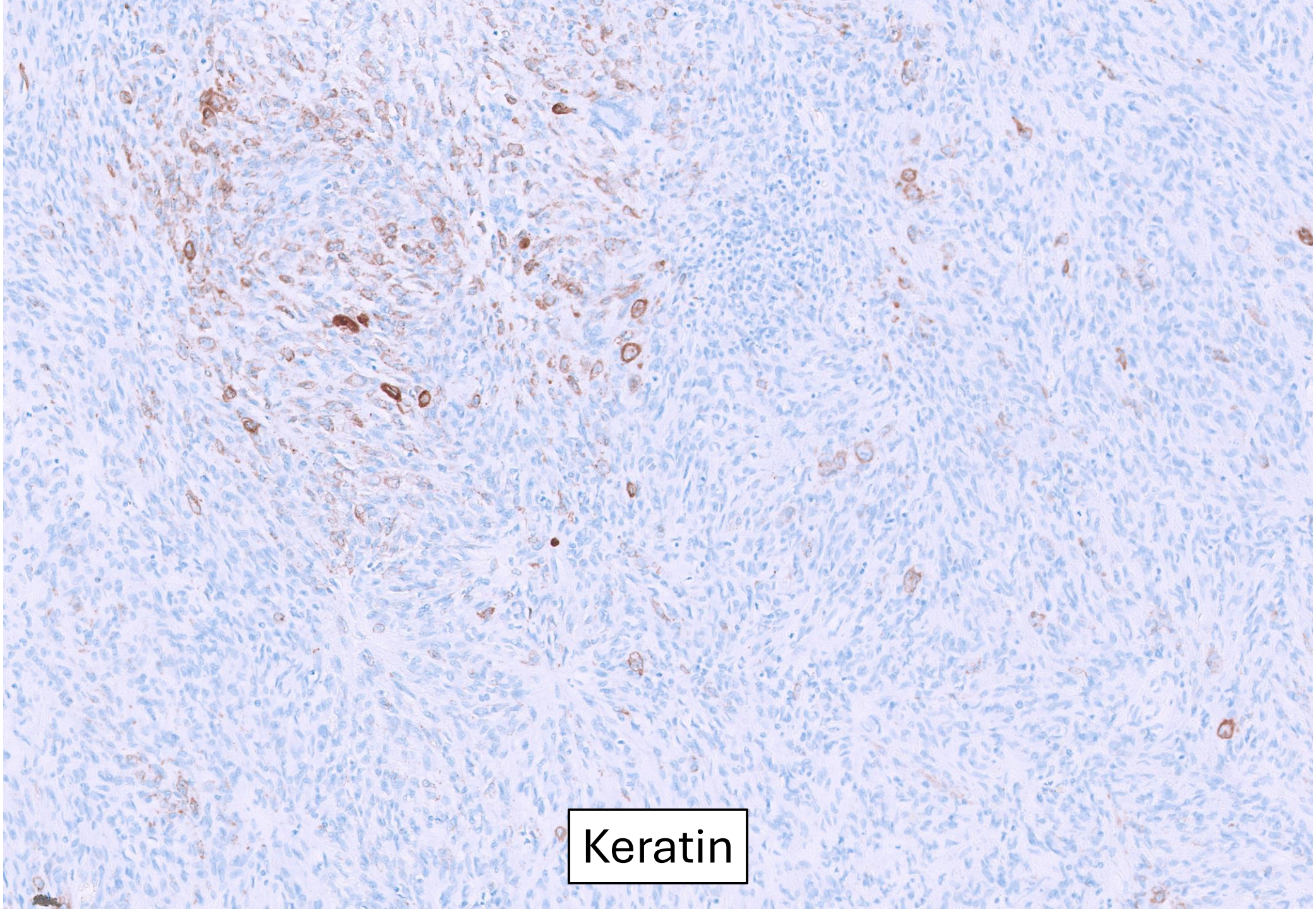
Keratin

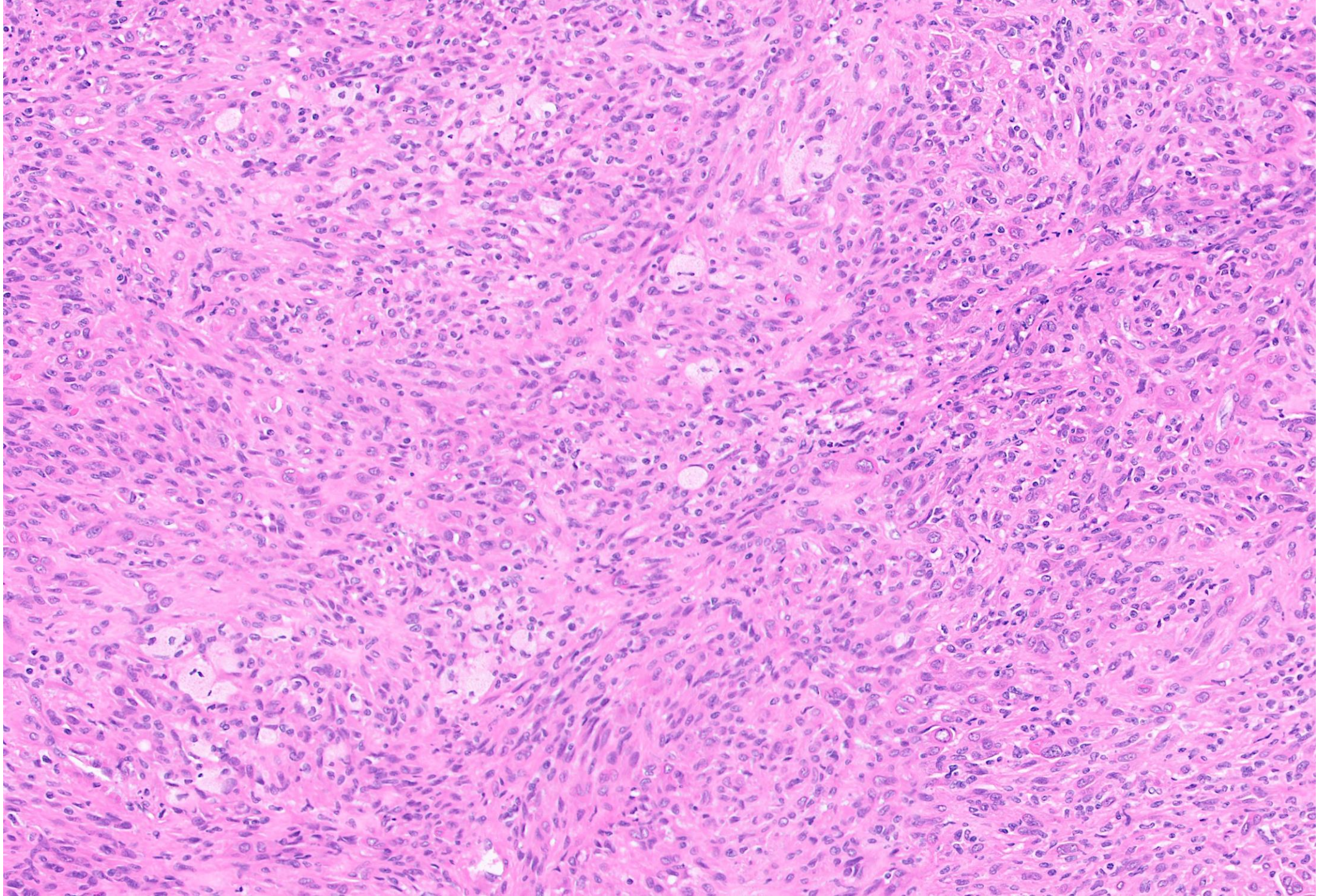

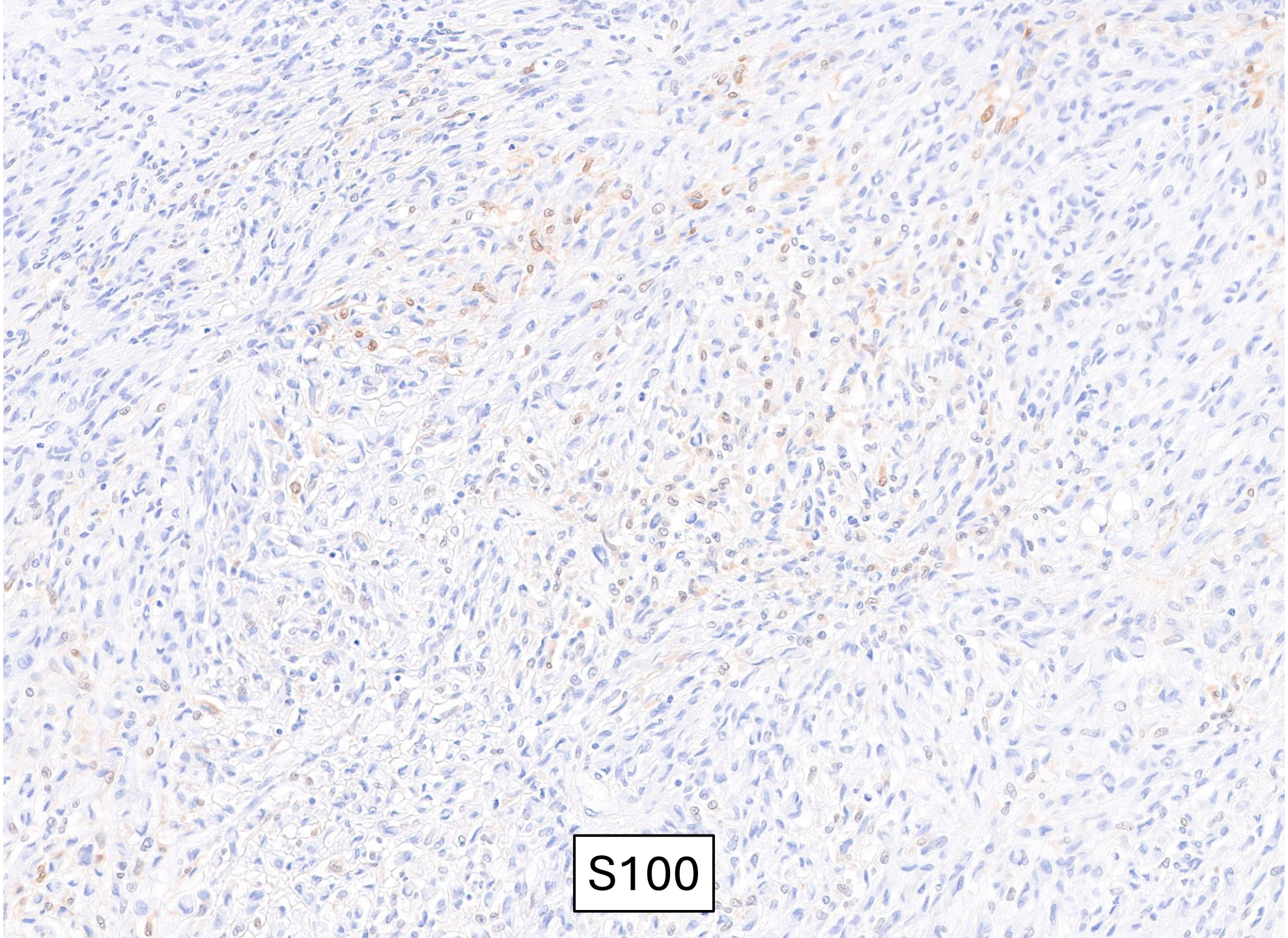
S100

Differential diagnosis

- Myositis ossificans
- Ossifying fibromyxoid tumor
- Pseudomyogenic hemangioendothelioma
- Epithelioid sarcoma
- Synovial sarcoma
- Sarcomatoid carcinoma
- Xanthogranulomatous epithelial tumor
  - Keratin-positive giant cell-rich soft tissue tumor
- Giant cell tumor of soft tissue
- Extraskeletal osteosarcoma

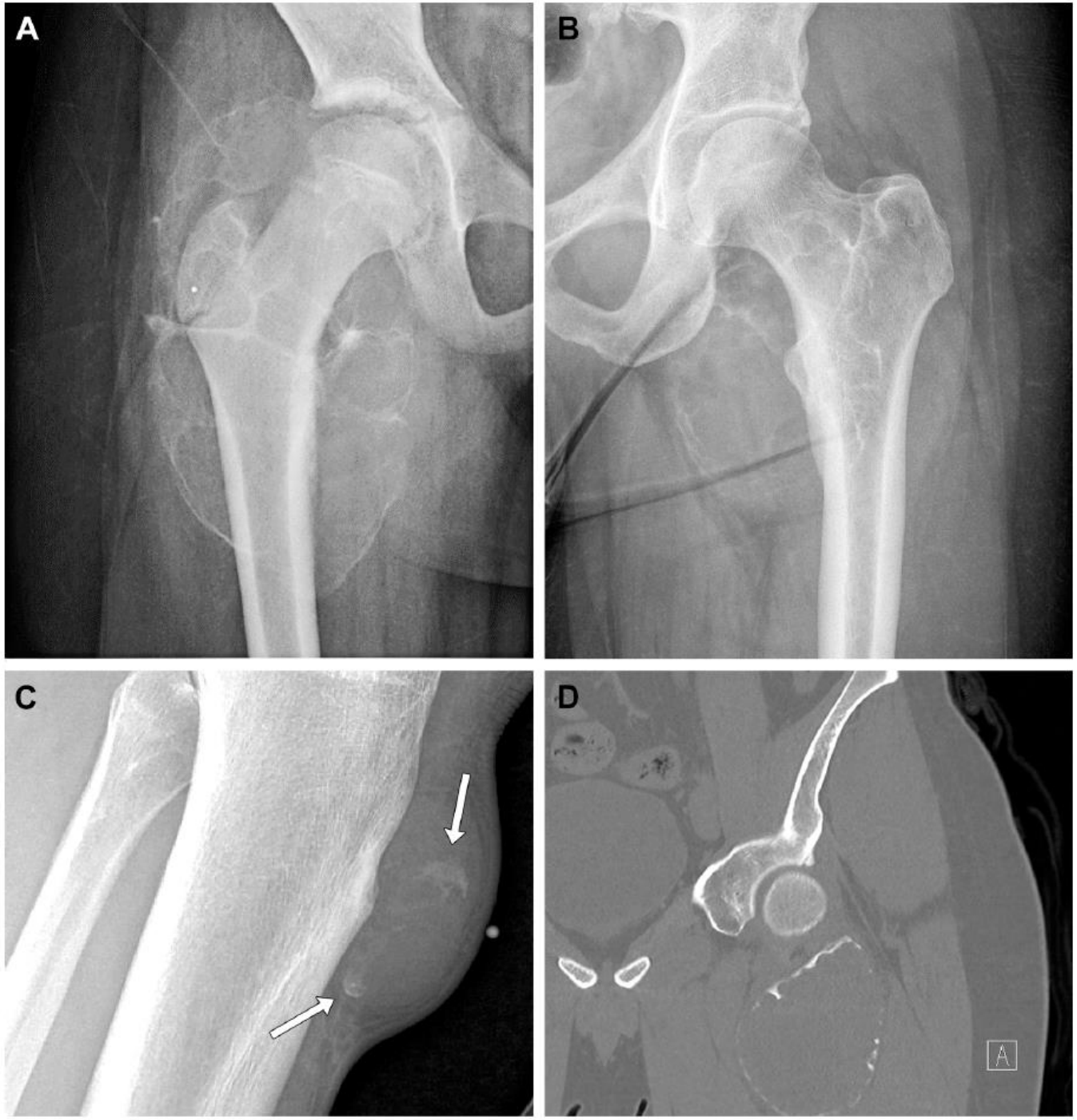
A
B
C
D
A

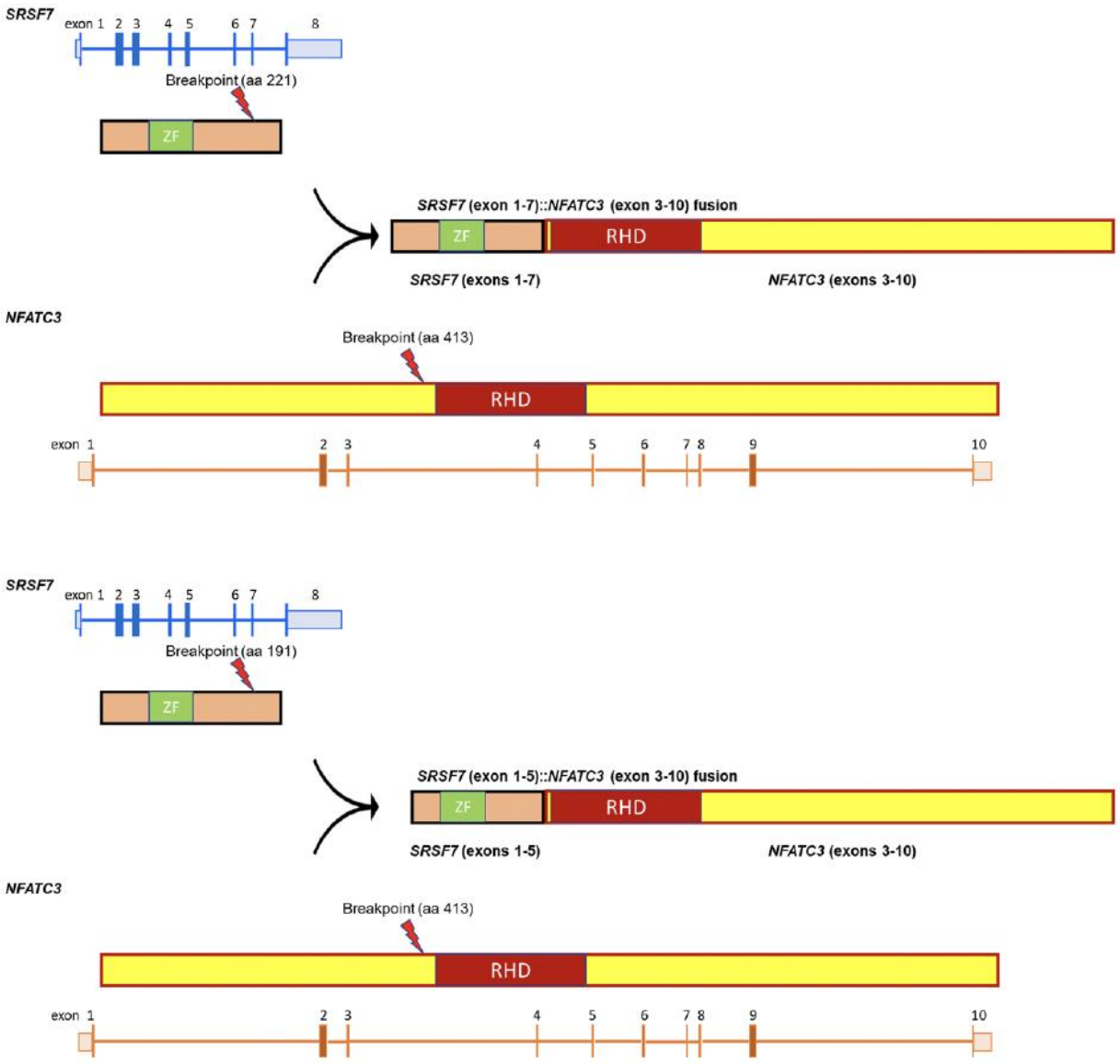
SRSF7
exon 1 2 3 4 5 6 7 8
Breakpoint (aa 221)
ZF
SRSF7 (exon 1-7)::NFATC3 (exon 3-10) fusion
ZF
RHD
SRSF7 (exons 1-7)
NFATC3 (exons 3-10)
NFATC3
Breakpoint (aa 413)
RHD
exon 1 2 3 4 5 6 7 8 9 10
SRSF7
exon 1 2 3 4 5 6 7 8
Breakpoint (aa 191)
ZF
SRSF7 (exon 1-5)::NFATC3 (exon 3-10) fusion
ZF
RHD
SRSF7 (exons 1-5)
NFATC3 (exons 3-10)
NFATC3
Breakpoint (aa 413)
RHD
exon 1 2 3 4 5 6 7 8 9 10

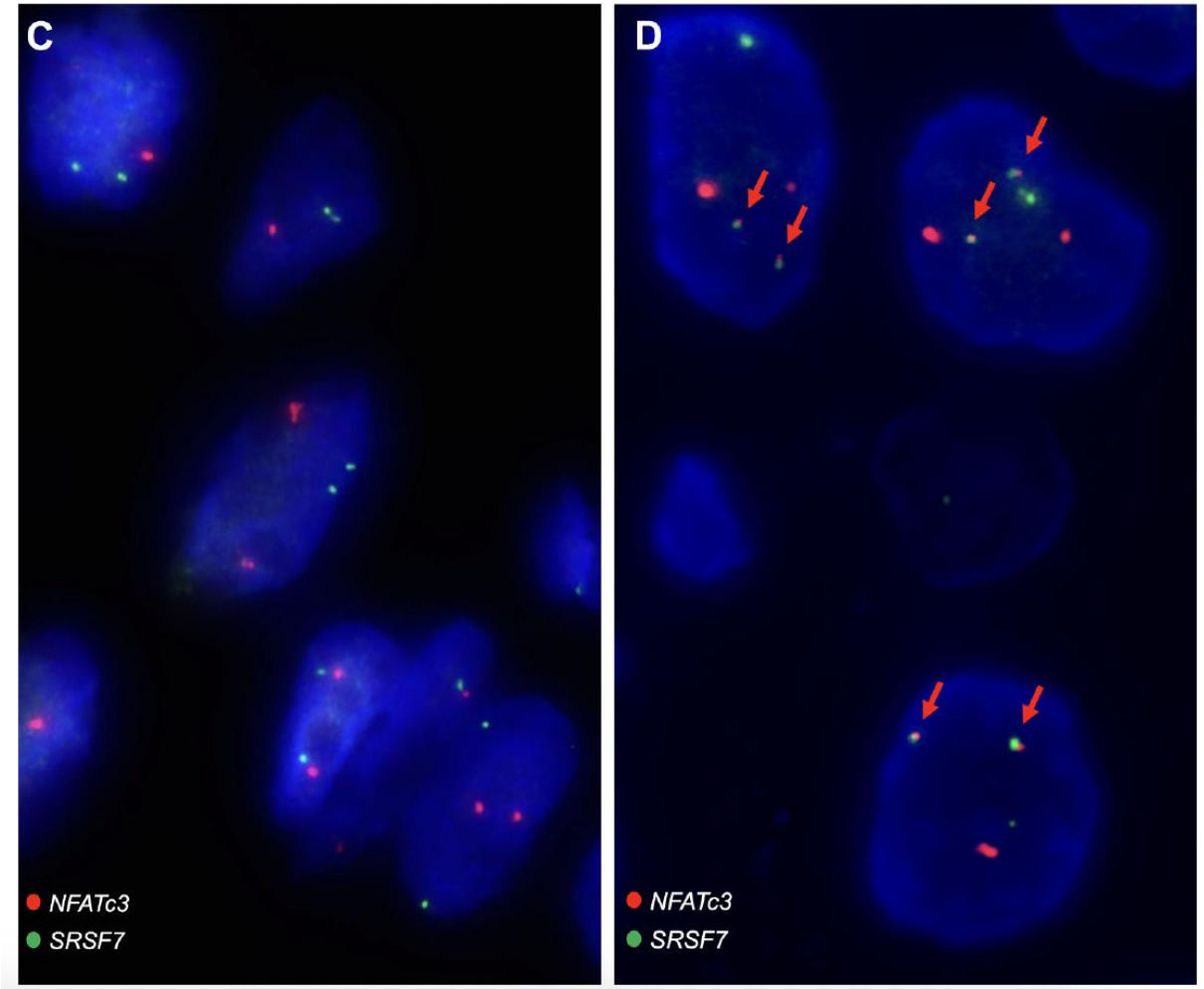
C
NFATc3
SRSF7
D
NFATc3
SRSF7

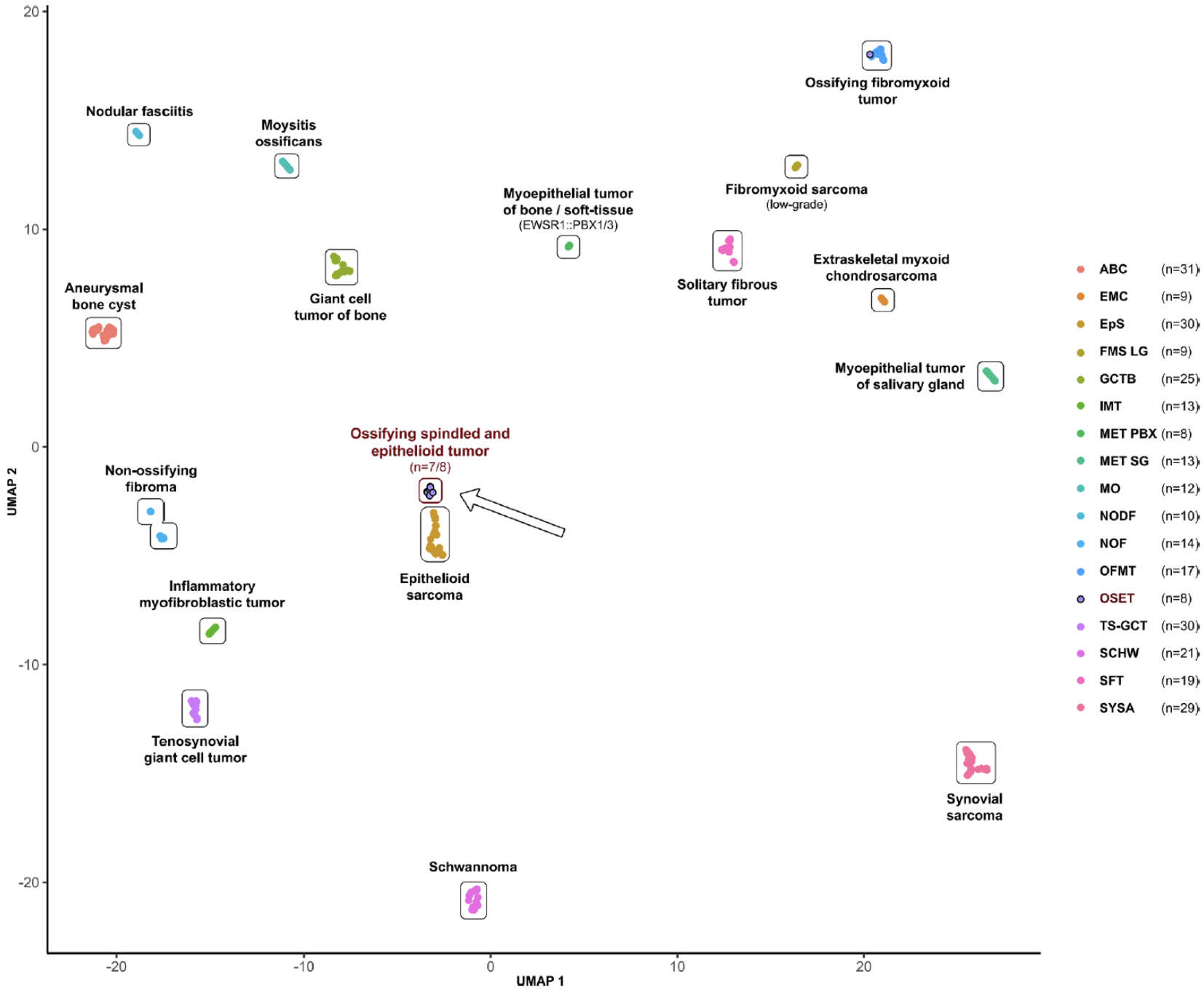
Ossifying fibromyxoid tumor
Nodular fasciitis
Moysitis ossificans
Fibromyxoid sarcoma (low-grade)
Myoepithelial tumor of bone / soft-tissue (EWSR1::PBX1/3)
Solitary fibrous tumor
Extraskeletal myxoid chondrosarcoma
Aneurysmal bone cyst
Giant cell tumor of bone
Myoepithelial tumor of salivary gland
Ossifying spindled and epithelioid tumor (n=7/8)
Non-ossifying fibroma
Epithelioid sarcoma
Inflammatory myofibroblastic tumor
Tenosynovial giant cell tumor
Synovial sarcoma
Schwannoma
UMAP 1
UMAP 2
20
10
0
-10
-20
ABC (n=31)
EMC (n=9)
EpS (n=30)
FMS LG (n=9)
GCTB (n=25)
IMT (n=13)
MET PBX (n=8)
MET SG (n=13)
MO (n=12)
NODF (n=10)
NOF (n=14)
OFMT (n=17)
OSET (n=8)
TS-GCT (n=30)
SCHW (n=21)
SFT (n=19)
SYSA (n=29)

Ossifying Spindled and Epithelioid Tumor: A Novel Soft Tissue Tumor

John M. Gross[a,*], Ying S. Zou[a], Michael Michal[b,c], Abbas Agaimy[d,e], Roberto A. Garcia[f], Christopher Hysell[g], Karen J. Fritchie[h], Josephine K. Dermawan[h], Brian P. Rubin[h], Melanie Klausner[a], Laura Morsberger[a], Jonathan Dudley[a], Alyza Skaist[i], Yan Zhang[i], Kornel Schuebel[i], Jennifer Meyers[i], Srinivasan Yegnasubramanian[i], Leslie Cope[i], Nasir Ud Din[j], Ali Alani[k], David I. Suster[l], Lisa Rooper[a], Pedram Argani[a], Ezra G. Baraban[a], Daniel Baumhoer[m,n], Baptiste Ameline[m], Gregory W. Charville[o], Andrew E. Rosenberg[p]

MODERN PATHOLOGY

USCAP UNITED STATES AND CANADIAN ACADEMY OF PATHOLOGY
Advancing Pathology Together

- Ossifying Spindled and Epithelioid Tumor (OSET) is a novel soft tissue tumor with a peripheral shell of bone, composed of bland myoid spindle and epithelioid cells that are keratin-positive
- 12 cases (6F, 6M), mean age 32 y, arising in extremities and proximal limb girdle
- Mitotic activity low, rare giant cells, non-infiltrative
- Strong, multifocal staining for keratin; S100 focally positive in 50%
- *SRFS7::NFATC3* fusion in at least a subset (4 of 8 tested tumors)

25-1006

Haijuan Gao, Brooke Howitt; Stanford

46 yo F with Total Abdominal Hysterectomy with Bilateral Salpingo-Oophorectomy (TAHBSO) for multiple uterine masses. Sections of the myometrium demonstrate multiple nodules, measuring up to 3.8 cm in greatest dimension

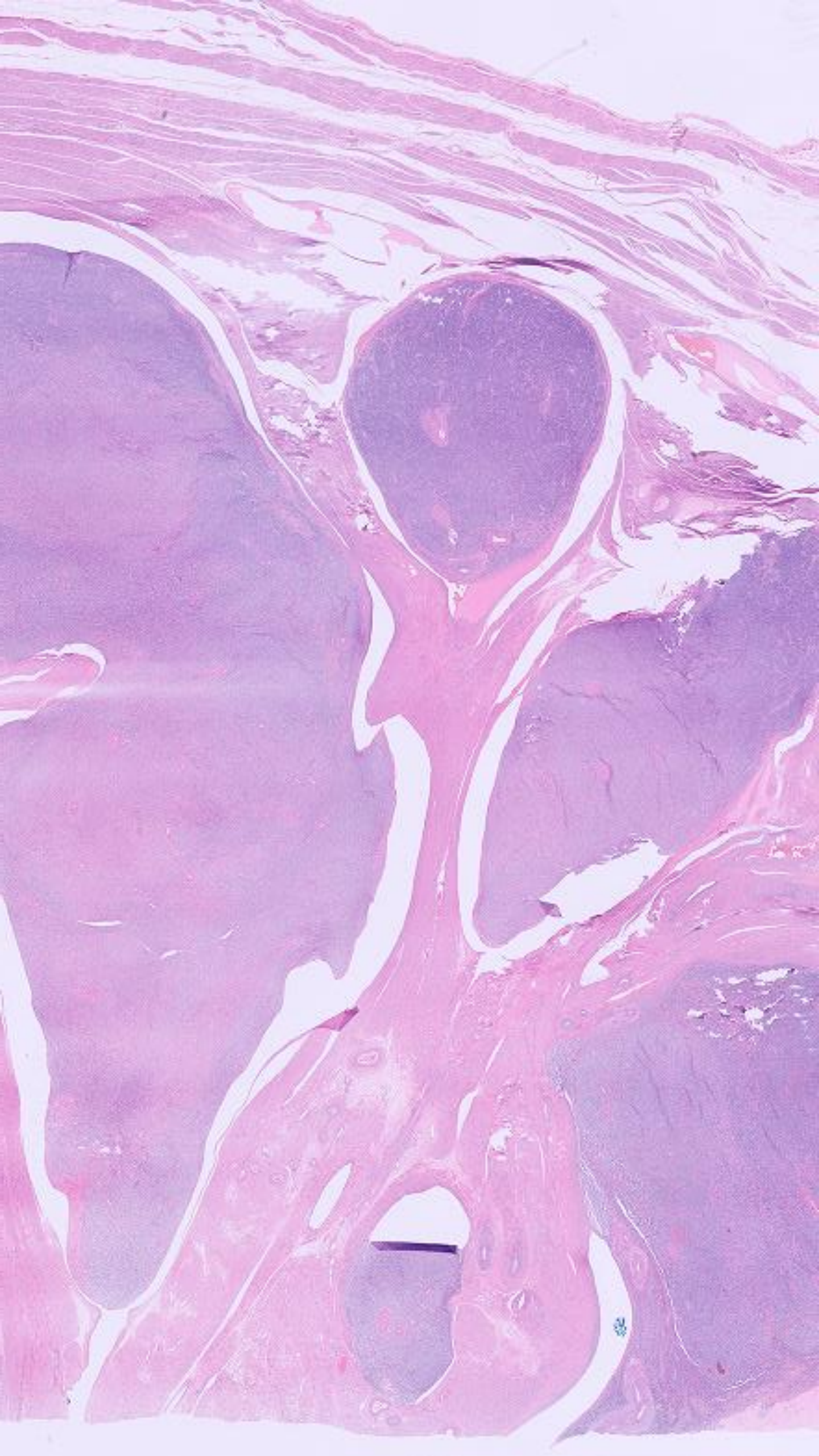

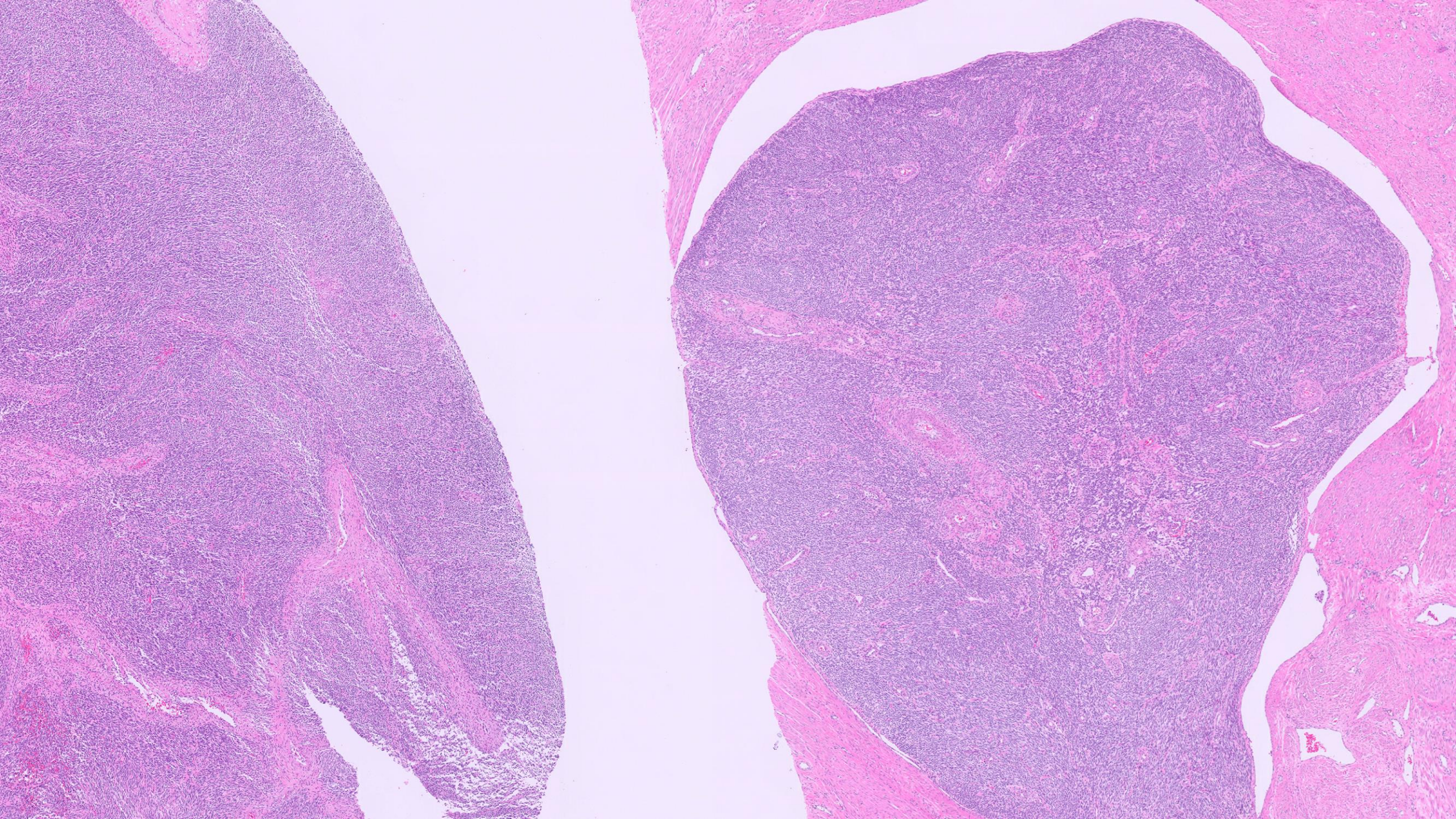

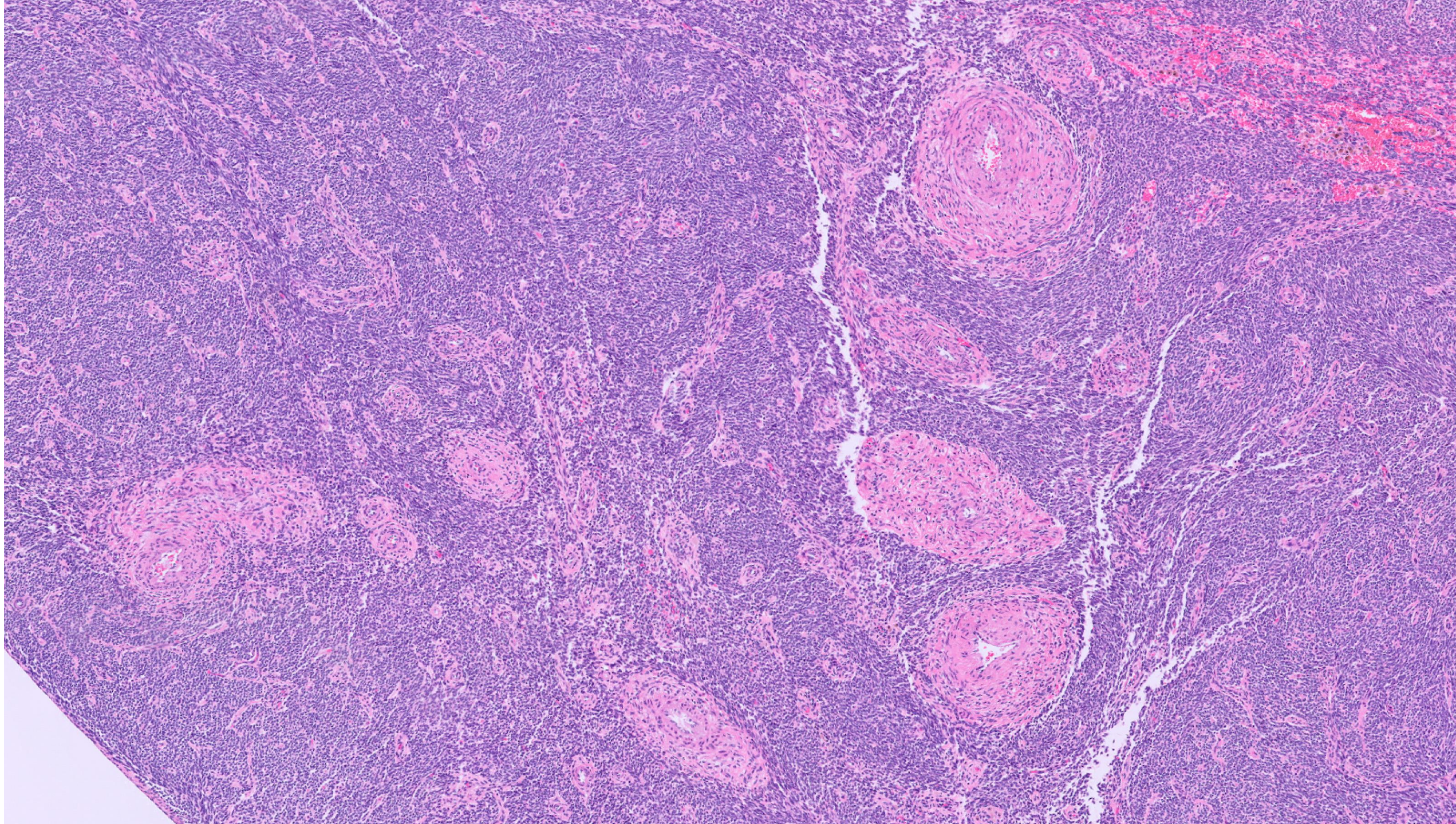

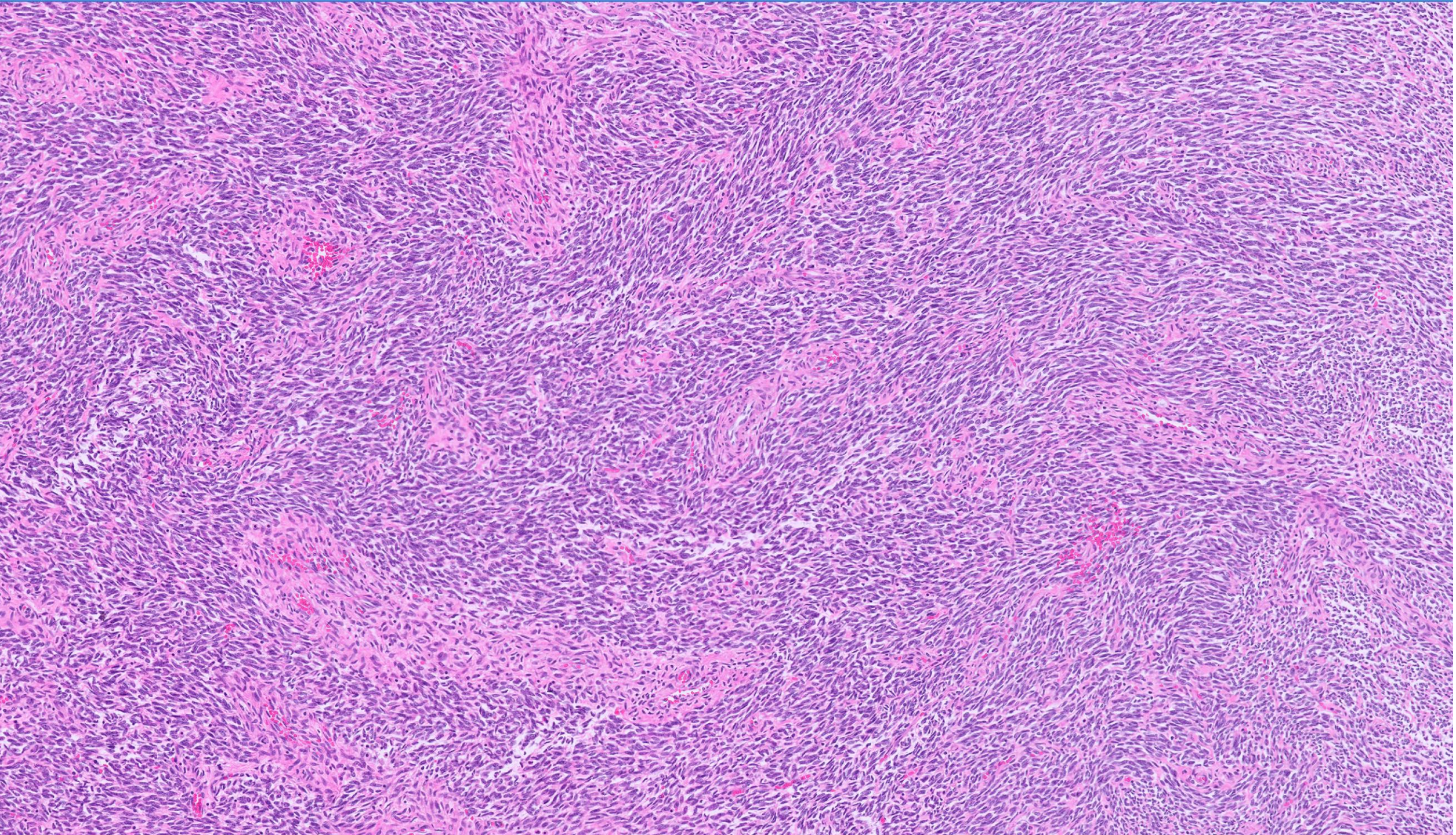

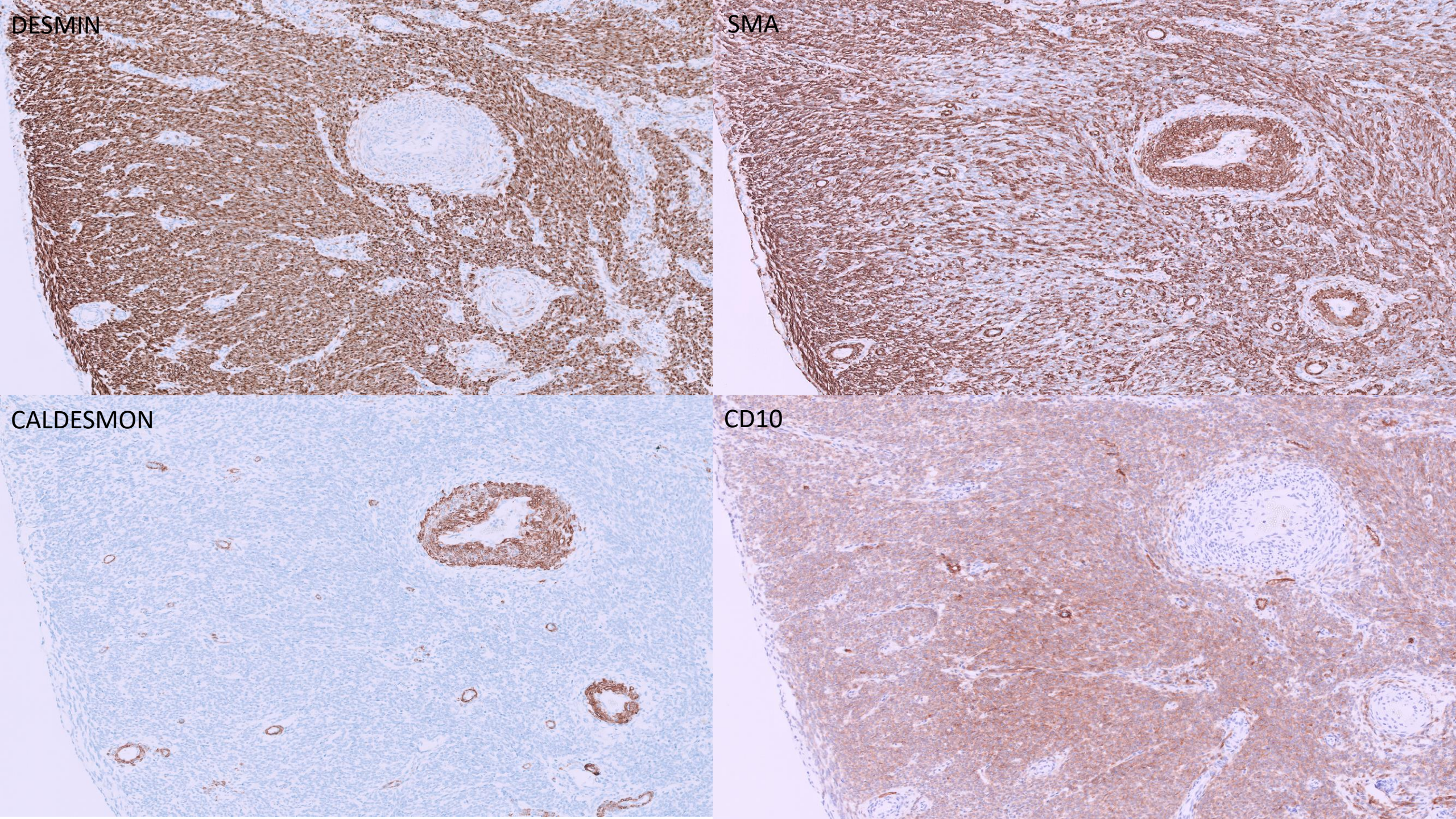
DESMIN
SMA
CALDESMON
CD10

Immunohistochemical Staining

Task Name	Result
DESMIN (DE-R-11) IHC	Positive
CALDESMON (h-CD) IHC	Negative
ACTIN SMA SMOOTH (1A4) IHC	Positive
CD10 (56C6) IHC	Positive
ALK (5A4) IHC	Negative
HMB45 (HMB45) IHC	Negative
ER (outside IHC)	Positive
PR (outside IHC)	Positive

DIAGNOSIS?

Your Impression?

- A. Leiomyoma With Hydropic Change
- B. Intravenous leiomyomatosis
- C. Low-Grade Endometrial Stromal Sarcoma
- D. Leiomyosarcoma With Prominent Intravascular Growth

Differential Diagnosis

- **Leiomyoma With Hydropic Change**
  - Nodules of smooth muscle cells free floating in spaces secondary to edema with secondary retraction artifact
  - Changes within confines of leiomyoma
  - CD31 negative (no endothelial cells)

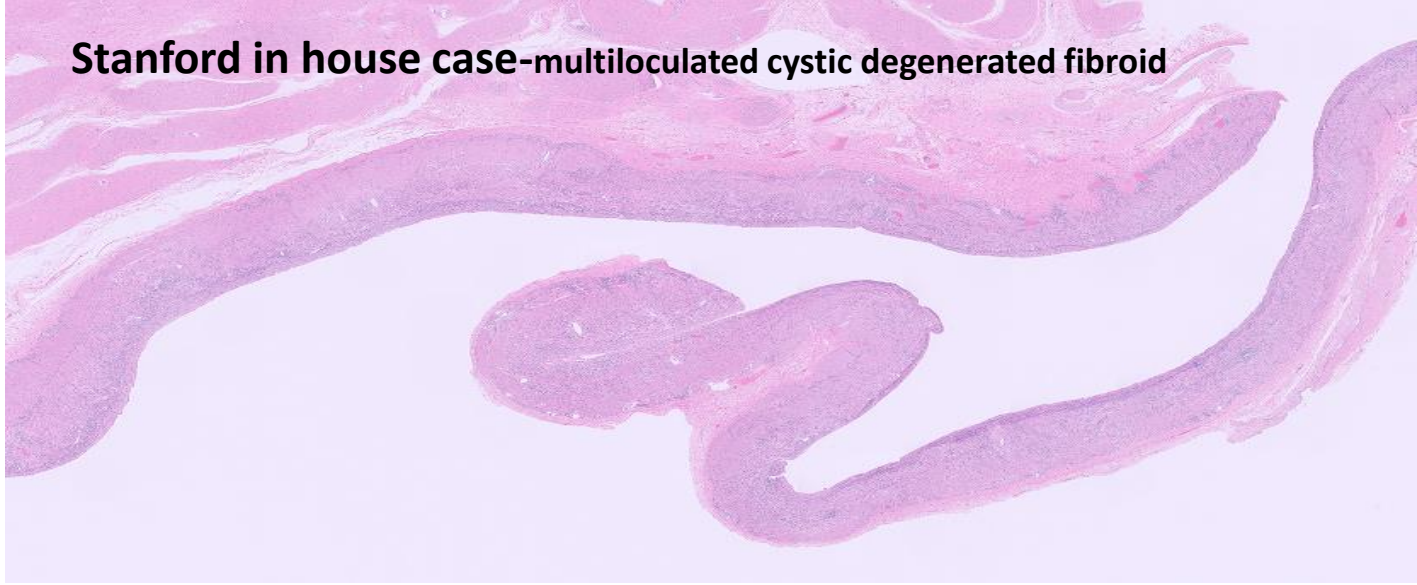

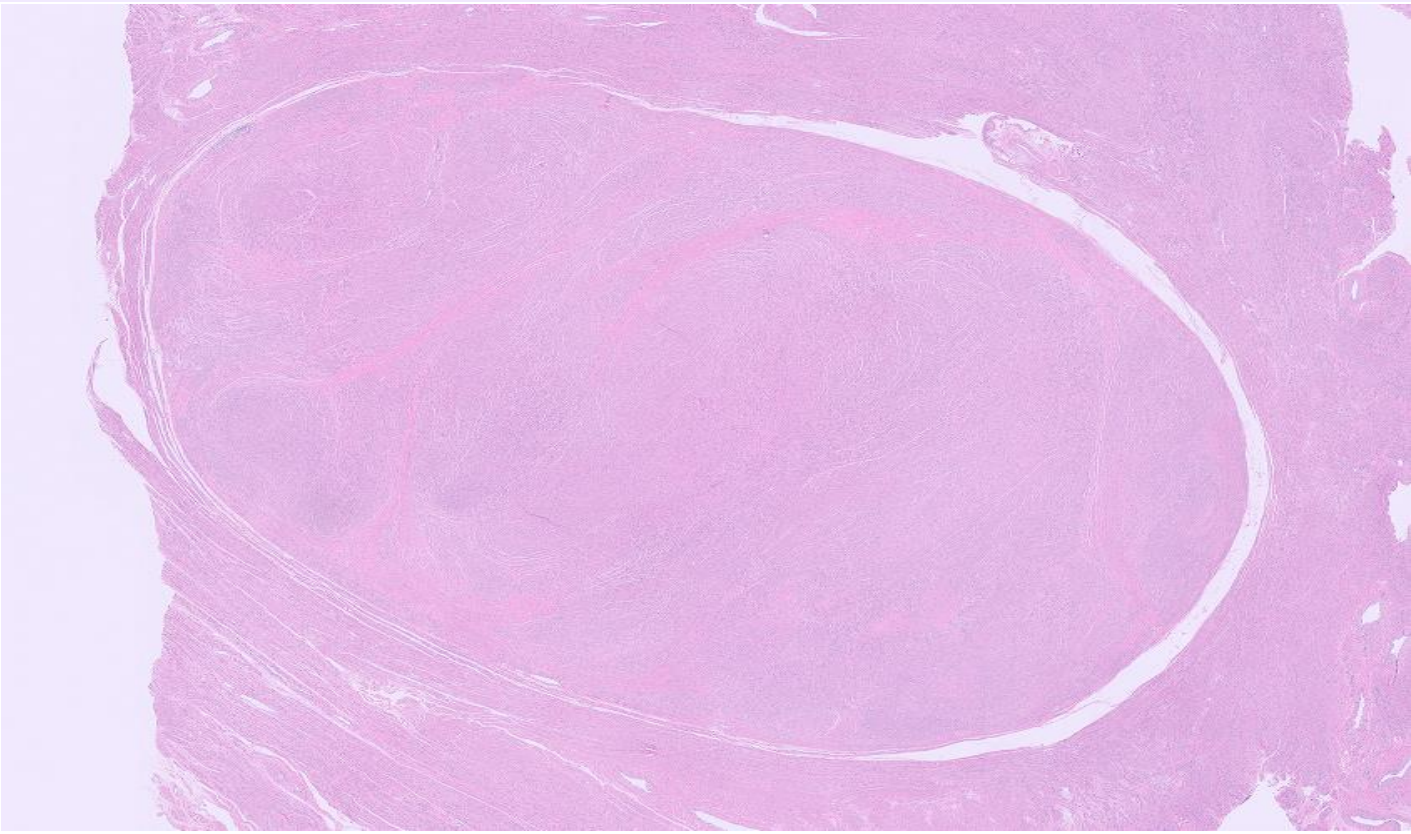

Differential Diagnosis

- **Intravenous leiomyomatosis**
  - Intravascular growth of histologically benign smooth muscle cells seen in absence (or outside confines) of leiomyoma
  - Myometrial or extrauterine (broad ligament most commonly) vascular involvement seen grossly in ~ 50%
  - CD31 positive in endothelial cells within vessels

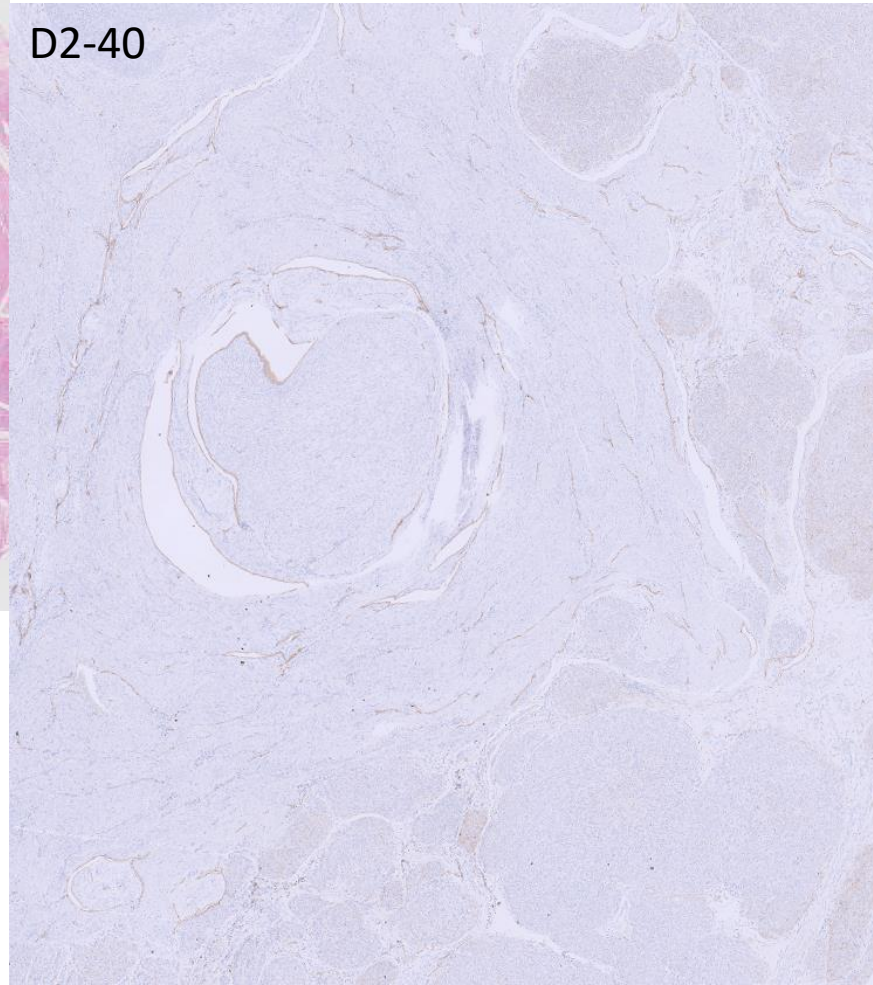

Clinical Presentation - Gross examination

- **Extension of tumor into the broad ligament and adjacent myometrial veins were frequently observed (wormlike plugs).**

- **Gross examination disclosed enlargement of the uterus by solitary or multiple masses.**

- **Accompanying uterine leiomyoma present sometimes.**

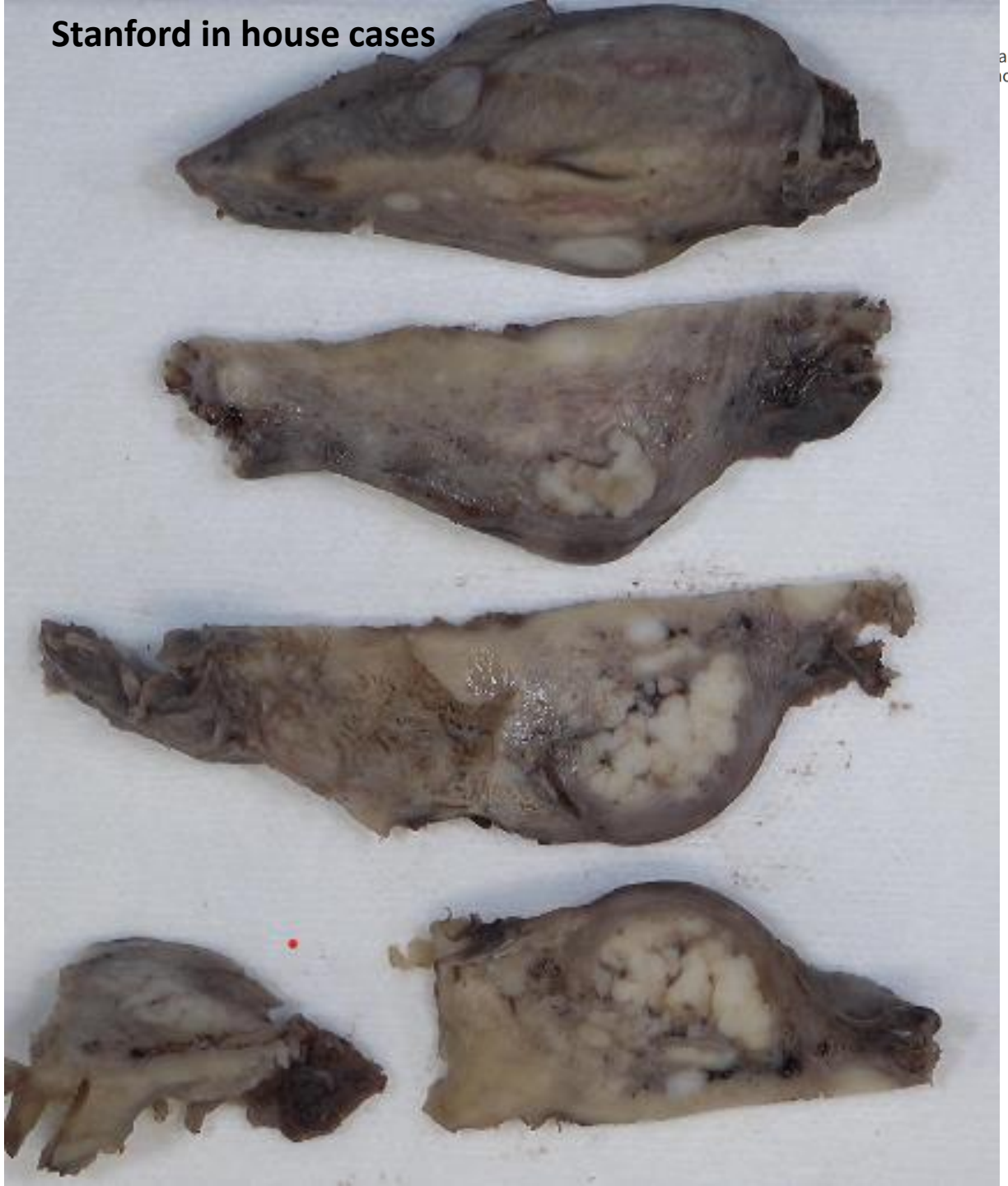

Differential Diagnosis

- **Low-Grade Endometrial Stromal Sarcoma**
  - Tongue-like infiltrative growth into myometrium
  - No large, thick-walled blood vessels
  - No cleft-like spaces or hydropic change
  - Desmin and caldesmon typically negative if conventional

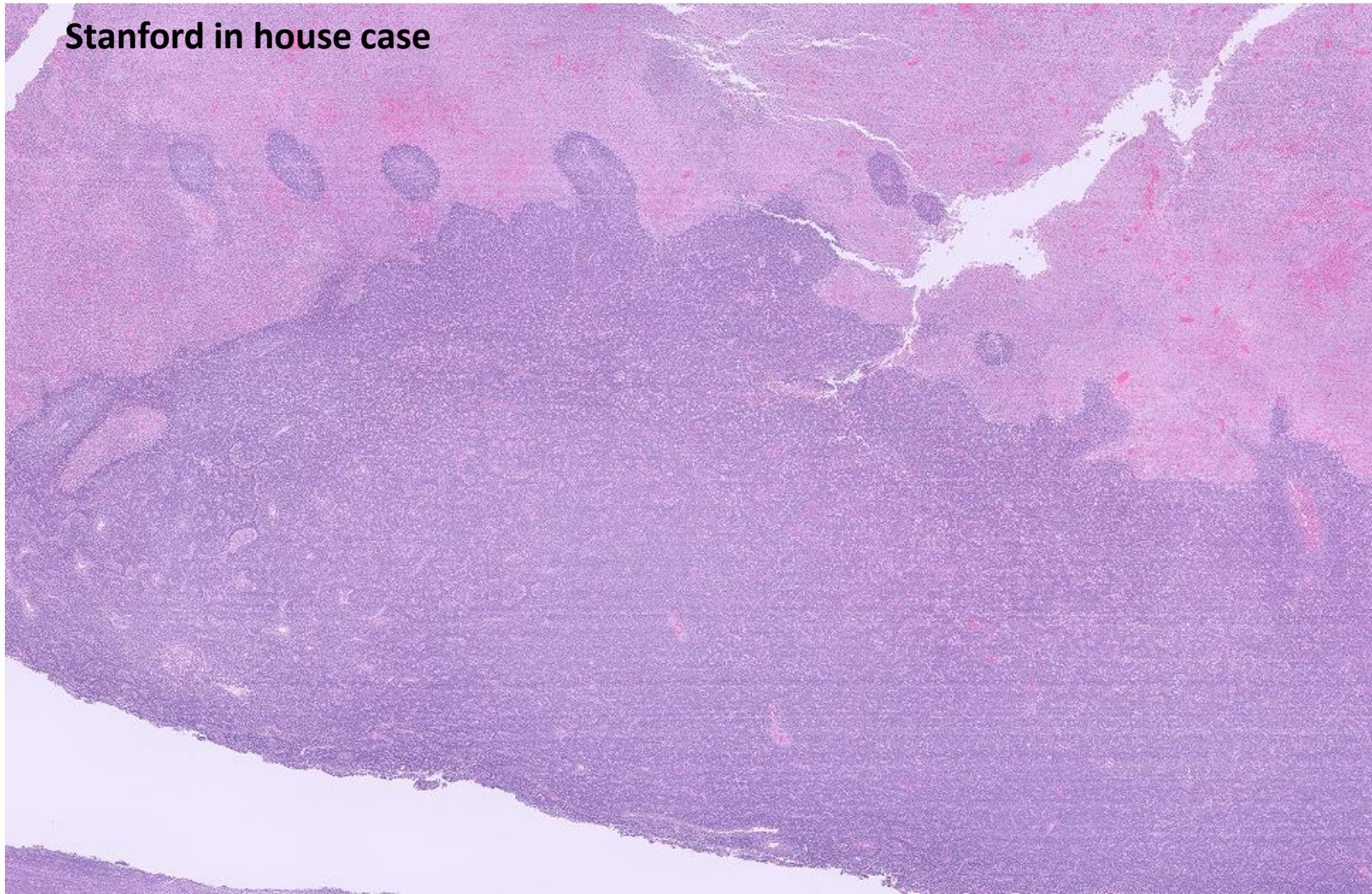

Stanford in house case

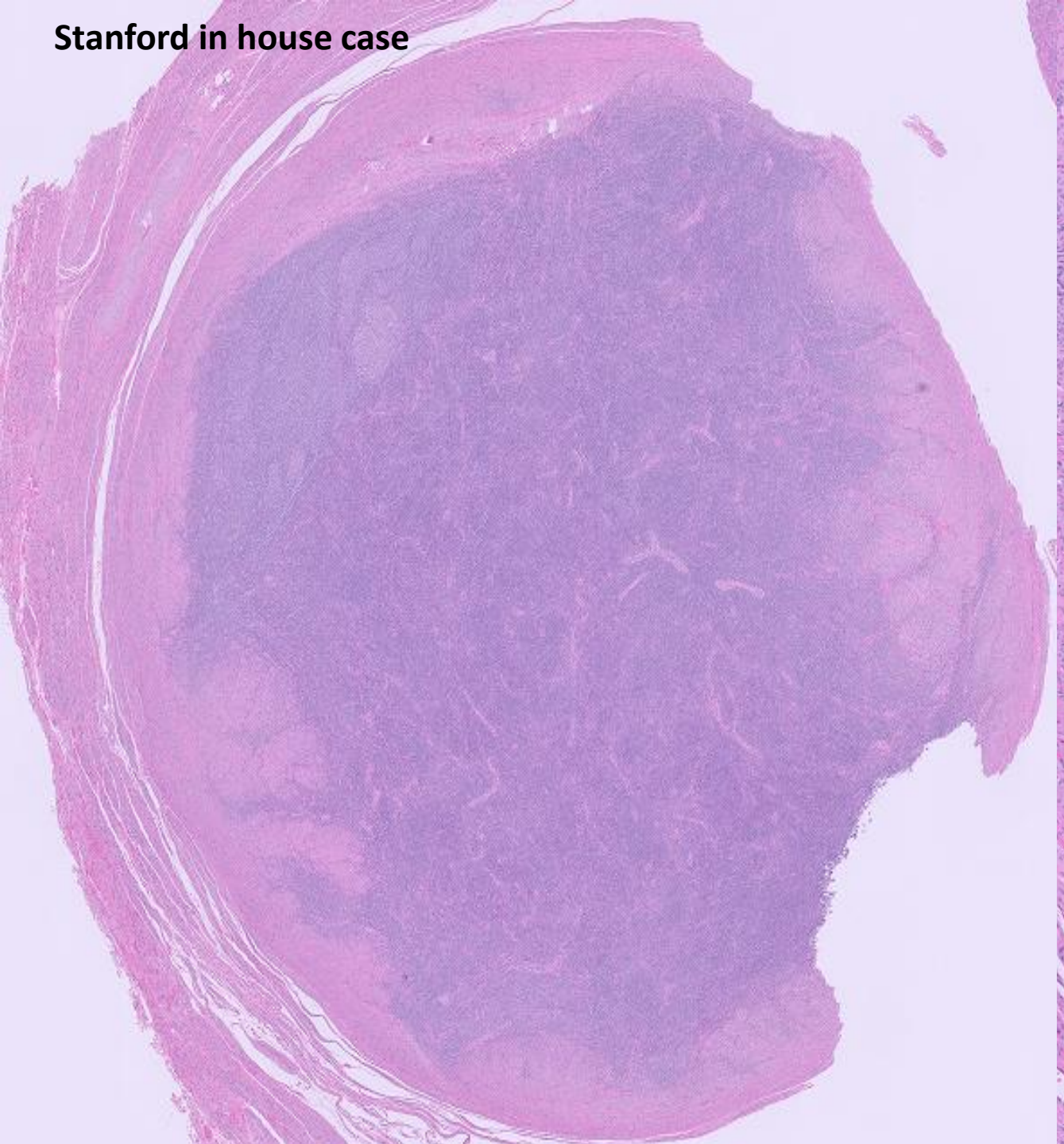

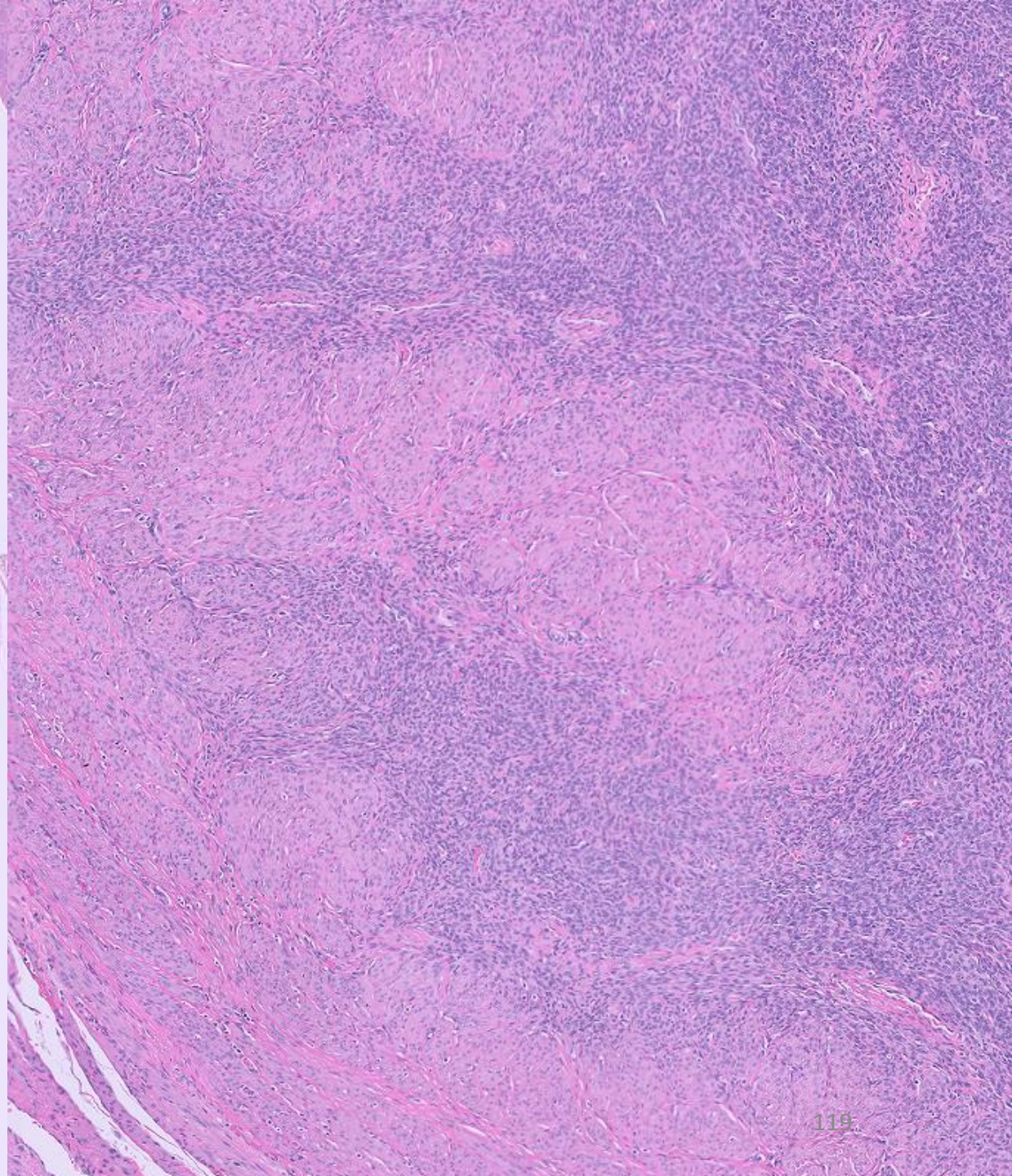

Stanford consult case: Vaginal Cuff lesion: Low-grade endometrial stromal neoplasm with *JAZF1::SUZ12* rearrangement

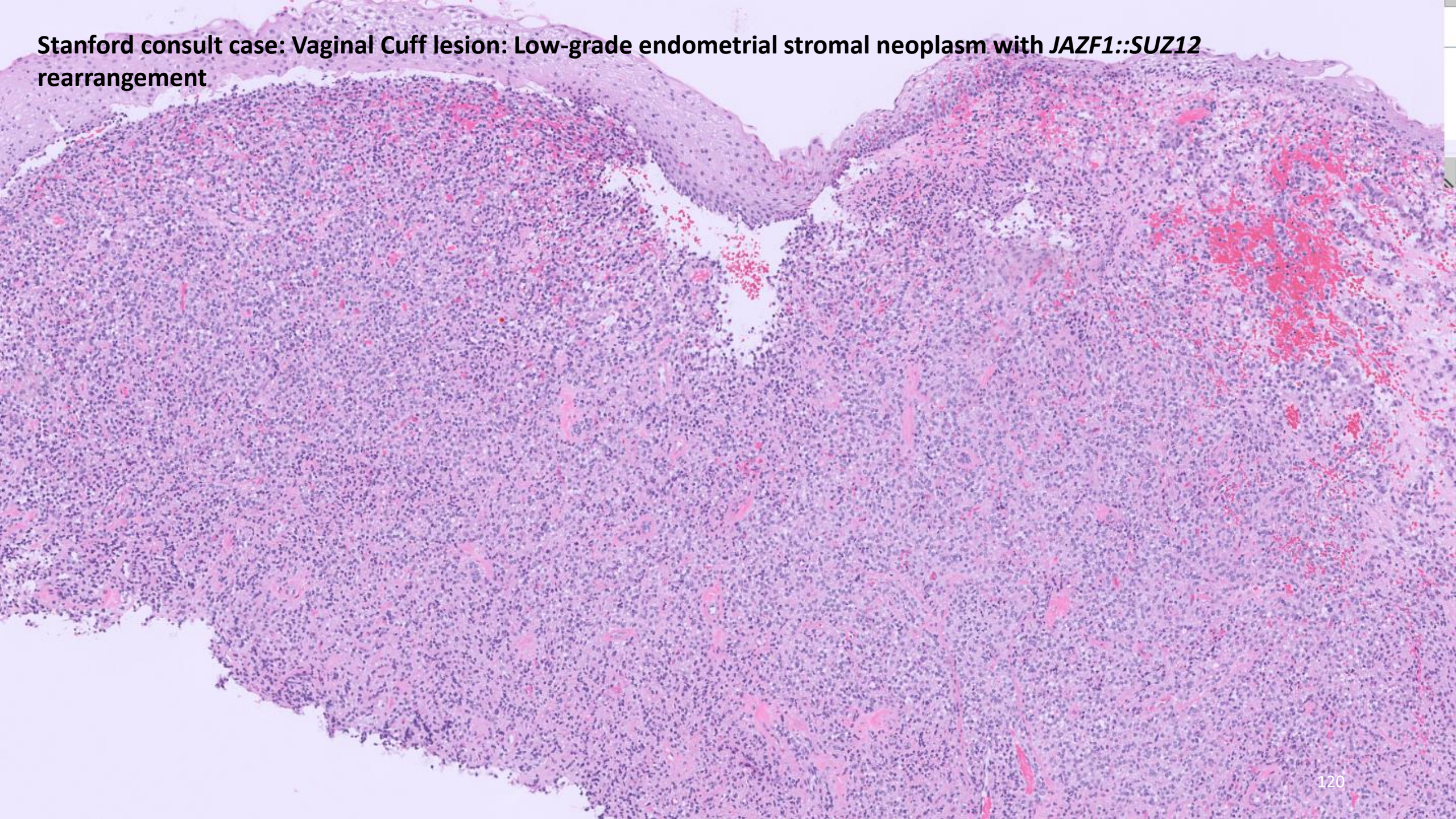

Differential Diagnosis

- **Leiomyosarcoma With Prominent Intravascular Growth**
  - Fleshy with areas of necrosis and hemorrhage
  - Cytologic atypia
  - Brick mitotic activity
  - Destructive invasion into myometrium

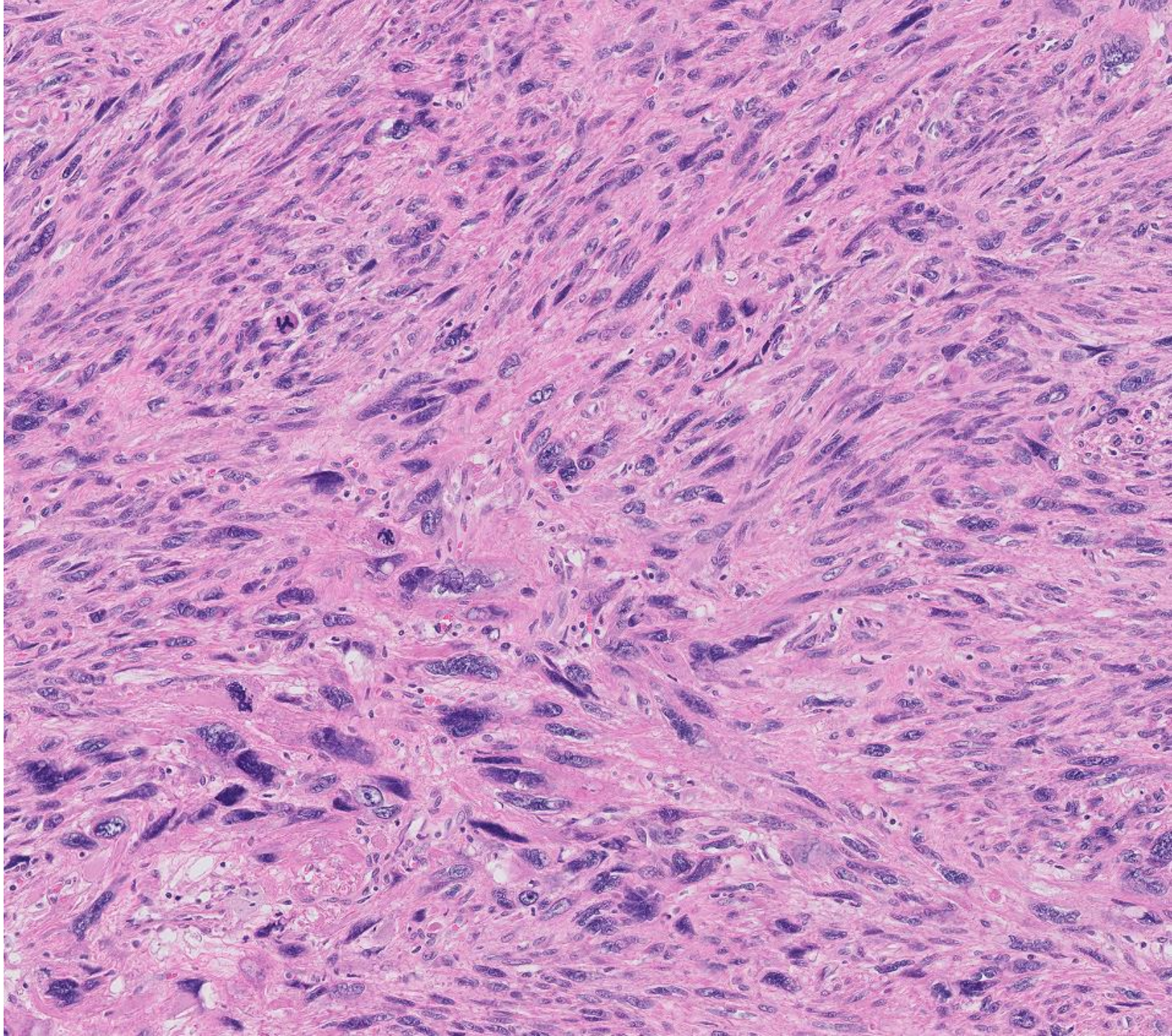

FISH Analysis Result

- **Myometrial nodule**
  - FISH negative for JAZF1 gene rearrangement
  - FISH negative for PHF1 gene rearrangement
  - FISH negative for YWHAE gene rearrangement
  - FISH negative for BCOR gene rearrangement

Diagnosis

- **Uterus, cervix, and bilateral fallopian tubes; total hysterectomy and bilateral salpingectomy**
  - **Myometrium and right parametrium**

    -- Intravenous leiomyomatosis (IVL)

Molecular Finding

- **In one study, recurrent 22q deletions (66%) and complex copy number alterations were detected using array comparative genomic hybridization (aCGH). None of these cases showed the most common MED12 mutation described in UL.**

- **A second study described recurrent 12q14.3 rearrangements by FISH along with *HMGA2* overexpression (58%, n=12) and loss of chromosome 22 in two out of three IVL analyzed by karyotyping.**

- **A third study using RNA sequencing (n=5) detected *HOXA13* as a distinctly upregulated gene in UL when compared to IVL or myometrium.**

- **The fourth study used array comparative genomic hybridization (aCGH) and showed the most common genetic alterations involved 1p (39%), 22q (36%), 2q (29%), 1q (25%), 13q (21%) and 14q (21%).**

25-1007

Maggie Lam; Stanford (Tri-Valley)

48-year-old woman with a right breast mass at 6:00 4 cm from nipple.

Mammogram and ultrasound showed a 1.1 cm mass. MRI showed an oval enhancing mass. No significant past medical history. No family history of breast or ovarian cancer

Right breast mammogram

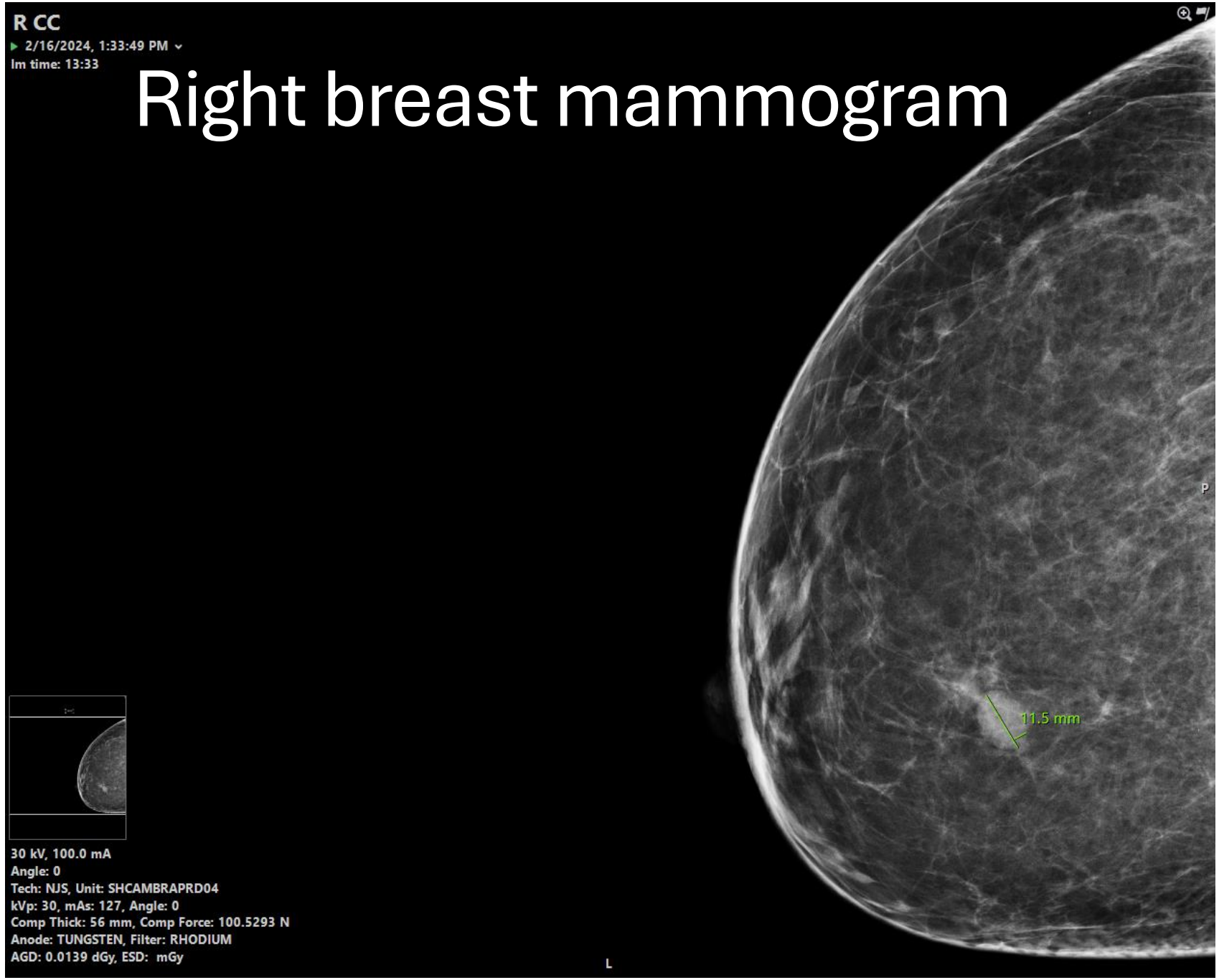

Outside Biopsy

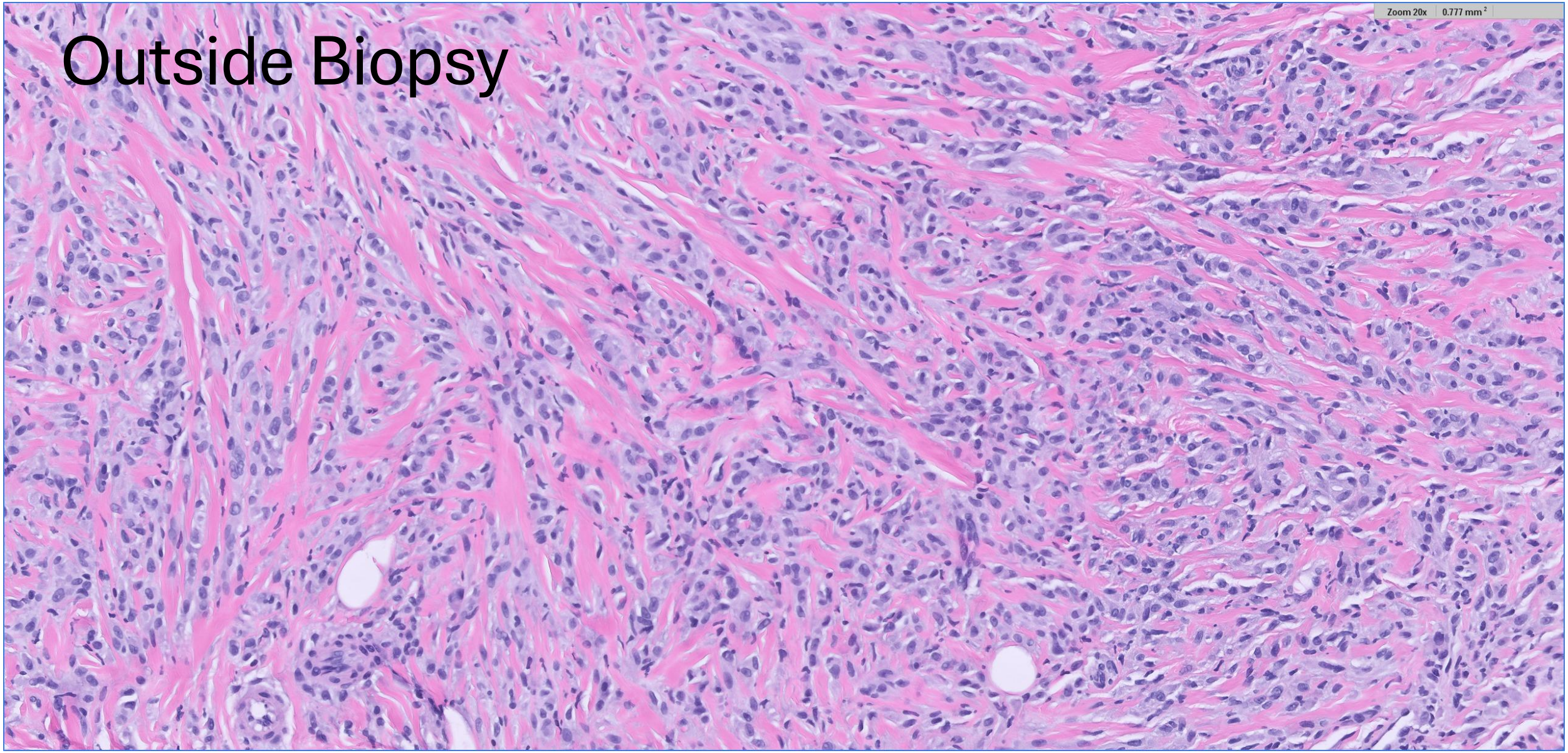

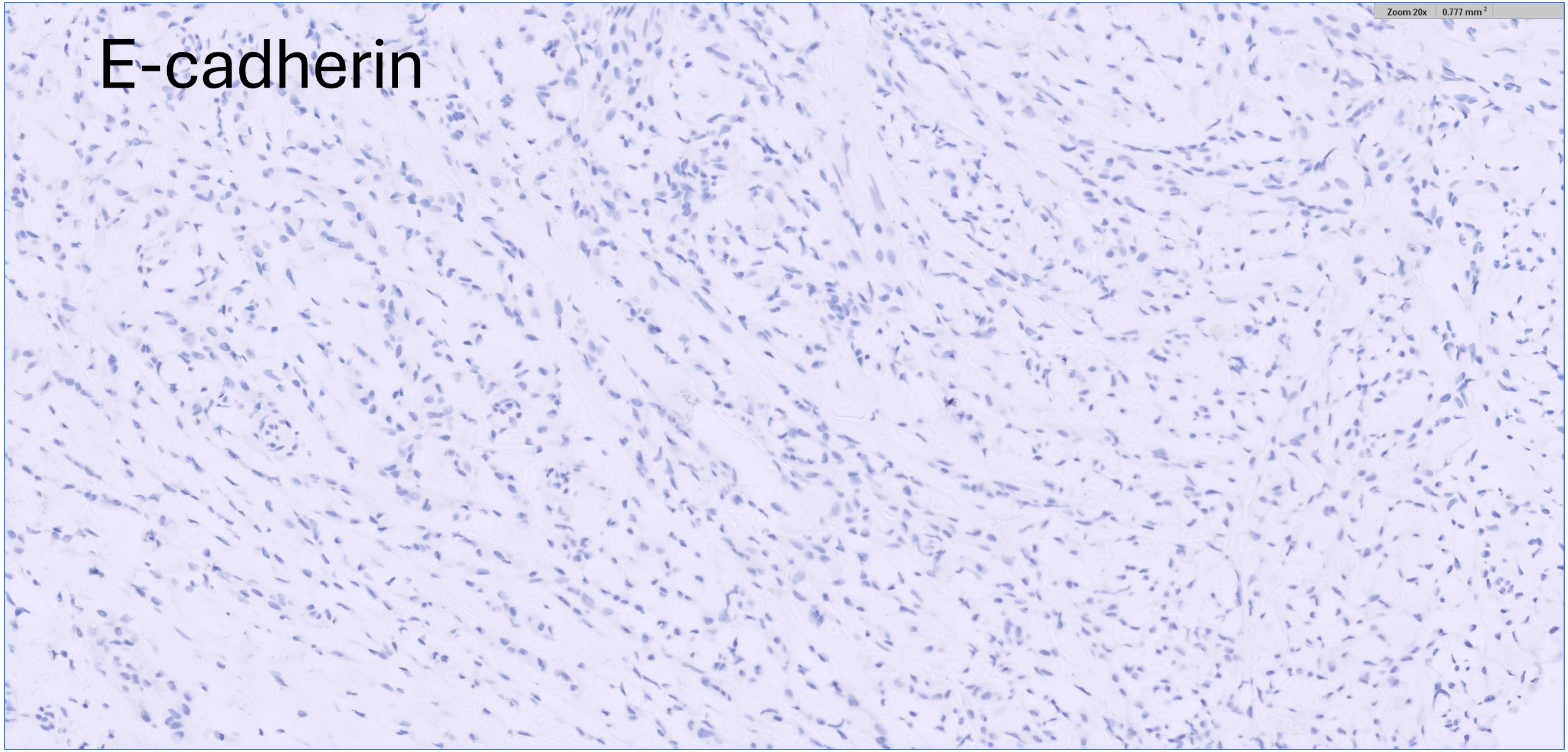
E-cadherin
Zoom 20x
0.777 mm²

Biopsy Diagnosis

- Invasive lobular carcinoma
- Provisional Histologic Grade: 2
  - Tubule formation: 3 out of 3
  - Nuclear grade: 1-2 out of 3
  - Mitotic count: 1 out of 3
  - Total score: 5-6 out of 9

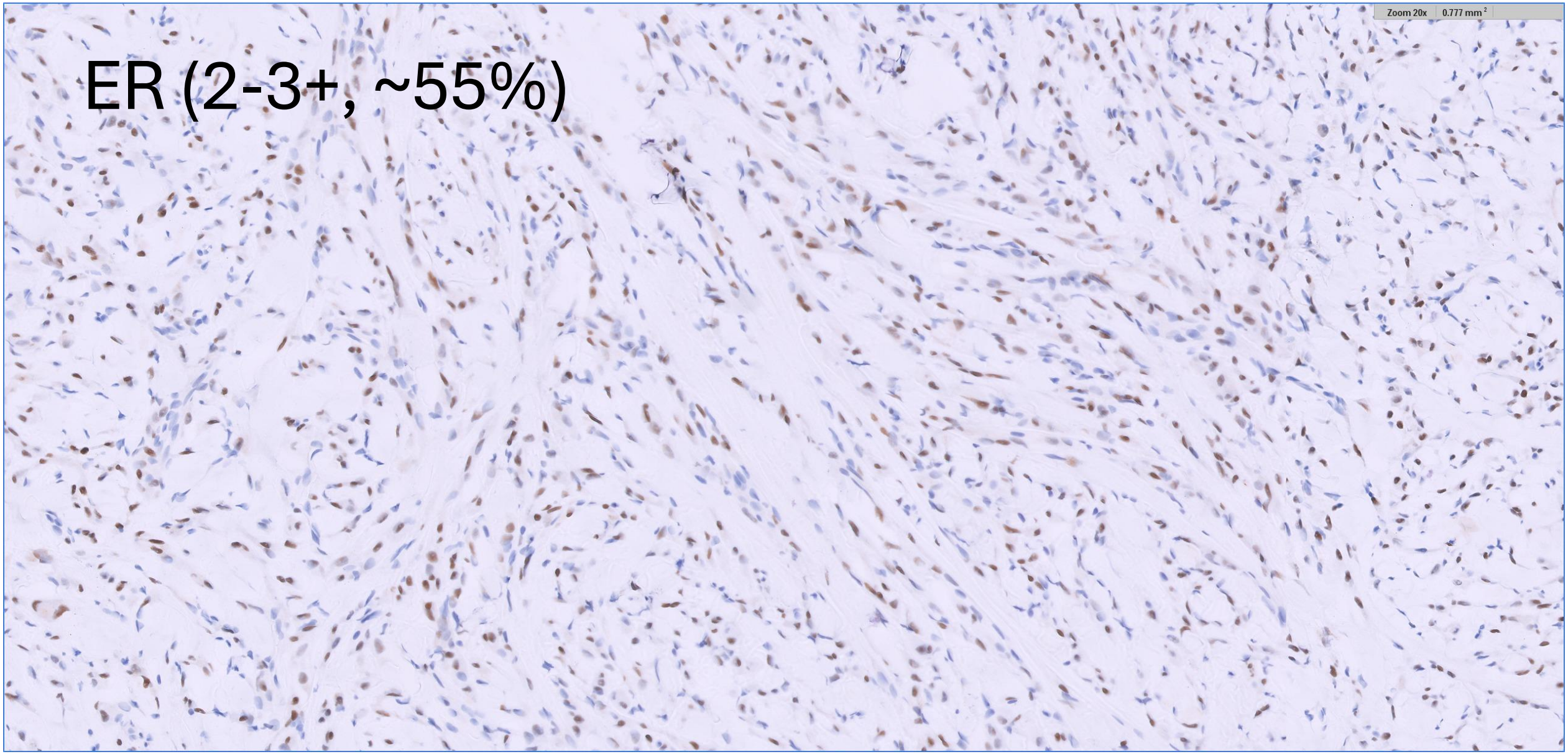
ER (2-3+, ~55%)
Zoom 20x
0.777 mm²

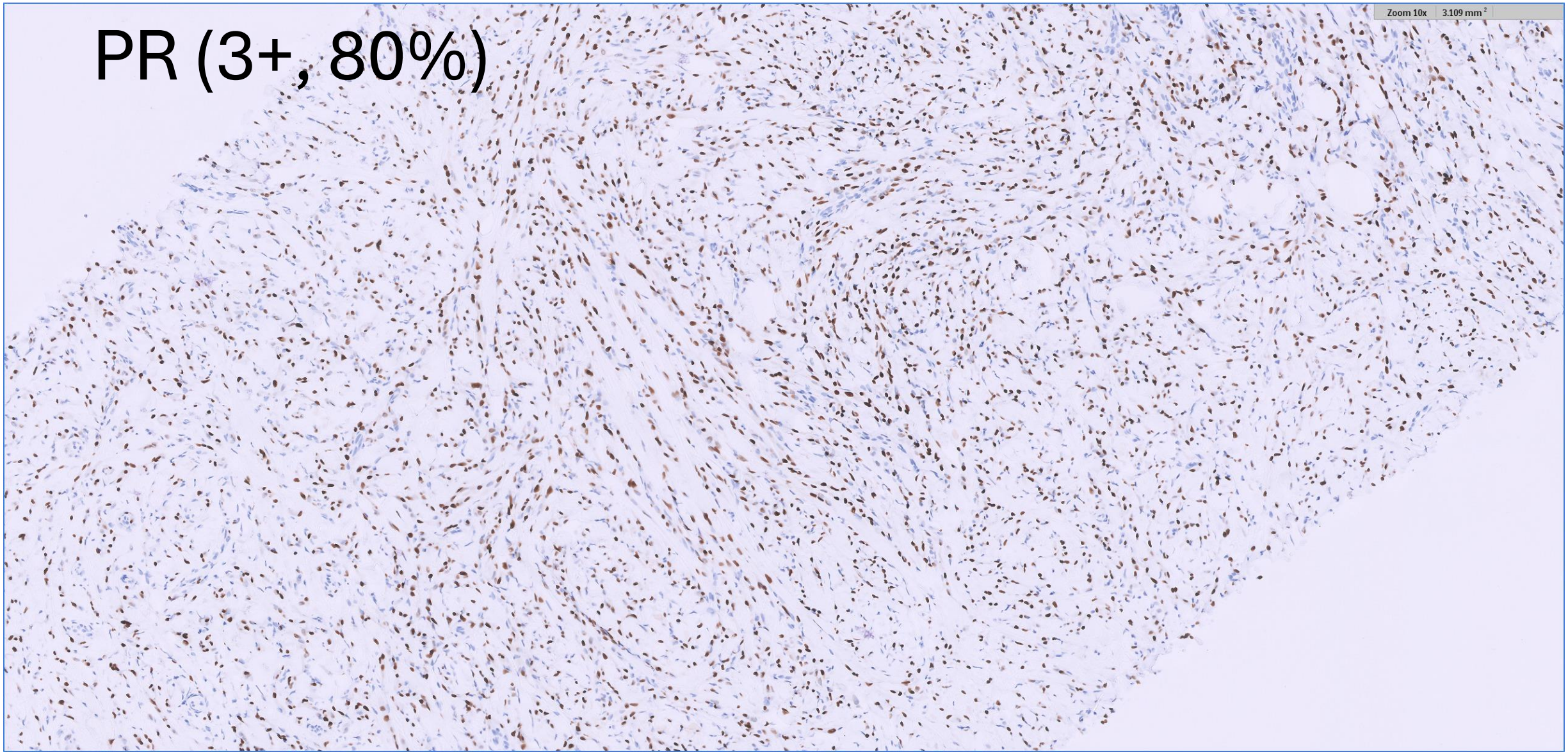
PR (3+, 80%)
Zoom 10x
3.109 mm²

HER2 IHC: Equivocal (2+)

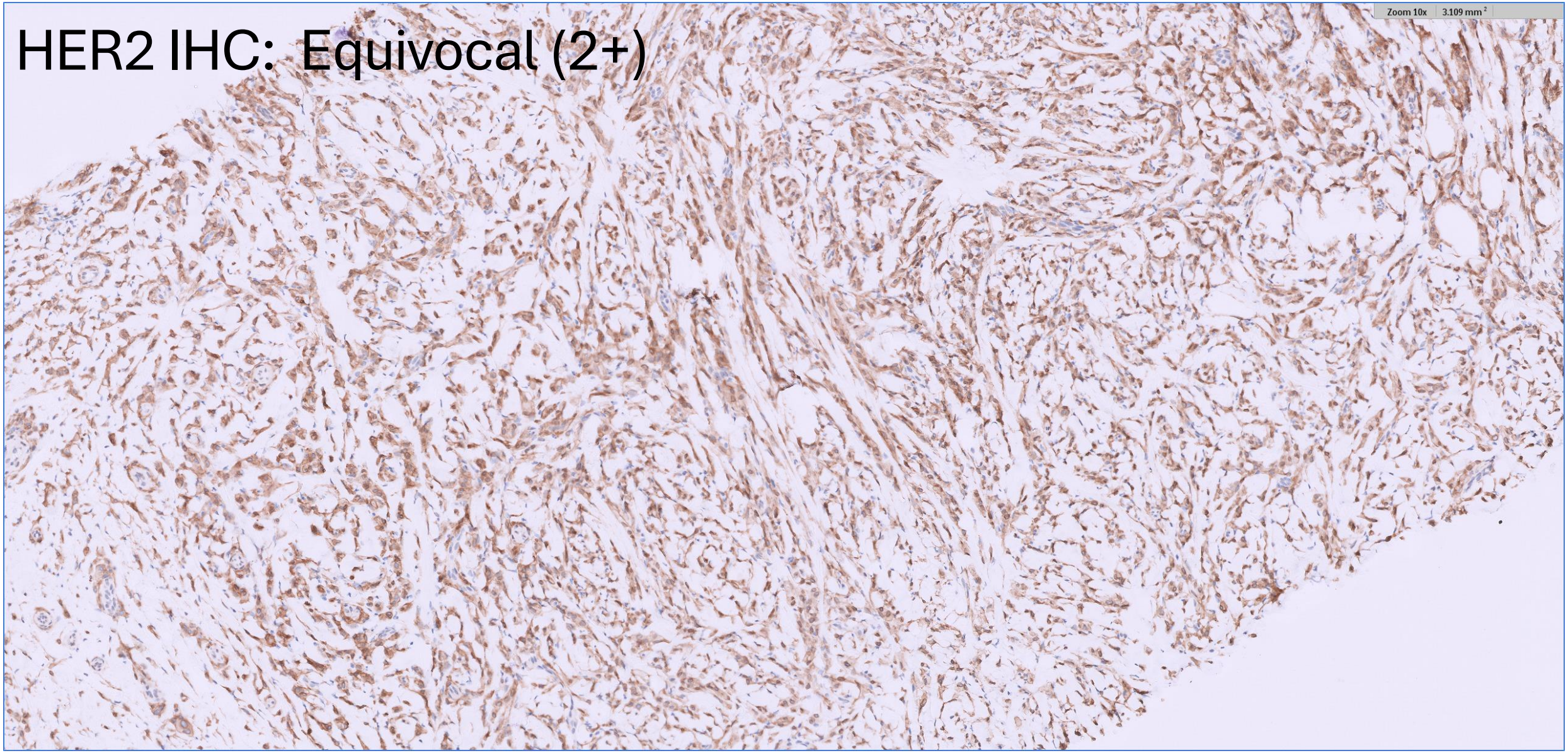

HER2 FISH: Not amplified (Avg HER2 signals: 2.02, Avg CEN 17 signals: 1.92, HER2/CEN17 ratio: 1.05)

Right breast 6:00 lumpectomy

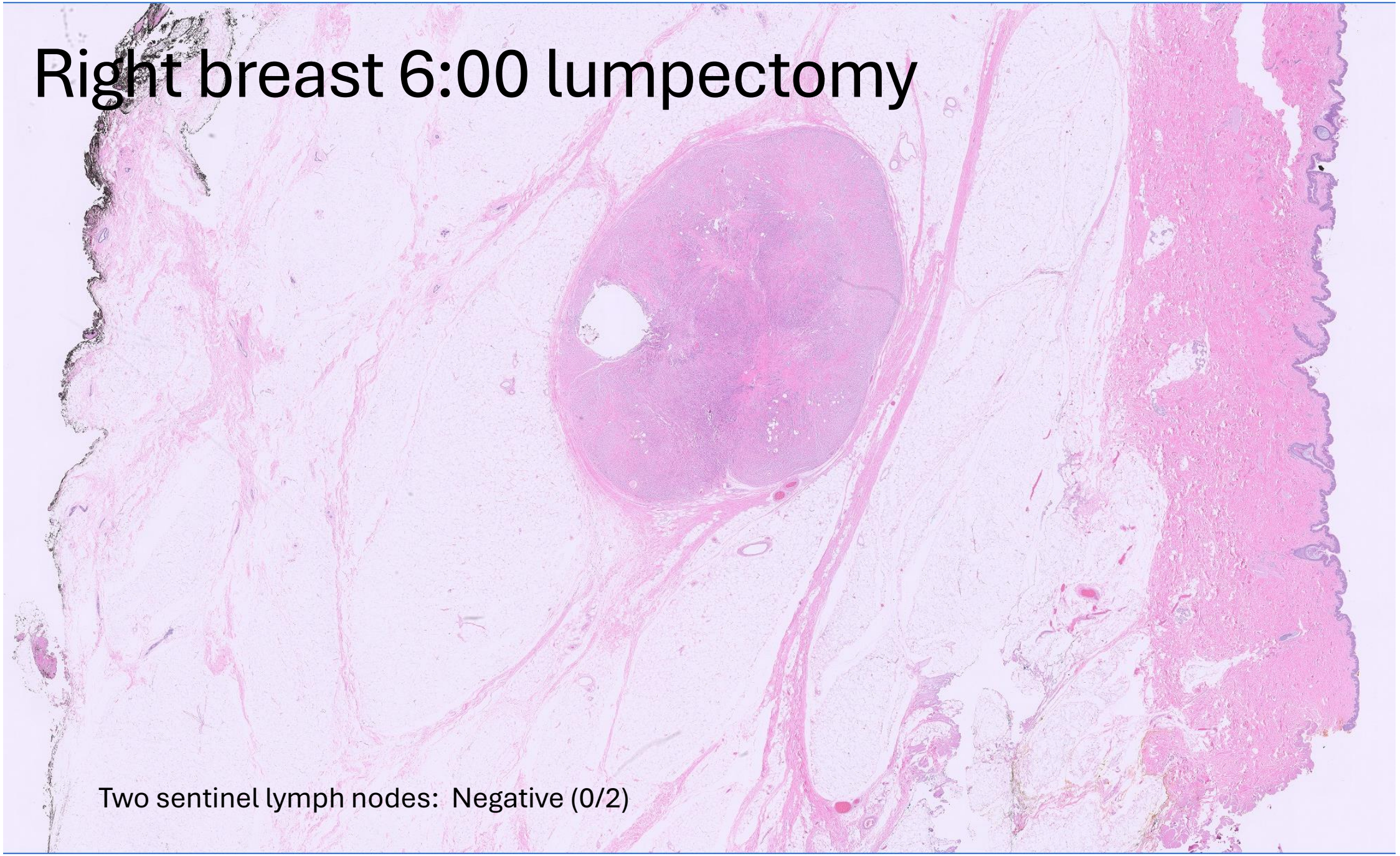

Two sentinel lymph nodes: Negative (0/2)

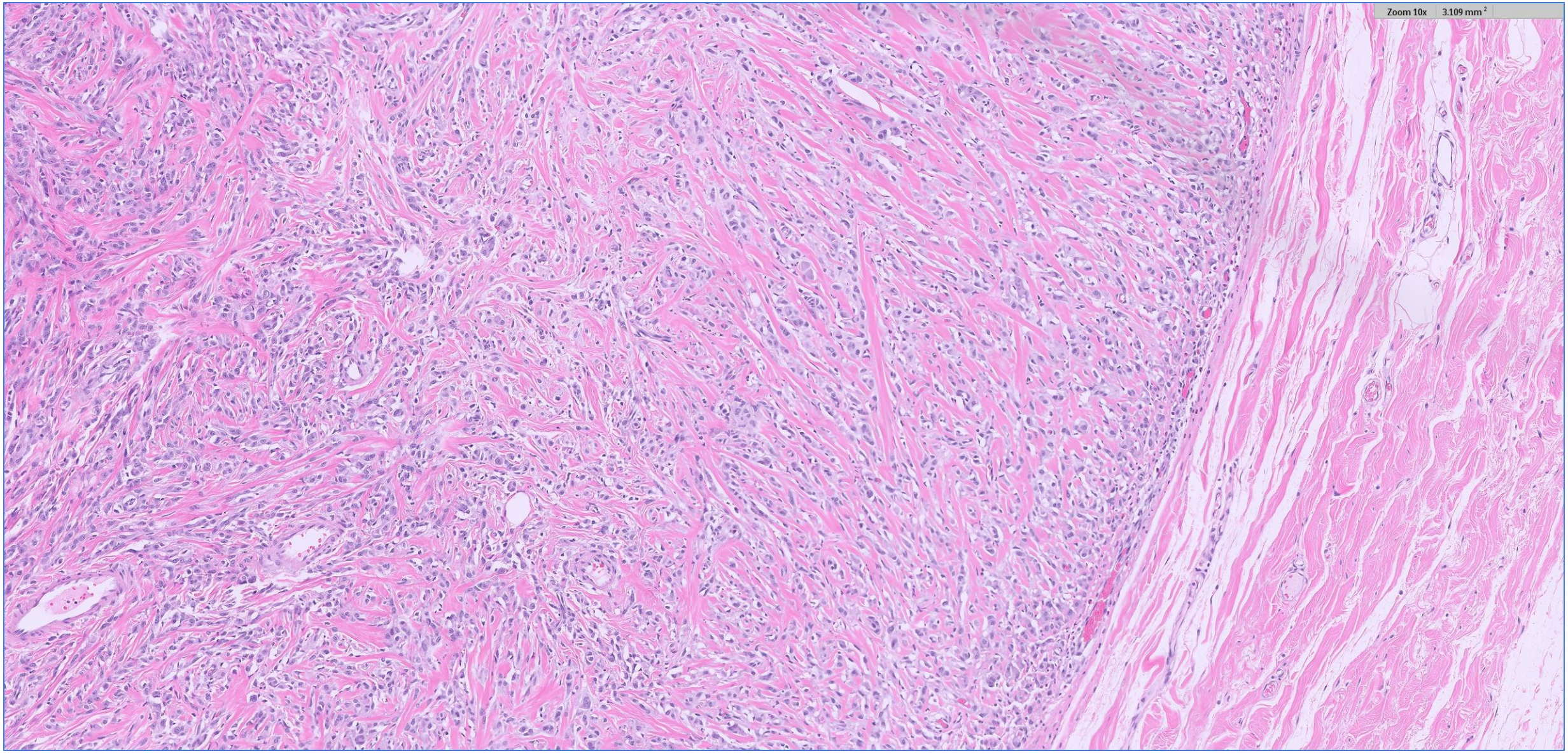
Zoom 10x
3.109 mm 2

DIAGNOSIS?

Keratin mix (AE1/AE3 & cam5.2)



CK5/6, keratin 34betaE12, CK7, p63 negative

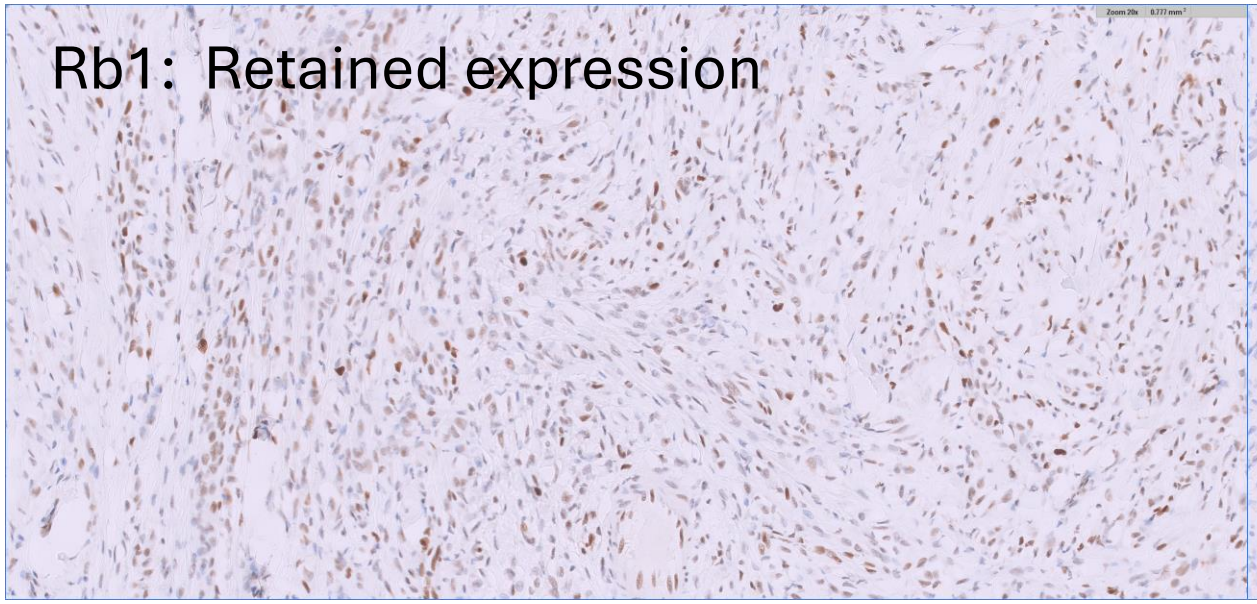

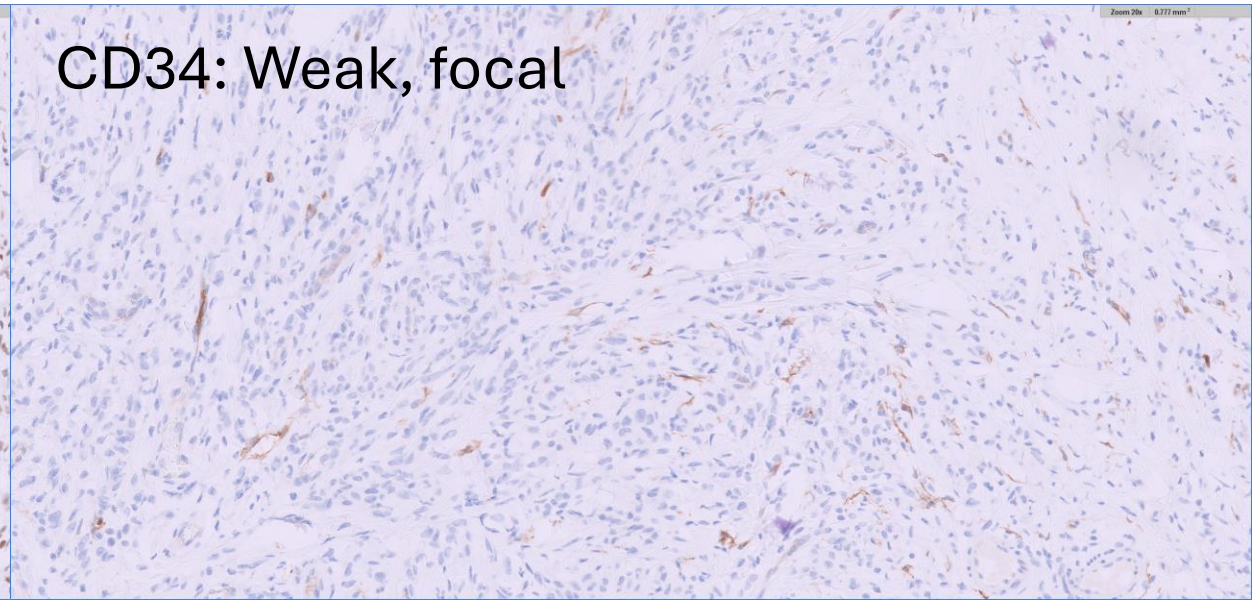

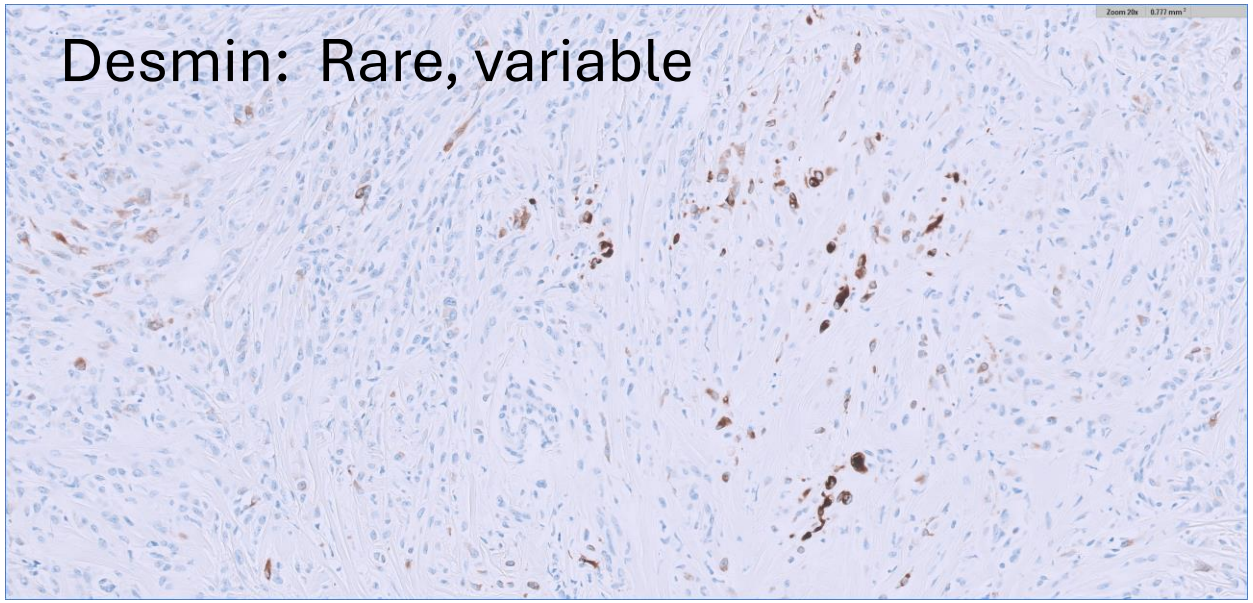

Repeat:
ER: Positive (50%, 1–2+)
PR: Positive (50%, 3+)

Additional Immunostains/Studies

- ALK, S100, SOX10, STAT6, SMA, and caldesmon negative
- Beta catenin: Negative nuclear staining
  - Excludes inflammatory myofibroblastic tumor, epithelioid schwannoma (or other neural neoplasm), melanoma, solitary fibrous tumor, leiomyoma, and fibromatosis
- Stanford Actionable Mutation Panel for Solid Tumors (STAMP): No variants detected

Diagnosis: Epithelioid Myofibroblastoma

- Classic morphology, ER expression, and absence of immunohistochemical support for any other diagnostic considerations, make the findings most consistent with an epithelioid myofibroblastoma
- Rare, benign tumors of mammary stromal fibroblasts and myofibroblasts
- Cured with excision and have no tendency to recur (1)
- Diffuse, strong CD34 expression classically described, but can uncommonly show absent or focal CD34 staining (2)
- Many harbor deletion of RB1 (13q14) by FISH, but deletion is not always reflected by loss of Rb1 protein by IHC (2)
- Variants of myofibroblastomas, particularly epithelioid type, can closely mimic invasive carcinoma
  - Misinterpretation as invasive lobular carcinoma is a diagnostic pitfall.
  - Cords and singly dispersed epithelioid cells with interlacing fibrous stroma creates a pseudoinfiltrative appearance
  - Jing et al: >40% of epithelioid myofibroblastoma cases initially misinterpreted as invasive carcinoma, especially as invasive lobular carcinoma (3)

25-1008

Nivaz Brar, John Higgins; Stanford

66-year-old male, with a history of hyperlipidemia presents with subacute fevers, nausea/vomiting, headaches, liver injury and found to be pancytopenia and raising concern for possible HLH.

Lab values

Test	Result
WBC	2.4 K/uL (L)
Hemoglobin	12.6 g/dL (L)
Hematocrit	37.3 % (L)
Platelet Count	119 K/uL (L)
MCV	88.0 fL
RDW	14.8 % (H)
RBC	4.24 MIL/uL (L)
MCH	29.7
MCHC	33.8
Triglyceride, Ser/Plas	374 mg/dL (H)
Bilirubin Total	13.0 mg/dL (H)
AST	581 U/L (H)
ALT	1,514 U/L (H)
Alk P'TASE, Total, Ser/Plas	258 U/L (H)

Additional lab findings:

Test	Result
C-Reactive Protein	2.6 (H)
IgA, Serum	Not provided
IgG, Serum	768
IgG, Serum (second value)	768
Mitochondrial Antibody, M2	<0.1 (Negative)
Liv-Kid-Microsome Ab	<1:20
Soluble IL 2R	8612.6 (H)
Anti-Smooth Muscle Antibody	Negative
Interleukin-6	37 (H)
Rheumatoid Factor	Negative
ANA Result	Negative
A-1-A ANTITRYPSIN PHENOTYPE	MM (normal)
Alpha-1-Antitrypsin	170

Infectious labs all negative except for EBV IgG and CMV IgG.

CT Abdomen/Pelvis Findings:

1. Stranding within the porta hepatis surrounding the cystic duct, common hepatic duct, and extending inferior around the second portion of the duodenum. Mild hyperemia of the gallbladder and cystic duct. Findings could reflect cholangitis or possibly duodenitis, with groove pancreatitis considered less likely.
2. No biliary obstruction or radiopaque cholelithiasis. No gallbladder dilation to suggest cholecystitis.

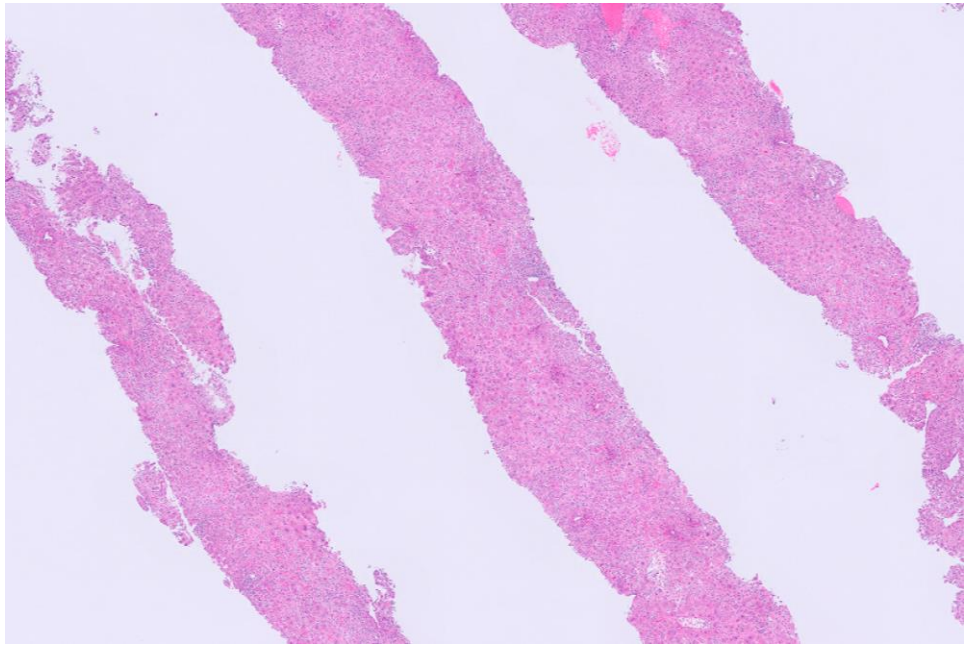

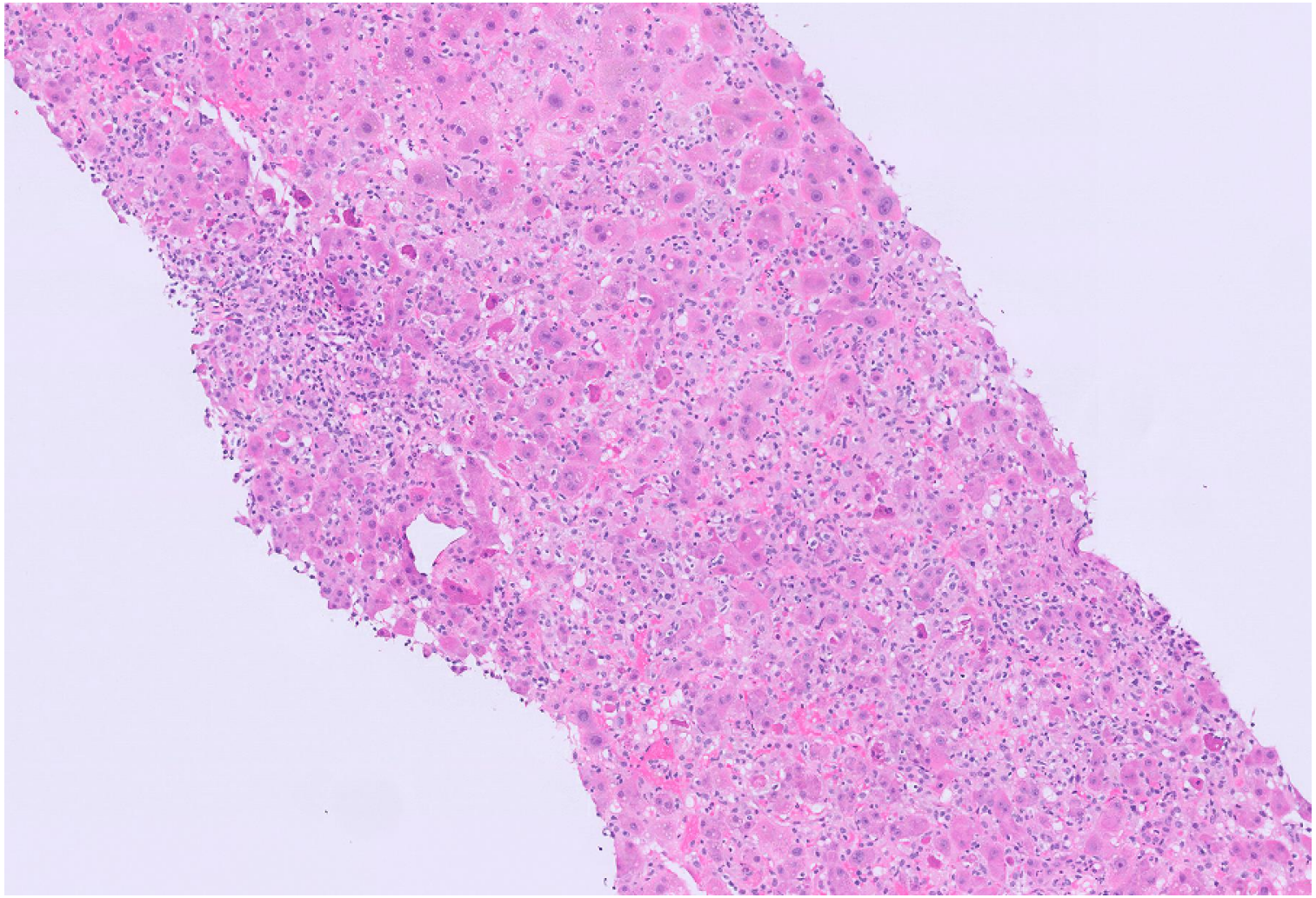

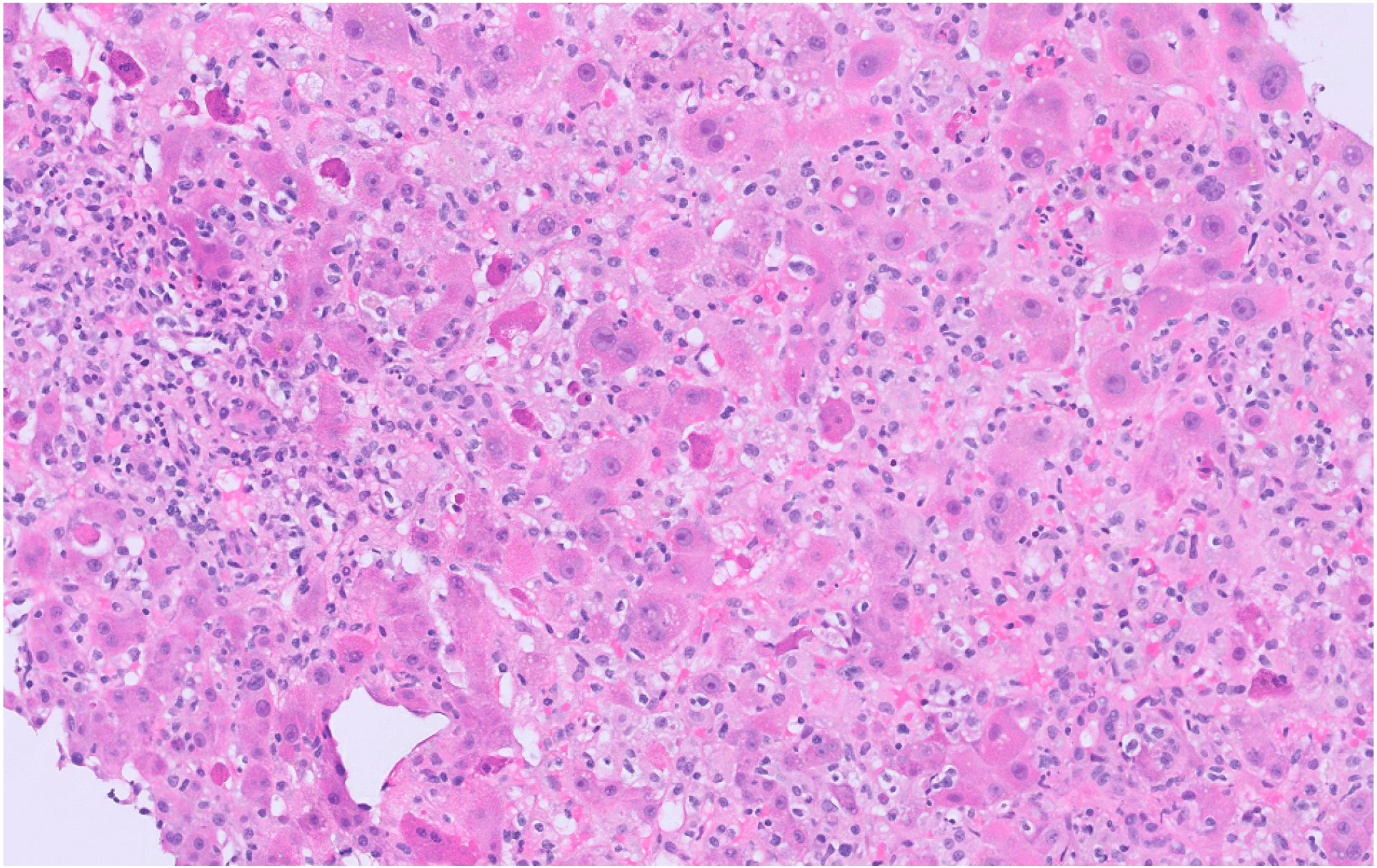

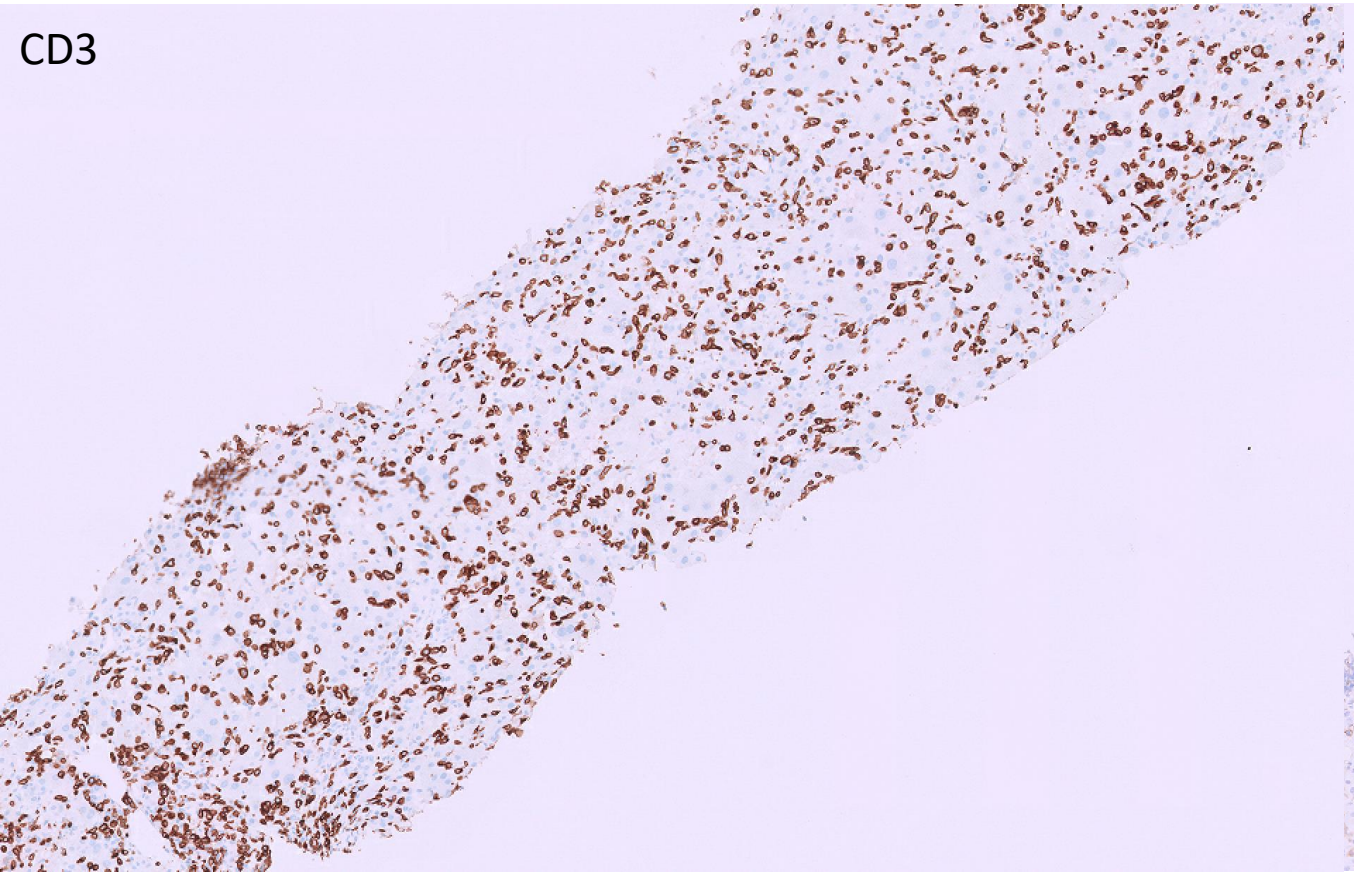
CD3

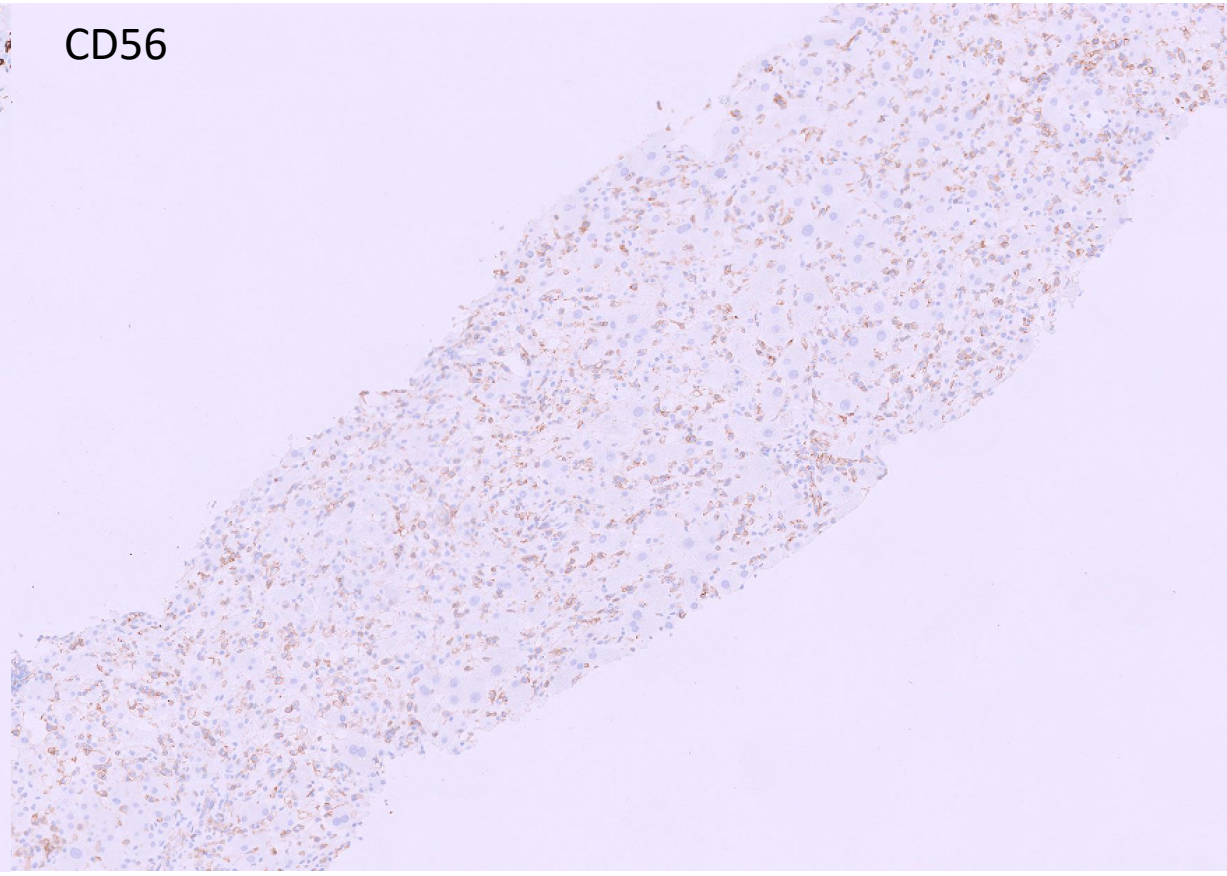
CD56

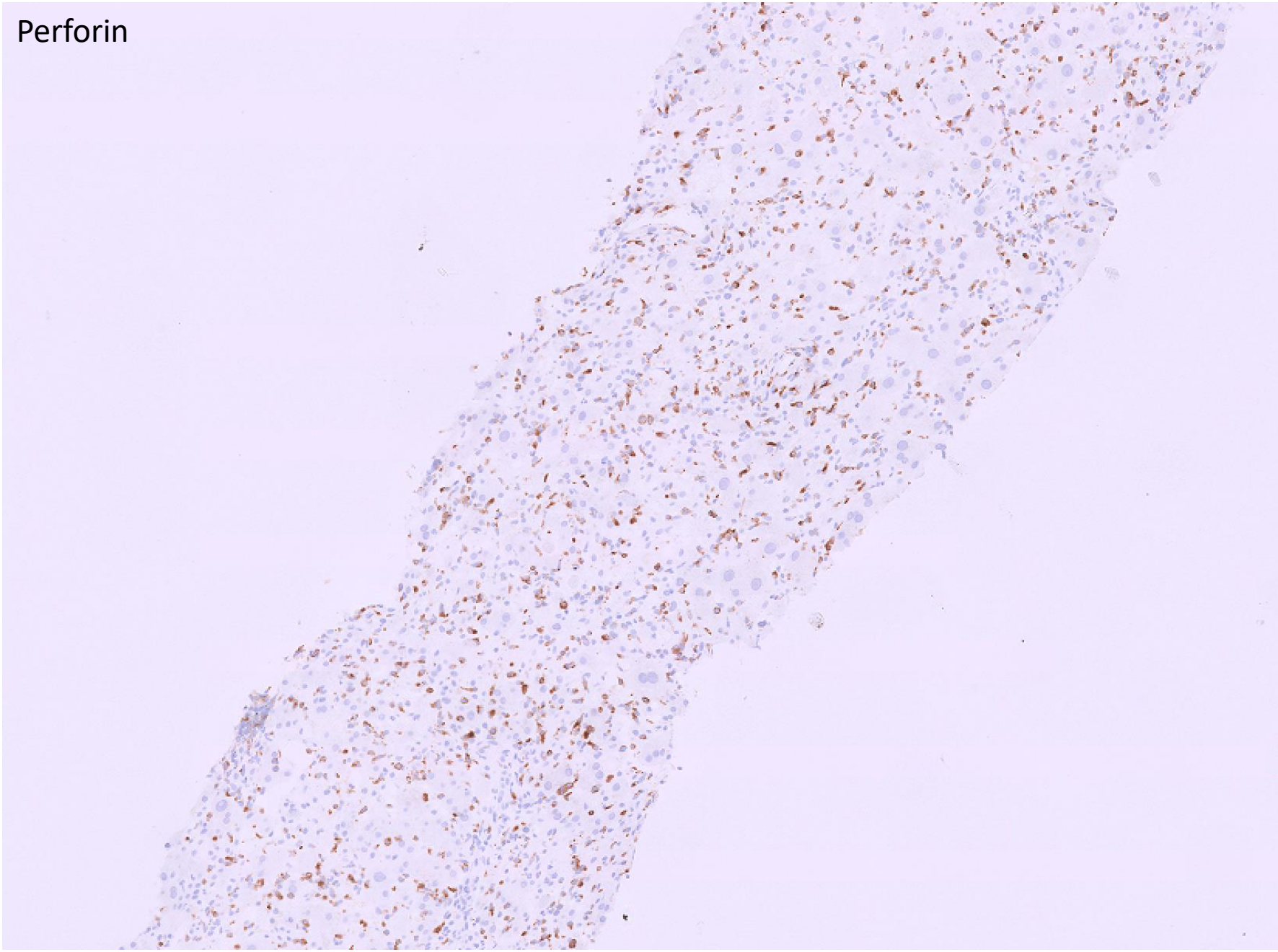
Perforin

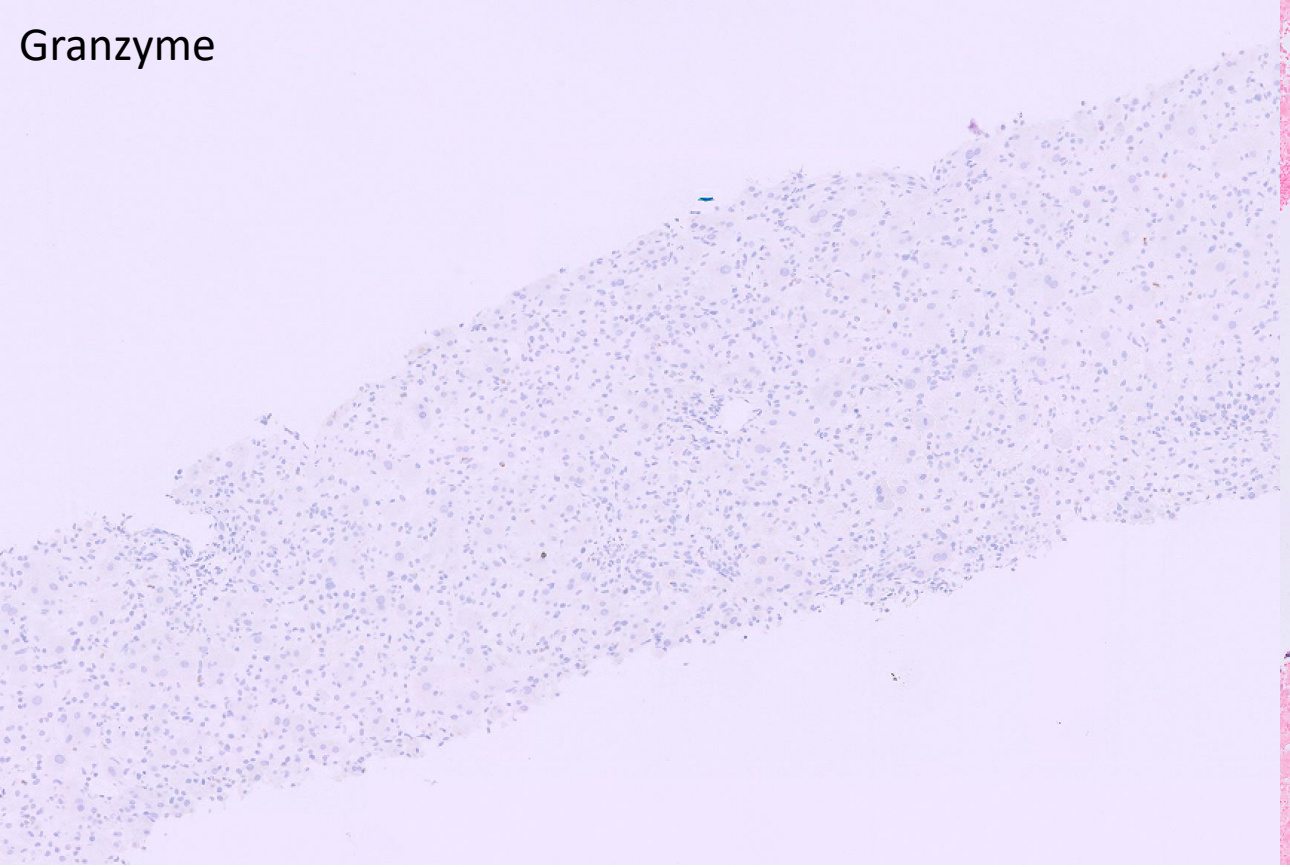
Granzyme

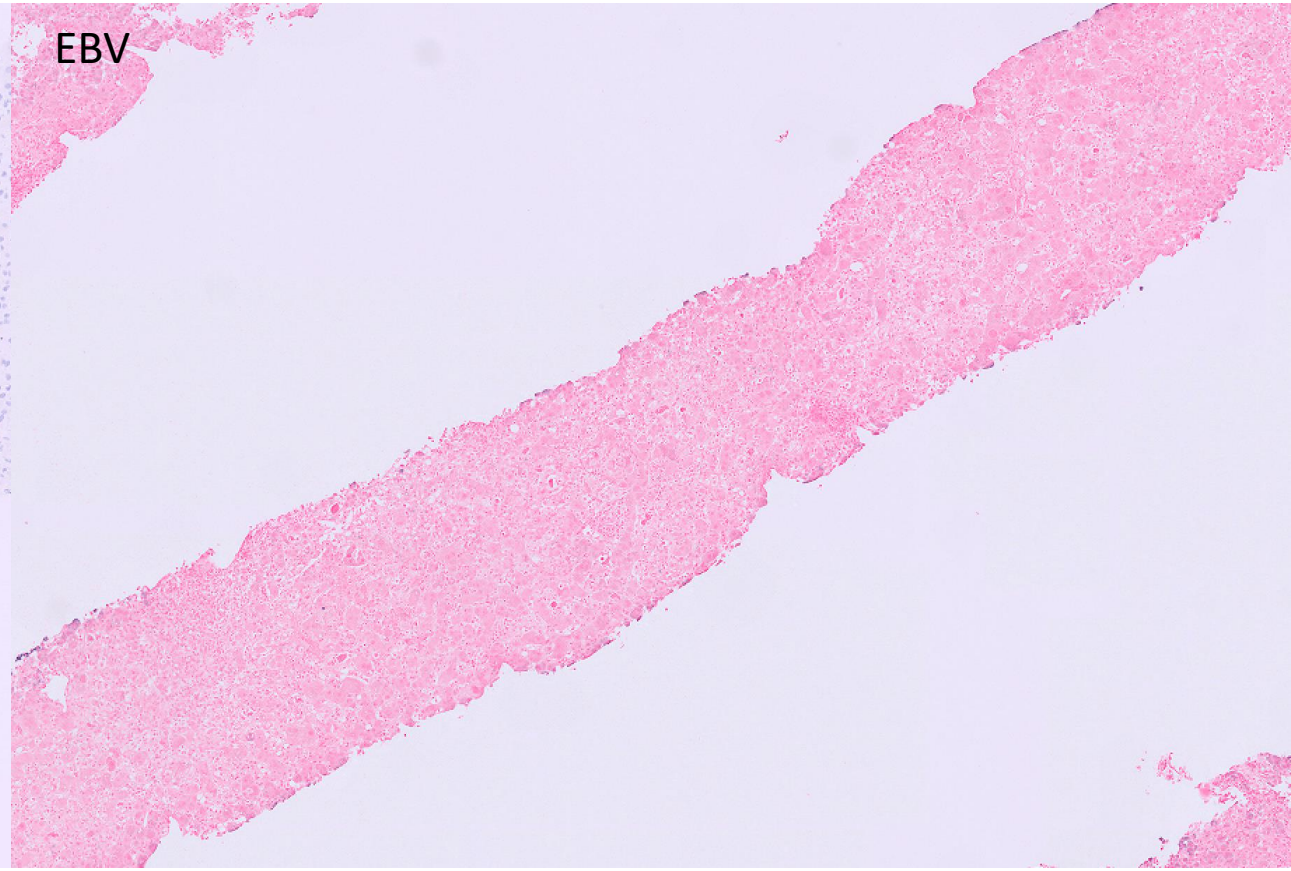
EBV

DIAGNOSIS?

Differential diagnosis?

- Hepatosplenic T-cell lymphoma
- Aggressive NK
- Extranodal NK T-cell lymphoma
- T-large granular lymphocytic leukemia (T-LGLL)

Molecular findings

- Karyotype: 26~29,inc[cp8]/46,XY[13]
  - 8/21 metaphases analyzed with a near haploid karyotype of 26 to 29 chromosomes with numerous aneuploidies, structural anomalies and marker chromosomes
    - Negative for isochromosome 7q or trisomy 8
- HEME-STAMP mutational analysis:
  - TP53 (VAF 10%) and STAT5B (VAF 4%)
  - T-cell clonality by next-generation sequencing showed both TCR-gamma (*TRG*) and TCR-beta (*TRB*) gene rearrangements.

Flow cytometry

- **Cerebrospinal fluid, flow cytometry immunophenotyping**
  - Abnormal NK cell population with high forward scatter, 13.1% of lymphocytes and 6.4% of CD45+ events, expressing CD7 (bright), CD56 (bright), cytoplasmic CD3, CD8 (dim), and CD45, and not expressing CD2, CD5, CD4, CD16, cTCR g/d, cTRBC1, or cTRBC2
  - CD3+ T lymphocytes without immunophenotypic abnormality

Aggressive NK-cell lymphoma

- Most cases are EBV positive (90%) and associated with HLH
- **Essential criteria**: fever, constitutional symptoms, systemic involvement, leukemic, and absence of T-cell receptor protein expression and/or clonal TR rearrangement.

Extranodal NK T-cell lymphoma:

- ENKTL usually seen with necrosis and is angiodestructive.
- Essential criteria: Majority of cells positive for EBV.

Case correlation: Exclusion of ANKL based on *TRG* and/or *TRB* gene rearrangements, however, non-neoplastic NK-cells can show *TRG* gene rearrangements

Hepatosplenic T-cell lymphoma

- Sinusoidal infiltrate in the liver
- Clinically presents with hepatomegaly and splenomegaly
- Isochromosome 7q; trisomy 8
- Usually EBER negative
- Commonly associated with immune dysregulation and Crohn's disease
- **Case correlation:**
  - Bone marrow shows tumor cells negative for TCR beta and delta
  - Given the TCR-gamma (*TRG*) and TCR-beta (*TRB*) gene rearrangements "TCR-silent" HSTCL was considered
  - Patient had no hepatomegaly or splenomegaly

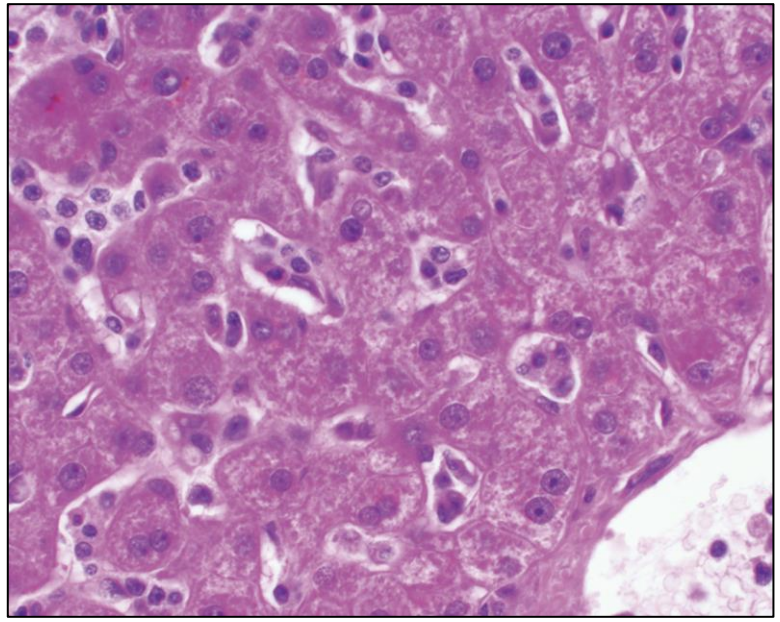

Final diagnosis:

***Favor aggressive NK/T-cell leukemia*, EBV-negative**

Am J Surg Pathol. Author manuscript; available in PMC: 2018 Jan 1.

Published in final edited form as: Am J Surg Pathol. 2017 Jan;41(1):67–74. doi: 10.1097/PAS.0000000000000735

EBV-Negative Aggressive NK-Cell Leukemia/Lymphoma: Clinical, Pathological and Genetic Features

Alina Nicolae [1], Karthik A Ganapathi [1], Trinh Hoc-Tran [1], Xi Liqiang [1], Carlos A Torres-Cabala [2], Nahid M Nanaji [3], Hongbin D Zha [4], Zhen Fan [5], Sybil Irwin [6], Stefania Pittaluga [1], Mark Raffeld [1], Elaine S Jaffe [1]

- Review of 7 patients with EBV negative ANKTL
- Immunophenotype: positive for CD56 (7/7), CD2 (5/5), CD8 (3/7), CD30 (4/5) and Granzyme B (6/6), and negative for surface CD3, CD4, CD5, Beta F1, TCRγ, LMP1 and EBER
- Associated with complex karyotype with unbalanced chromosomal abnormalities
- 4 cases with sufficient DNA showed polyclonal TCR-gamma rearrangements
- 2 cases with a custom NGS panel were positive for STAT3 mutations
- Slightly better prognosis than EBV+ ANKTL