

FEB 2020 DIAGNOSIS LIST

20-0201: clear cell carcinoma (urethra/GU pathology)

20-0202: renal cell carcinoma with leiomyomatous stroma, TSC1 mutated (kidney/GU pathology)

20-0203: necrotizing myopathy, favored secondary to PD1 inhibitor (muscle/neuropathology)

20-0204: NTRK fusion sarcoma (cervix/GYN pathology)

20-0205: leiomyoma with fumarate hydratase deficiency morphology (uterus/GYN pathology)

20-0206: follicular lymphoma with features suspicious for histiocytic sarcoma (lymph node/hematopathology)

20-0207: lymphoepithelioma-like carcinoma (bladder/GU pathology)

20-0208: primary melanoma (bladder/GU pathology)

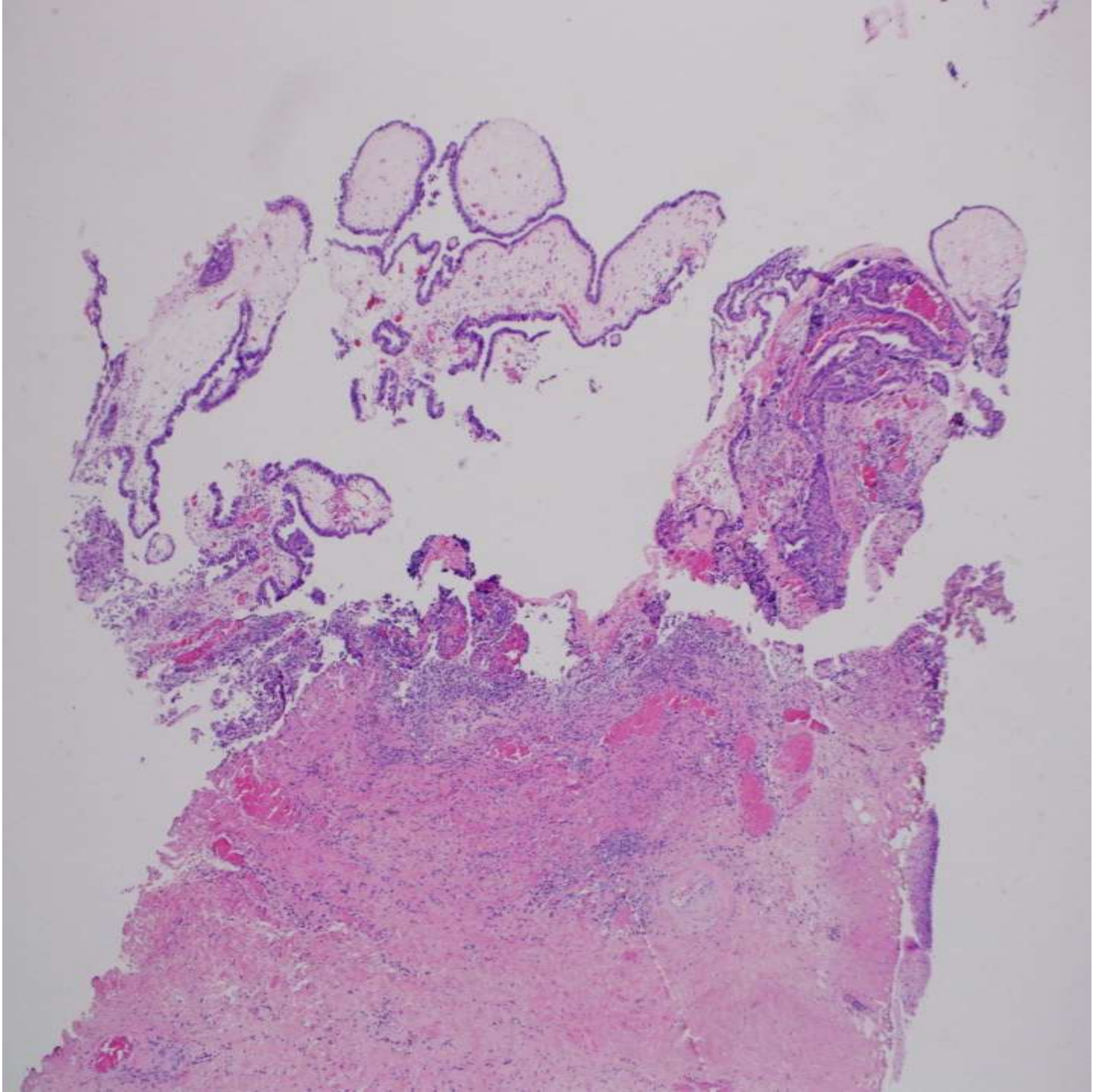
20-0209: low grade fibromyxoid sarcoma, DOG1+ (soft tissue/soft tissue pathology)

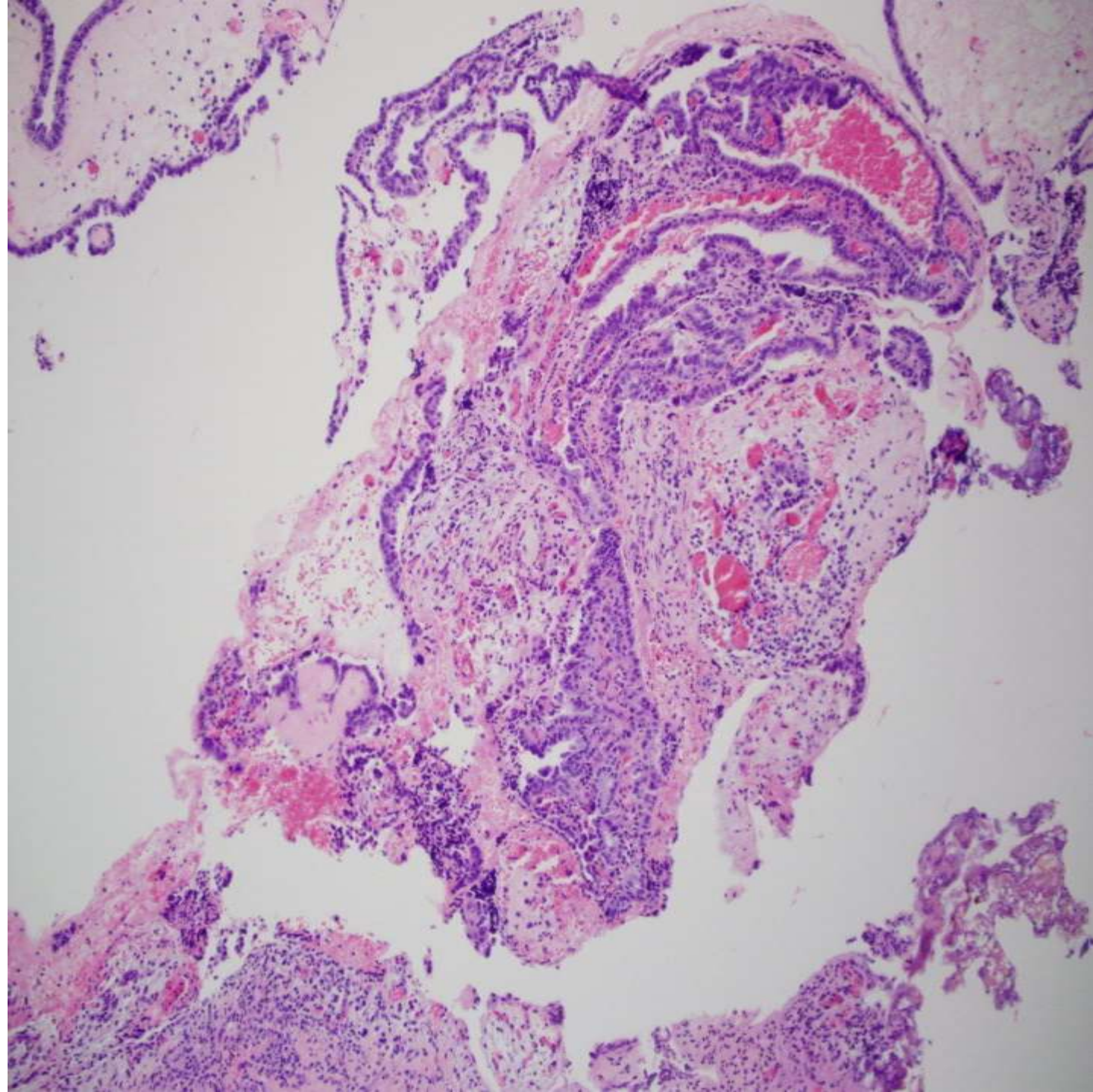
20-0210: CD8 positive cutaneous T-cell lymphoma (skin/dermatopathology & hematopathology)

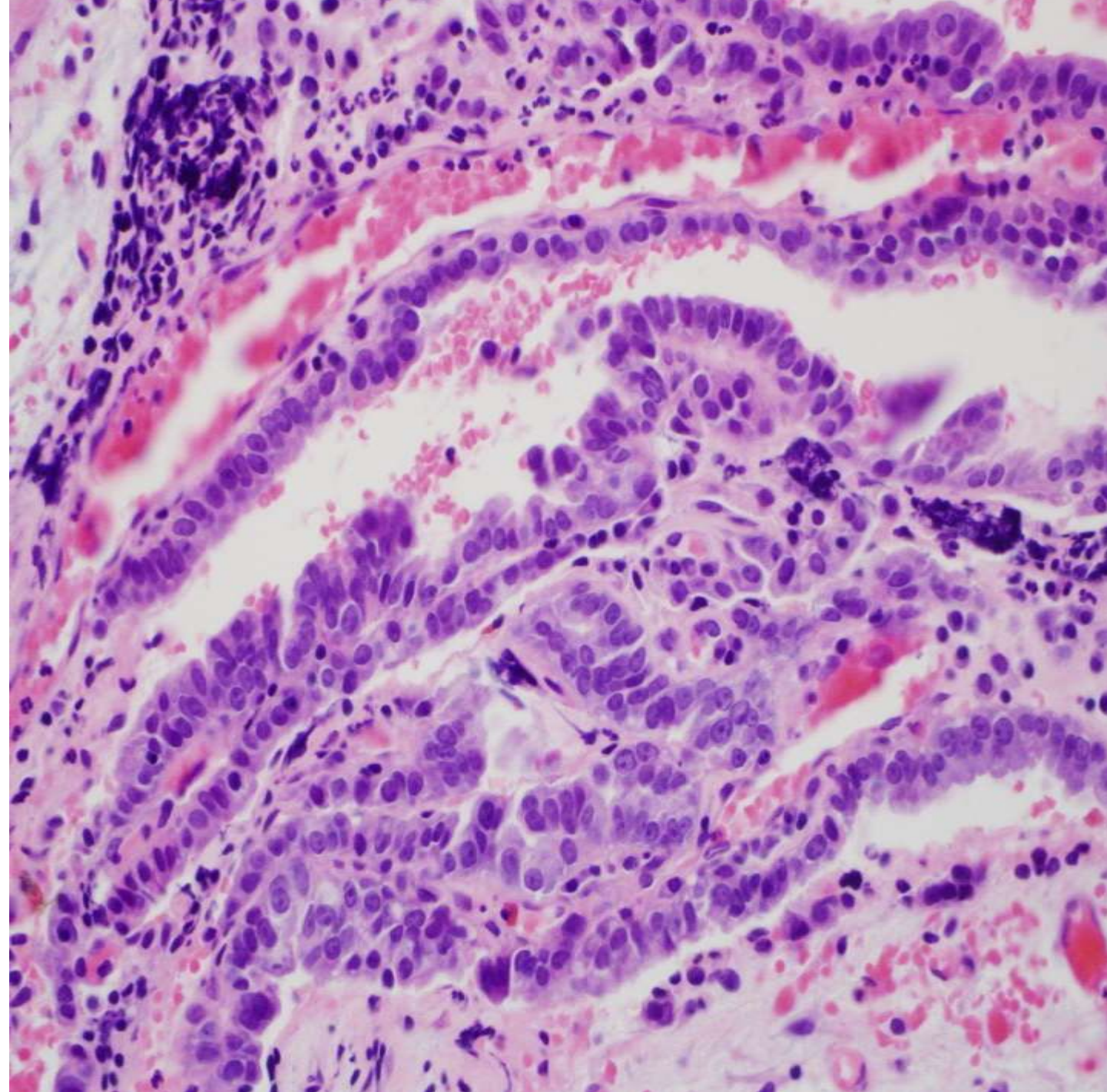
20-0201

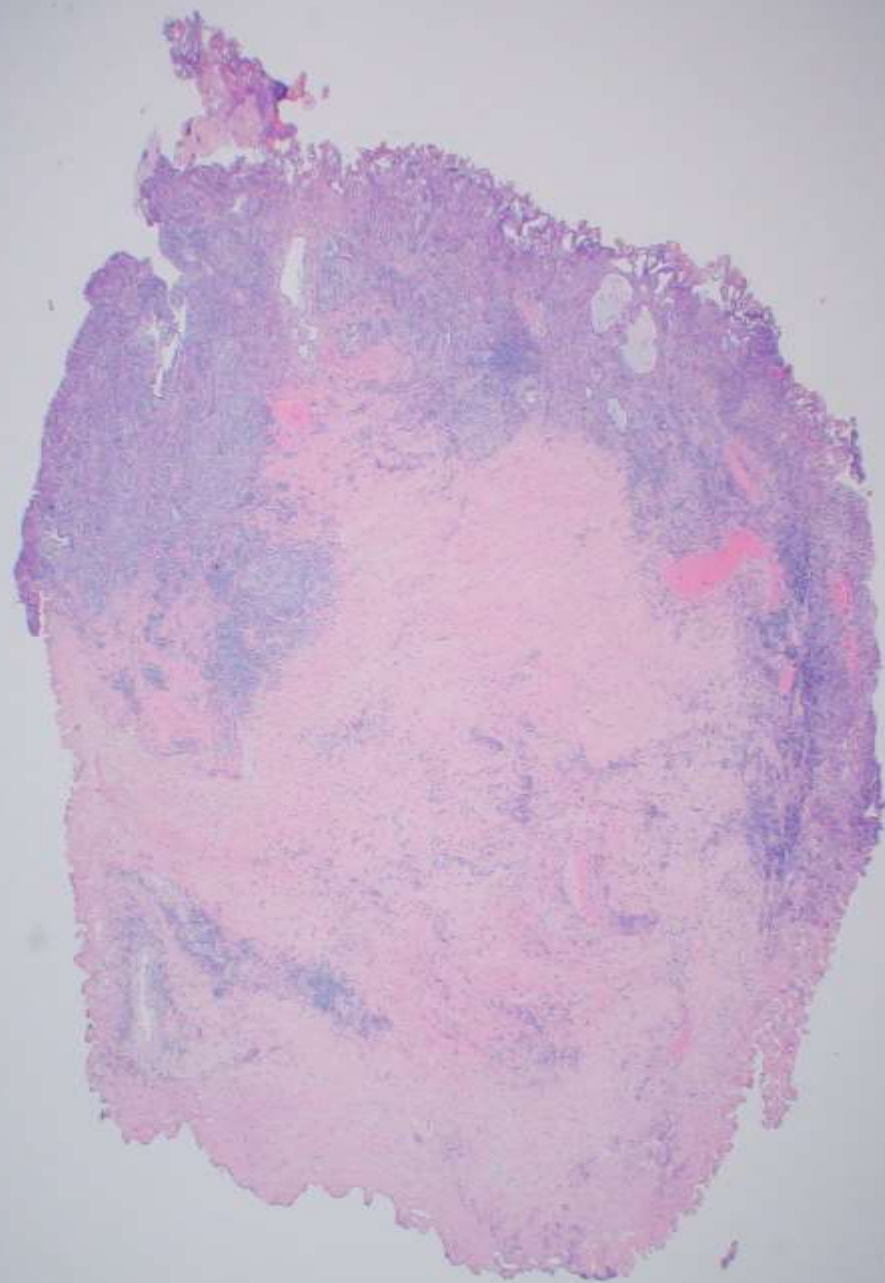
Christian Sebastian/Emily Chan/Jeff Simko; UCSF

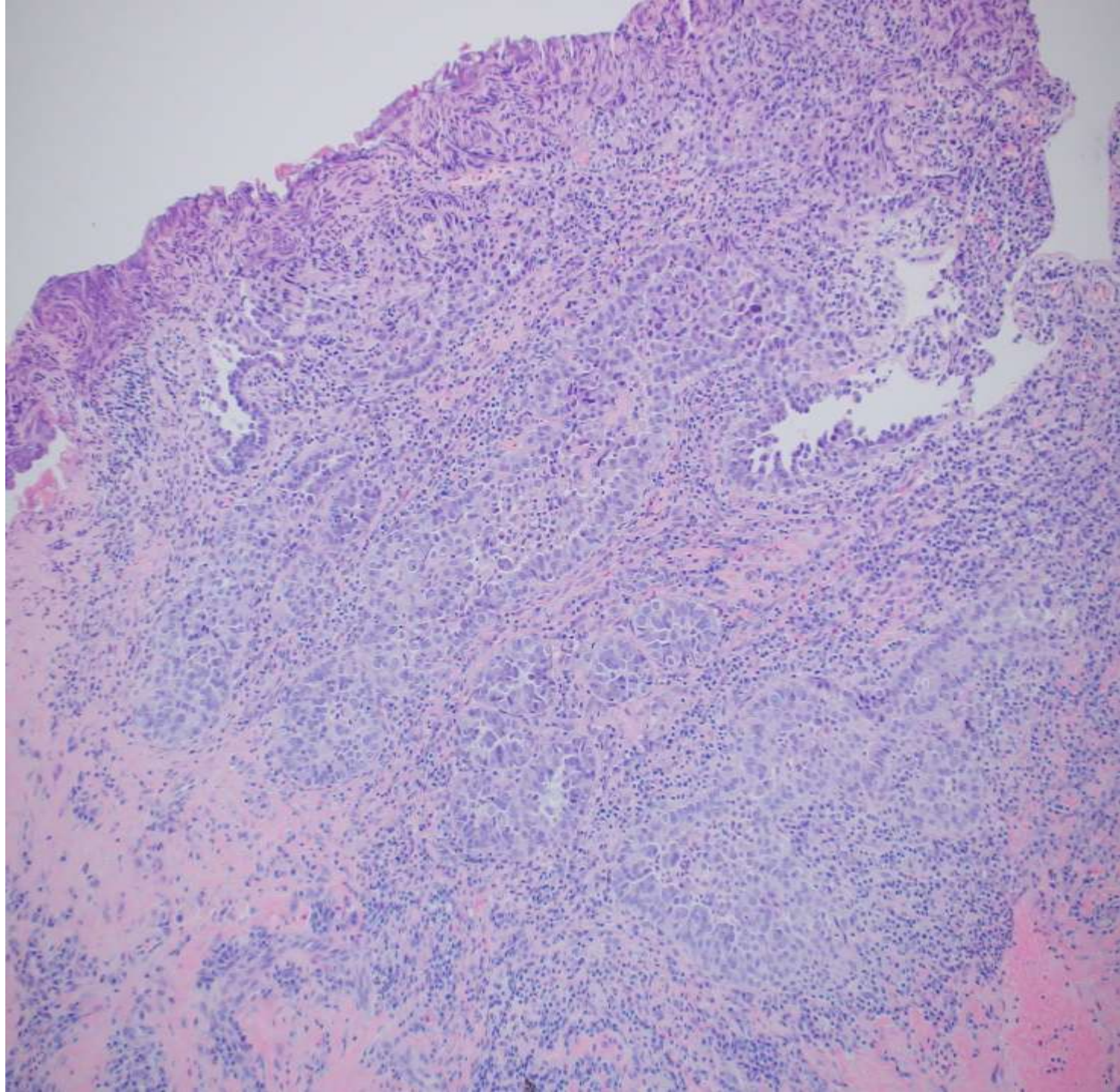
66-year-old M with h/o colorectal cancer treated with radiation >15 years prior, now with a urethral stricture. He undergoes transurethral resection of a papillary mass in the left lateral proximal bulbar and prostatic urethra.

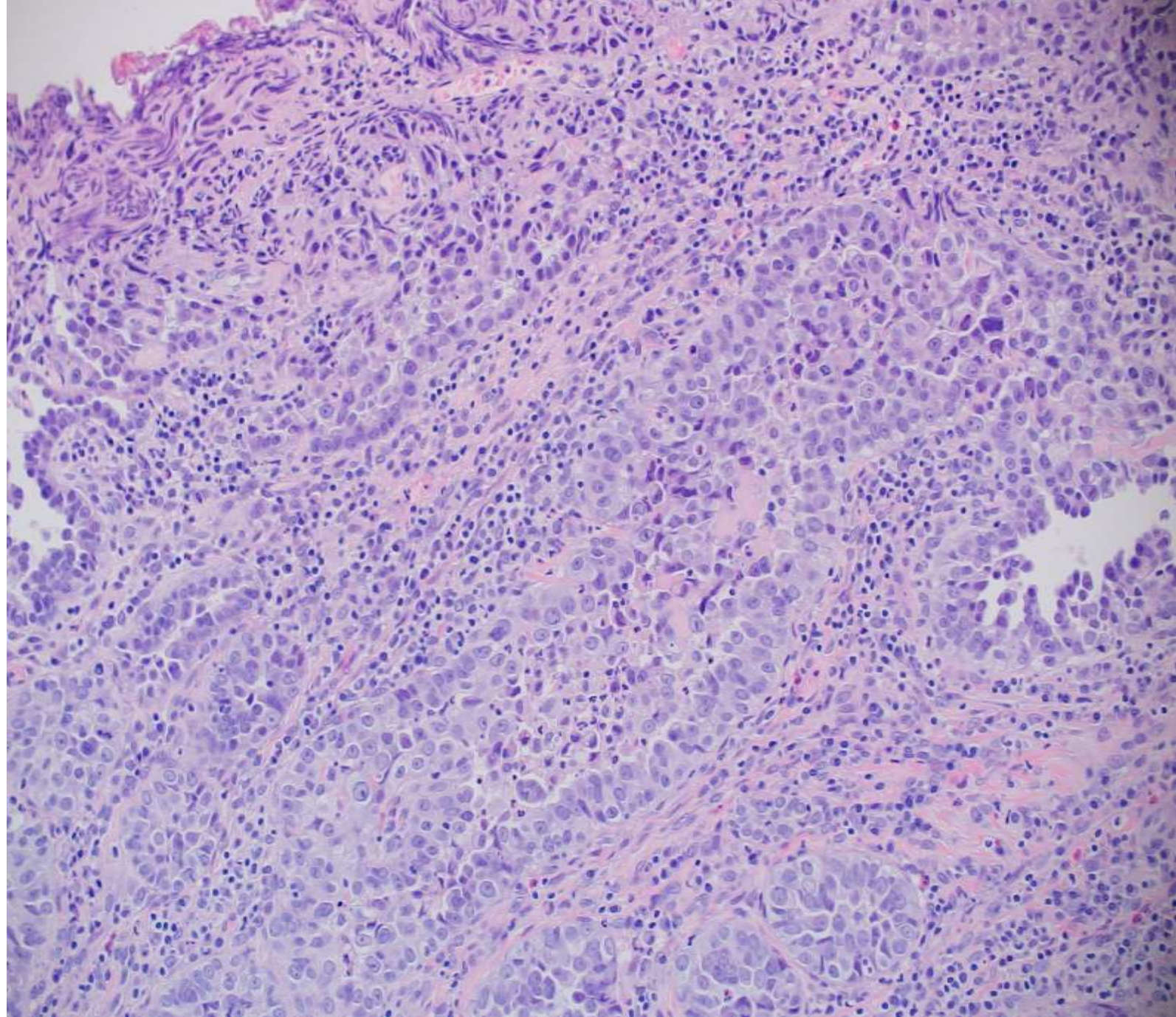


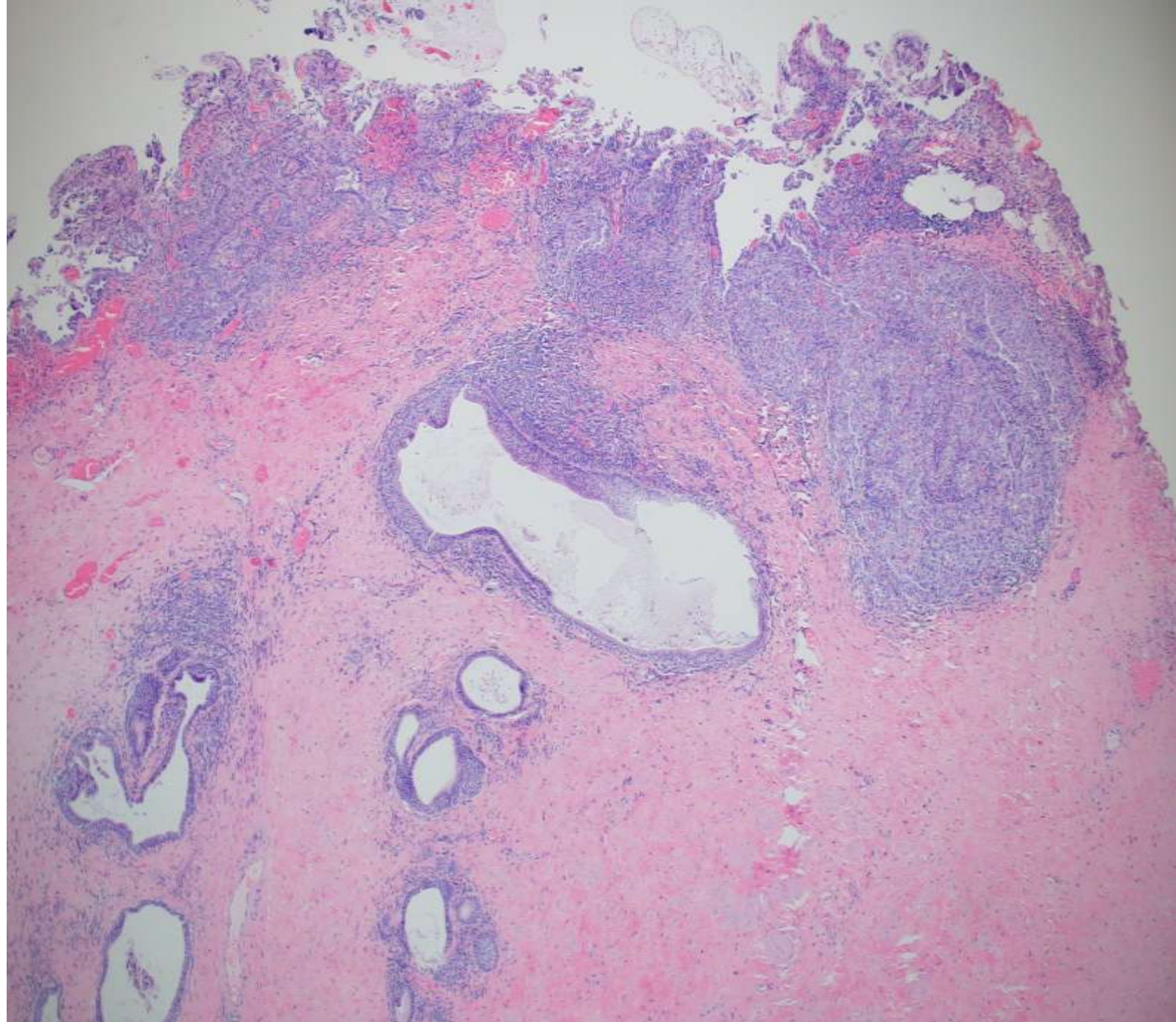


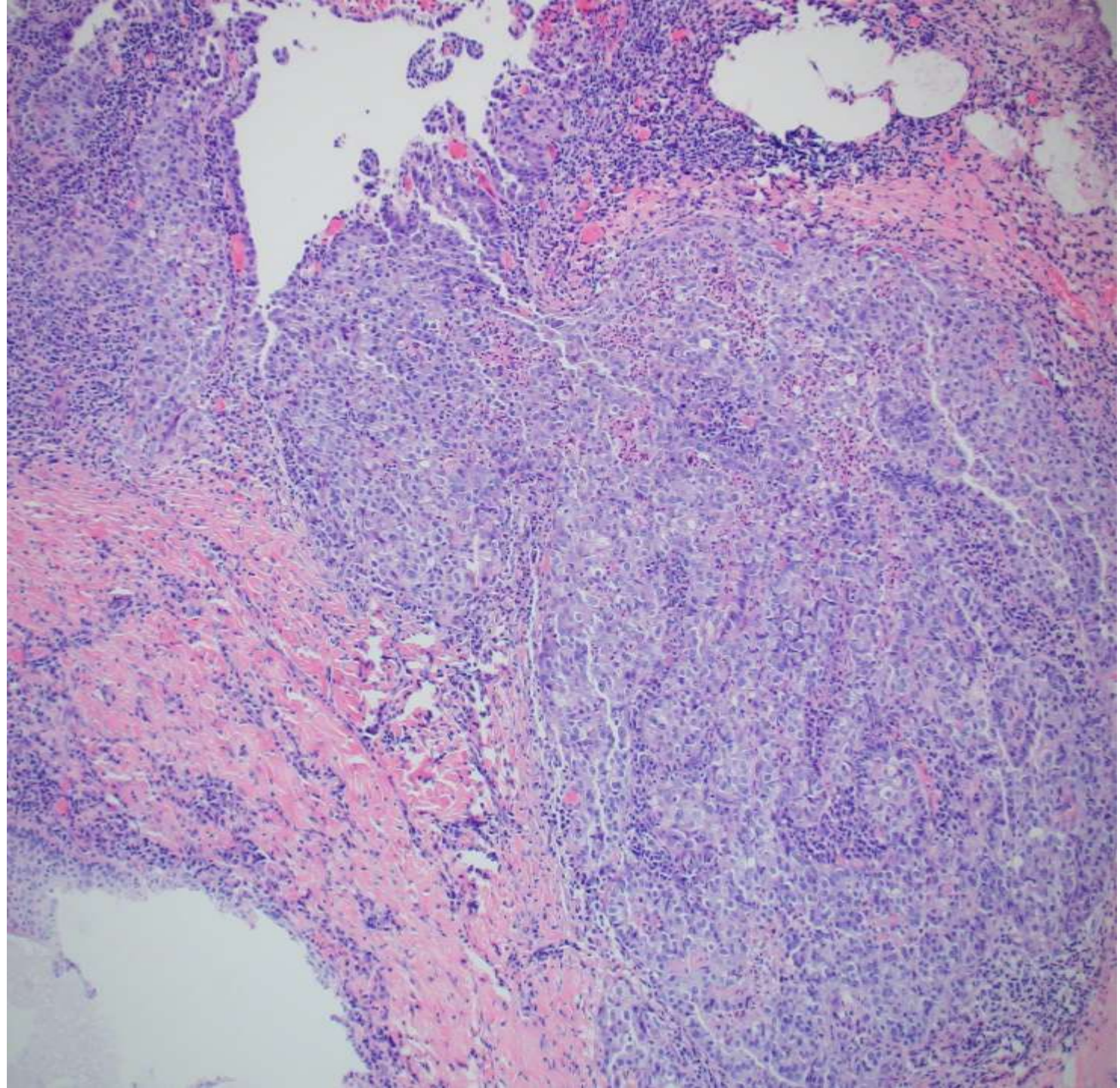


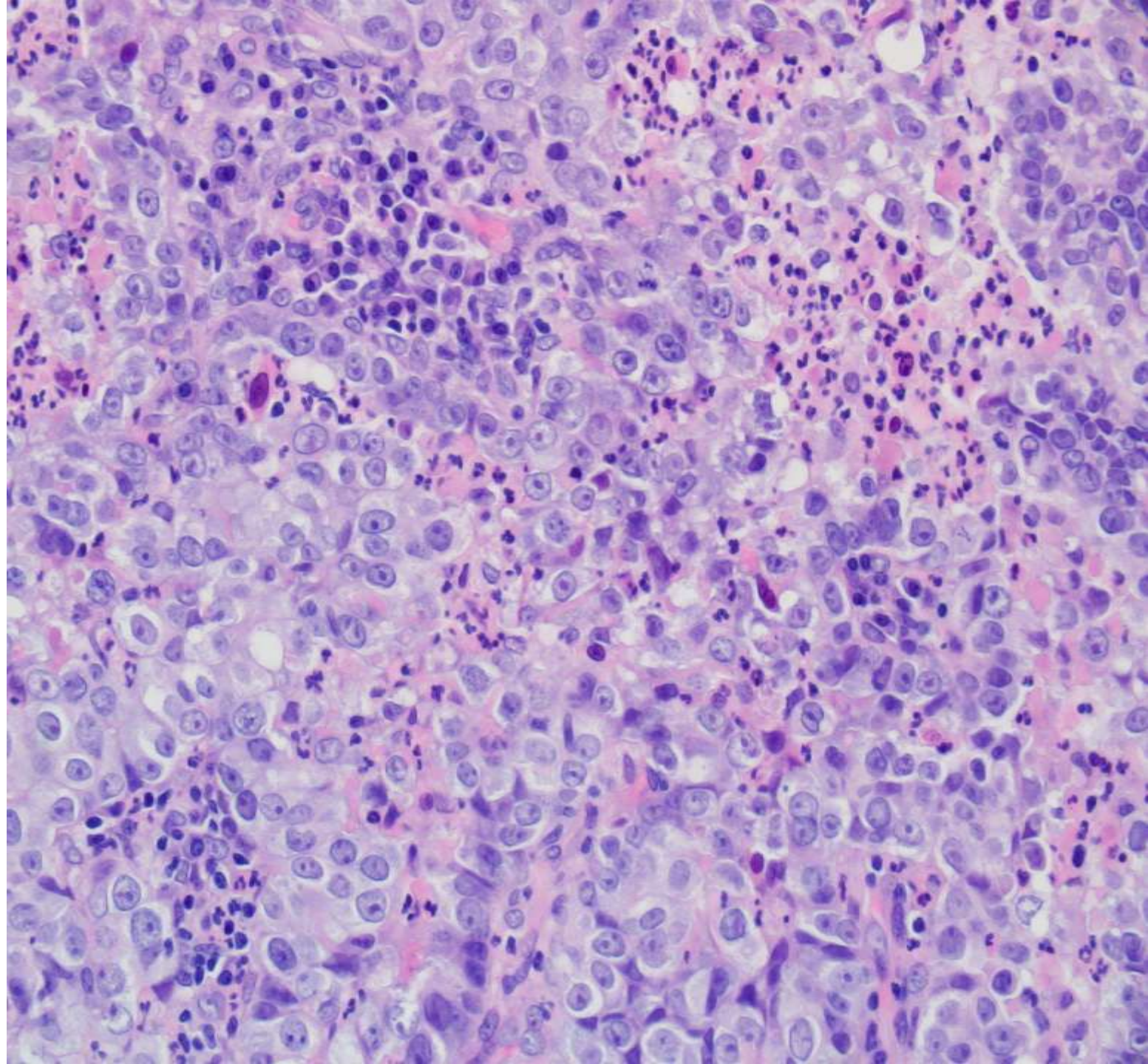






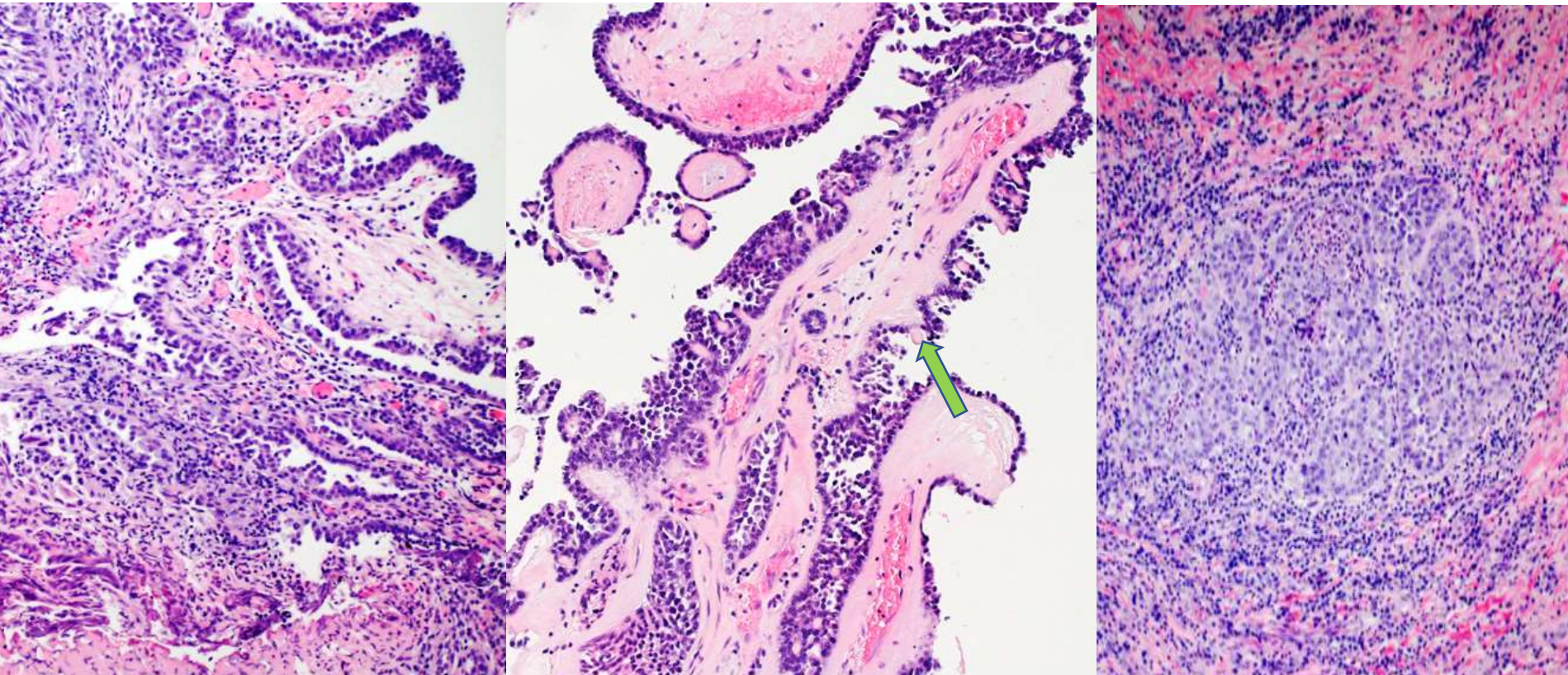






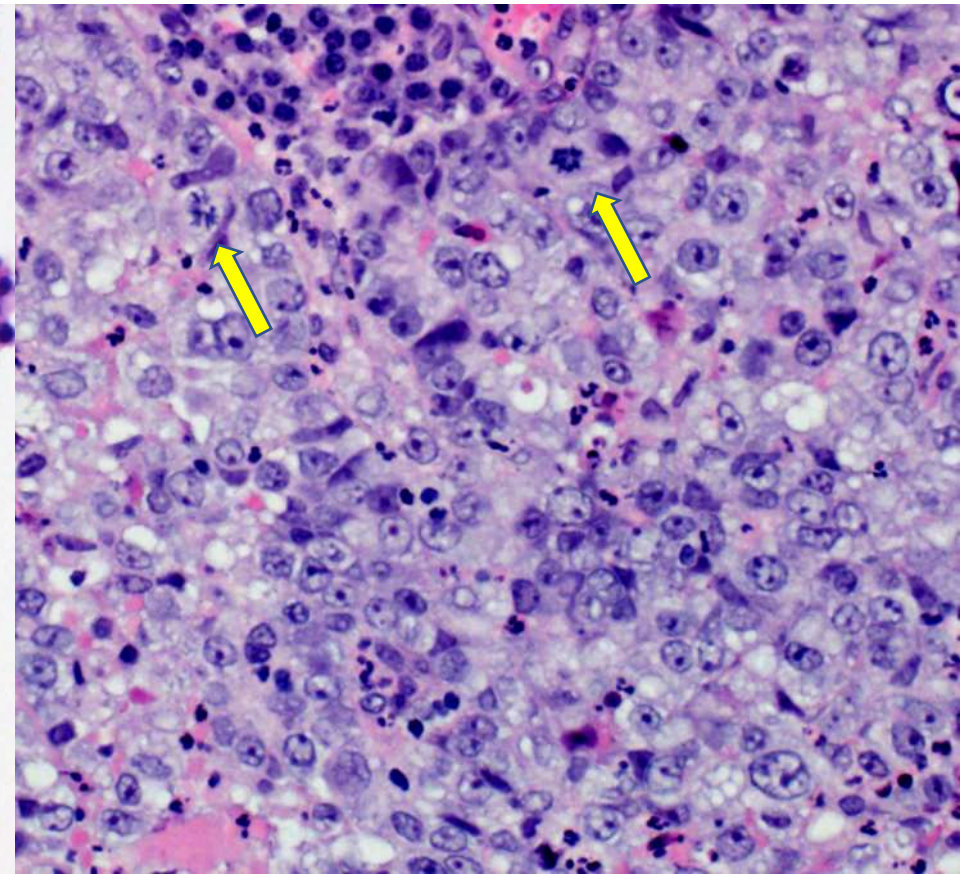
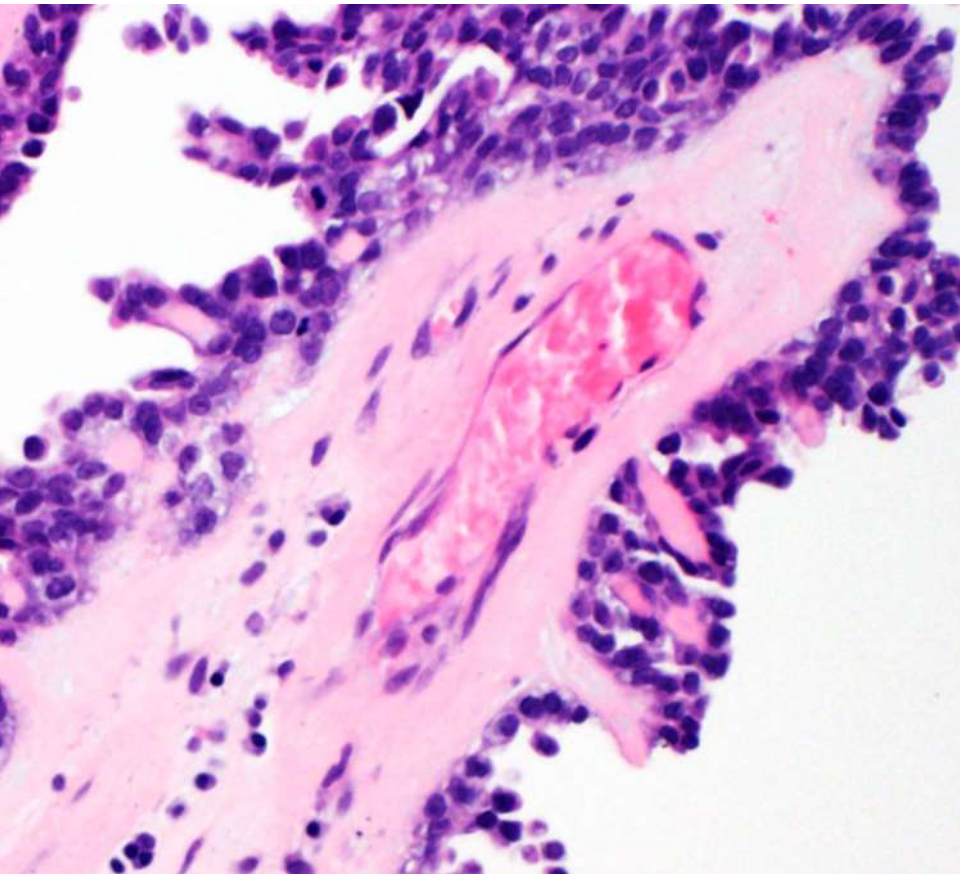
Architecture: Variable.

- Tubulocystic, papillary, and solid architecture.
- Hyalinized fibrovascular cores.



Cytology

- Single/pseudostratified layer of atypical hobnail cells in papillary and glandular foci.
- Variable amounts of clear to eosinophilic cytoplasm.
- Focally high mitotic rate. Some areas with uniformity to nuclei.



Differential diagnosis.

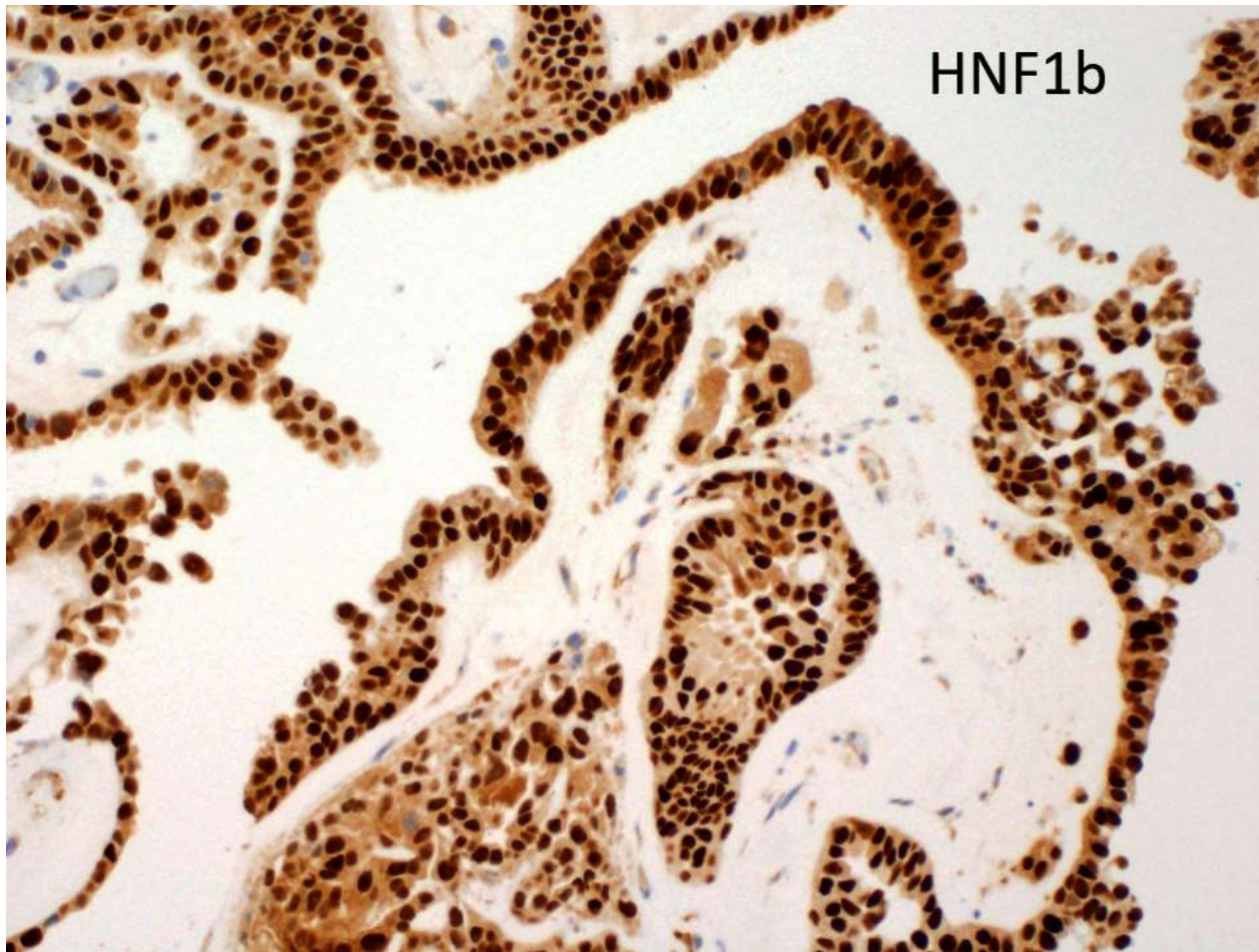
Primary

- Urothelial carcinoma.
 - Gata-3+, P63+, Uroplakin+, CK20+.
- Clear cell adenocarcinoma.
 - Pax-8+, Napsin+, HNF1b+, Ki67 >10%
- Nephrogenic adenoma.
 - Pax-8+, HNF1b -
- Adenocarcinoma of urethra.
 - CK20+, CDX-2+, Beta-catenin cytoplasmic.

Metastatic/direct extension

- Prostatic adenocarcinoma.
 - NKX3.1+, PSA+.
- Colonic adenocarcinoma.
 - CDX2+, SATB2+, CK20+, nuclear beta-catenin.
- Metastatic GYN clear cell adenocarcinoma (if female).
 - Pax-8+, Napsin+, HNF1b+ (Exclude with imaging).
- Metastatic cervical adenocarcinoma.

Immunohistochemistry



Pax-8: Positive

Napsin: Variable/positive

HNF1b: Positive

AMACR: Positive

P63: Negative

Gata-3: Negative

NKX3.1: Negative

PSA: Negative

P53: Non-contributory

Ki67: >10%

Differential diagnosis

Nomenclature: Can be confused with more common *clear cell variant of urothelial carcinoma*.

Primary

- Urothelial carcinoma.
 - Gata-3+, P63+, Uroplakin+, CK20+.
- Clear cell adenocarcinoma.
 - Pax-8+, Napsin+, HNF1b+, Ki67 >10%
- Nephrogenic adenoma.
 - Pax-8+, HNF1b -
- Adenocarcinoma of urethra.
 - CK20+, CDX-2+, Beta-catenin cytoplasmic.

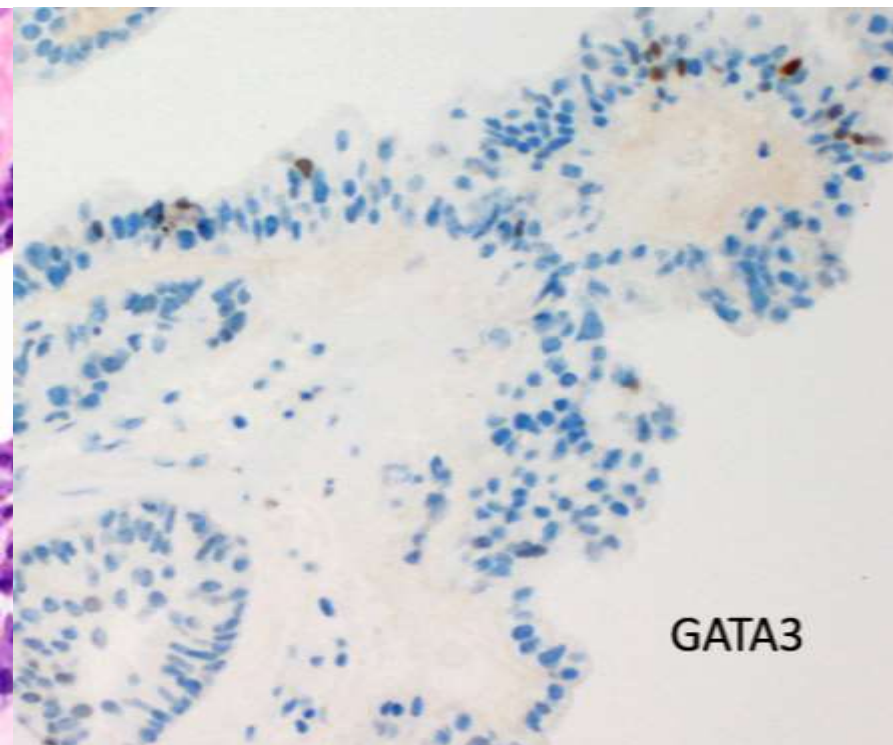
Metastatic/direct extension

- Prostatic adenocarcinoma.
 - NKX3.1+, PSA+.
- Colonic adenocarcinoma.
 - CDX2+, SATB2+, CK20+, nuclear beta-catenin.
- Metastatic GYN clear cell adenocarcinoma (if female).
 - Pax-8+, Napsin+, HNF1b+ (Exclude with imaging).
- Metastatic cervical adenocarcinoma.

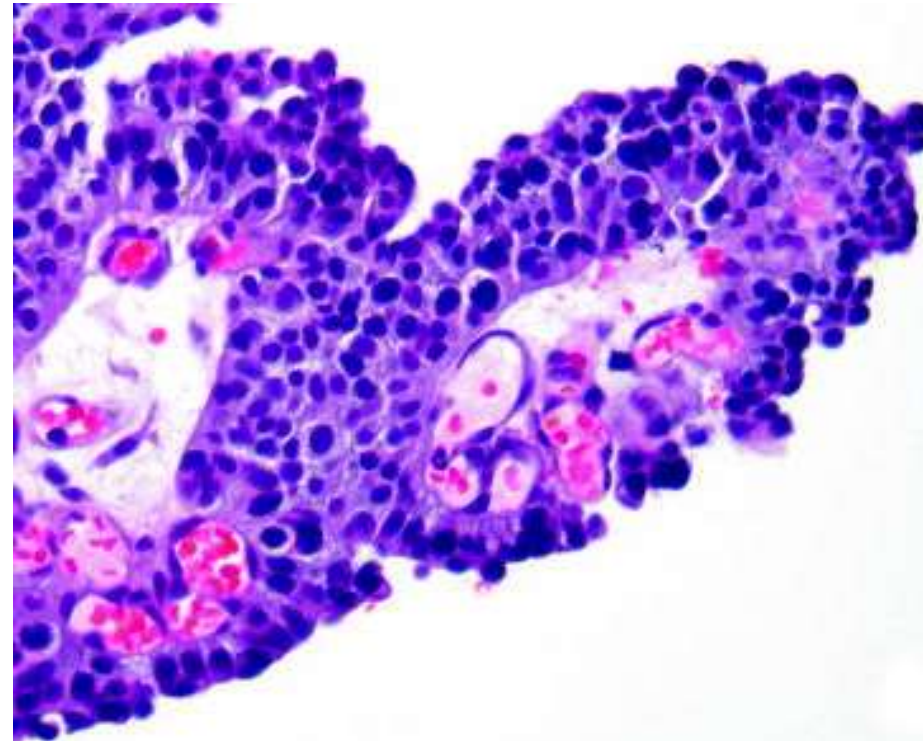
Clear cell adenocarcinoma of the GU tract.

- Rare subtype of urothelial adenocarcinoma of uncertain histogenesis.
- Occurs more often in women (2-3:1), often in association with urethral diverticulum.
- Histologically and immunophenotypically analogous to clear cell carcinoma of gynecologic origin.
 - MAY NOT ALWAYS HAVE CLEAR CELLS.
- Rarity makes prognostication difficult, but may behave more aggressively than other urothelial carcinomas when matched for stage.
 - Often treated with cystectomy +/- adjuvant chemoradiotherapy.
 - Do not respond to intravesicular therapy.
 - TURBT of low stage lesions has been successful

Differential diagnosis: High-Grade Papillary Urothelial Carcinoma



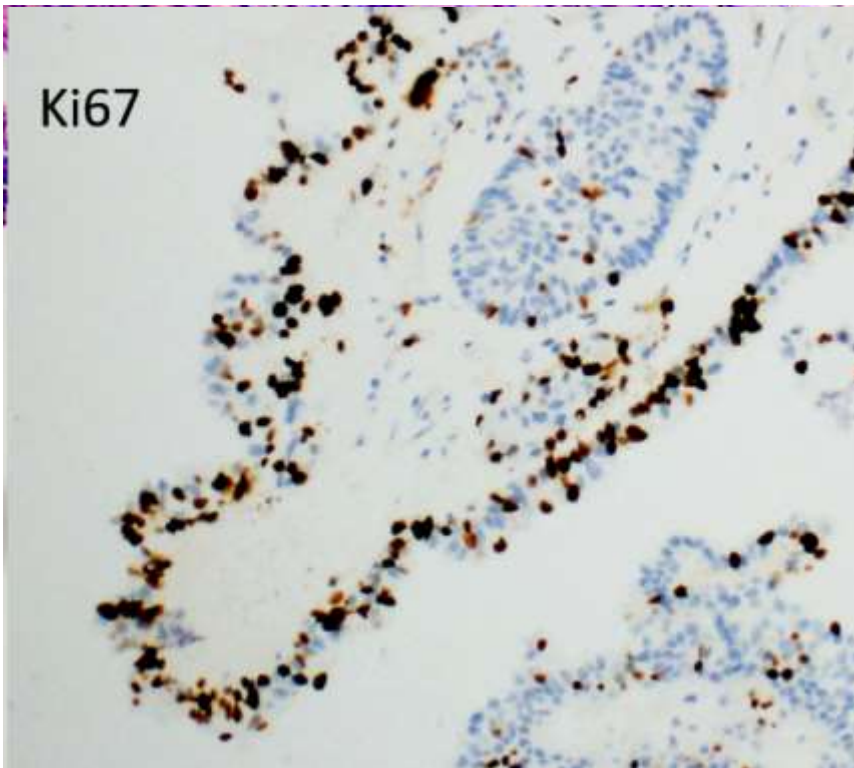
vs



- Single/pseudostratified with hobnail cells
- PAX8+
- Napsin/HNF1b +
- GATA3-, p63-

- Multilayered epithelium, no hobnail cells, greater nuclear pleomorphism.
- Gata3 +
- P63+
- Pax8-/Napsin-/HNF1b-

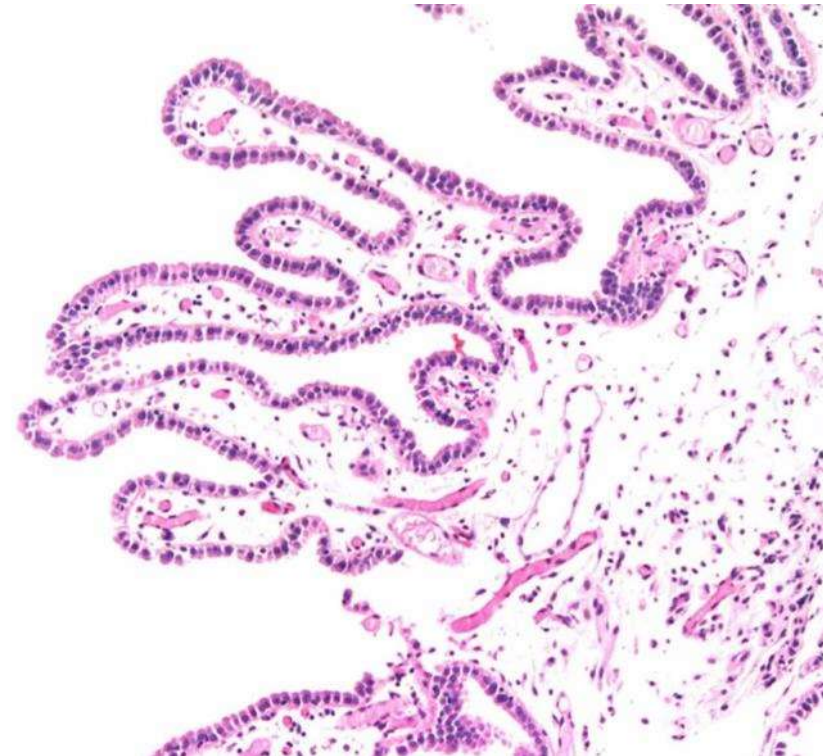
Differential diagnosis: Nephrogenic Adenoma



Clear cell adenocarcinoma.

- Increased nuclear atypia, frequent mitosis
- P53 aberrant.
- Ki67 10-80%

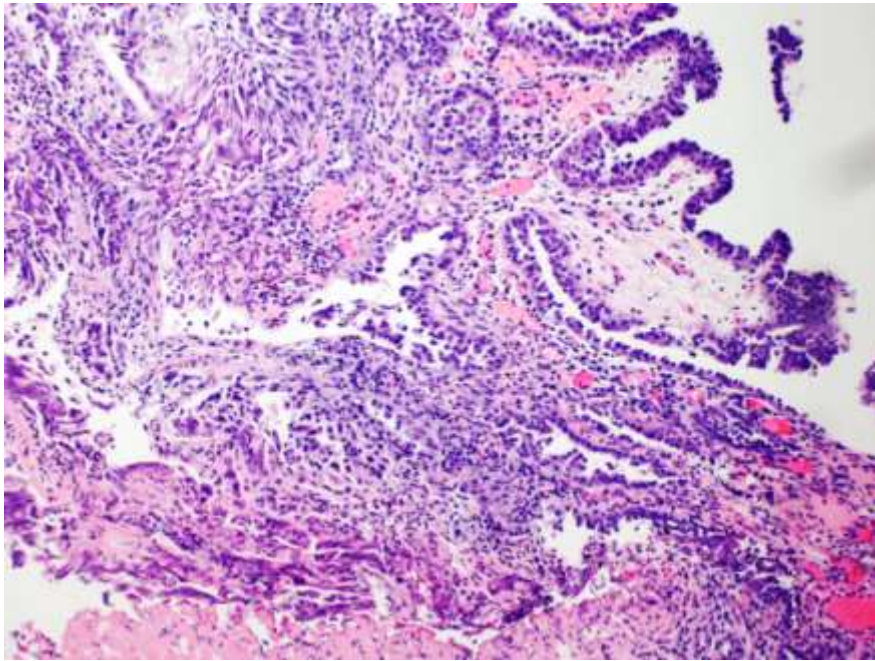
vs



Nephrogenic adenoma

- No significant nuclear atypia or mitoses.
- Rarely solid architecture.
- P53 wt
- Ki67 < 5%

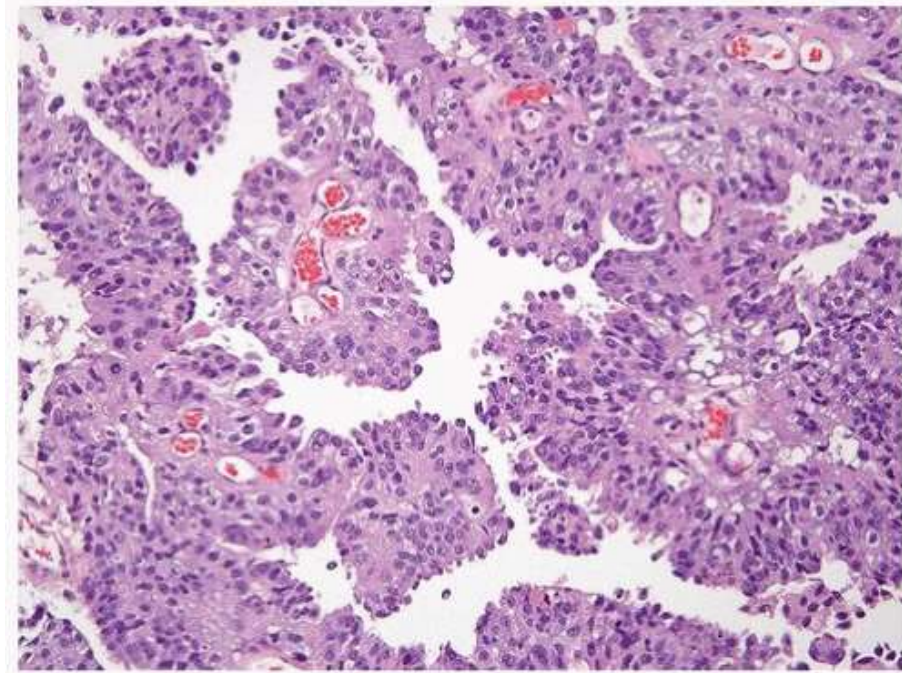
Differential diagnosis: Prostatic adenocarcinoma



Clear cell adenocarcinoma.

- AMACR + HMWCK - P63 -
- PAX8+
- NKX3.1 -

vs



Prostatic adenocarcinoma with pseudopapillary architecture.

- AMACR + HMWCK - P63 -
- NKX3.1 +
- PSA+

Image from Gordetski J. Epstein, J; Am J Surg Pathol 2014;38:941-945

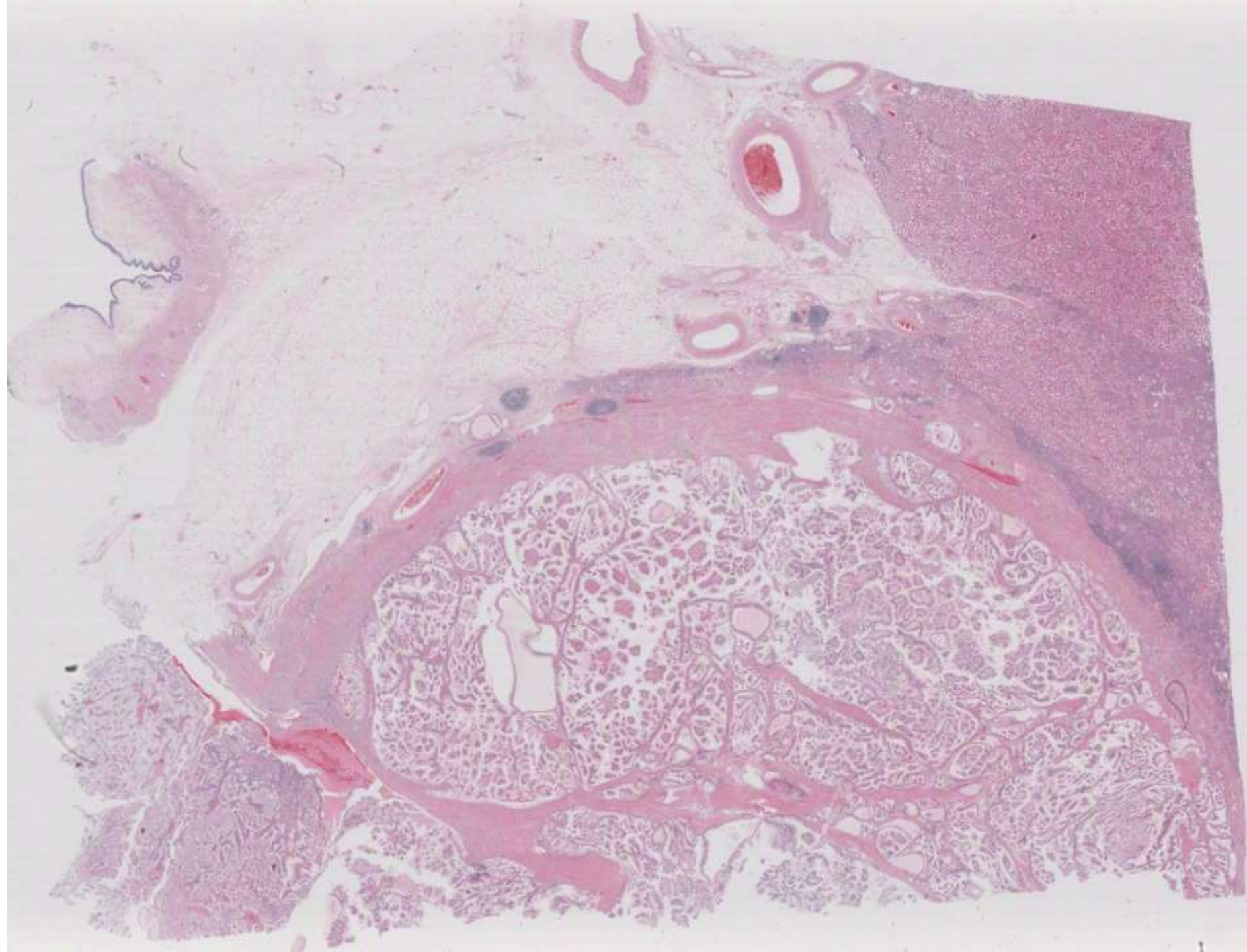
Follow up.

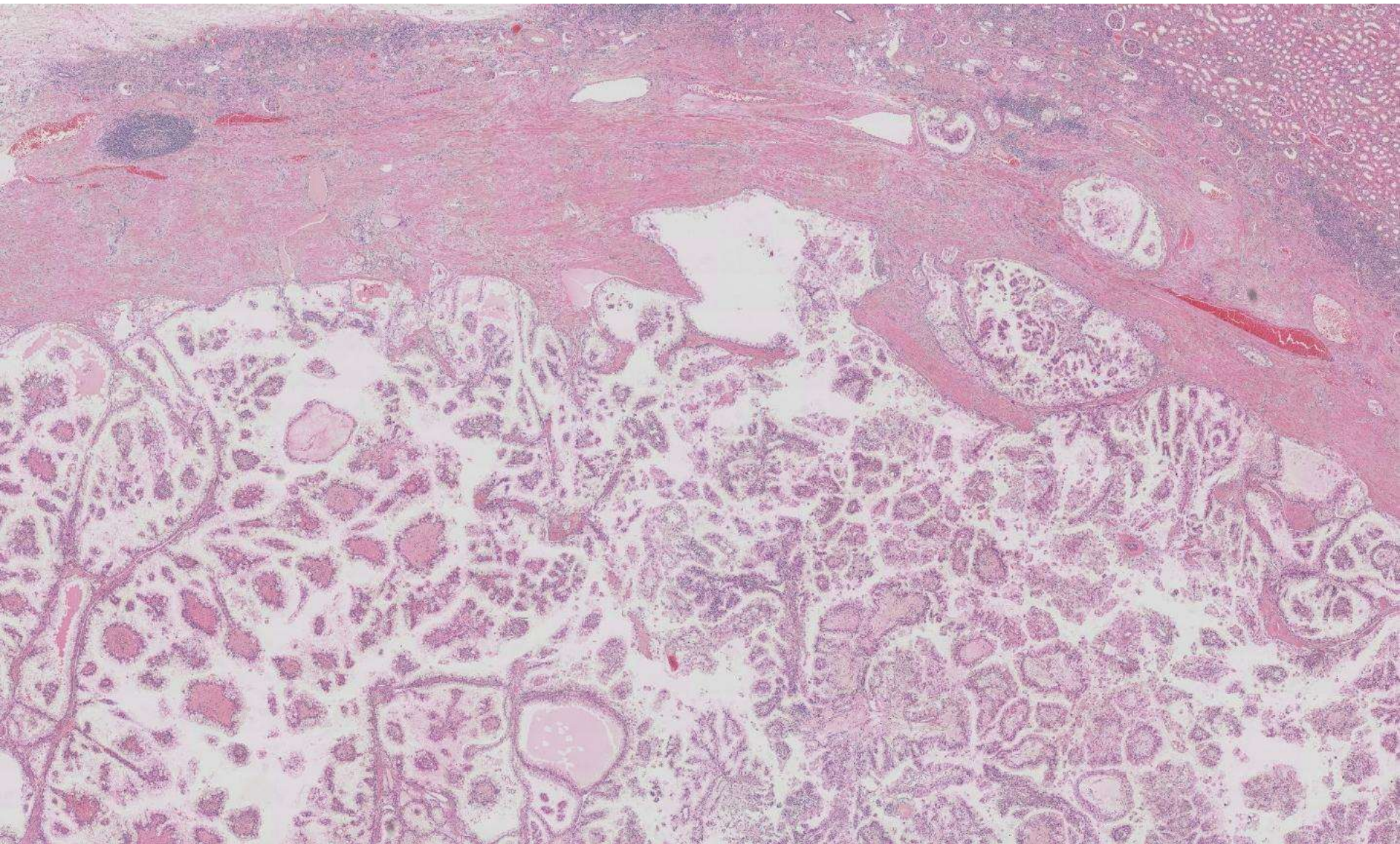
Our patient underwent radical cystoprostatectomy and pelvic LND 1/2018 w/ residual pT1 disease on final pathology. He remains disease free as of 12-2019

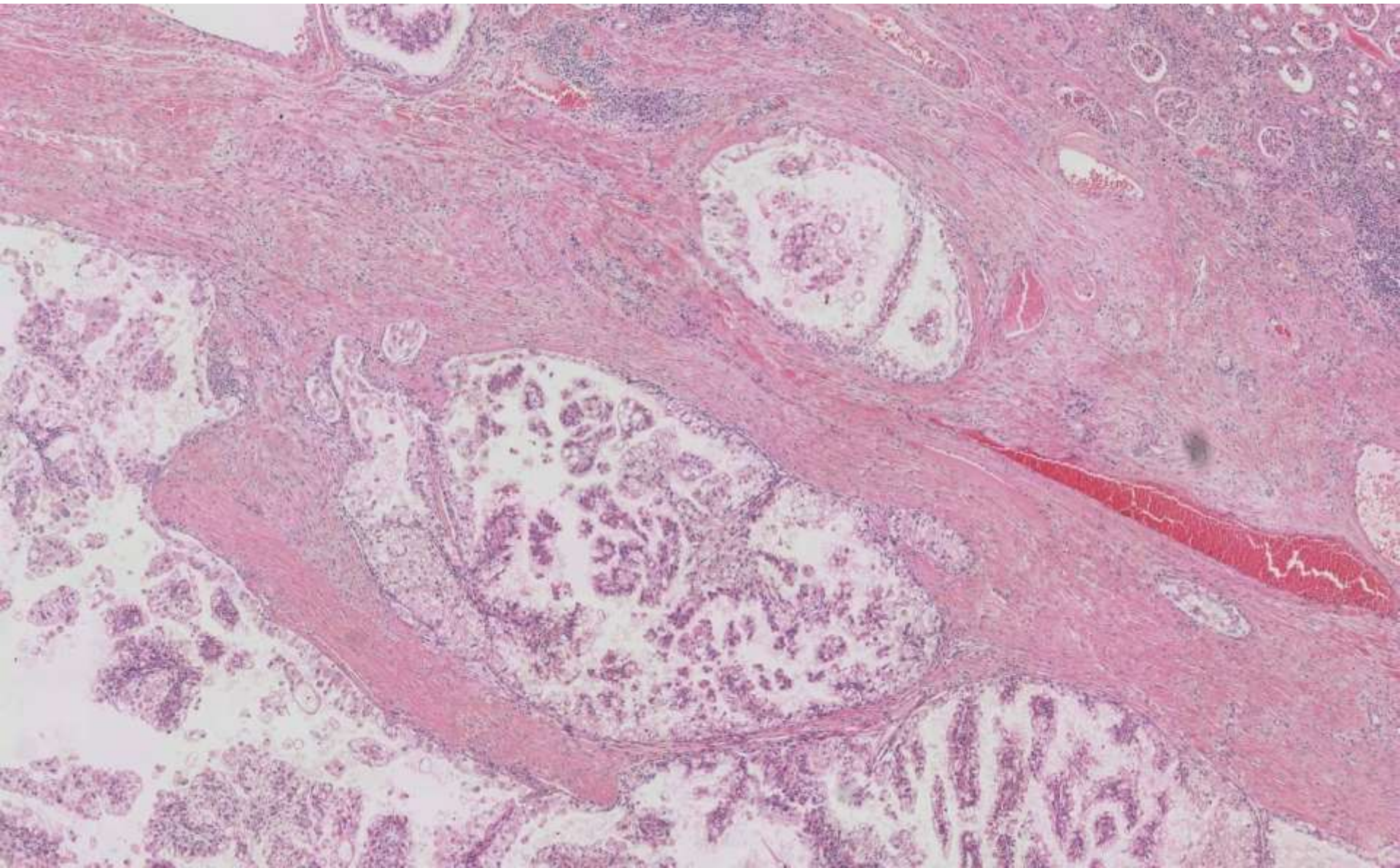
20-0202
scanned slide available!

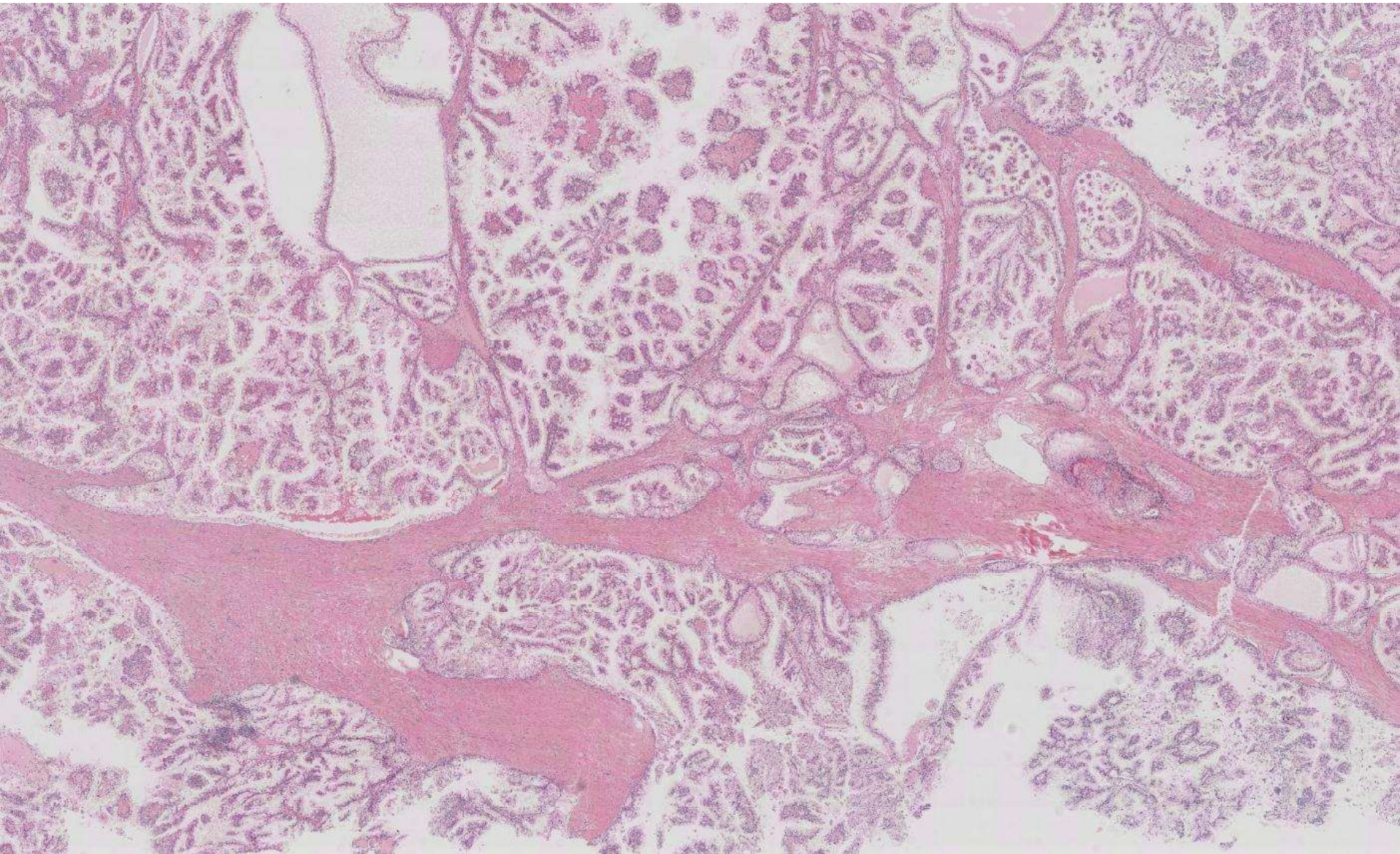
Emily Chan; UCSF

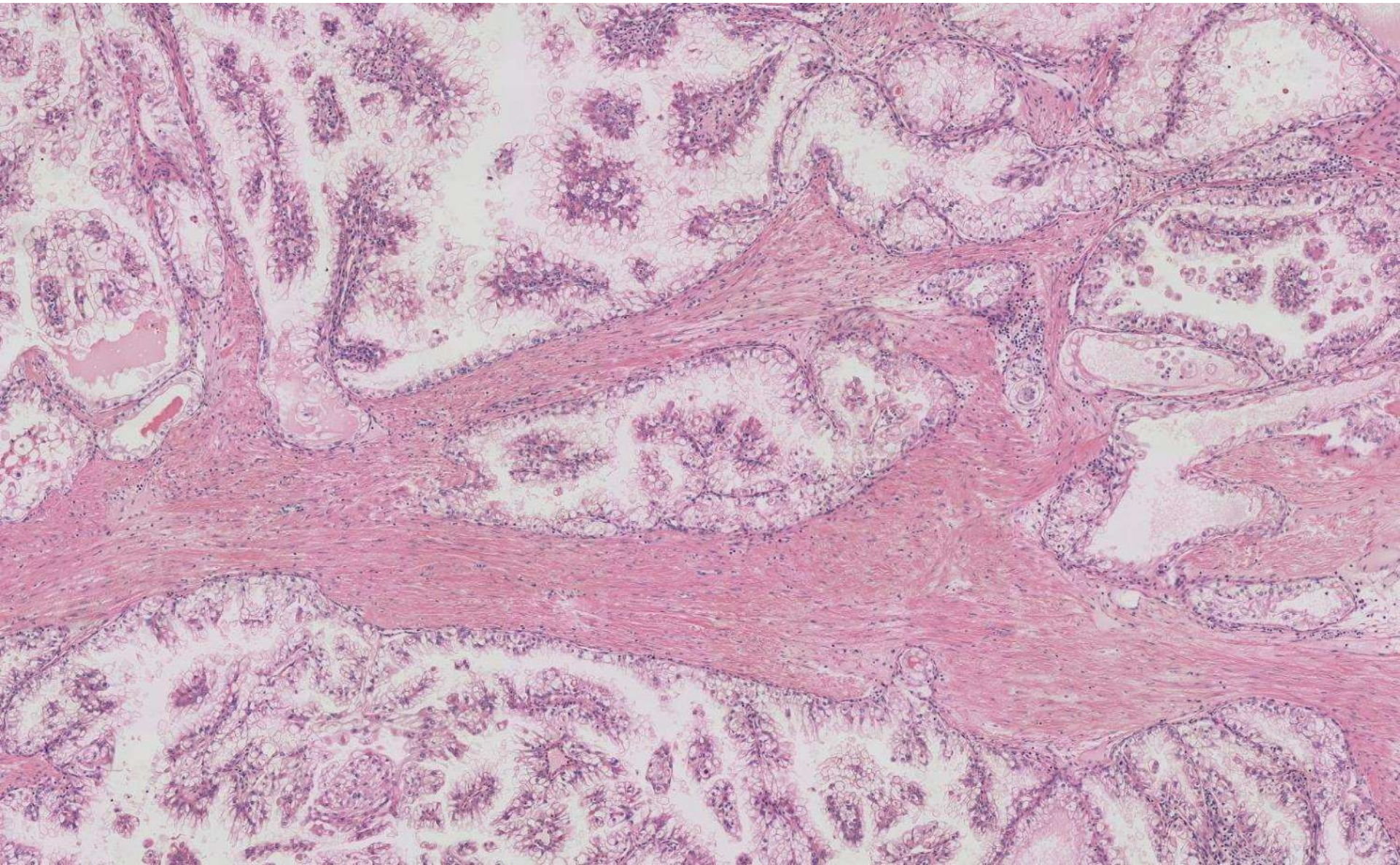
48-year-old F with incidental 5.8cm enhancing left lower pole renal mass, and a few small but prominent left periaortic lymph nodes.

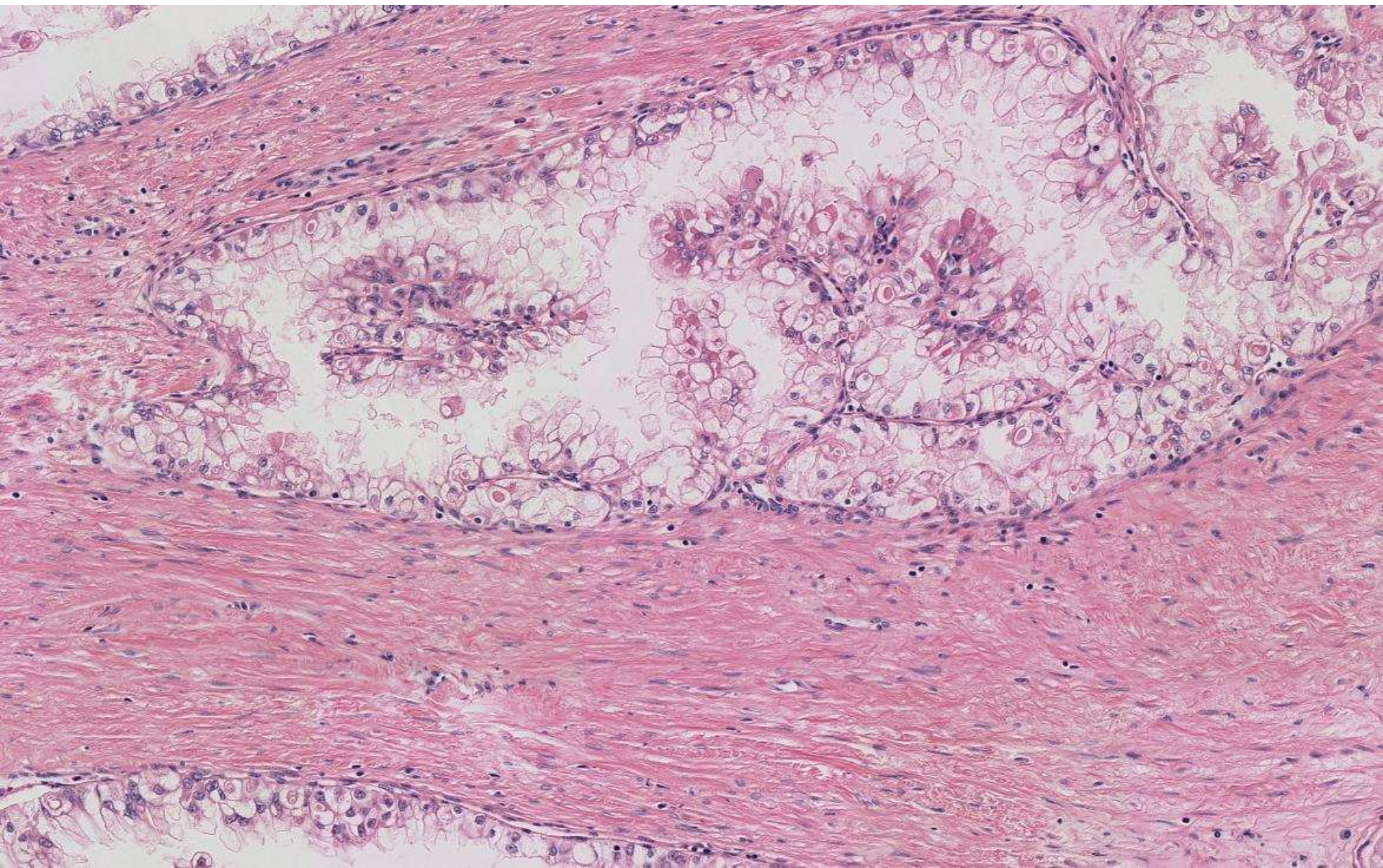


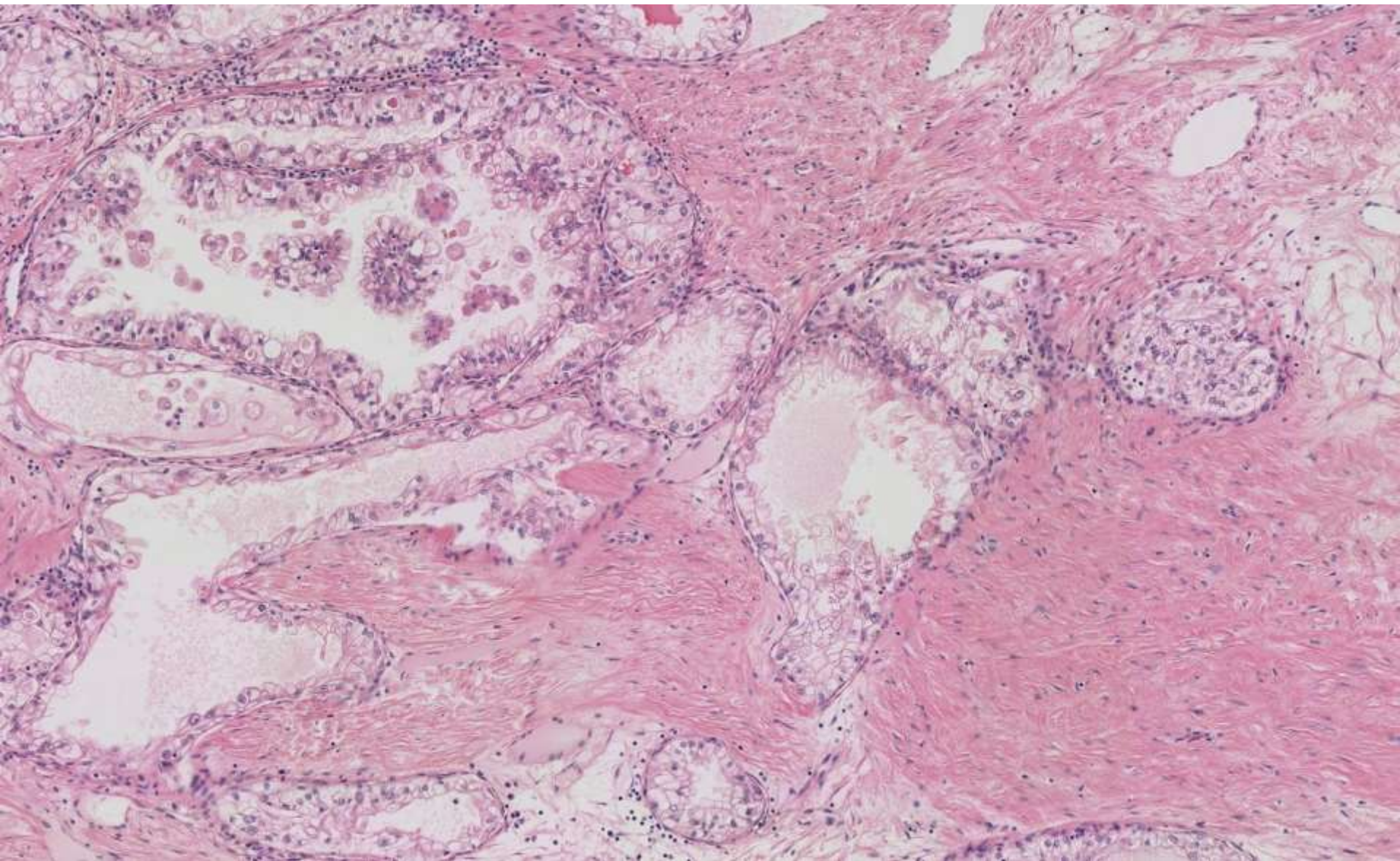


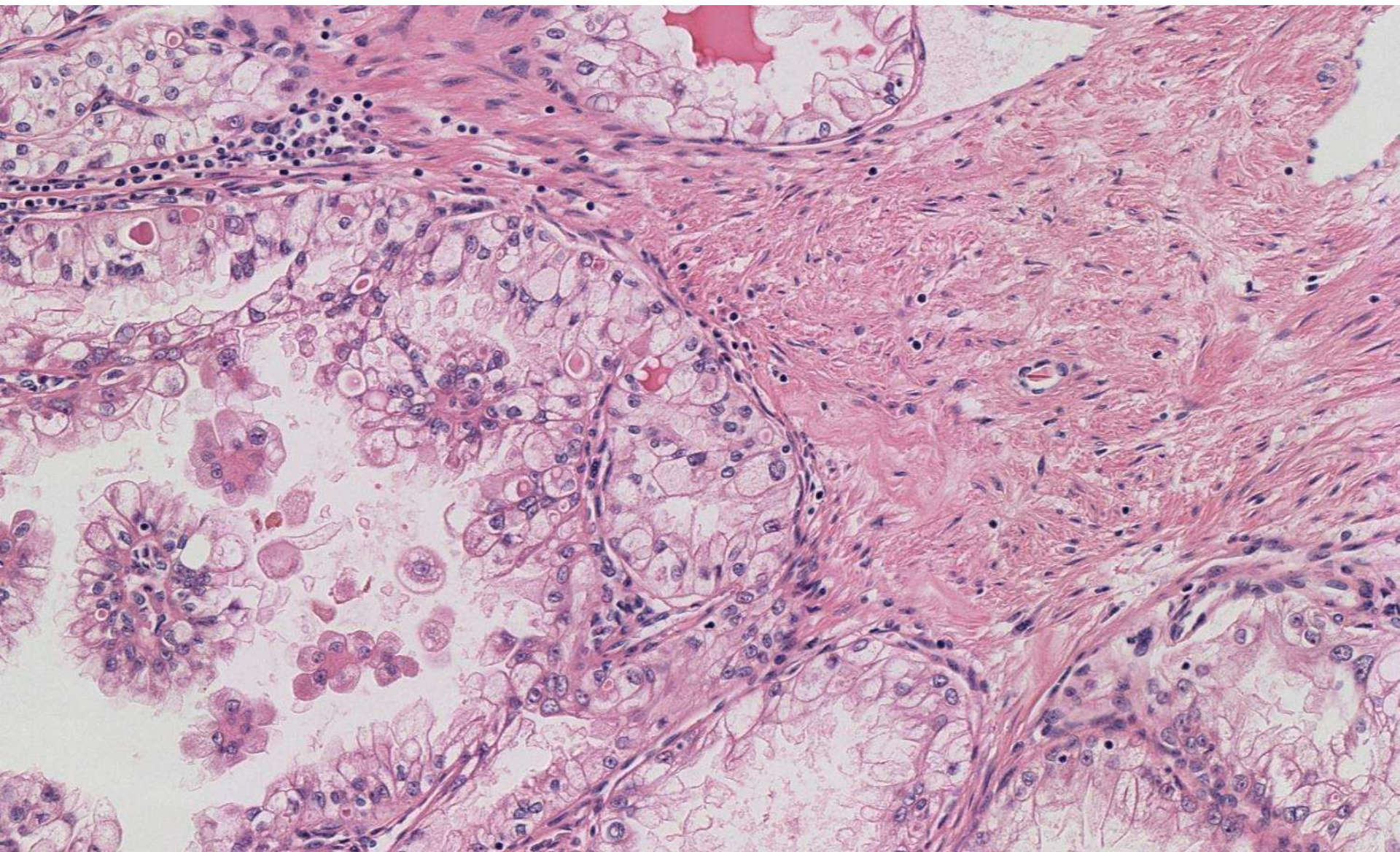


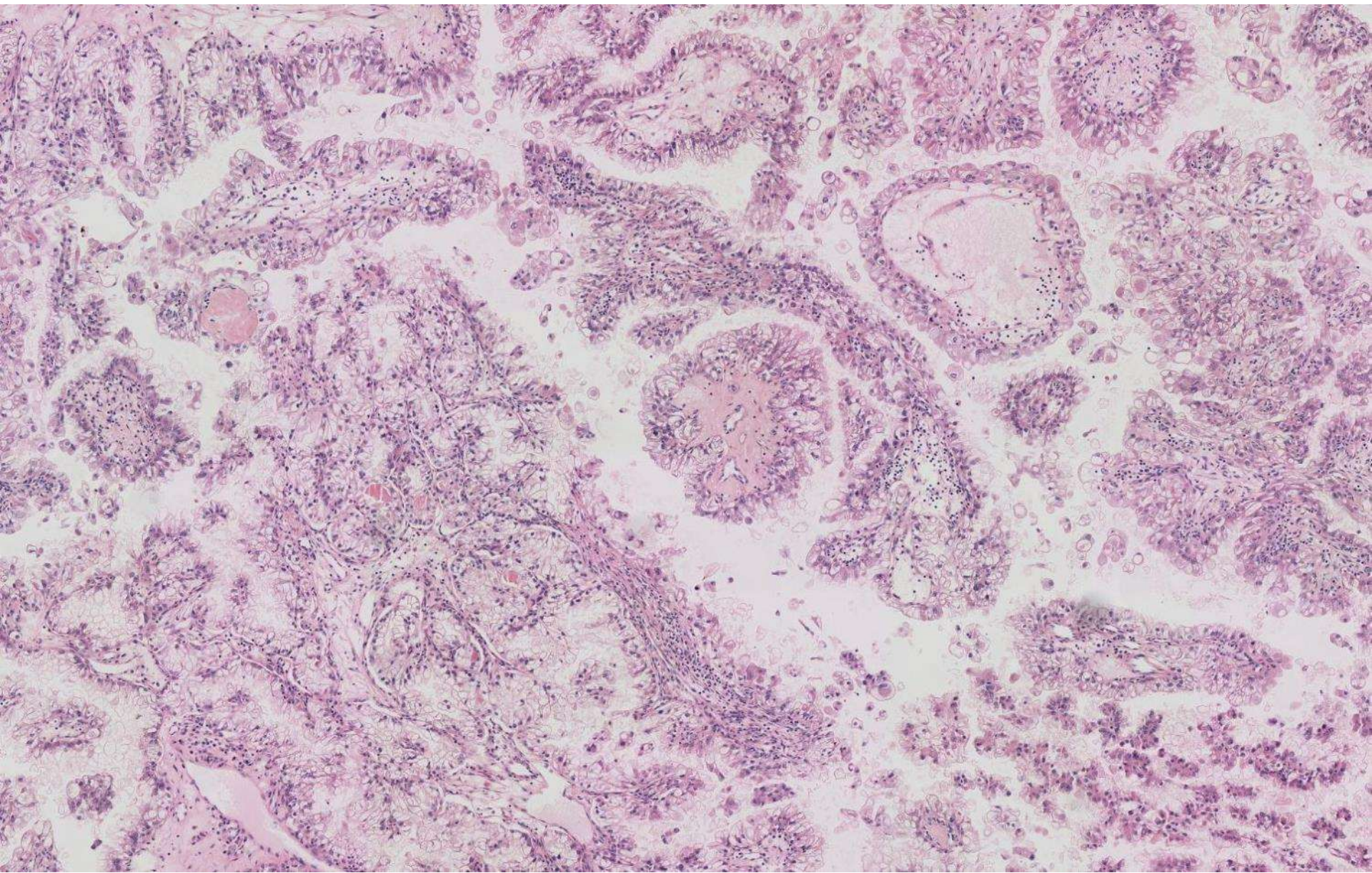


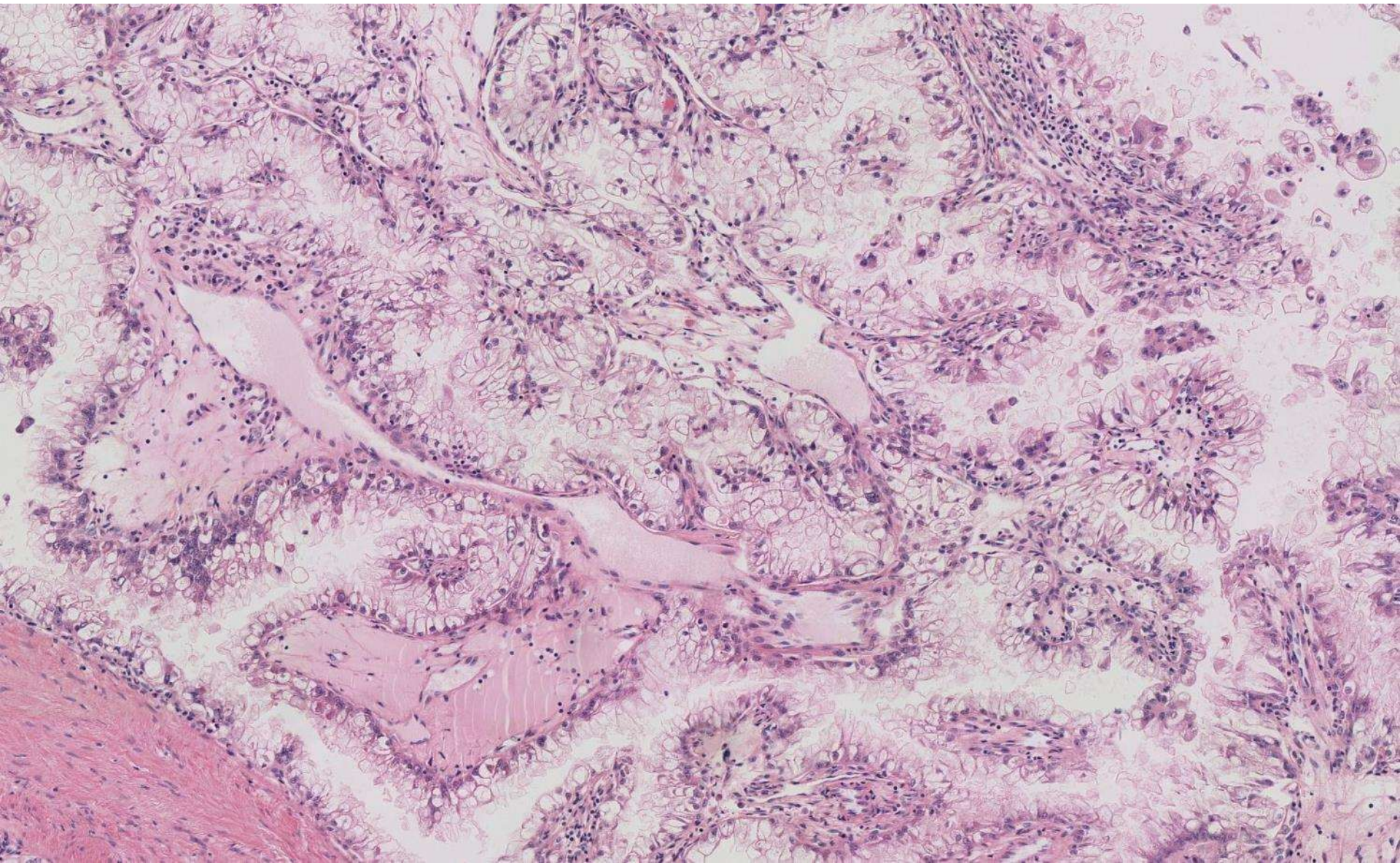


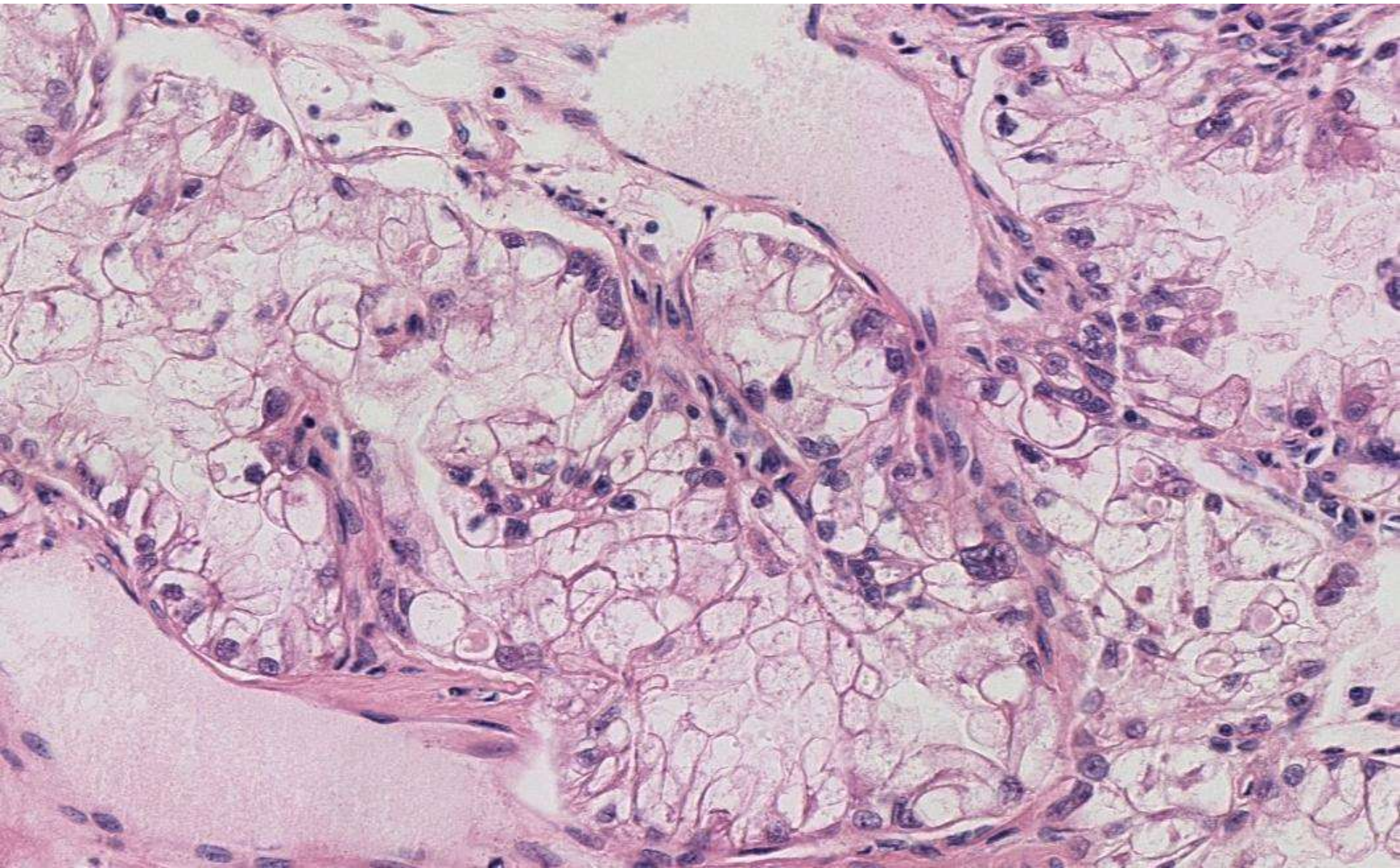


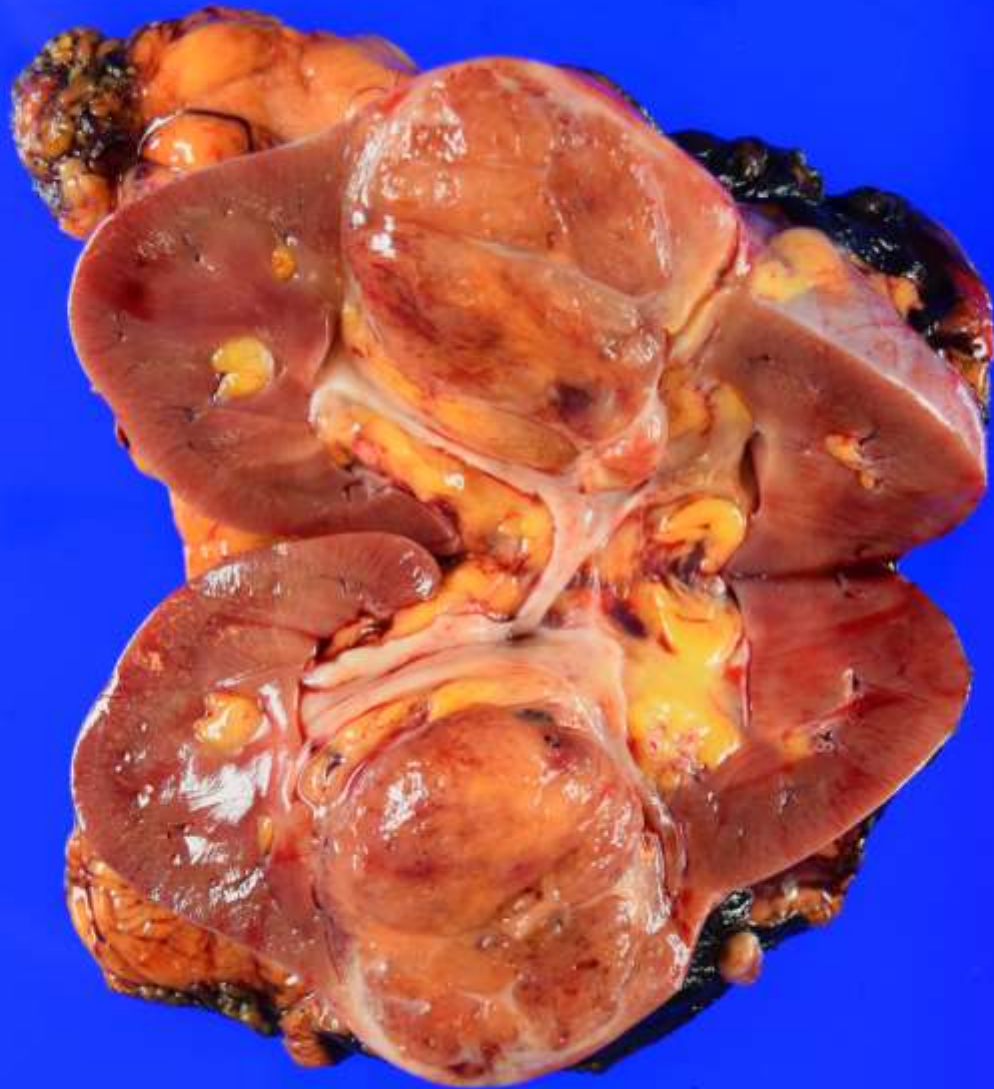



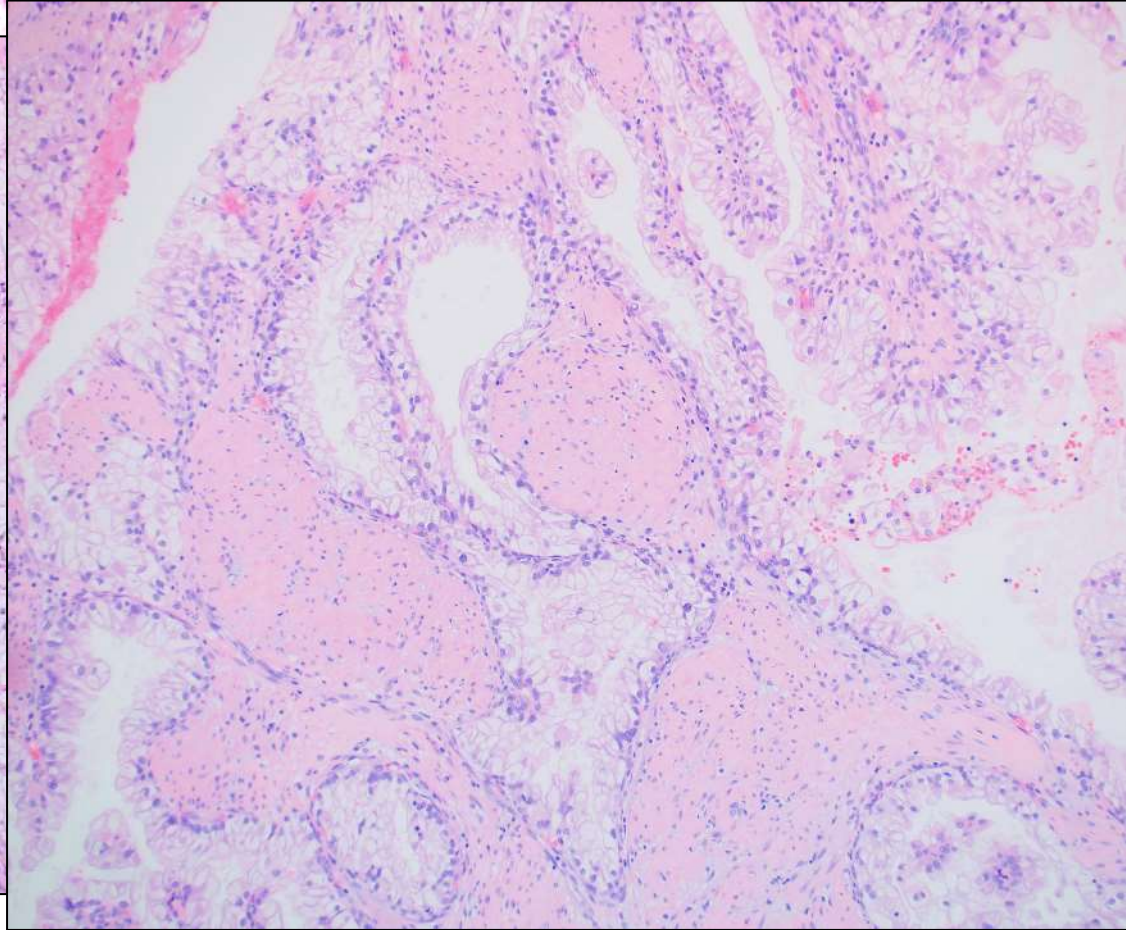
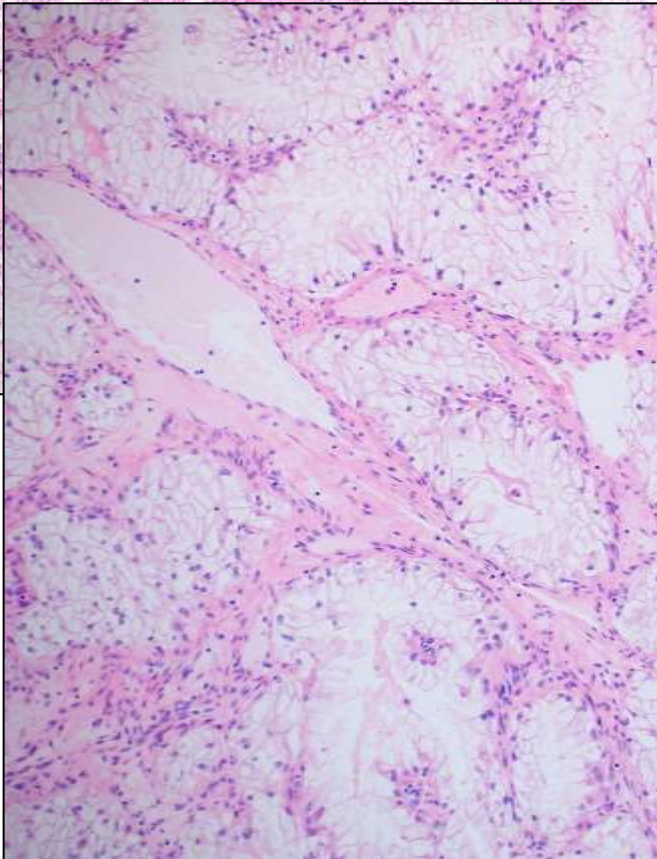
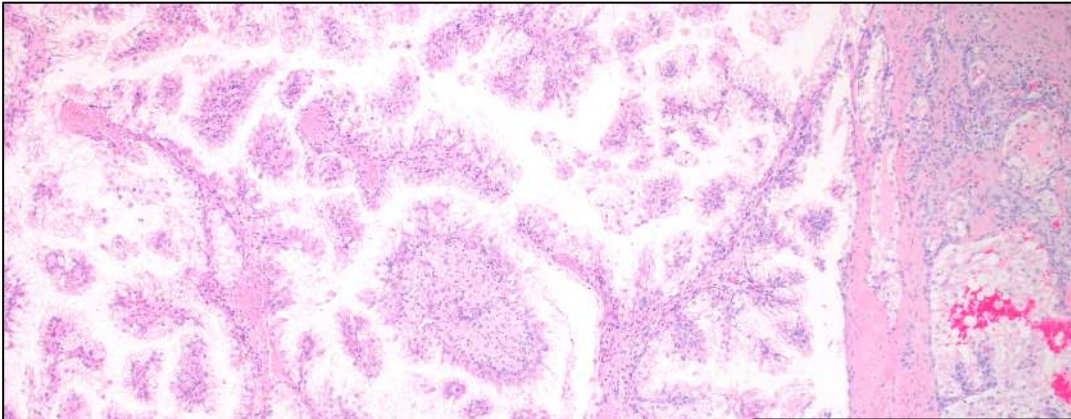






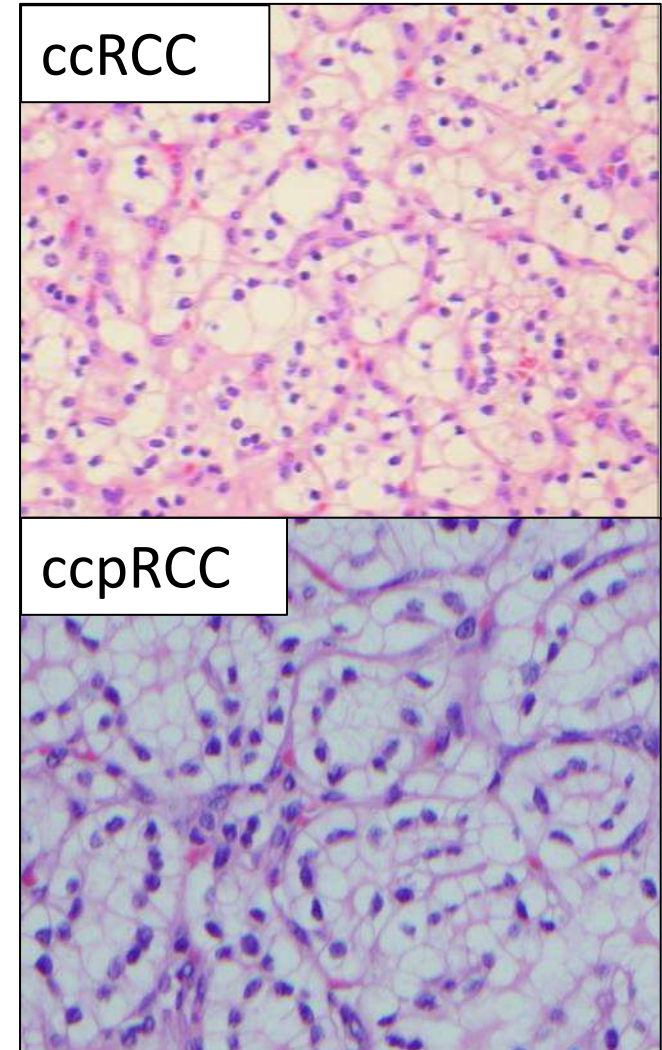


Current case

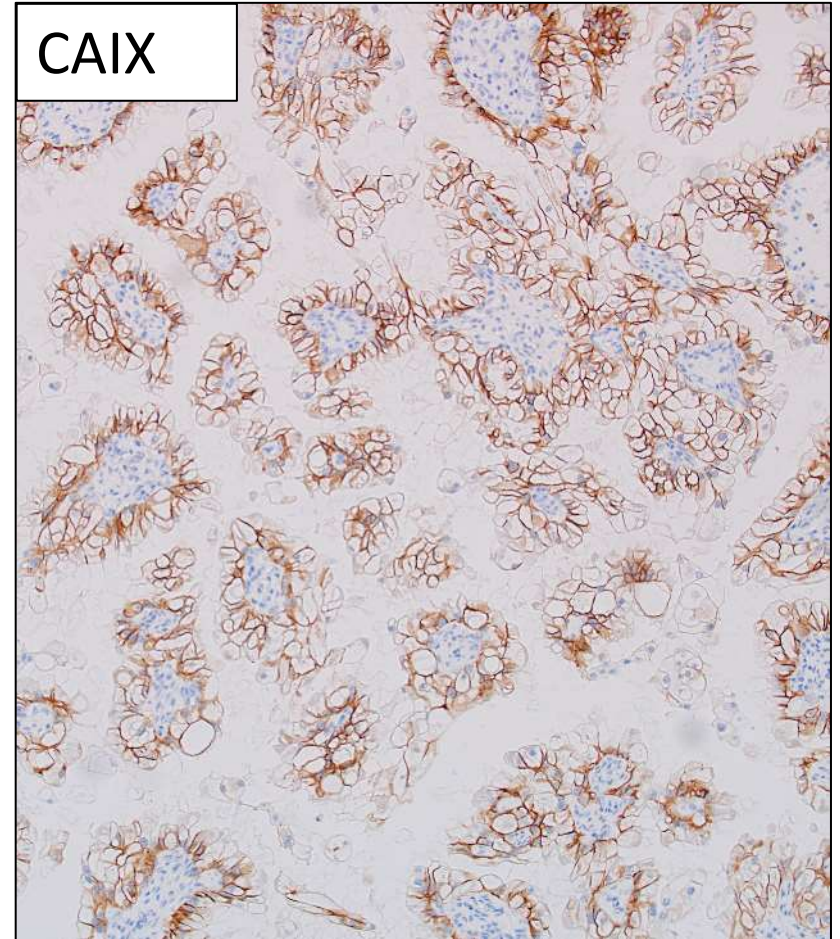
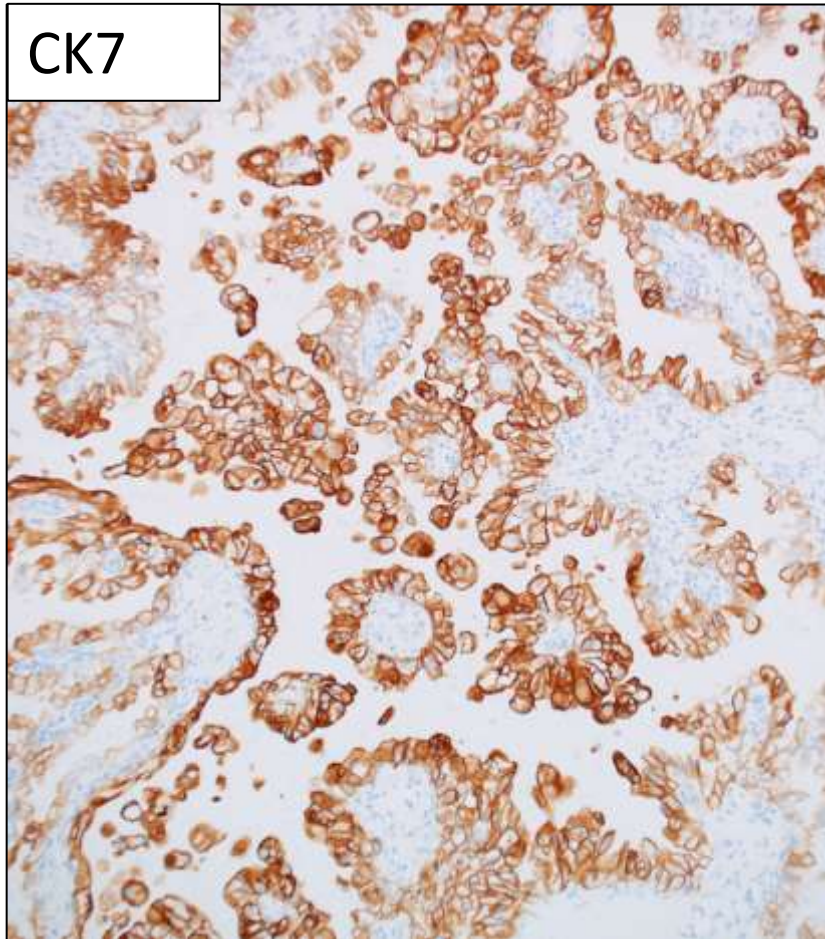


Differential diagnosis

- **RCC with leiomyomatous stroma**
- Clear cell RCC
- Clear cell papillary RCC
- Translocation associated RCC
- RCC, unclassified



Current case: IHC workup

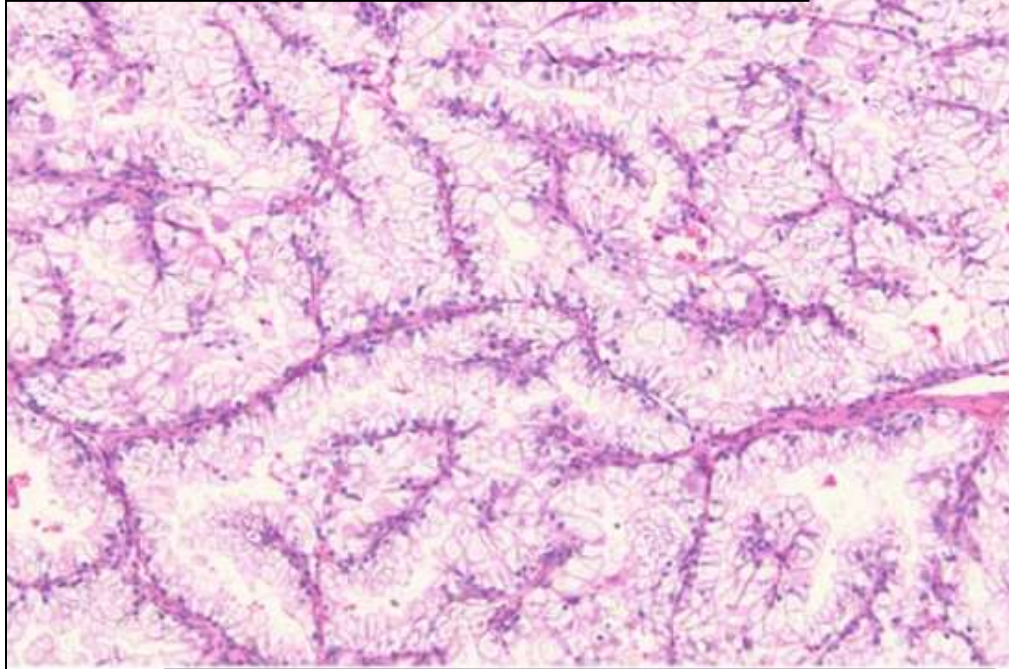


MelanA, TFE3 Negative

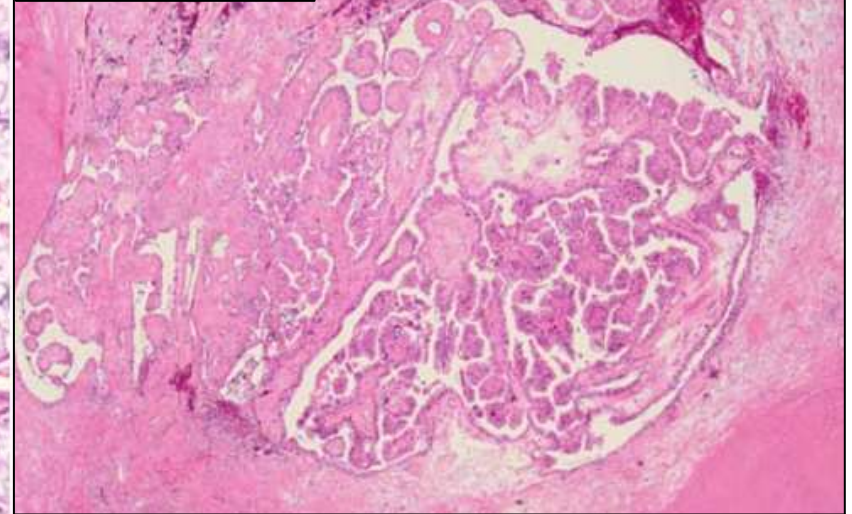
Renal cell carcinoma with leiomyomatous stroma

- 2016 WHO emerging/provisional entity
- Previously called RAT (renal angiomyoadenomatous tumor)
- Histology: Branching tubules lined by cells with abundant clear to granular cytoplasm, admixed with smooth muscle stroma
- IHC: CK7 diffuse positive, CAIX circumferential (but can have areas of cup-like)

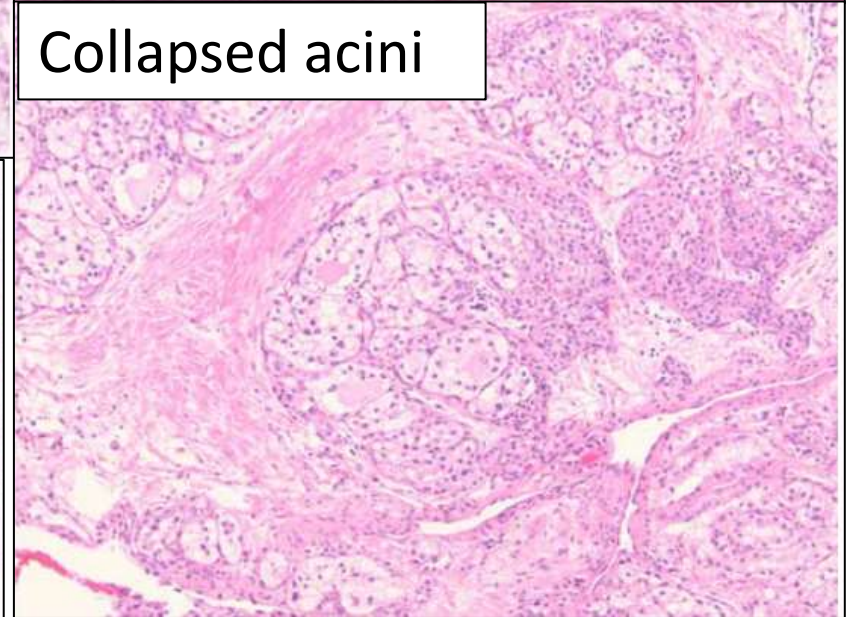
Elongated branching tubules



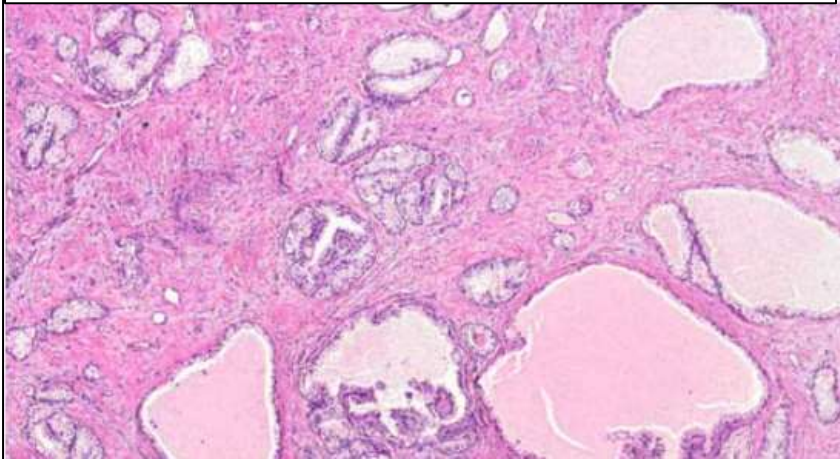
Papillary



Collapsed acini



Variable amounts of smooth muscle stroma



Genetic Underpinnings of Renal Cell Carcinoma With Leiomyomatous Stroma

*Megan Parilla, MD, Mir Alikhan, MD, Mustafa Al-Kawaaz, MD, Sushant Patil, PhD,
Sabah Kadri, PhD, Lauren L. Ritterhouse, MD, PhD, Jeremy Segal, MD, PhD,
Carrie Fitzpatrick, PhD, and Tatjana Antic, MD*

AJSP 2019

“Renal Cell Carcinoma With Leiomyomatous Stroma” Harbor Somatic Mutations of *TSC1*, *TSC2*, *MTOR*, and/or *ELOC* (*TCEB1*): Clinicopathologic and Molecular Characterization of 18 Sporadic Tumors Supports a Distinct Entity

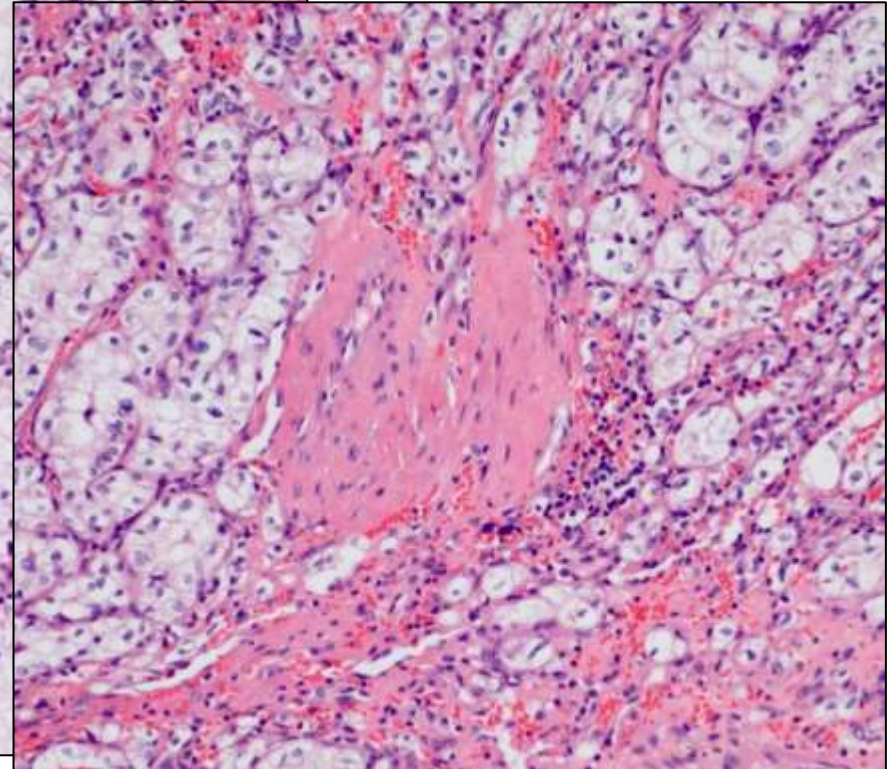
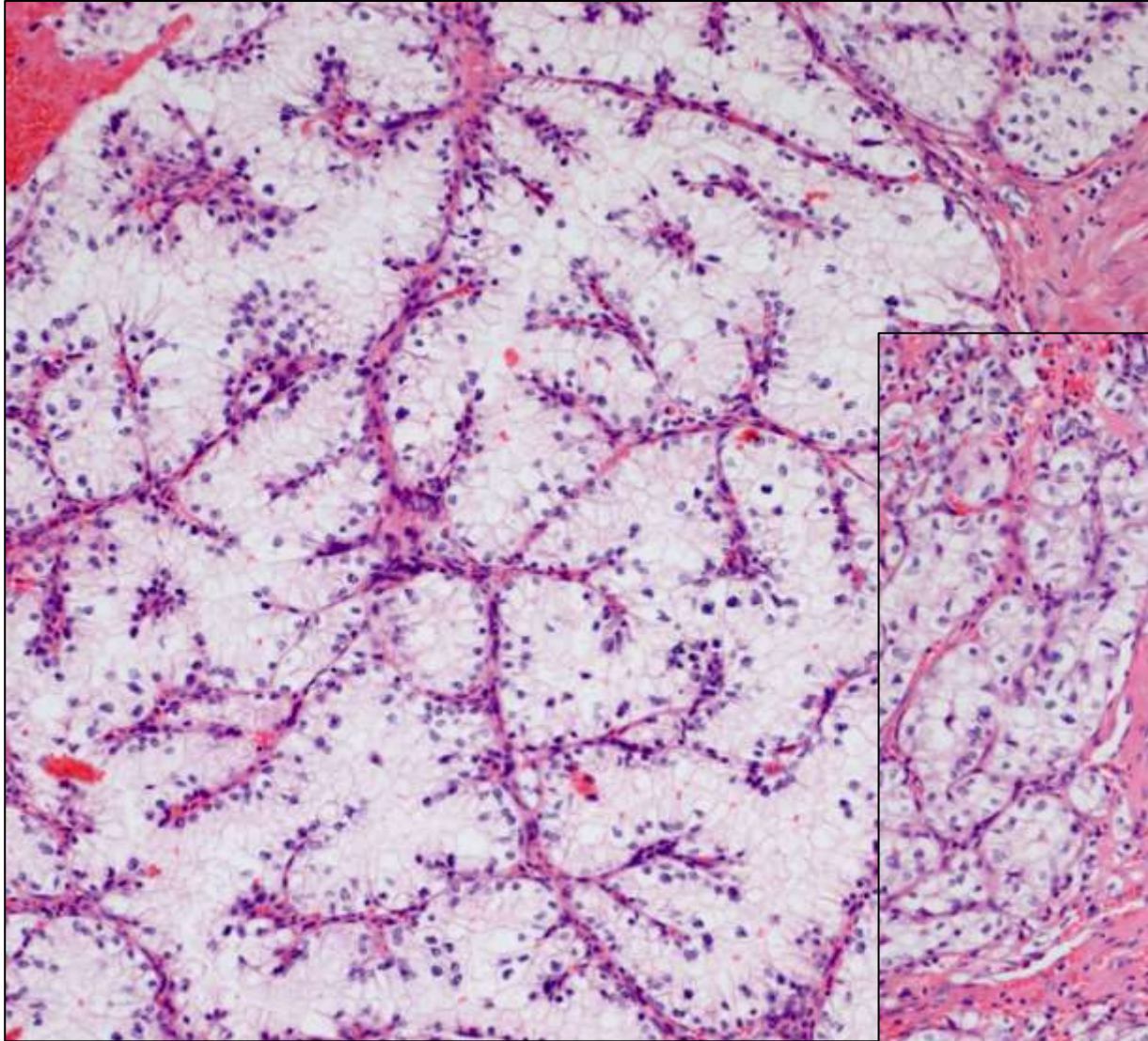
Rajal B. Shah, MD, Bradley A. Stohr, MD, PhD,† Zheng Jin Tu, PhD,* Yuan Gao, MD,‡
Christopher G. Przybycin, MD,* Jane Nguyen, MD, PhD,* Roni M. Cox, MD,*
Fariborz Rashid-Kolvear, MD,‡ Michael D. Weindel, MD,* Daniel H. Farkas, PhD, HCLD,*
Kiril Trpkov, MD,‡ and Jesse K. McKenney, MD**

AJSP 2019

Genetics of RCC with leiomyomatous stroma

- Parilla et al: 15 cases
 - TCEB1: 3 cases
 - TSC1/2: 5 cases (one with known TSC)
 - VHL: 2 cases
 - None of the above: 5 cases (likely ccpRCC?)
- Shah et al: 14 cases
 - TCEB1: 2 cases
 - TSC1/2: 7 cases
 - MTOR: 6 cases
 - *one case had both TCEB1 and TSC1 mutation

October 2018 Southbay
RCC with leiomyomatous stroma -TCEB1 mutated

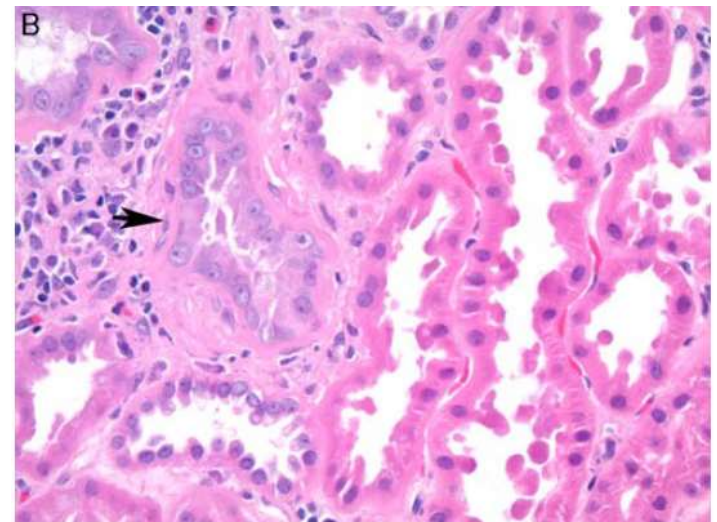
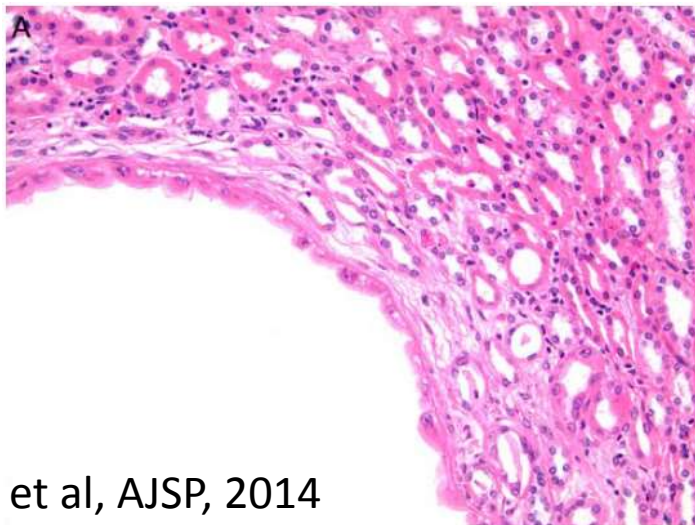
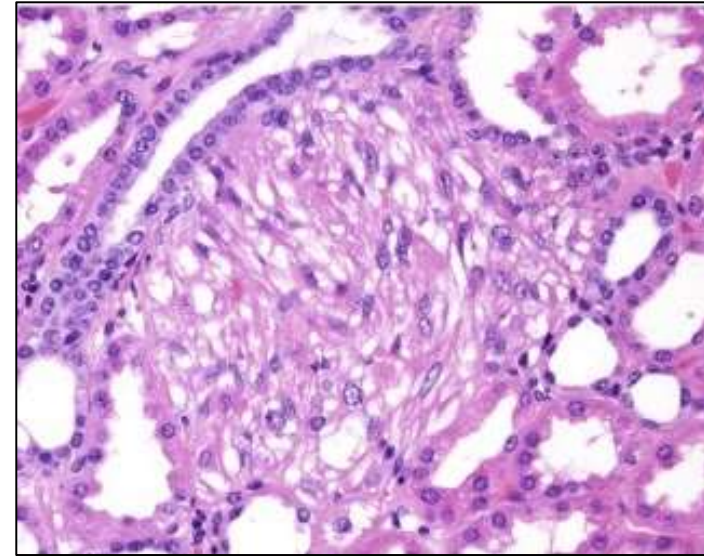


Current case UCSF500:

TSC1 p.Q654* mutation with copy neutral loss of heterozygosity of chromosome 9q

TSC1/2-mutated RCC can be germline or sporadic: Need to assess for tuberous sclerosis!

- Background kidney changes in TSC
 - AML, including tumorlets
 - Cysts lined by prominent eosinophilic cytoplasm
 - Renal tubules with cytoplasmic atypia and/or peritubular hyalinization
- Recommend genetic counseling



Diagnosis without Molecular Available

- RCC with leiomyomatous stroma
- CK7 and CAIX positive
- Many have underlying mutations in either TCEB1, TSC1/2, or MTOR. Molecular testing can be performed to distinguish these possibilities if clinically indicated.
- Recommend genetic counseling (particularly if young or see any features of TSC in background kidney-need to look!)
- Thought to be more clinically indolent than ccRCC

Putative Drivers of Aggressiveness in *TCEB1*-mutant Renal Cell Carcinoma: An Emerging Entity with Variable Clinical Course

Renzo G. DiNatale^{a,b,c}, Alexander N. Gorelick^{c,d}, Vladimir Makarov^b, Kyle A. Blum^a, Andrew W. Silagy^a, Benjamin Freeman^a, Diego Chowell^b, Julian Marcon^a, Roy Mano^a, Alex Sanchez^a, Kyrollis Attalla^a, Stanley Weng^a, Martin Voss^e, Robert J. Motzer^e, Paul Russo^a, Jonathan A. Coleman^a, Victor E. Reuter^f, Ying-Bei Chen^f, Timothy A. Chan^b, Ed Reznik^c, Satish K. Tickoo^{f,*}, A. Ari Hakimi^{a,*}

- Identified 4 cases with high stage disease
 - Two cases with metastatic disease
 - Three cases pT3 or higher
 - Two cases WHO grade 3/4

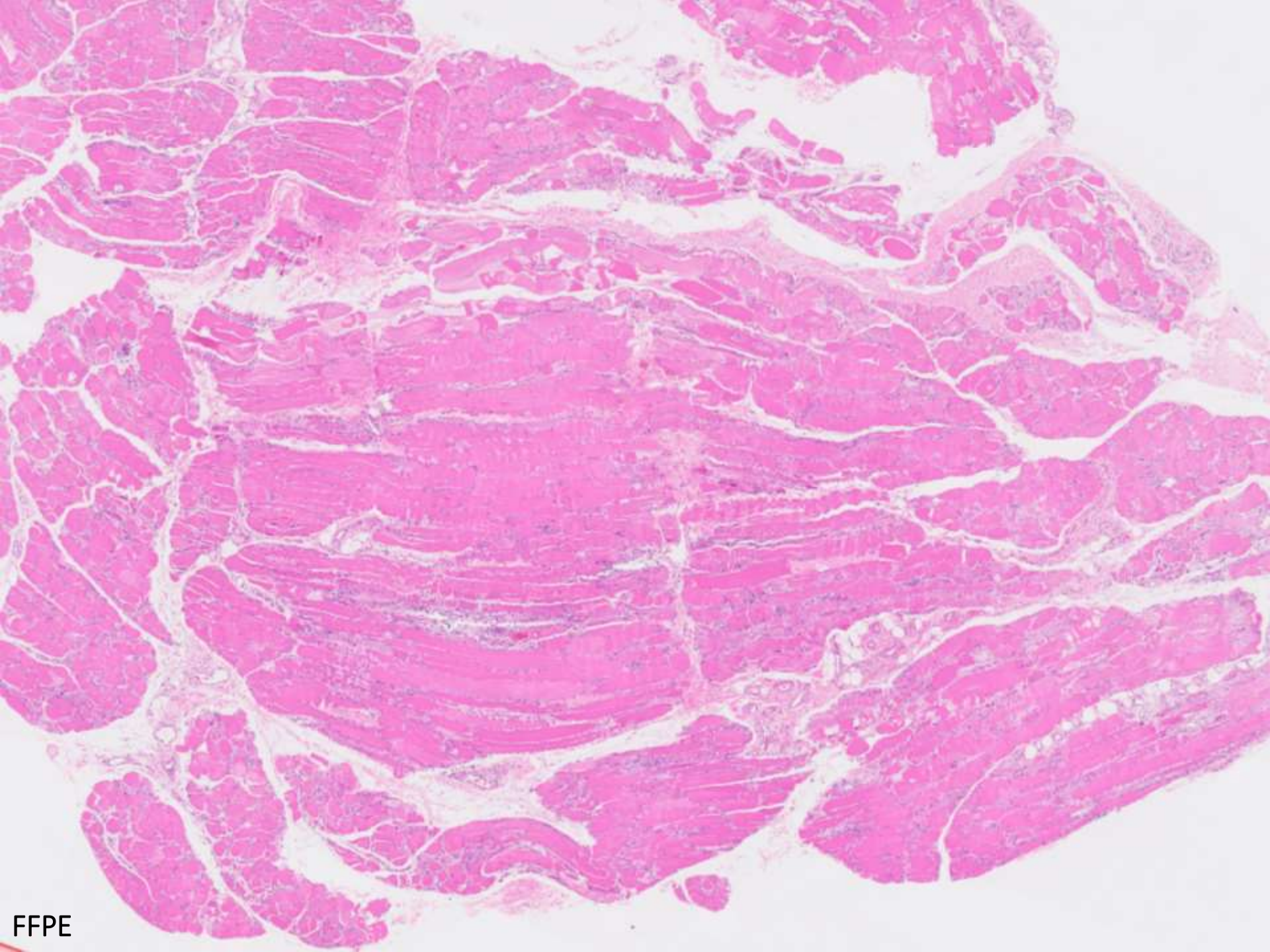
Diagnosis without Molecular Available

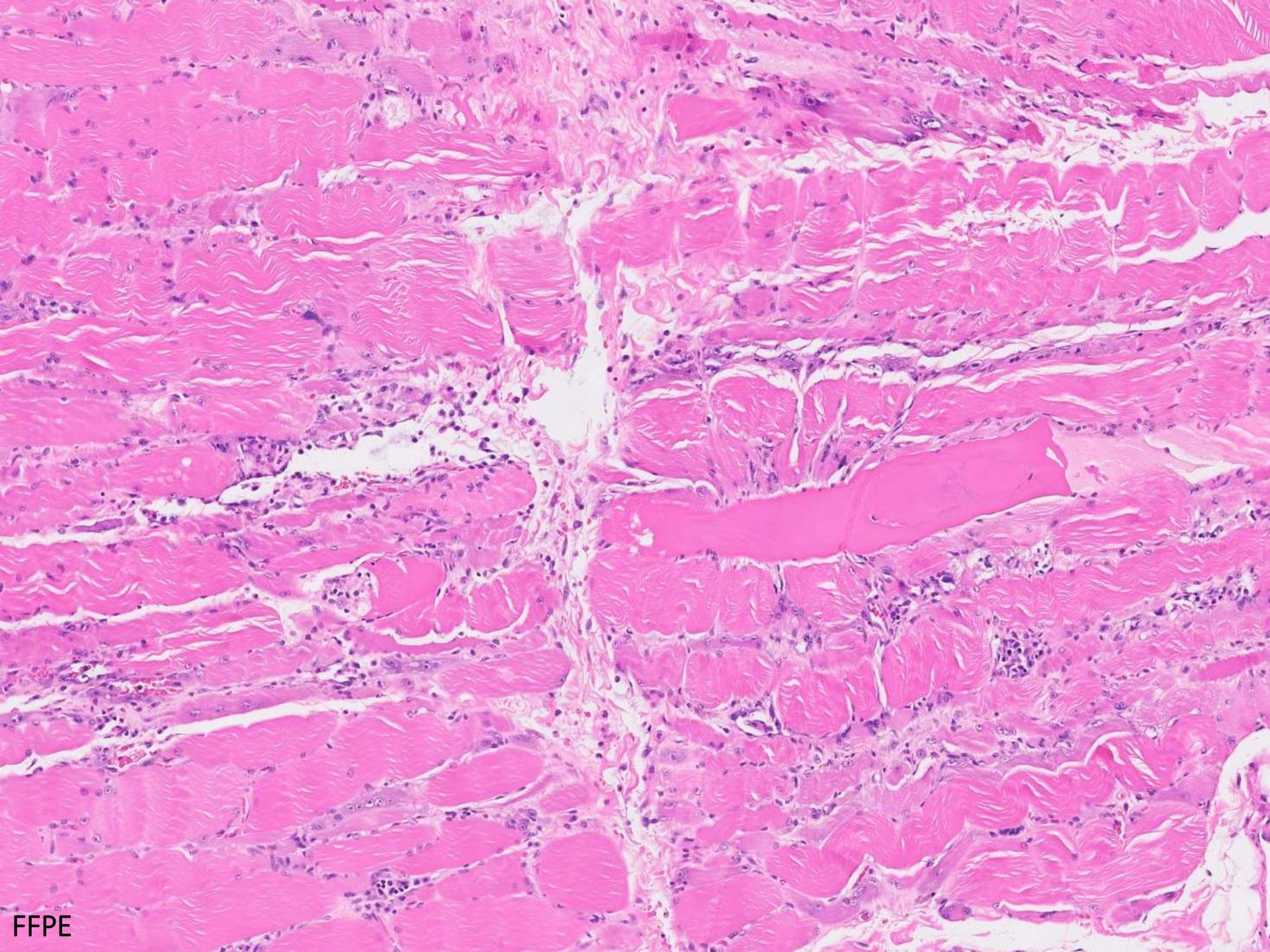
- RCC with leiomyomatous stroma
- CK7 and CAIX positive
- Many have underlying mutations in either TCEB1, TSC1/2, MTOR. Molecular testing can be performed to distinguish these possibilities if clinically indicated.
- Recommend genetic counseling (particularly if young or see any features of TSC in background kidney-need to look!)
- ~~Thought to be more clinically indolent than ccRCC~~

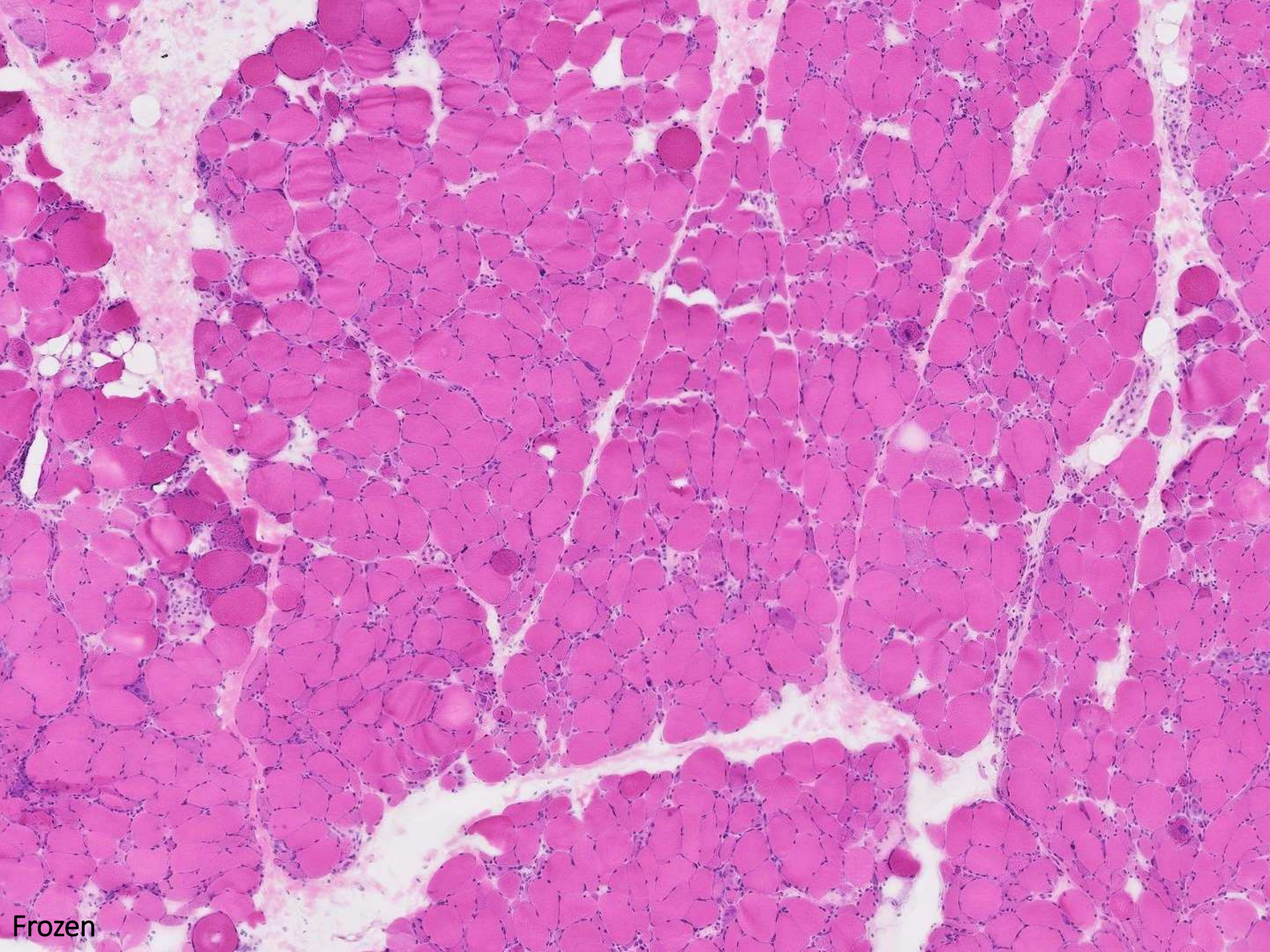
20-0203

Romain Cayrol/Hannes Vogel; Stanford

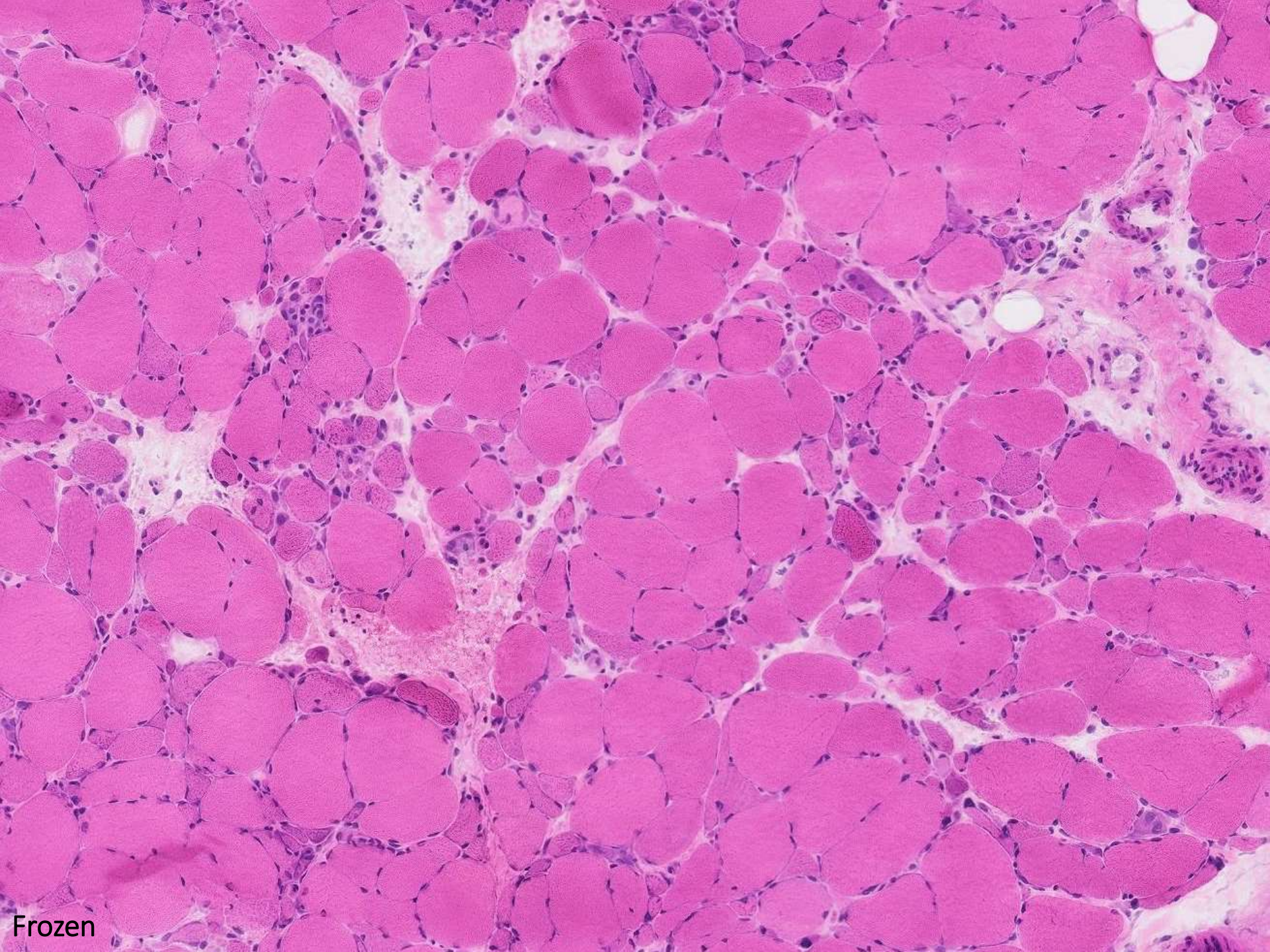
48-year-old F who presents with progressive proximal muscle weakness for 3 months. H/O stage III serous ovarian cancer Dx in 2016, Tx w/chemo+XRT. Recurrence in 2018 Tx with XRT+pembrolizumab (anti-PD1). Progression of disease Tx w/olaparib (PARP inhibitor). CK up to 1758U/L. Electrodiagnostic studies show mixed myopathic & neurogenic abnormalities, most c/w a diffuse myopathy w/secondary denervation.



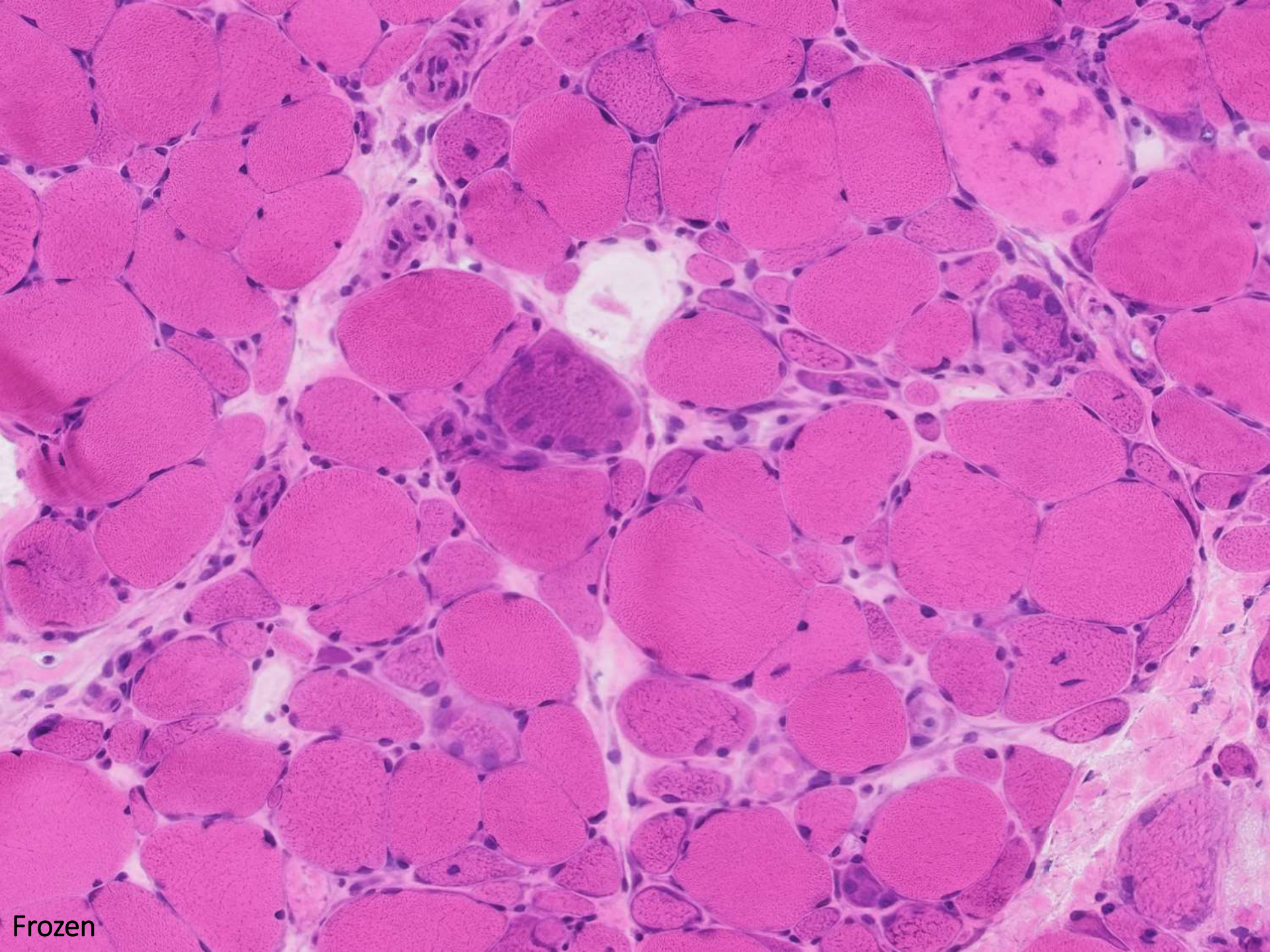




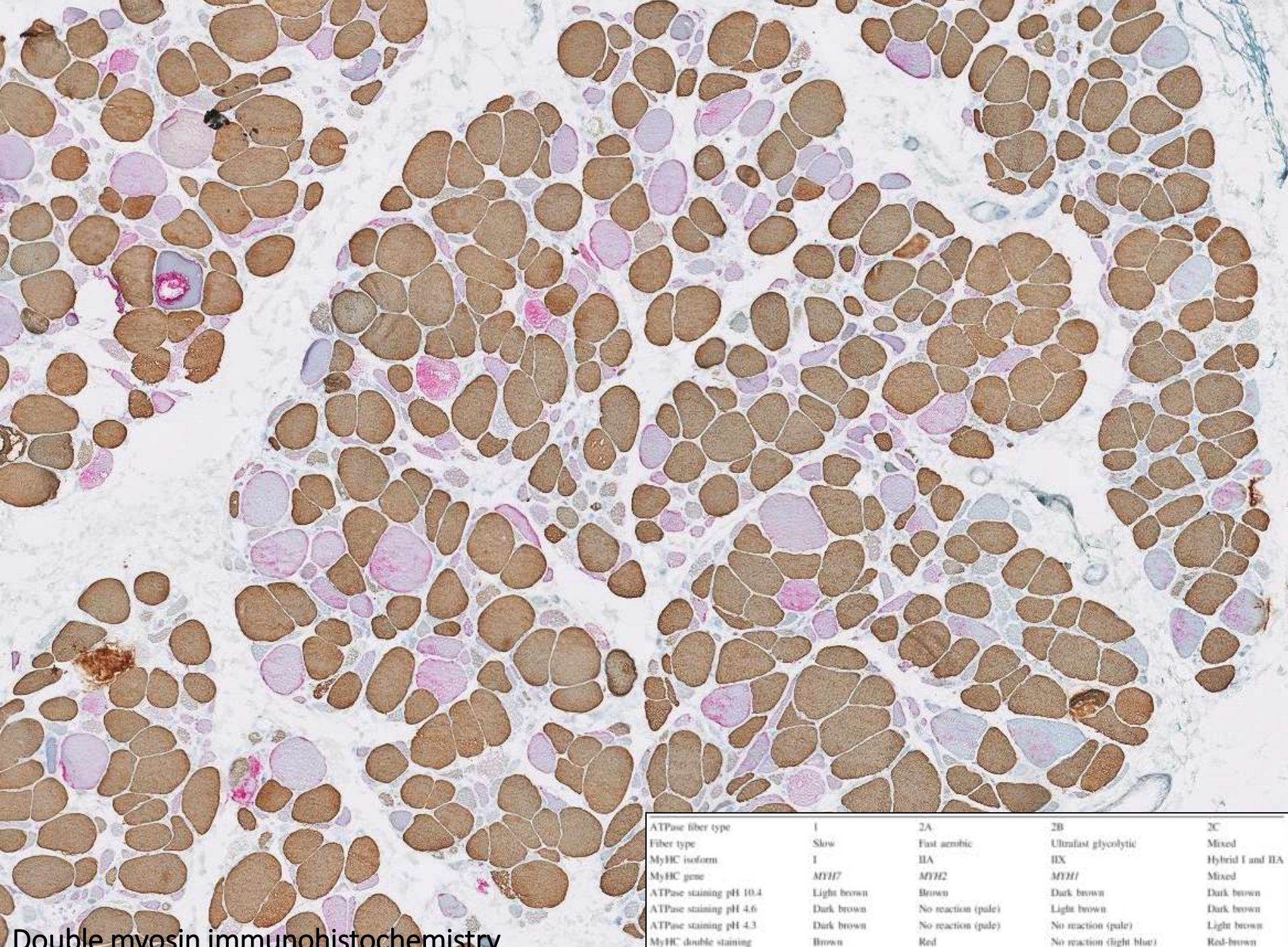
Frozen



Frozen

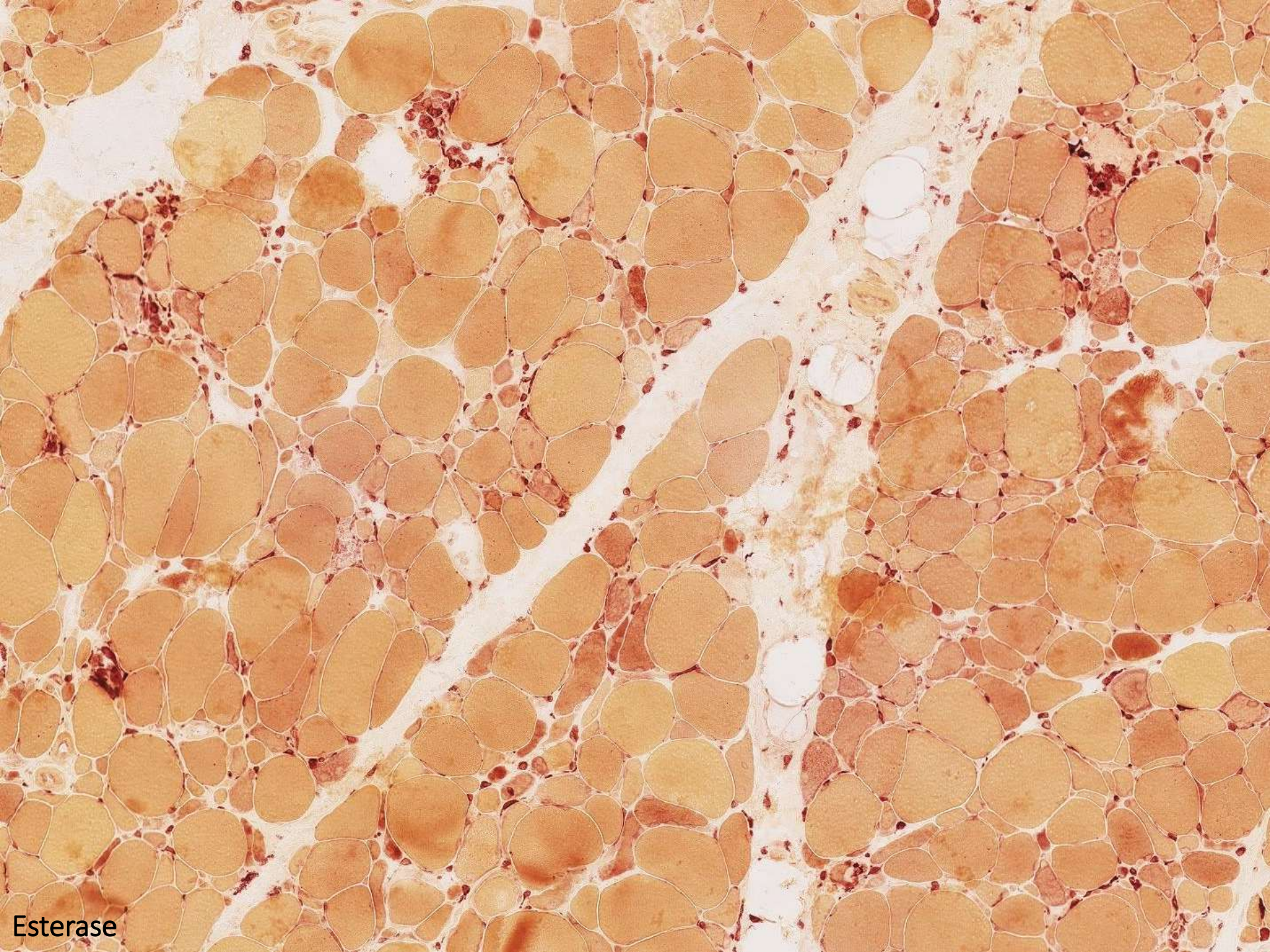


Frozen

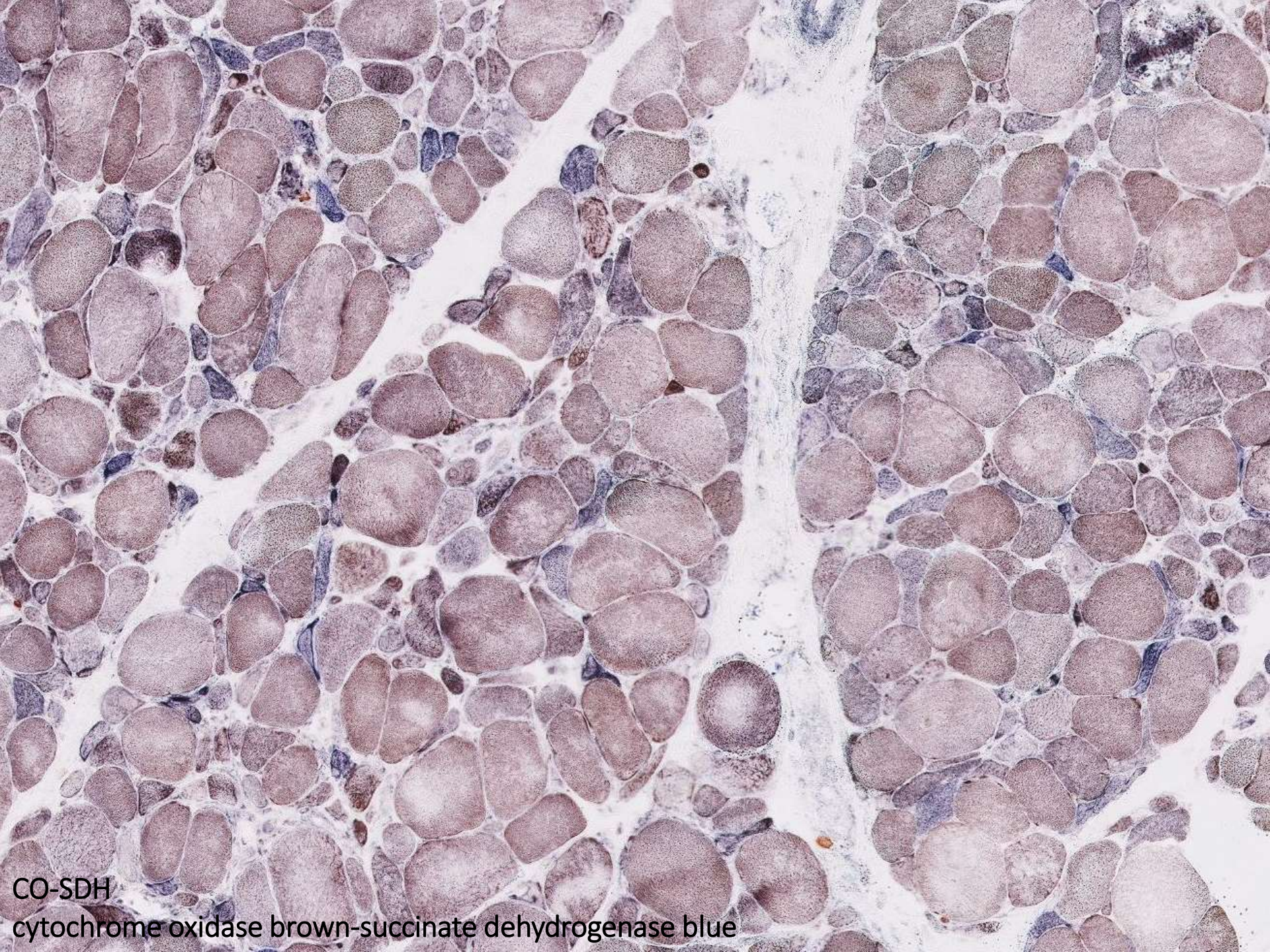


ATPase fiber type	I	2A	2B	2C
Fiber type	Slow	Fast aerobic	Ultrafast glycolytic	Mixed
MyHC isoform	I	IIA	IIx	Hybrid I and IIA
MyHC gene	<i>MYH7</i>	<i>MYH2</i>	<i>MYH1</i>	Mixed
ATPase staining pH 10.4	Light brown	Brown	Dark brown	Dark brown
ATPase staining pH 4.6	Dark brown	No reaction (pale)	Light brown	Dark brown
ATPase staining pH 4.3	Dark brown	No reaction (pale)	No reaction (pale)	Light brown
MyHC double staining	Brown	Red	No reaction (light blue)	Red-brown

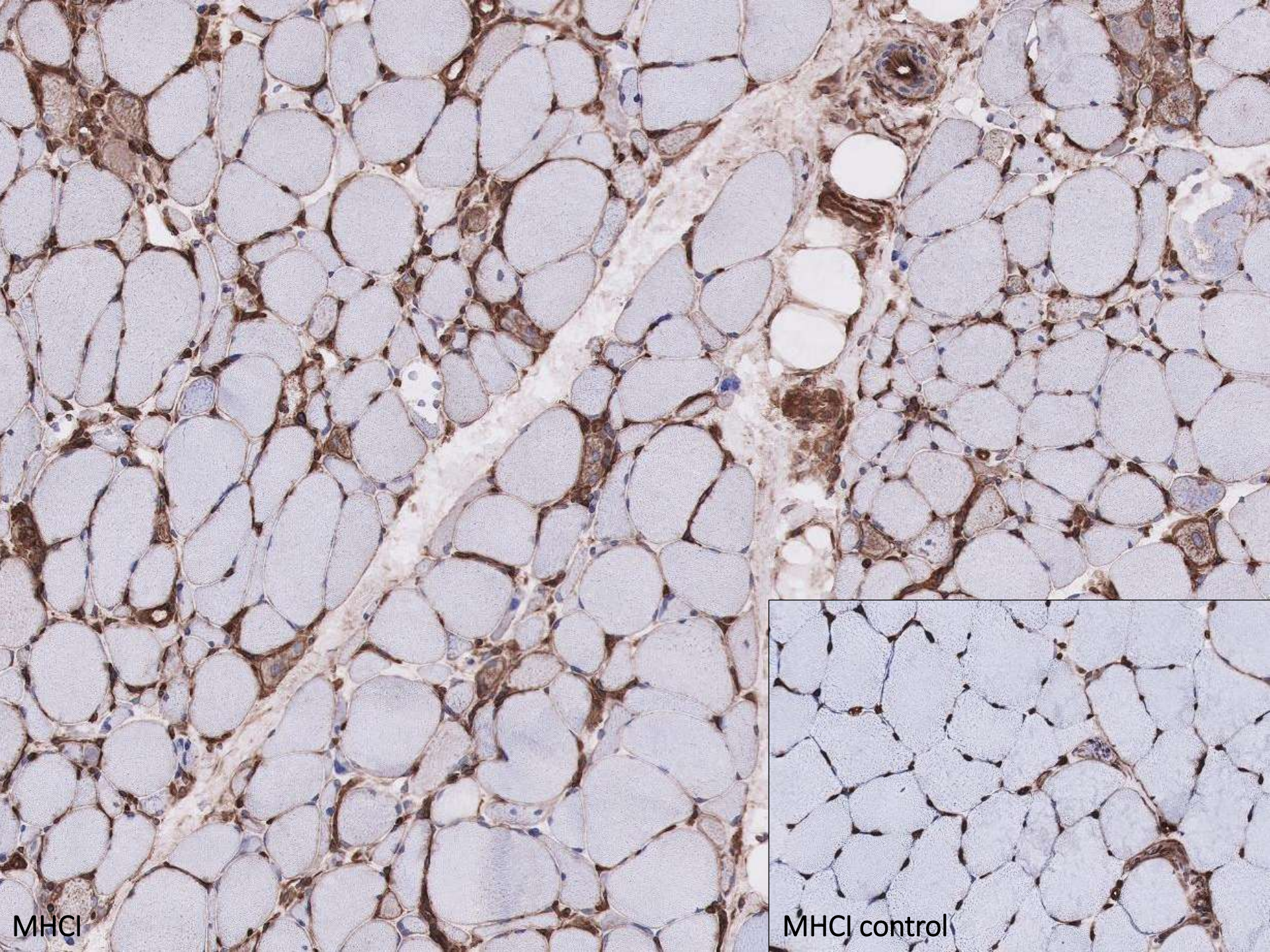
Double myosin immunohistochemistry



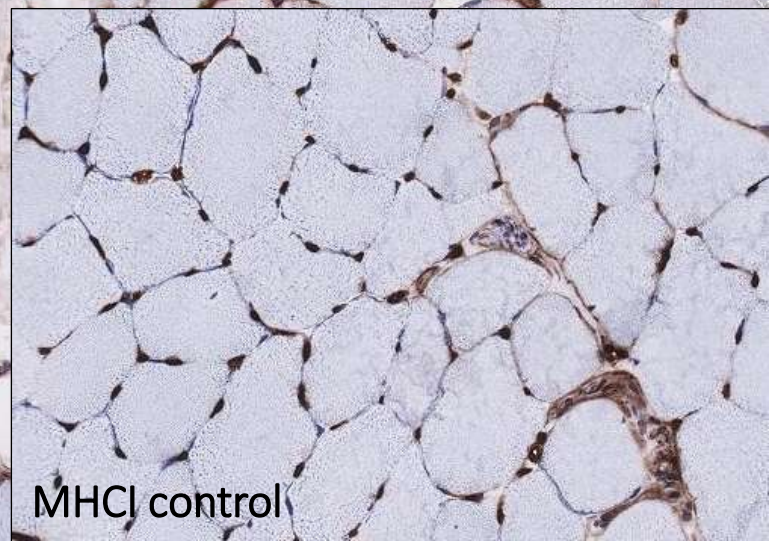
Esterase



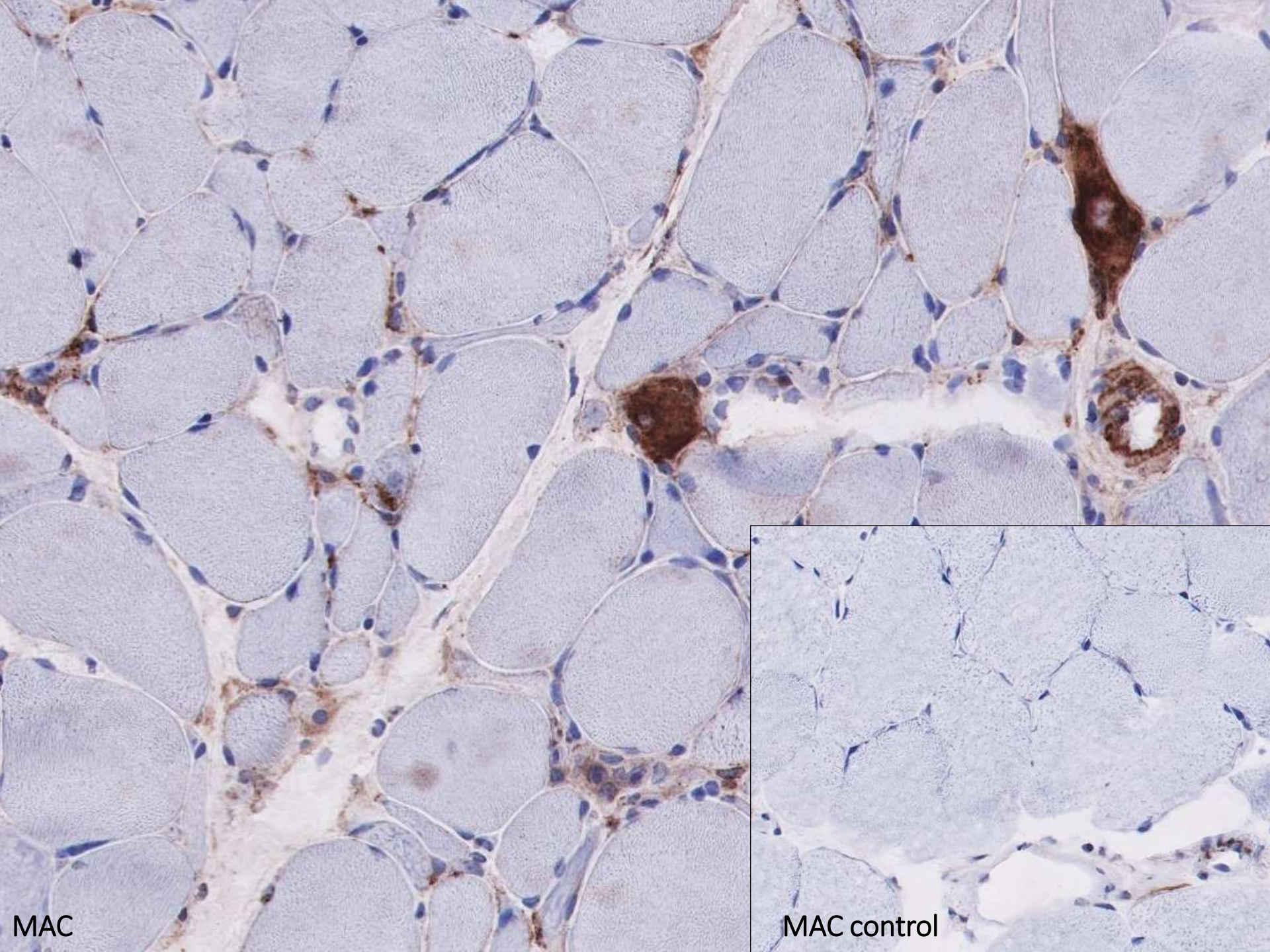
CO-SDH
cytochrome oxidase brown-succinate dehydrogenase blue



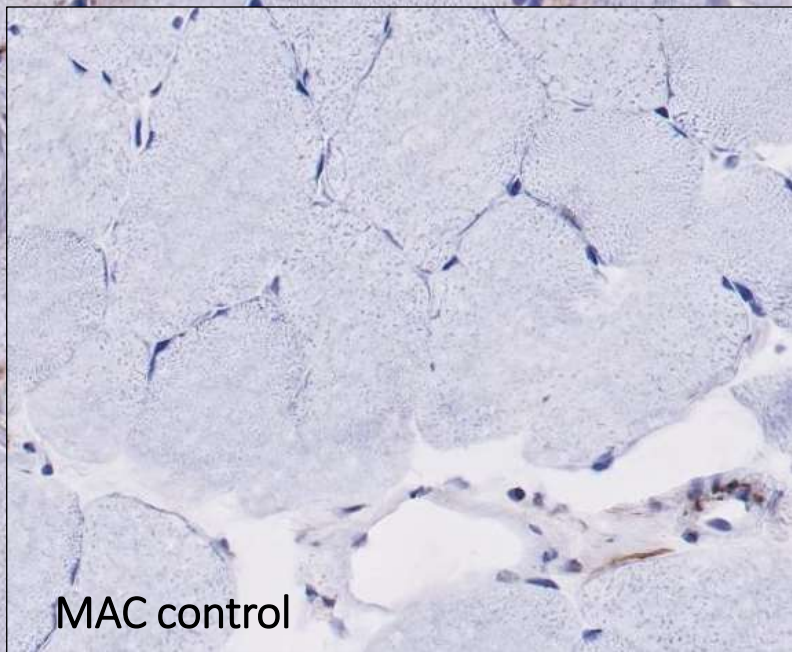
MHC



MHC control

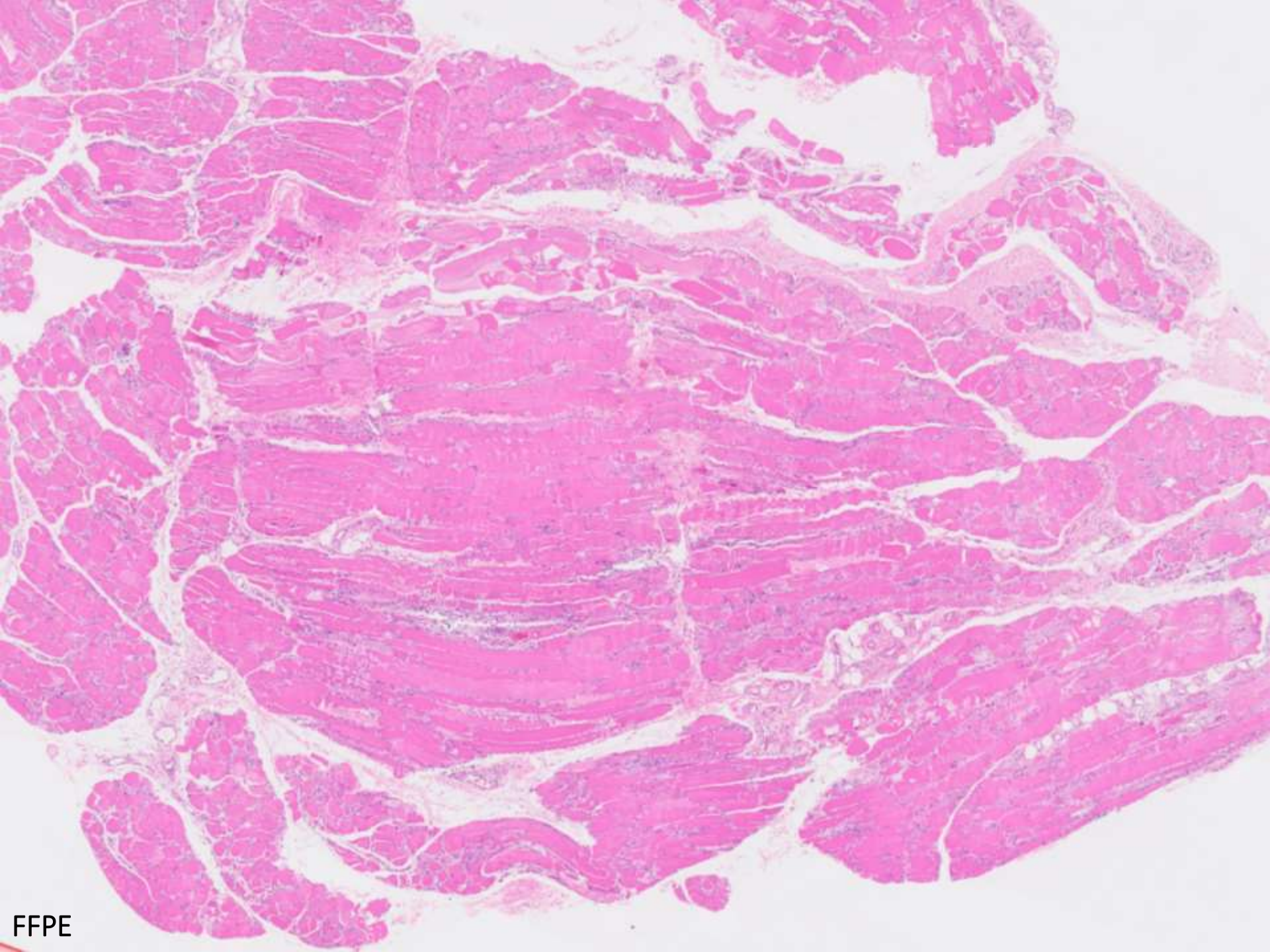


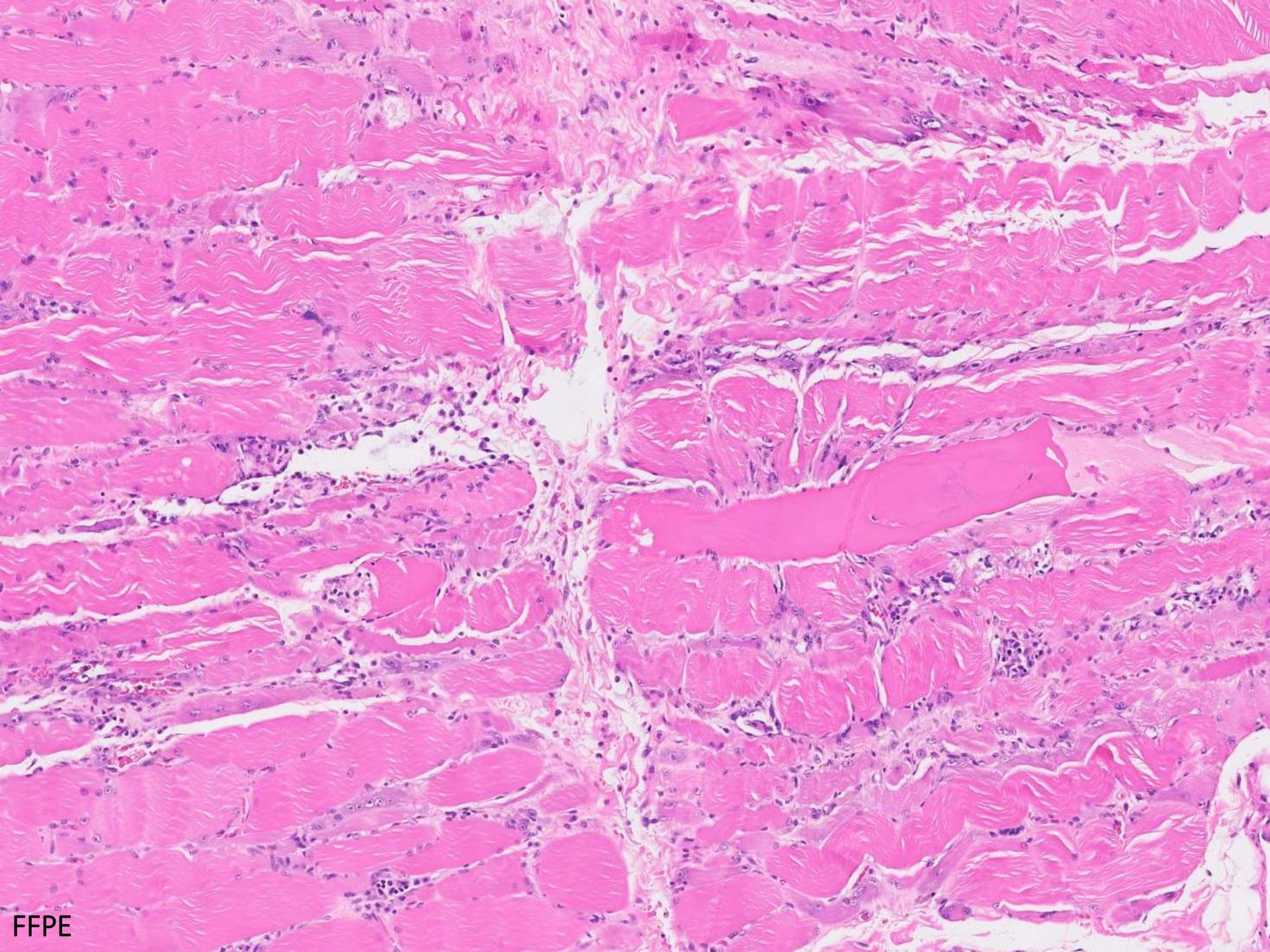
MAC

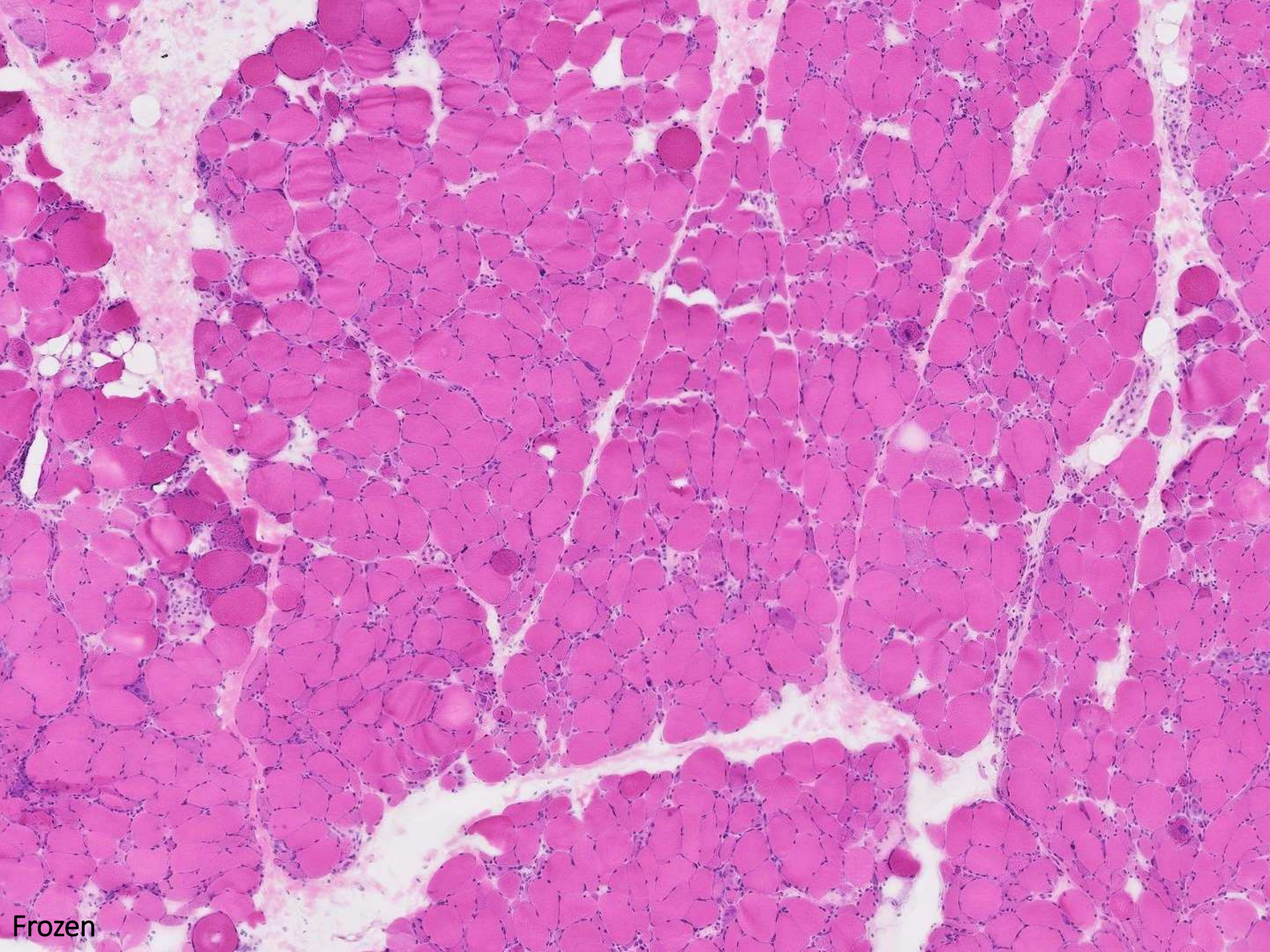


MAC control

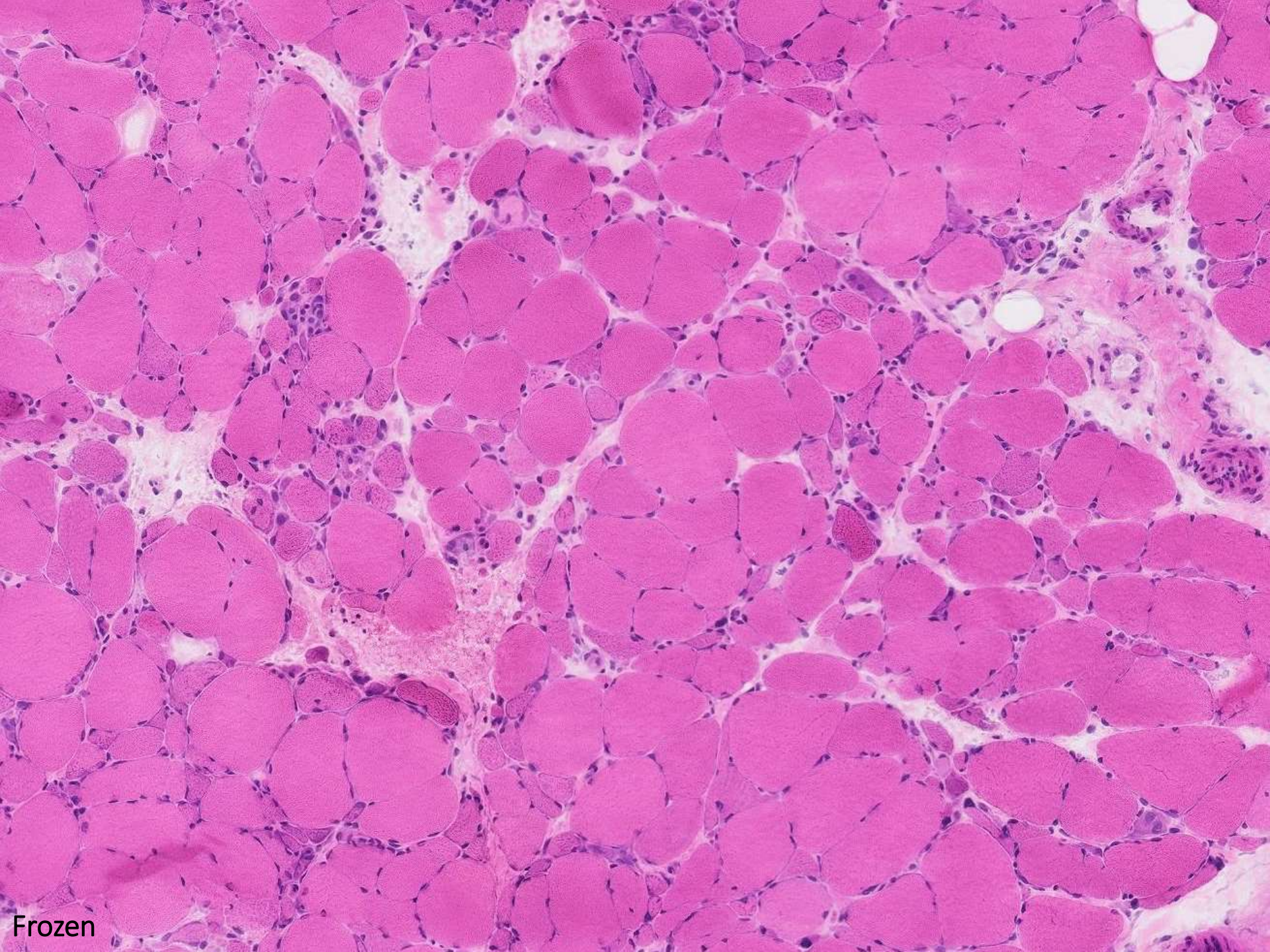
- 48 year old female with who presents progressive proximal muscle weakness for 3 month
- History of stage III serous ovarian cancer dx 2016 treated with chemotherapy and radiation
- Recurrence in 2018 treated with radiation and pembrolizumab (anti-PD1). Progression of disease treated with olaparib (PARP inhibitor)
- CK up to 1758 U/L
- Electrodiagnostic studies show mixed myopathic and neurogenic abnormalities, most consistent with a diffuse myopathy with secondary denervation



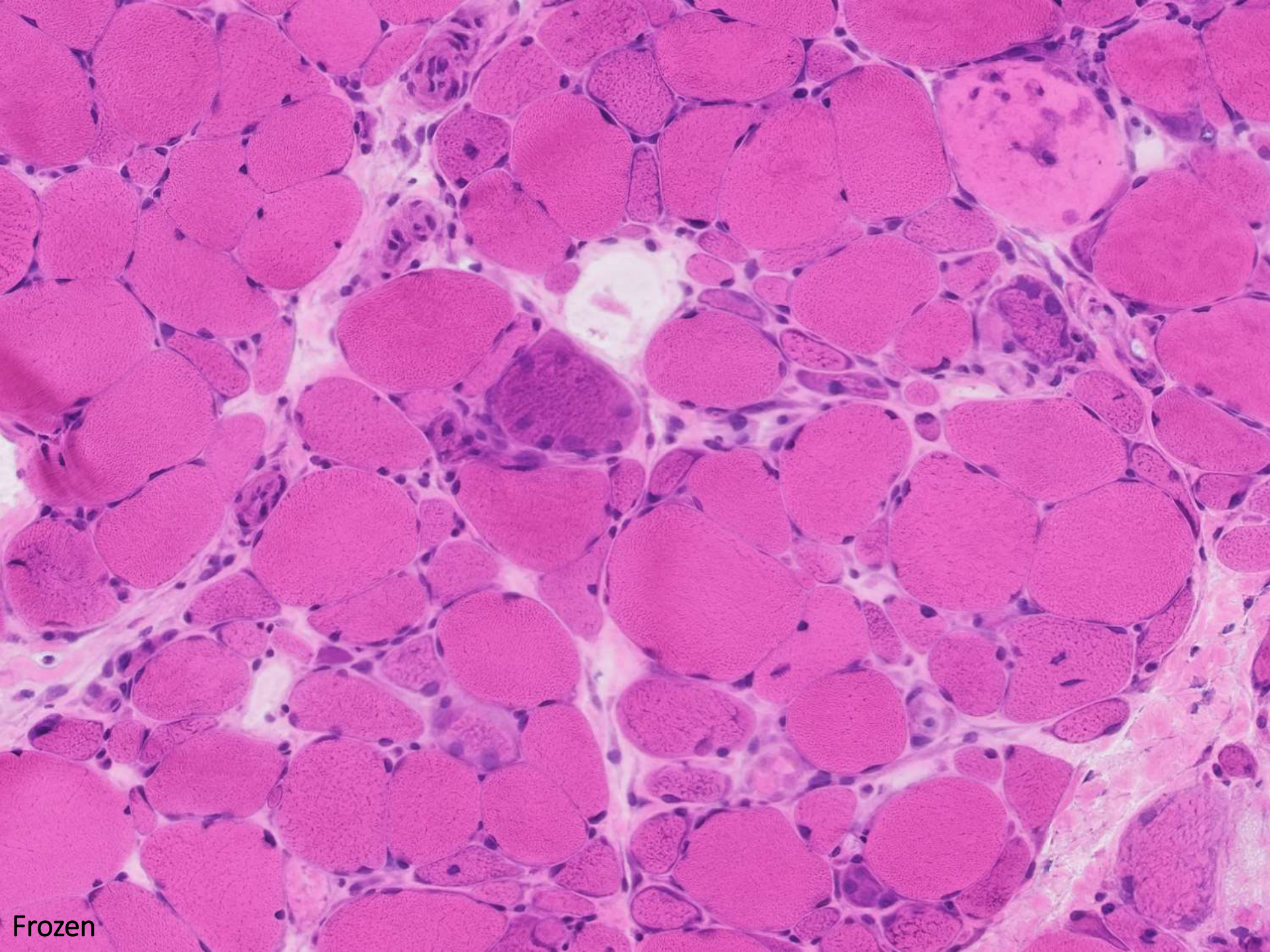




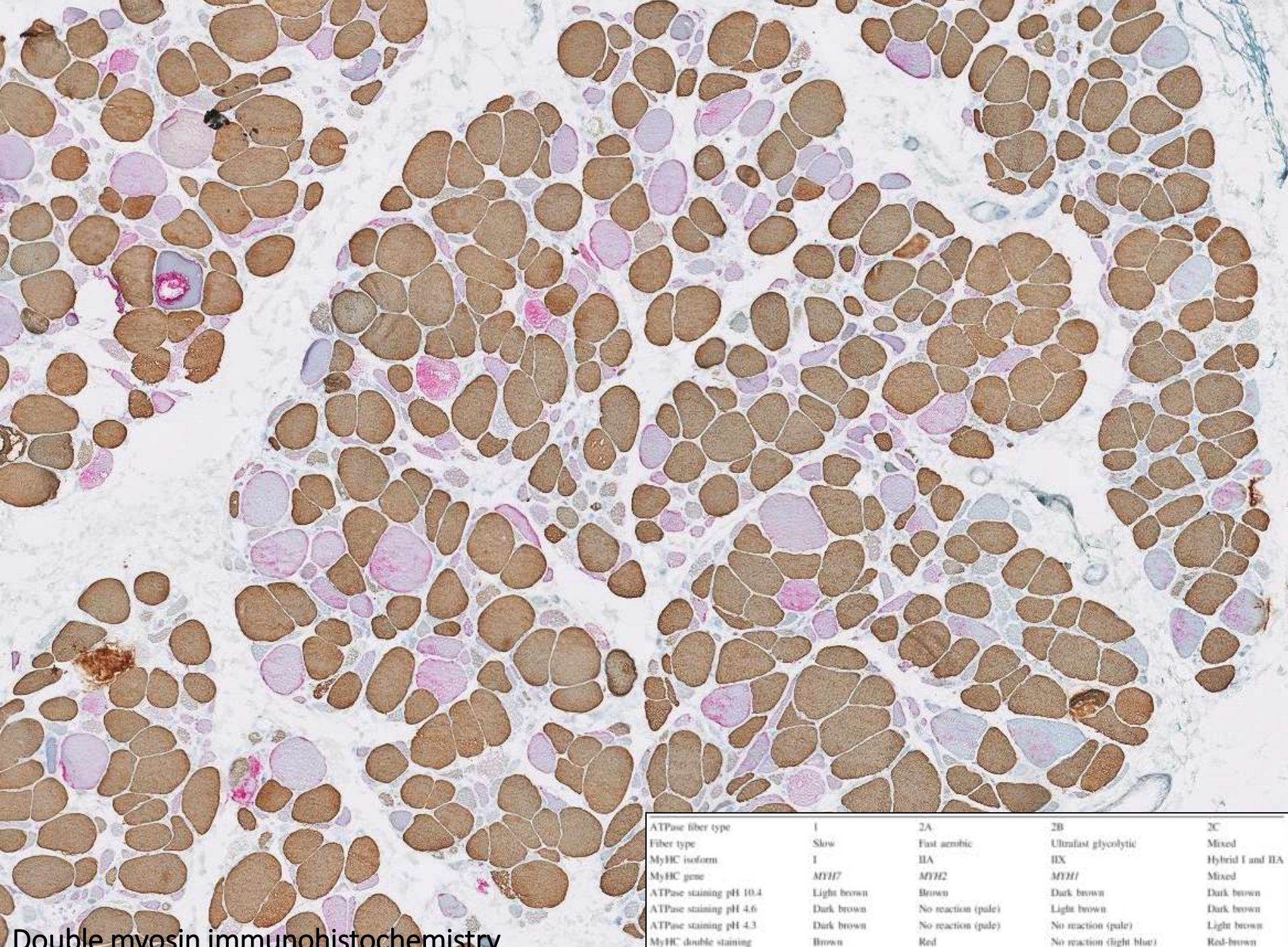
Frozen



Frozen

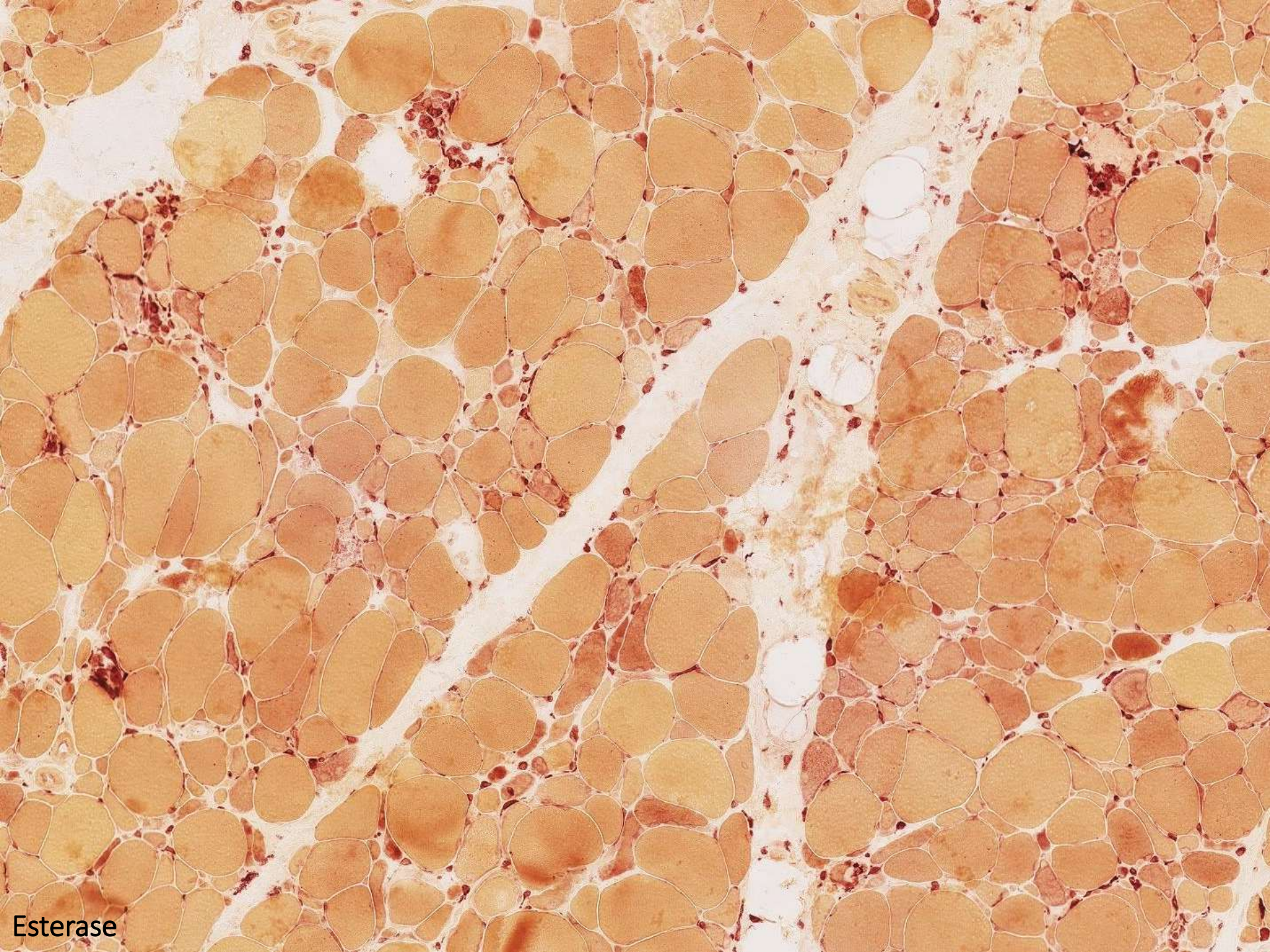


Frozen

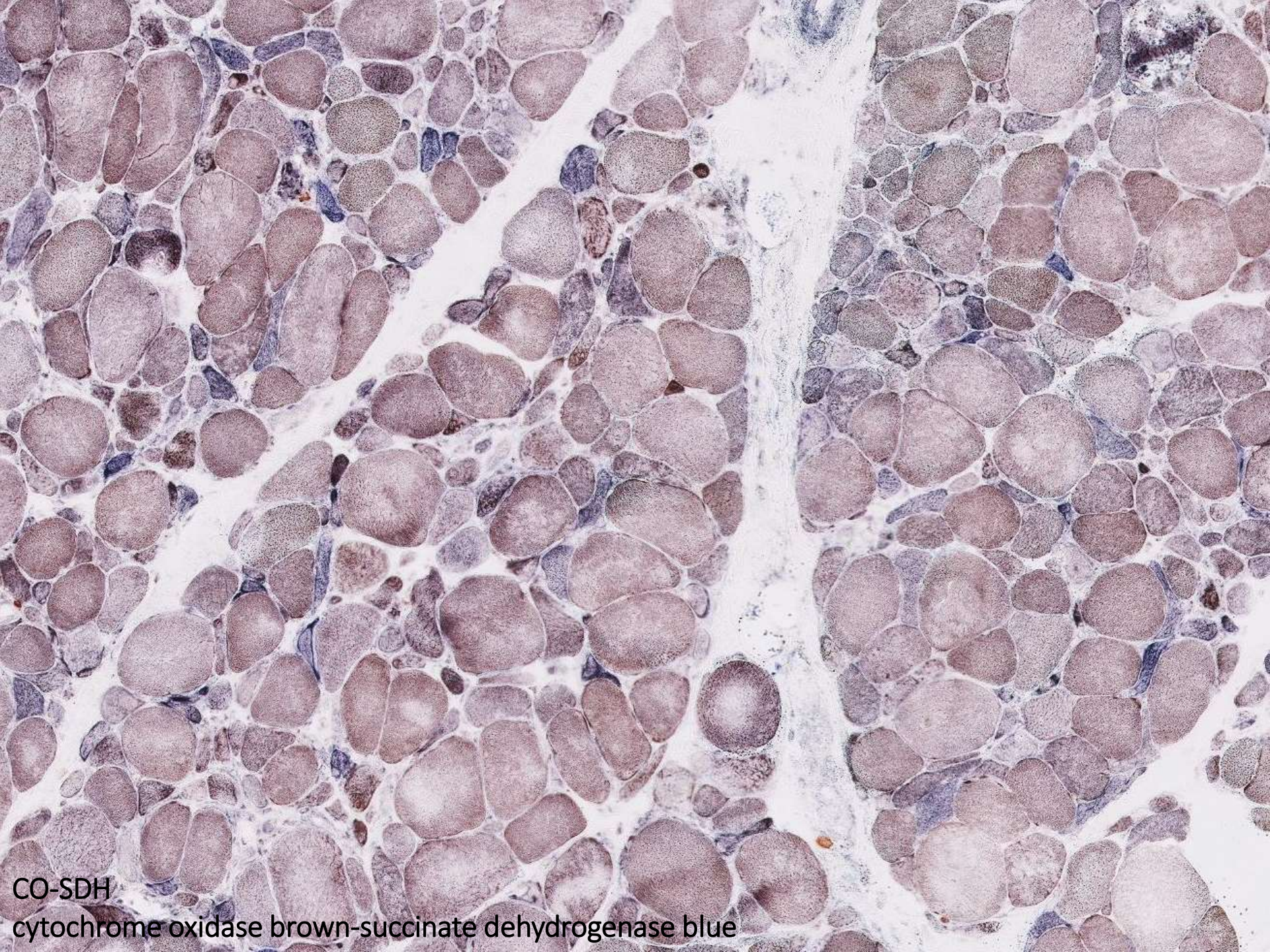


ATPase fiber type	1	2A	2B	2C
Fiber type	Slow	Fast aerobic	Ultrafast glycolytic	Mixed
MyHC isoform	I	IIA	IX	Hybrid I and IIA
MyHC gene	<i>MYH7</i>	<i>MYH2</i>	<i>MYH1</i>	Mixed
ATPase staining pH 10.4	Light brown	Brown	Dark brown	Dark brown
ATPase staining pH 4.6	Dark brown	No reaction (pale)	Light brown	Dark brown
ATPase staining pH 4.3	Dark brown	No reaction (pale)	No reaction (pale)	Light brown
MyHC double staining	Brown	Red	No reaction (light blue)	Red-brown

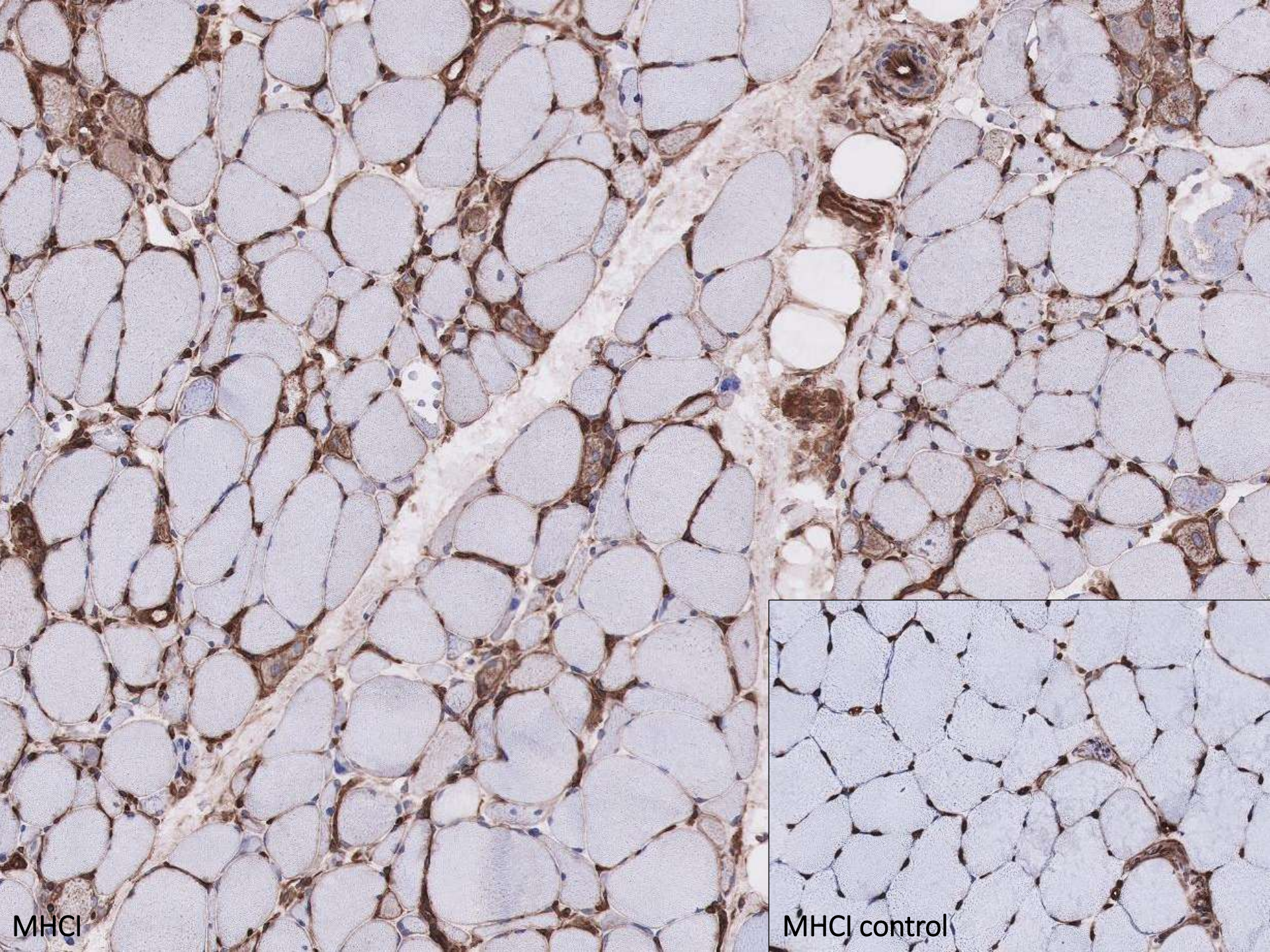
Double myosin immunohistochemistry



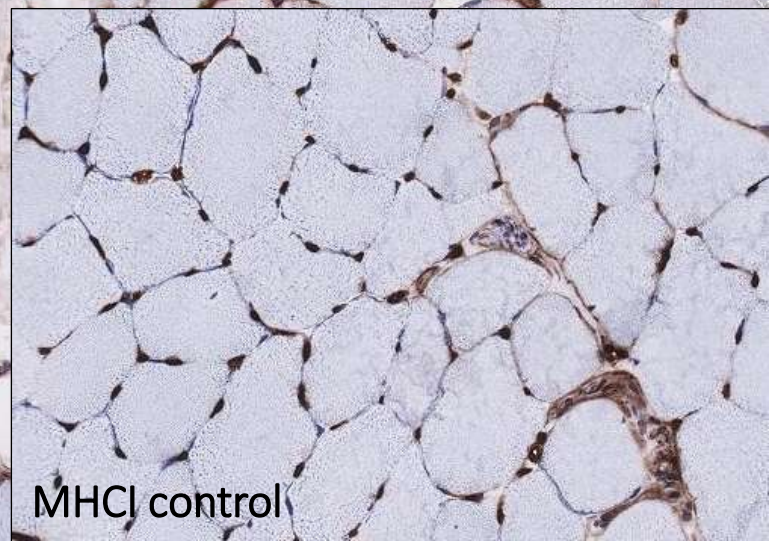
Esterase



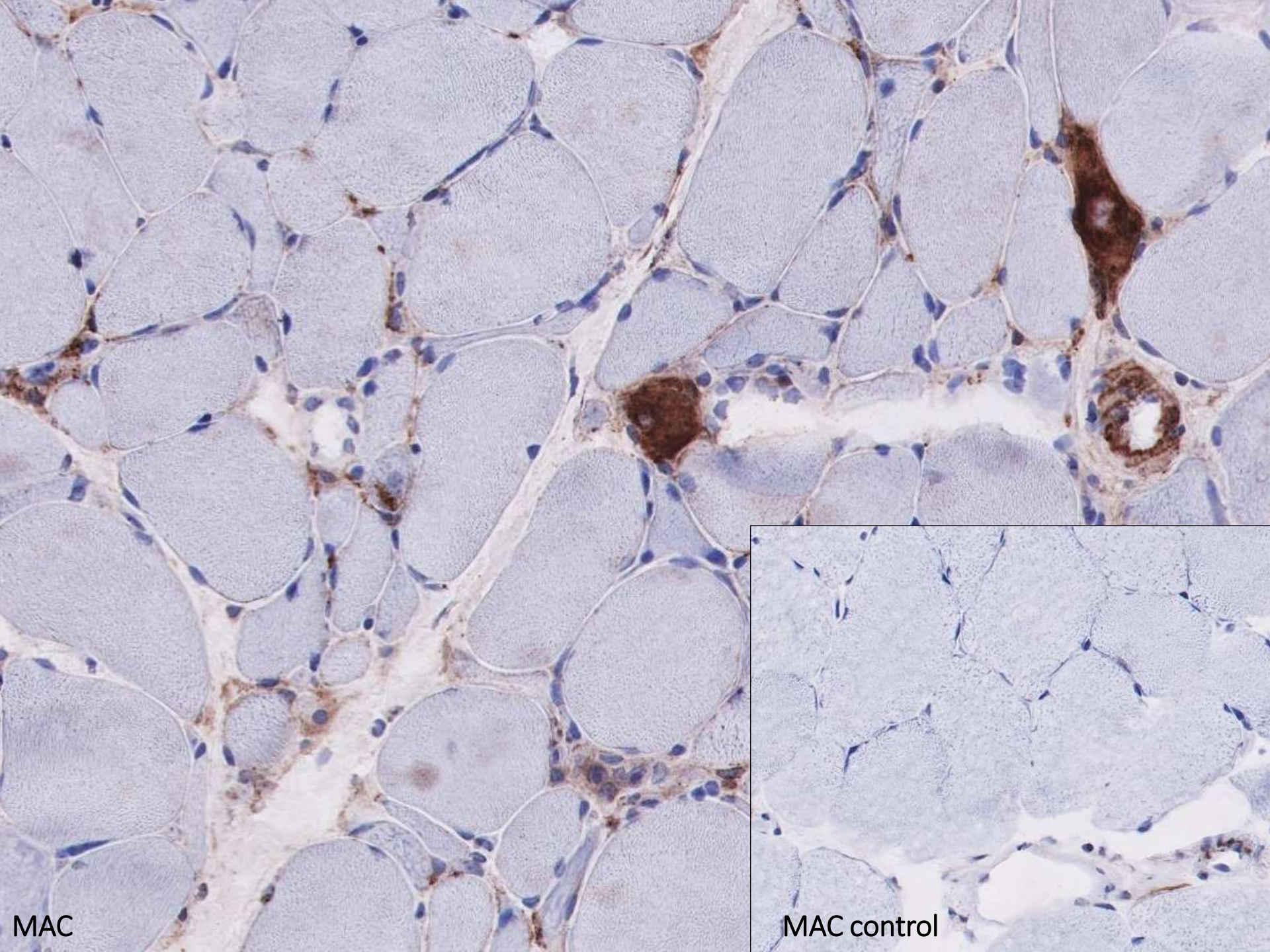
CO-SDH
cytochrome oxidase brown-succinate dehydrogenase blue



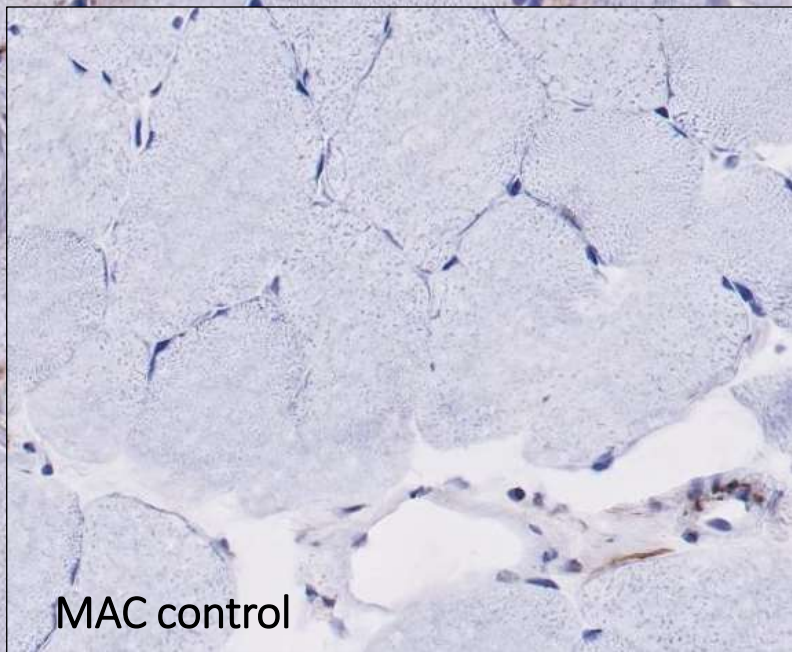
MHC1



MHC1 control



MAC



MAC control

Diagnosis

- SKELETAL MUSCLE, RIGHT BICEP, BIOPSY



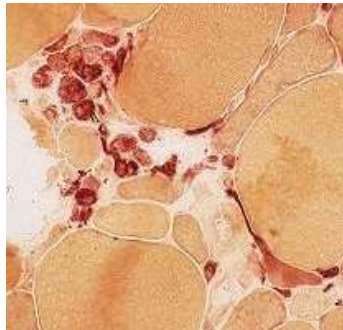
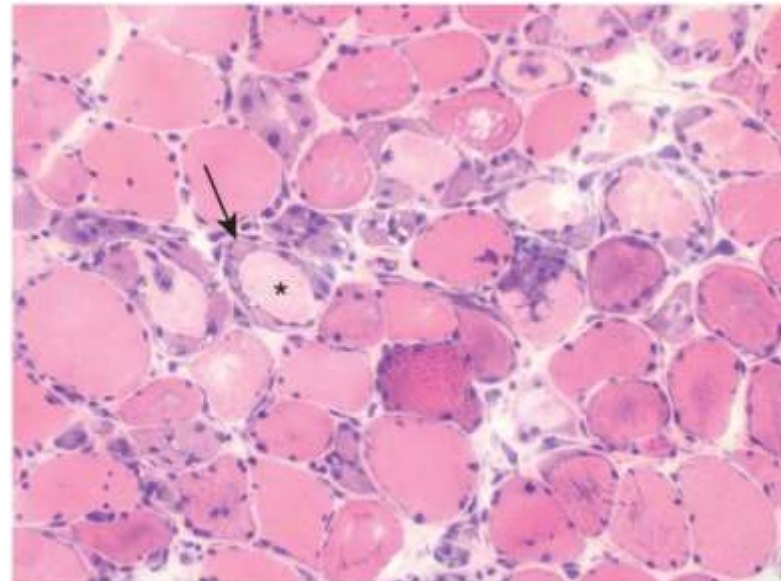
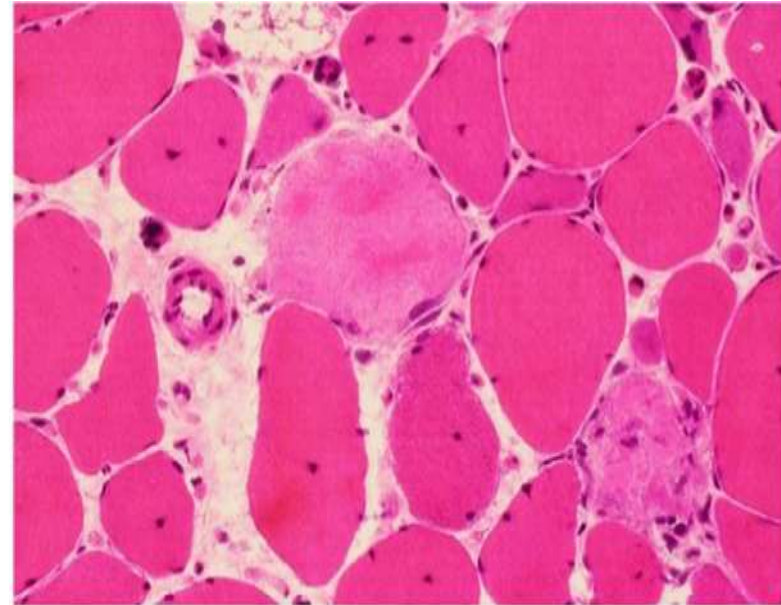
Diagnosis

- SKELETAL MUSCLE, RIGHT BICEP, BIOPSY
-- NECROTIZING MYOPATHY

COMMENT: The differential diagnosis for a necrotizing myopathy is broad, but given the histologic features and the clinical history of PD-1 inhibitor, a toxic/metabolic (drug effect) is favored. However paraneoplasia and a primary autoimmune myopathy (polymyositis, including anti-HMGCR, anti-SRP or anti-synthetase) may display the pathology seen in this case. Further clinical and serological correlation is recommended.

NECROTIZING MYOPATHY

- Immune mediated necrotizing myopathy
- Recently recognized entity
 - Prominent myofiber necrosis, regeneration and myophagocytosis
 - Minimal inflammation
- Immune mediated mechanism
- Heterogeneous group of disease with many etiologies



NECROTIZING MYOPATHY

- Clinical features
 - Subacute (weeks to months), moderate to severe, symmetrical proximal progressive muscle weakness
 - Myalgia, respiratory fatigue, facial weakness, fatigue, weight loss
 - Elevated creatine phosphokinase (CK, often > 3000 U/L)
 - MRI can identify active inflammation and chronic muscle damage
 - Myopathic changes on electromyogram

NECROTIZING MYOPATHY

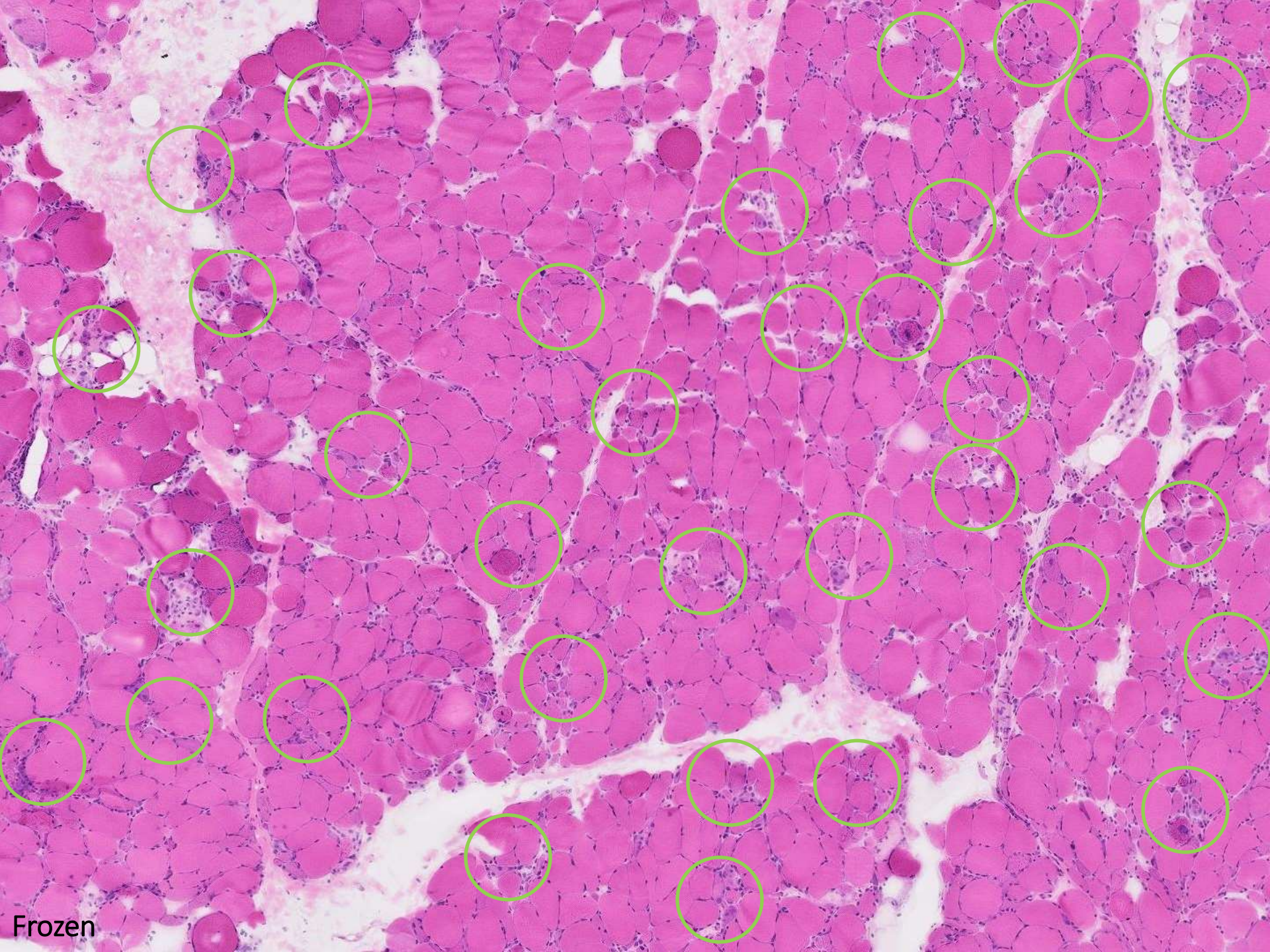
- Myositis specific autoantibodies
 - Anti-HMGCoAR (25-50%), cholesterol biosynthesis pathway, +/- statin exposure (alimentary statins), +/- malignancy, moderate weakness, IVIG
 - Anti-SRP (20-40%), ribonucleotide protein, severe weakness, elevated CKs, prolonged immunotherapy, myocardial involvement
 - Seronegative (25-40%), likely heterogeneous group of diseases, association with malignancy, consider other causes of muscle necrosis
- Potential risk factors
 - Viral infection, genetic (mostly HLA genes), malignancy, connective tissue disease, drugs/toxins, metabolic defects, etc.

Non-immunological causes of muscle necrosis [1,5,141,142,149].

Drugs	Statins (pharmacological and alimentary) (*) Multiple others reported, including: fibrates, cyclosporine, tacrolimus, propofol, labetalol, telbivudine, antipsychotics, voriconazole, malarone Epsilon-aminocaproic acid, ipecac, organophosphates, entecavir, zidovudine, colchicine, selective serotonin reuptake inhibitors, lithium, large doses of intravenous steroids
Drugs of abuse	Alcohol Cocaine Opiates Phencyclidine (Angel dust)
Toxins	Some wild mushrooms Snake venom
Needle myopathy	Focal necrosis caused by intramuscular injection of drugs and toxins
Infections	Hepatitis B, C (*), E HIV (*) Other viral (*): Influenza A or B, adenovirus, Epstein Barr Virus, Coxsackie Bacterial and parasitic infections
Metabolic	Genetic disorders of glycogenolysis and glycolysis Disorders of lipid metabolism Mitochondrial myopathies Hypokalaemia Hypocalcaemia Hypophosphataemia Nonketotic hyperosmotic disorders Diabetic ketoacidosis Thyroid dysfunction Adrenal insufficiency
Other	Muscular dystrophy

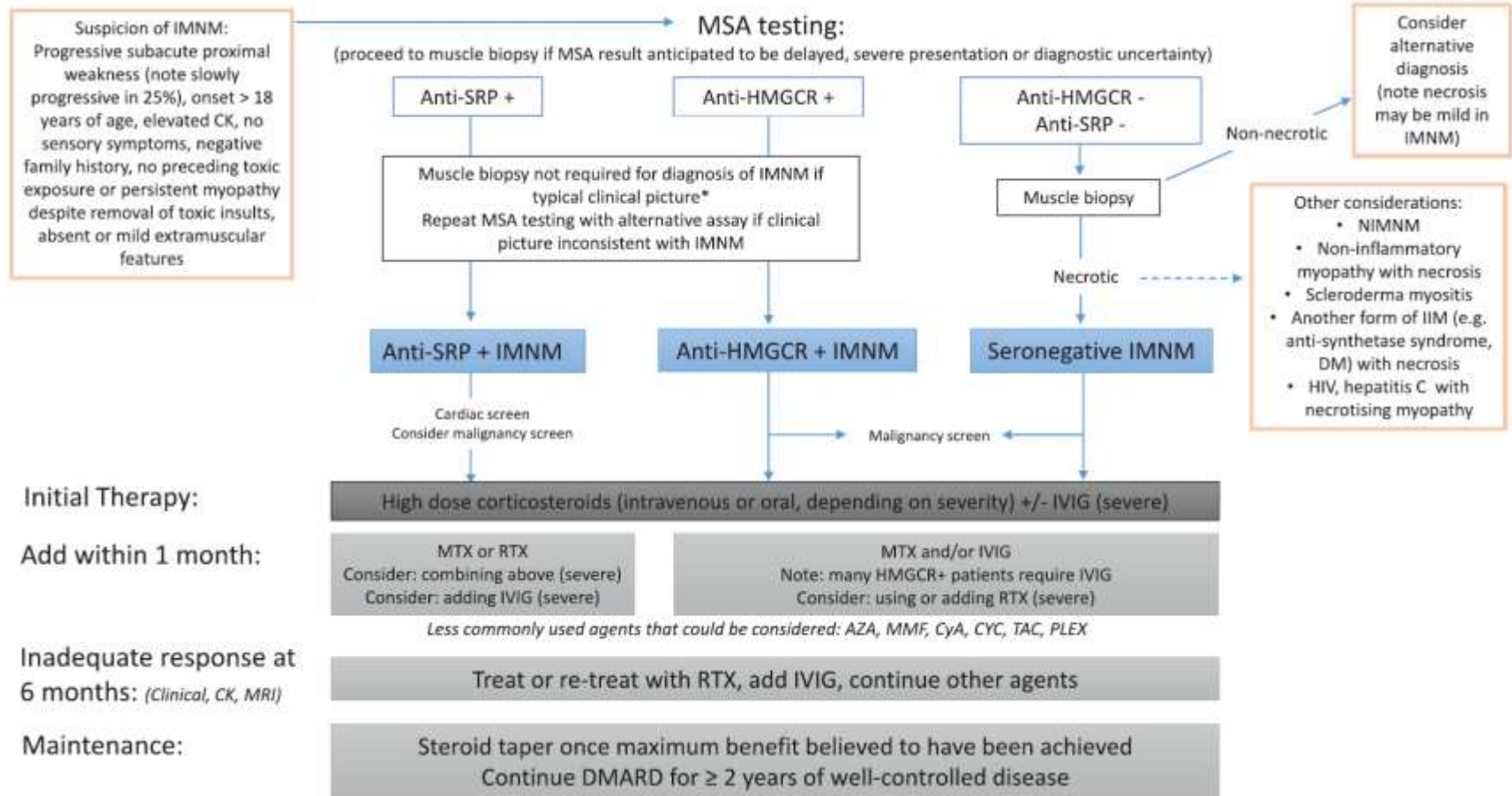
NECROTIZING MYOPATHY

- PD1 inhibitors are associated with immune related adverse events in many systems including the skin, the GI tract, endocrine, hepatic and pulmonary.
- Recent literature describes a necrotizing myopathy associated with PD1 inhibitors (Seki M et al, 2019; 19 cases)
 - 85% myalgias, 70% muscle weakness, 70% ocular involvement reminiscent of Myasthenia Gravis, 53% had bulbar symptoms, 30% respiratory involvement, 20% heart involvement, Elevated CK (average 5000)
 - No classic myositis specific antibody (anti-titin and/or anti-Kv1.4 in 68% of cases)
 - **Multifocal confluent foci** of myofiber necrosis/regeneration with aberrant MHC class I
 - Rare CD4 and CD8 T cells (CD4 < CD8)
 - Treatment generally effective with gradual improvement in most patients
 - STOP PD1 inhibitor, +/- immunosuppression, +/- IVIG, +/- plasma exchange, +/- tacrolimus



Frozen

NECROTIZING MYOPATHY



SUMMARY

- Immune mediated necrotizing myopathy is a recently described type of autoimmune myopathy
 - Myofiber necrosis and regeneration with minimal inflammation
- Subdivided by autoantibody
 - Anti-SRP, anti-HMGCoAR and seronegative
- PD-1 inhibitors have been associated with an inflammatory myopathy characterized by multifocal small groups of necrotic/regenerating myofibers
- Clinical and serological correlation is essential

REFERENCES

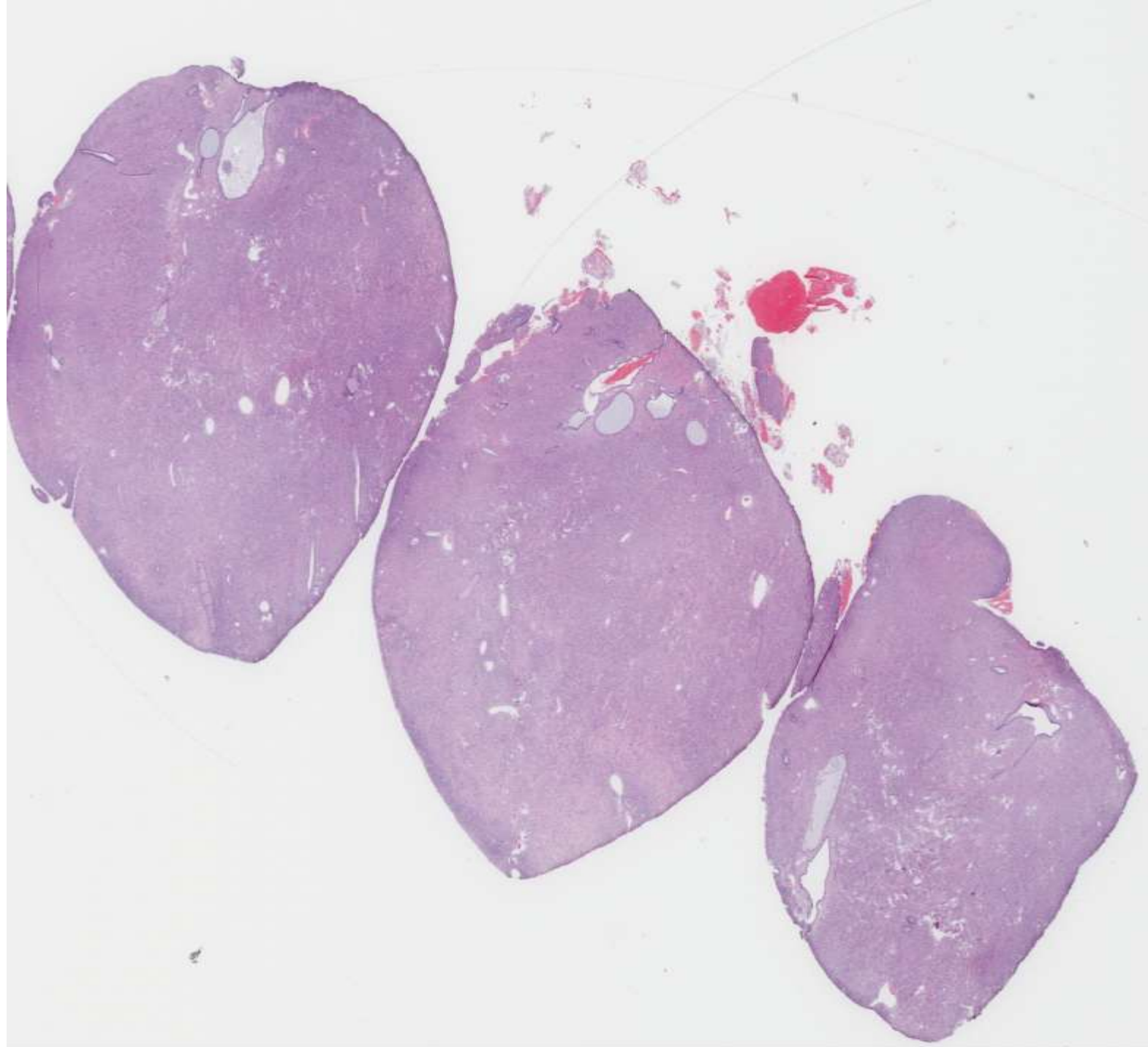- Inflammatory myopathy associated with PD-1 inhibitors. Seki M, Uruha A, Ohnuki Y, Kamada S, Noda T, Onda A, Ohira M, Isami A, Hiramatsu S, Hibino M, Nakane S, Noda S, Yutani S, Hanazono A, Yaguchi H, Takao M, Shiina T, Katsuno M, Nakahara J, Matsubara S, Nishino I, Suzuki S. J Autoimmun. 2019 Jun;100:105-113
- Immune-mediated necrotising myopathy: A critical review of current concepts. Day JA, Limaye V. Semin Arthritis Rheum. 2019 Dec;49(3):420-429
- Immune-Mediated Necrotizing Myopathy. Pinal-Fernandez I, Casal-Dominguez M, Mammen AL. Curr Rheumatol Rep. 2018 Mar 26;20(4):21.

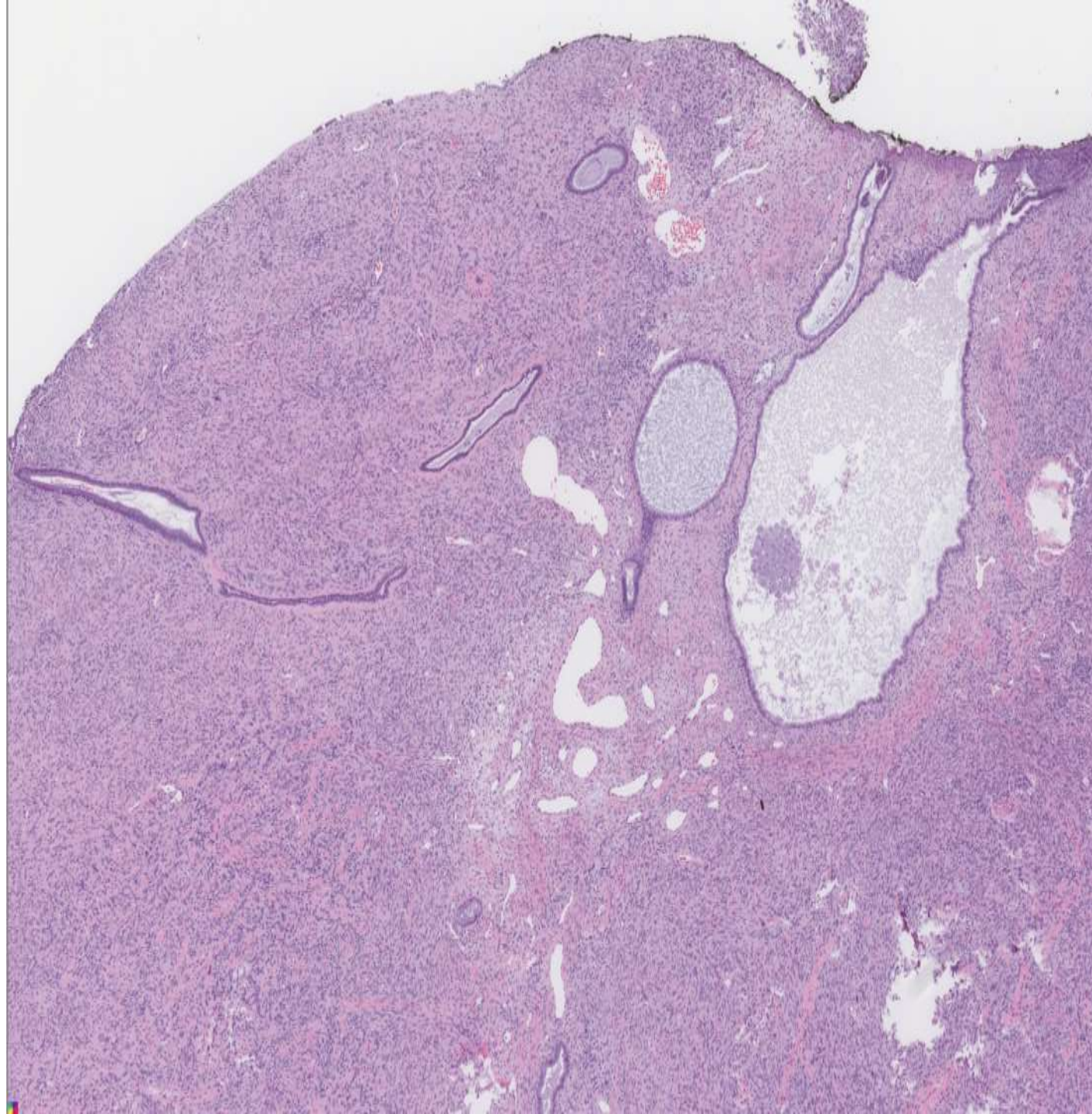


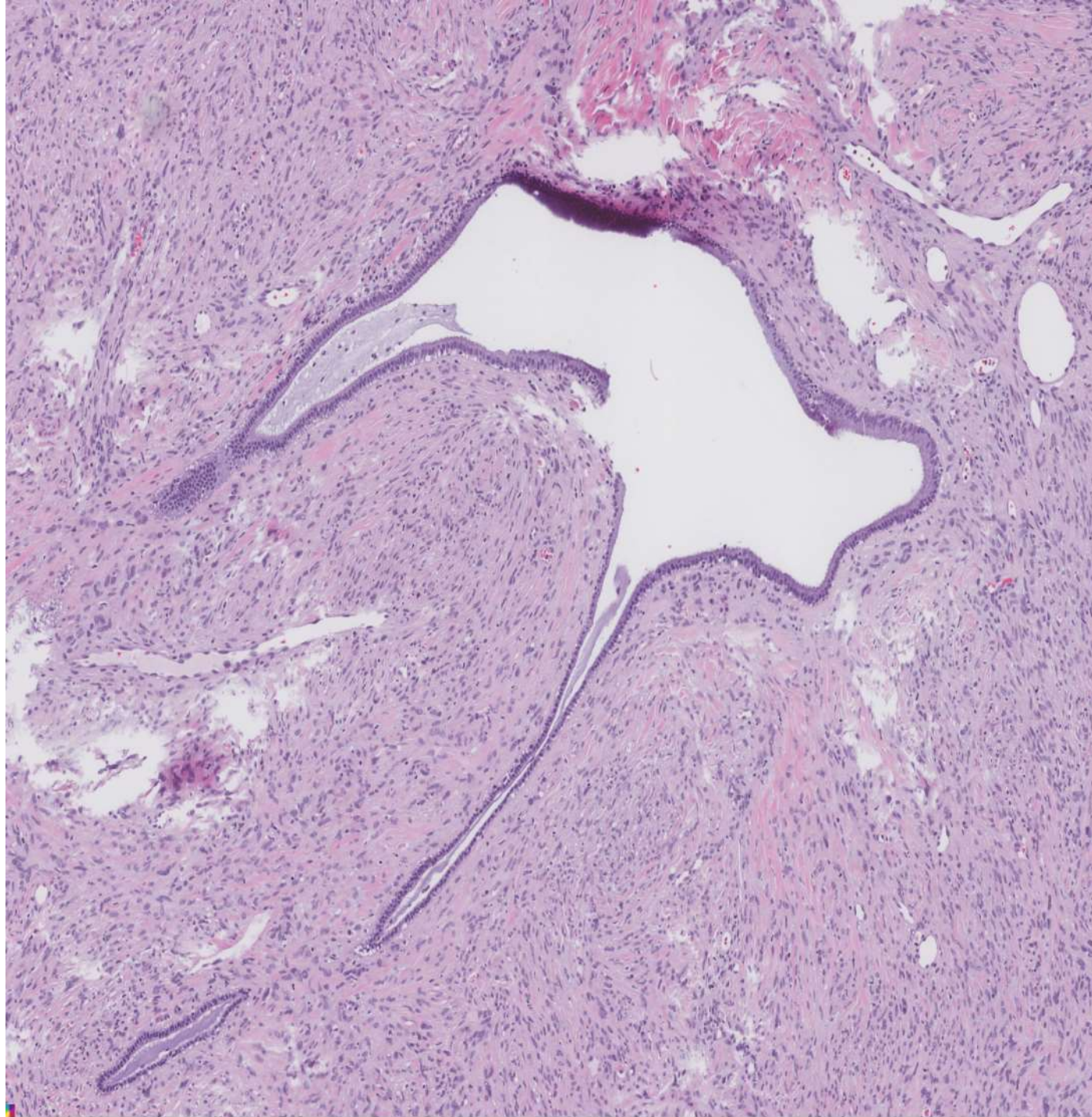
20-0204

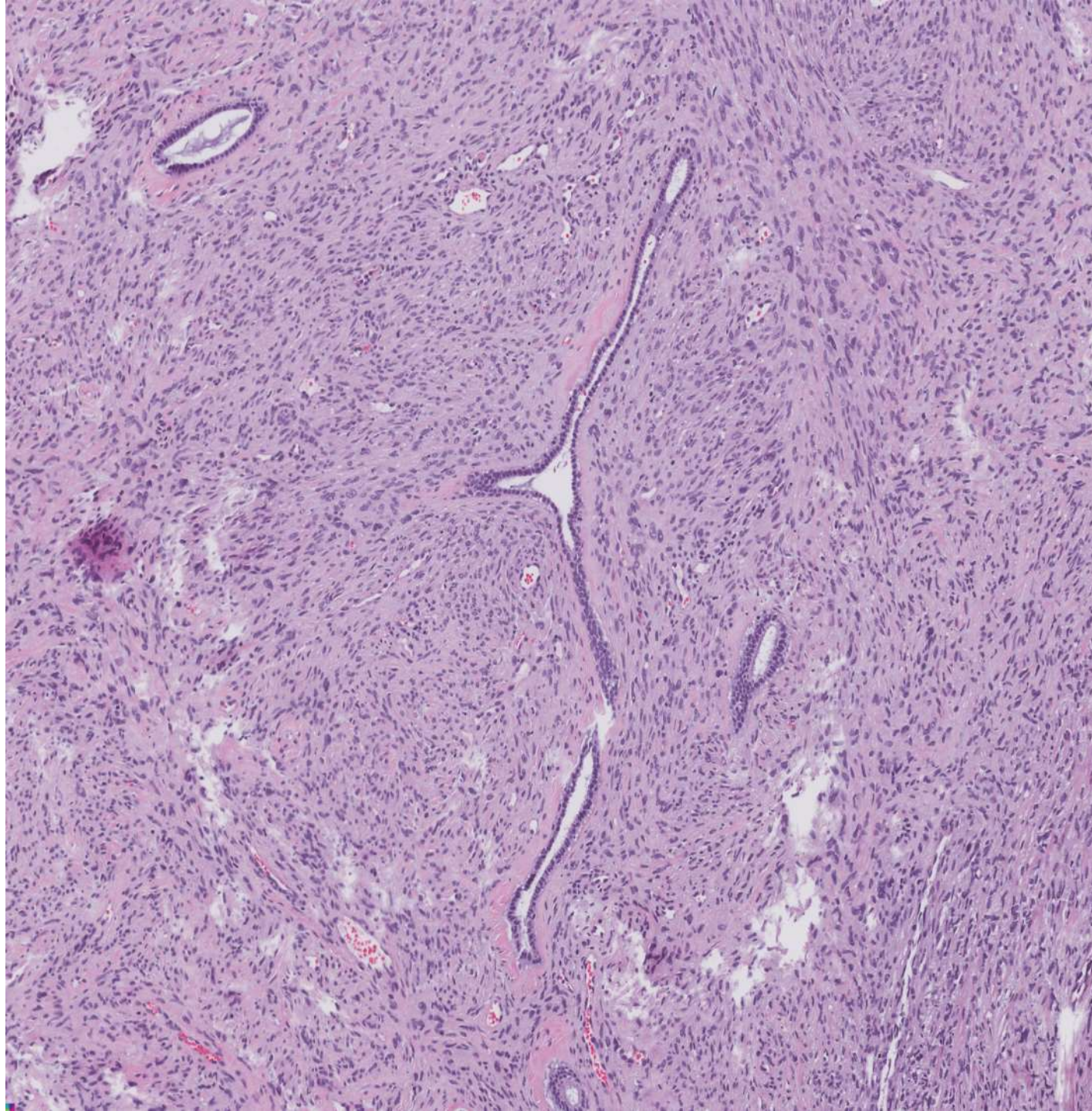
Joseph Rabban; UCSF

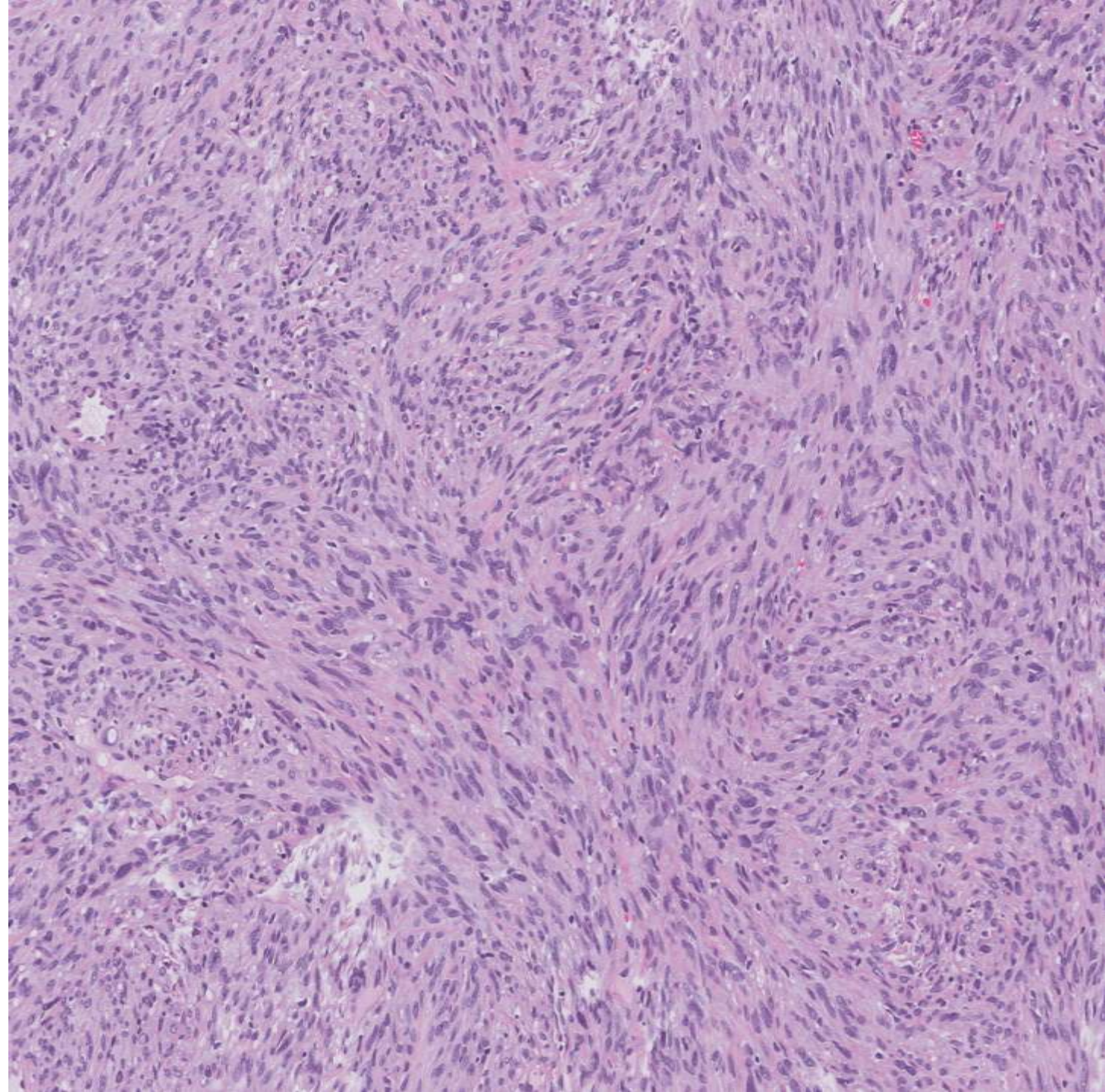
49-year-old F with 1.8cm prolapsed uterine fibroid at the cervical os that was locally excised.

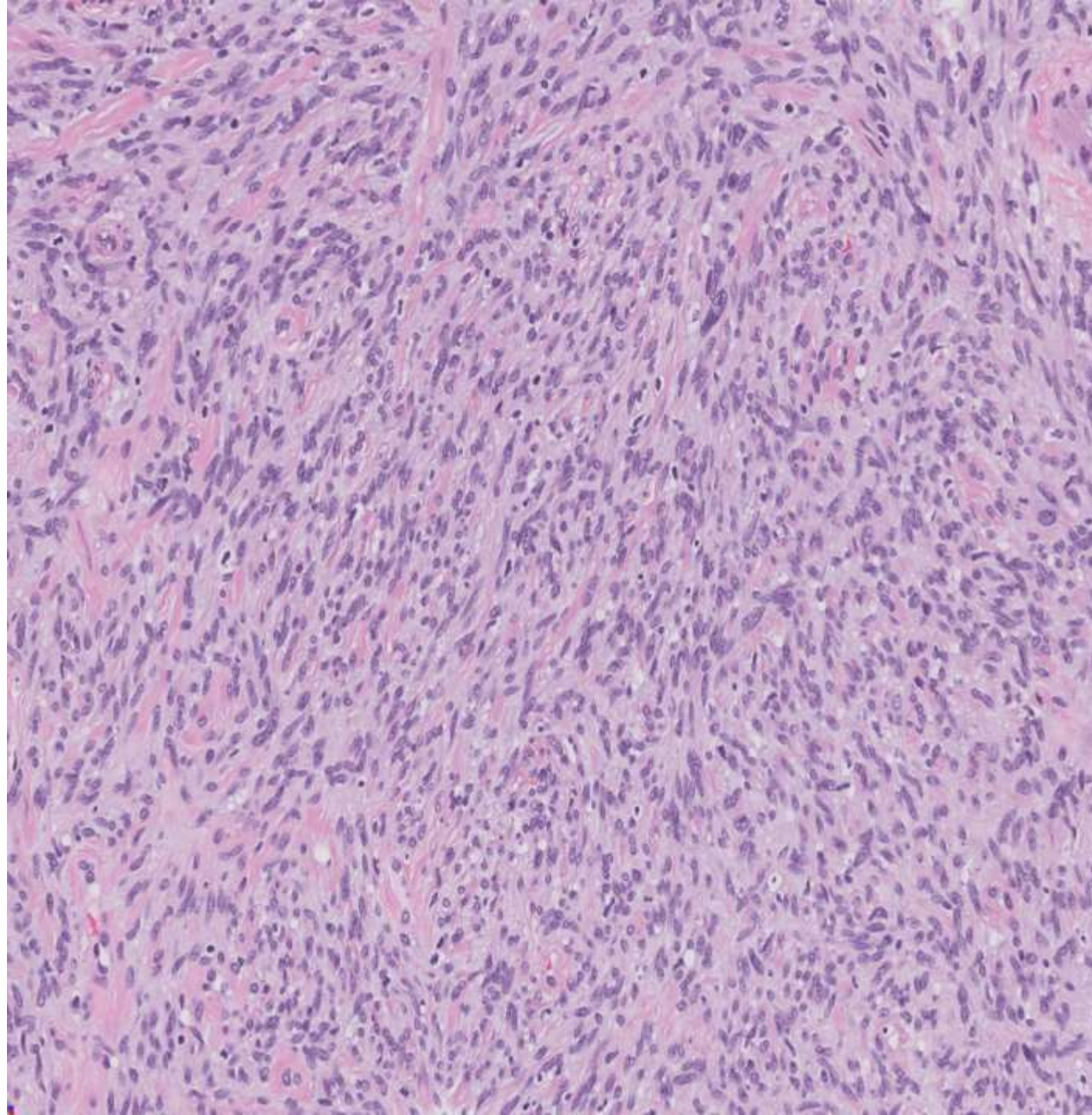


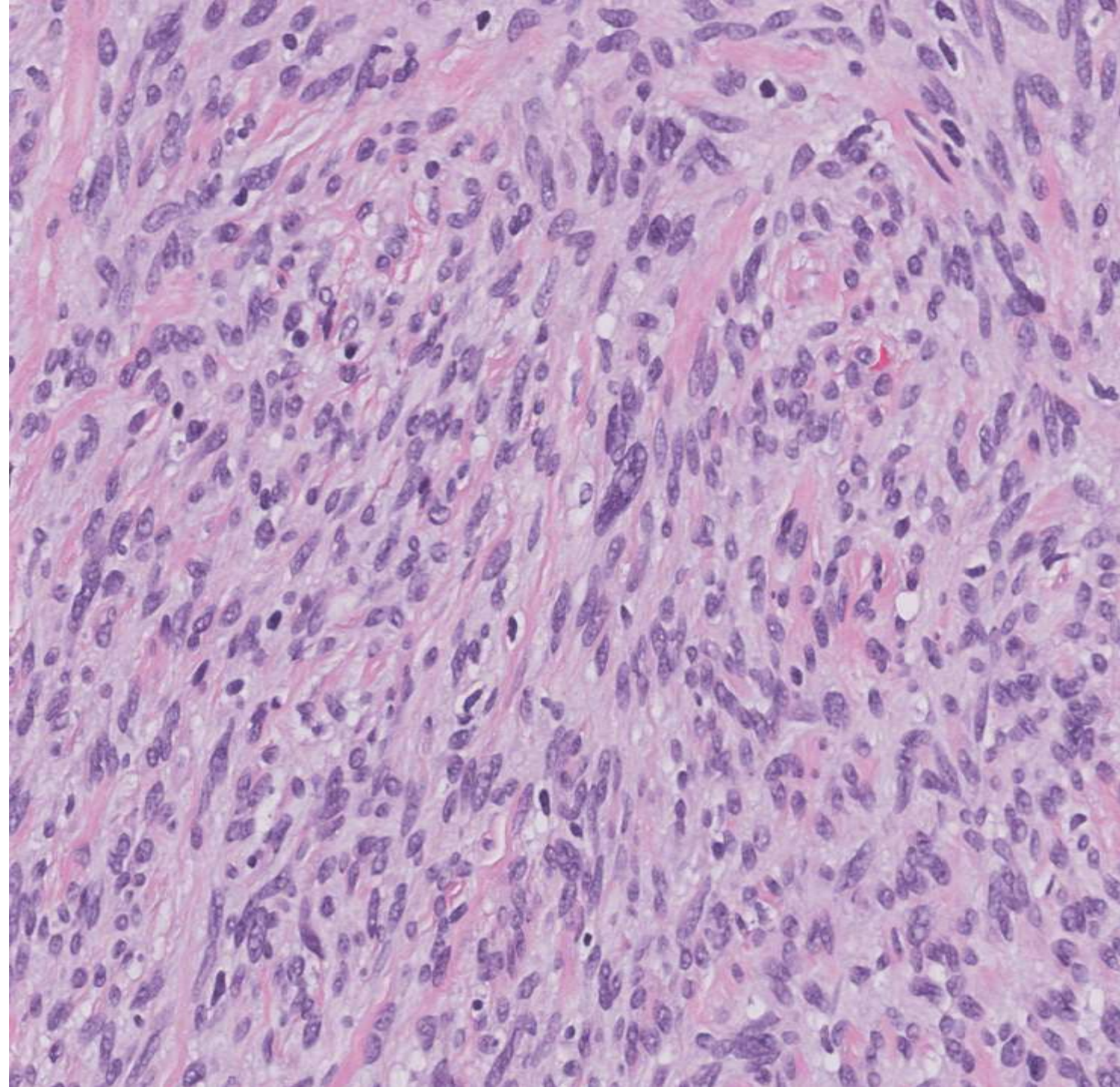












Low grade fascicular spindle cell tumor of uterus
Mild / focal moderate atypia; rare mitoses

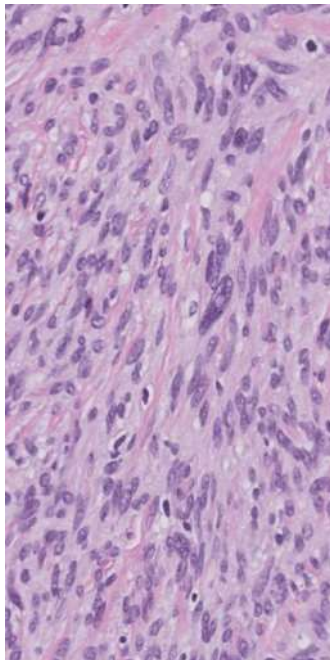
Initial Differential Diagnosis	Markers: All Negative Results
Leiomyoma variant	Desmin, caldesmon, SMM, SMA
Adenosarcoma variant	ER
PEComa	HMB45
Inflammatory myofibroblastic tumor	ALK
Endometrial stromal tumor variant	CD10, ER, cyclinD1, CD117, BCOR
Sarcomatoid carcinoma	Keratin, CK7, p63, p16

NTRK Fusions Define a Novel Uterine Sarcoma Subtype With Features of Fibrosarcoma

Sarah Chiang, MD, Paolo Cotzia, MD,* David M. Hyman, MD,† Alexander Drilon, MD,‡ William D. Tap, MD,§ Lei Zhang, MD,* Jaclyn F. Hechtman, MD,* Denise Frosina, BS,* Achim A. Jungbluth, MD, PhD,* Rajmohan Murali, MBBS, MD, FRCPA,* Kay J. Park, MD,* Robert A. Soslow, MD,* Esther Oliva, MD,||¶ A. John Iafrate, MD, PhD,||¶ Ryma Benayed, PhD,* Marc Ladanyi, MD,* and Cristina R. Antonescu, MD**

Abstract: Tropomyosin receptor kinase (Trk) inhibitors have shown high response rates in patients with tumors harboring *NTRK* fusions.

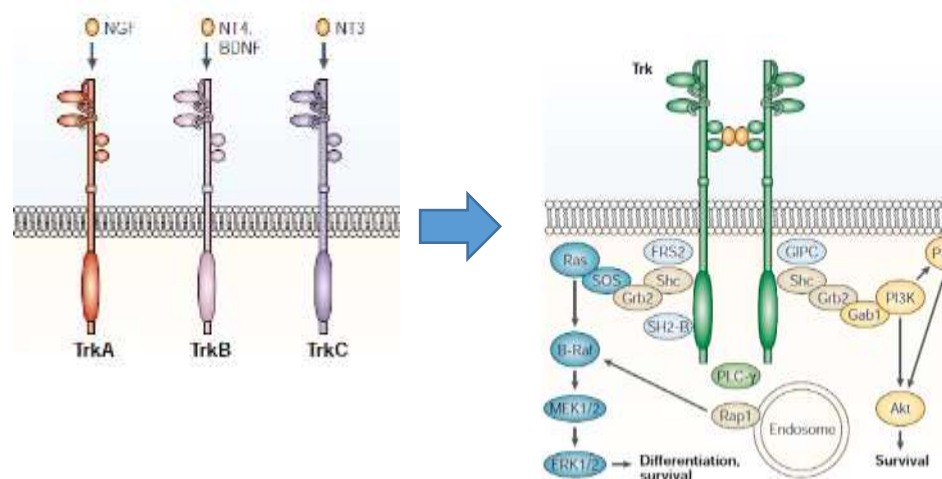
Key Words: *NTRK*, uterine sarcoma, fibrosarcoma
(*Am J Surg Pathol* 2018;42:791–798)



- **Young women (20-40)**
- **Cervical mass / polyp**
- **“Fibrosarcoma-like”**
 - Fascicular growth
 - Spindle cells with mild/mod atypia
 - Variable mitoses
- **Negative for myoid, endometrial stromal markers**
- **Positive for S100**

***NTRK* = neurotrophic tyrosine receptor kinase**

Gene	Protein	Main Receptor Ligand
<i>NTRK1</i>	Tropomyosin receptor kinase A (TrkA)	Nerve growth factor
<i>NTRK2</i>	Tropomyosin receptor kinase B (TrkB)	Brain-derived neurotrophic factor
<i>NTRK3</i>	Tropomyosin receptor kinase C (TrkC)	Neurotrophin 3



Normal roles

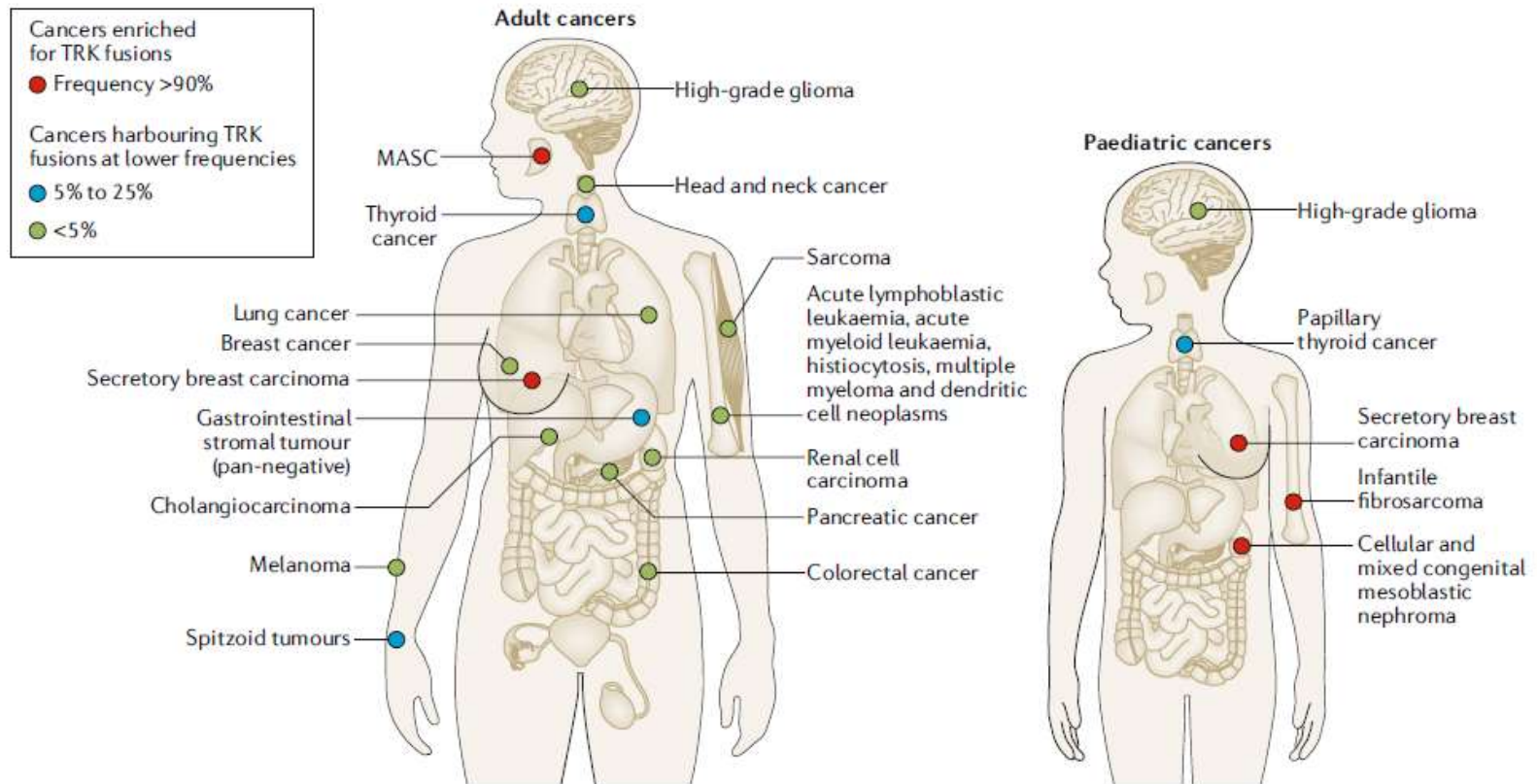
Mediate neurotrophin activation of signaling cascade

Developmental role: nervous system

Regulatory role: pain, appetite, proprioception, memory

***NTRK* fusion is recognized in an expanding spectrum of malignancies**

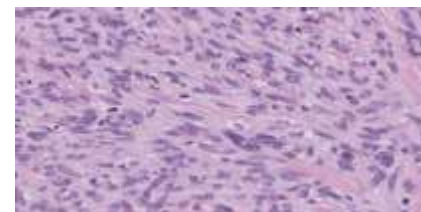
- Two groups:
1. Tumors highly enriched for *NTRK* fusion
 2. Tumors with low prevalence of *NTRK* fusion



Clinical relevance of recognizing *NTRK* fusion cervical sarcoma

1. Metastatic / recurrent potential in a subset

-not enough cases to identify prognostic variables

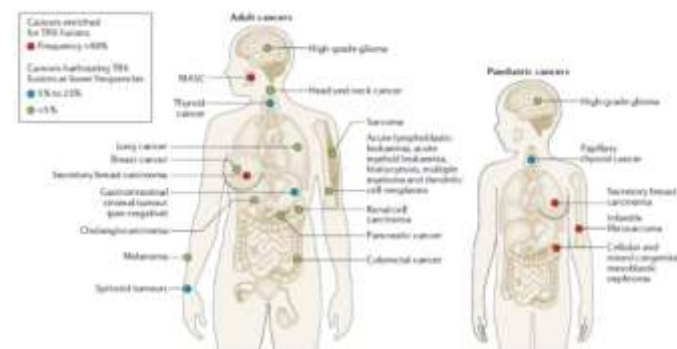


	Stage I	Metastasis / Local recurrence	Death
Chiang et al. AJSP 2018	4/4	1/4	1/4
Croce et al. Mod Pathol 2019	5/7	2/6	0
Rabban et al. Histopath. 2020	3/3	1/3	0
Michael et al. AJSP 2019	1/1	0	0

2. Targeted therapy approved by FDA for *NTRK* fusion positive tumors

-agnostic to tumor type / origin

“Basket” Clinical Trials	TRK inhibitor
NCT02122913 trial SCOUT trial NAVIGATE trial Drilon et al. NEJM 2018	Larotrectinib
ALKA-372 trial STARTRK-1 trial STARTRK-2 trial Doebele et al. Lanc Oncol 2020	Entrectinib



- **Detection Methods for *NTRK* fusion**

DNA or RNA sequencing

RT-PCR

FISH

IHC: pan-TRK (Trk A, Trk B and Trk C)

- **Pan-TRK IHC**

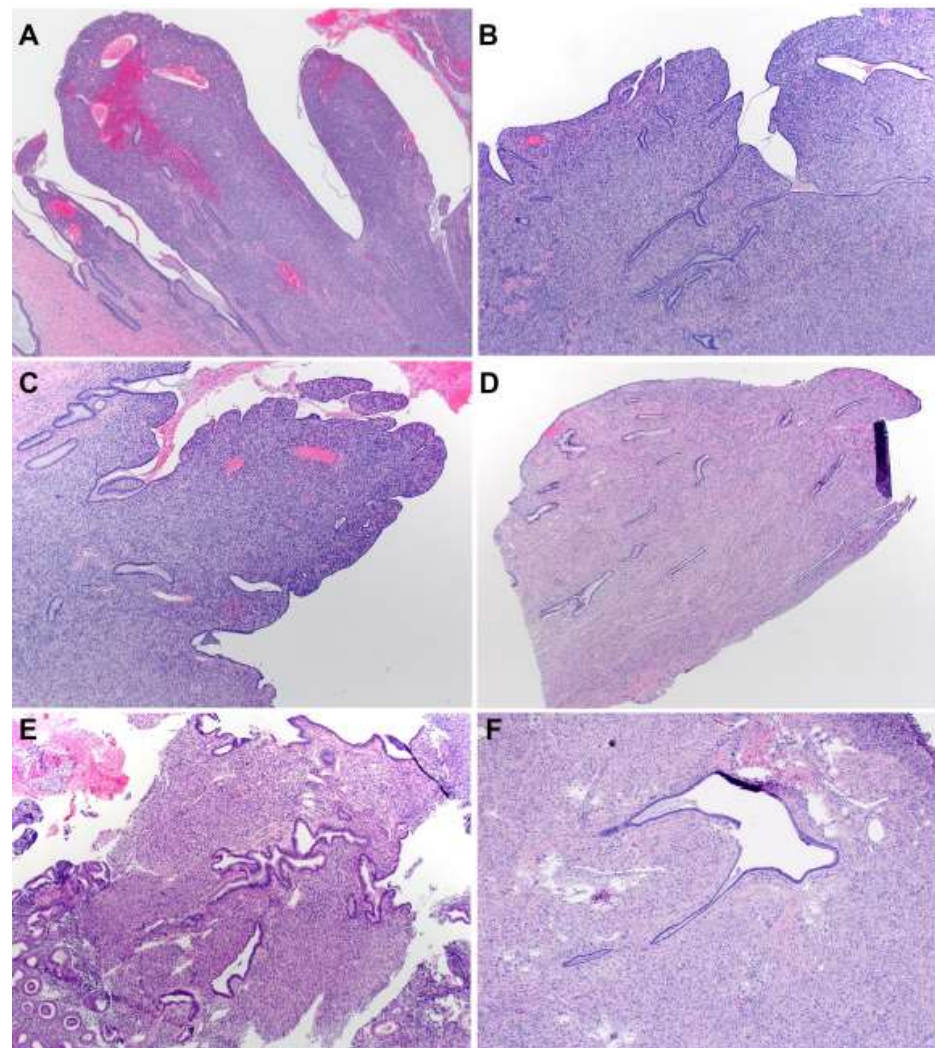
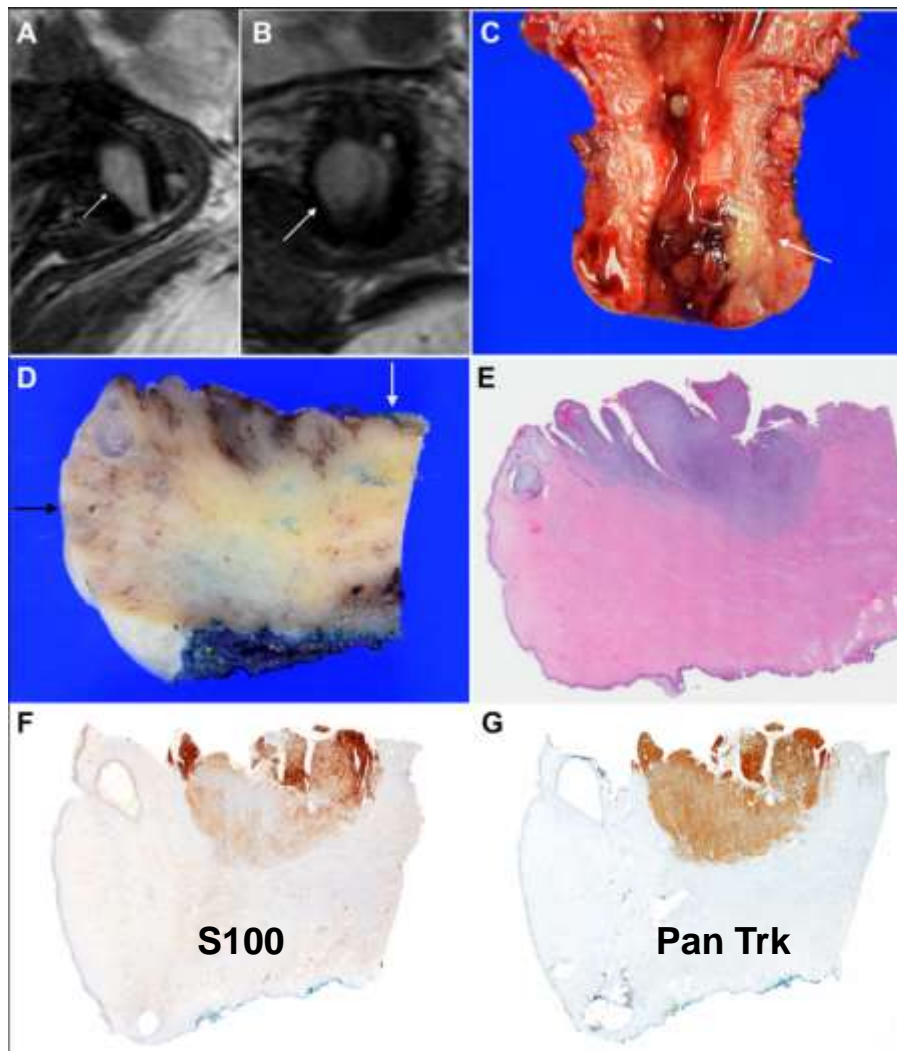
Fusion	Staining Pattern
None	None
<i>NTRK1</i>	Cytoplasmic (diffuse / moderate to strong)
<i>NTRK2</i>	Cytoplasmic (diffuse / moderate to strong)
<i>NTRK3</i>	Nuclear +/- cytoplasmic (diffuse / moderate to strong)

Sensitivity	~81%-97 % (lower for <i>NTRK3</i>)
Specificity	~92%-98%

Rudzinski, AJSP 2018
 Gatalica, Mod Pathol 2019
 Hechtman, AJSP 2017
 Hung, Histopath 2018
 Suurmeijer, Gene Chr Canc 2019
 Solomon, Mod Pathol 2019



**S100 often positive in mesenchymal tumors
with *NTRK* fusion**



Histopathology, 2020 Jan 23. doi: 10.1111/his.14069. [Epub ahead of print]

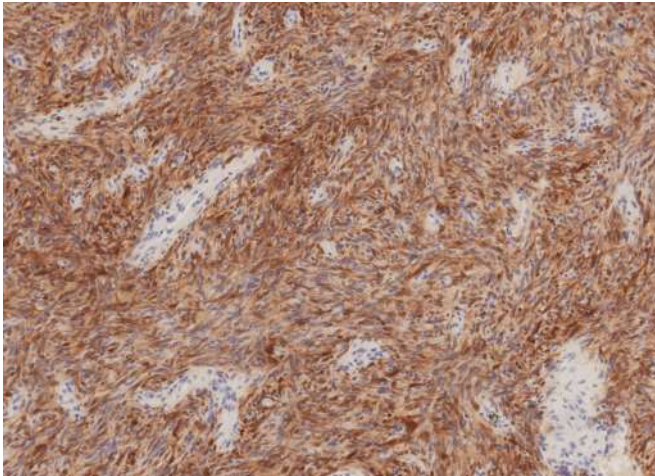
NTRK Fusion Cervical Sarcoma: A Report of 3 Cases, Emphasizing Morphological and Immunohistochemical Distinction from Other Uterine Sarcomas, including Adenosarcoma.

Rabban JT¹, Devine P¹, Sangoi AR², Poder L³, Alvarez E⁴, Davis JL⁵, Rudzinski E⁶, Garg K¹, Bean GR¹.

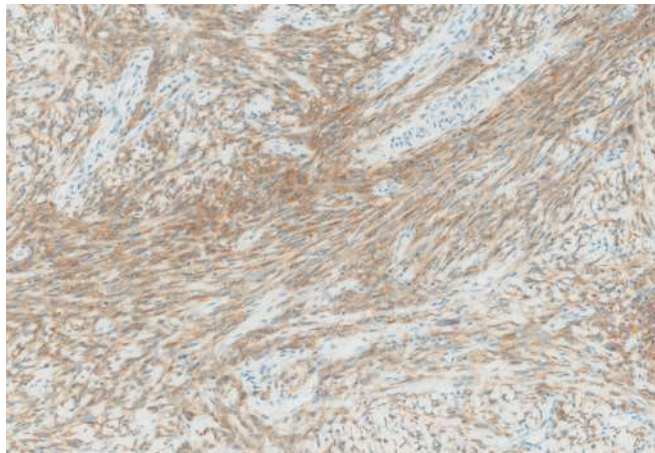
South Bay case 20-204

Diagnosis: *NTRK* fusion cervical sarcoma

S100

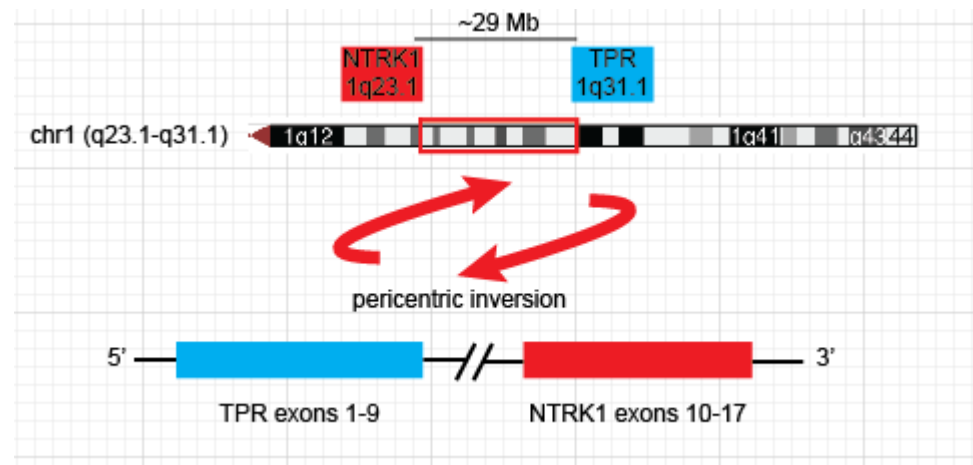


Pan Trk



UCSF500 NGS test:

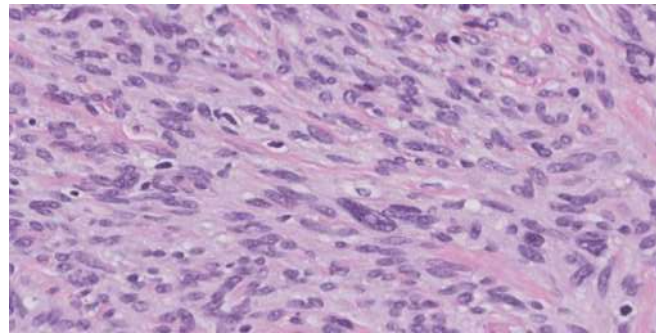
TPR – NTRK1 fusion



South Bay case 20-204

Take-home Message

Uterine fibrosarcoma-like or adenosarcoma-like tumor
Morphology and IHC don't fit classical differential diagnosis



S100 or pan Trk stain



Positive



Work up *NTRK* fusion



Negative

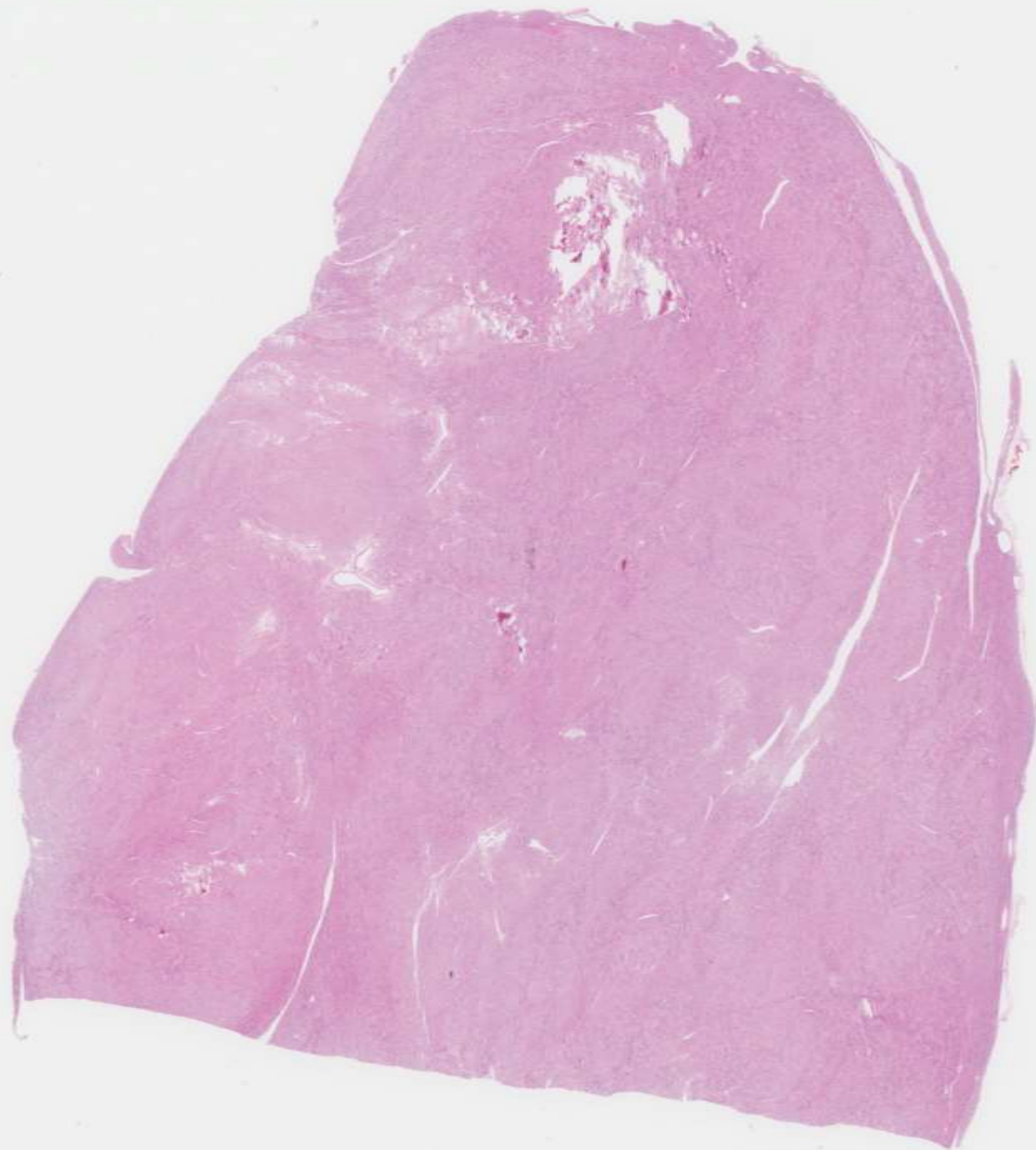


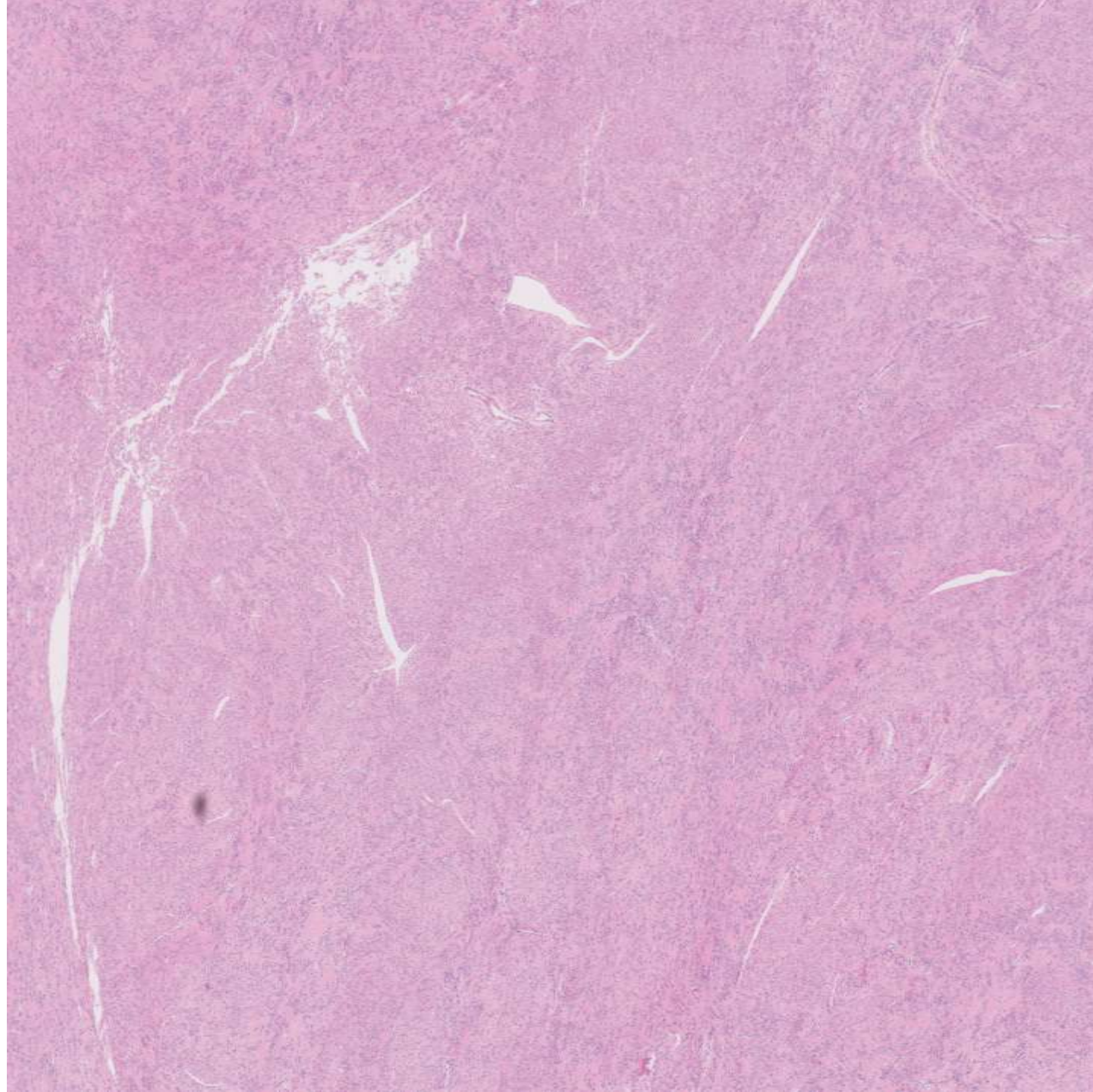
Descriptive Diagnosis

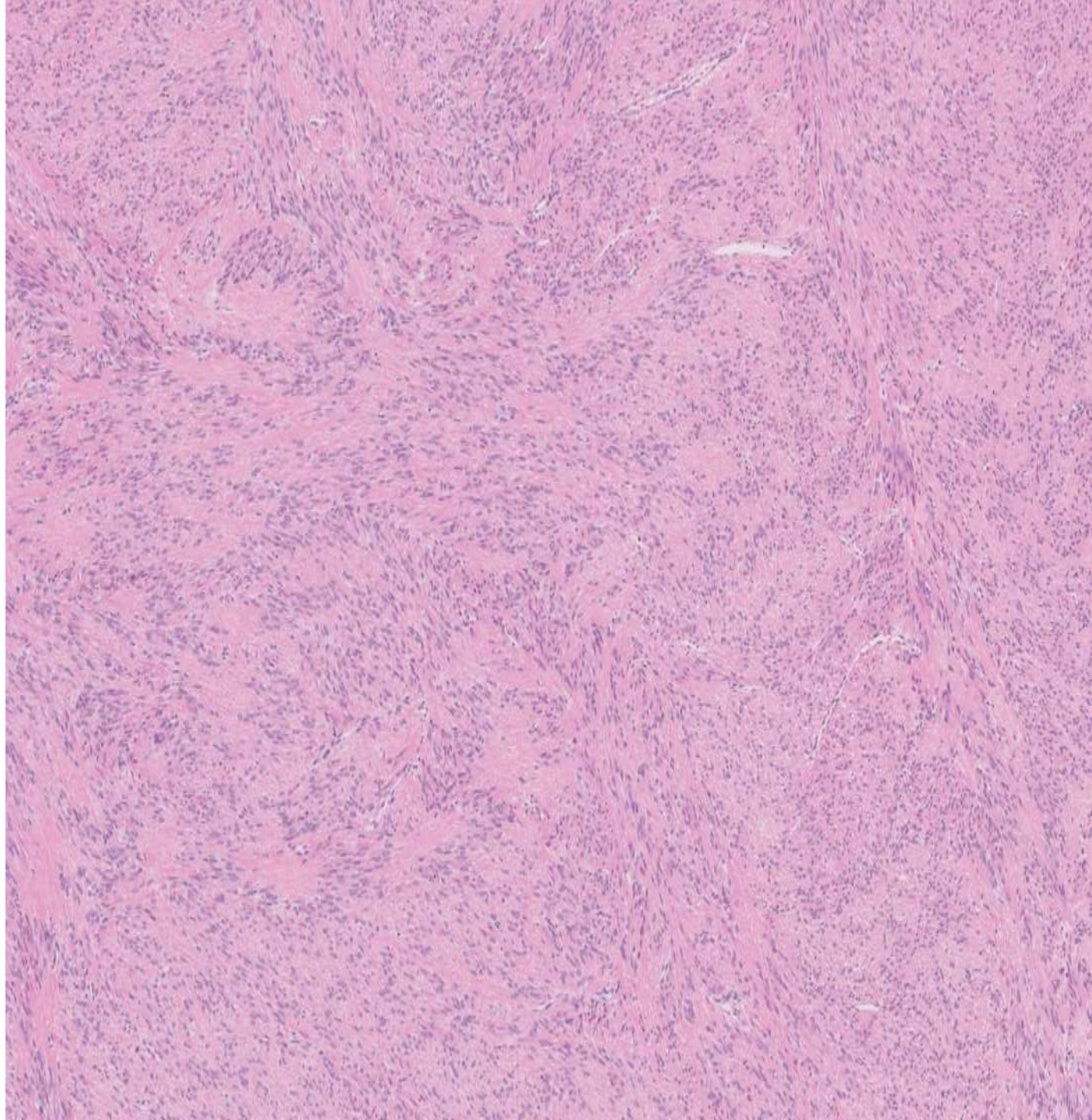
20-0205

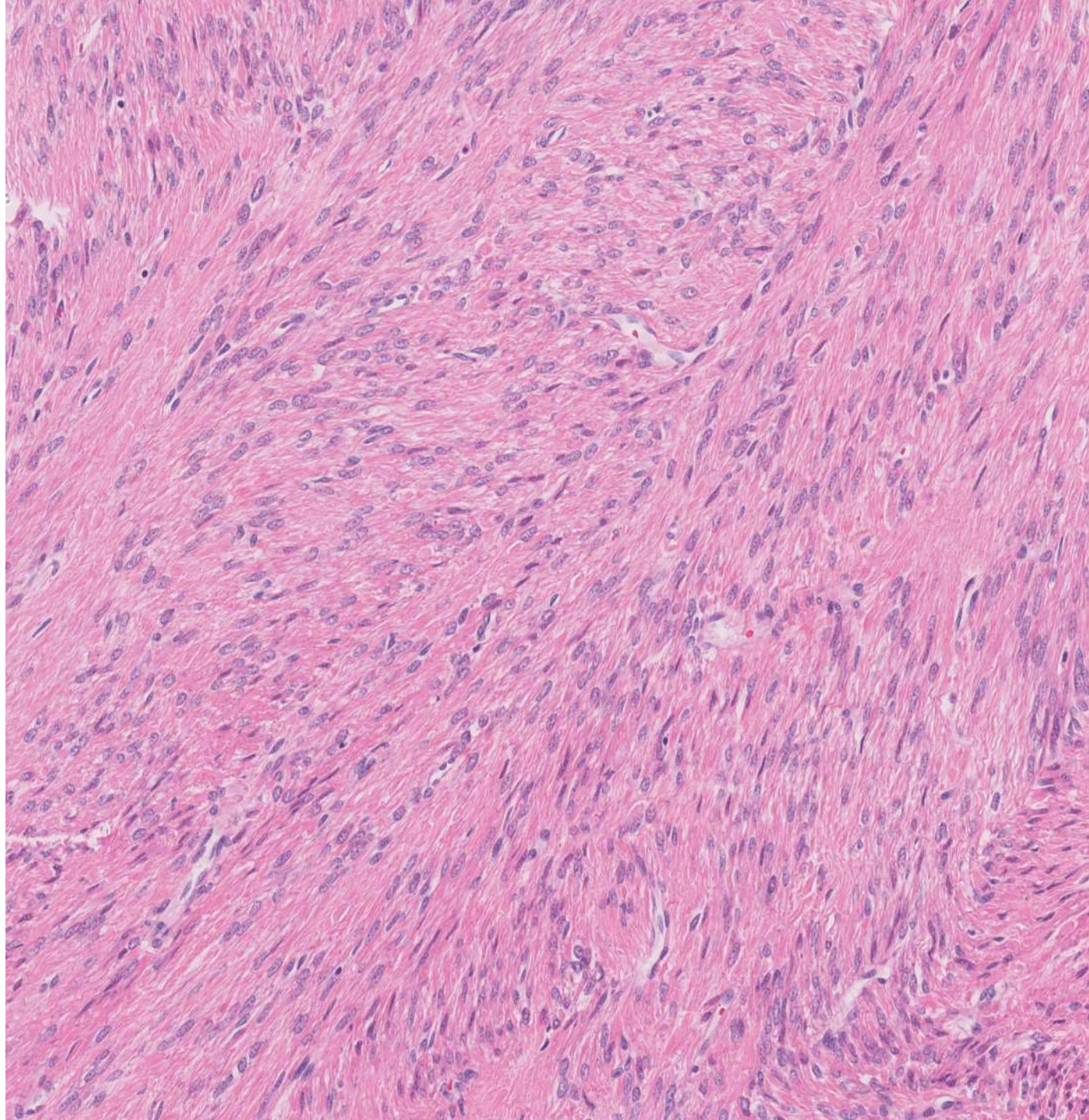
Joseph Rabban; UCSF

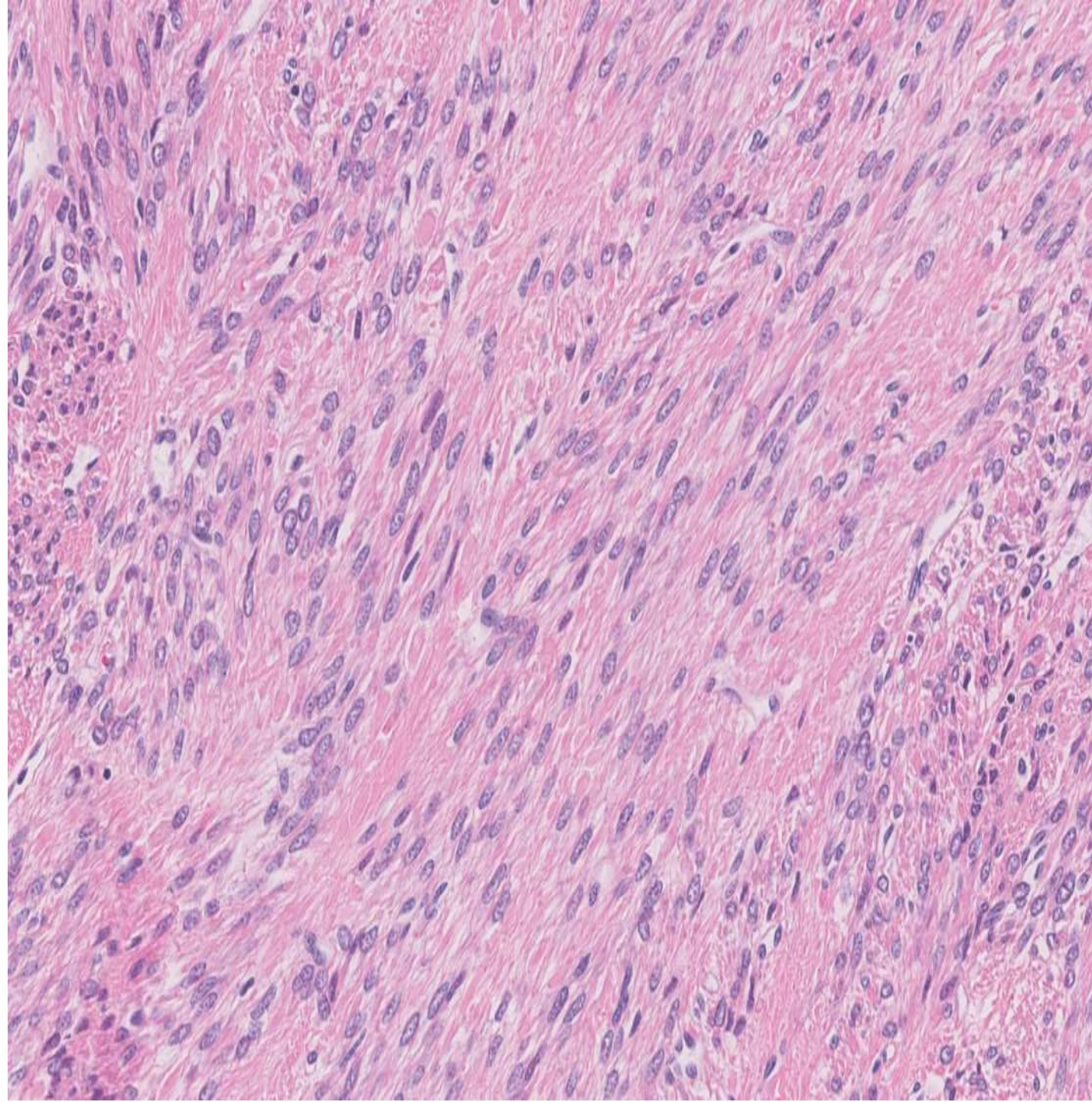
36-year-old F with multiple large fibroids who underwent myomectomy. Gross exam was consistent with conventional leiomyomas, with no features suspicious for sarcoma.

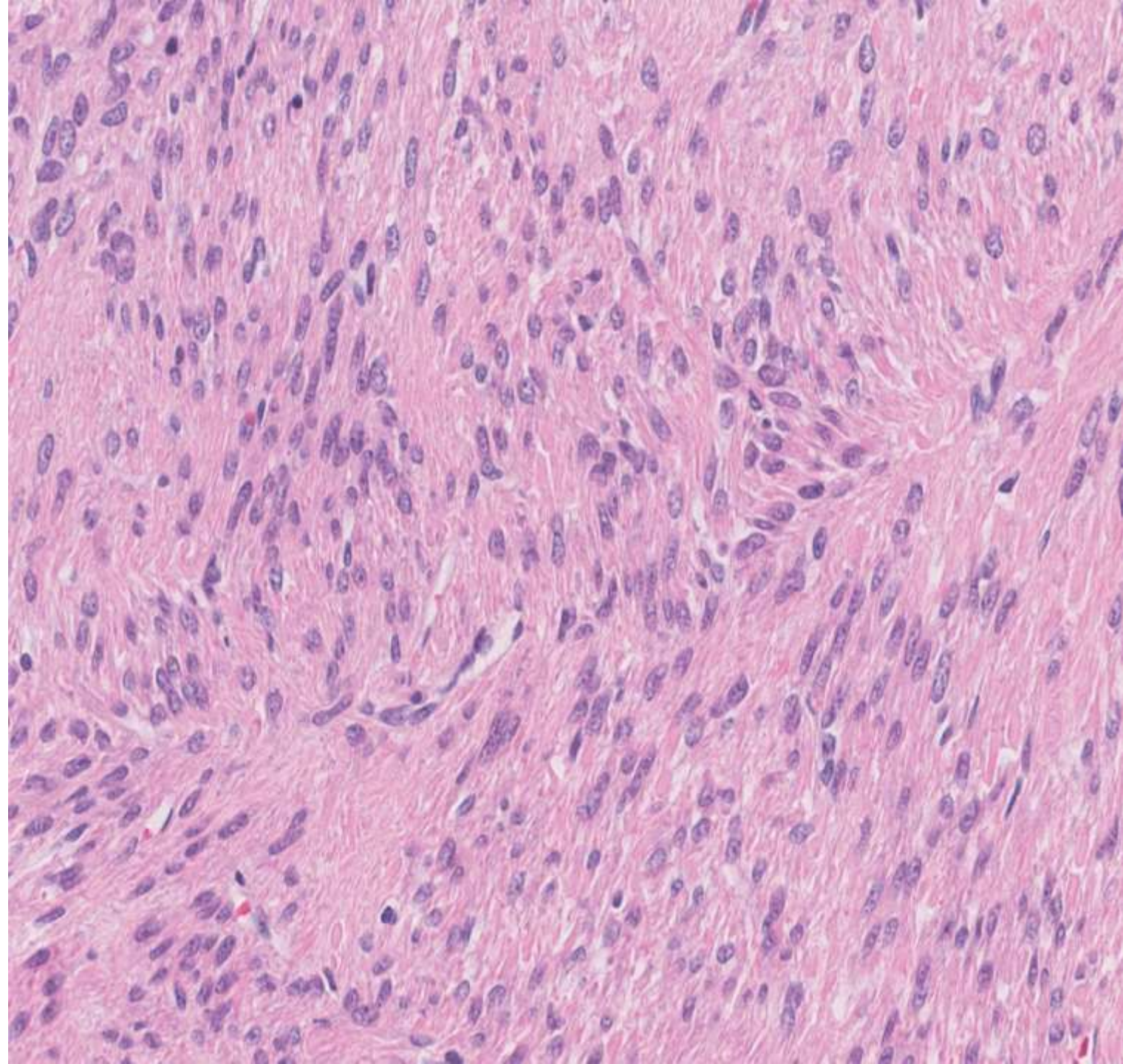


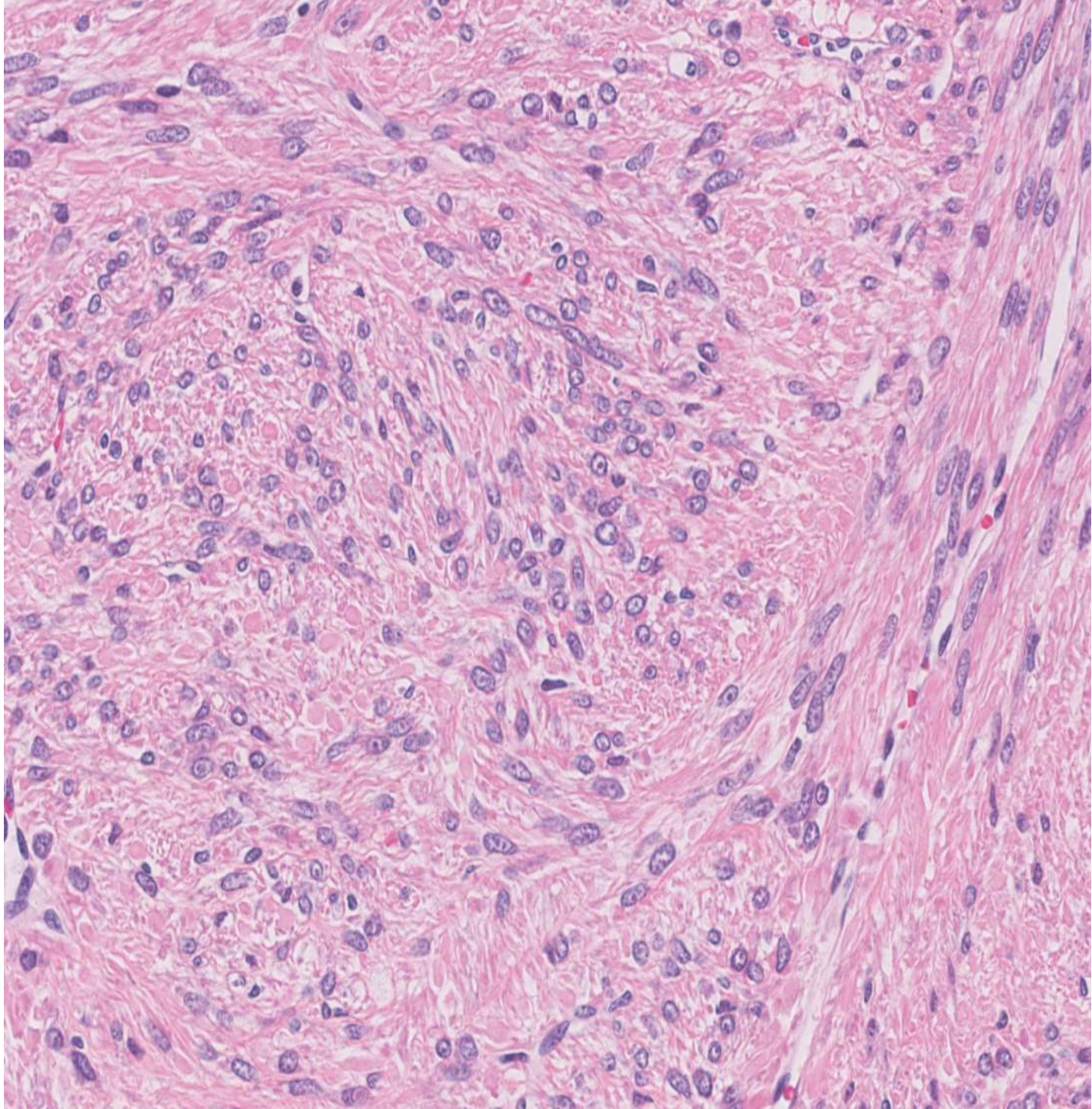


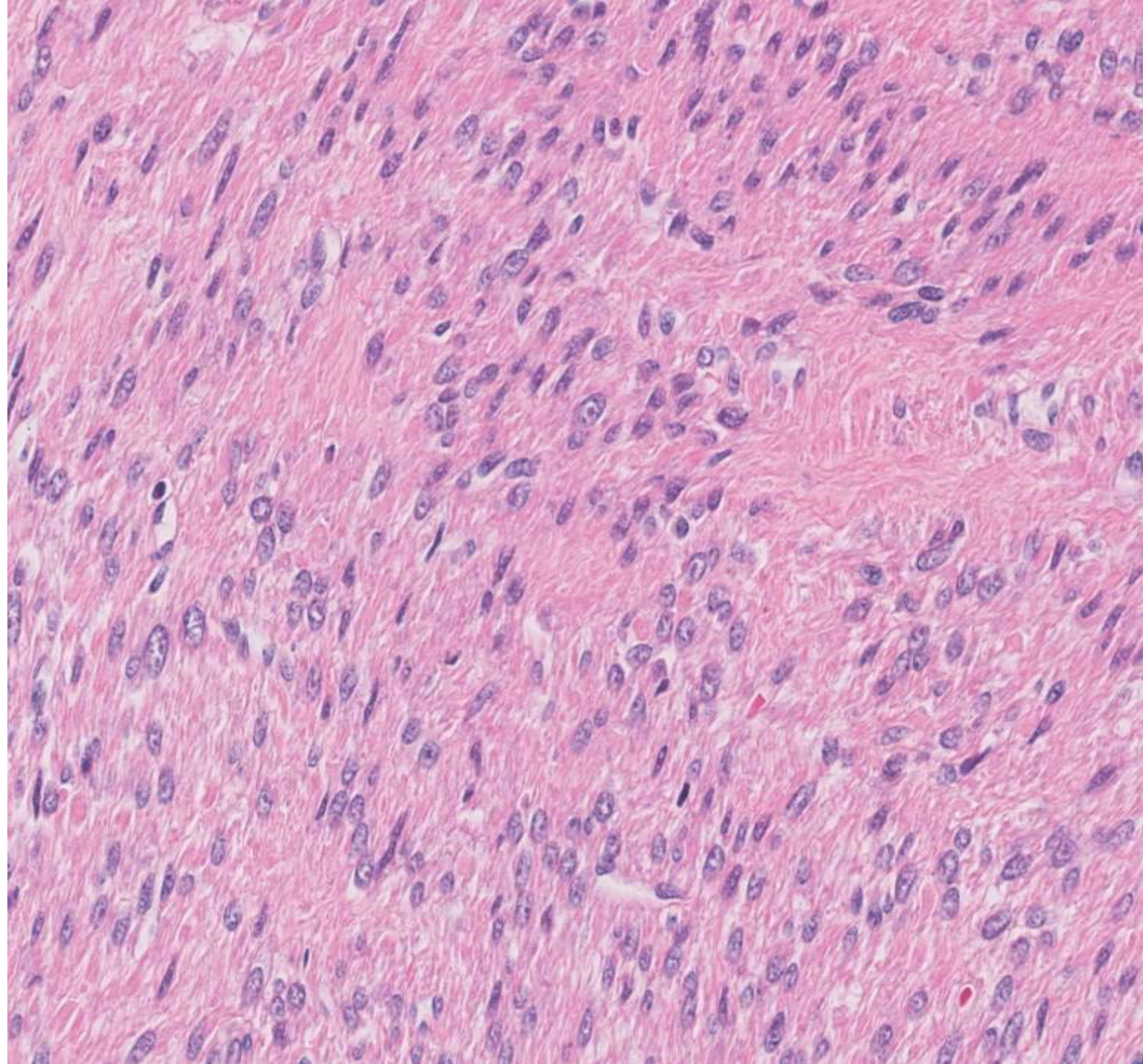












Hereditary Leiomyoma Renal Cell Carcinoma Syndrome (HLRCC)

- **Germline Mutation in Fumarate Hydratase gene** (Krebs cycle)
- **Autosomal dominant**
- **Most affected women:**

Average age 28

Uterine and/or cutaneous leiomyomas

Multiple, large, painful

- **10-15% affected women:**

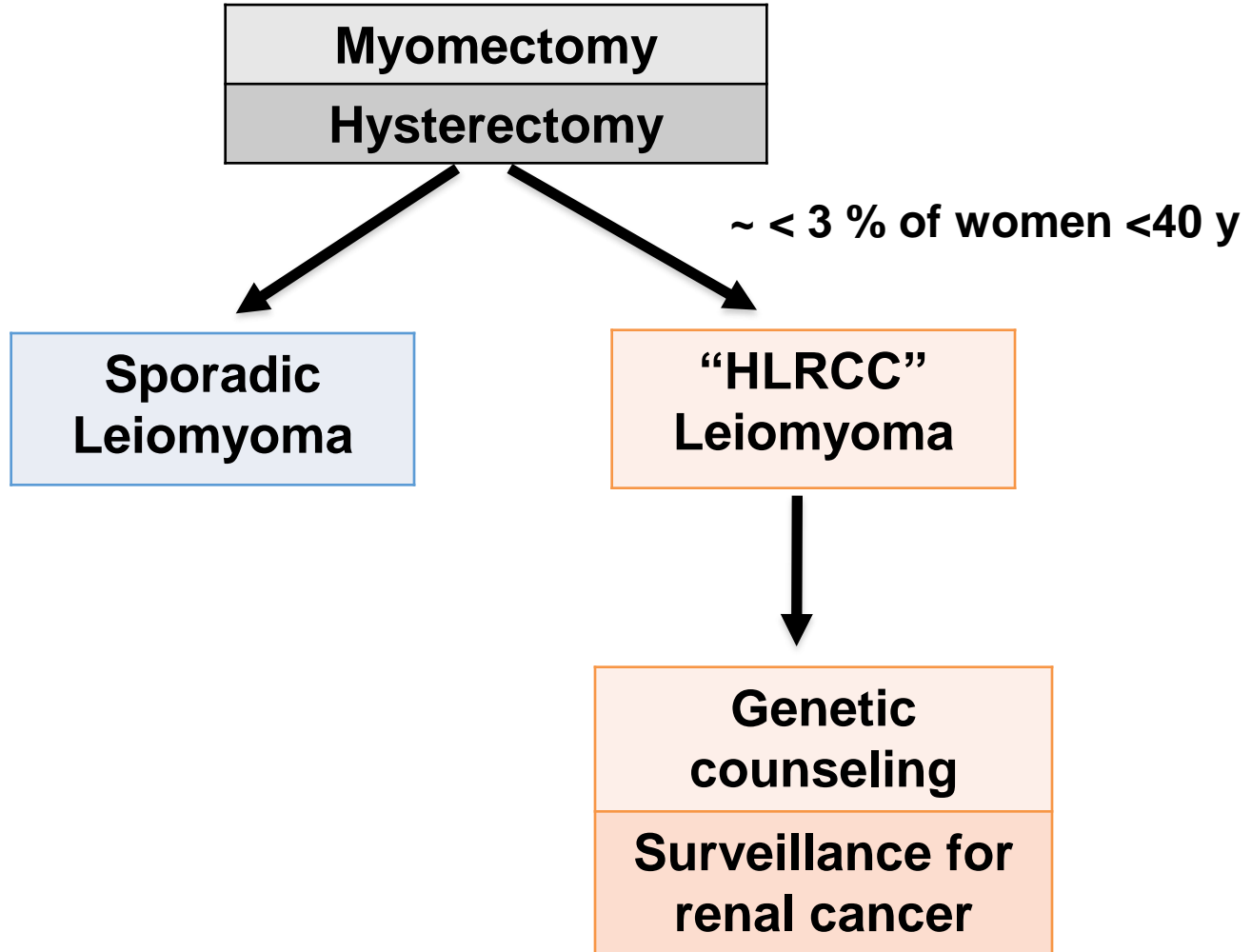
Average age 36

Renal cell carcinoma

Advanced stage / aggressive

Hereditary Leiomyoma Renal Cell Carcinoma Syndrome (HLRCC)

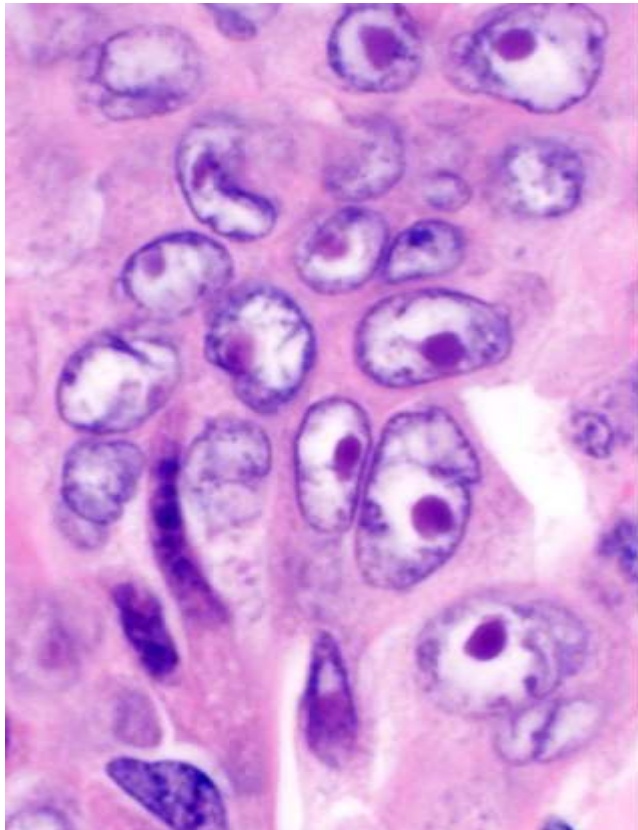
Is Screening Possible Using Pathology of Leiomyoma ?



Similar Morphology in Tumors of HLRCC Syndrome

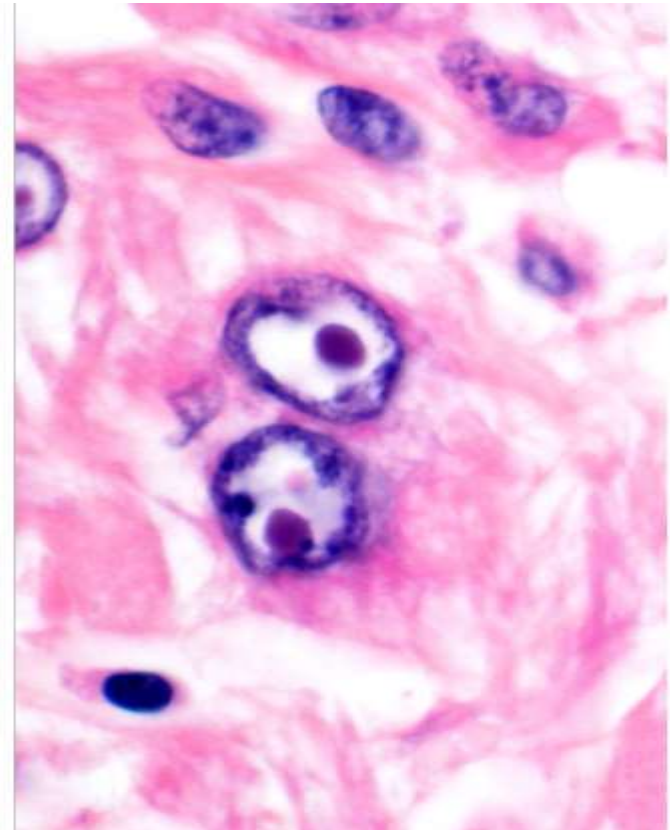Macronucleoli surrounded by halo

Renal Cell Carcinoma



Chen et al. Am J Surg Pathol 2014;38:627–637

Uterine Leiomyoma



Reyes et al. Mod. Pathol. 2014; 27: 1020.
Sanz-Ortega et al. Am. J. Surg. Pathol. 2013; 37: 74.
Joseph et al. Am. J. Surg. Pathol. 2015; 39: 1529.

Morphology of Fumarate Hydratase Deficient Uterine Leiomyoma

Low Magnification Clues

Alveolar-pattern edema

Staghorn-shape blood vessels

Chain-like distribution of tumor cells


High Magnification Criteria

Macro-nucleoli surrounded by halo

Cytoplasmic eosinophilic globules



**Normal
Fumarate Hydratase**

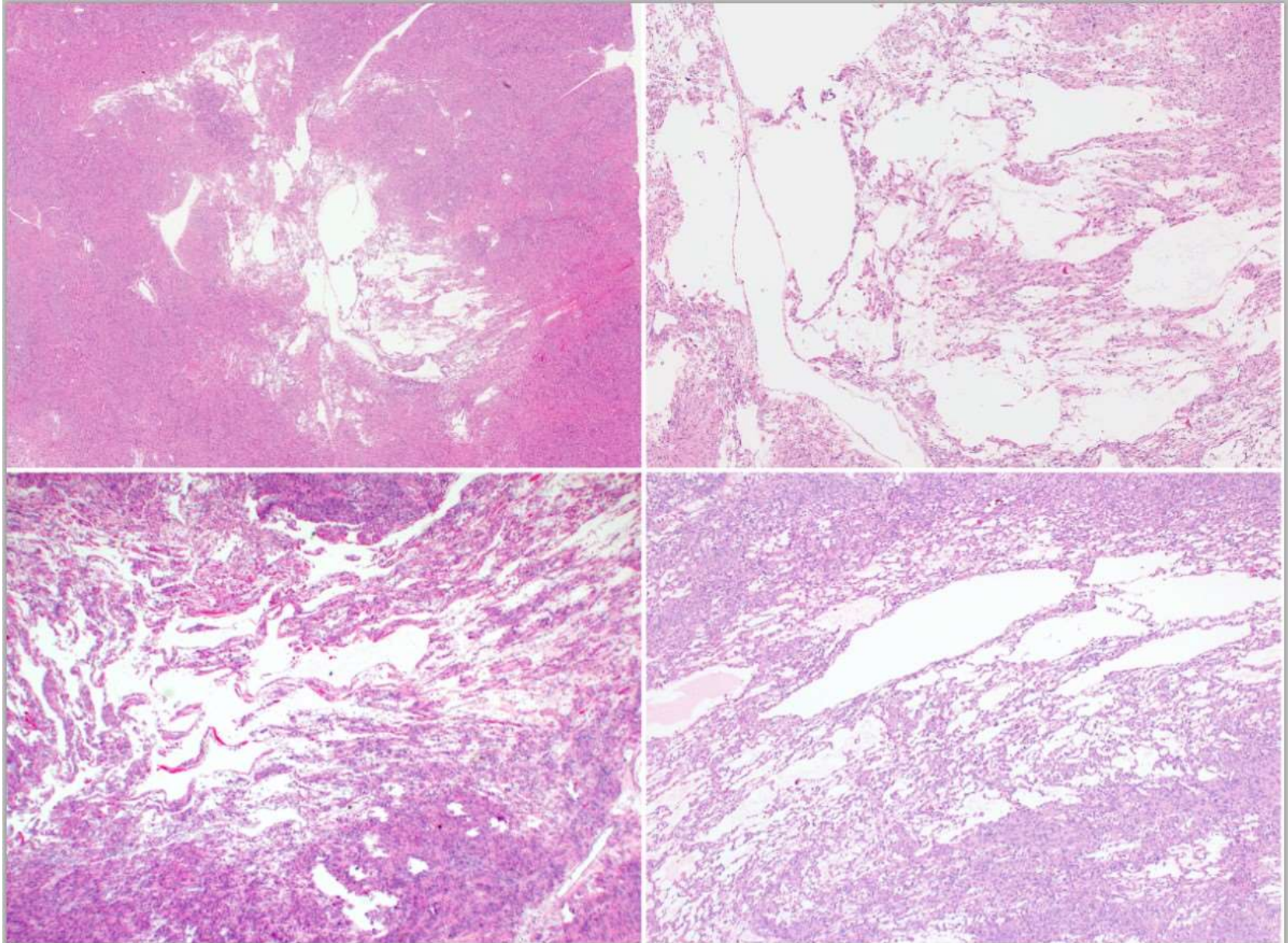


**Fumarate Hydratase-
Deficiency**

- **Somatic mutation** (not HLRCC)
- **Germline mutation** (HLRCC)

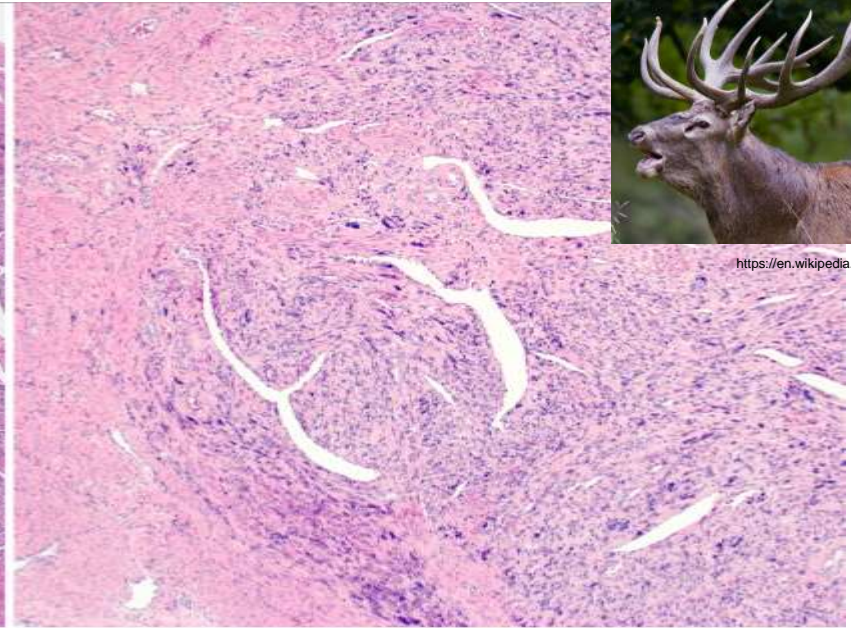
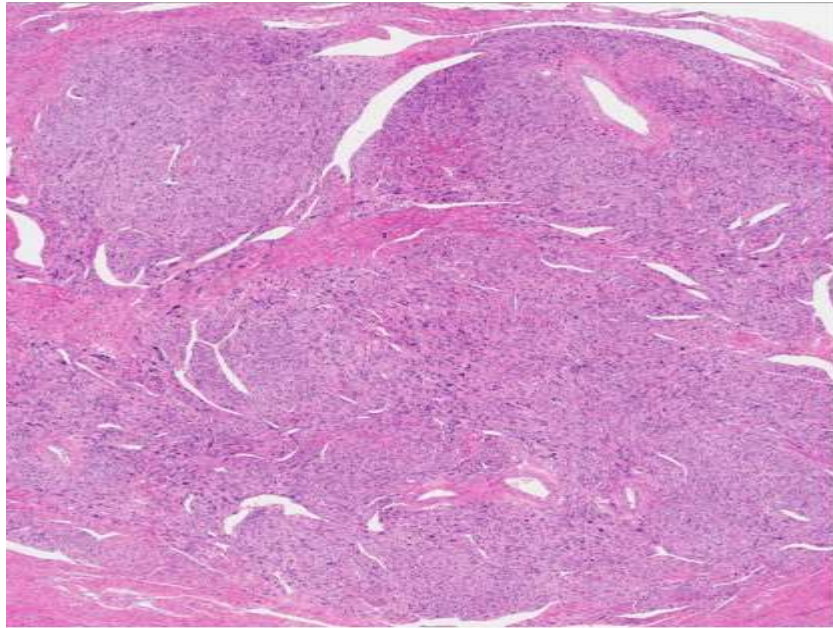
FH-d Morphology

Alveolar pattern edema

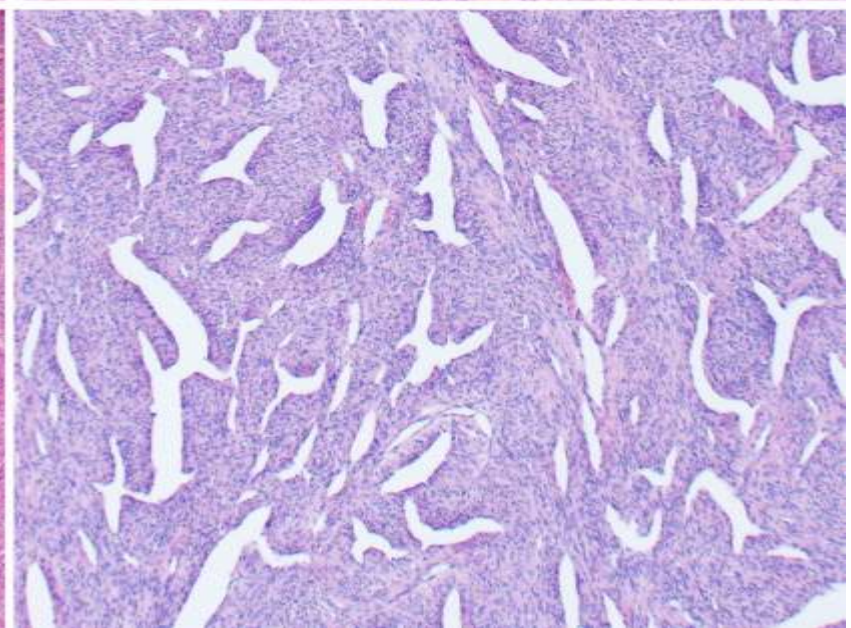
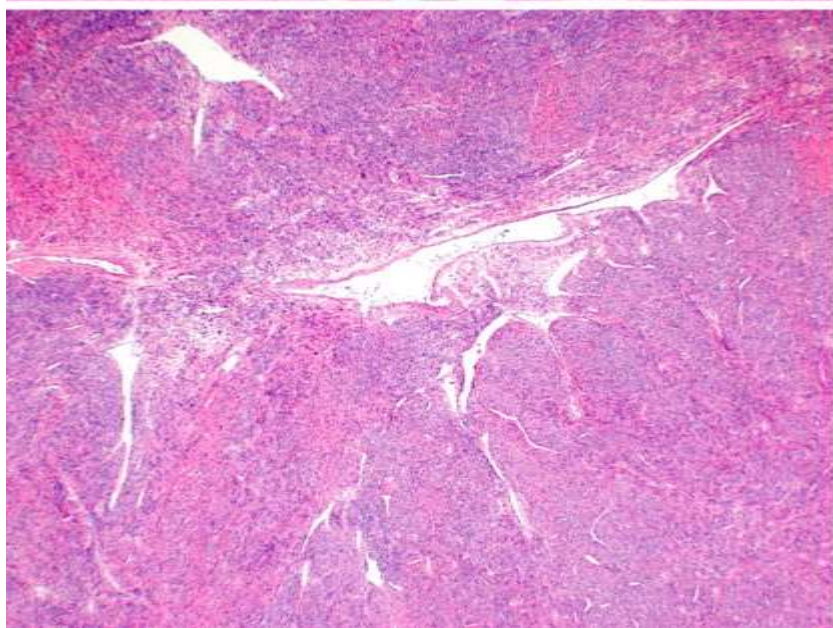


FH-d Morphology

Staghorn shape vessels

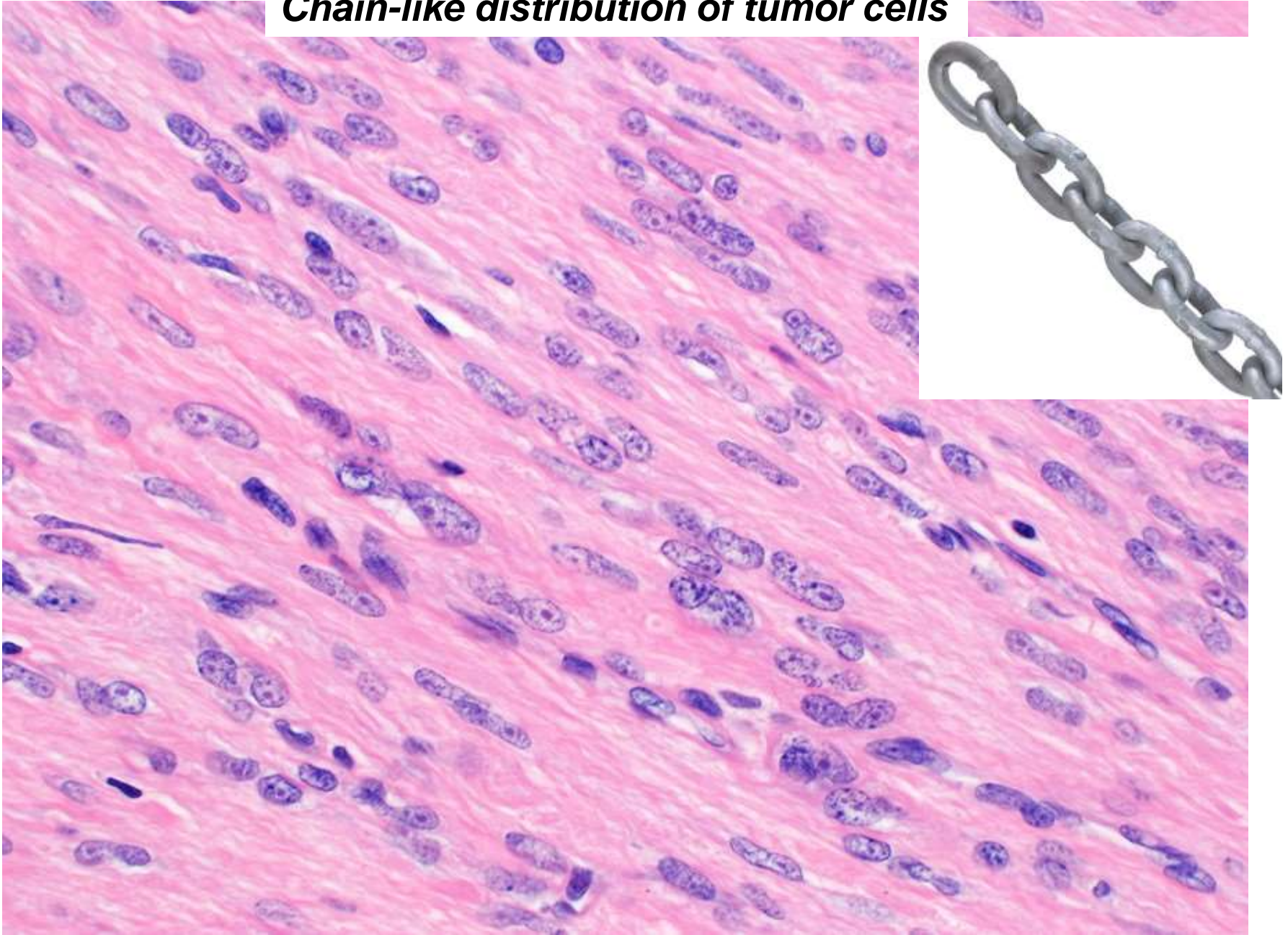


<https://en.wikipedia.org/wiki/Antler>



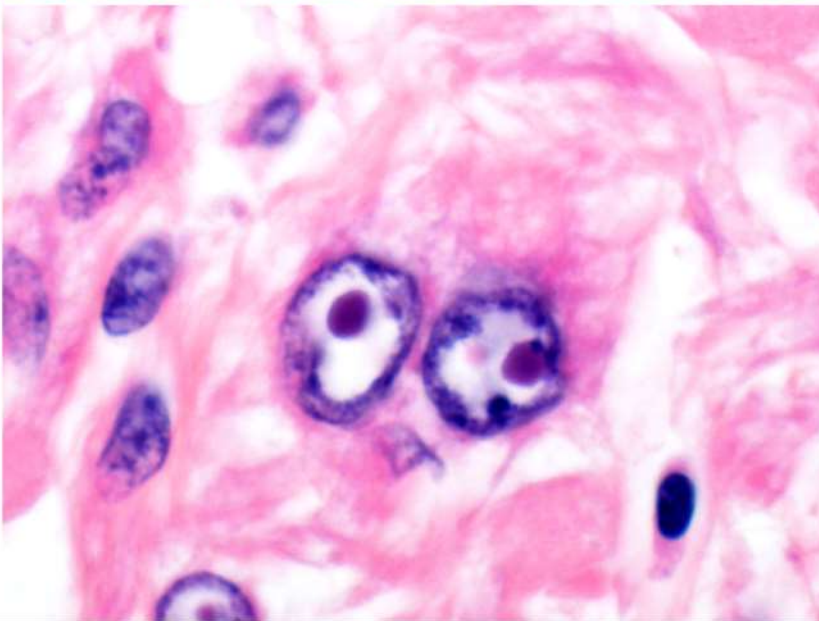
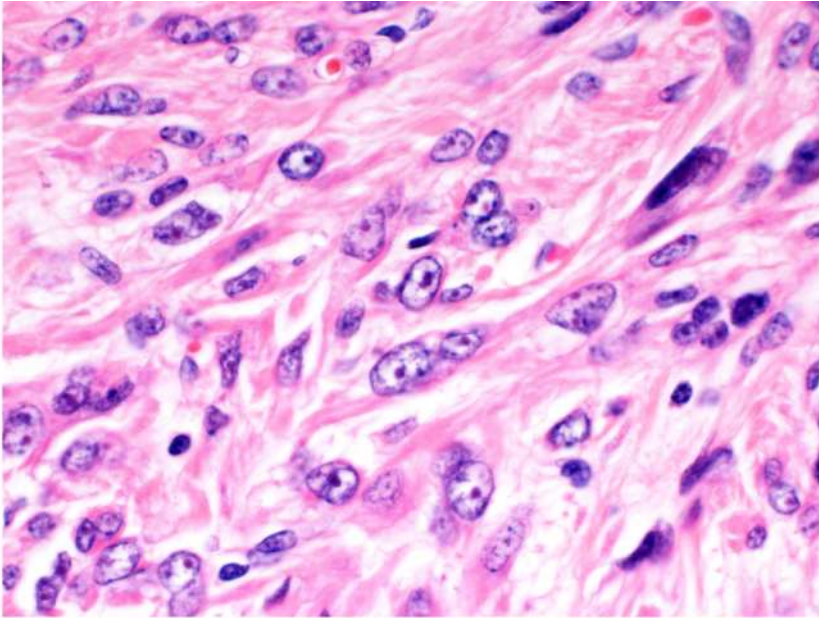
FH-d Morphology

Chain-like distribution of tumor cells

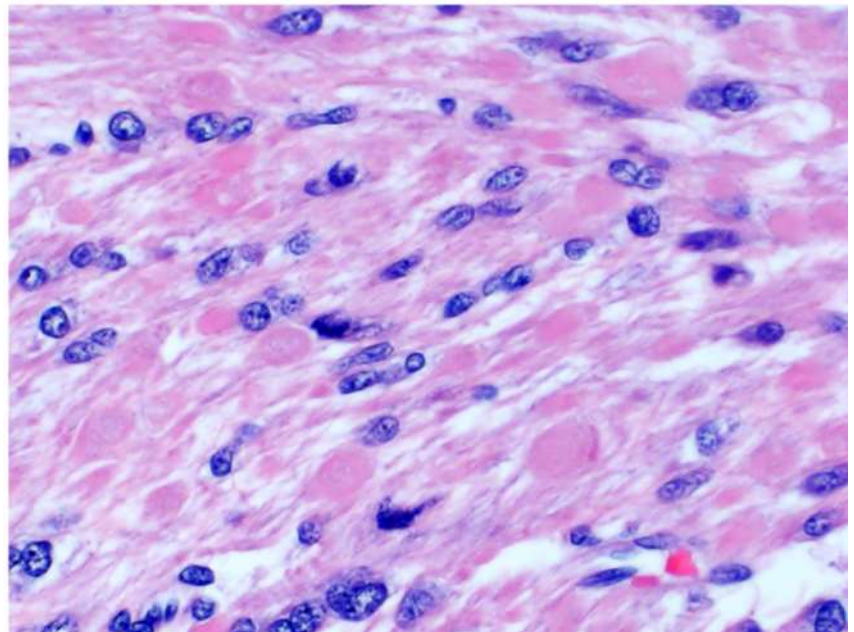
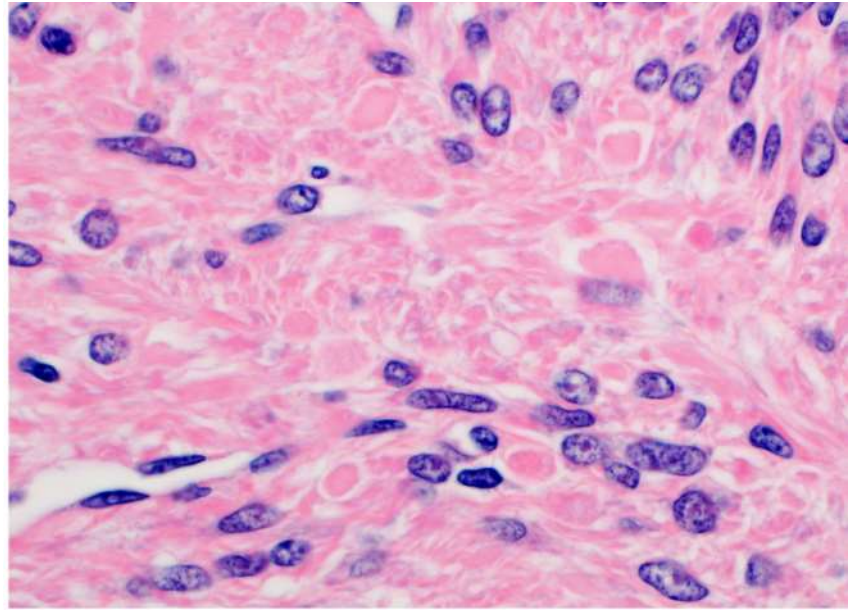


FH-d Morphology

Macronucleoli surrounded by halo

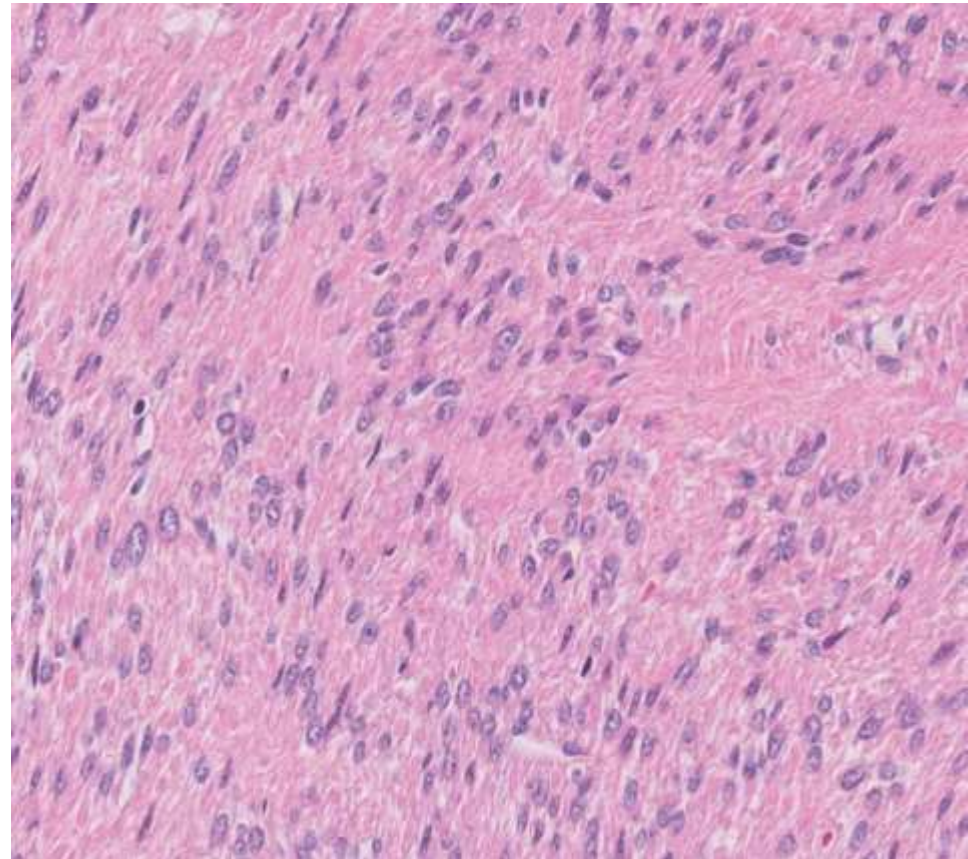
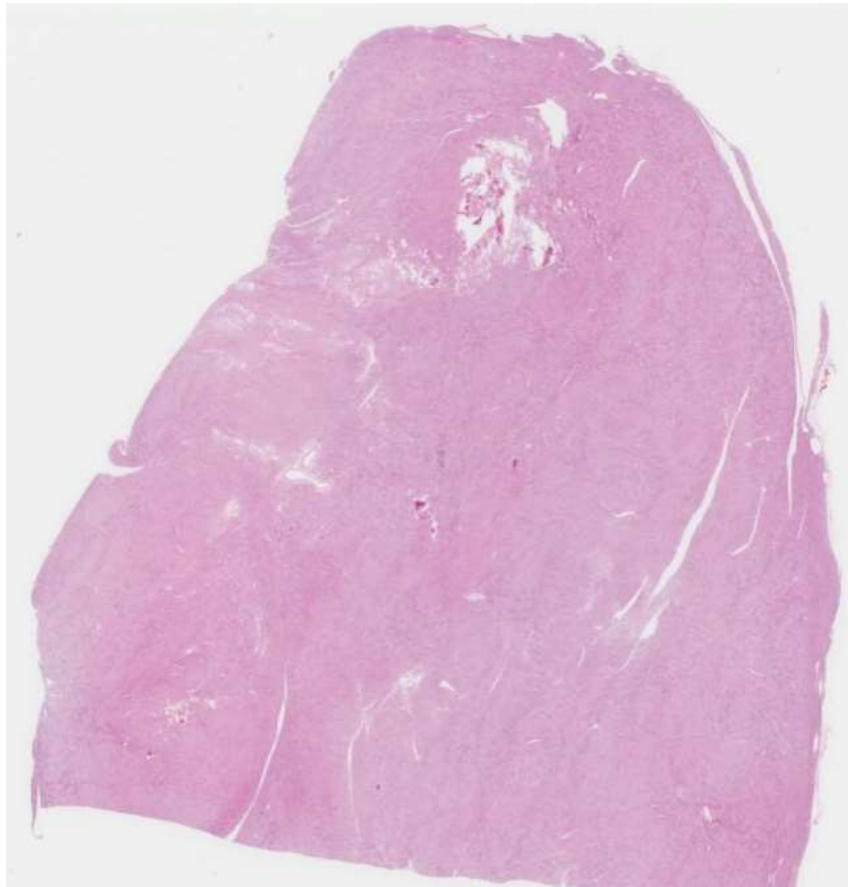


Eosinophilic Globules



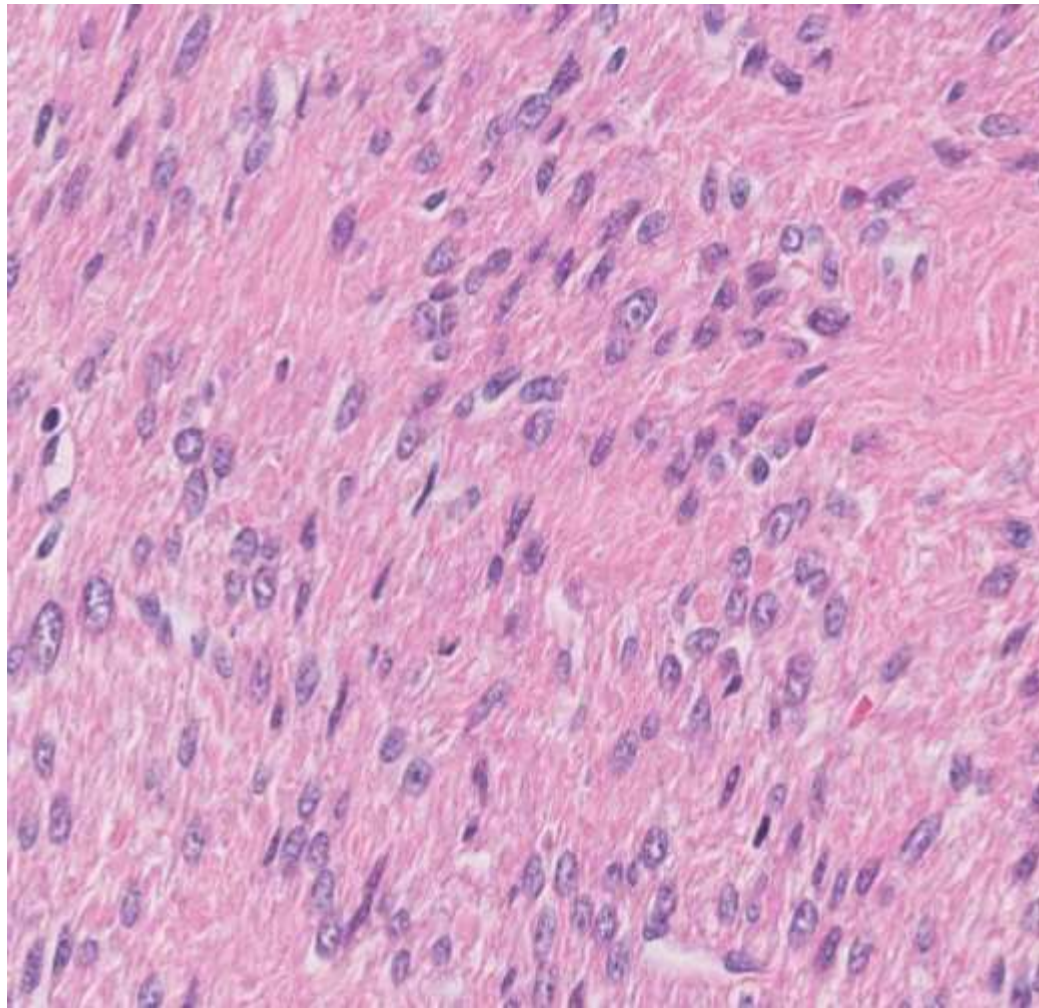
South Bay case 20-205

Low mag clues	
Alveolar edema	? maybe
Staghorn vessels	? maybe
Chain-like pattern	focal



South Bay case 20-205

High Magnification Criteria	
Macronucleoli	Yes-but focal, and on the smaller end of spectrum
Eosinophilic globules	Yes-but focal



South Bay case 20-205

Practical Questions:

How much FH-d morphology needs to be present to raise concern ?

Is there a minimum % of the leiomyoma that must show FH-d findings ?

Is there a minimum size required to be a macro-nucleolus ?

Is there a role for FH immunostain ?

Prospective Detection of Germline Mutation of *Fumarate Hydratase* in Women With Uterine Smooth Muscle Tumors
Using Pathology-based Screening to Trigger Genetic
Counseling for Hereditary Leiomyomatosis Renal Cell
Carcinoma Syndrome

A 5-Year Single Institutional Experience

Joseph T. Rabban, MD, MPH, Emily Chan, MD, PhD,* Julie Mak, MS, LCGC,†
Charles Zaloudek, MD,* and Karuna Garg, MD**

Am J Surg Pathol 2019;43:639–655

- No minimum requirement for FH-d morphology. Any amount counted.
- 30 cases with FH-d morphology out of 2,060 patients (subset pursued genetic testing)
 - 50% went on to test positive for FH germline mutation
 - 40% with FH germline mutation had NORMAL FH staining

South Bay case 20-205

Final Diagnosis: Leiomyoma with FH-d morphology

Genetic Diagnosis: Pathogenic FH germline mutation

Take Home Messages

1. **Apply a low threshold for reporting FH-d morphology.**

Particularly in young women (<40 yrs)

2. **H&E stain is sufficient. Avoid FH immunostain.**

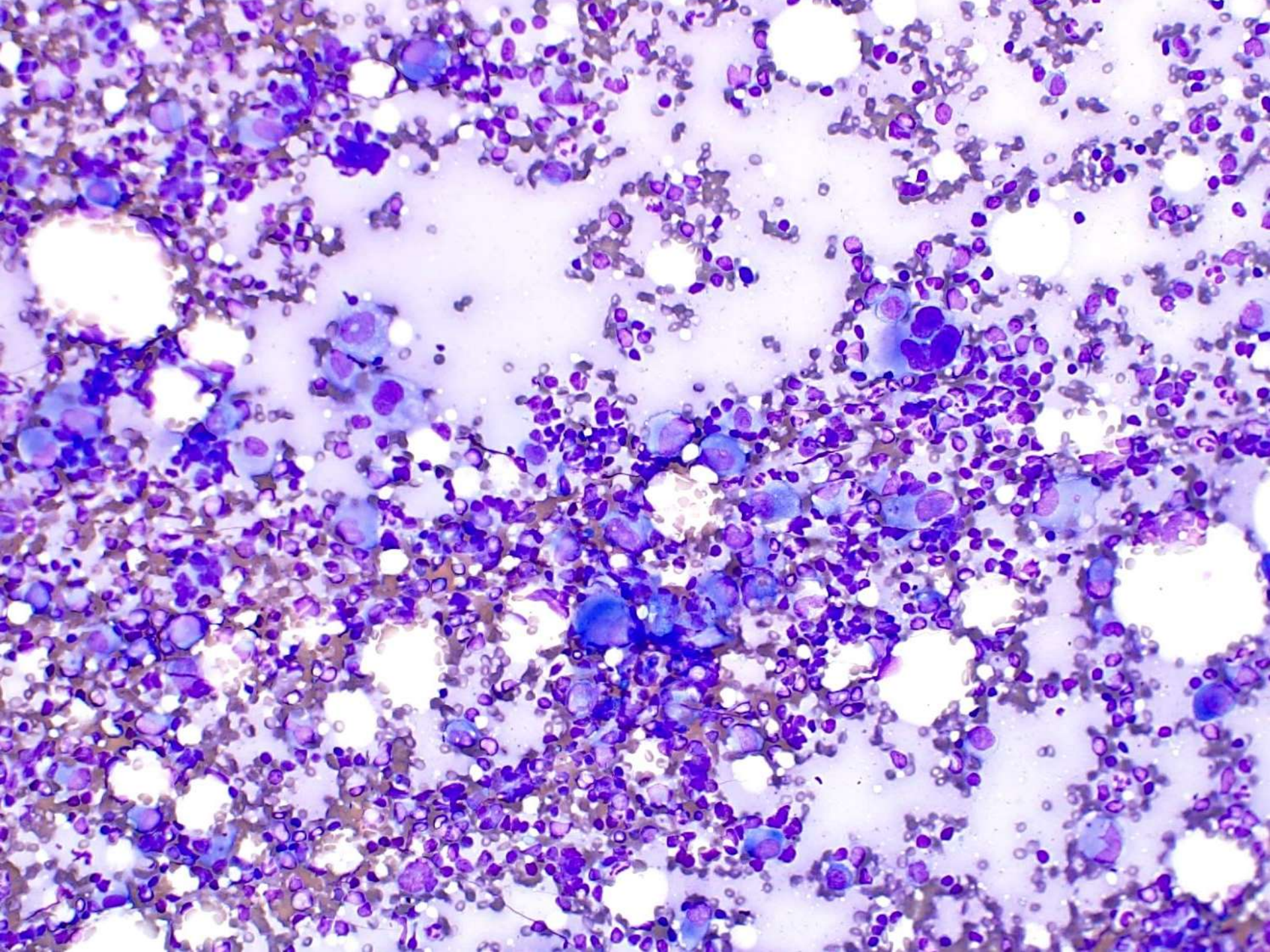
An intact result does not exclude FH germline mutation.

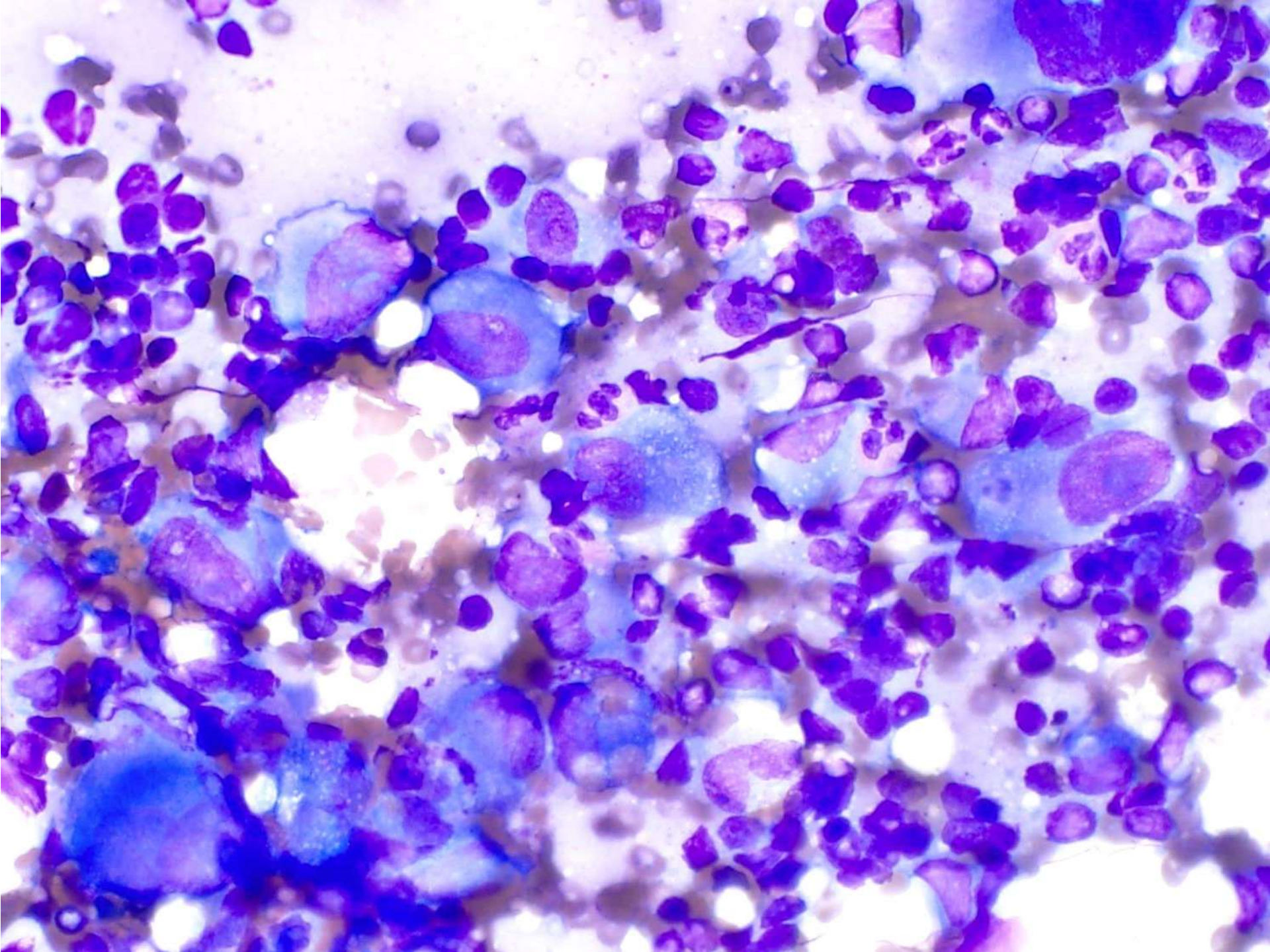
An abnormal result does not prove FH germline mutation.

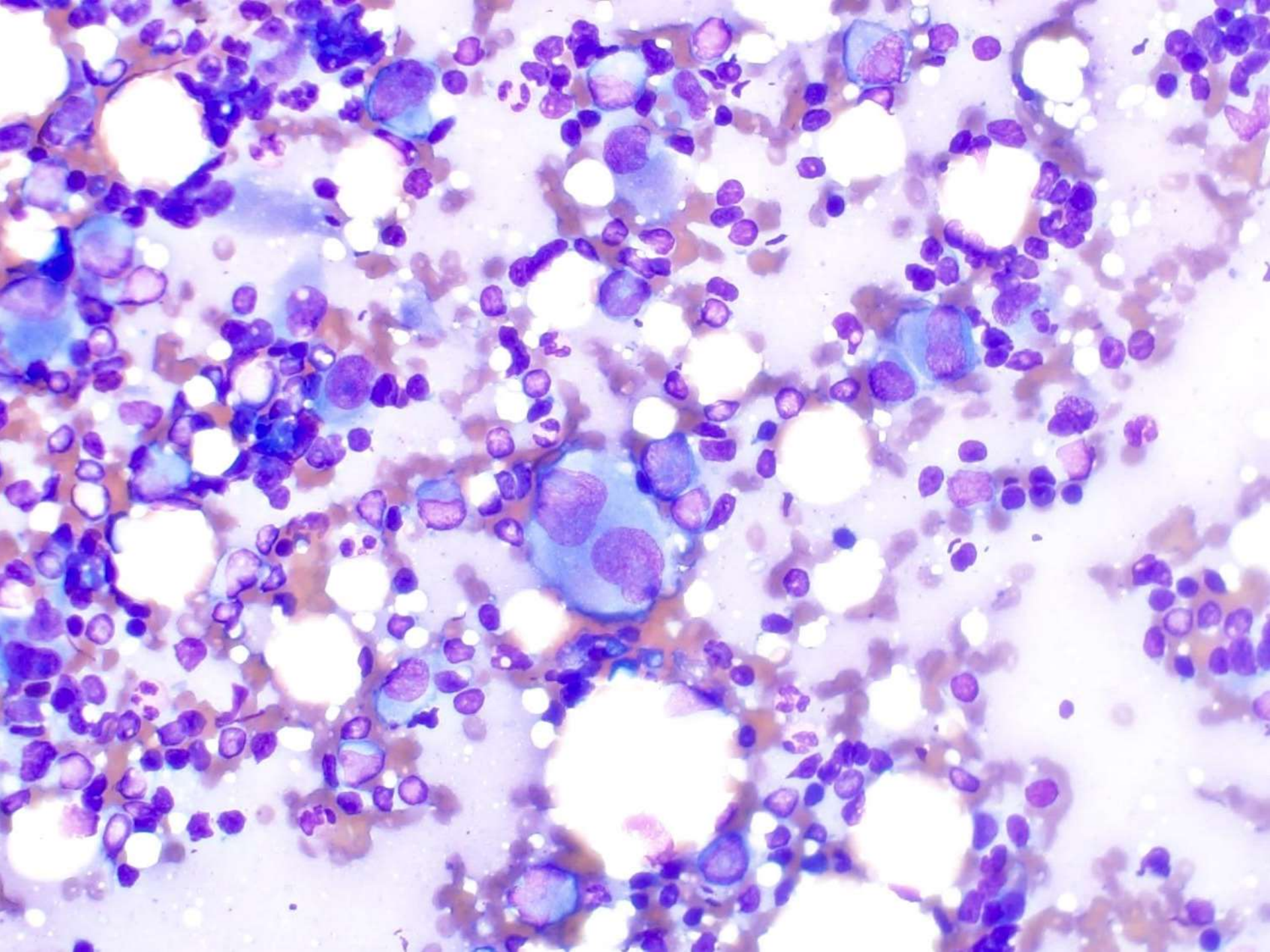
20-0206

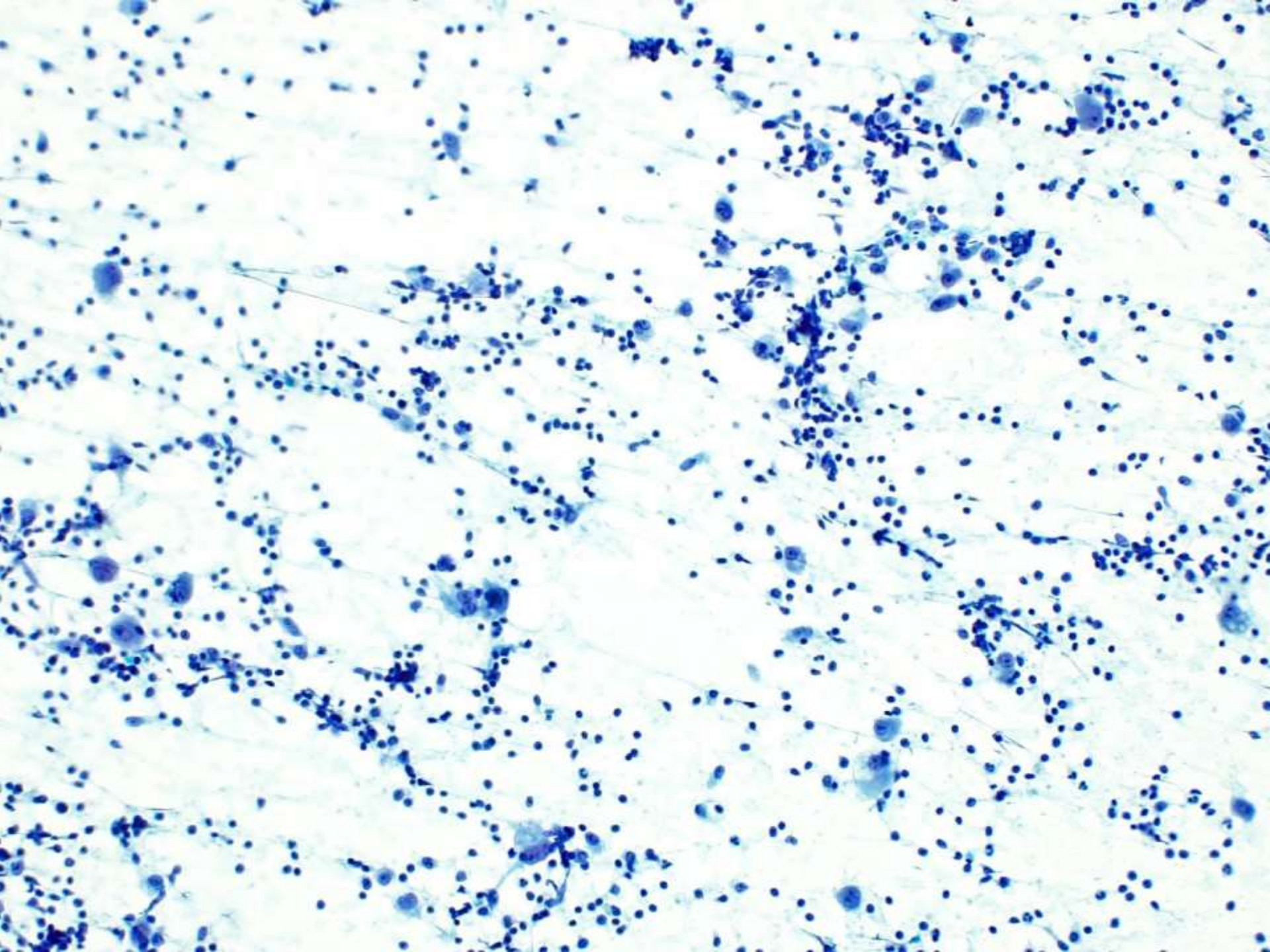
Sara Zadeh/Brock Martin; Stanford

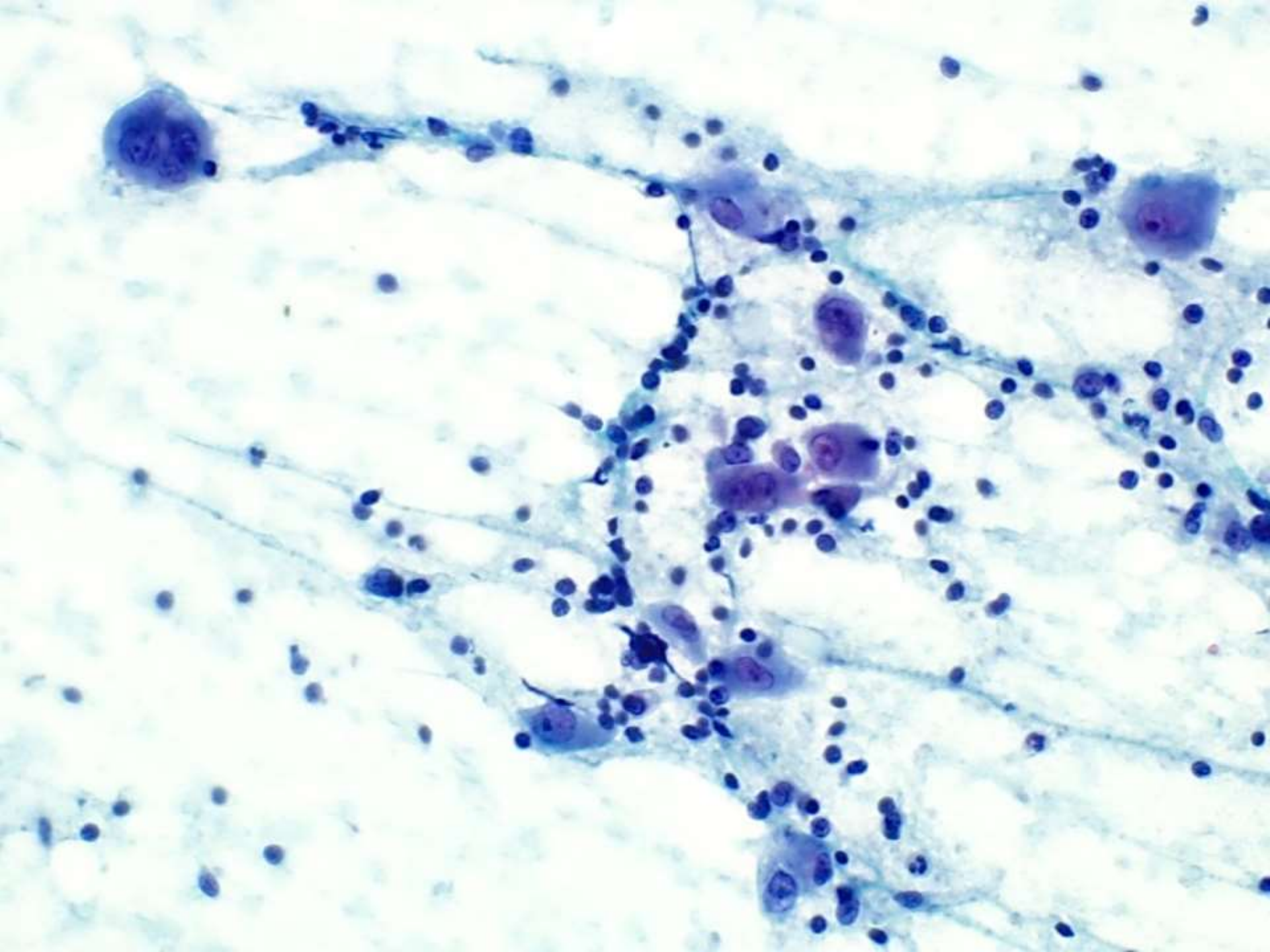
78-year-old F follicular lymphoma and mixed response to radiation therapy. FNA of non-responding cervical lymph nodes performed.

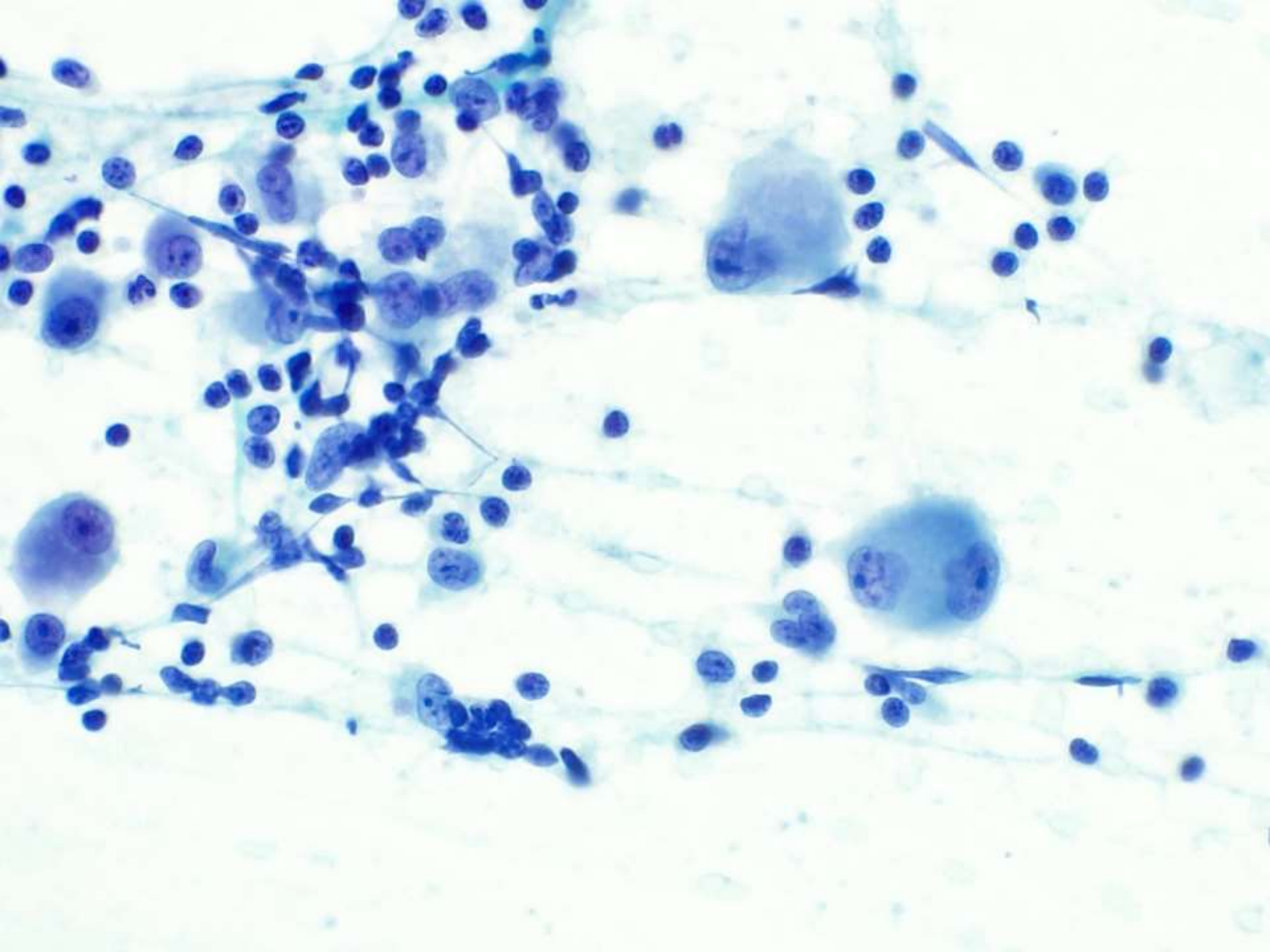


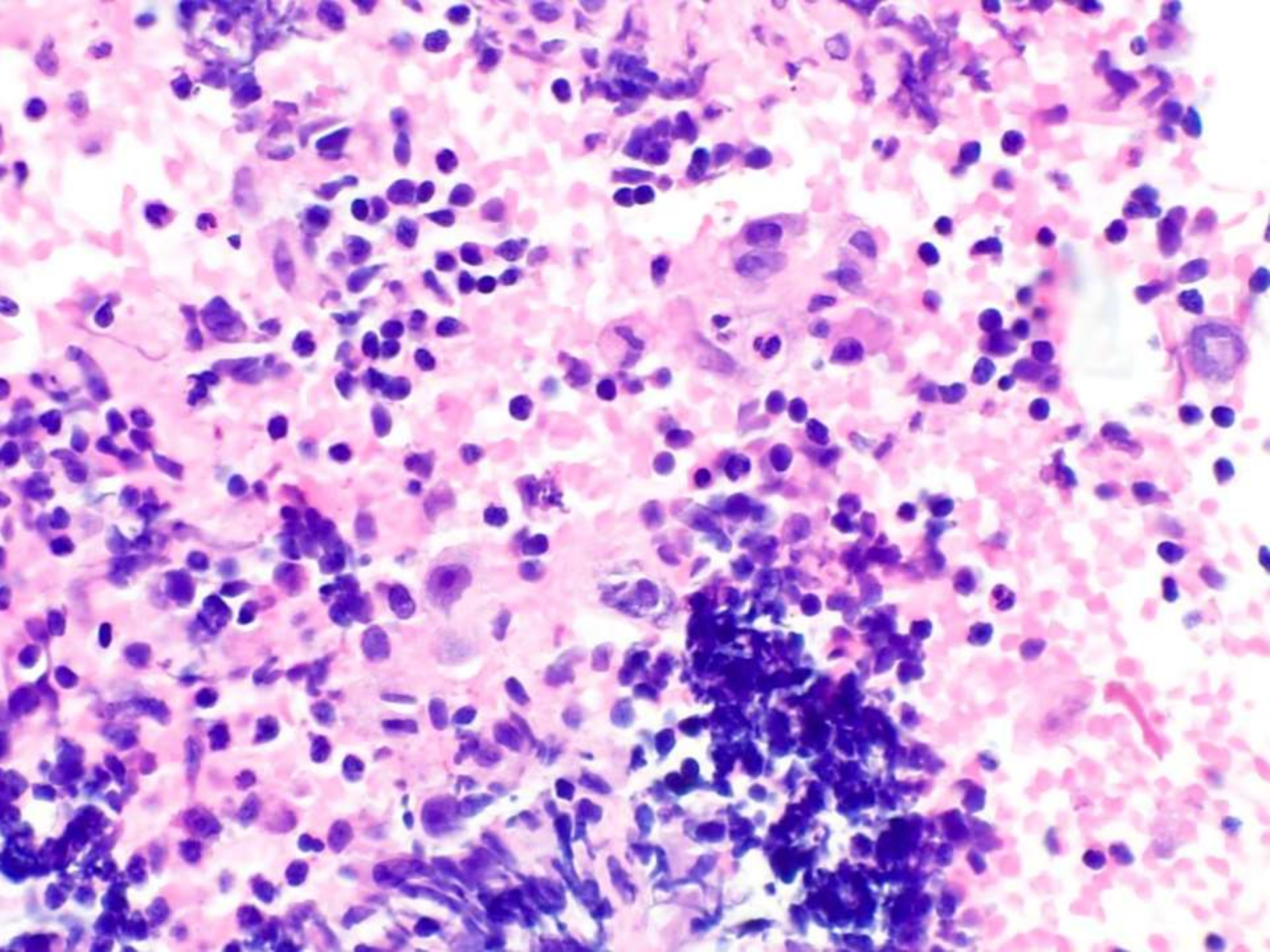


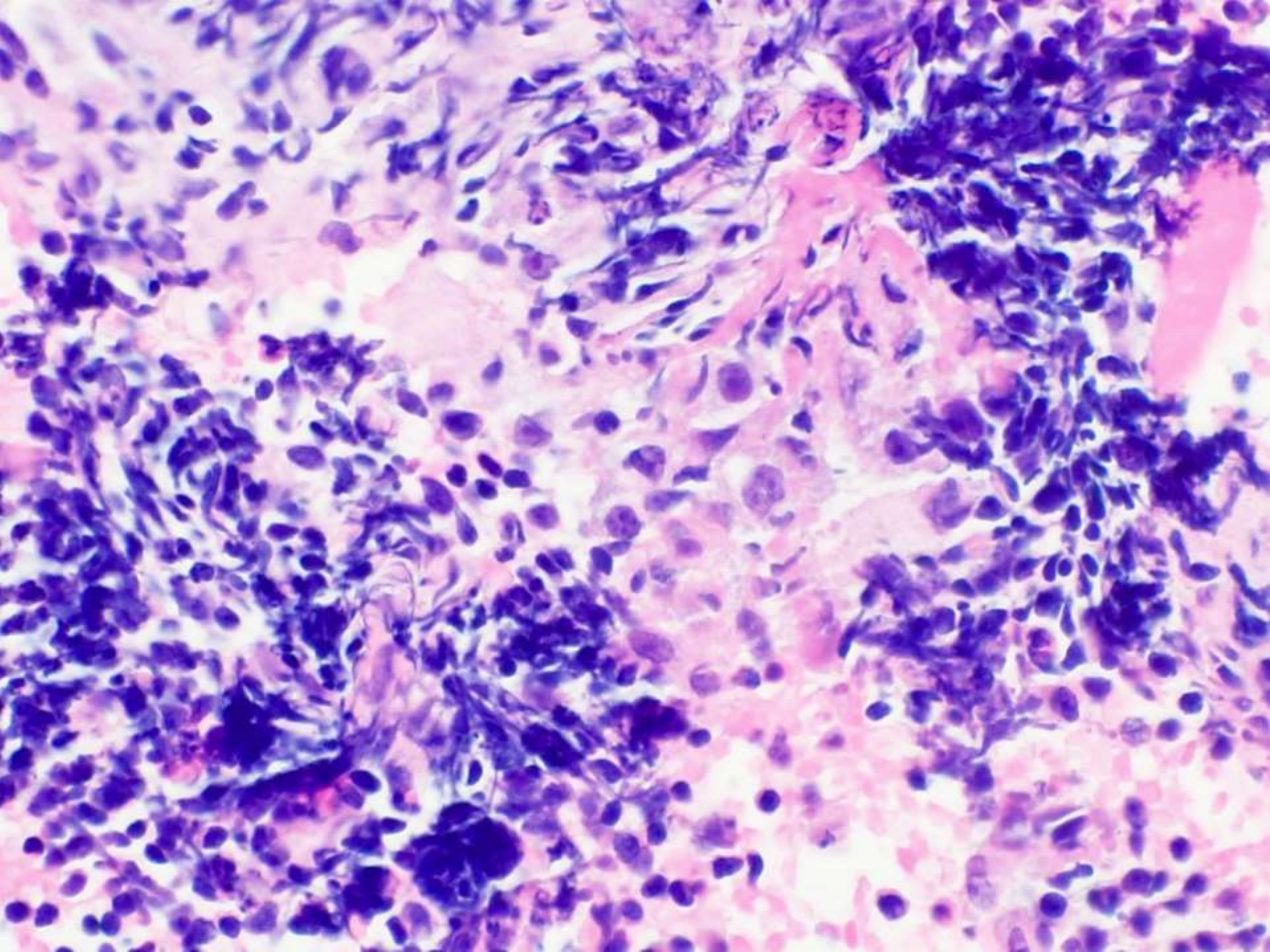


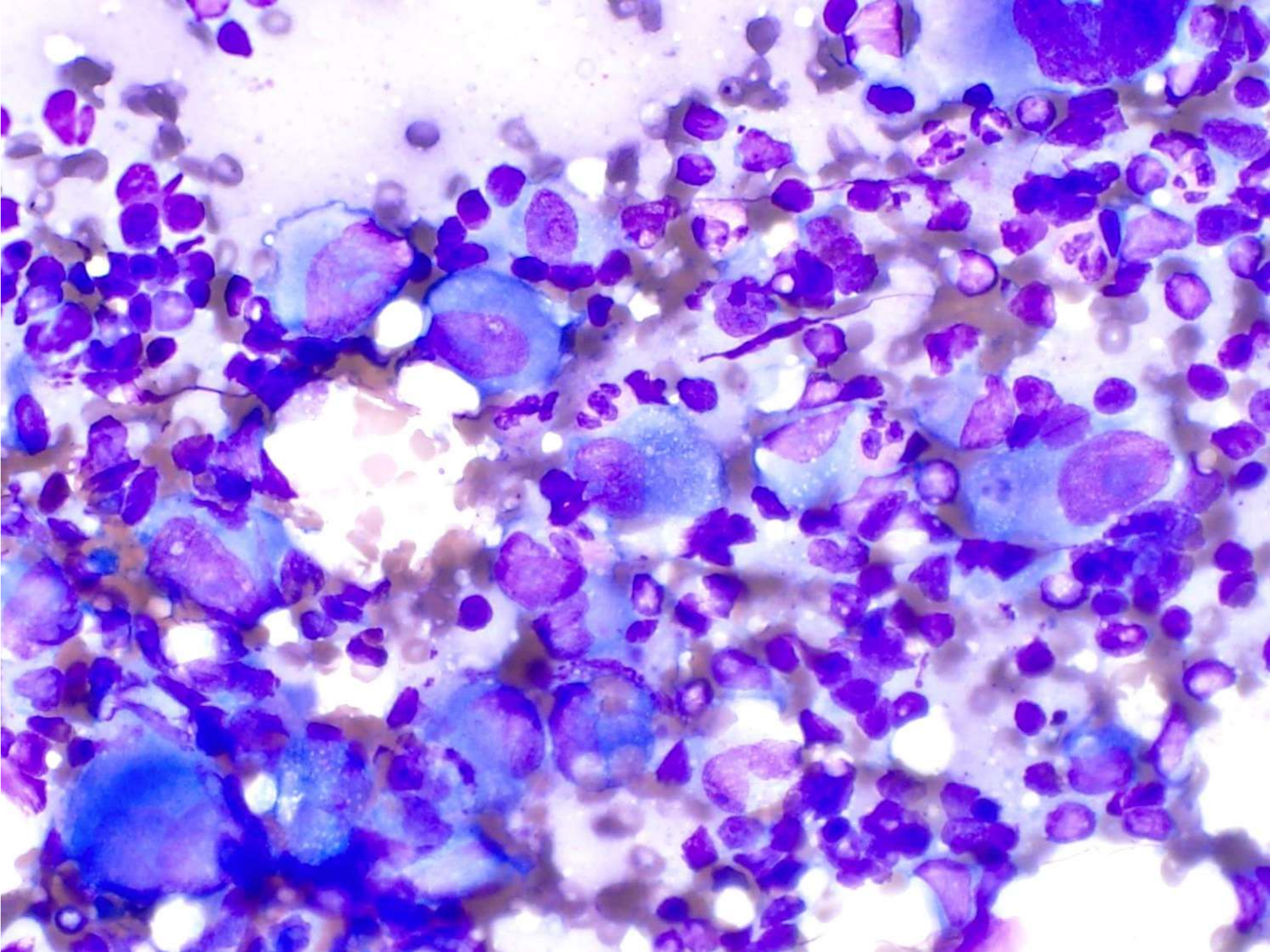


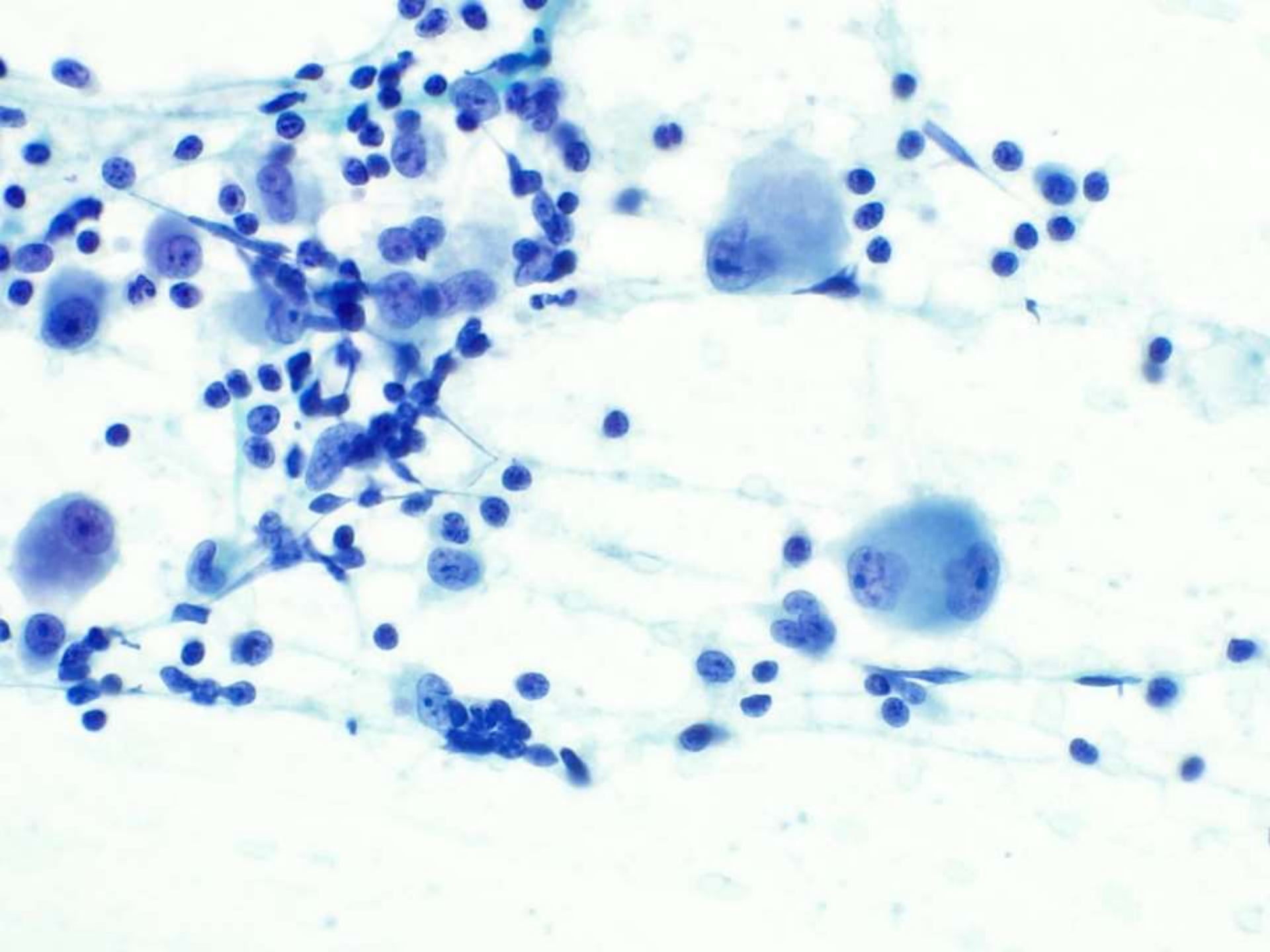


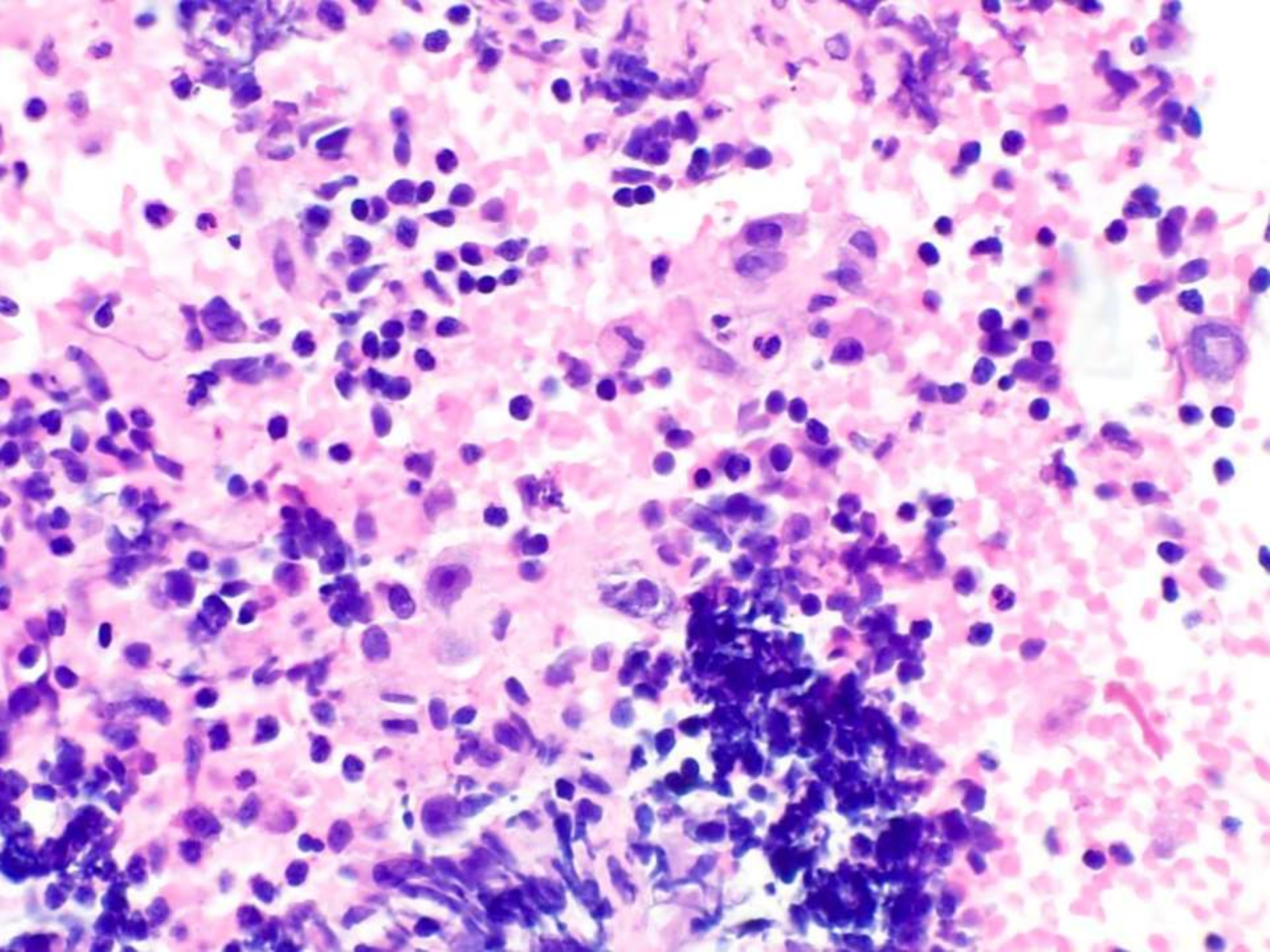


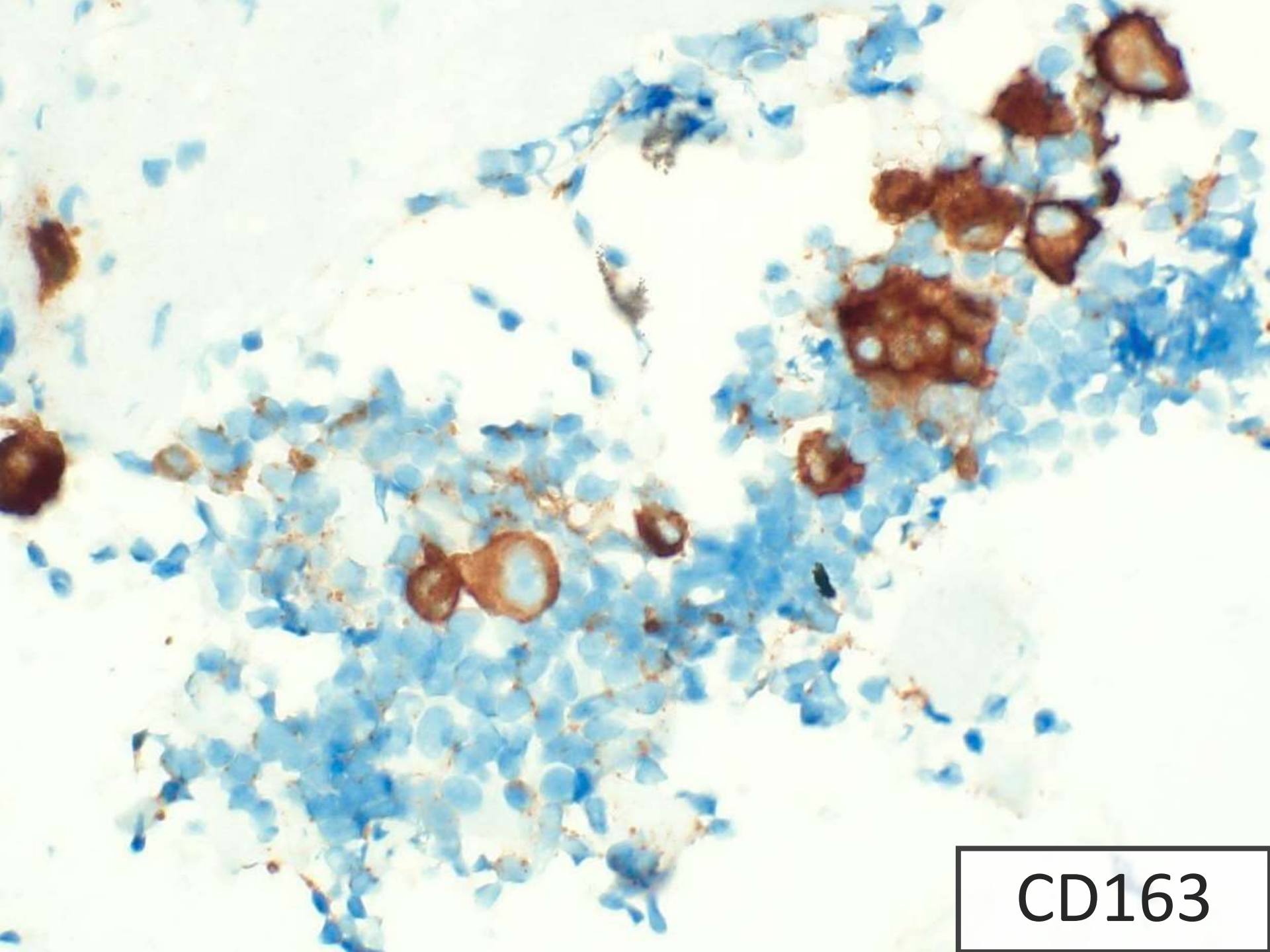




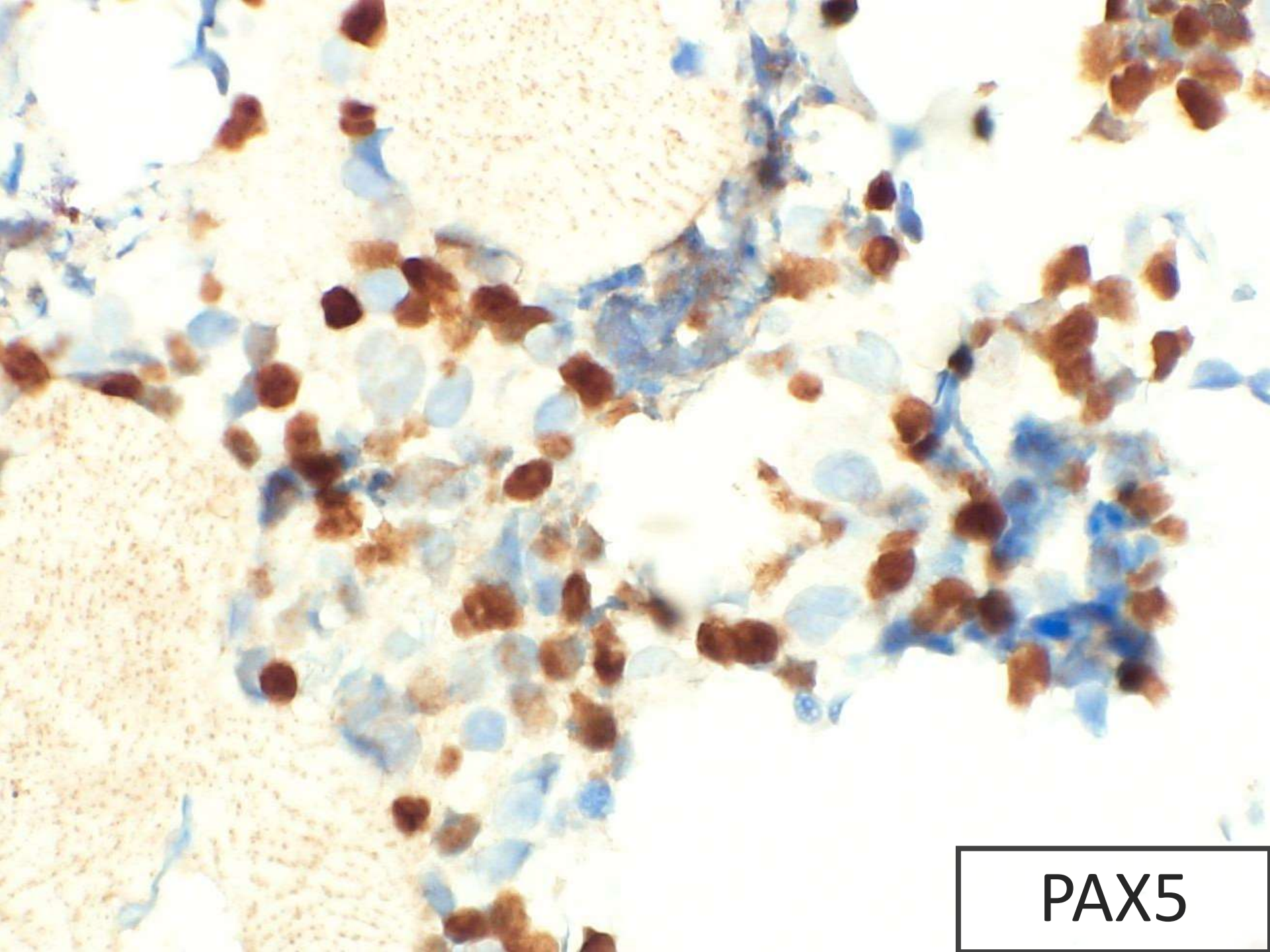








CD163



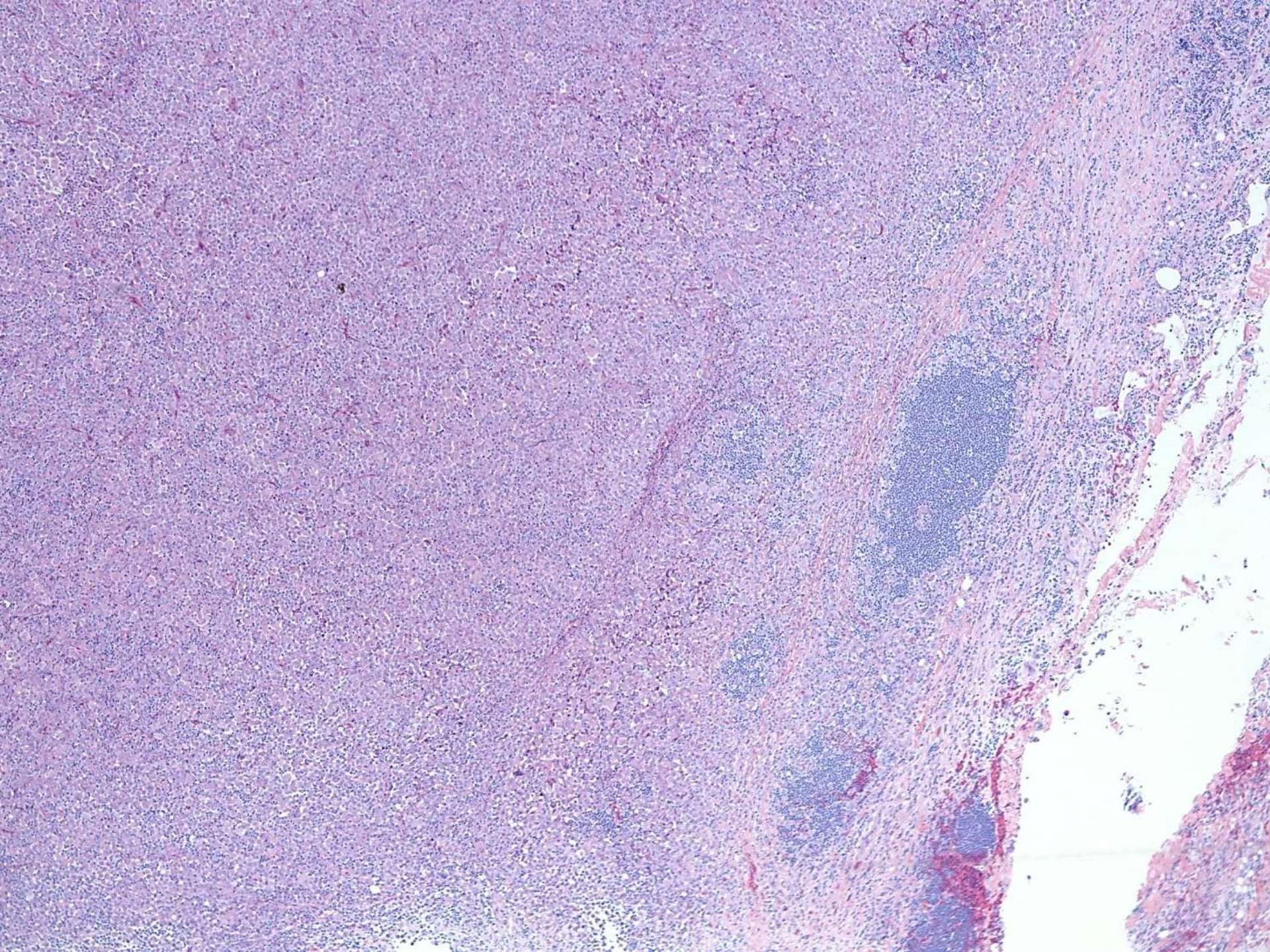
PAX5

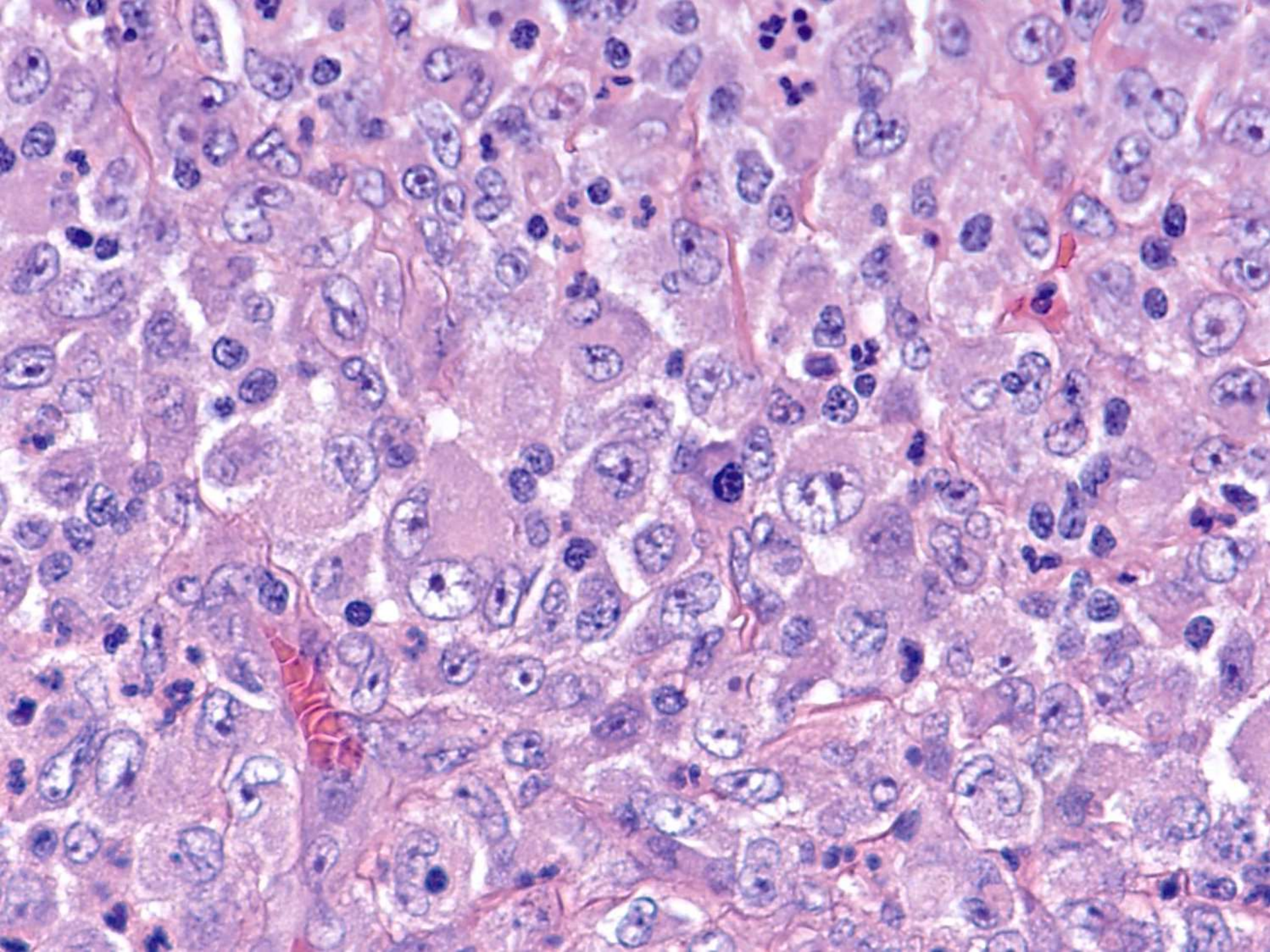
FNA Diagnosis: Follicular lymphoma
with features suspicious for
histiocytic sarcoma

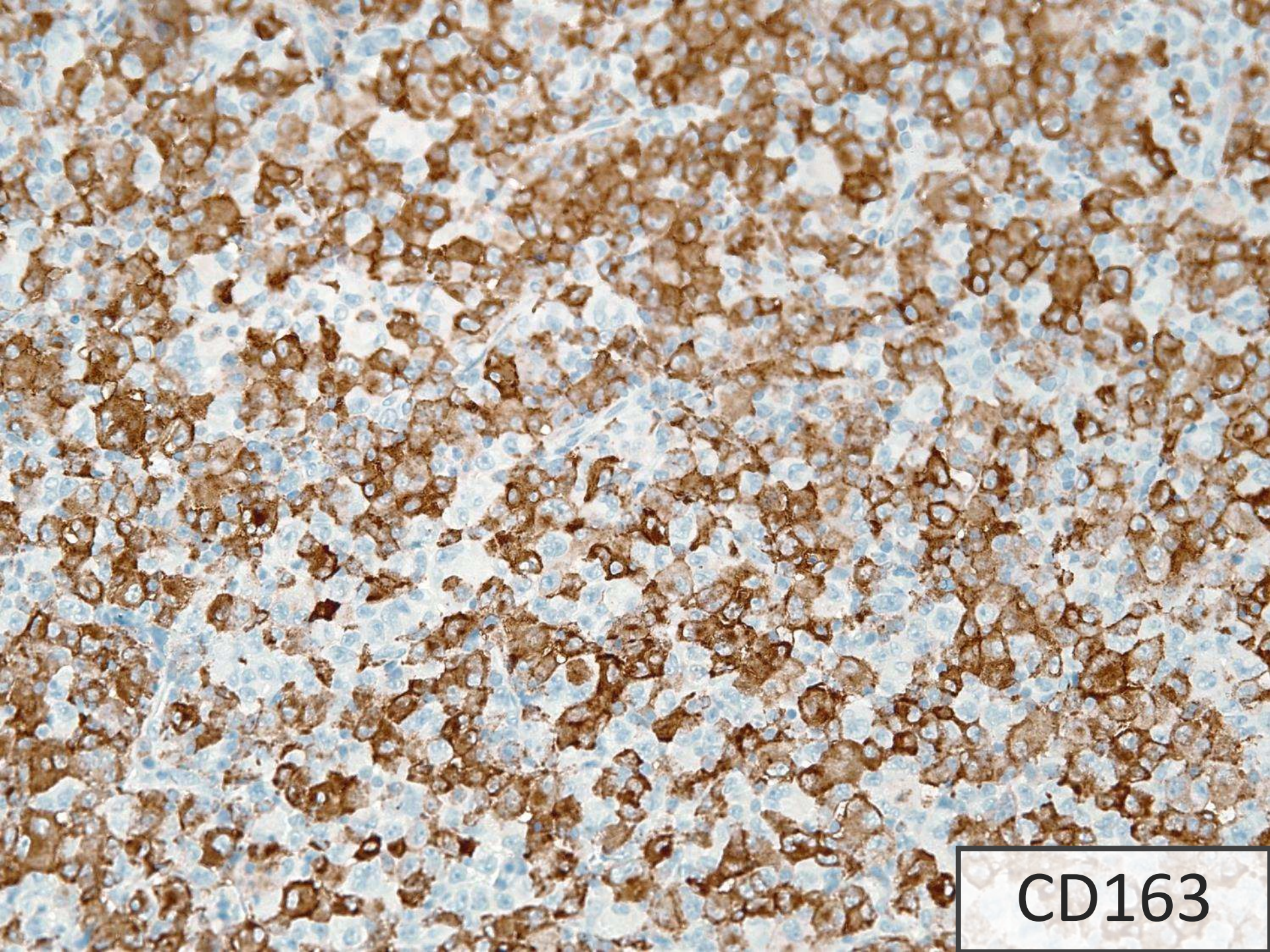
Excisional Biopsy: Histiocytic sarcoma
with focal areas of residual grade 1-2
follicular lymphoma

A photograph of an excisional biopsy specimen, showing several dark, irregularly shaped tissue fragments with some internal structure visible, set against a light background. The text "Excisional Biopsy" is overlaid in white.

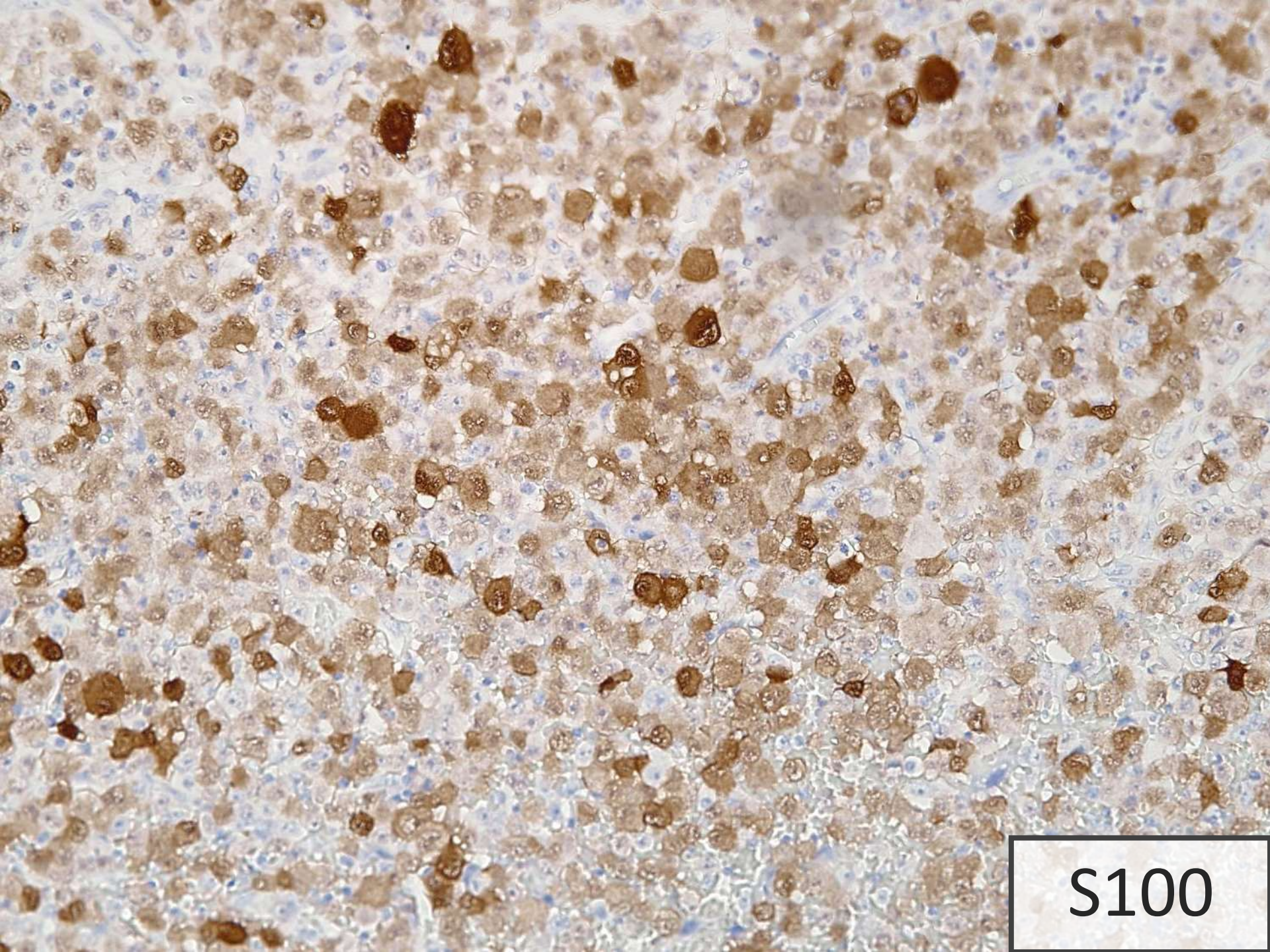
Excisional Biopsy







CD163



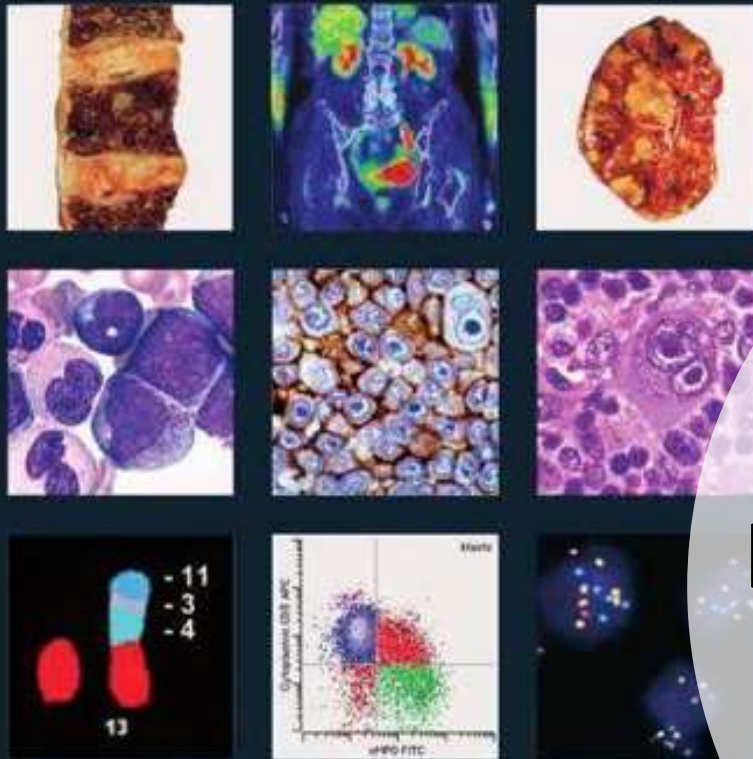
S100



BCL2

WHO Classification of Tumours of Haematopoietic and Lymphoid Tissues

Steven H. Swerdlow, Elias Campo, Nancy Lee Harris, Elaine S. Jaffe, Stefano A. Pileri,
Harald Stein, Jürgen Thiele, Daniel A. Arber, Robert P. Hasserjian,
Michelle M. Le Beau, Attilio Orazi, Rainer Siebert



Histiocytic Sarcoma

Differential Diagnosis

- Anaplastic large cell lymphoma
 - High-grade B-cell lymphoma
 - Hodgkin lymphoma
 - Myeloid sarcoma
 - Follicular dendritic cell sarcoma
 - Langerhans cell sarcoma
-
- Melanoma
 - Epithelioid sarcoma
 - Epithelioid angiosarcoma
 - Unclassified pleomorphic sarcoma

Immunohistochemistry

Positive

- **Histiocyte marker: CD68, CD163 (CD11c, lysozyme, PU.1)**
- CD45
- HLA-DR
- S100 (subset +)
- CD31 (subset +)
- Ki-67: 5-50%

Negative

- Epithelial: keratins, EMA
- B-cell markers: PAX5, CD20
- T-cell markers: CD4*, CD8
- Myeloid: CD13, CD33, MPO
- Dendritic: CD21, CD23, CD35
- Langerhans cell: CD1a* and langerin
- Melanocytic: SOX10, Melan A, HMB-45
- Vascular: CD34, ERG
- CD15 and CD30

* May be focally positive

Immunohistochemistry

Positive

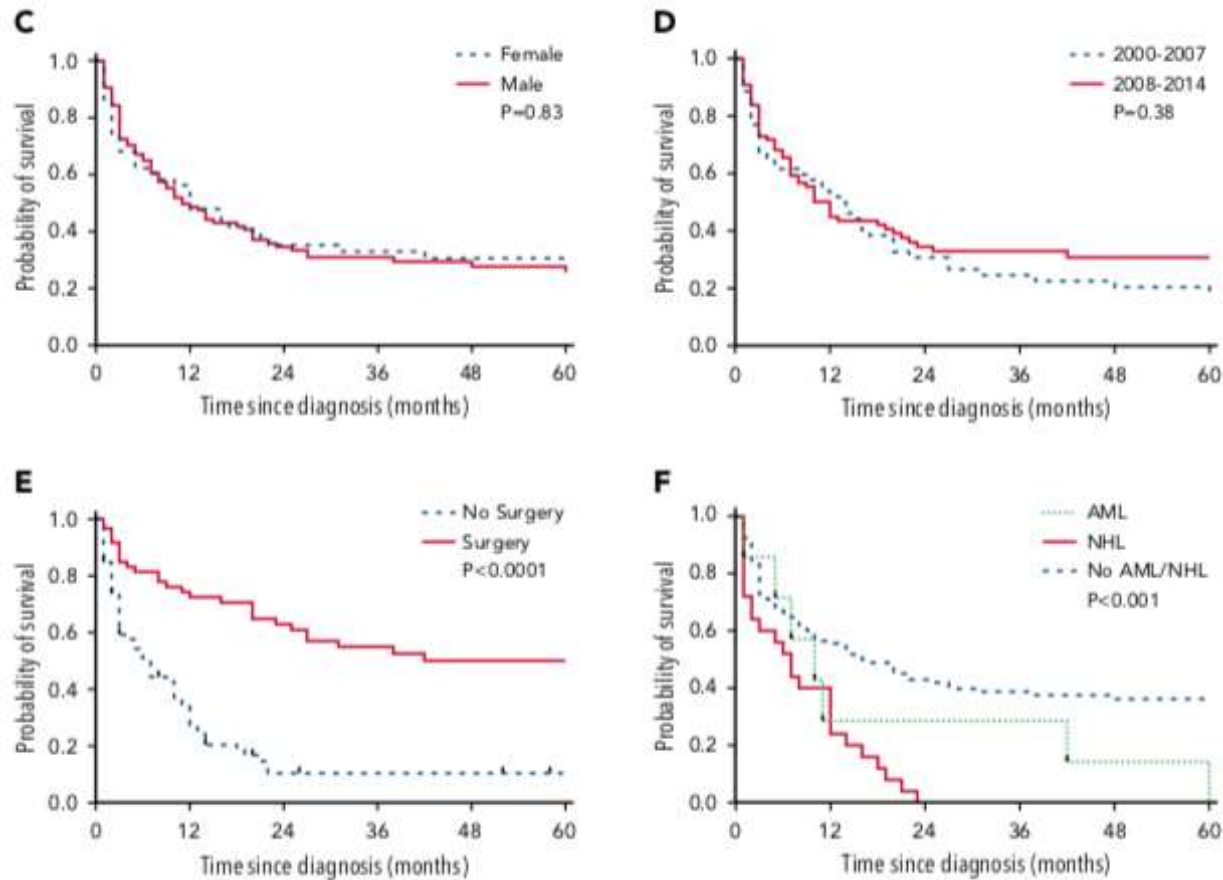
- **Histiocyte marker: CD68, CD163 (CD11c, lysozyme, PU.1)**
- CD45
- HLA-DR
- S100 (subset +)
- CD31 (subset +)
- Ki-67: 30-40%
- BCL2
- PDL1 (variable)

Negative

- Epithelial: keratins, EMA
- B-cell markers: PAX5, CD20
- T-cell markers: CD4*, CD8
- Myeloid: CD13, CD33, MPO
- Dendritic: CD21, CD23, CD35
- Langerhans cell: CD1a* and langerin
- Melanocytic: SOX10, Melan A, HMB-45
- Vascular: CD34, ERG
- CD15 and CD30
- BRAF (V600E)
- Others: CD123, CD117, CD38, desmin, EBV ish

* May be focally positive

Overall Survival




Kommalapati, A. et al. (2018). Histiocytic sarcoma: a population-based analysis of incidence, demographic disparities, and long-term outcomes. *Blood*, 131(2), 265

ARTICLE



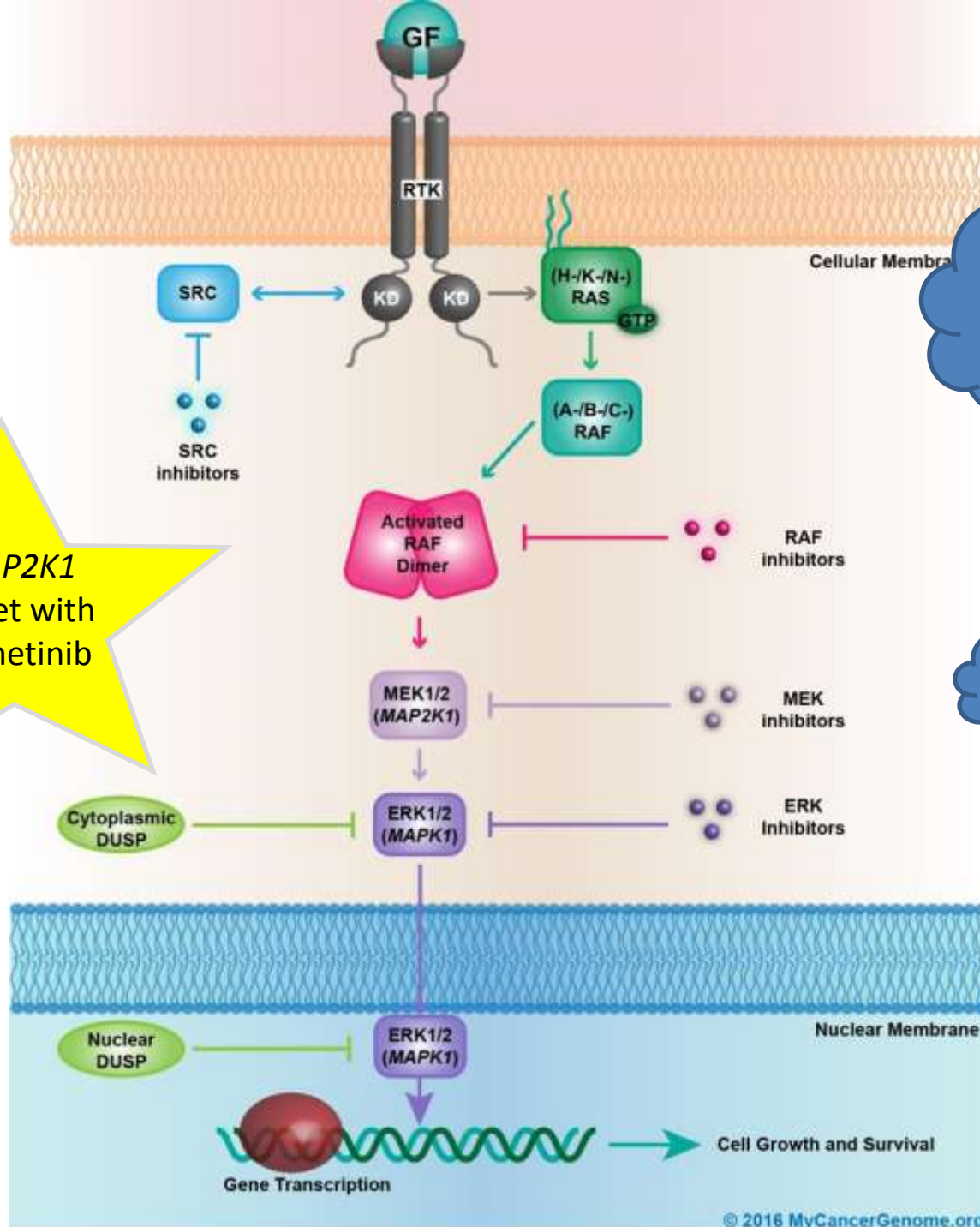
Identification of diverse activating mutations of the RAS-MAPK pathway in histiocytic sarcoma

Vignesh Shanmugam^{1,2} · Gabriel K. Griffin^{1,2} · Eric D. Jacobsen^{2,3} · Christopher D. M. Fletcher^{1,2} · Lynette M. Sholl^{1,2} · Jason L. Hornick^{1,2} 

Received: 22 October 2018 / Revised: 24 November 2018 / Accepted: 24 November 2018 / Published online: 9 January 2019
© United States & Canadian Academy of Pathology 2019

Abstract

Recent studies have demonstrated recurrent activating mutations involving the classical MAPK and PI3K signaling pathways in a large proportion of histiocytic neoplasms, such as Langerhans cell histiocytosis. However, very little is known about the molecular genetics of histiocytic sarcoma, a rare aggressive malignant neoplasm that shows pathologic characteristics of mature macrophages. Here we report the genomic characteristics of a large cohort of histiocytic sarcomas ($n = 28$) using a targeted next-generation sequencing approach to identify driver alterations. We identified recurrent mutations involving the RAS-MAPK signaling pathway (*MAP2K1*, *KRAS*, *NRAS*, *BRAF*, *PTPN11*, *NF1*, *CBL*) in a majority (57%) of histiocytic sarcoma cases and report a clinical response to a MEK inhibitor (Cobimetinib) in a patient with a *NF1*-mutated histiocytic sarcoma. A smaller subset of cases (21%) also showed mutations resulting in activation of the PI3K signaling pathway (*PTEN*, *MTOR*, *PIK3R1*, *PIK3CA*). In addition, the tumor-suppressor gene *CDKN2A* was the most frequently altered gene (46%). Further, a subset of histiocytic sarcoma cases shows striking molecular genetic similarities to B cell lymphomas, supporting a clonal relationship between B cell neoplasms and a subset of histiocytic sarcomas. These findings support a cooperative role for MAPK, PI3K, and cyclin-CDK4/6-INK4 signaling in the pathogenesis of histiocytic sarcoma and provide a rational basis for targeting these pathways.



MAP2K1
Target with
Trametinib

IGHJ5-BCL2

PPM1D

BIRC3

CREBBP

PIM1

Take Away Points: Histiocytic Sarcoma

- If you see large atypical cells in a patient with follicular lymphoma, think of histiocytic sarcoma!
- Must exclude mimics with IHC
- Median overall survival is 6 months
- Can occur in isolation (~75%) or in association with other heme neoplasms (~25%) via transdifferentiation
- RAS-MAPK pathway, PI3K pathway, and *CDKN2A* gene alterations

References

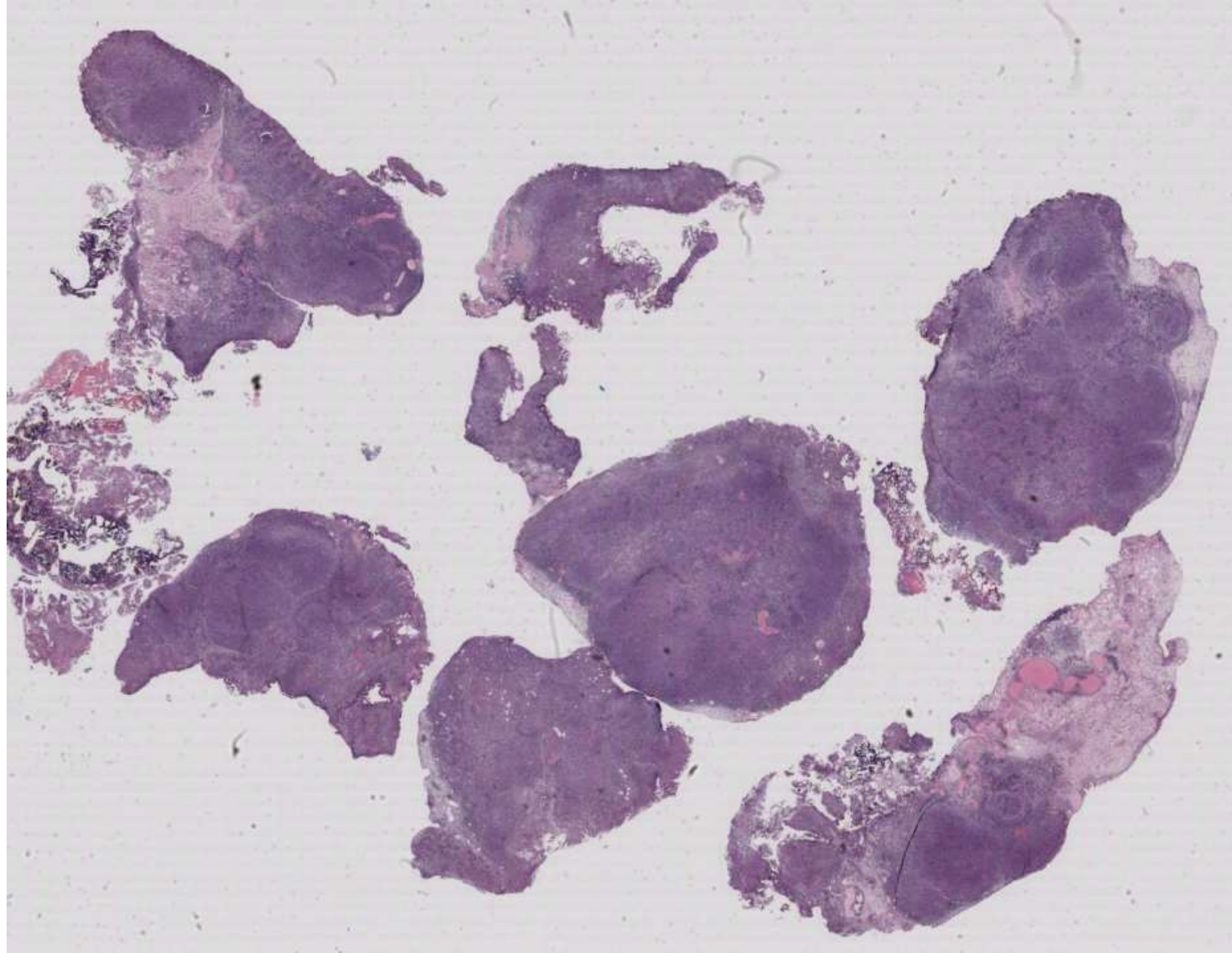
- Farris, M., Hughes, R. T., Lamar, Z., Soike, M. H., Menke, J. R., Ohgami, R. S., & Winkfield, K. (2019). Histiocytic sarcoma associated with follicular lymphoma: evidence for dramatic response with rituximab and bendamustine alone and a review of the literature. *Clinical Lymphoma Myeloma and Leukemia*, 19(1), e1-e8
- Fernandez-Pol, S., Bangs, C. D., Cherry, A., Arber, D. A., & Gratzinger, D. (2016). Two cases of histiocytic sarcoma with BCL2 translocations and occult or subsequent follicular lymphoma. *Human pathology*, 55, 39-43.
- Gounder, M. M., Solit, D. B., & Tap, W. D. (2018). Trametinib in histiocytic sarcoma with an activating MAP2K1 (MEK1) mutation. *The New England journal of medicine*, 378(20), 1945.
- Hornick, J. L., Jaffe, E. S., & Fletcher, C. D. (2004). Extranodal histiocytic sarcoma: clinicopathologic analysis of 14 cases of a rare epithelioid malignancy. *The American journal of surgical pathology*, 28(9), 1133-1144.
- Kommalapati, A., Tella, S. H., Durkin, M., Go, R. S., & Goyal, G. (2018). Histiocytic sarcoma: a population-based analysis of incidence, demographic disparities, and long-term outcomes. *Blood*, 131(2), 265
- Lian, T., Li, C., & Wang, H. (2019). Trametinib in the treatment of multiple malignancies harboring MEK1 mutations. *Cancer treatment reviews*, 101907.
- Péricart, S., Waysse, C., Siegfried, A., Struski, S., Delabesse, E., Laurent, C., & Evrard, S. (2019). Subsequent development of histiocytic sarcoma and follicular lymphoma: cytogenetics and next-generation sequencing analyses provide evidence for transdifferentiation of early common lymphoid precursor—a case report and review of literature. *Virchows Archiv*, 1-6
- Skala, S. L., Lucas, D. R., & Dewar, R. (2018). Histiocytic sarcoma: review, discussion of transformation from B-cell lymphoma, and differential diagnosis. *Archives of pathology & laboratory medicine*, 142(11), 1322-1329.
- Skala, S. L., Ye, J. C., Stumph, J., Macon, W. R., Quinones, F. R., Khachaturov, V., ... & Dewar, R. (2019). Combined Tumors in Hematolymphoid Neoplasms: Case Series of Histiocytic and Langerhans Cell Sarcomas Arising From Low-Grade B-Cell Lymphoma. *Clinical Pathology*, 12, 2632010X19878410.

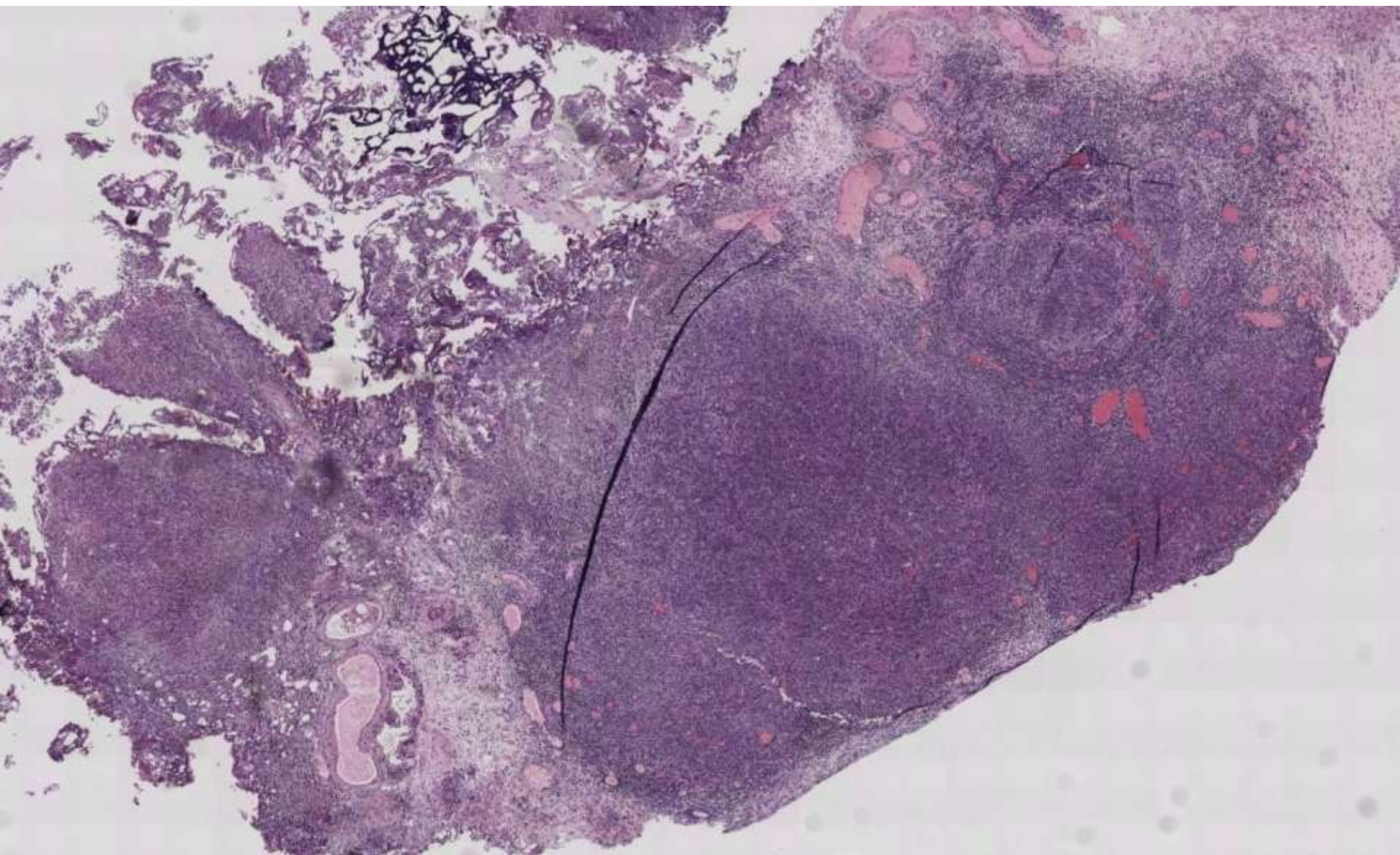
20-0207

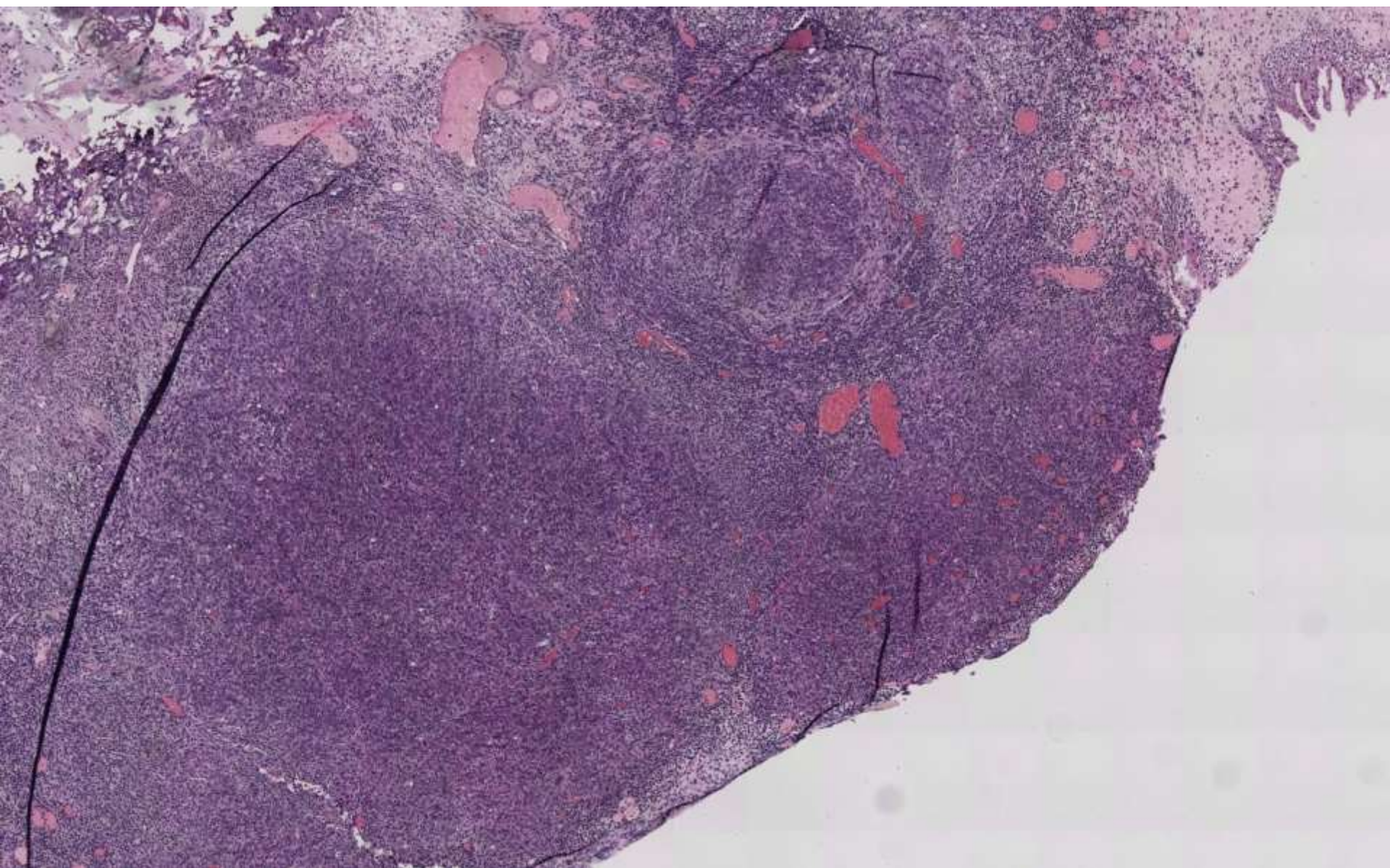
scanned slide available!

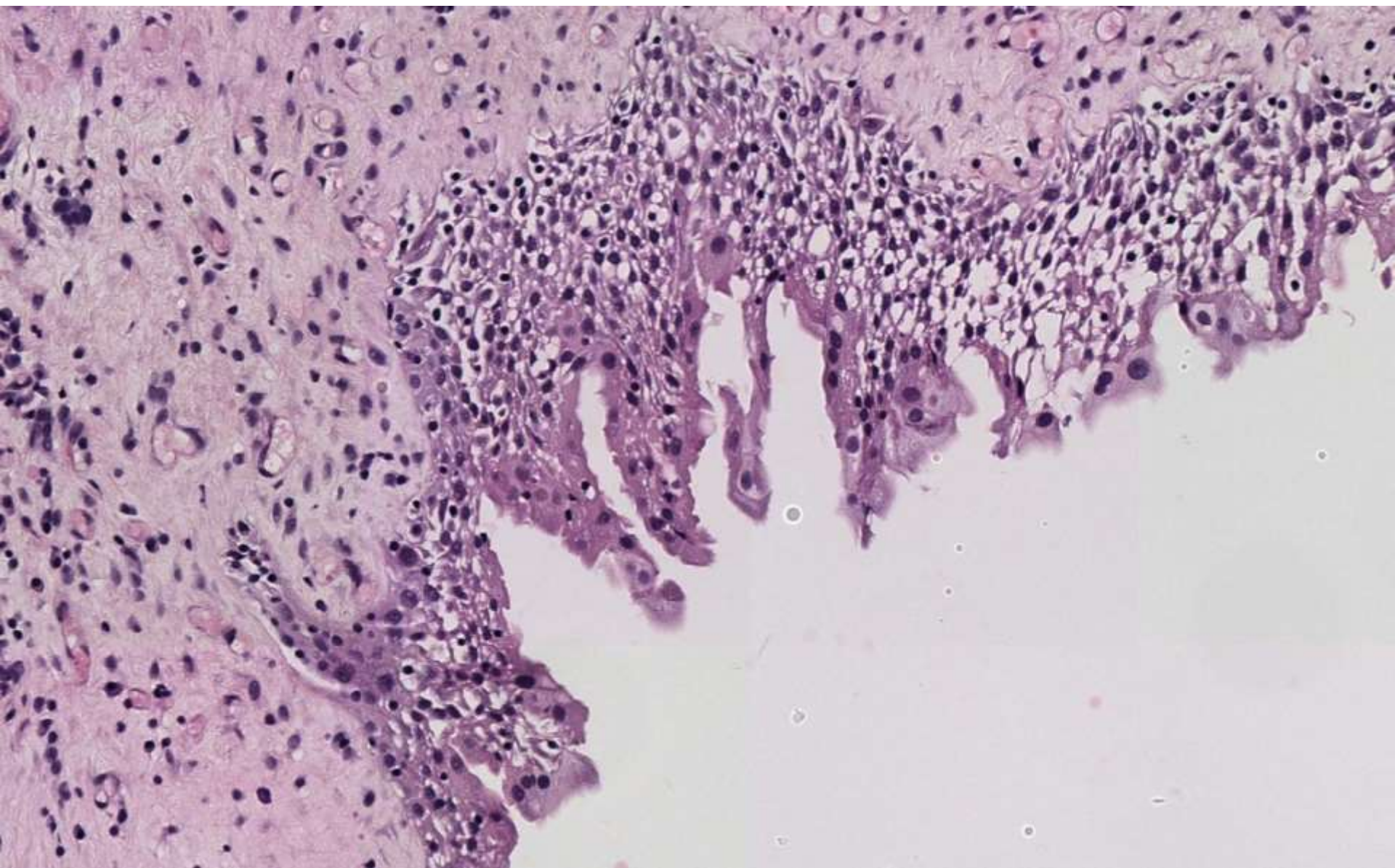
Ankur Sangoi; El Camino Hospital

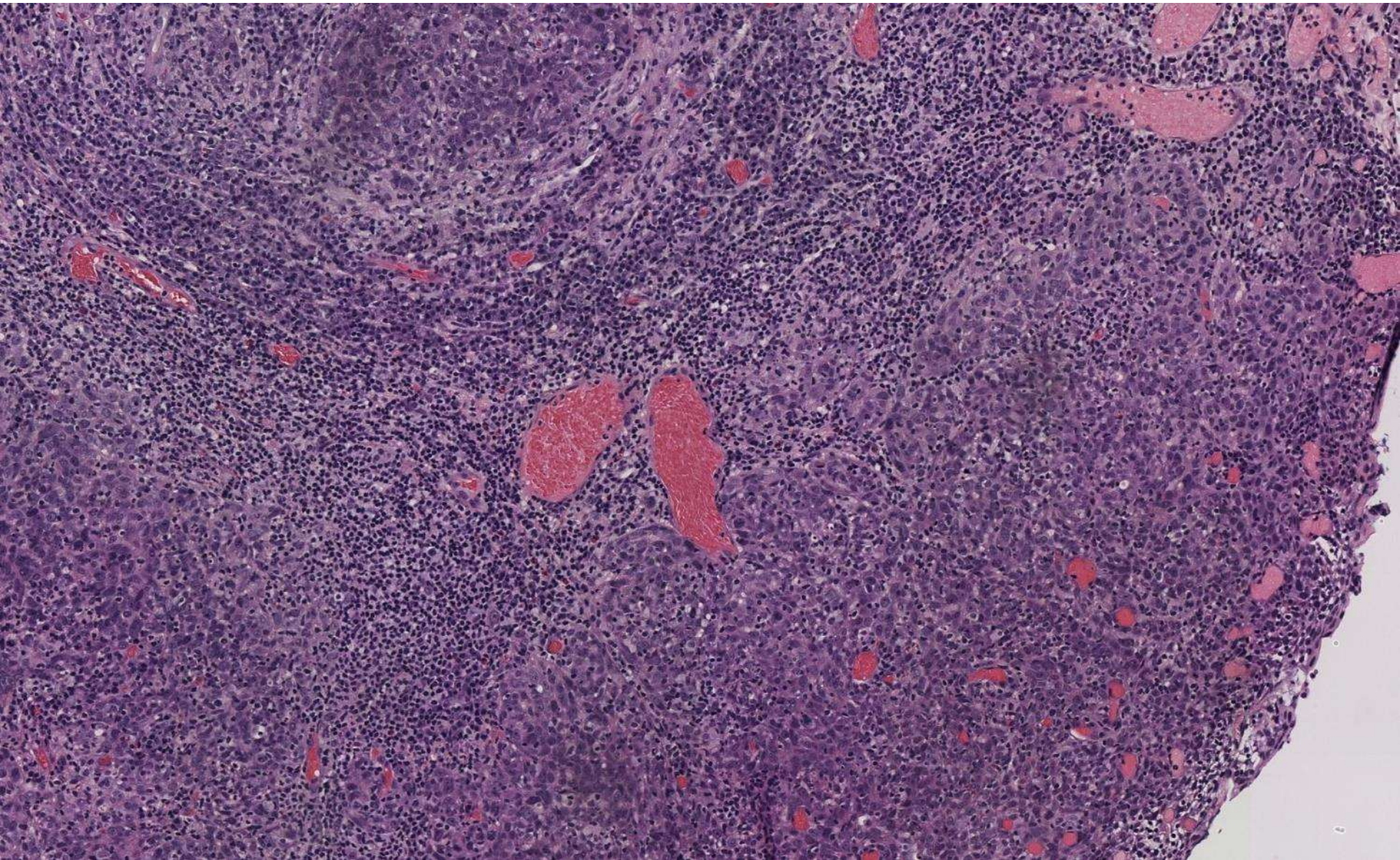
84-year-old M with bladder mass, TURBT.

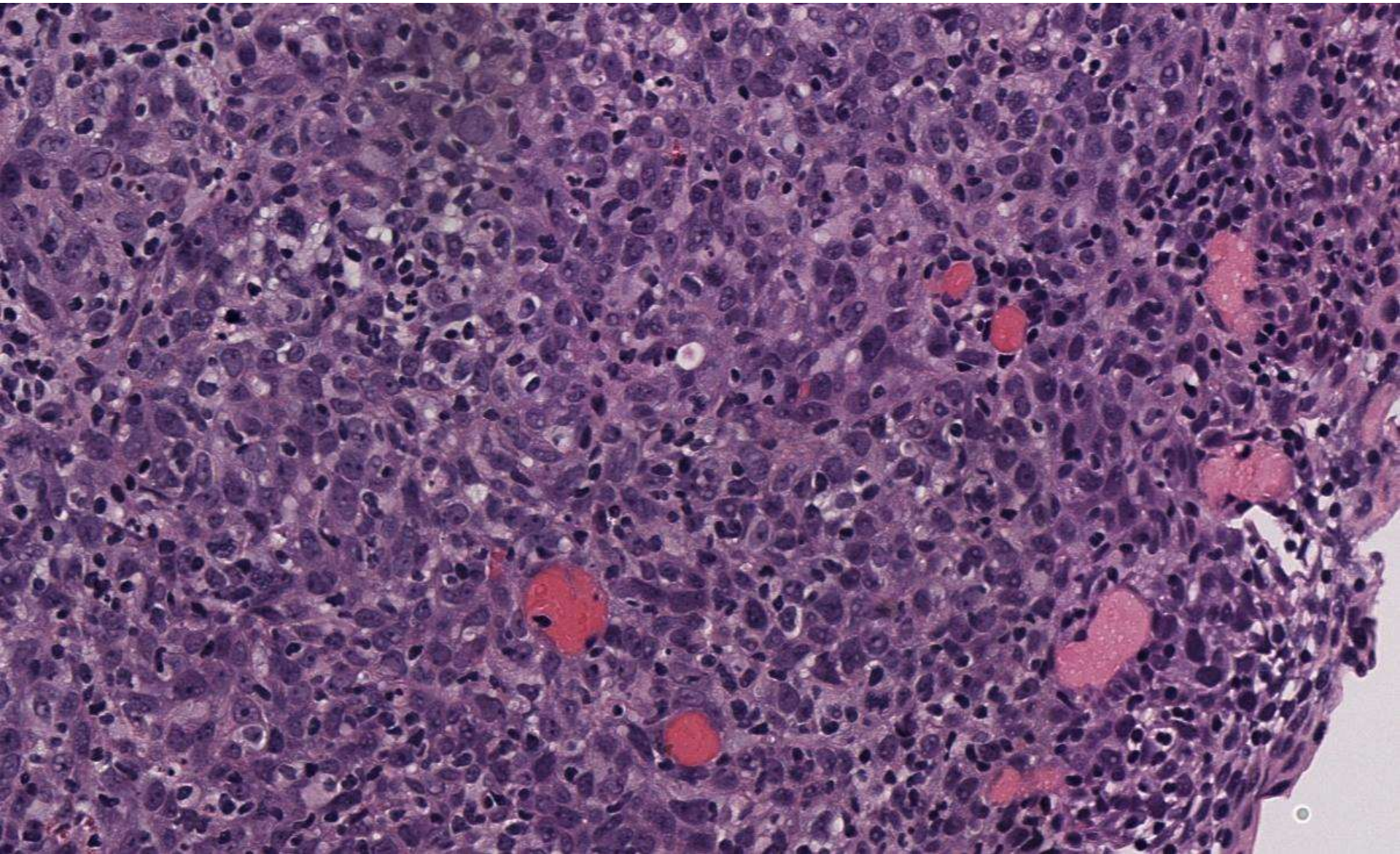


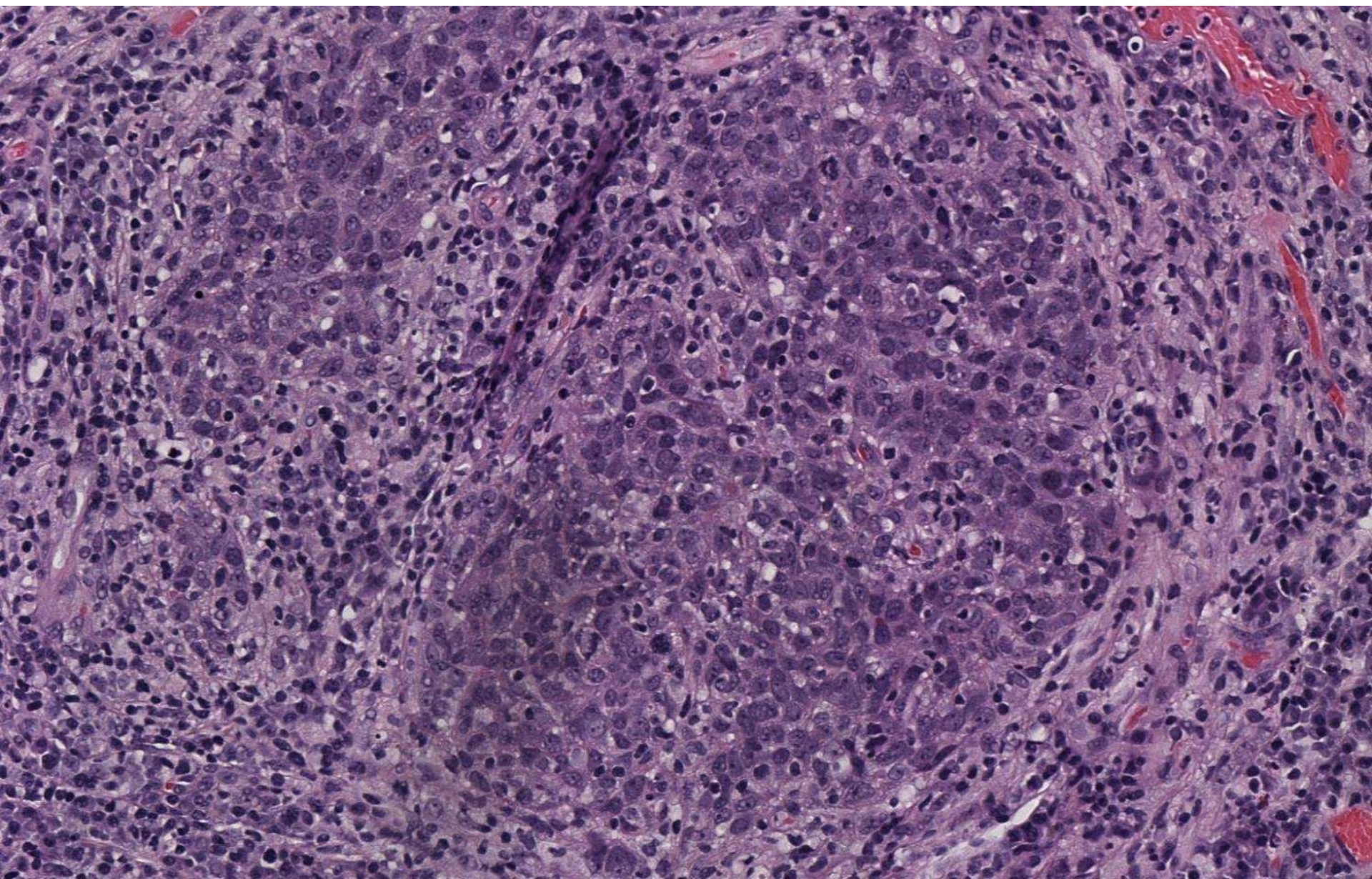


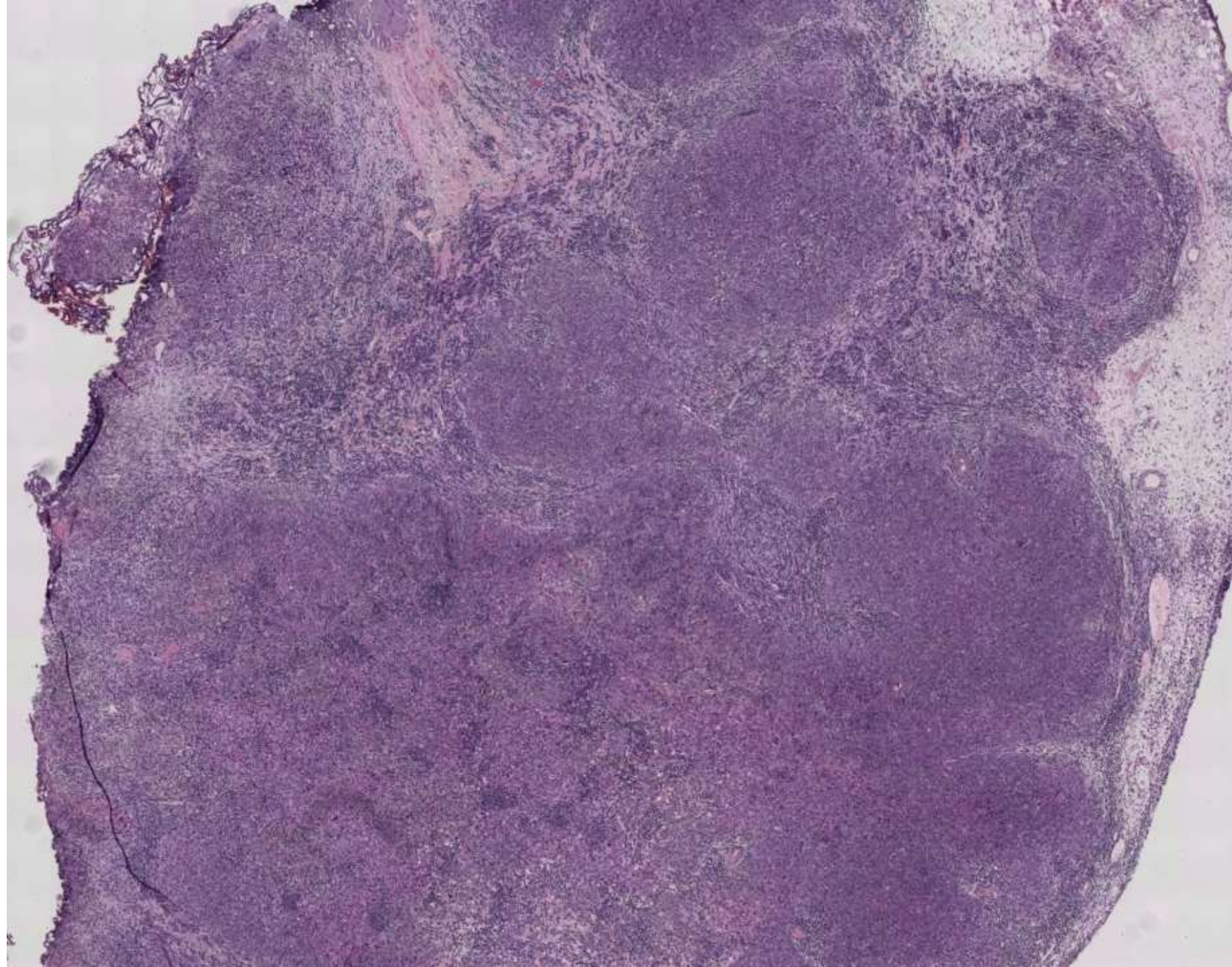


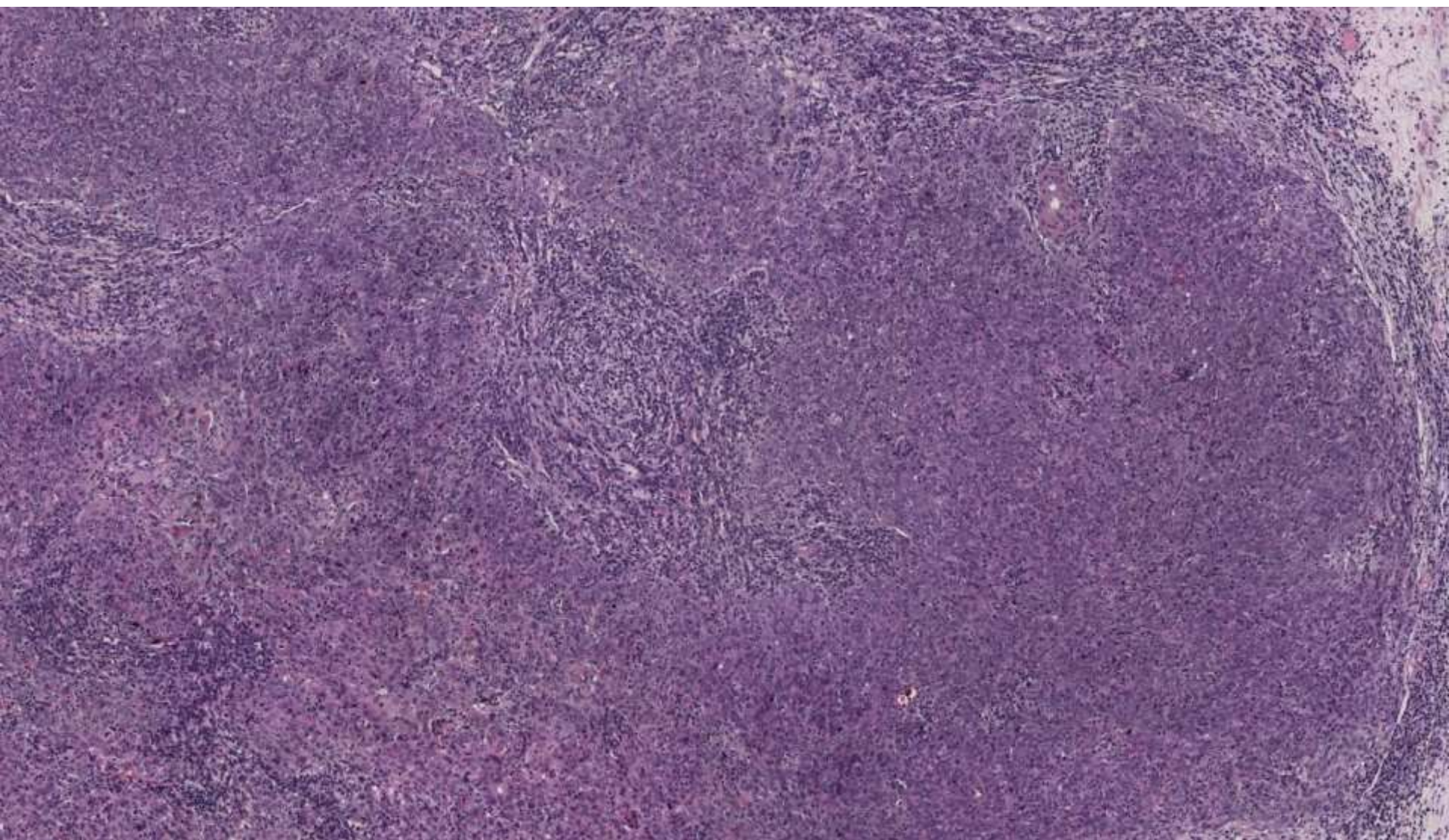

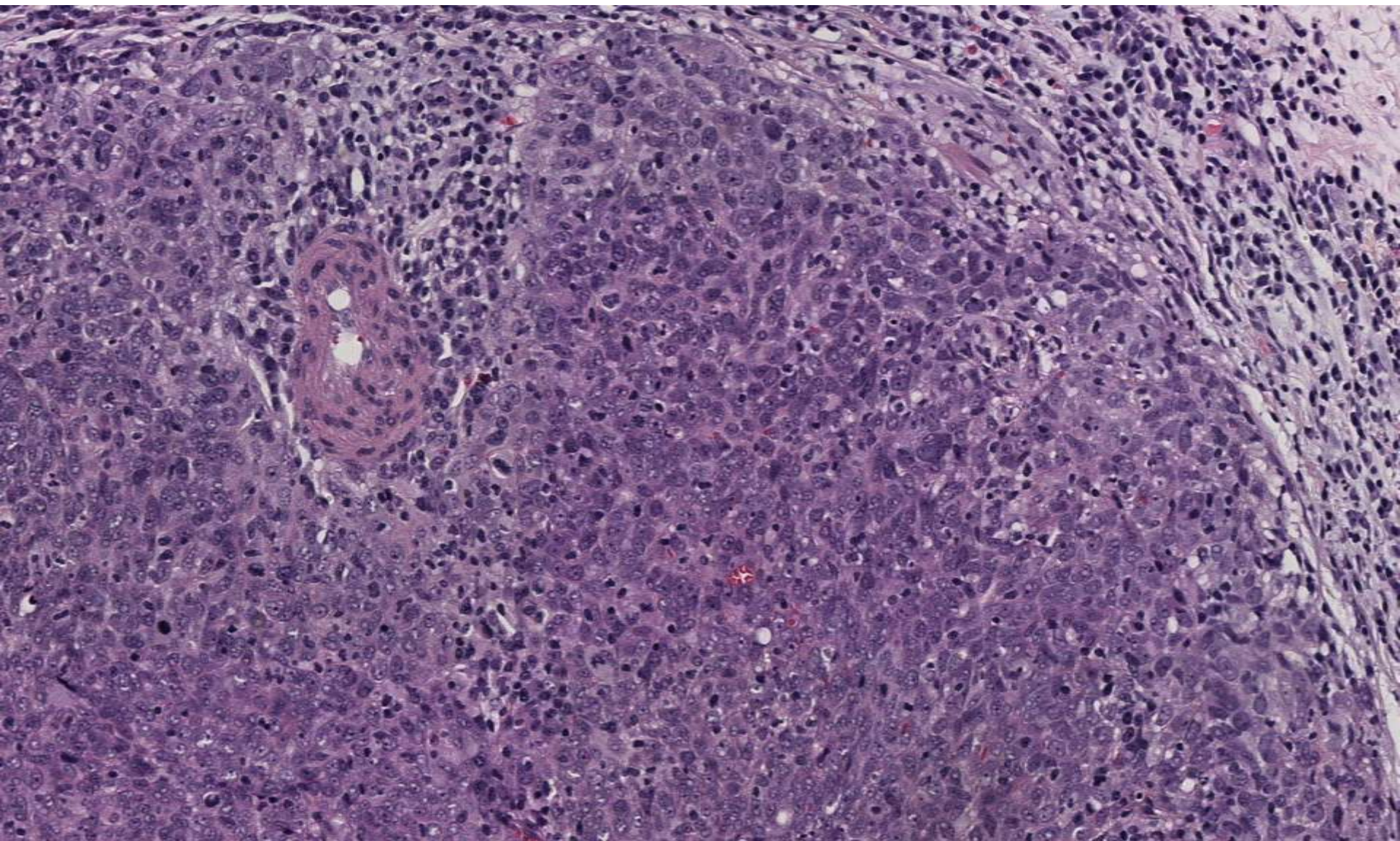


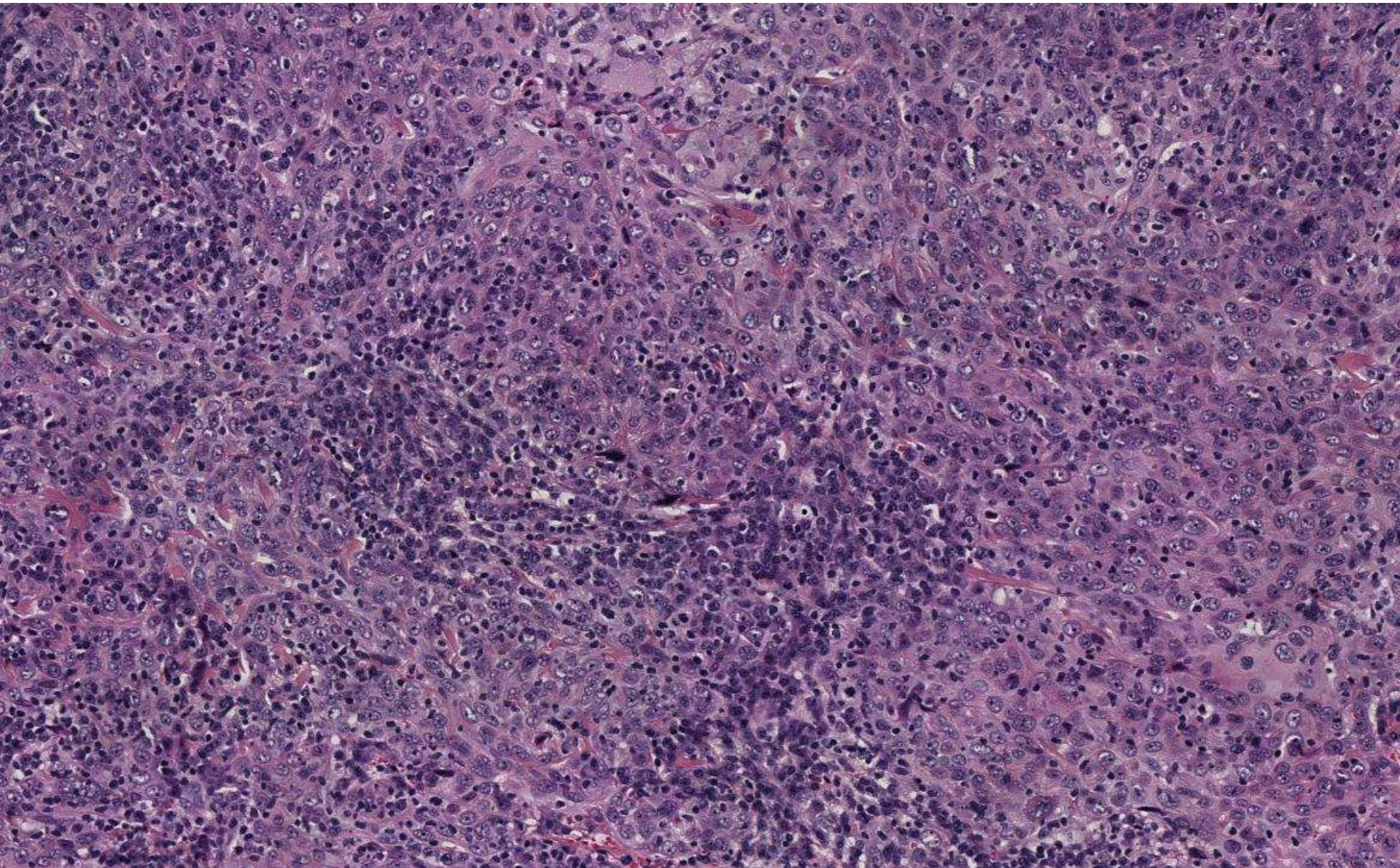


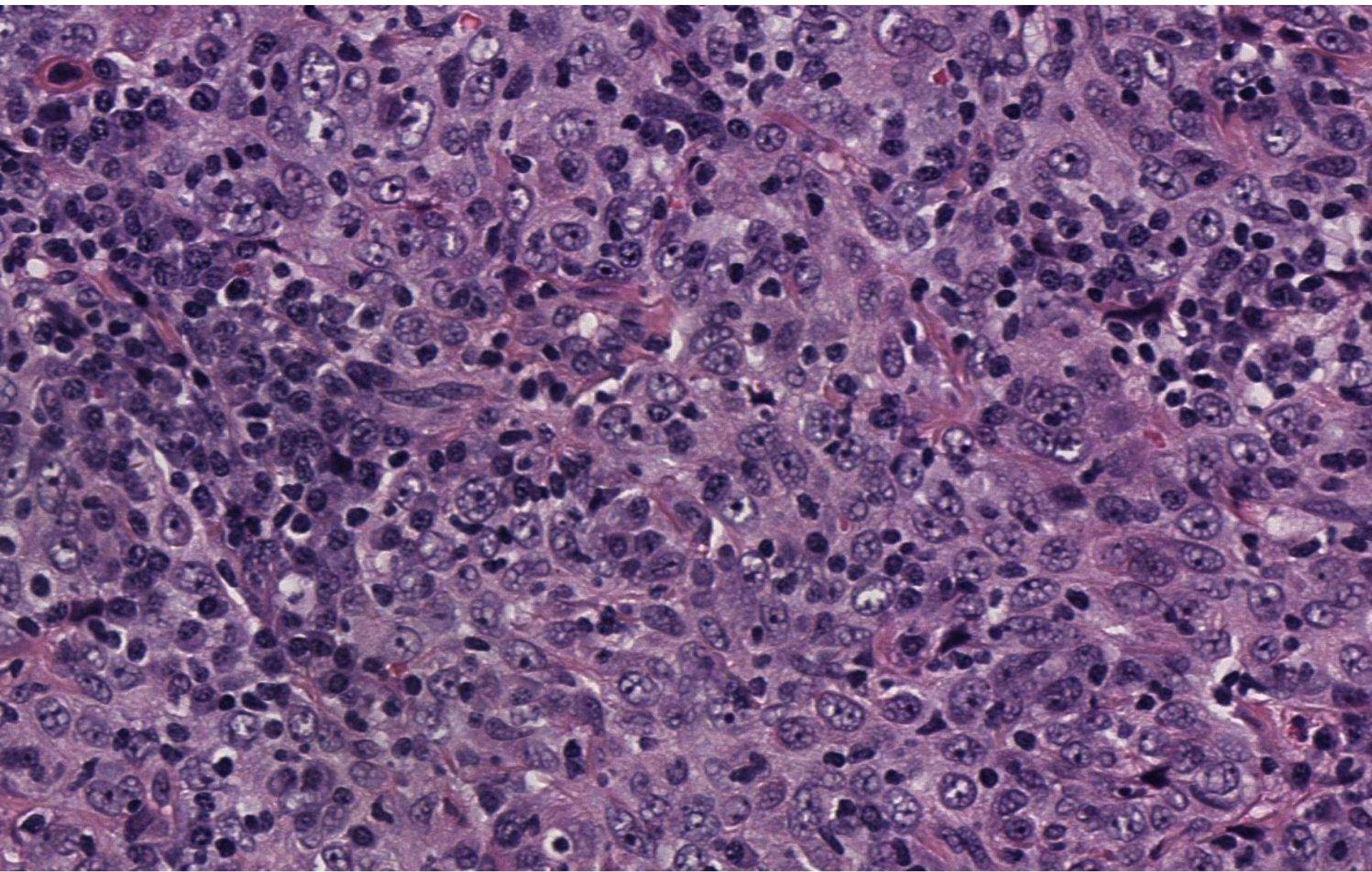












DDx

- **Lymphoepitheloma-like carcinoma**
- **Urothelial carcinoma with prominent lymphoid stroma**
- **Lymphoma**
- **Small cell carcinoma**



AE1/AE3

This image shows a histological section of tissue, likely a tumor, stained with the hematoxylin and eosin (H&E) stain, specifically the AE1/AE3 cocktail. The tissue exhibits a complex, irregular architecture with numerous small, dark brown, granular areas interspersed with lighter, pinkish-white regions. The overall appearance suggests a high degree of cellular density and architectural disorganization, characteristic of malignant tissue. The text "AE1/AE3" is overlaid in the center in a blue, bold, sans-serif font.



A histological section of tissue, likely from the head and neck region, stained for p63. The tissue shows a complex architecture with numerous nests and cords of cells. The p63 staining is indicated by a blue color, which is visible in the nuclei of many cells, particularly in the basal layers of the nests. The overall appearance is that of a malignant epithelial neoplasm, such as squamous cell carcinoma.

p63

EBV ISH

FINAL DIAGNOSIS

- **Lymphoepithelioma-like carcinoma**
 - Primary urothelial origin

DDx of LEL-like carcinoma

- **Urothelial carcinoma with prominent lymphoid stroma**
 - Lacks syncytia of cells
 - Poorly differentiated urothelial histology
- **Lymphoma**
 - CD45+ and keratin –
- **Small cell carcinoma**
 - Neuroendocrine features
 - keratin+ and NE IHC+

Lymphoepithelioma-like carcinoma of the urinary tract: a clinicopathological study of 30 pure and mixed cases

Ecaterina F Tamas¹, Matthew E Nielsen², Mark P Schoenberg² and Jonathan I Epstein^{1,2,3}

¹Department of Pathology, Johns Hopkins Hospital, Baltimore, MD, USA; ²Department of Urology, Johns Hopkins Hospital, Baltimore, MD, USA and ³Department of Oncology, Johns Hopkins Hospital, Baltimore, MD, USA

We studied 28 cases of lymphoepithelioma-like carcinoma of the bladder, one case in the renal pelvis, and one in the urethra. The mean age of the patients was 67.6 years with 21 (70%) males. Seventeen cases (56.7%) were pure with the remaining mixed with other patterns of carcinoma, including invasive urothelial carcinoma ($n=10$), invasive adenocarcinoma ($n=3$), and squamous cell carcinoma ($n=2$). The surface demonstrated carcinoma *in situ* (CIS) in six cases, noninvasive high-grade papillary urothelial carcinoma in three cases, and *in situ* adenocarcinoma in one case. In 19/30 (66%) cases, there was a heavy lymphocytic infiltrate and in the remaining 11/30 (34%) cases a mixed inflammatory infiltrate. None of the 26 cases labeled for EBV-encoded RNA by *in situ* hybridization. Tumor stages at presentation were: seven cases T1 (23%); 14 cases T2 (47%); seven cases T3 (23%); and two cases T4 (7%). Treatment consisted of radical cystectomy in 13/30 cases (43%); partial cystectomy in 4/30 cases (13%); nephrectomy in one case (3%), and transurethral resection often followed by radiation or chemotherapy in 12/30 (40%) cases. The mean follow up for patients without progression was 31 months. Eight of 27 cases with follow-up (30%) cases had tumor recurrence, with seven patients having metastases. In cases treated with cystectomy, the 5-year actuarial recurrence-free risk was 59% (62 and 57%, for pure and mixed cases, respectively). Lymphoepithelioma-like carcinoma, whether in pure or mixed form, has a similar prognosis to ordinary urothelial carcinoma when treated by cystectomy. Of the three pure cases treated by chemotherapy, two were free of disease at 4 and 65 months and the third had recurrent disease at 17 months. Given the association of lymphoepithelioma-like carcinoma with urothelial carcinoma in 47% of our cases and its propensity for multifocality, partial cystectomy would typically be ill advised for lymphoepithelioma-like carcinoma.

Modern Pathology (2007) 20, 828–834; doi:10.1038/modpathol.3800823; published online 1 June 2007

Lymphoepithelioma-like Carcinoma of the Urinary Bladder: Clinicopathologic, Immunohistochemical, and Molecular Features

Sean R. Williamson, MD,* Shaobo Zhang, MD,* Antonio Lopez-Beltran, MD,† Rajal B. Shah, MD,‡
Rodolfo Montironi, MD, FRCPath, IFCAP,§ Puay-Hoon Tan, MD,|| Mingsheng Wang, MD,*
Lee Ann Baldridge, BA, HT(ASCP),* Gregory T. MacLennan, MD,¶ and Liang Cheng, MD*#

Introduction: Lymphoepithelioma-like carcinoma (LELC) in the urinary tract is a rare malignancy, named for its resemblance to nasopharyngeal undifferentiated carcinoma or lymphoepithelioma. Investigation of immunohistochemical and molecular characteristics of bladder LELC is limited. The pathogenesis and biological behavior of these tumors are controversial.

Materials and Methods: We examined clinicopathologic features of the urinary tract LELC, including light microscopy; immunohistochemistry for cytokeratin 7 (CK7), CK20, 34βE12, p53, p63, α-methylacyl-CoA racemase, thyroid transcription factor-1, Epstein-Barr virus latent membrane protein-1, and CD30; in situ hybridization for human papillomavirus; and UroVysion fluorescence in situ hybridization (FISH).

Results: We identified tumors from 34 patients, the largest series to date, (male:female, 2.8:1), ranging from 54 to 84 years of age (mean, 70 years). Urothelial carcinoma in situ was identified in 50% of patients. 34βE12 (75%), CK7 (57%), and p63 (53%) were frequently positive in tumor cells, whereas thyroid transcription factor-1 and CD30 were consistently negative. Expression of p53 was noted in a subset of tumors (61%), whereas CK20 staining was negative with weak positivity in a single case. UroVysion FISH showed frequent chromosomal abnormalities similar to those of urothelial carcinoma. In tumors with concurrent urothelial, squamous, sarcomatoid, and glandular components, identical FISH abnormalities were noted in both areas. In situ hybridization for human papillomavirus and immunostaining for Epstein-Barr virus were negative in all studied lesions. Five patients with pure or predominant LELC tumors treated with transurethral resection

and followed by chemotherapy were alive without evidence of disease at 2 to 5 years. In contrast, 2 patients treated in this manner with < 50% LELC morphology had death from disease or distant metastasis.

Discussion: Urinary tract LELC is a rare histologic variant of urothelial carcinoma. The frequent presence of UroVysion FISH abnormalities, urothelial carcinoma in situ, and p53 positivity by immunohistochemistry in cases of urinary tract LELC suggests a similar pathogenesis to high-grade invasive urothelial carcinoma. In contrast to typical urothelial carcinoma, CK20 is frequently negative in LELC. Our findings support the hypothesis that pure or predominant LELC may be treated with transurethral resection and chemotherapy. However, a large-scale study with long-term follow-up is needed to better understand the biological behavior of urinary bladder LELC.

Key Words: urinary bladder, urinary tract, lymphoepithelioma-like carcinoma, TCC variants, genitourinary tract, histogenesis, differential diagnosis

(*Am J Surg Pathol* 2011;35:474-483)

In the nasopharynx, undifferentiated carcinoma associated with a dense lymphoid infiltrate has been designated as "lymphoepithelioma" or "lymphoepithelial carcinoma" for its histologic intermingling of syncytially arranged, malignant epithelial cells and a variable lymphoplasmacytic infiltrate.^{3,5} Other similar appearing lesions have been described in various other body sites including the urinary bladder, where they are commonly termed "lymphoepithelioma-like carcinoma" (LELC).^{1,19}

RNA Expression Profiling of Lymphoepithelioma-Like Carcinoma of the Bladder Reveals a Basal-Like Molecular Subtype

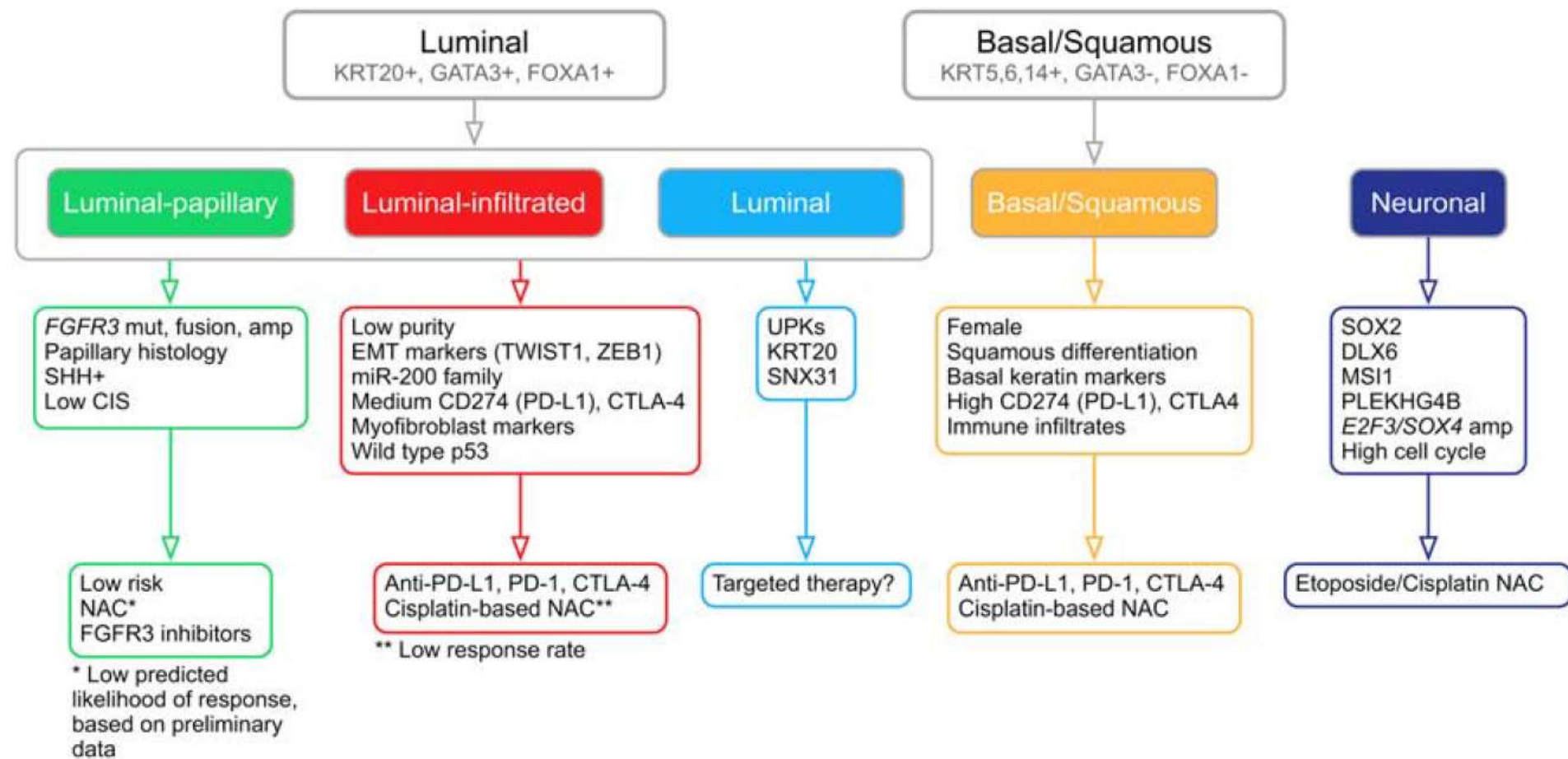
Ujjawal Manocha,^{*} Jordan Kardos,^{*} Sara Selitsky,^{*} Mi Zhou,^{*} Steven M. Johnson,[†] Cori Breslauer,[†] Jonathan I. Epstein,[‡] William Y. Kim,^{*,§¶} and Sara E. Wobker^{*,†}

From the UNC Lineberger Comprehensive Cancer Center,^{} and the Departments of Pathology and Laboratory Medicine,[†] Medicine,[§] and Genetics,[¶] University of North Carolina at Chapel Hill, Chapel Hill, North Carolina; and the Departments of Pathology, Urology and Oncology,[‡] Johns Hopkins Hospitals, Baltimore, Maryland*

Accepted for publication
September 5, 2019.

Address correspondence to Sara E. Wobker, M.D., M.P.H., 303 Brinkhous-Bullitt Bldg., CB#7525, Chapel Hill, NC 27599. E-mail: sara_wobker@med.unc.edu.

Lymphoepithelioma-like carcinoma of the bladder (LELC-B) is a rare subtype of urothelial carcinoma consisting of undifferentiated epithelial cells within a dense inflammatory cell infiltrate. We set out to molecularly characterize LELC-B through RNA expression profiling as well as immunohistochemistry (IHC) to understand its underlying biology. Sixteen cases of LELC-B were identified at Johns Hopkins University. RNA sequencing was performed on 14 cases. IHC staining for programmed cell death ligand 1 (PD-L1) and mismatch repair proteins MutL homolog 1 (MLH1), MutS homolog 2 (MSH2), MSH6, and PMS1 homolog, mismatch repair system component 2 (PMS2) was performed. Transcriptomic profiling of LELC-B showed that they are enriched in a basal-like phenotype, with 12 of 14 LELC-B cases correlating to the basal centroid of the bladder cancer analysis of subtypes by gene expression 47 (BASE47) predictive analysis of microarrays (PAM) classifier. Gene signature analysis confirmed the lymphocyte infiltration profile consistent with the histomorphology. LELC-B lacked features to explain the robust lymphocytic infiltrate, such as loss of mismatch repair protein expression or expression of Epstein-Barr virus transcripts. Nonetheless, PD-L1 IHC was positive in 93% of LELC cases. Our study demonstrates that LELC-B tumors are enriched in a basal-like molecular subtype and share a high level of immune infiltration and PD-L1 expression, similar to basal tumors. The basal-like phenotype is consistent with the known sensitivity of LELC-B to chemotherapy and suggests that immune checkpoint therapy should be explored in this rare disease. (*Am J Pathol* 2020, 190: 134–144; <https://doi.org/10.1016/j.ajpath.2019.09.007>)



LEL-like carcinoma

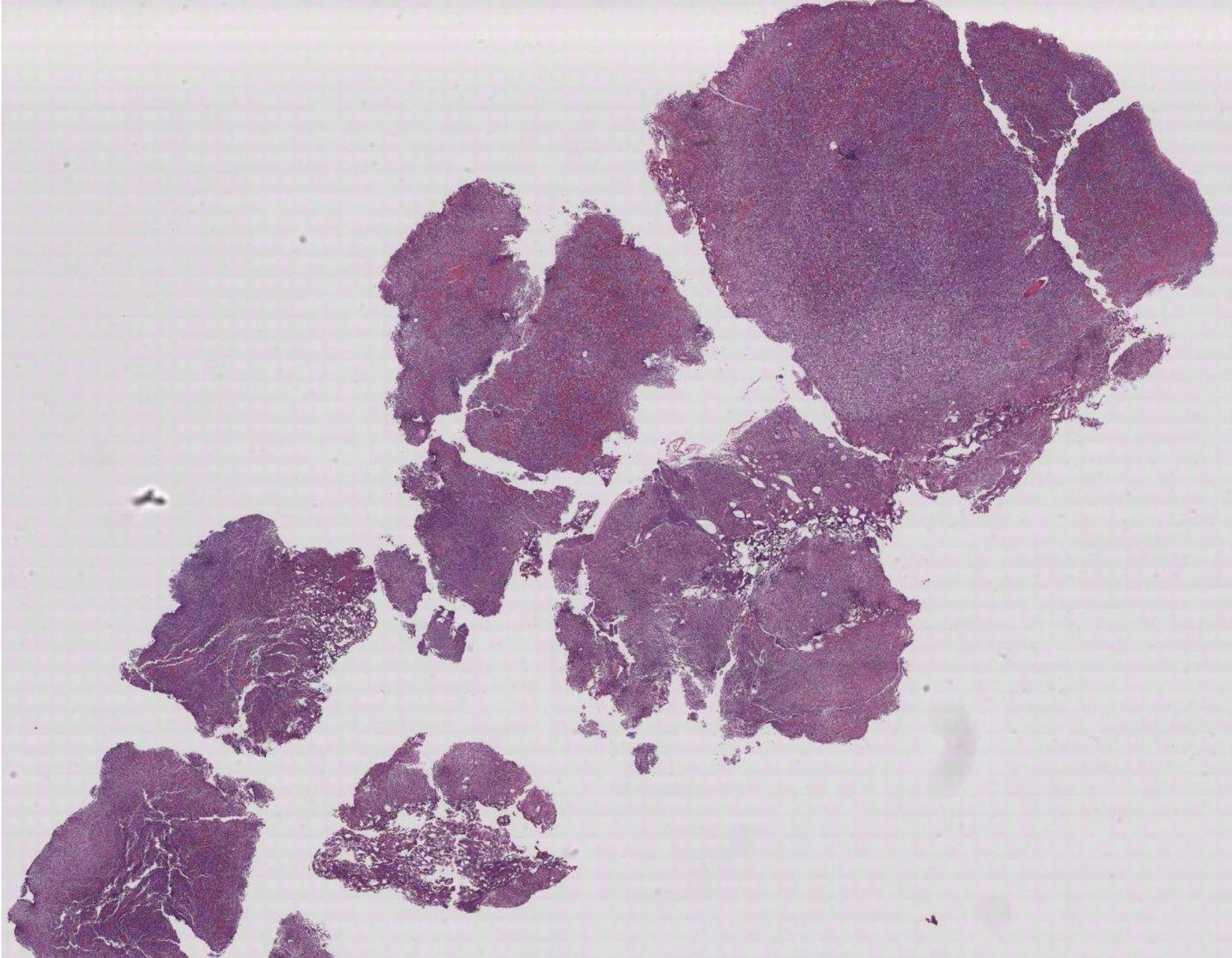
- Can be pure or mixed in form
- Lack EBV ISH
- Frequently CK20
- basal-like phenotype
 - High PDL1 expression
- Can be treated like typical urothelial carcinoma, with similar prognosis

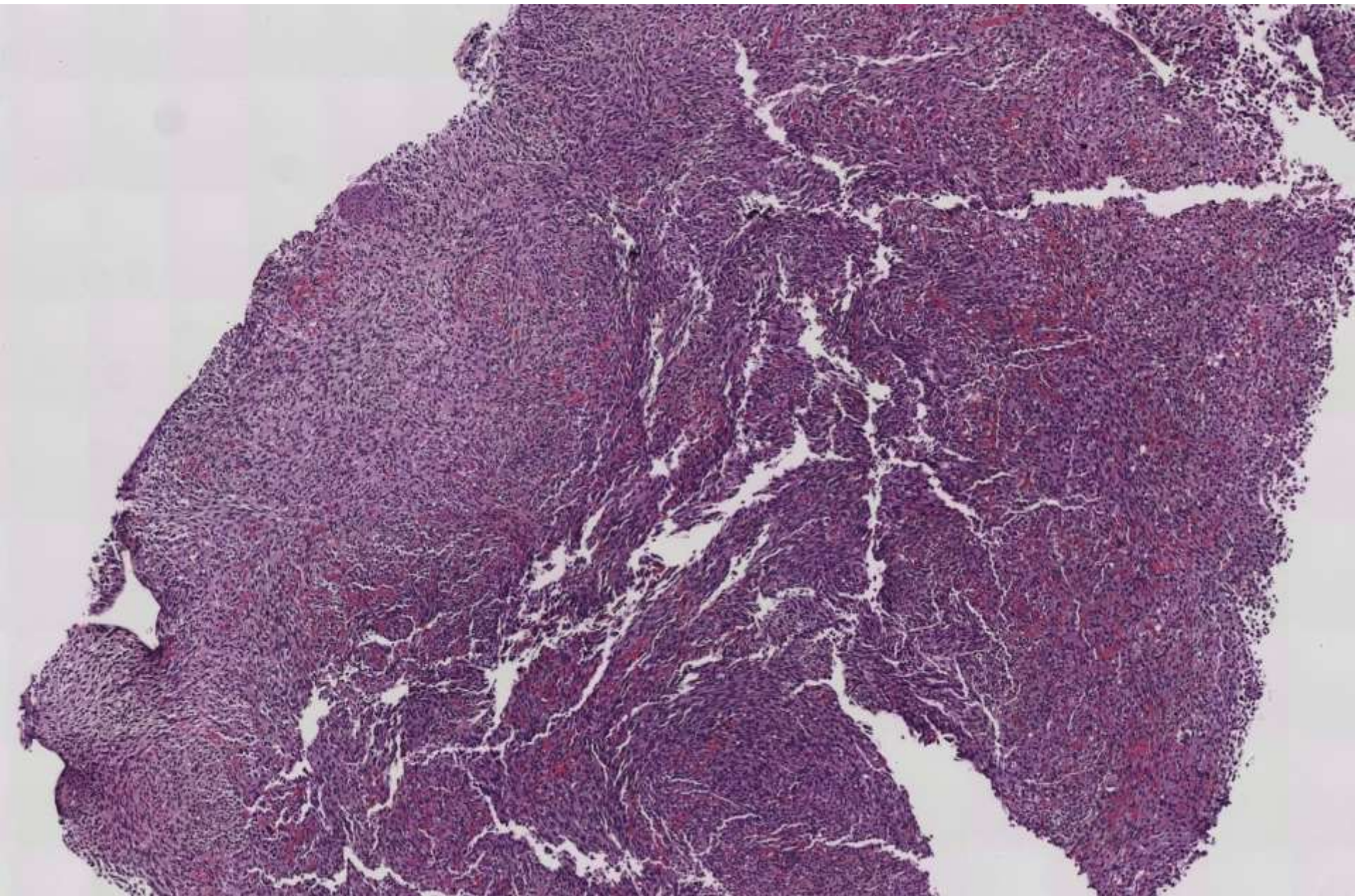
20-0208

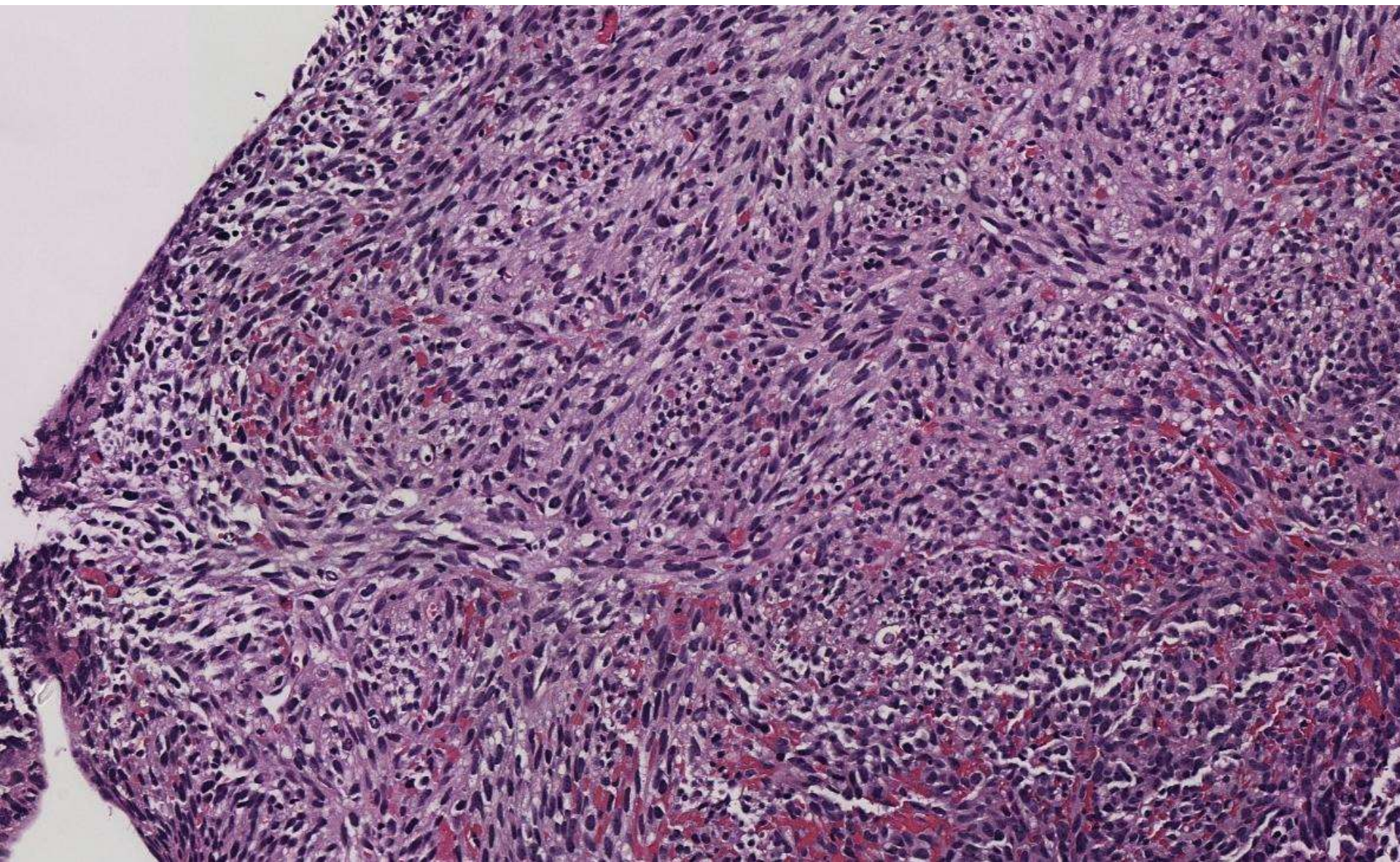
scanned slide available!

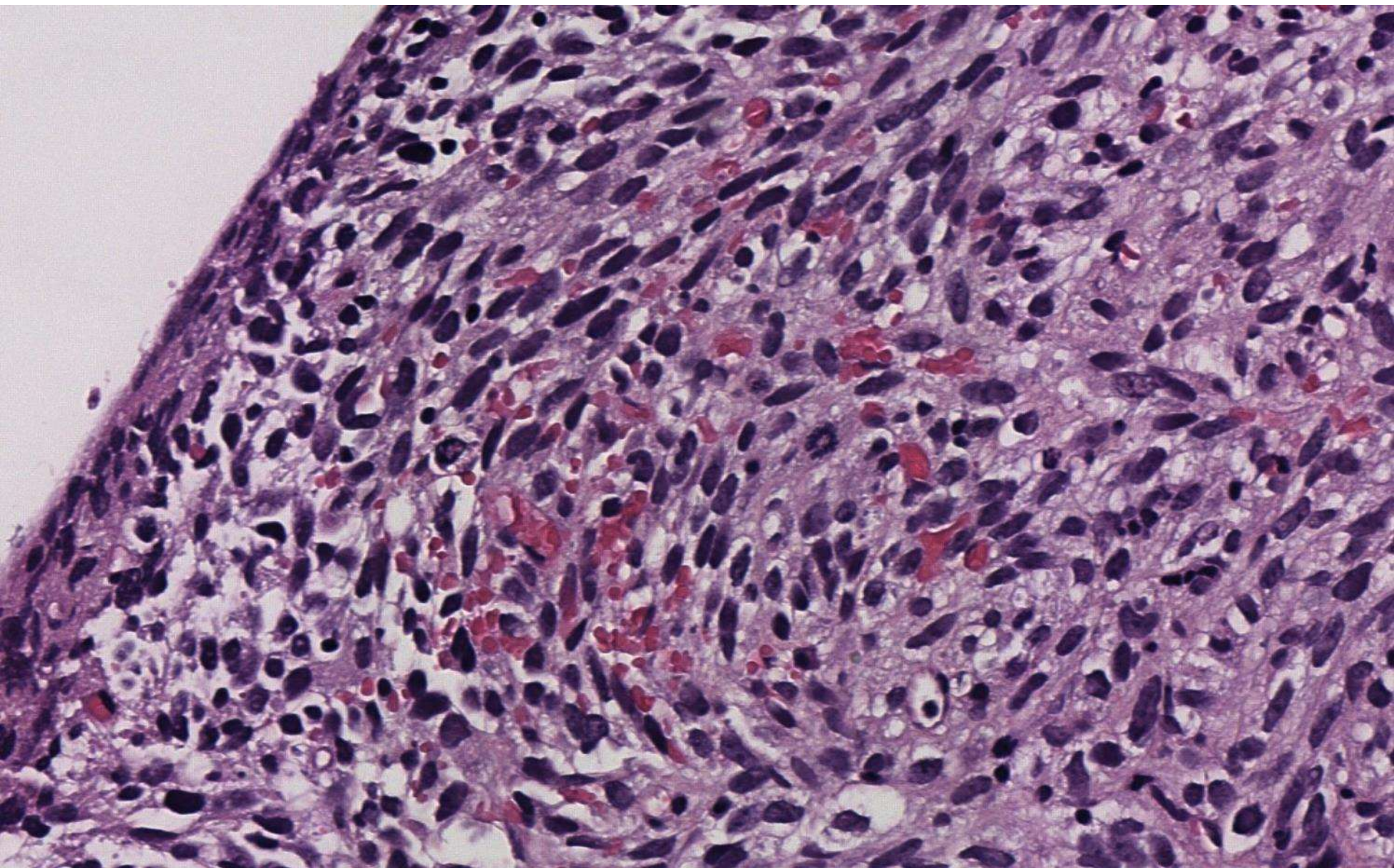
Ankur Sangoi; El Camino Hospital

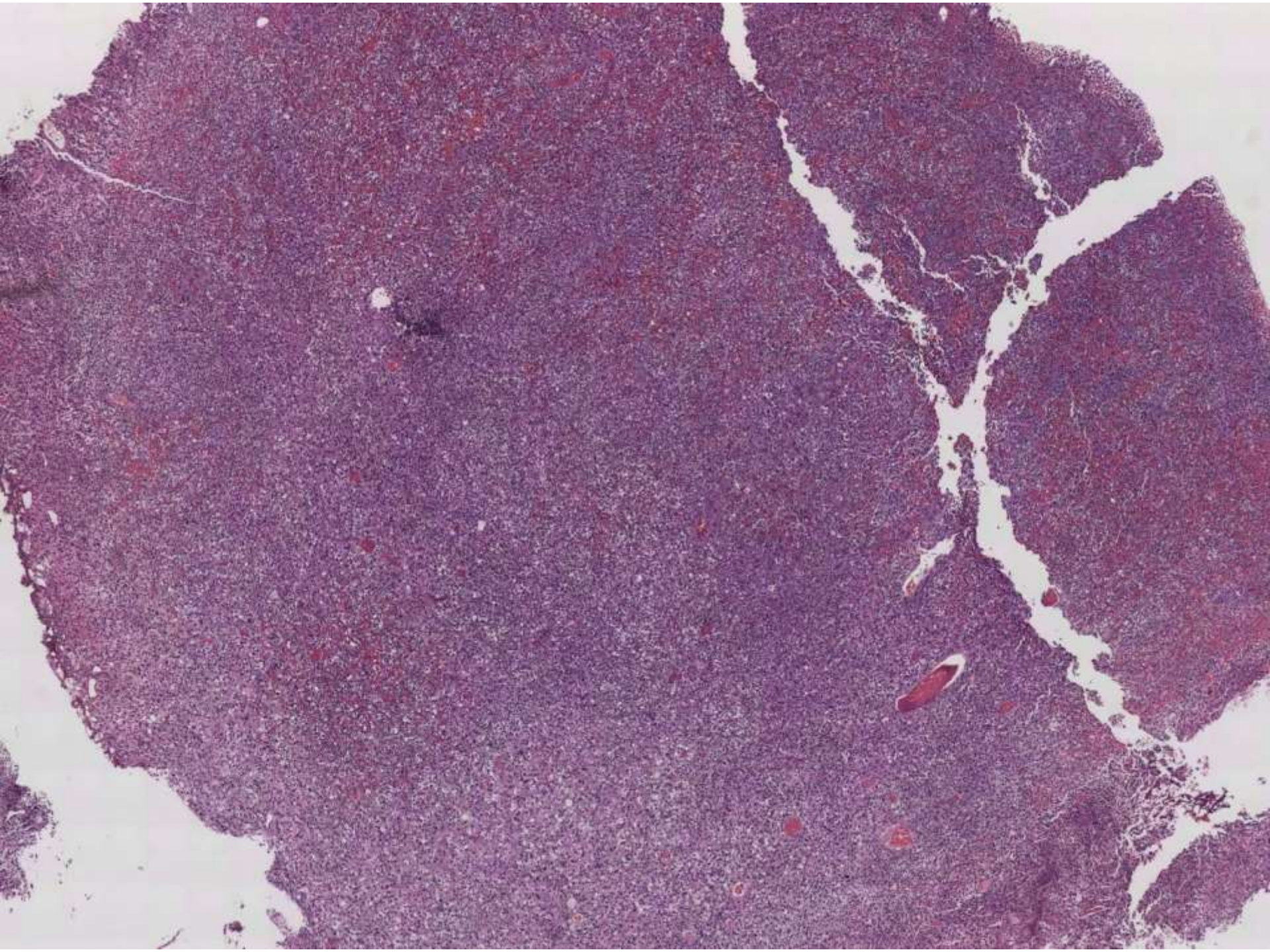
88-year-old F with bladder mass, TURBT.

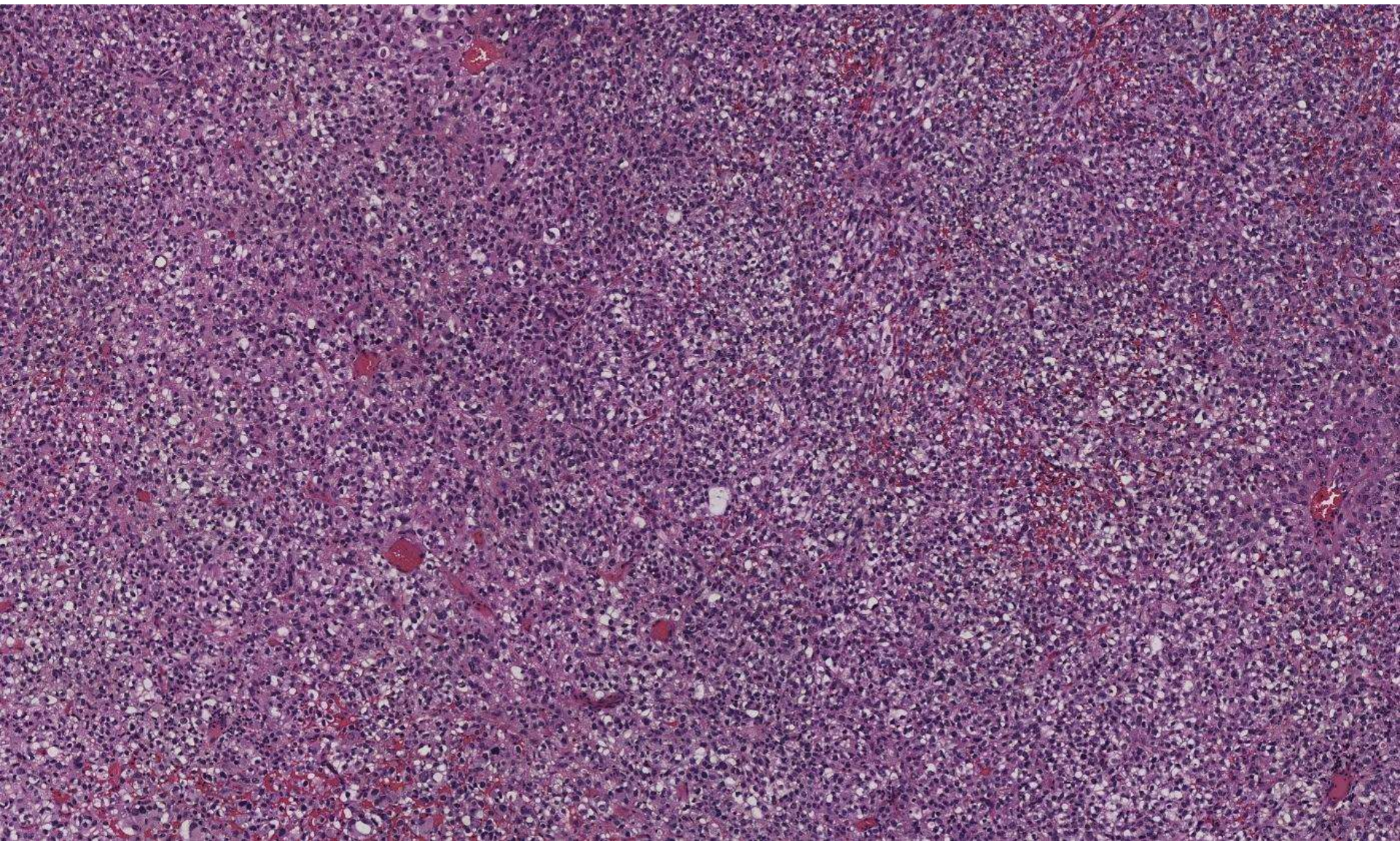

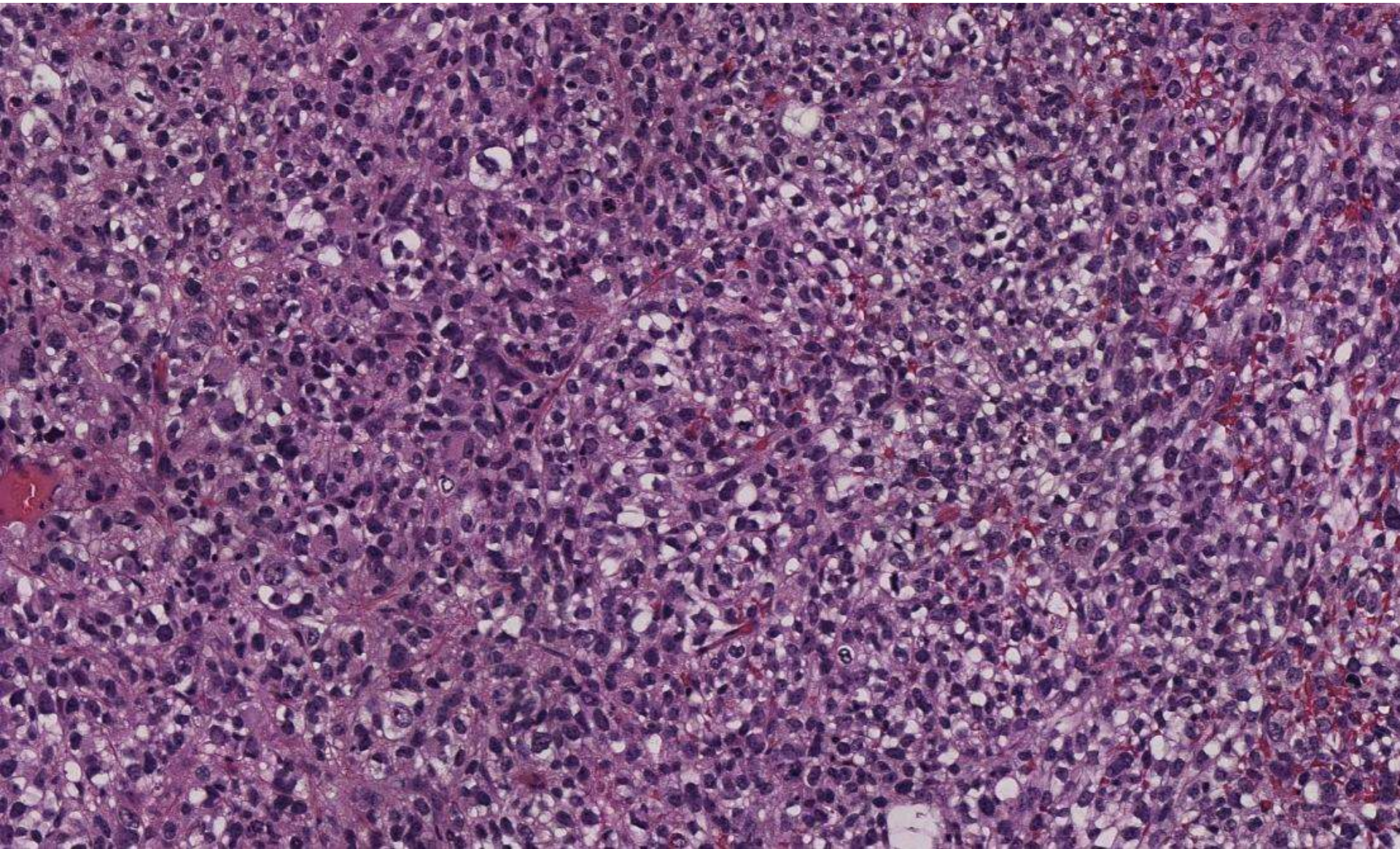


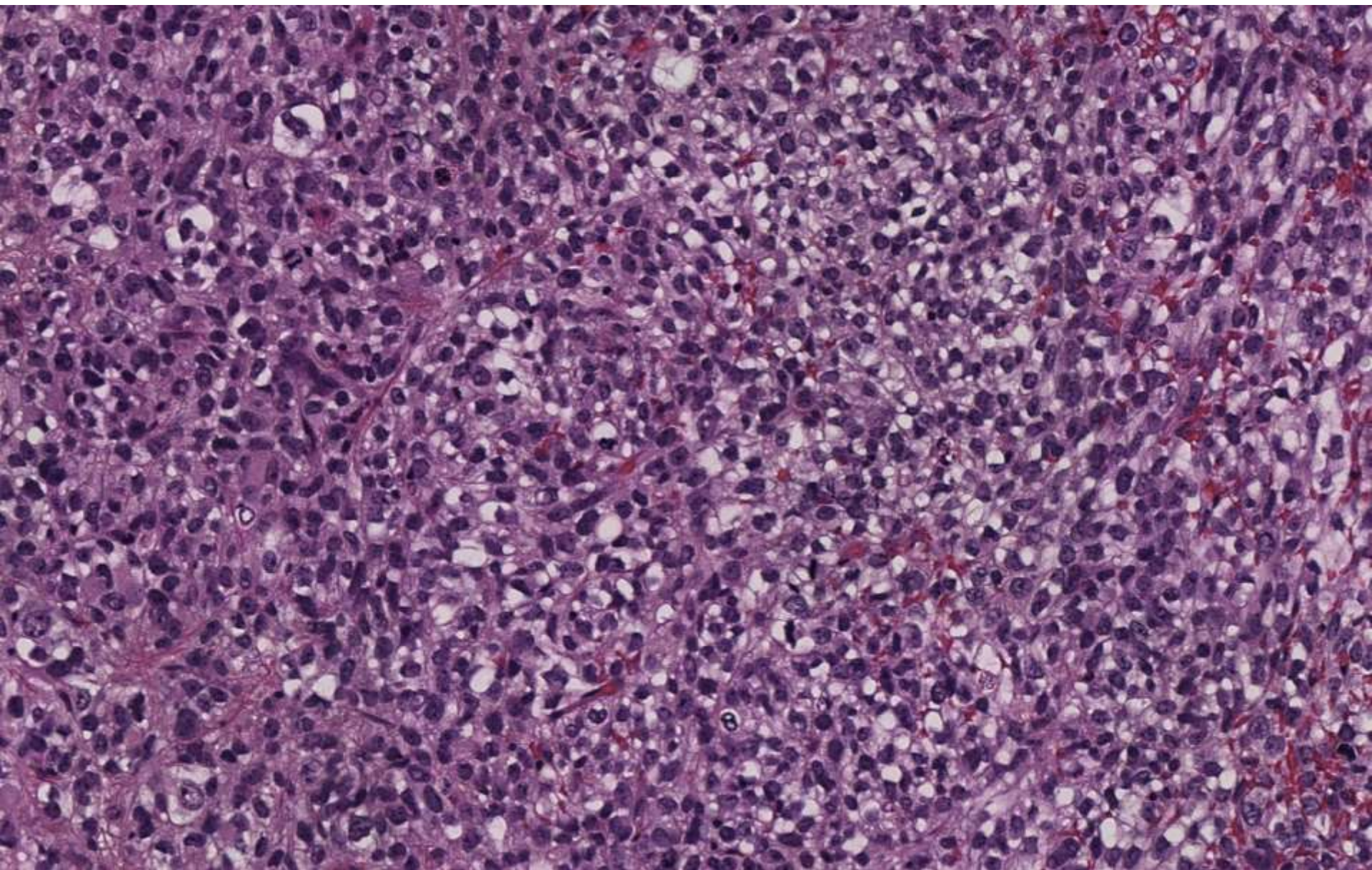


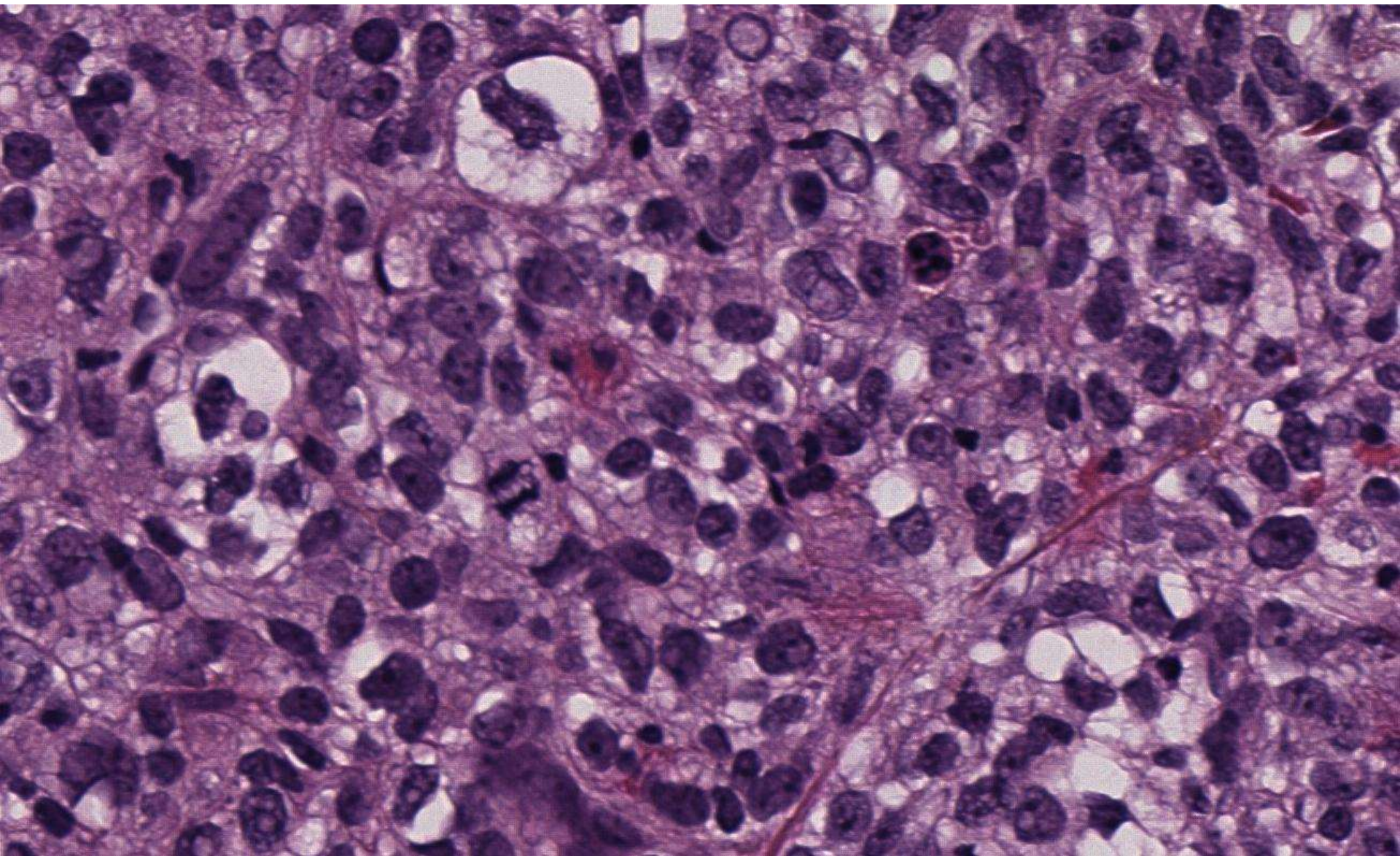








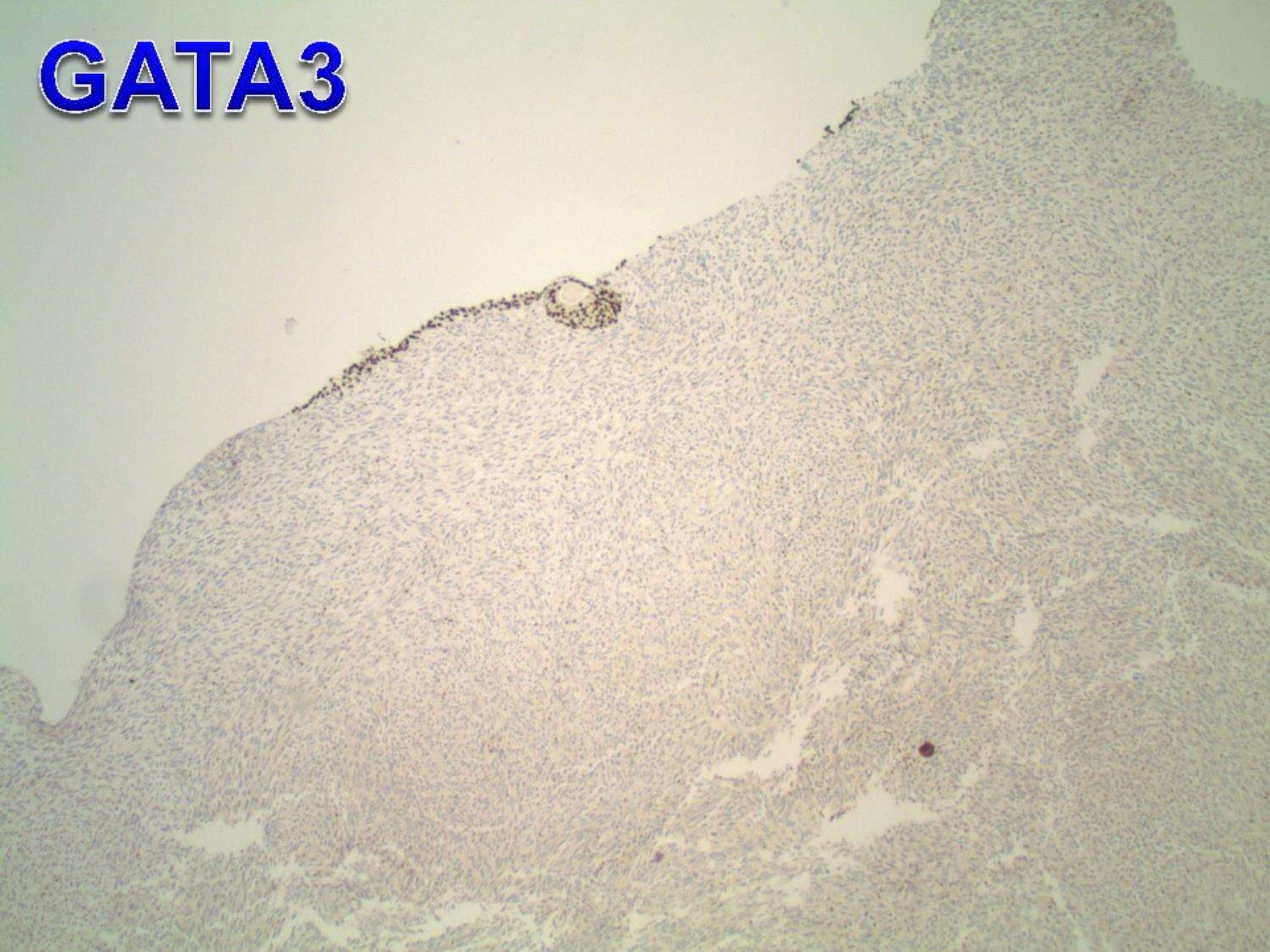




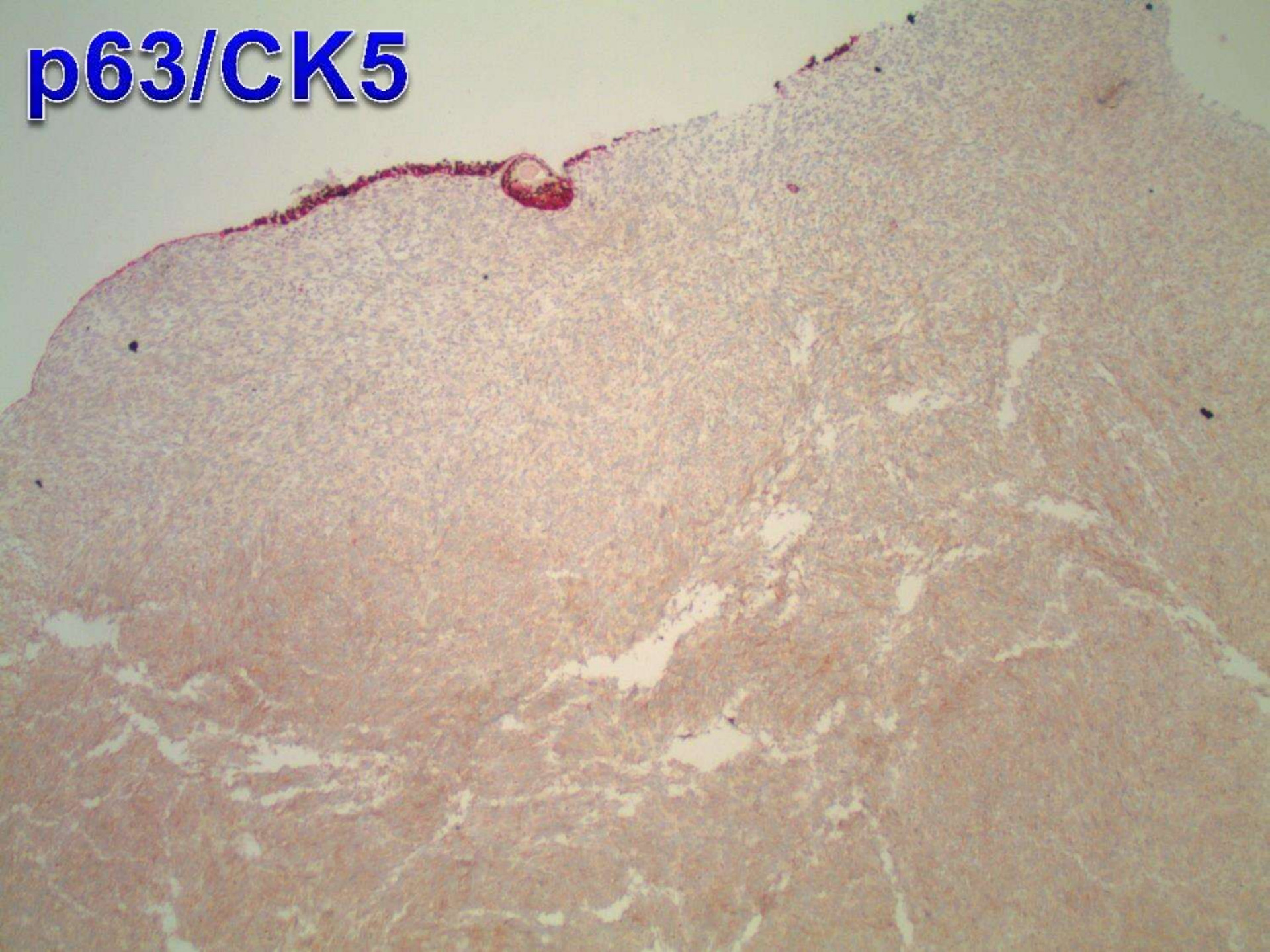
DDx

- **Sarcomatoid urothelial carcinoma**
- **Paraganglioma**
- **PEComa**
- **Endometrial stromal sarcoma**
- **Epithelioid angiosarcoma**
- **Epithelioid leiomyosarcoma**
- **Peripheral nerve sheath tumor**
- **Solitary fibrous tumor**
- **GIST**
- **melanoma**
- **Pleomorphic undifferentiated sarcoma**

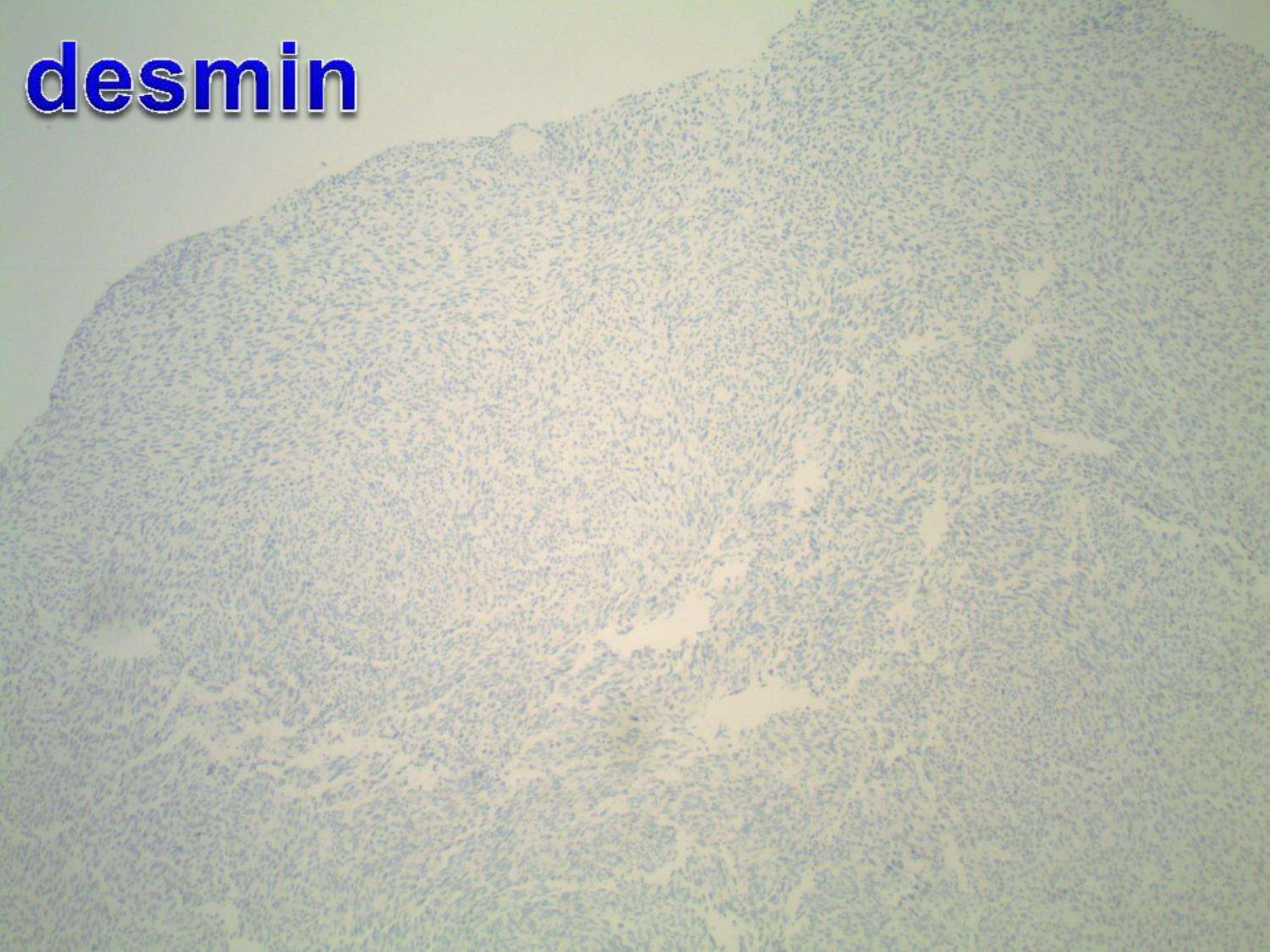
GATA3



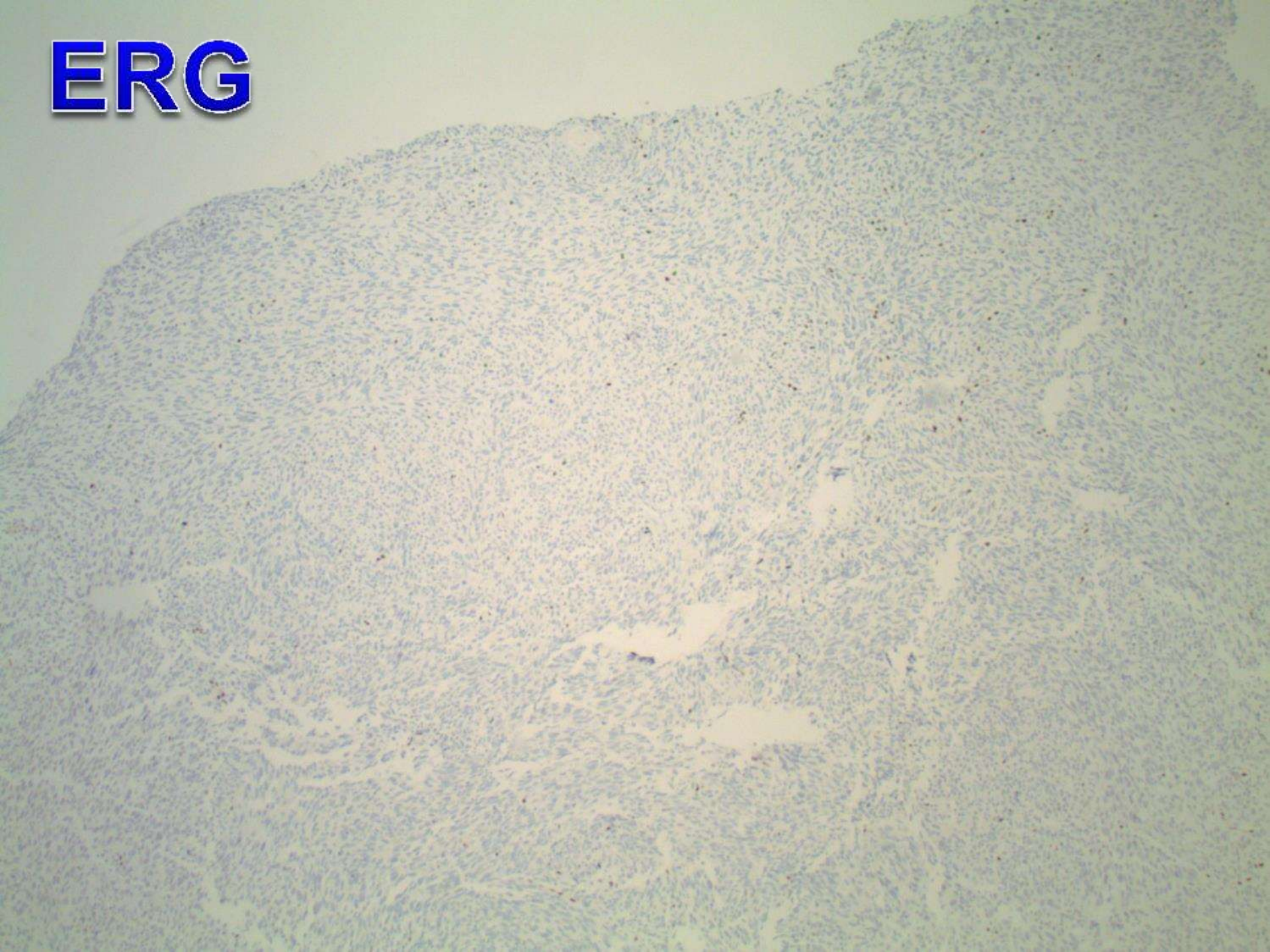
p63/CK5

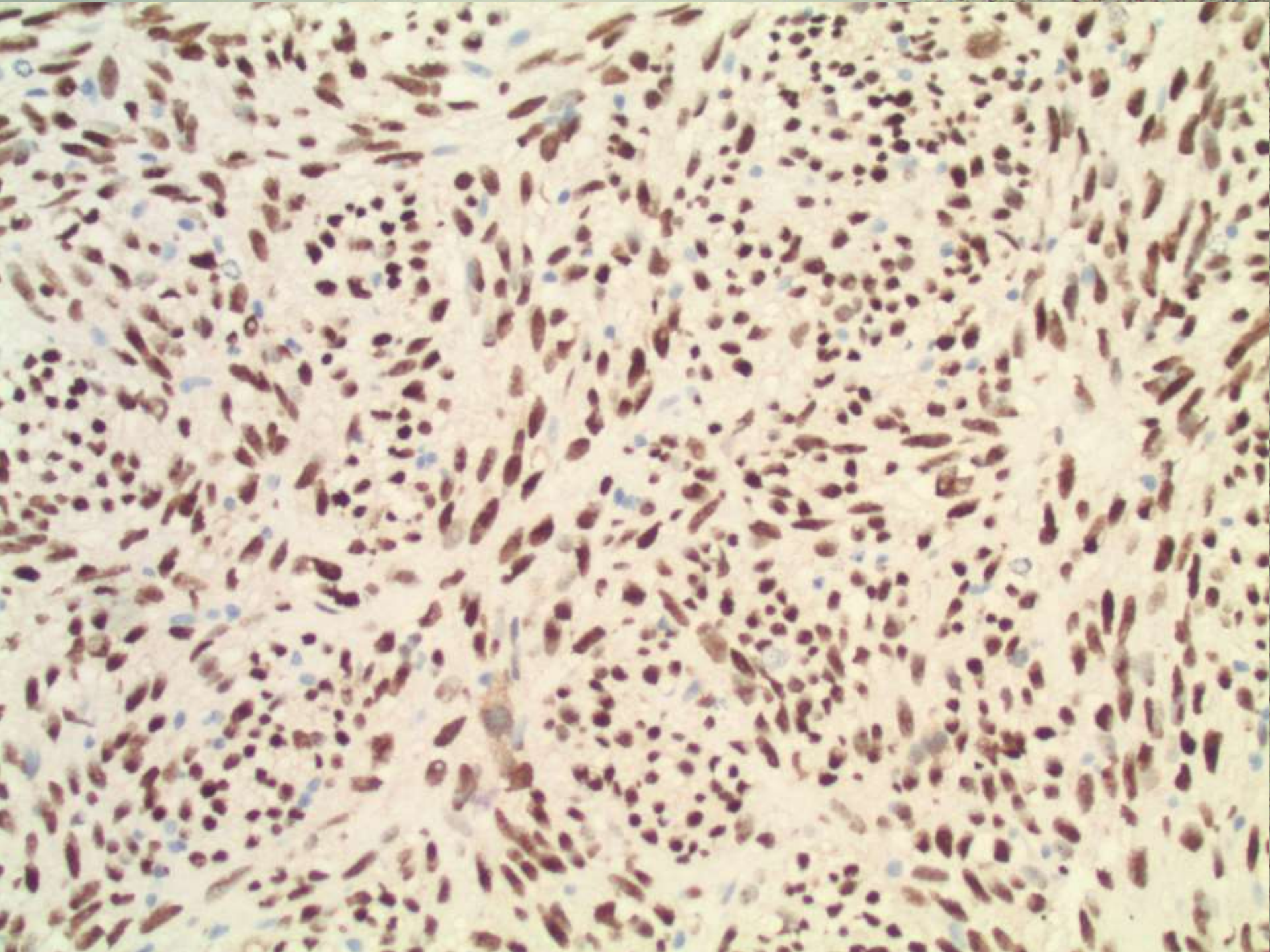


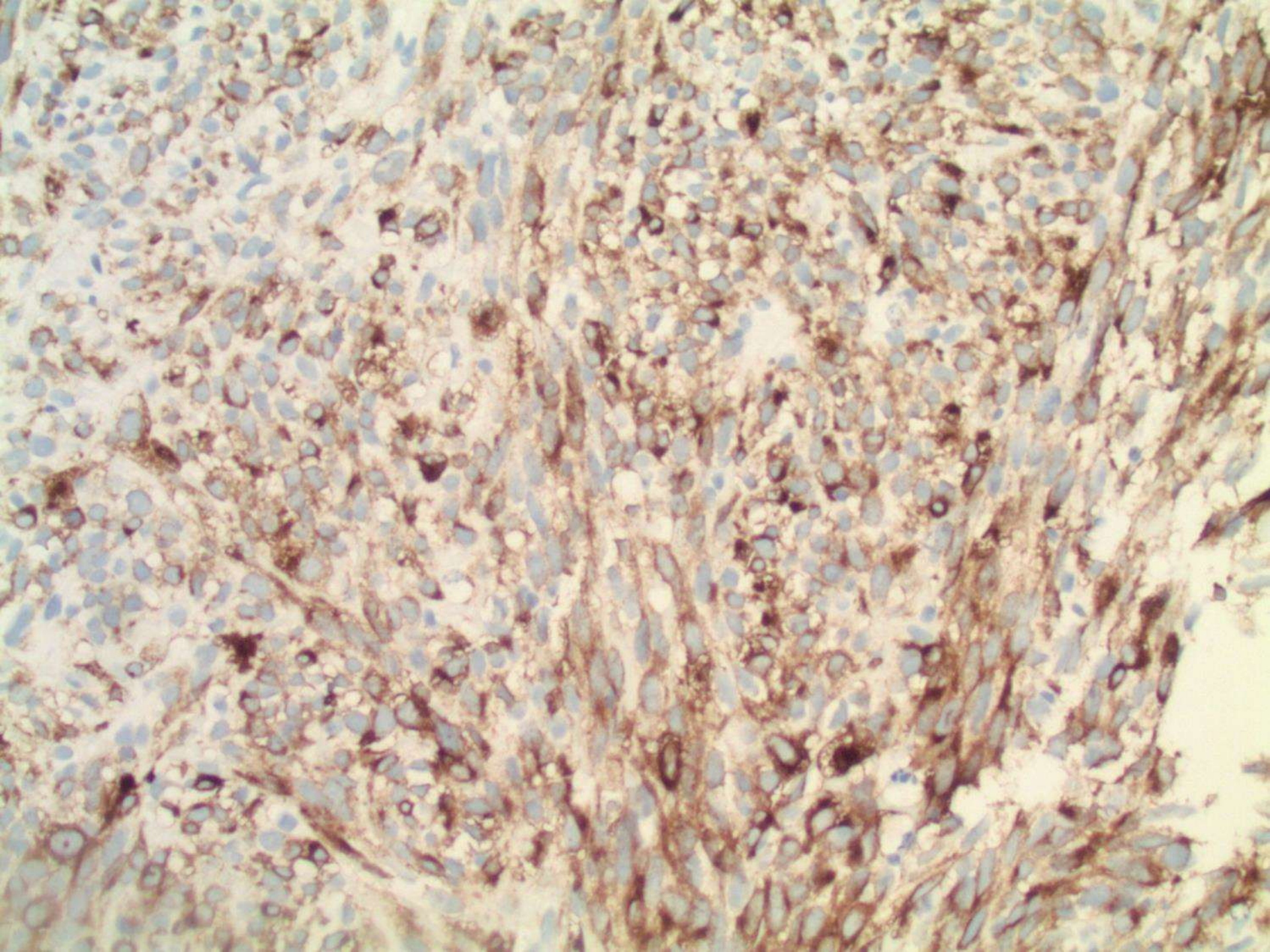
desmin



ERG

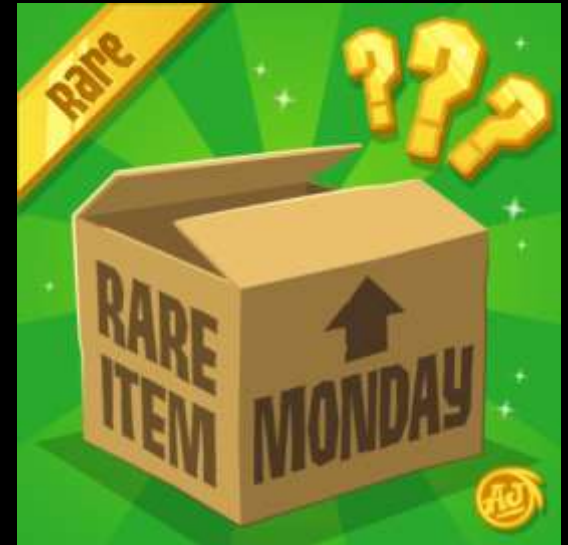





FINAL DX: MELANOMA

- **Presumably prior bladder**
 - RARE!
- **Follow up**
 - BRAF mutation negative
 - Being worked up for possible visceral metastasis



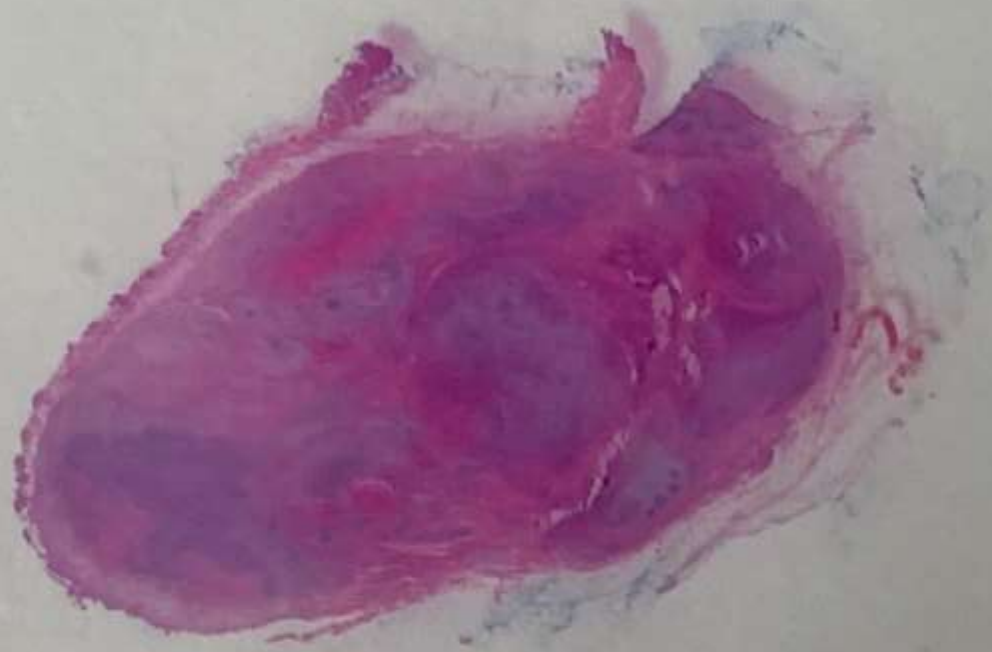20-0209

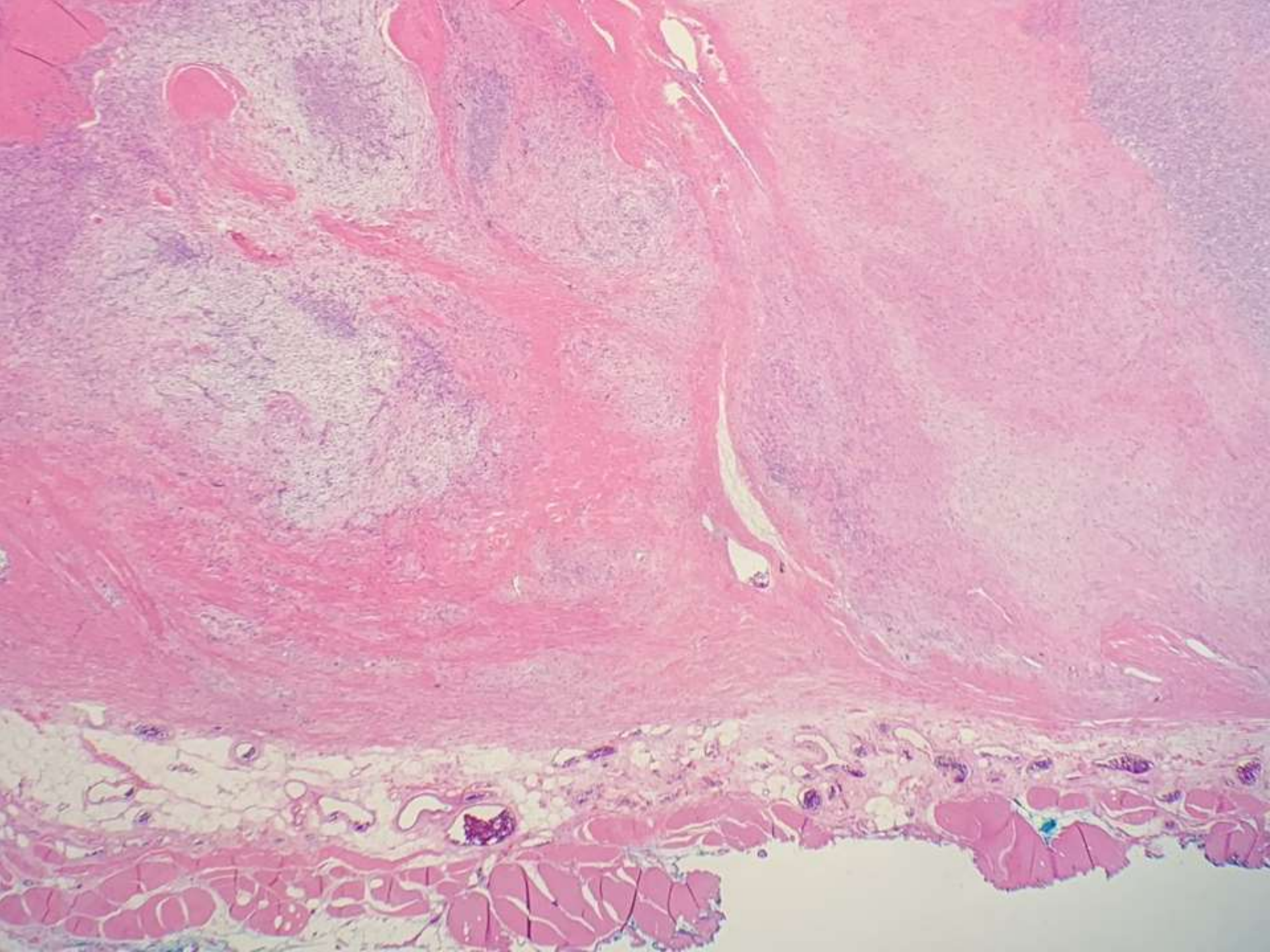
Matthew Koo/Greg Charville; Stanford

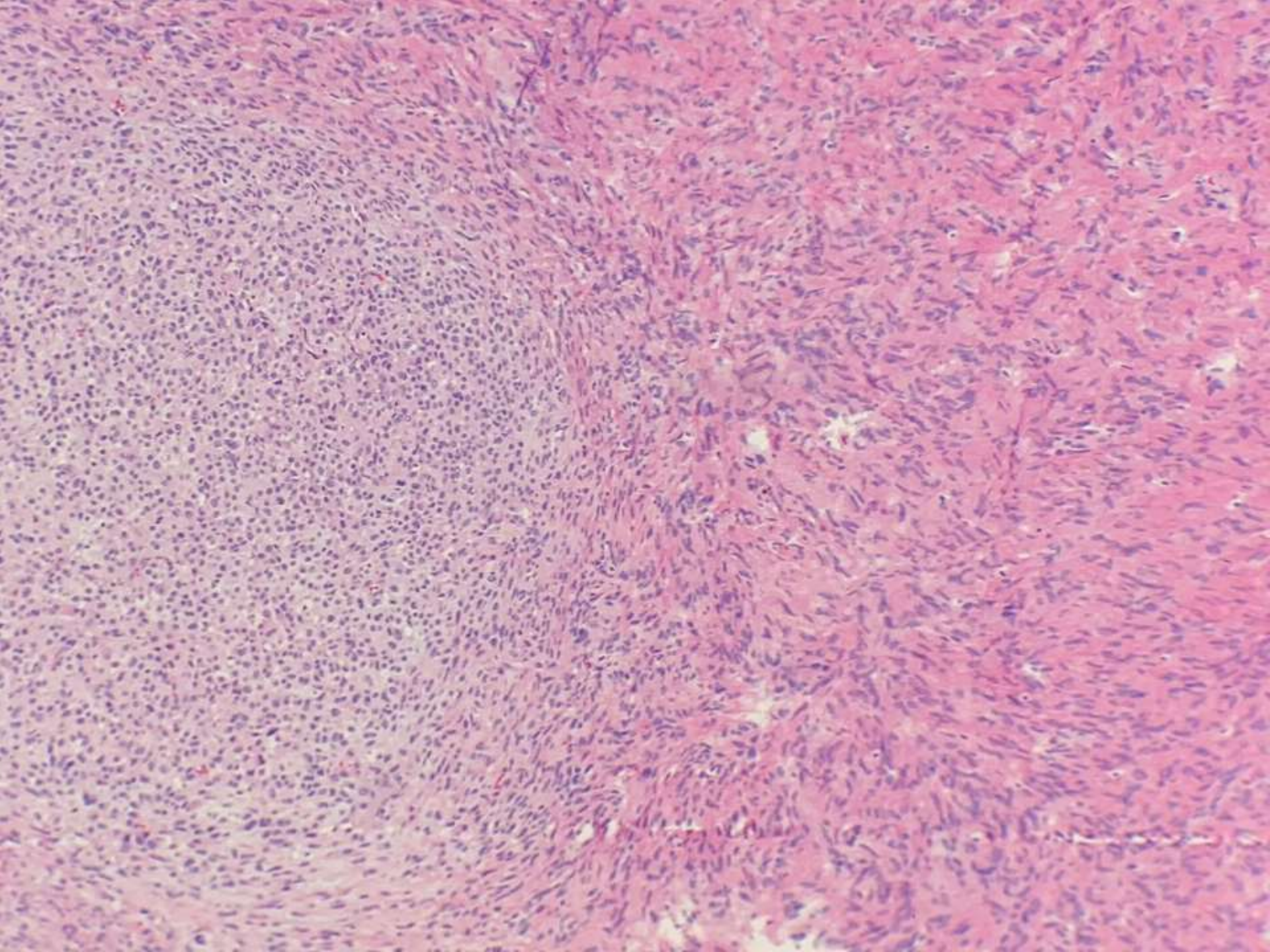
62-year-old M with abdominal mass.

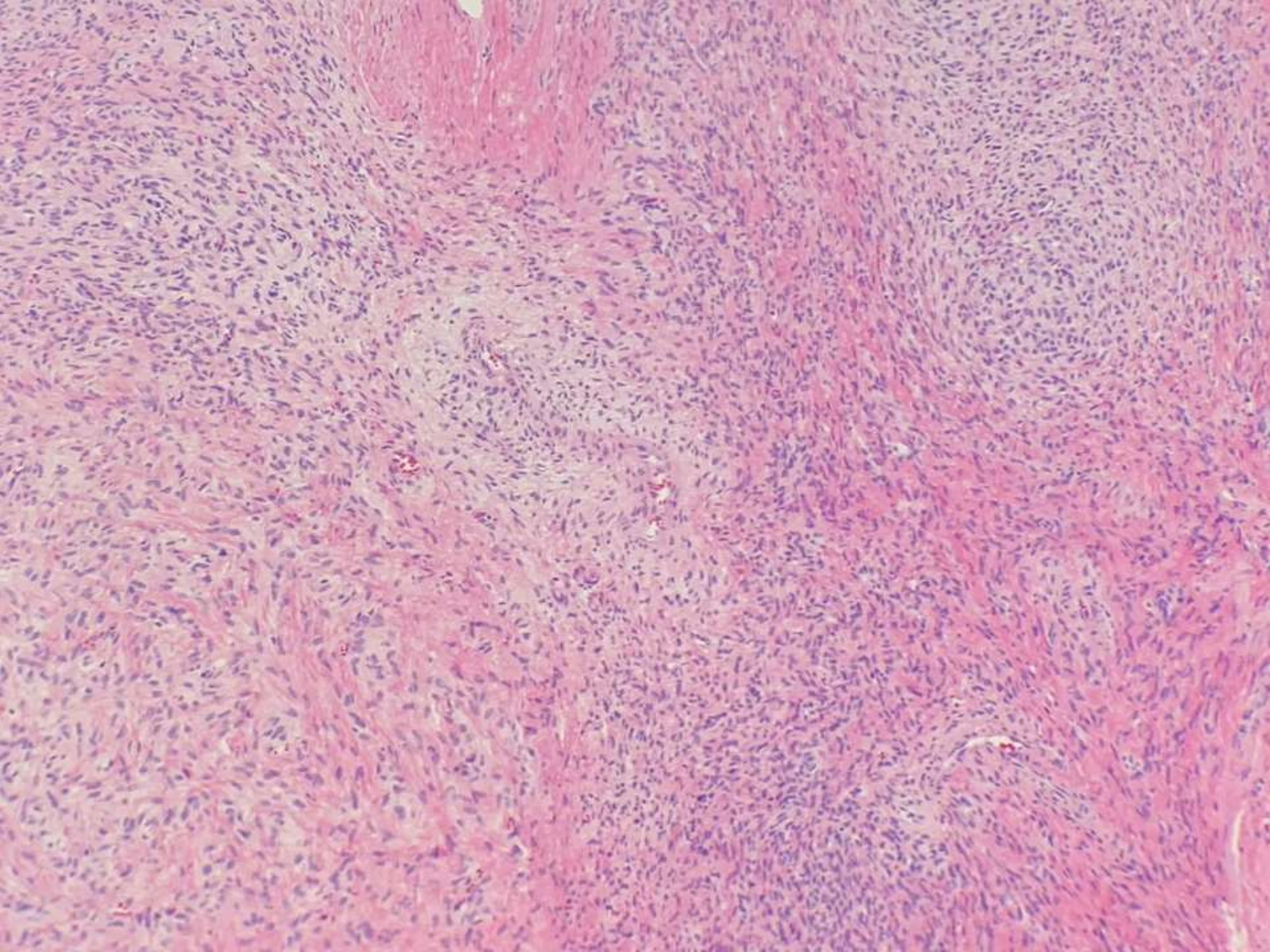
62-year-old man with abdominal mass

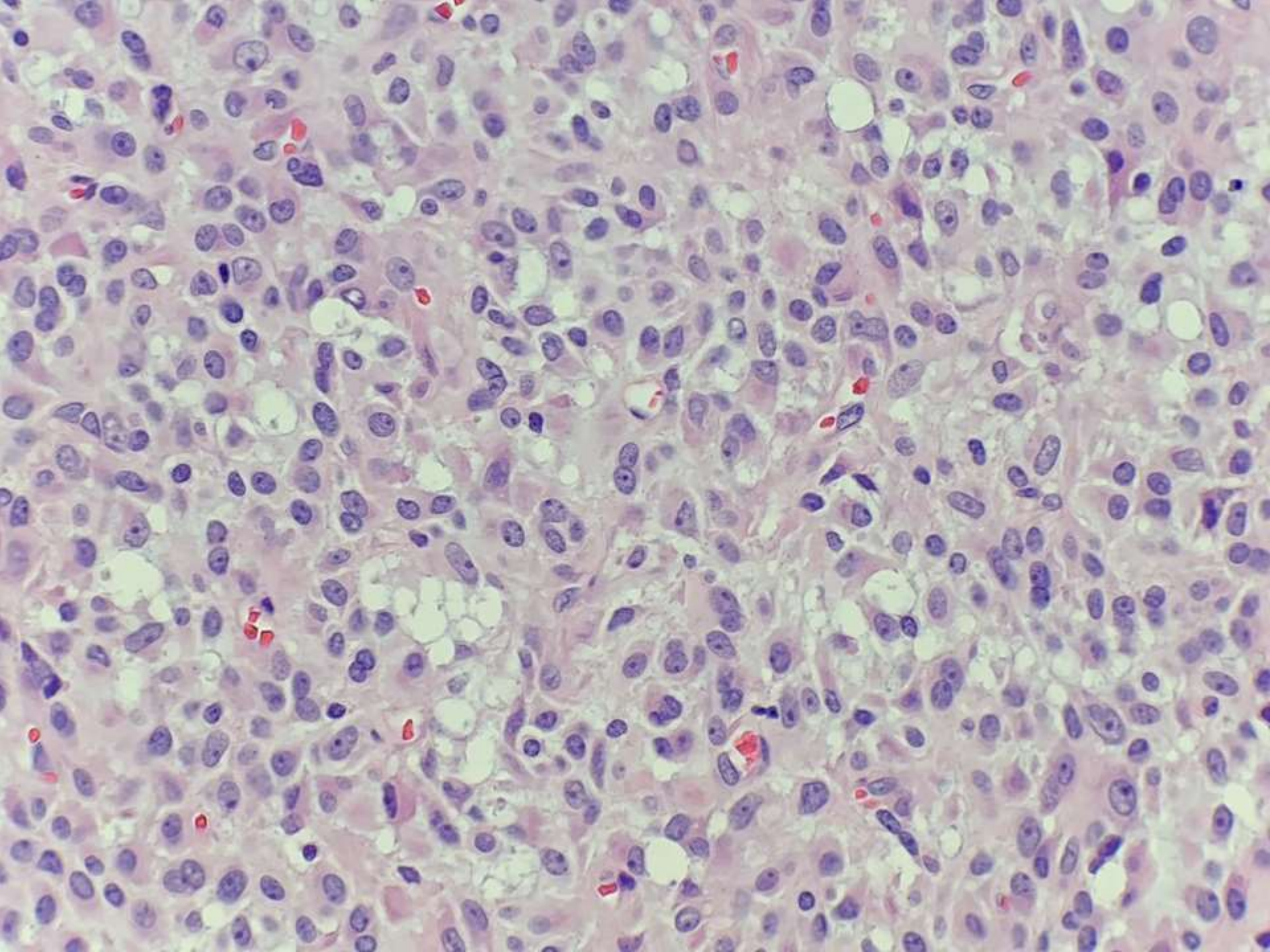
- Clinical history
 - 2.5 x 2.5 cm (8/2018) → 3.3 x 2.6 x 2.6 (4/2019)
- Gross examination
 - 5.5 x 3.6 x 3.3 cm whorled white-tan lobulated nodule

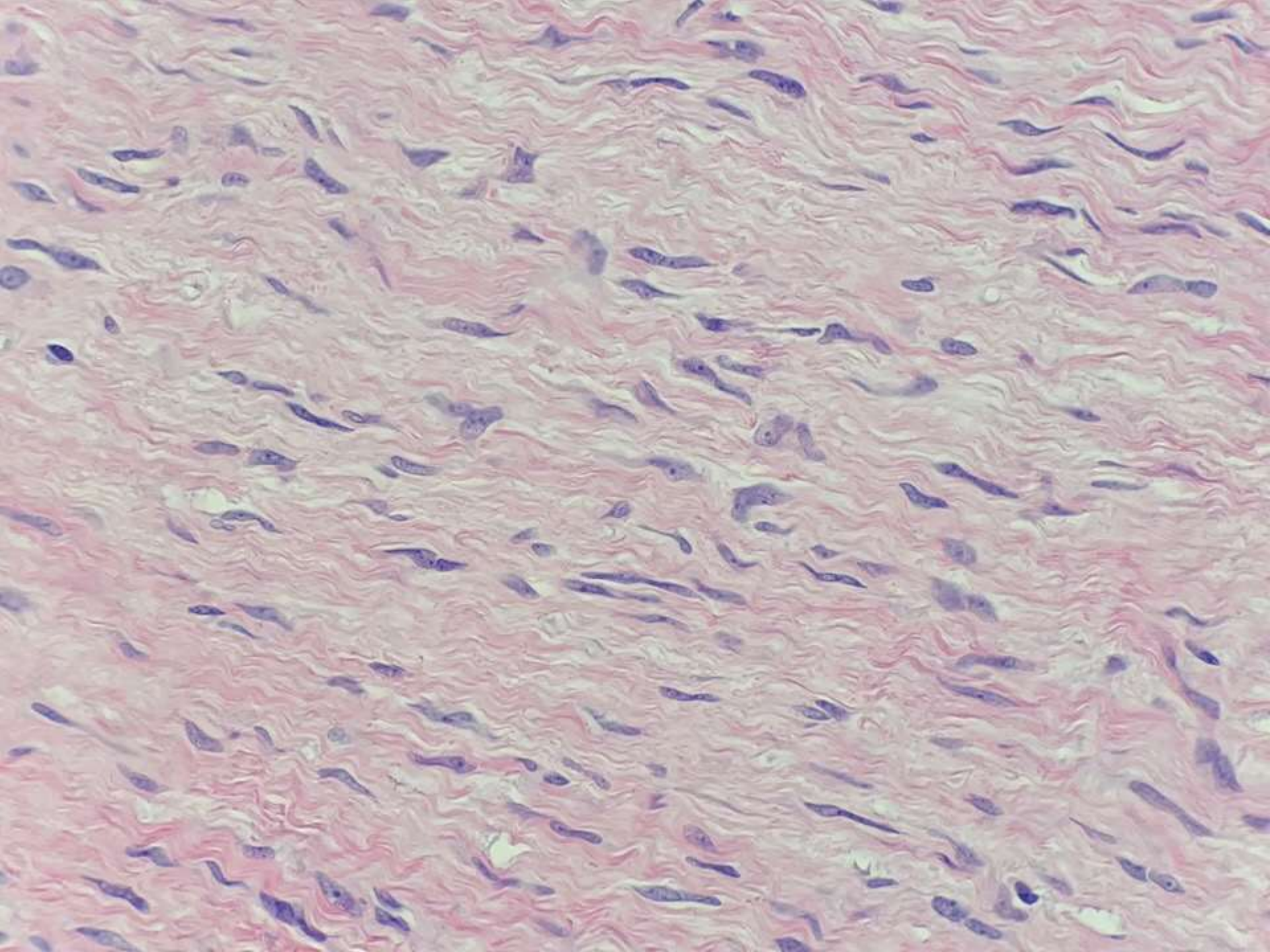


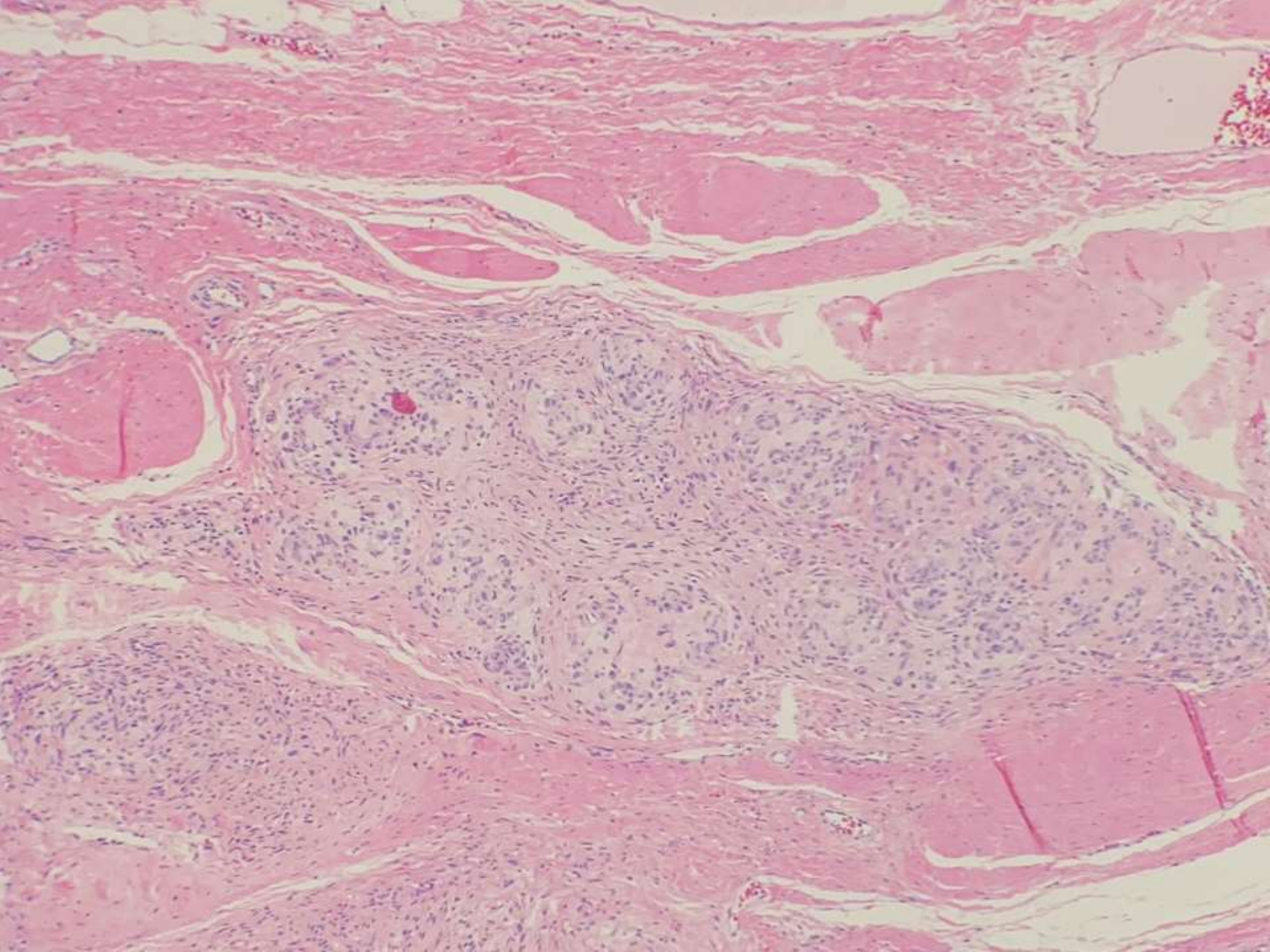


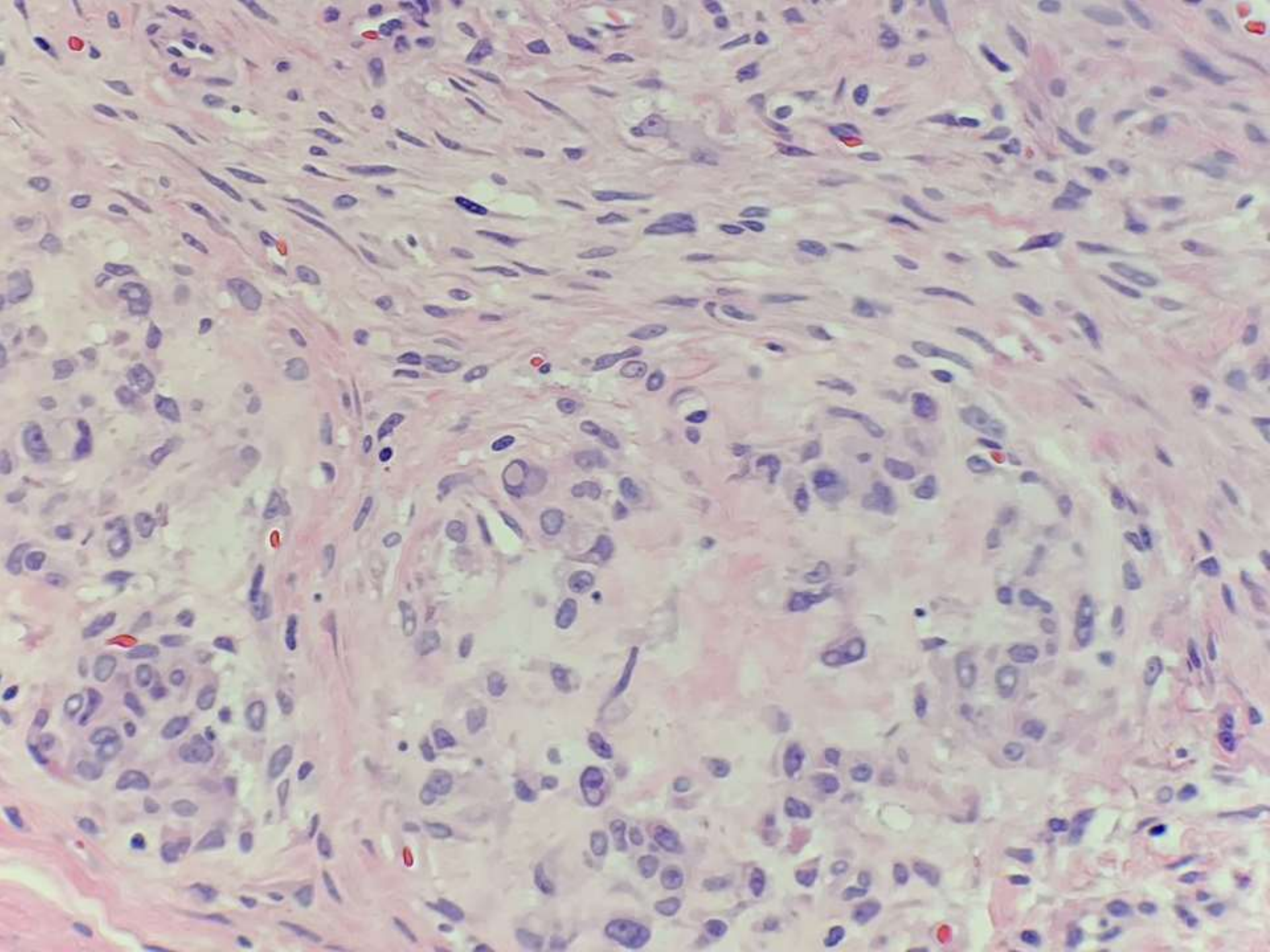








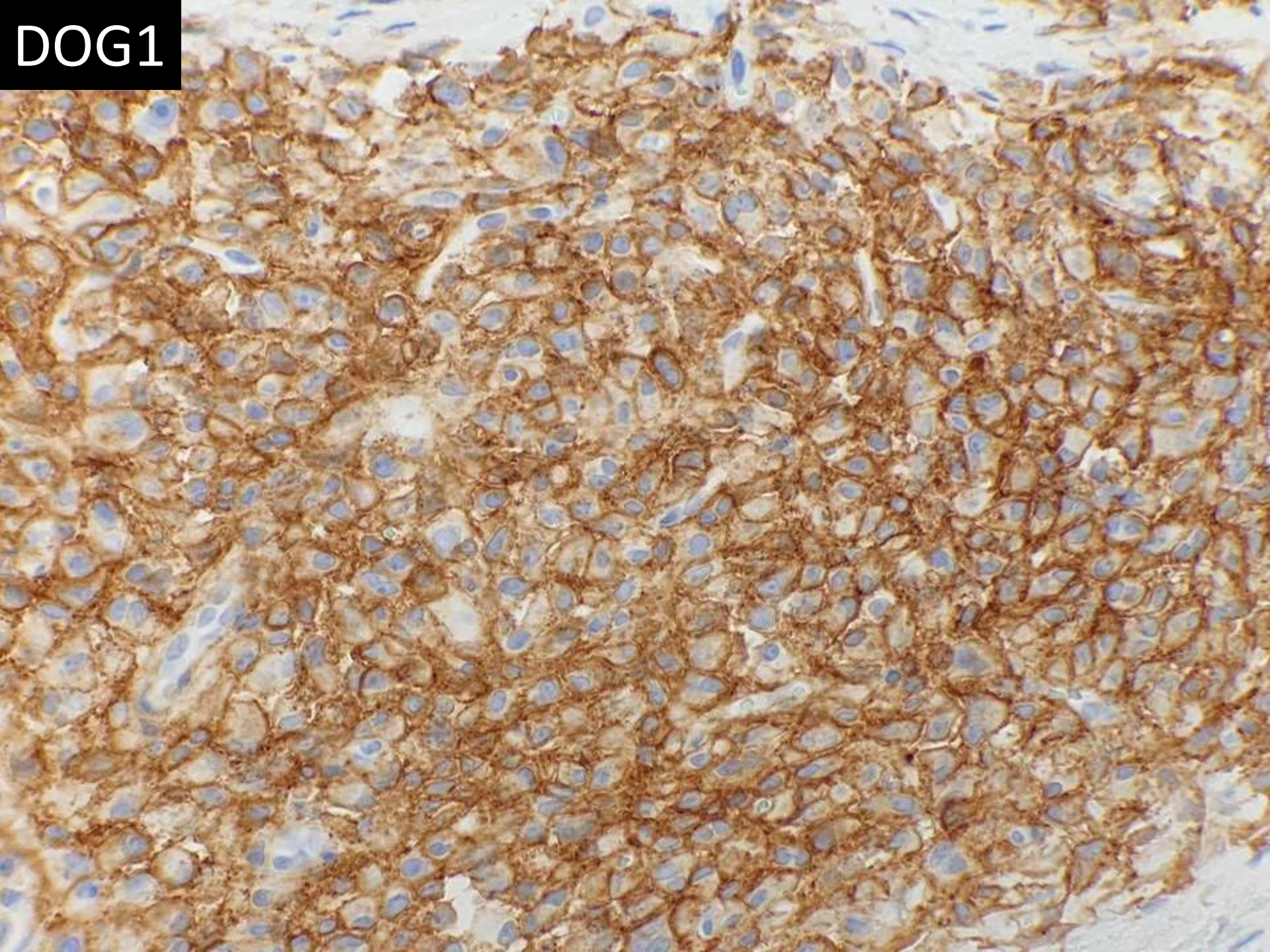




DOG1



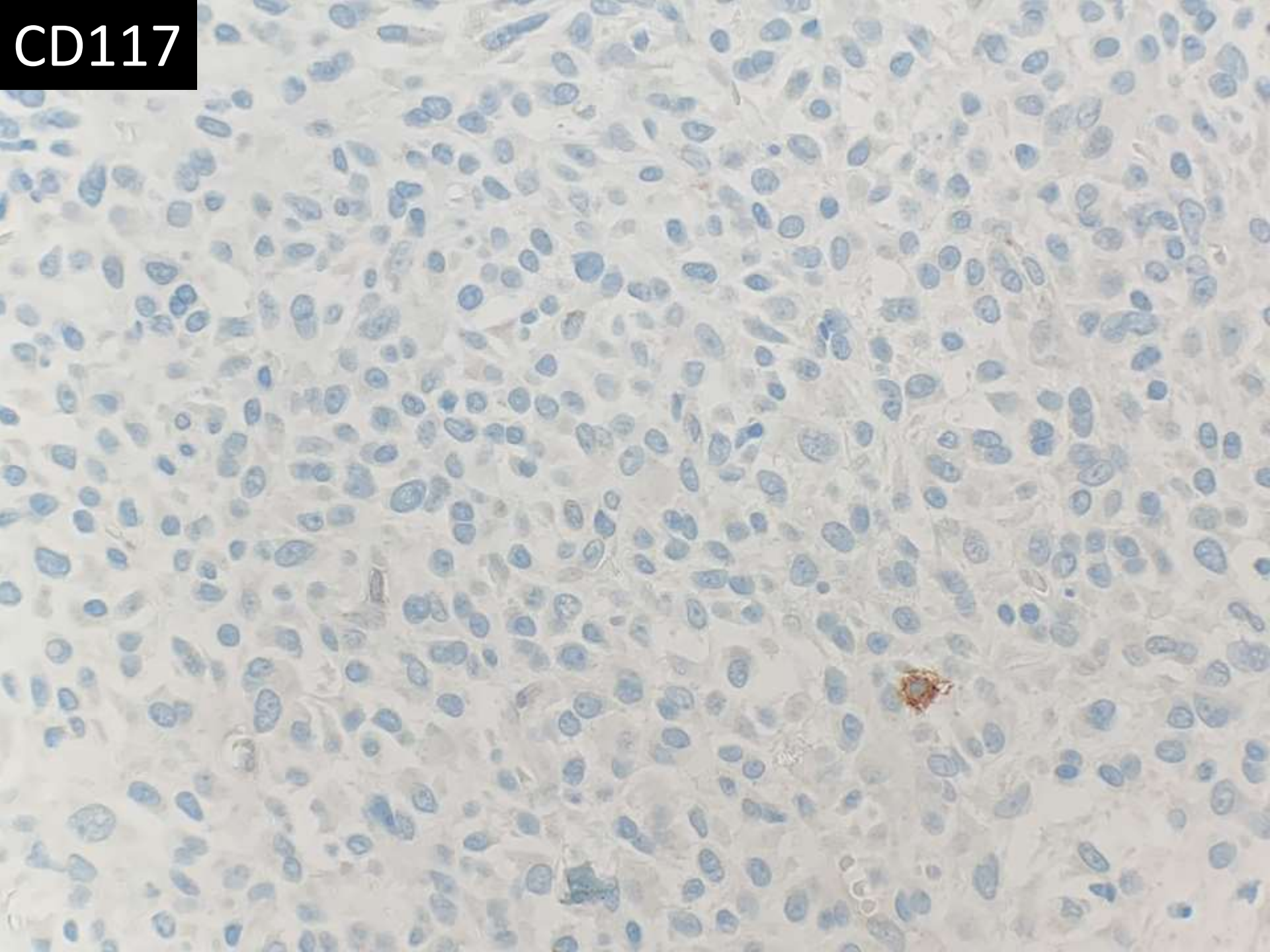
DOG1



CD117



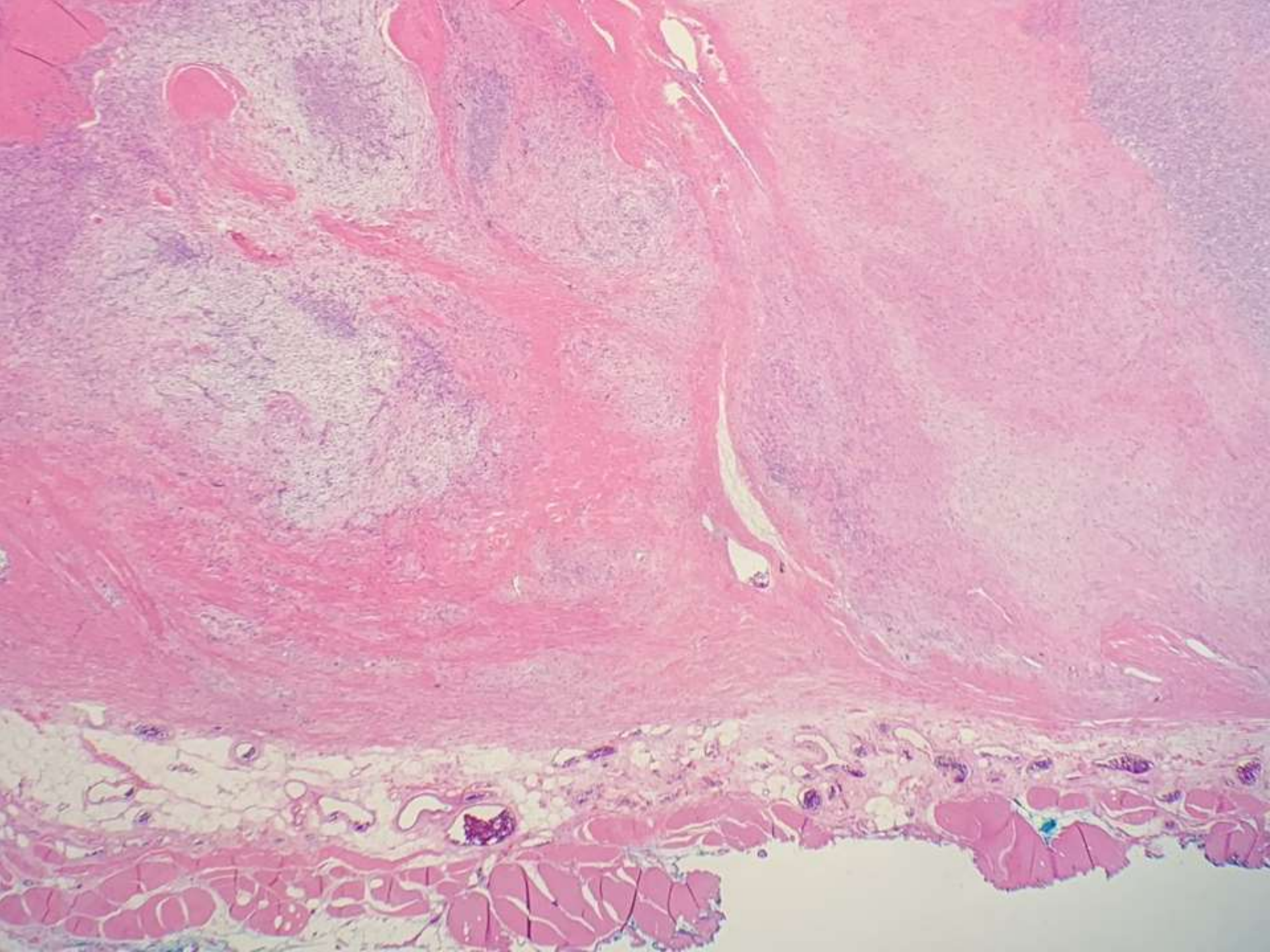
CD117

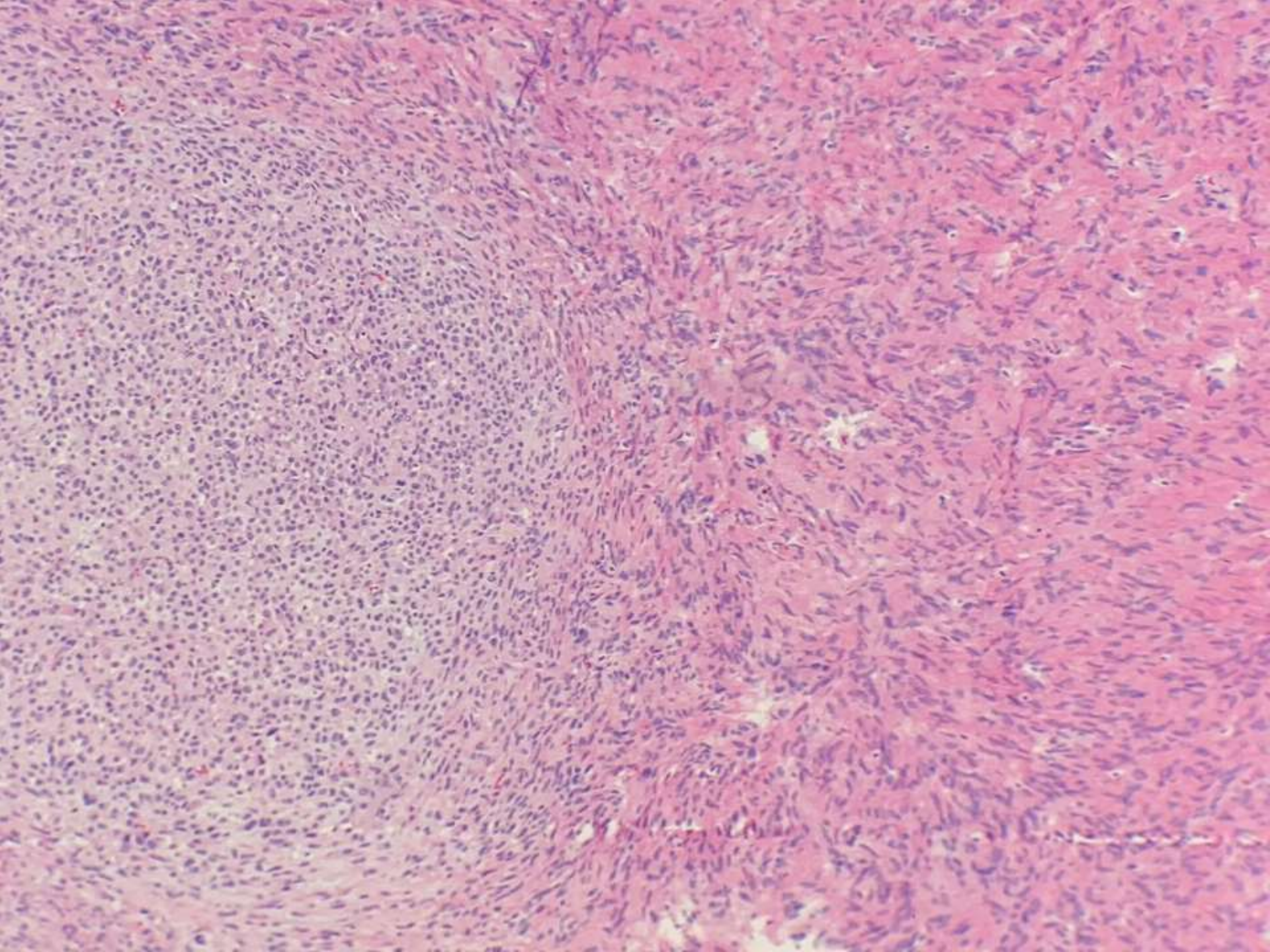


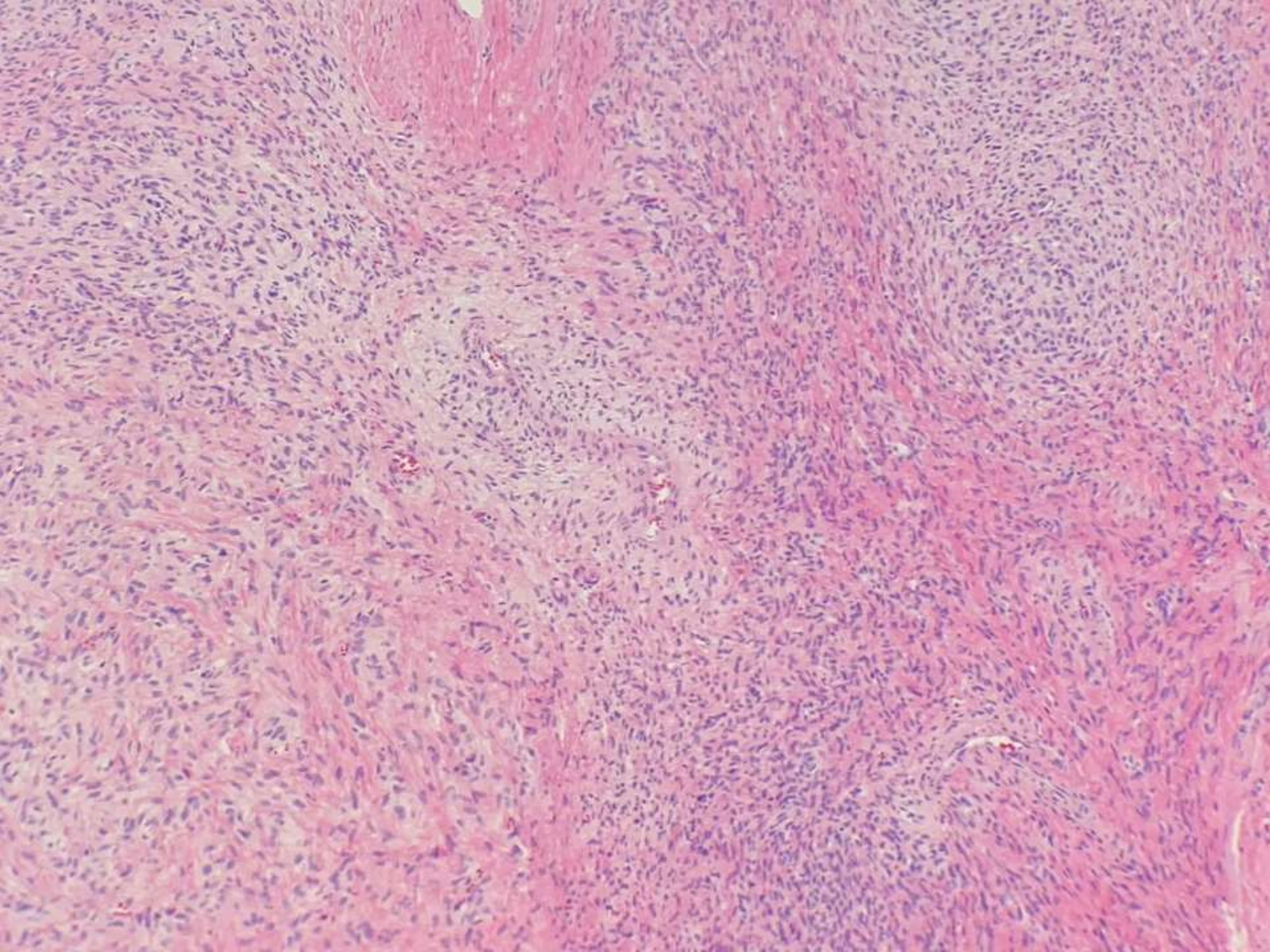
Additional Immunohistochemistry

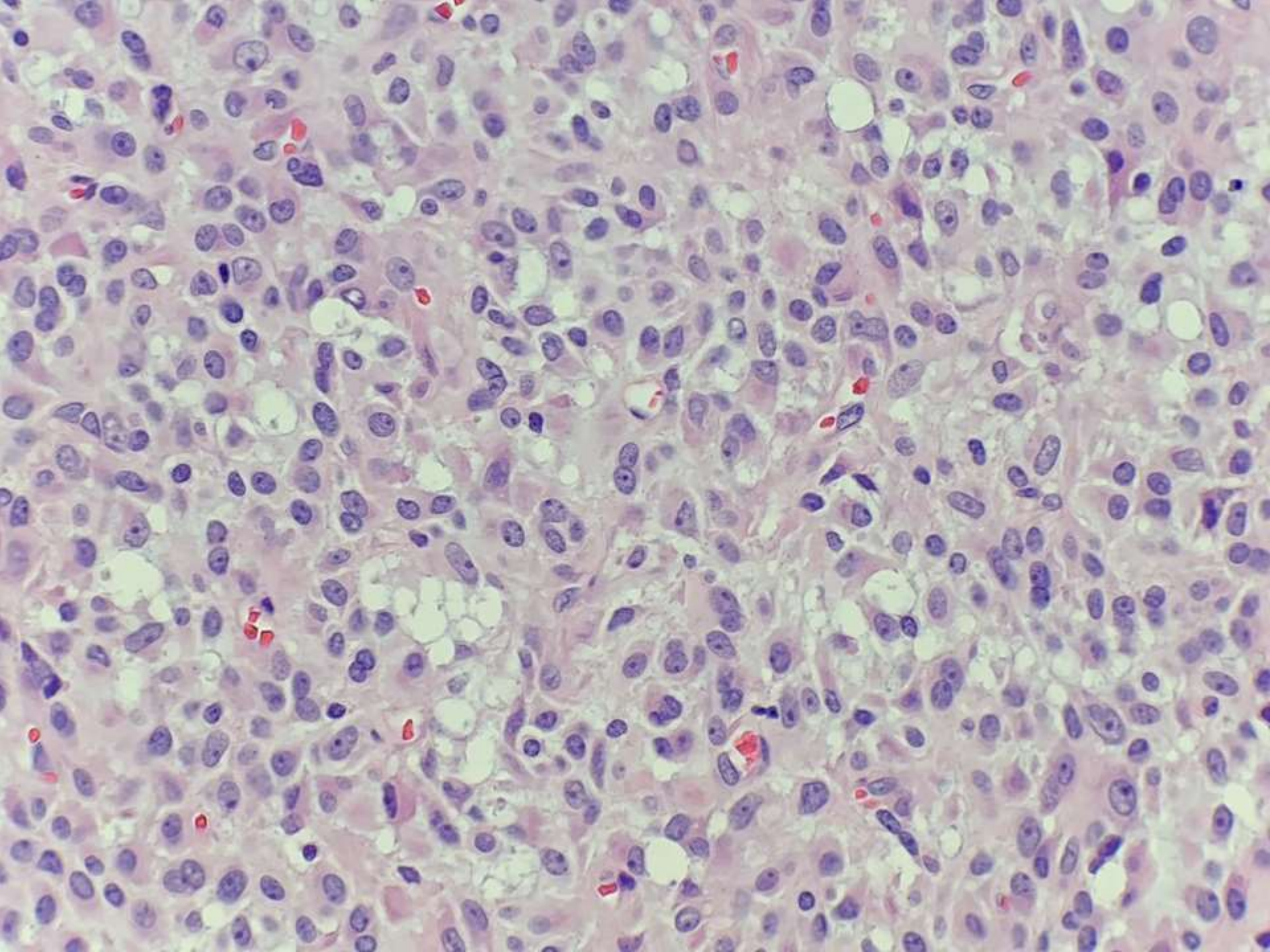
- Negative
 - CKAE1+Cam5.2, EMA, S100, HMB45, CD34, MDM2

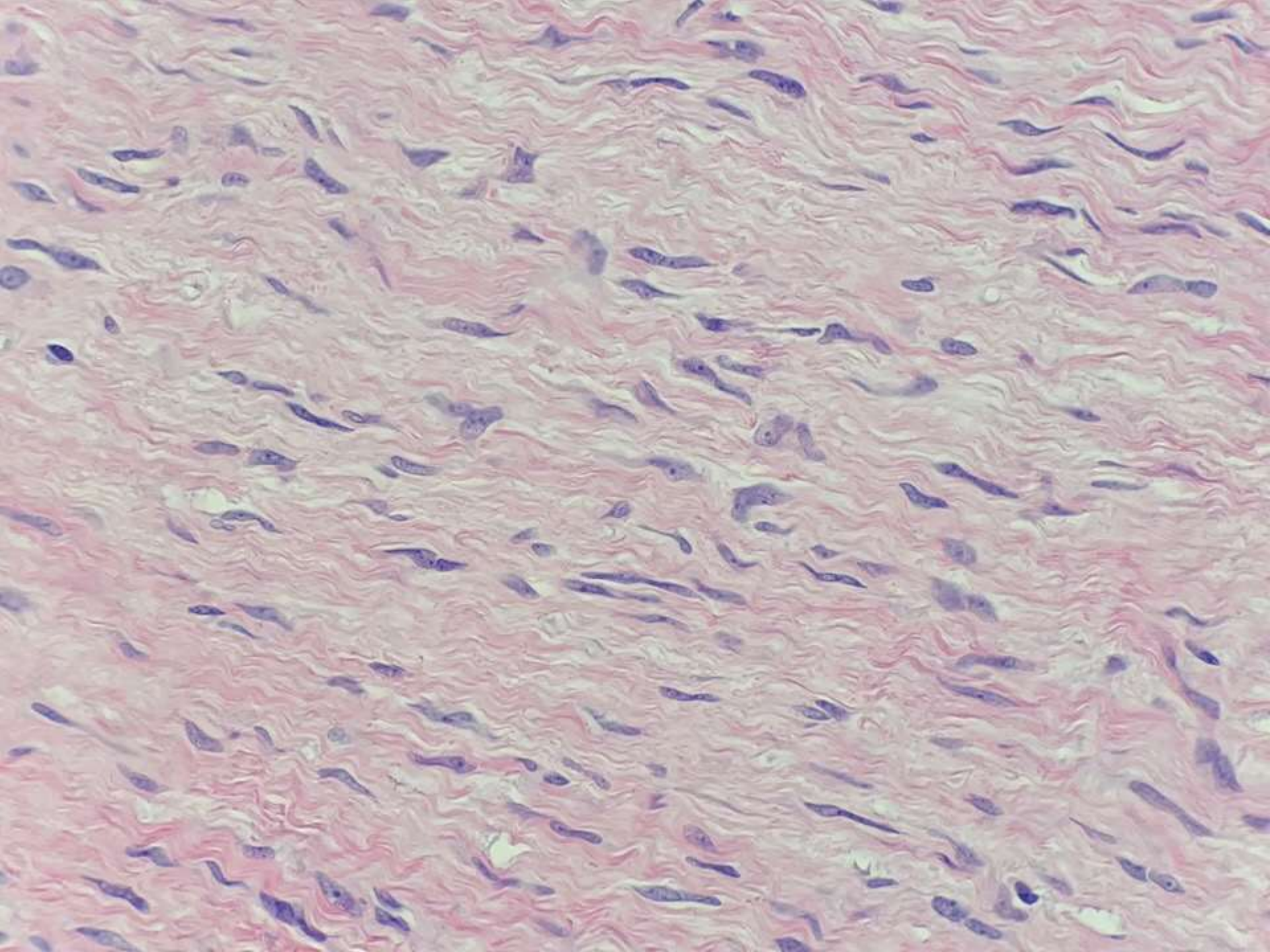


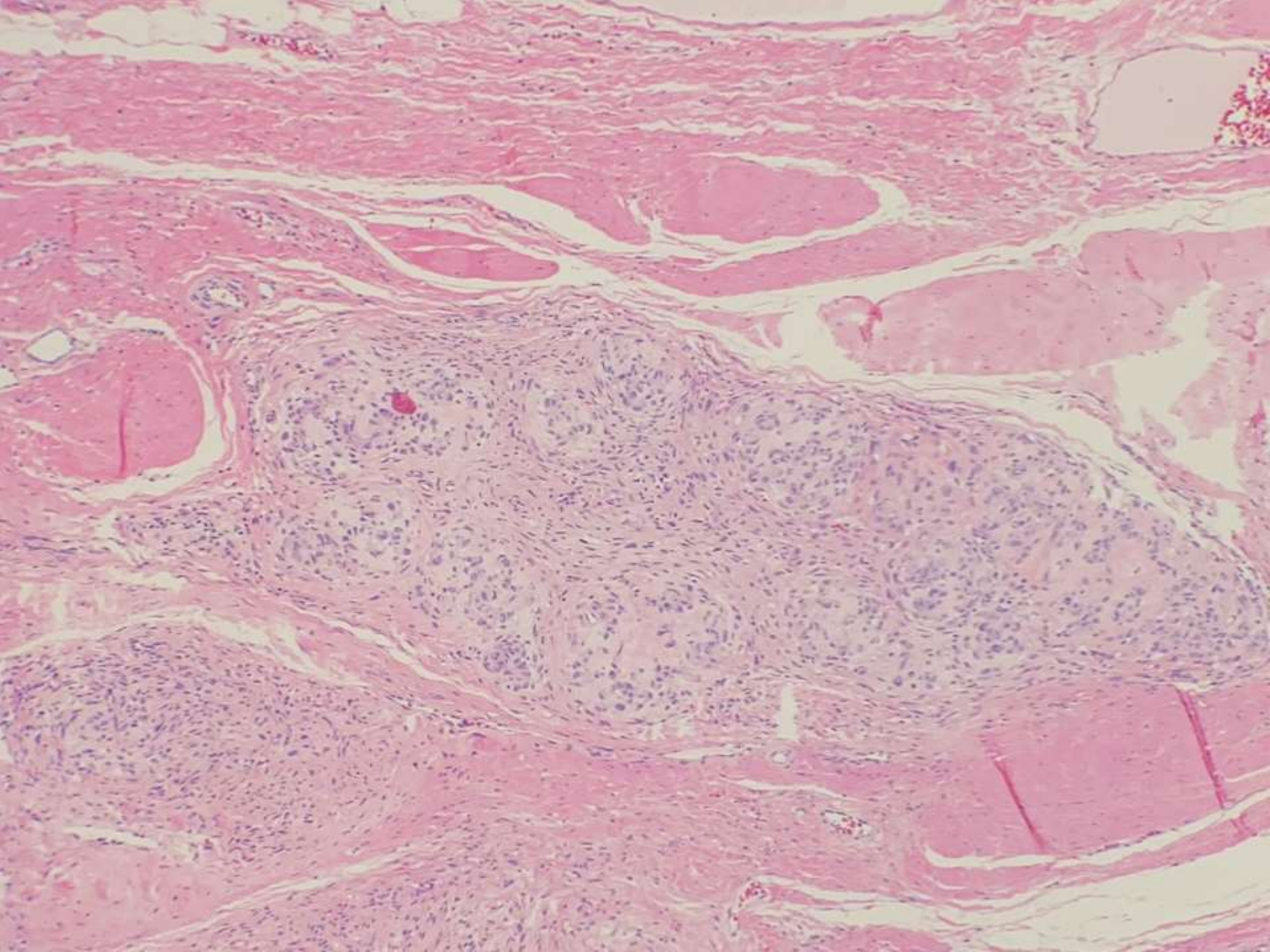


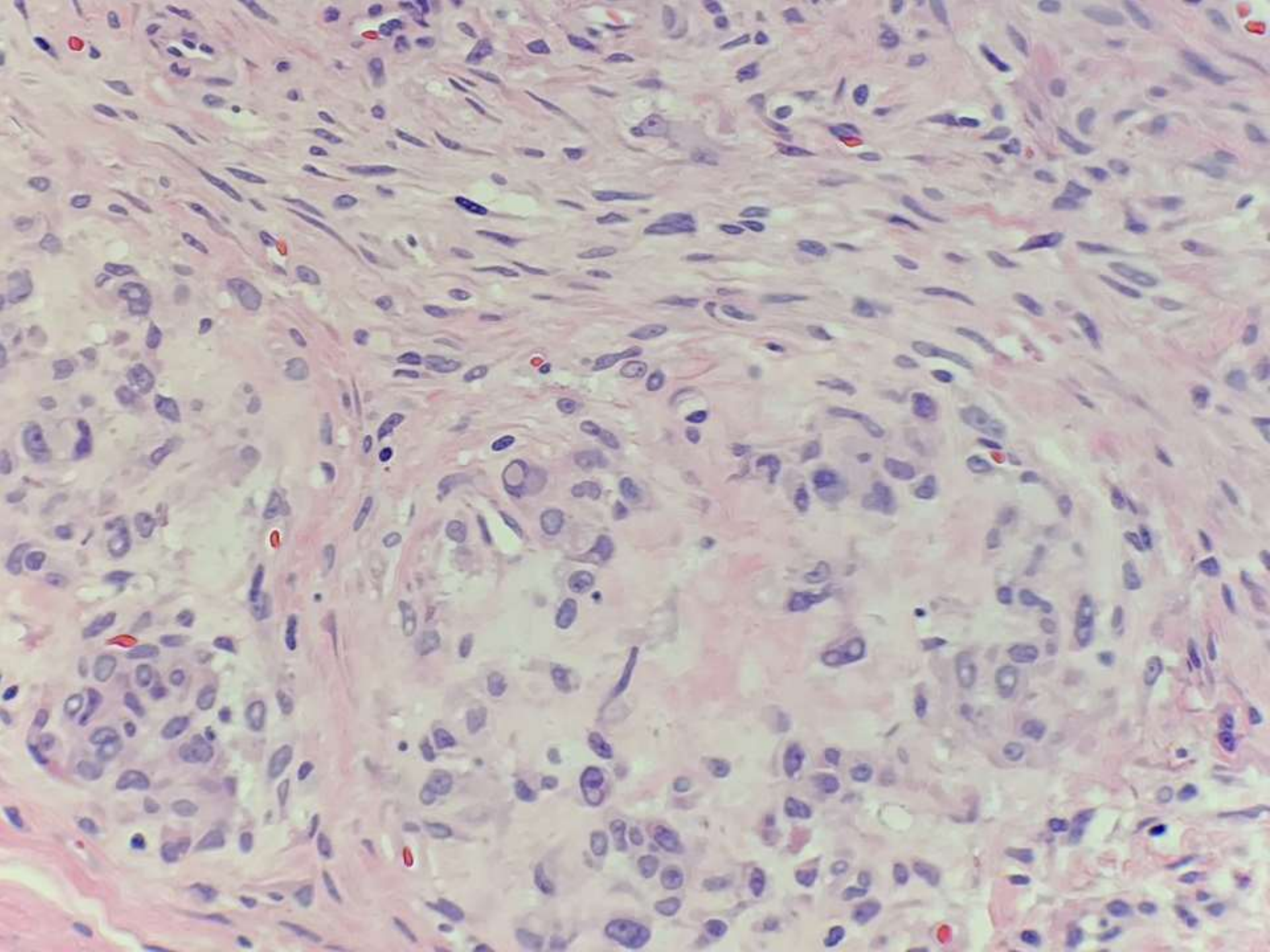








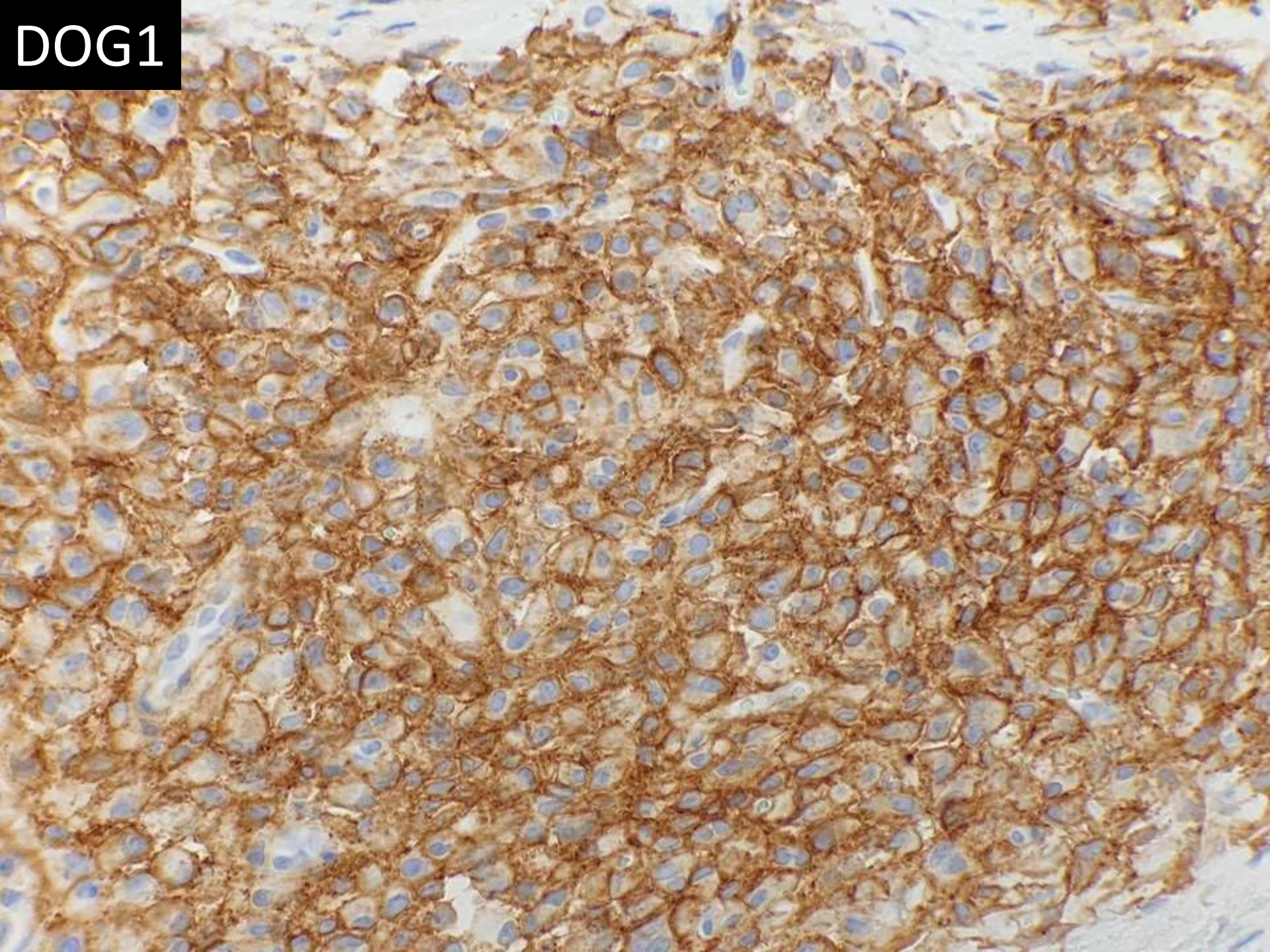




DOG1



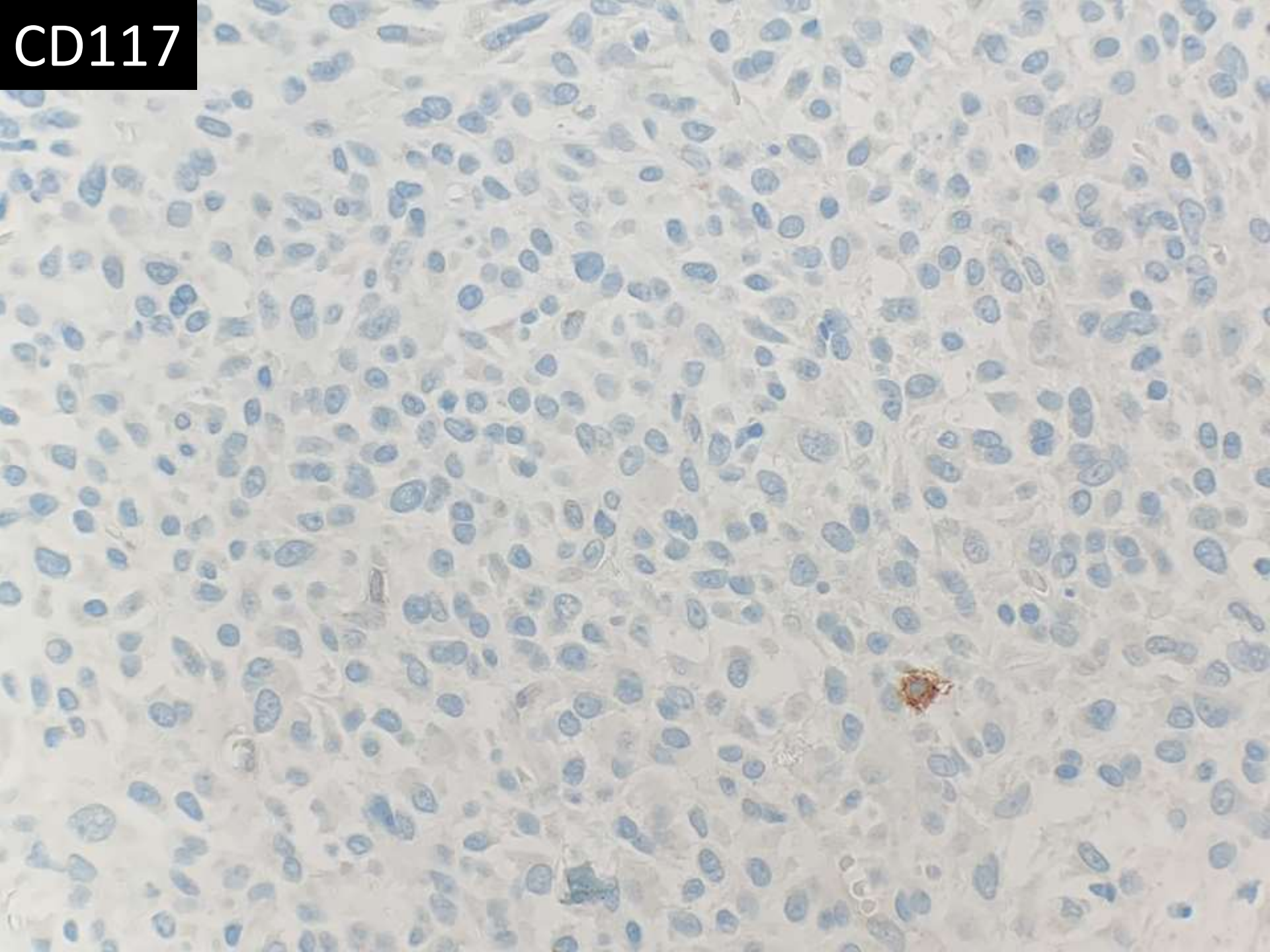
DOG1



CD117



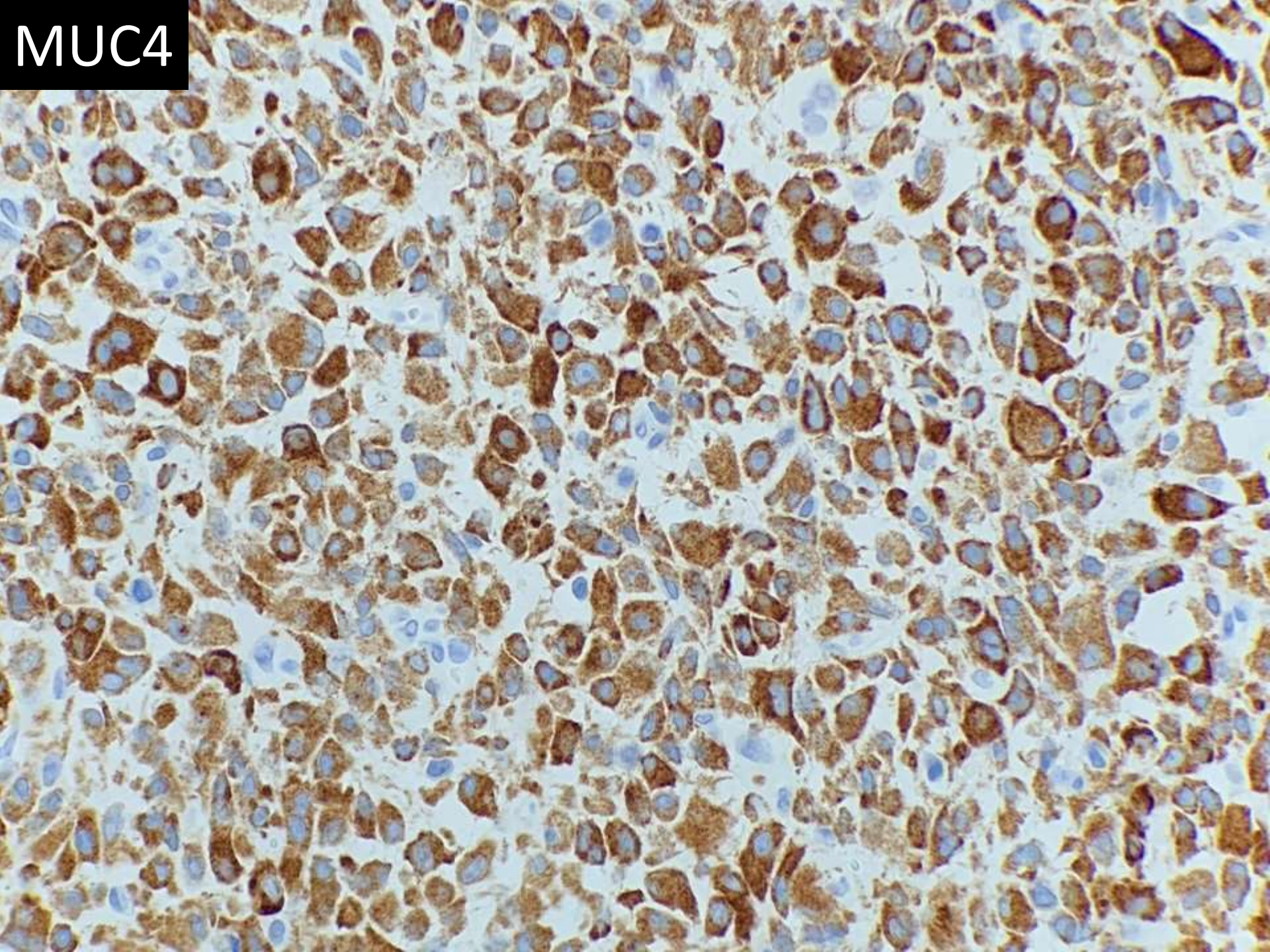
CD117



MUC4



MUC4



Additional Immunohistochemistry

- Negative
 - CKAE1+Cam5.2, EMA, S100, HMB45, CD34, MDM2

DIAGNOSIS

- Low-grade fibromyxoid sarcoma (LGFMS)

DOG1+ LGFMS

DOG1 Expression in Low-Grade Fibromyxoid Sarcoma: A Study of 11 Cases, With Molecular Characterization

Khin Thway, FRCPath¹, Wen Ng, FRCPath¹, Charlotte Benson, MRCP¹, John Chapman, FRCPath², and Cyril Fisher, MD, DSc, FRCPath¹

International Journal of Surgical Pathology

2015, Vol. 23(6) 454–460

© The Author(s) 2015

Reprints and permissions:

sagepub.com/journalsPermissions.nav

DOI: 10.1177/1066896915593801

ijs.sagepub.com



DOG1+ LGFMS

Table 1. Low-Grade Fibromyxoid Sarcoma: Molecular Features and Immunohistochemical MUC4 and DOG1 Expression^a.

Case No.	Morphology	Molecular Characteristics (<i>FUS-CREB3L2</i> Fusion Transcripts With RT-PCR or <i>FUS</i> or <i>EWSR1</i> Rearrangement With FISH)	MUC4 Expression	DOG1 Expression (Positive or Negative)	DOG1 Expression Intensity	% of Cells Expressing DOG1
1 (index case)	Hyalinized stroma only; no myxoid areas	<i>FUS-CREB3L2</i>	+	Positive	Strong	100%
2	Classical	N/A	+	Negative		
3	Classical	<i>FUS-CREB3L2</i>	+	Positive	Weak	10%
4	Classical	<i>FUS-CREB3L2</i>	+	Negative		
5	Classical	<i>FUS-CREB3L2</i>	+	Negative		
6	Classical	<i>FUS-CREB3L2</i>	+	Positive	Moderate	50%
7	Classical	<i>FUS-CREB3L2</i>	+	Positive	Strong	75%
8	Hyalinized stroma only; no myxoid areas	<i>FUS-CREB3L2</i>	+	Positive	Weak	30%
9	Classical	<i>FUS-CREB3L2</i>	+	Negative		
10	Classical	<i>EWSR1</i> rearrangement	+	Negative		
11	Classical	<i>FUS-CREB3L2</i>	+	Positive	Weak	5%

Abbreviations: FISH, fluorescence in situ hybridization; N/A, not applicable; RT-PCR, reverse transcription-polymerase chain reaction.

^aClassical indicates that both typical fibrous and myxoid areas were present in the tumor. + for MUC4 indicates diffusely positive.

DOG1+ LGFMS

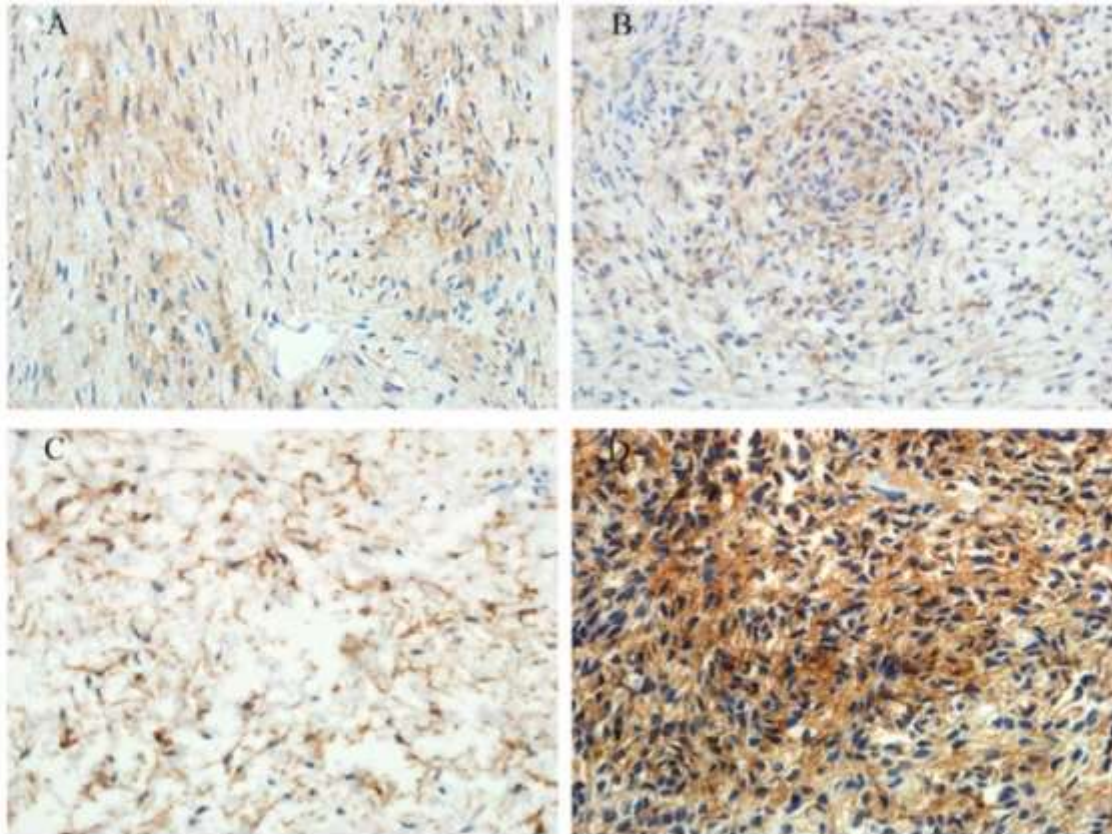
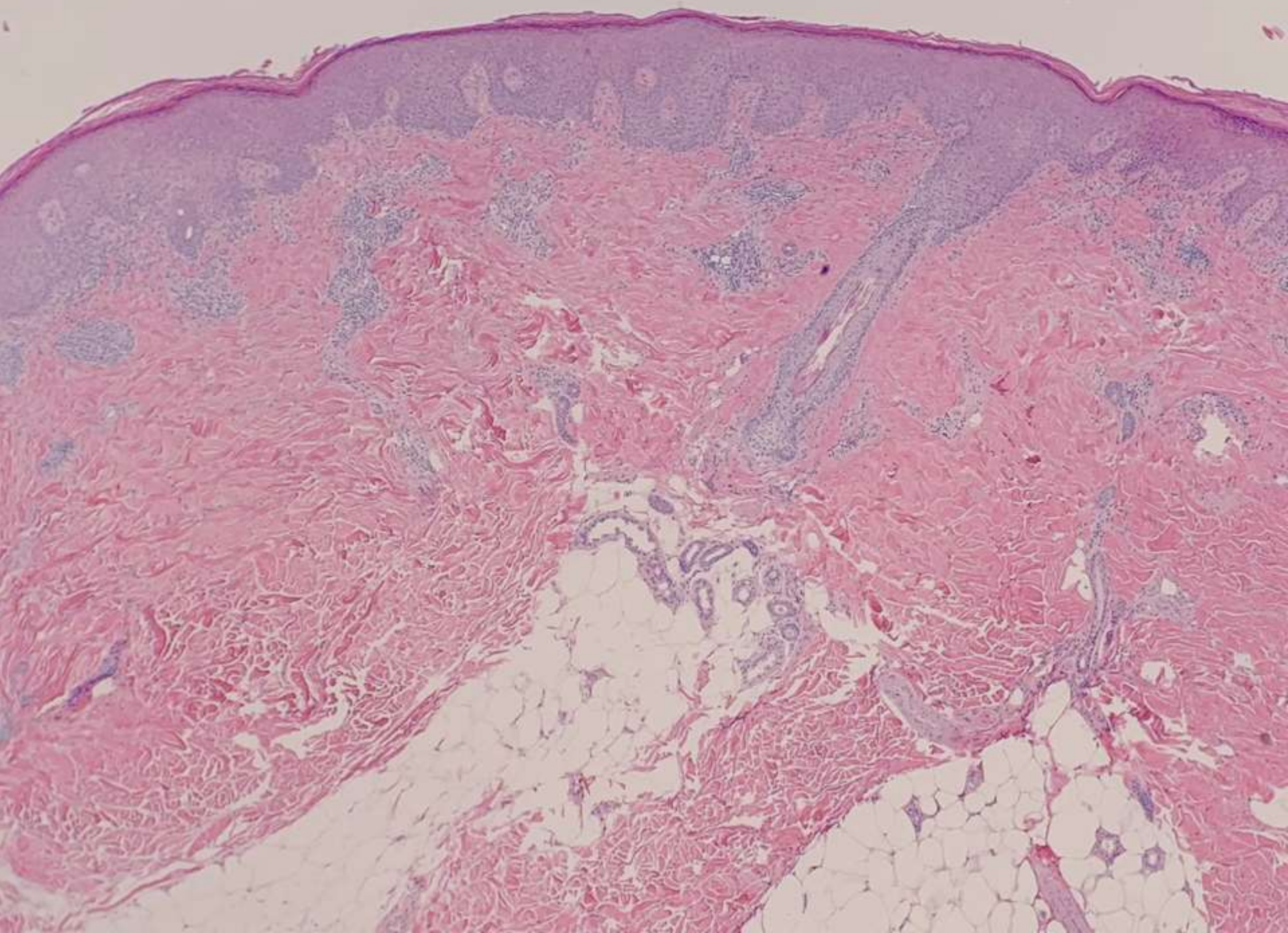


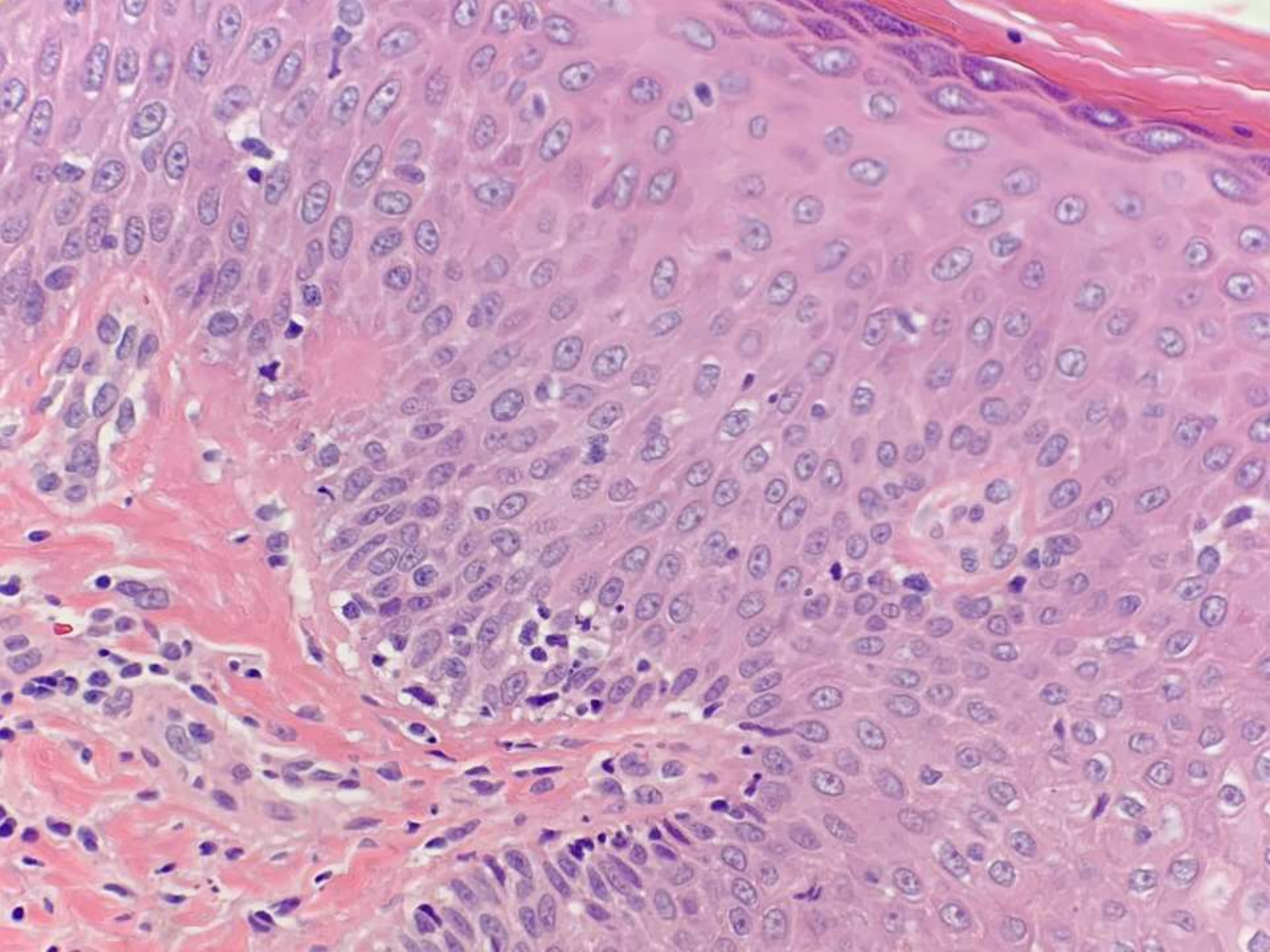
Figure 2. (A-D) These examples of molecularly proven LGFMS show a spectrum of DOG1 expression. Focal moderate cytoplasmic expression is seen in A and B, and seen accentuating a cellular whorl (B). (C) This example shows DOG1 expression in most cells, but the tumor is relatively sparsely cellular. (D) This case shows a cellular focus, in which there is diffuse and strong expression of DOG1.

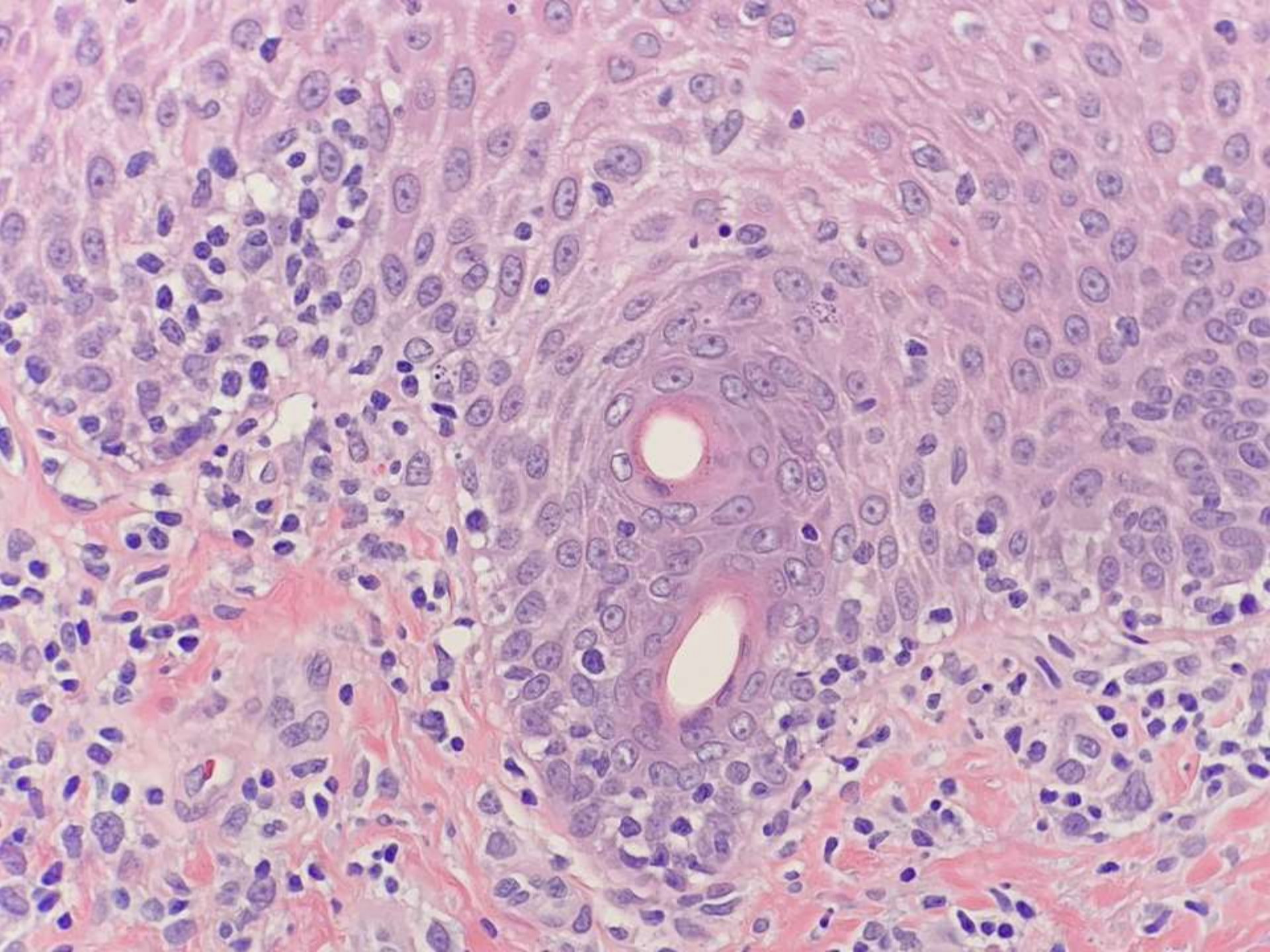
20-0210

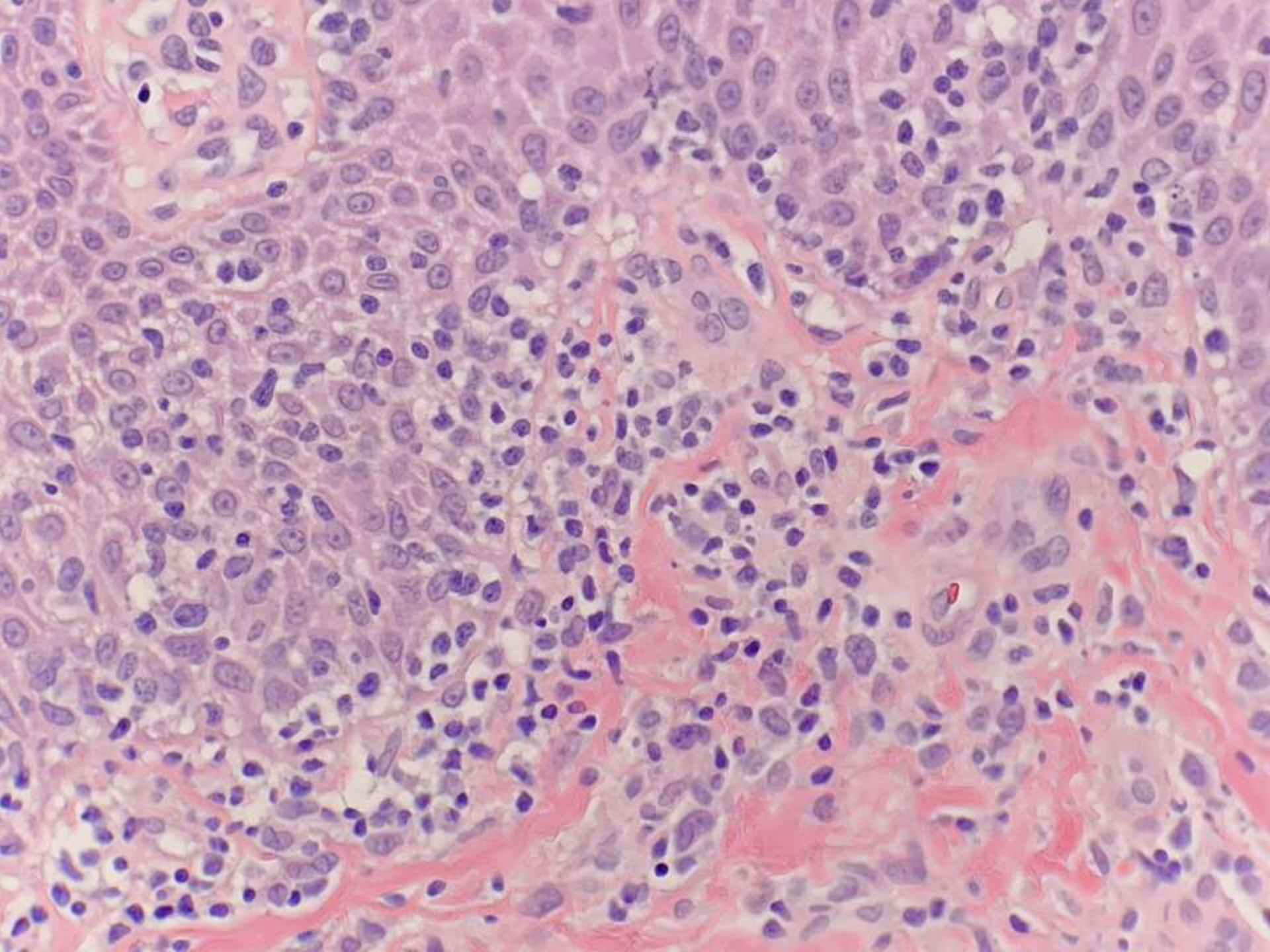
Matthew Koo/Roberto Novoa; Stanford

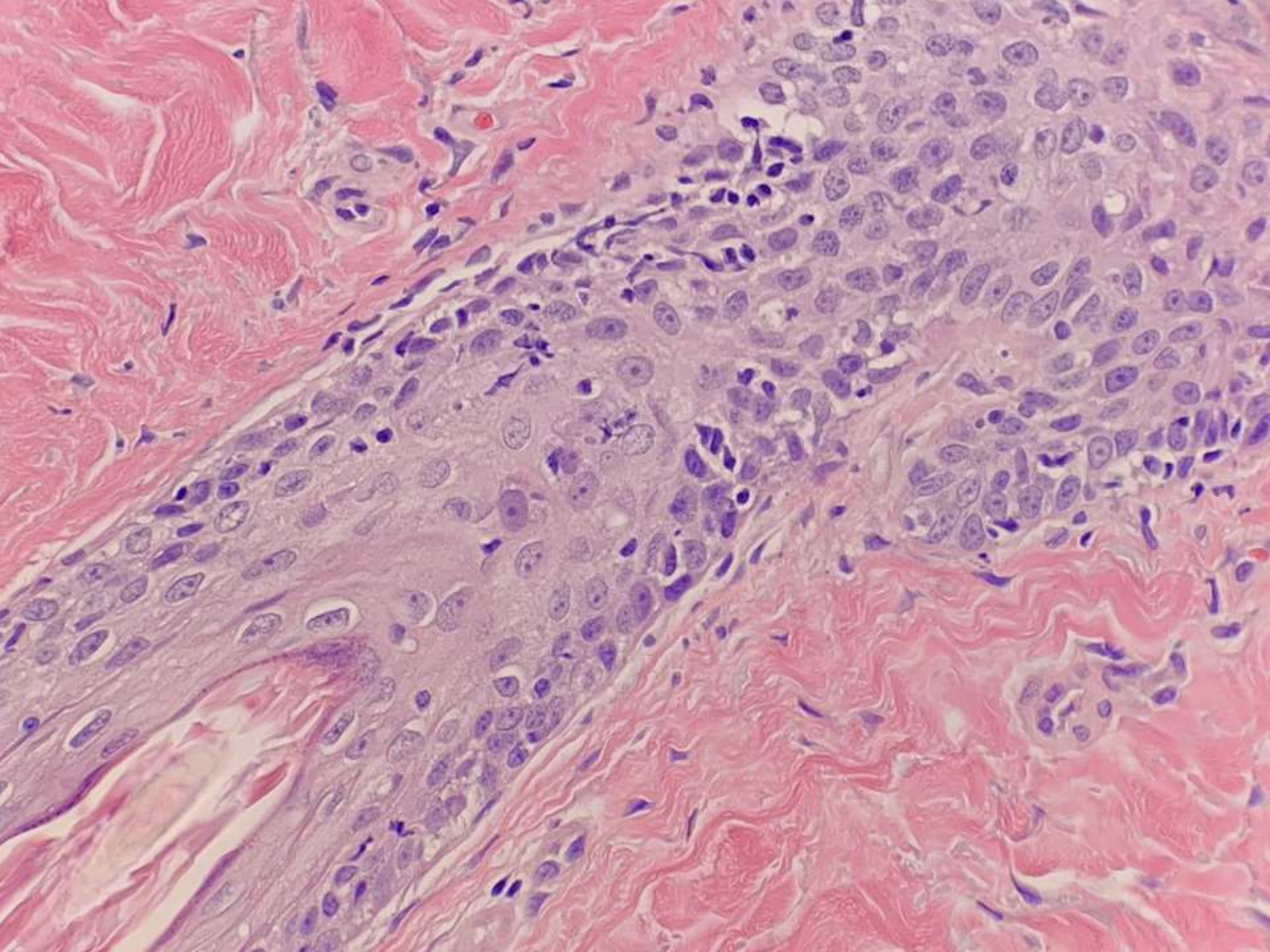
65-year-old M with rapidly progressive diffuse
pink patches.

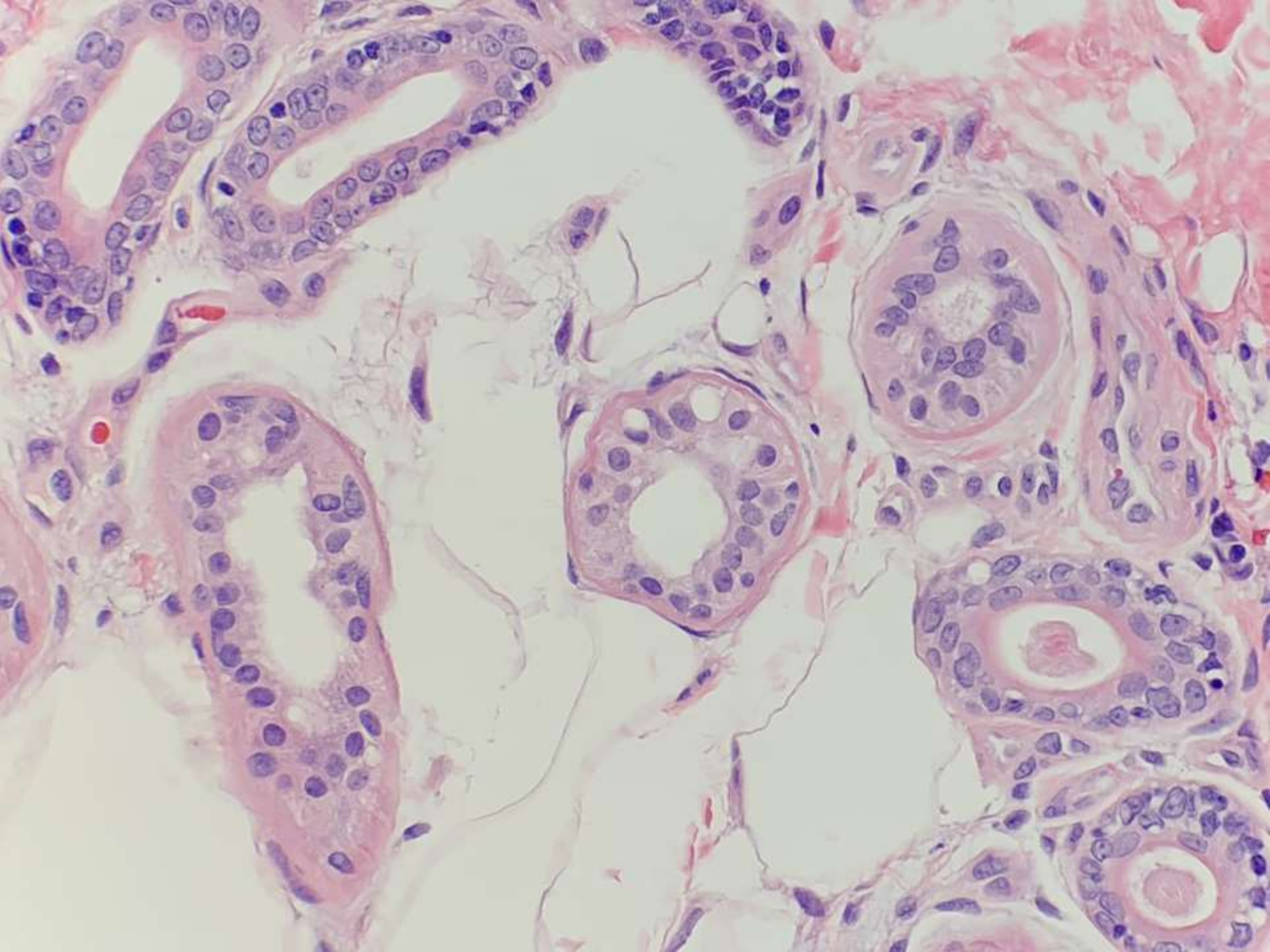

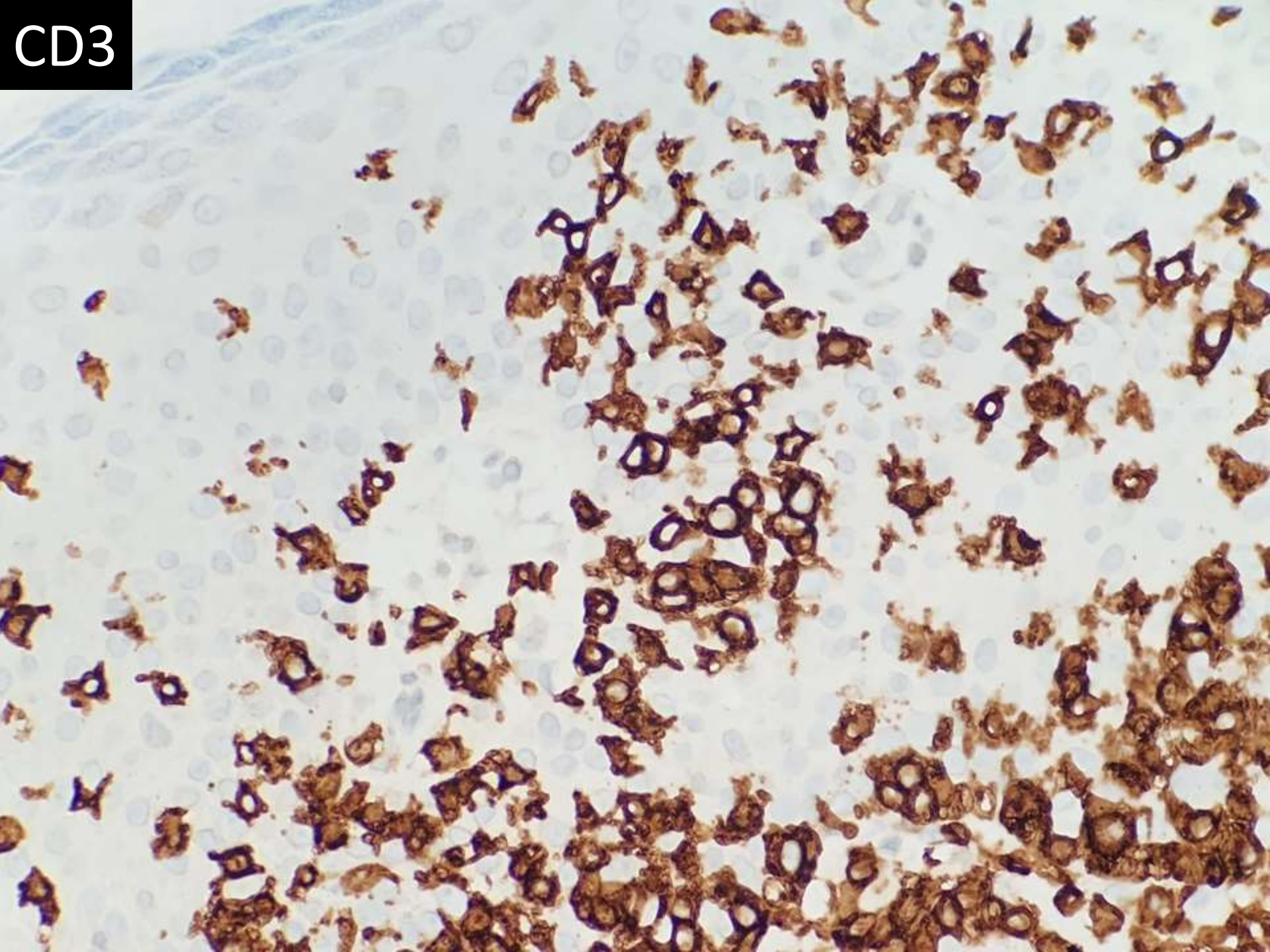




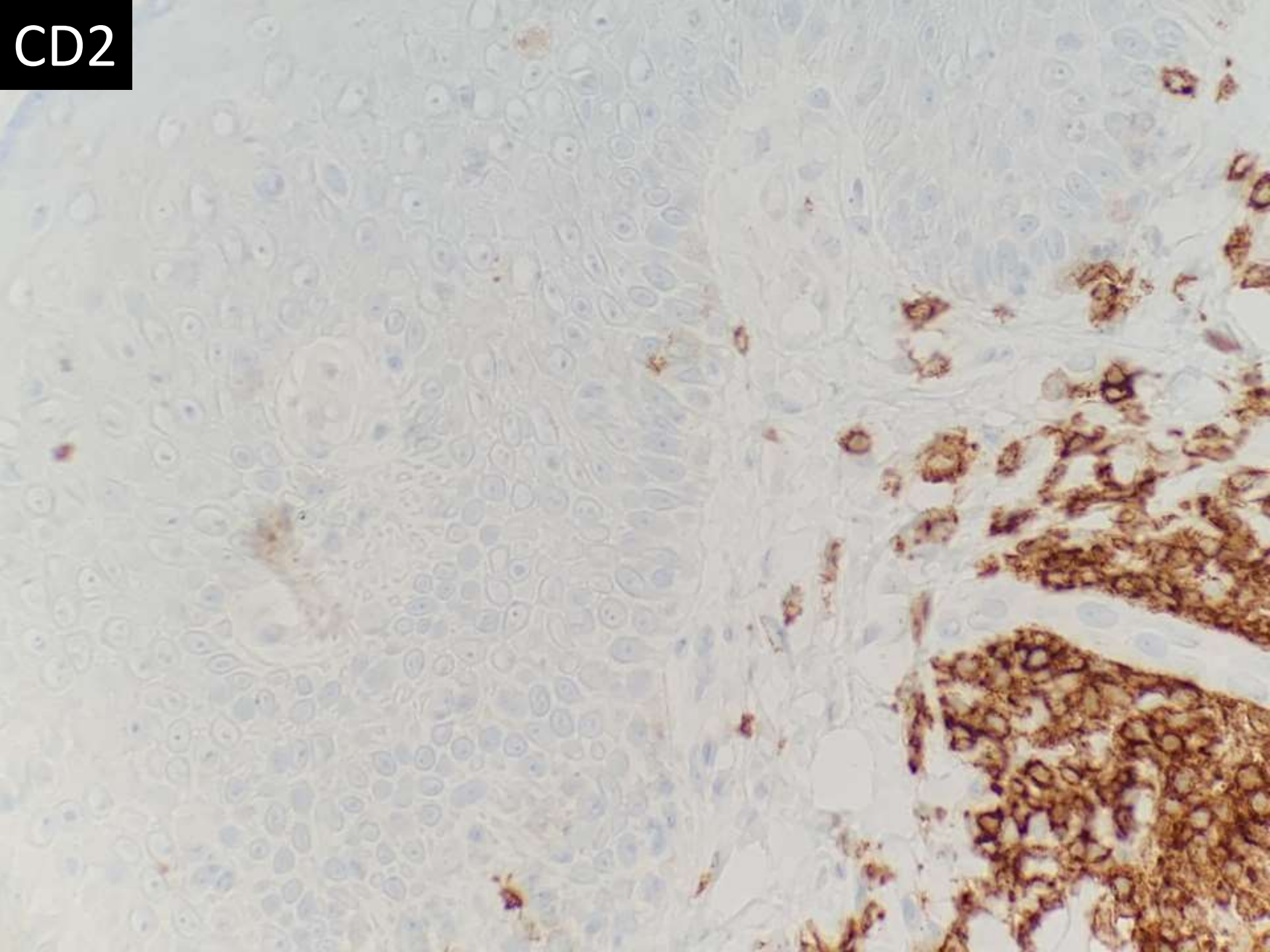




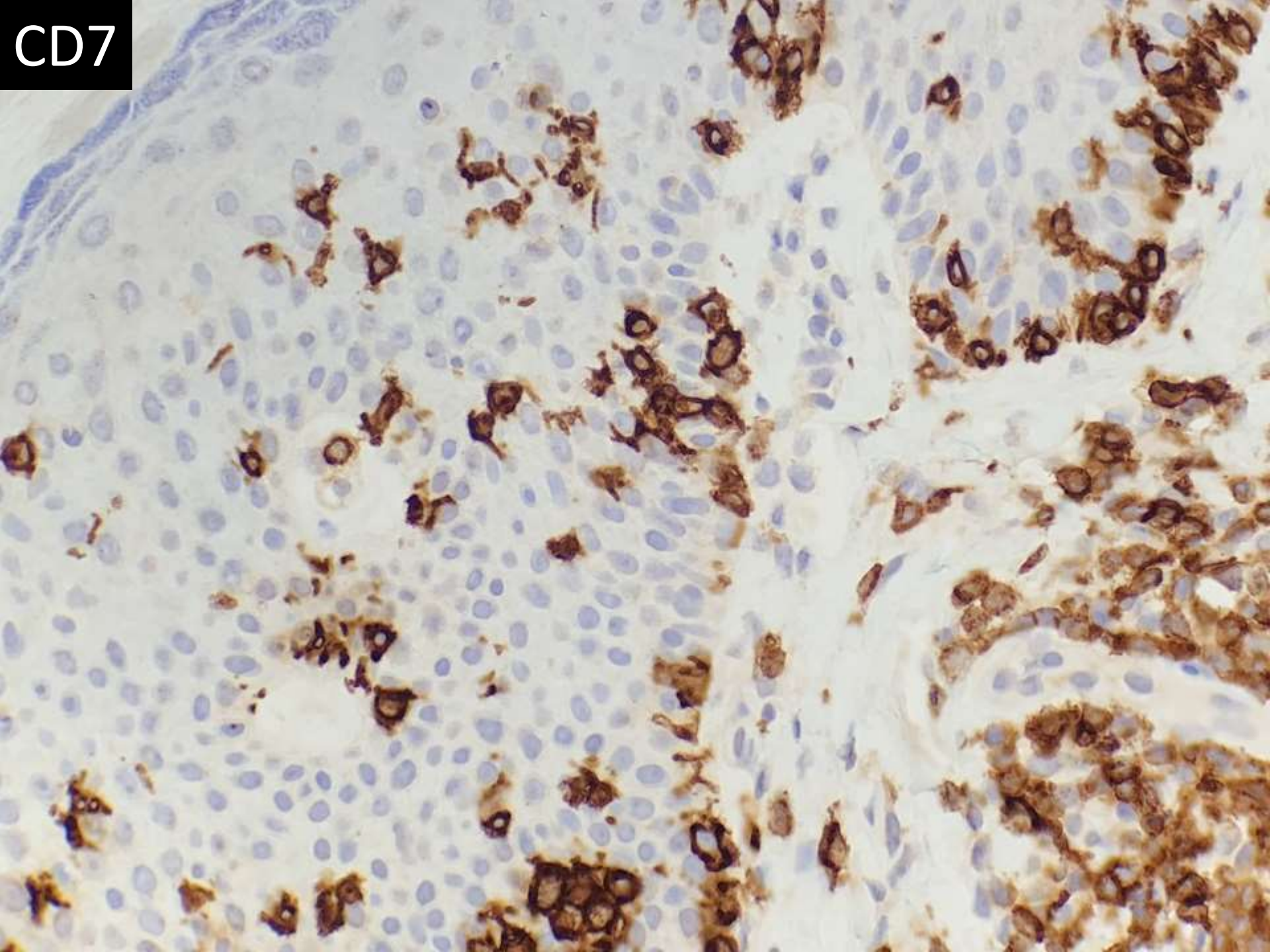


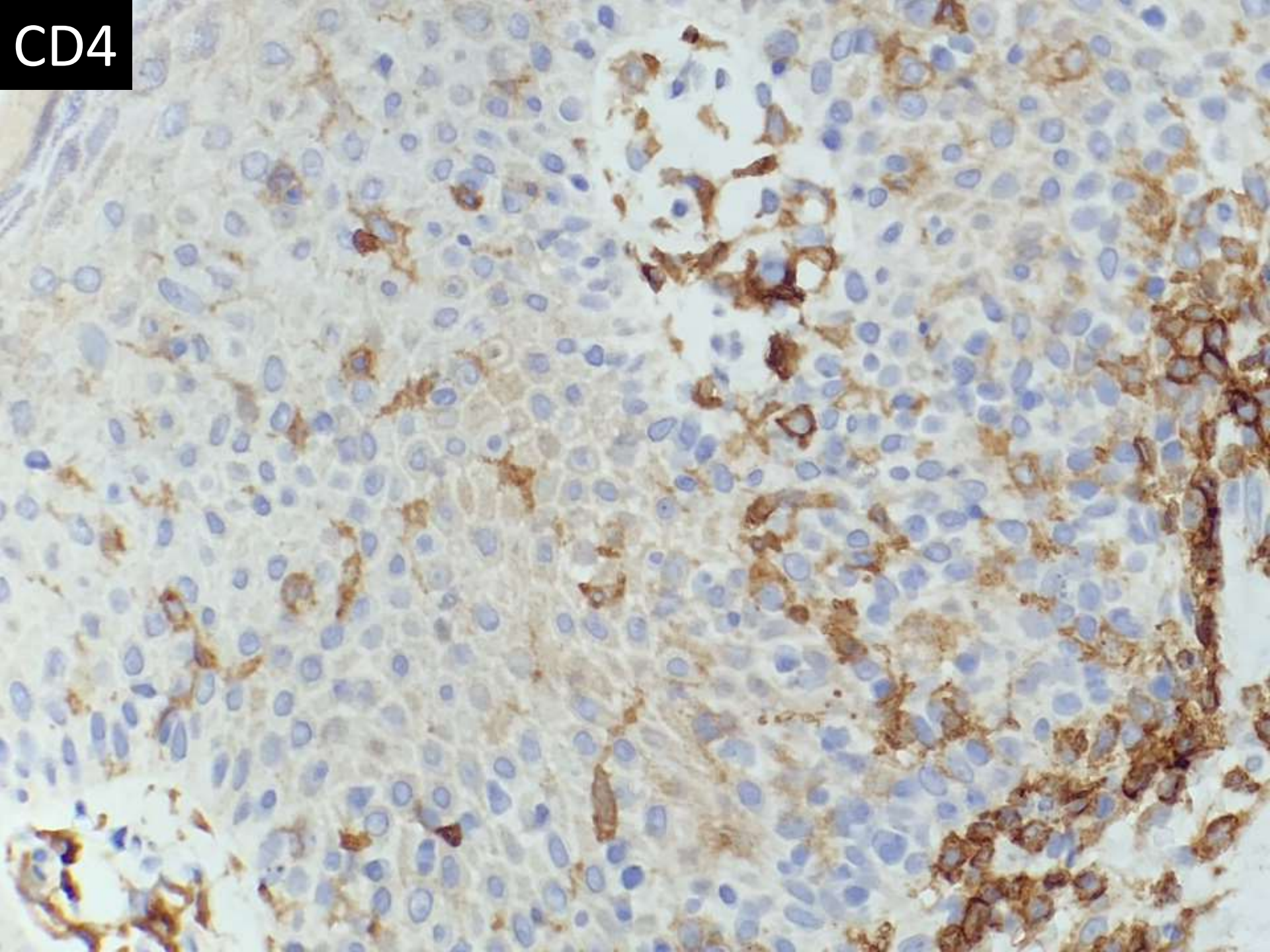


CD3

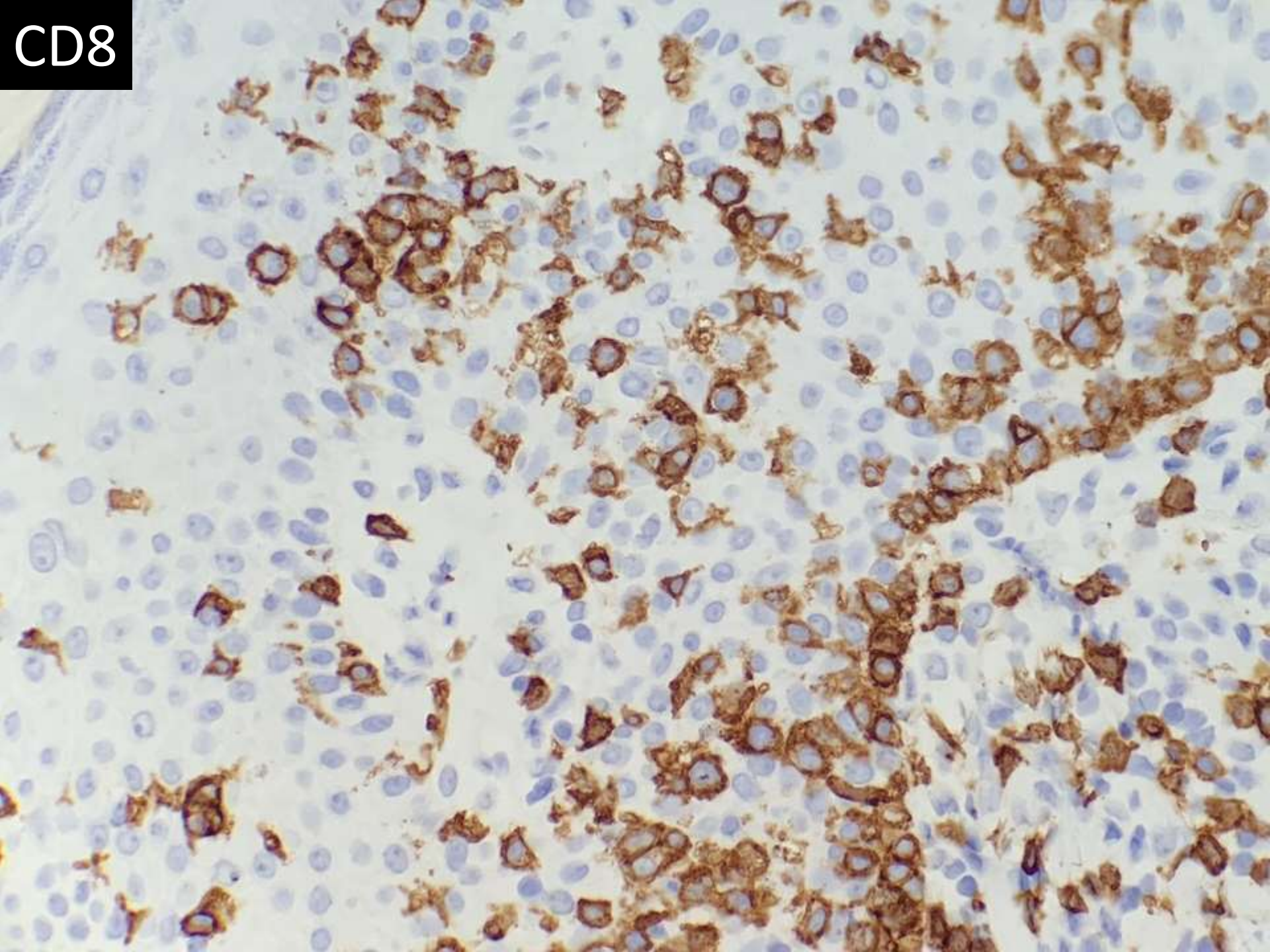


CD2



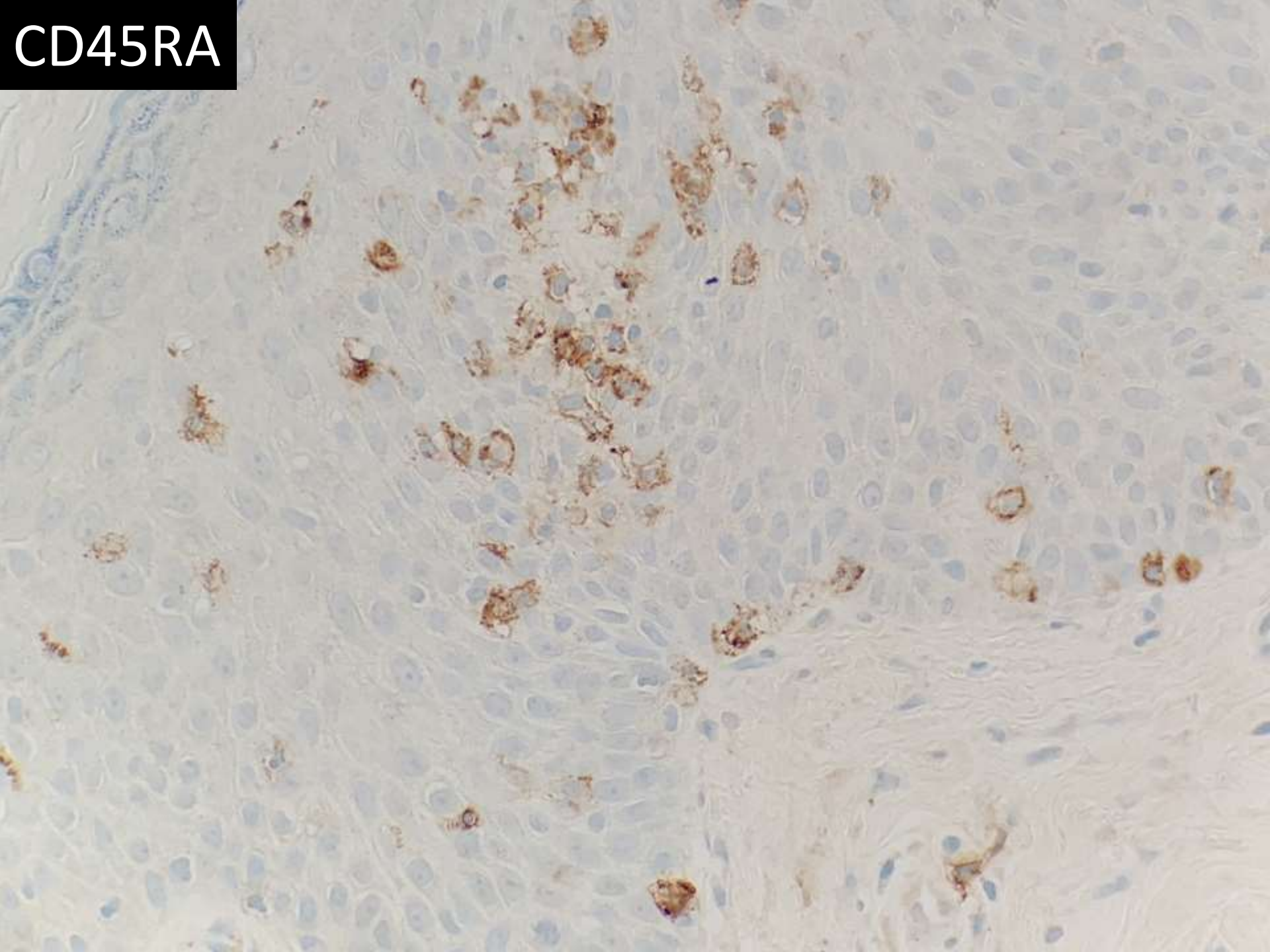


CD4

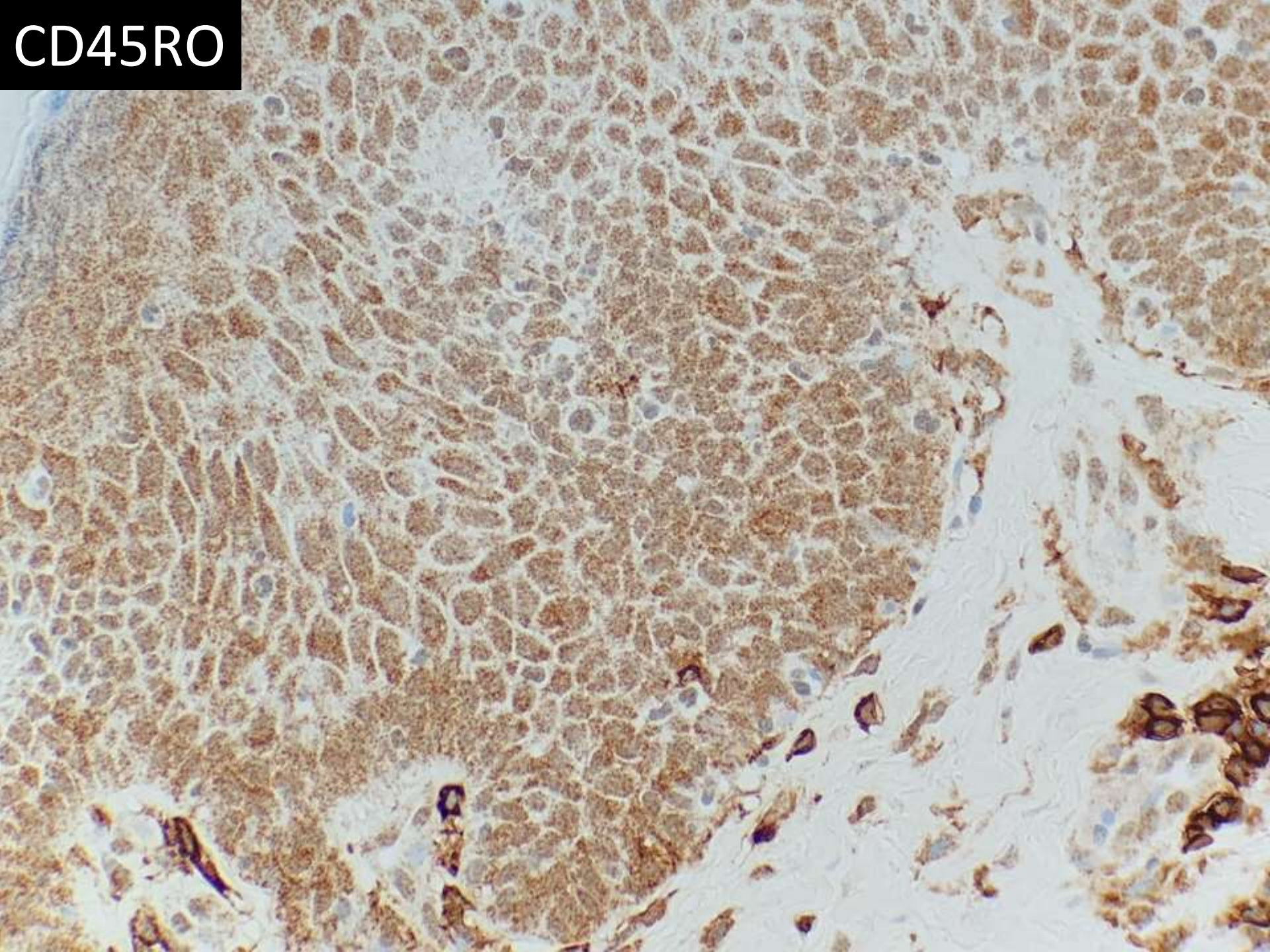


CD8

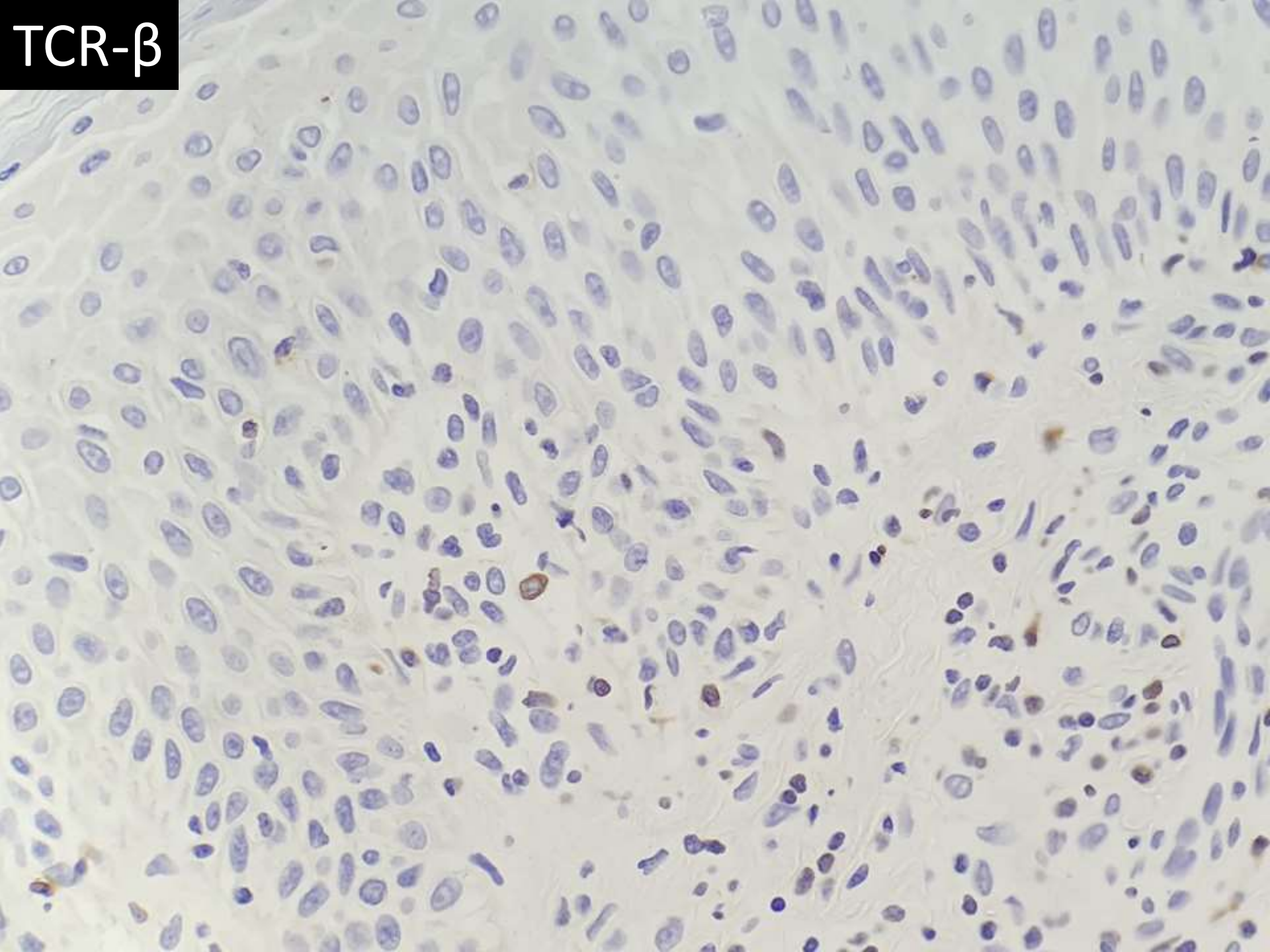
CD45RA



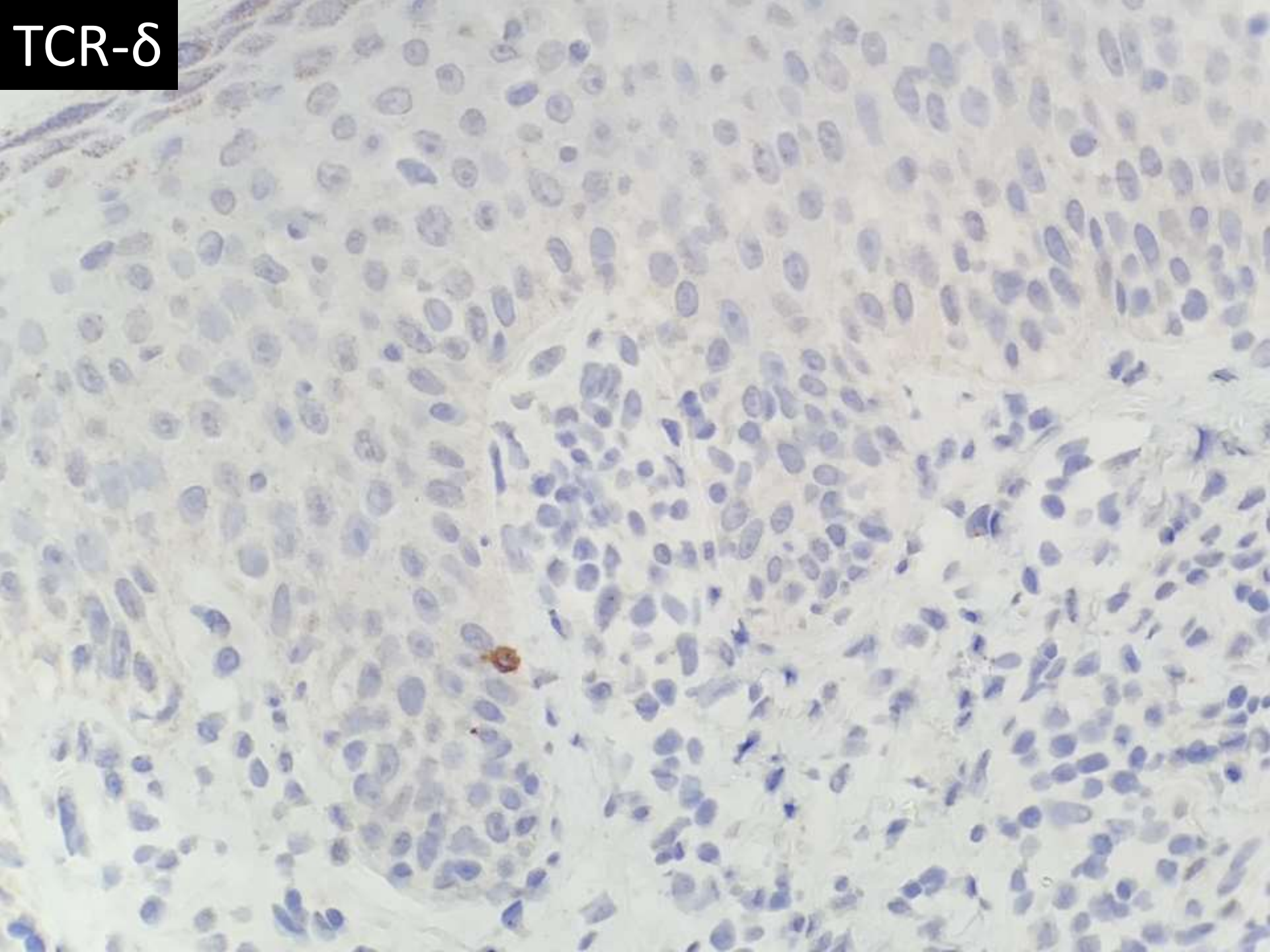
CD45RO



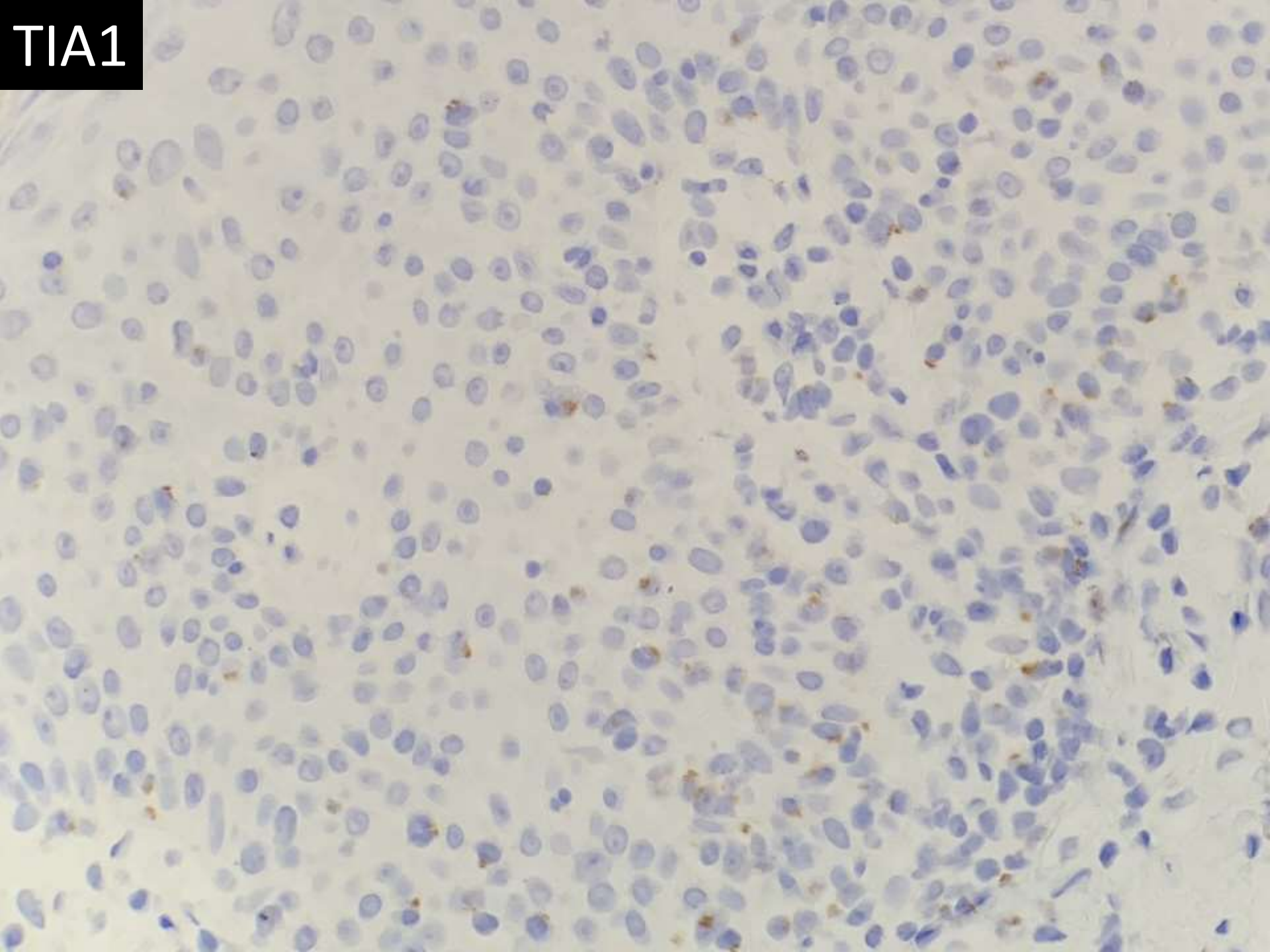
TCR- β



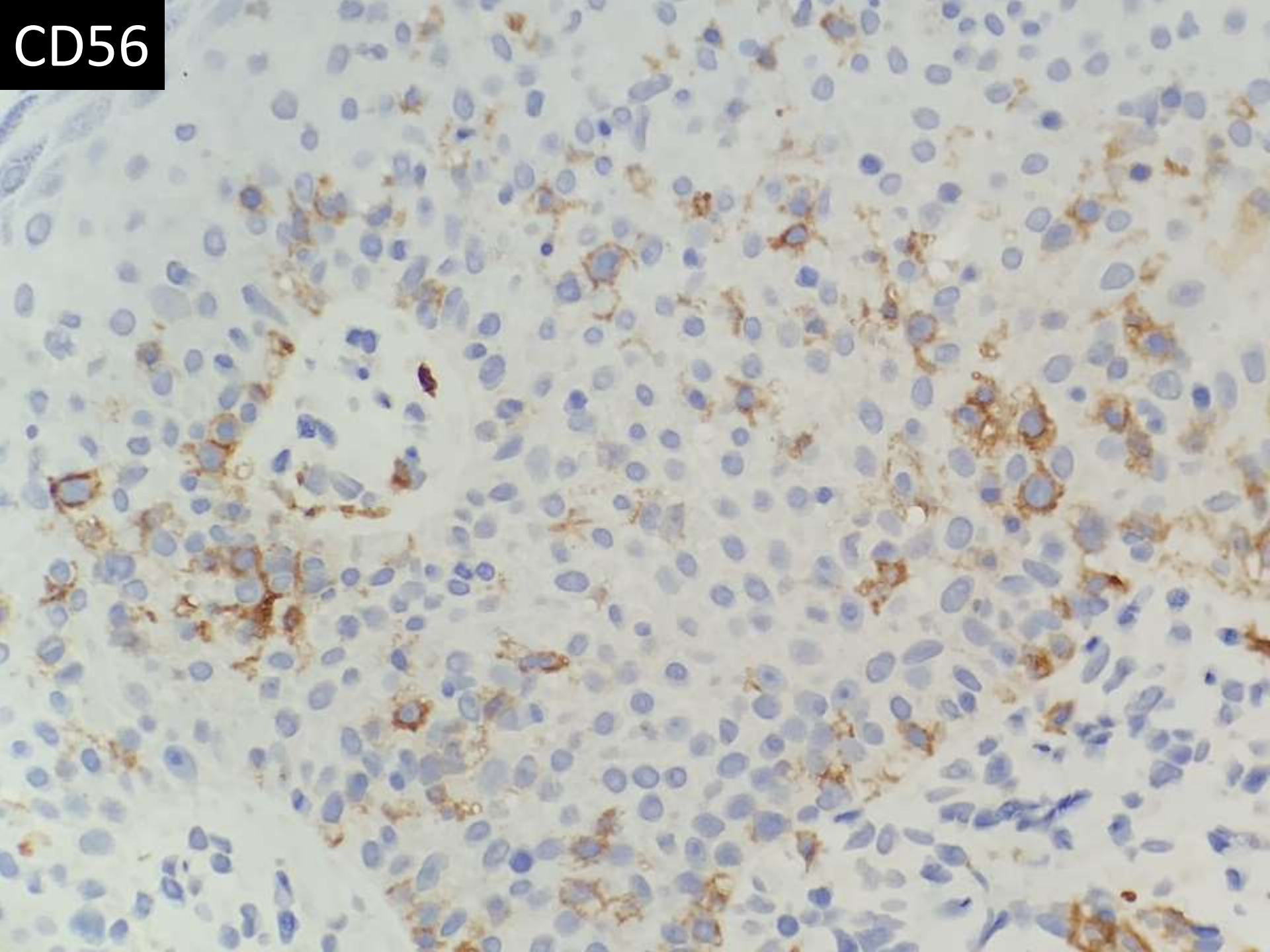
TCR- δ



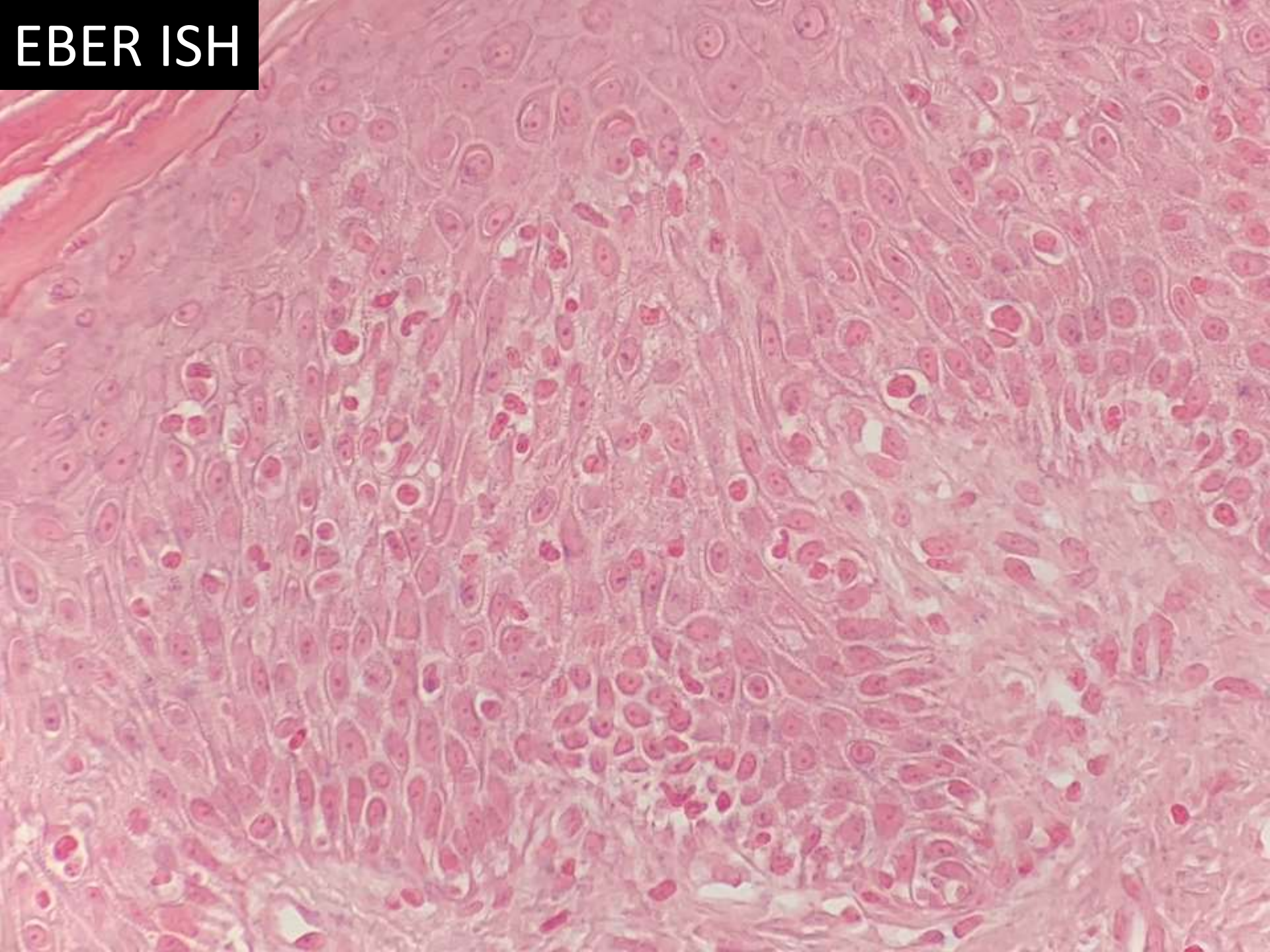
TIA1



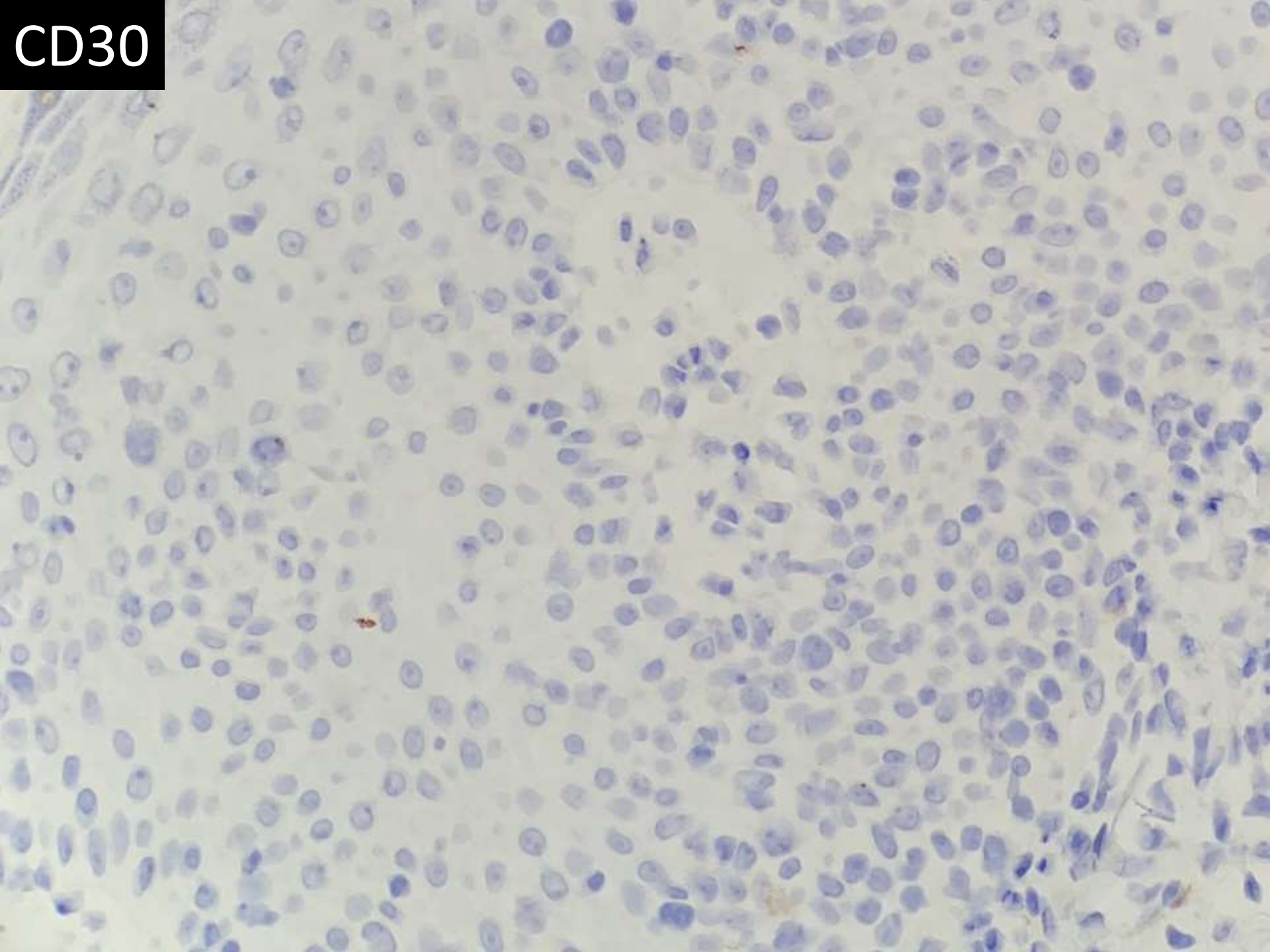
CD56

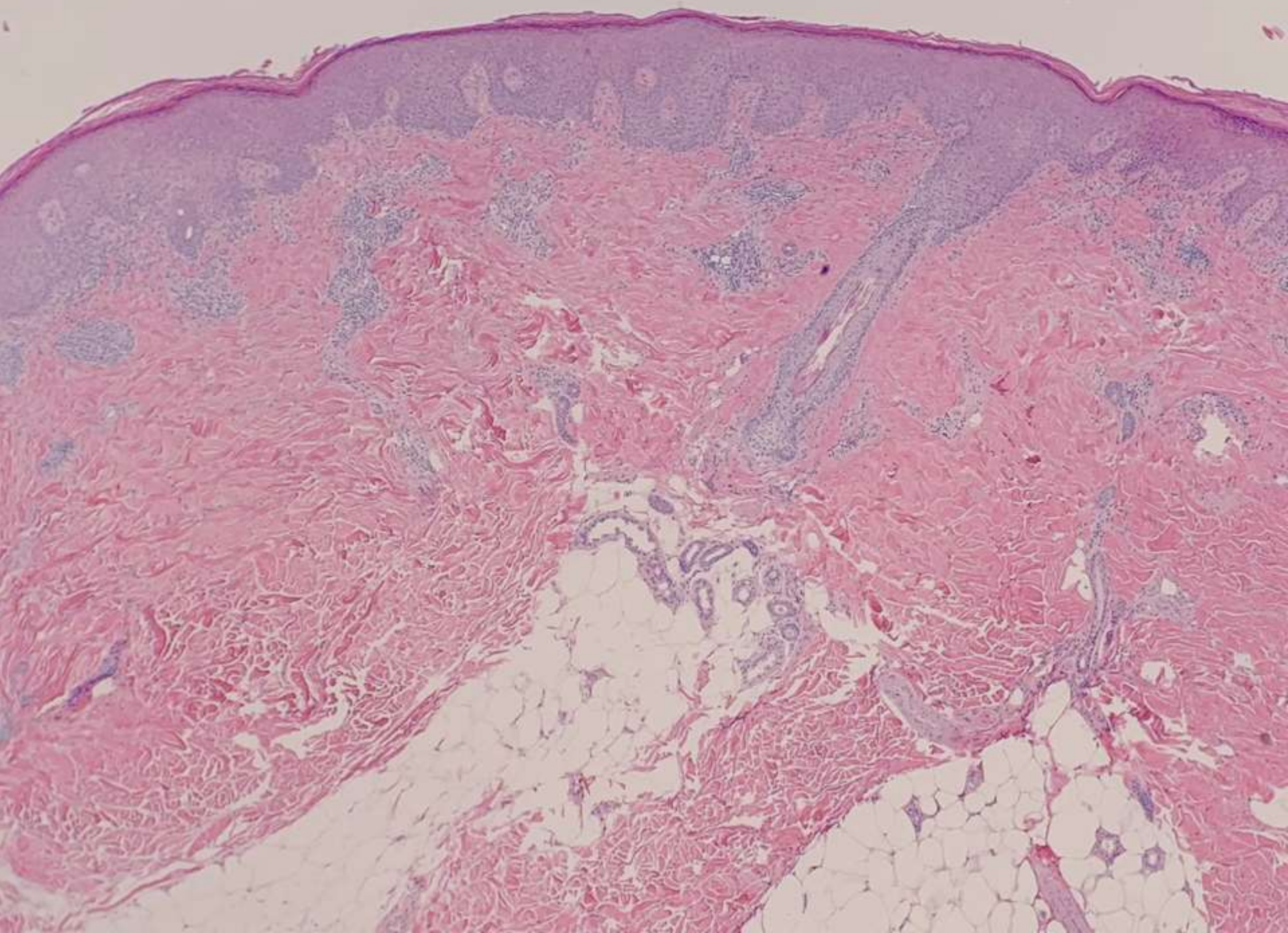


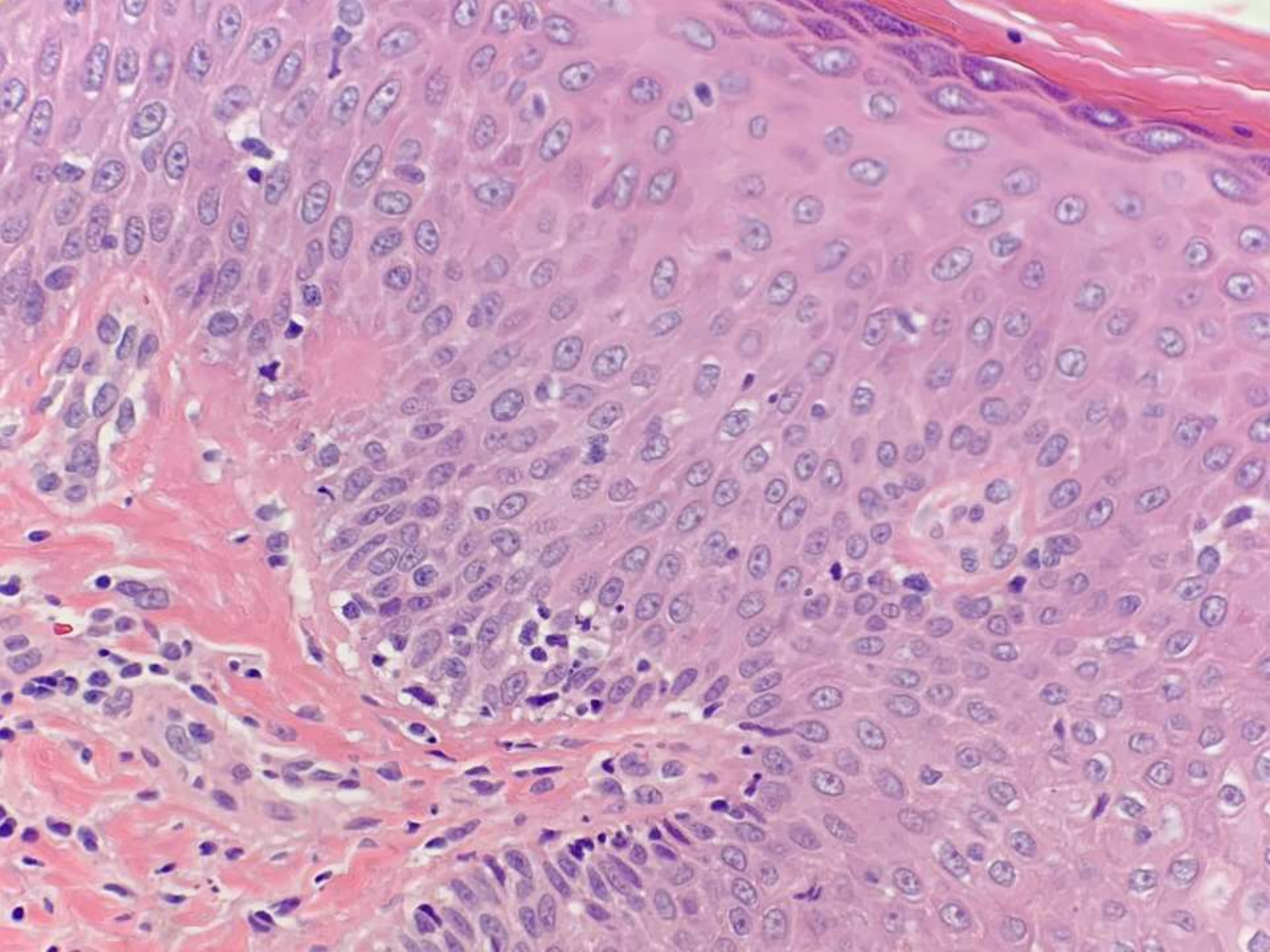
EBER ISH

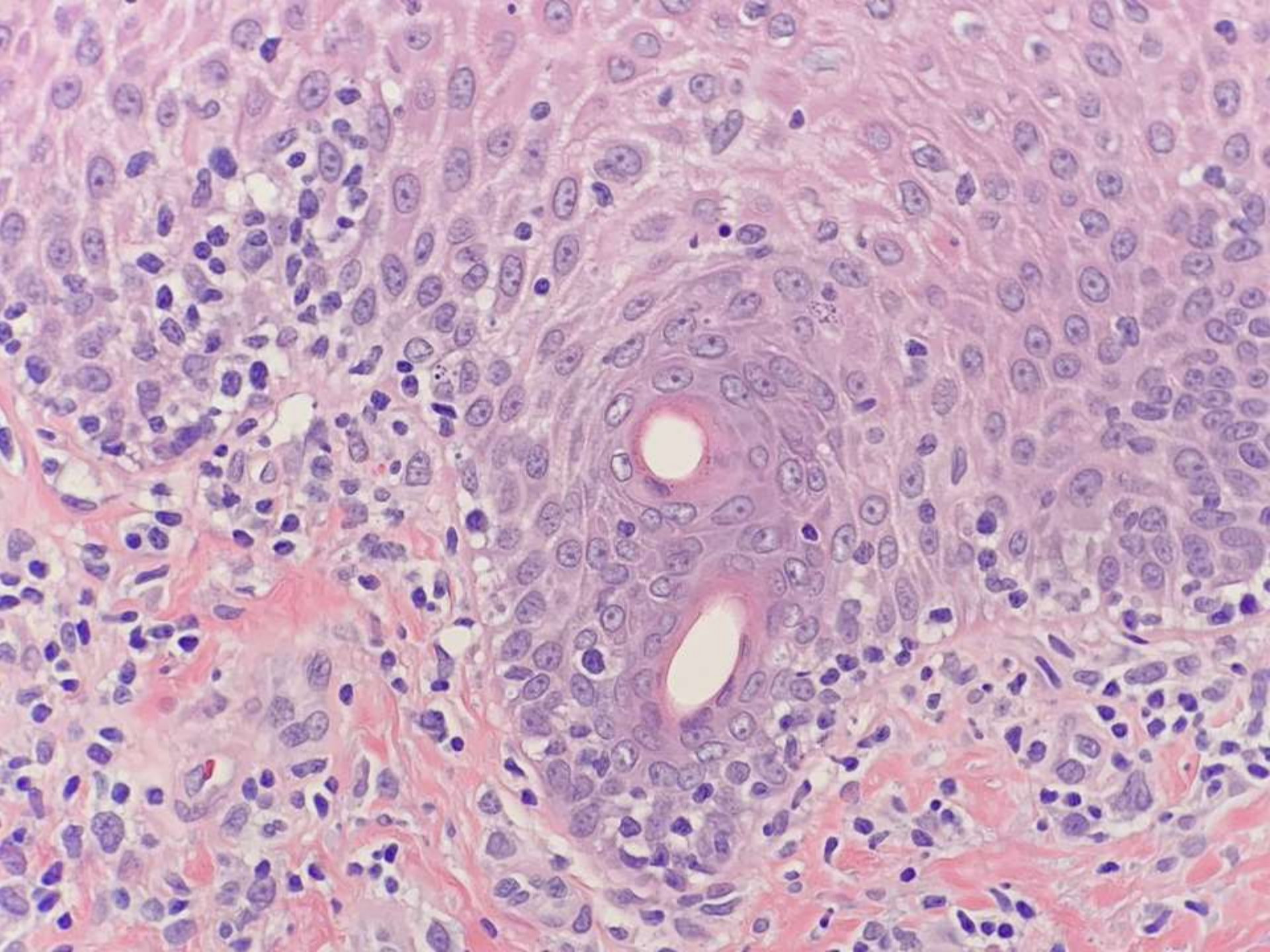


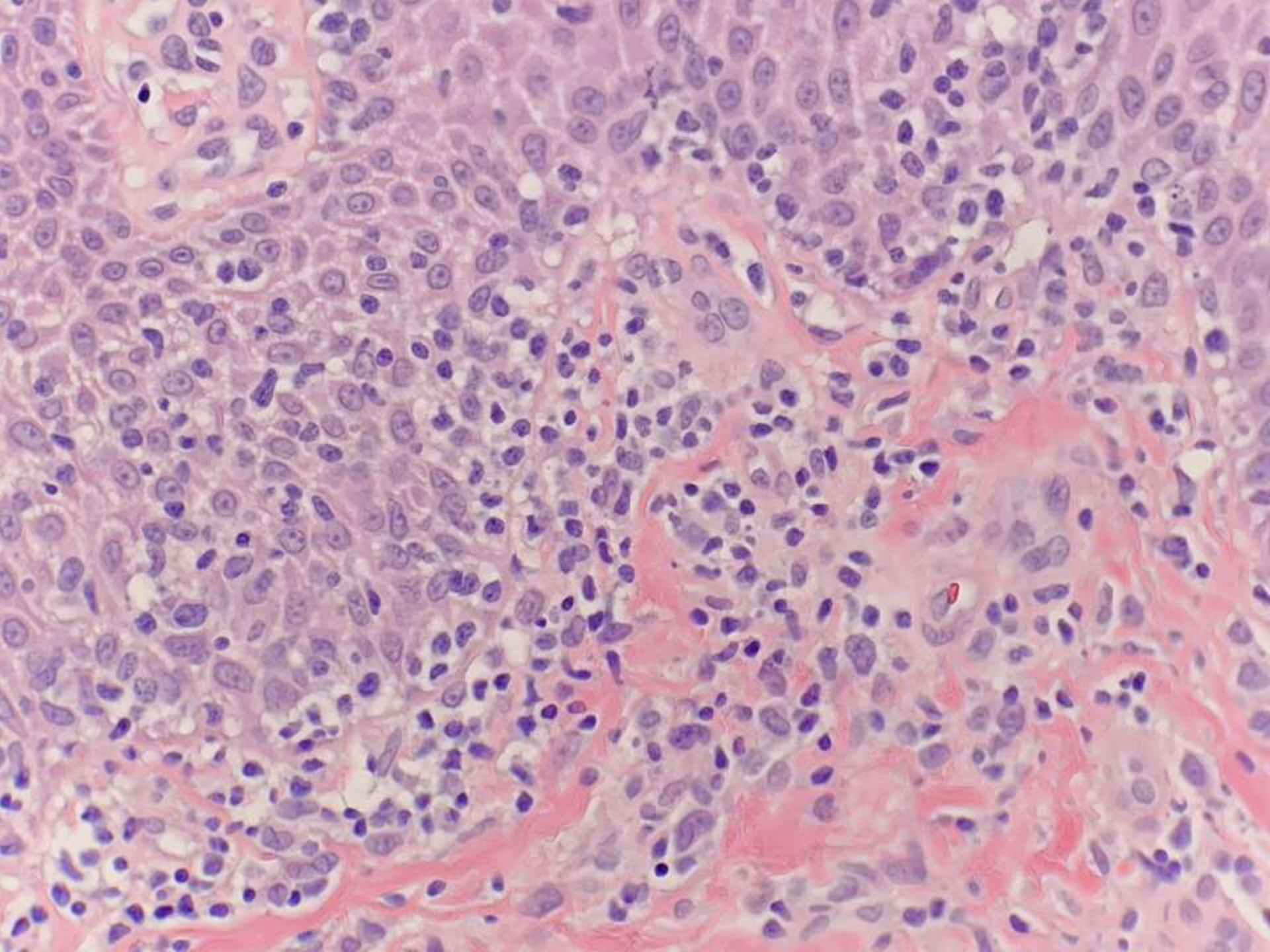
CD30

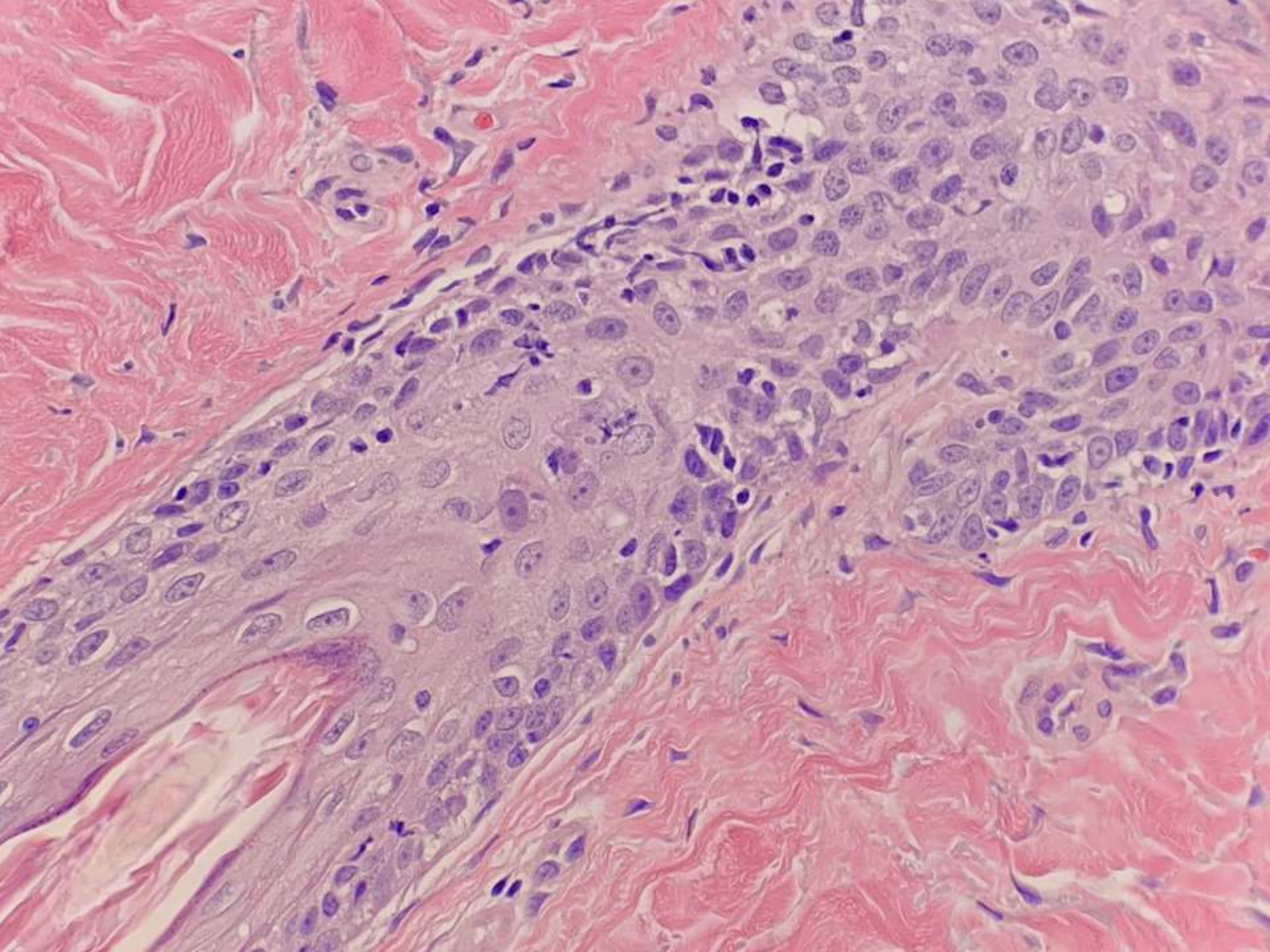




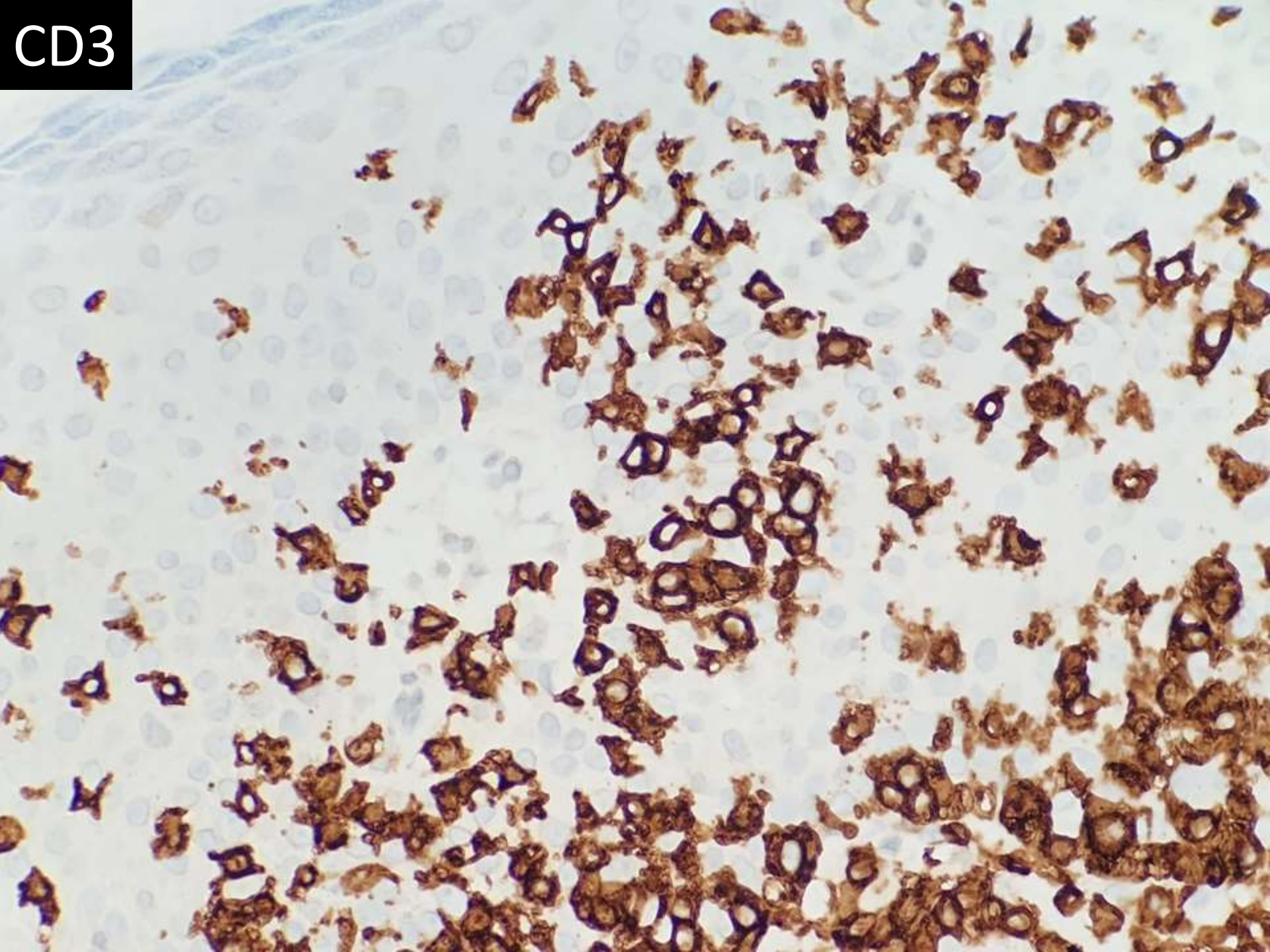




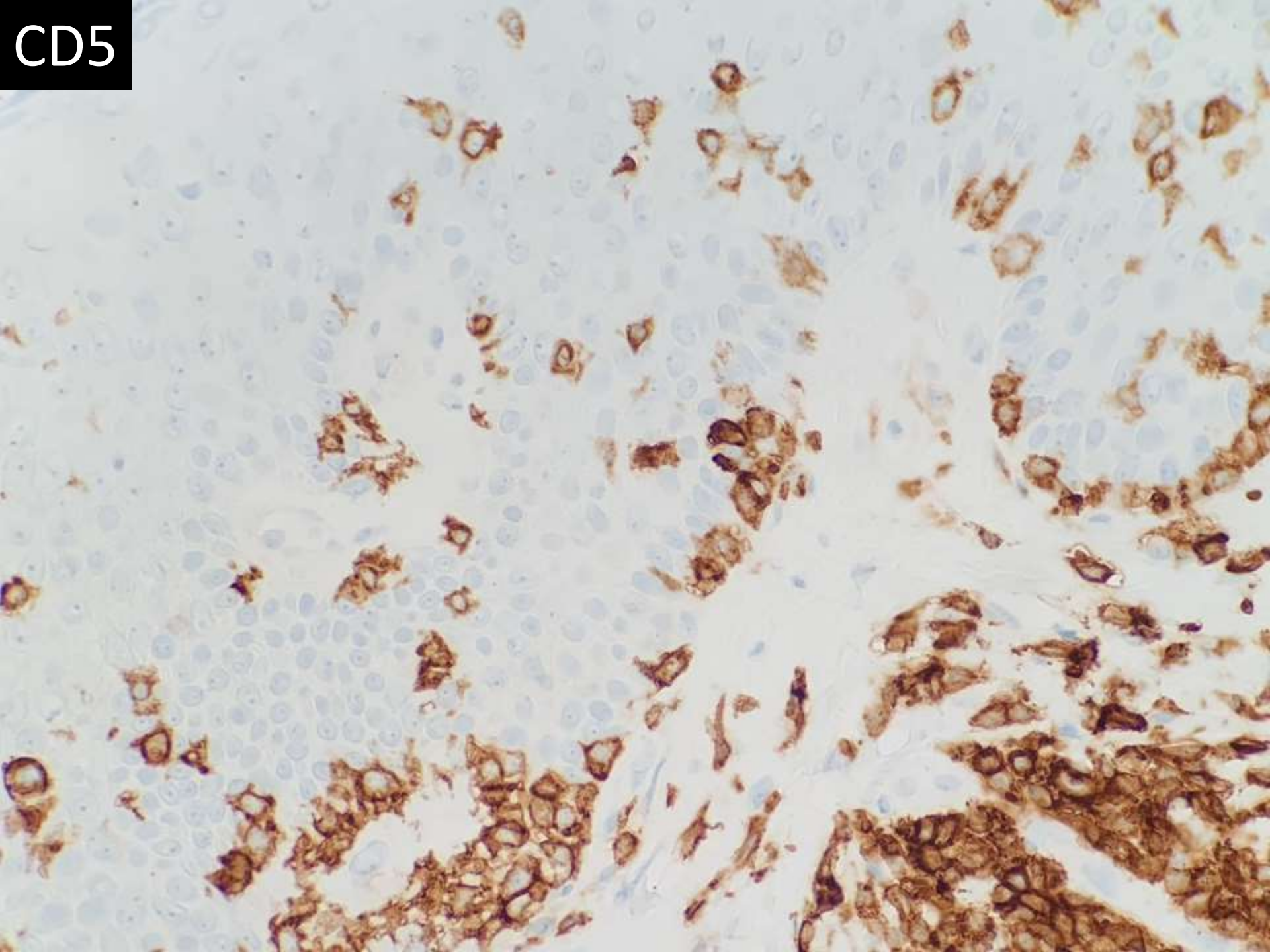




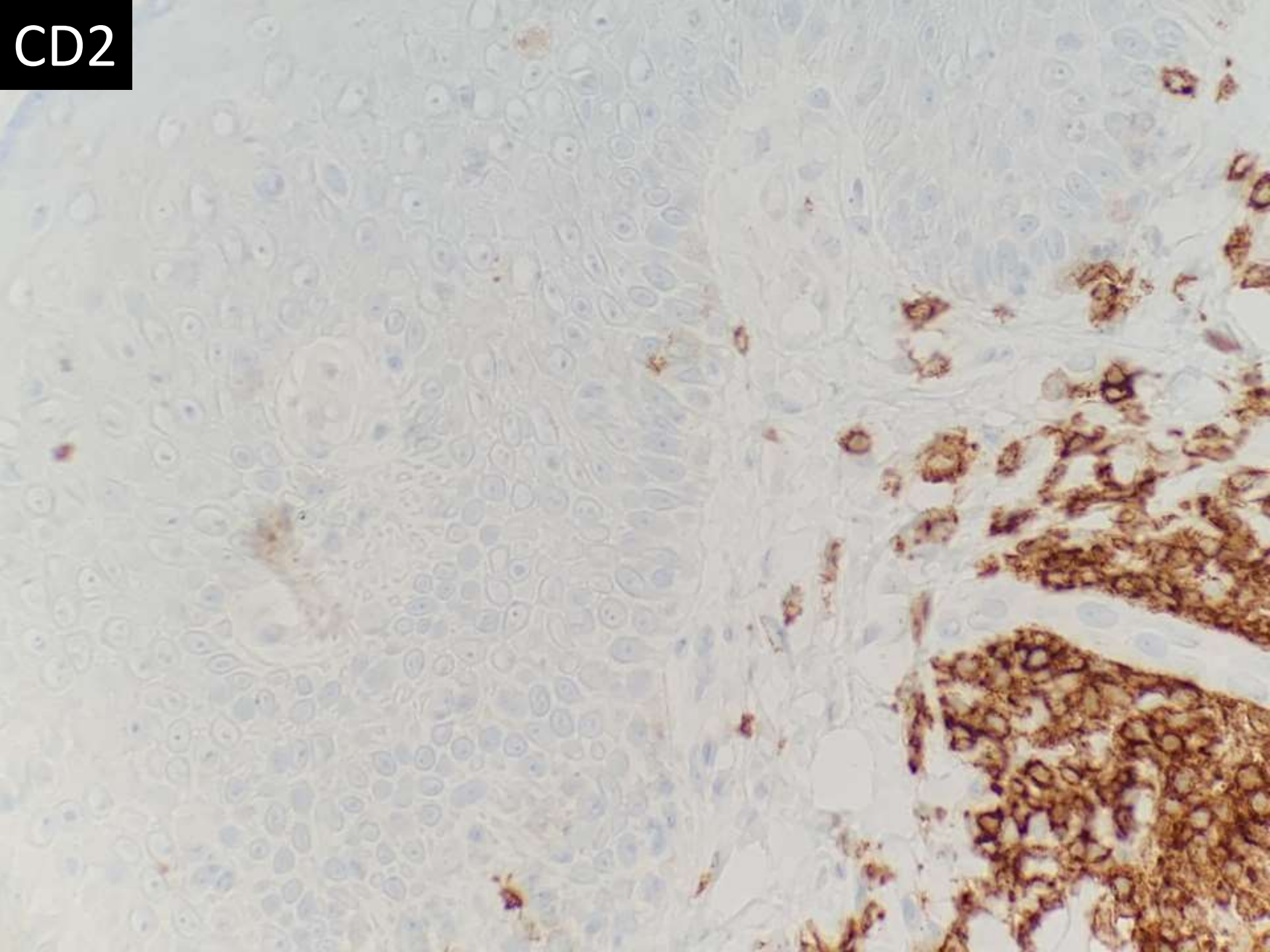




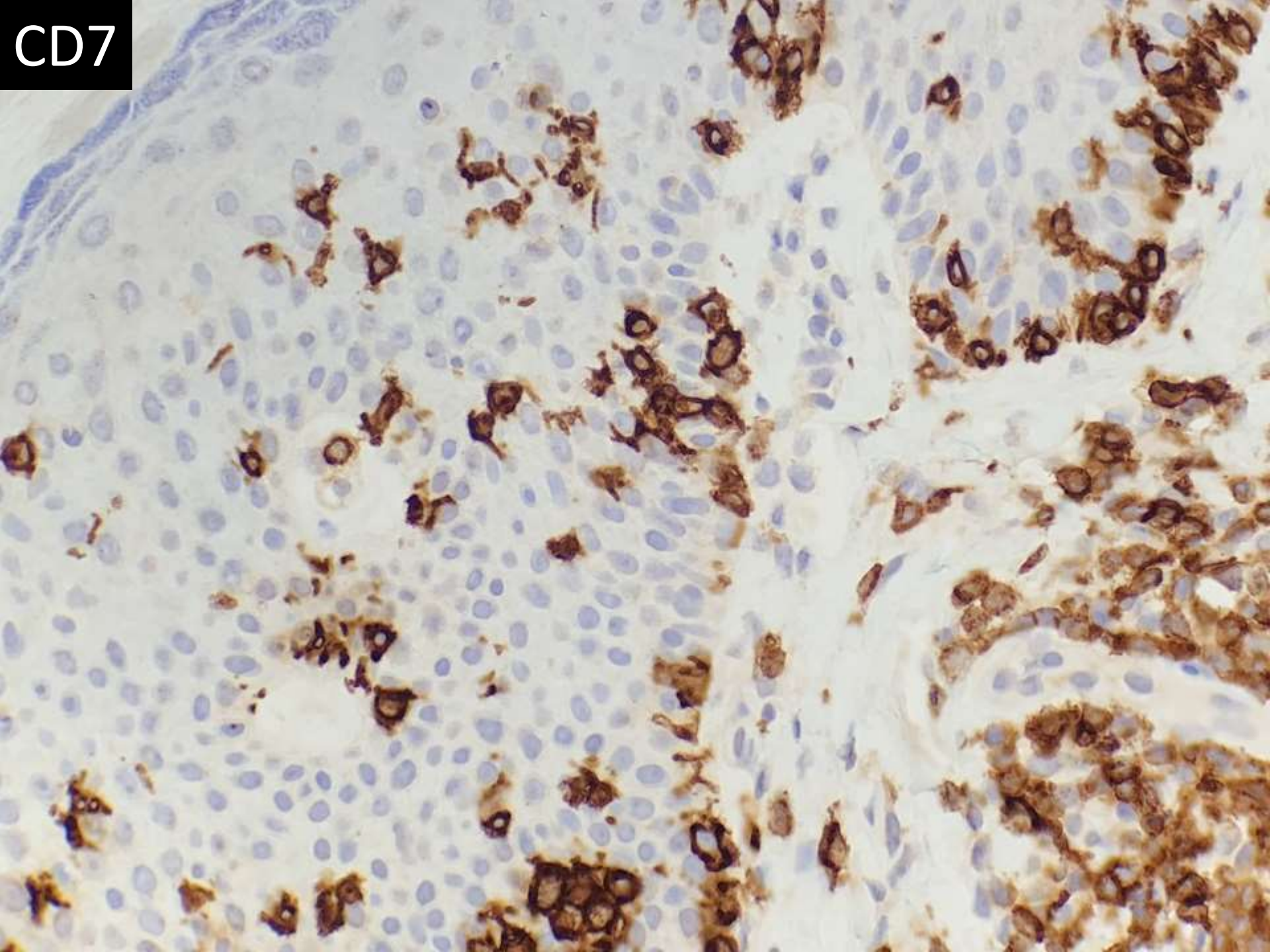
CD3



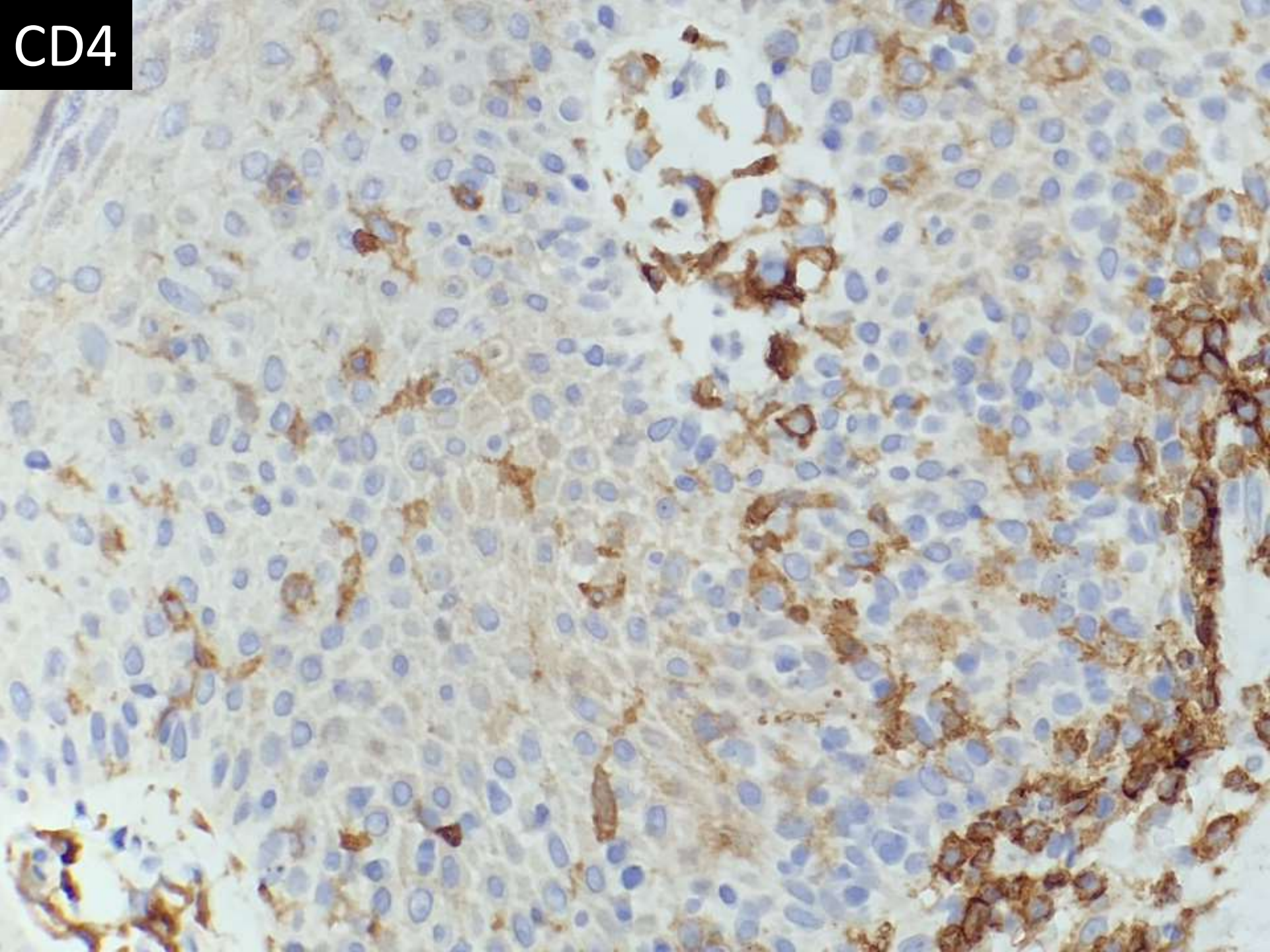
CD5



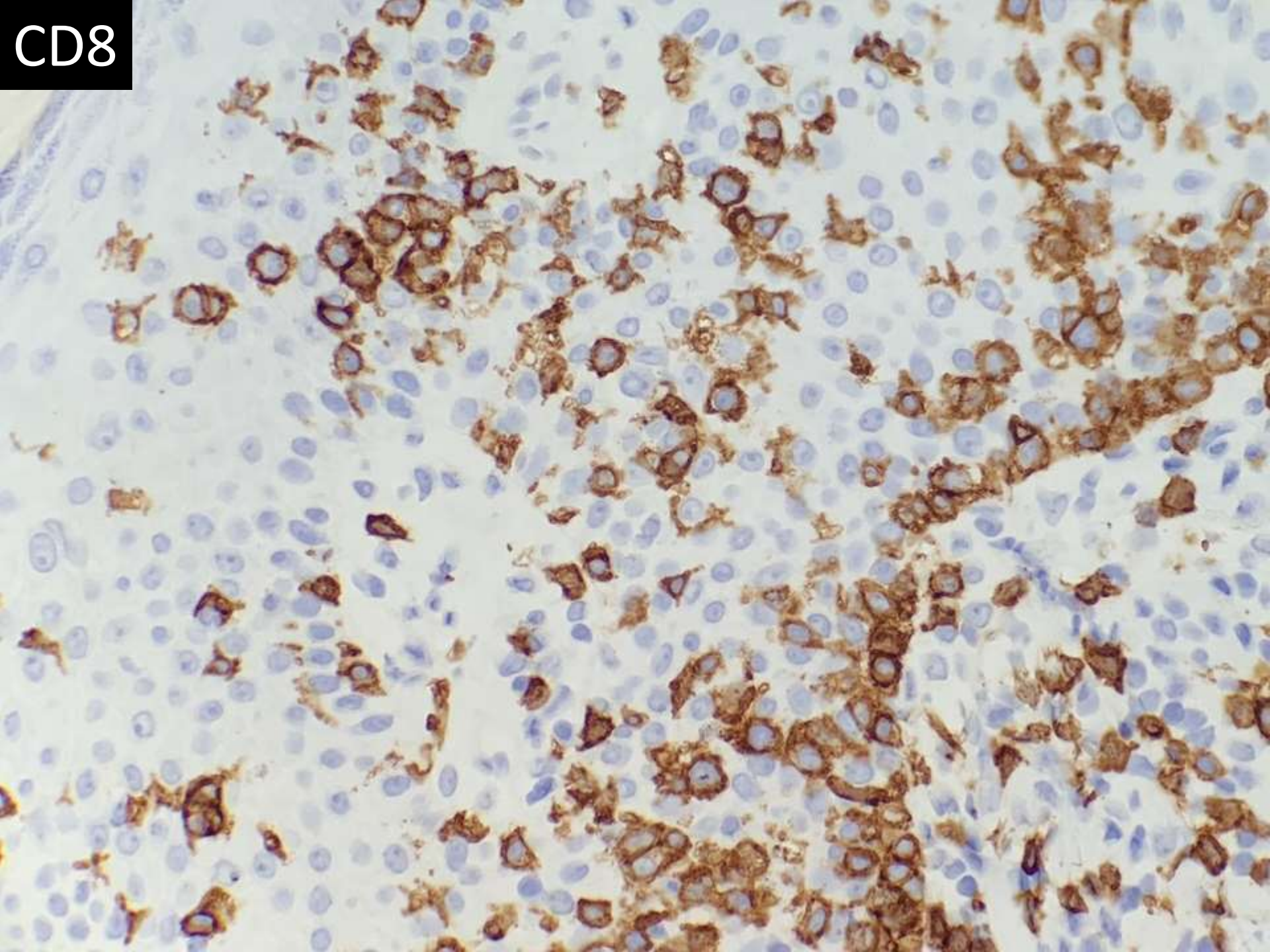
CD2



CD7

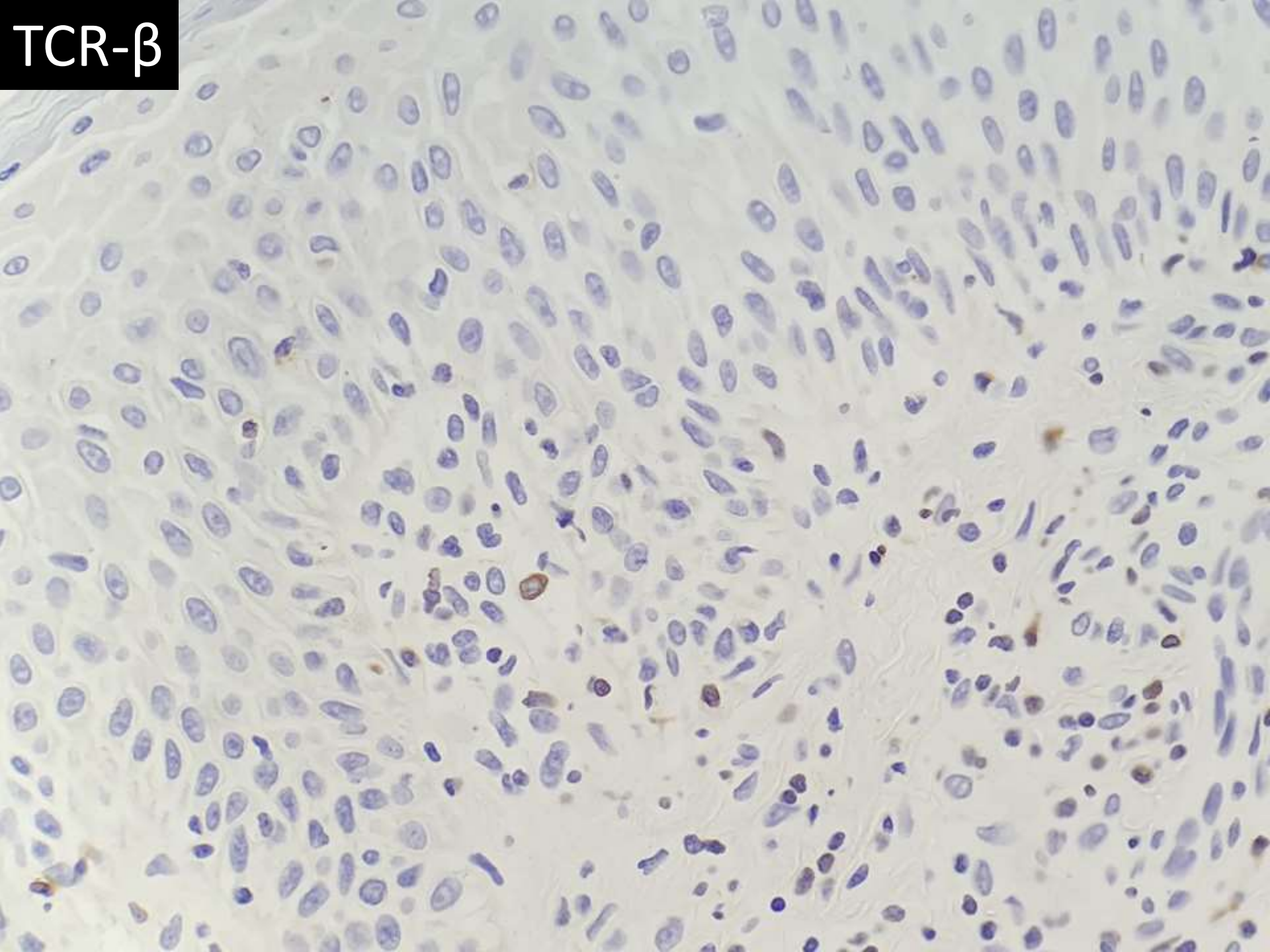


CD4

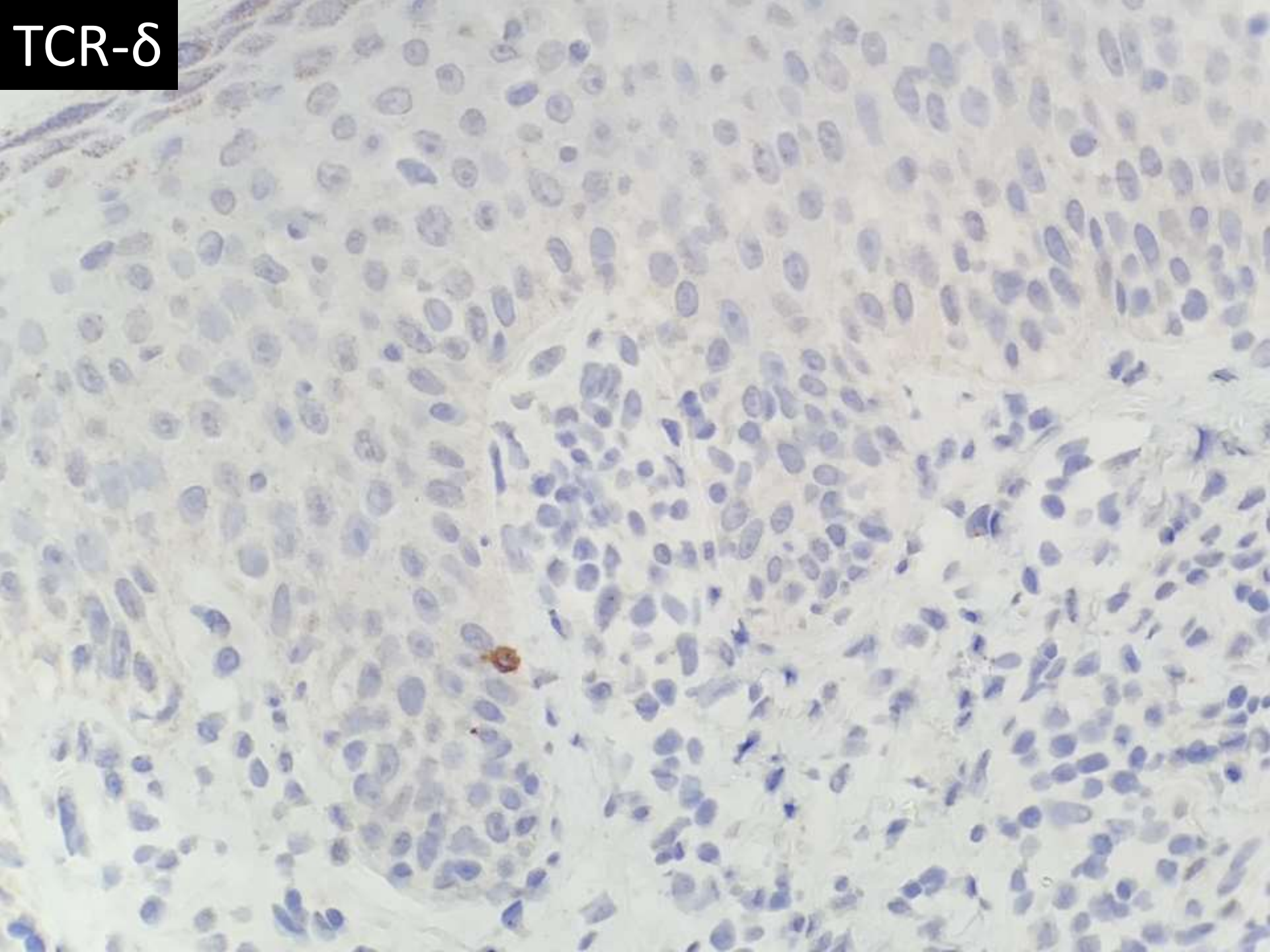


CD8

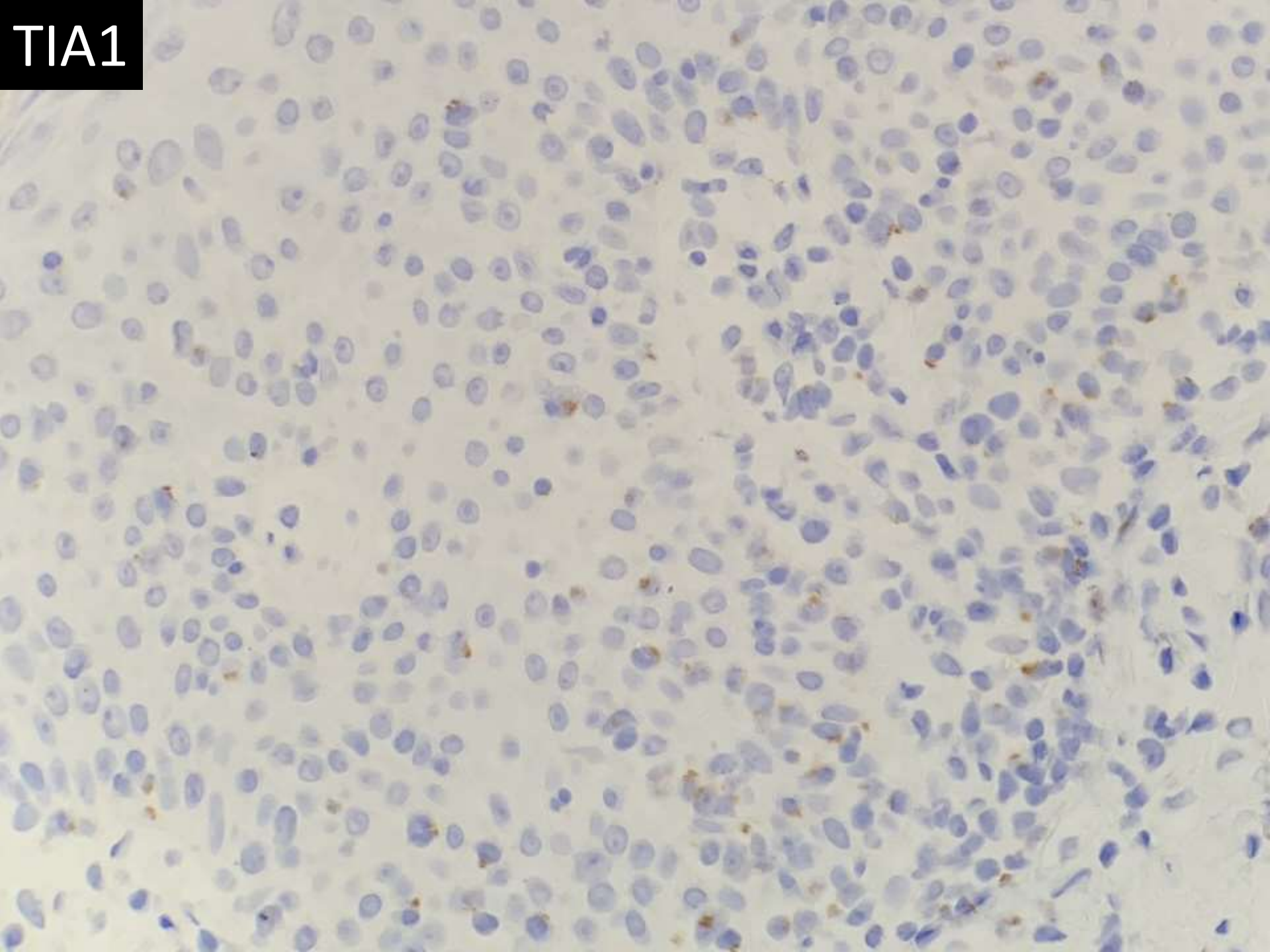
TCR- β



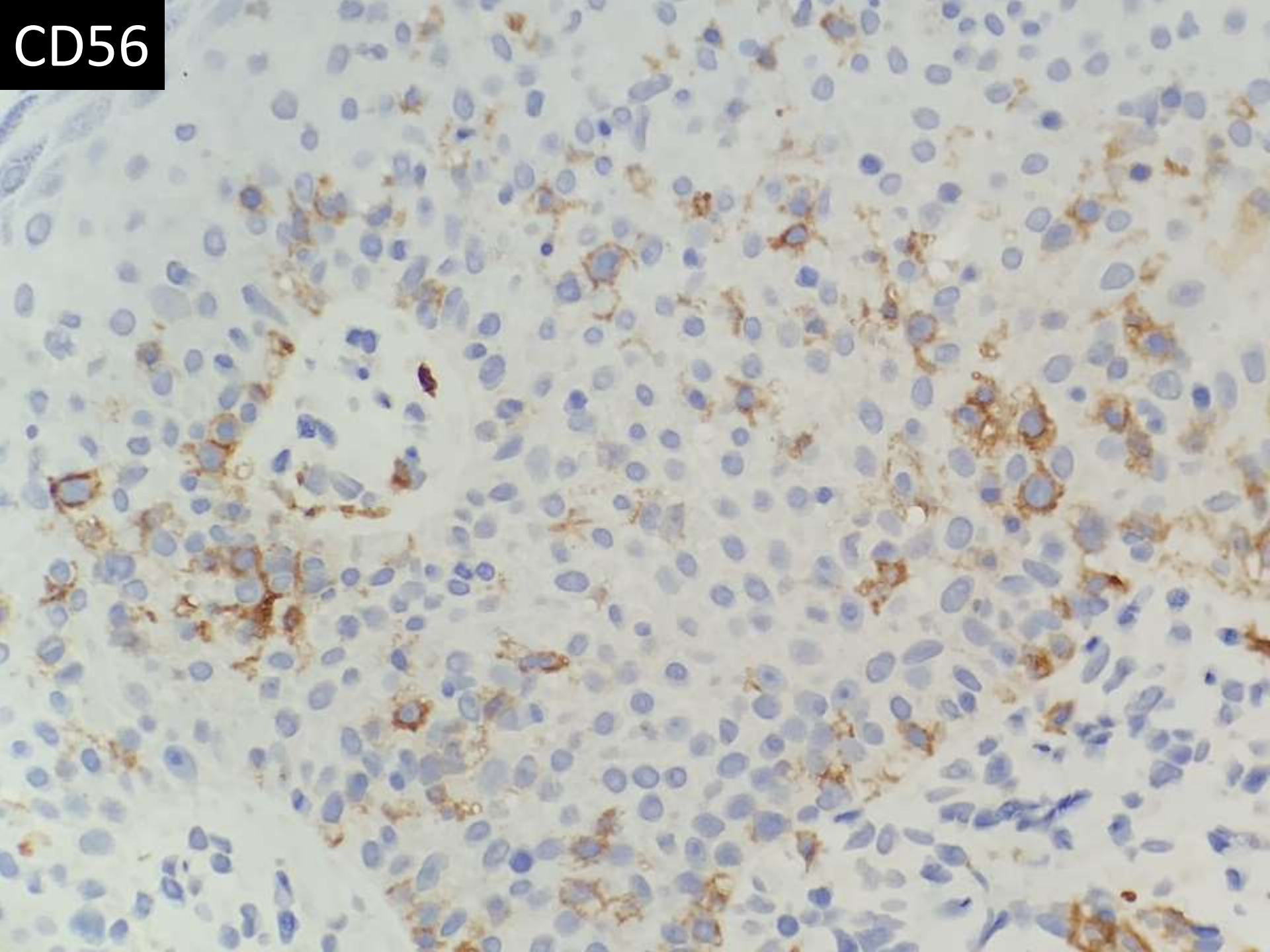
TCR- δ



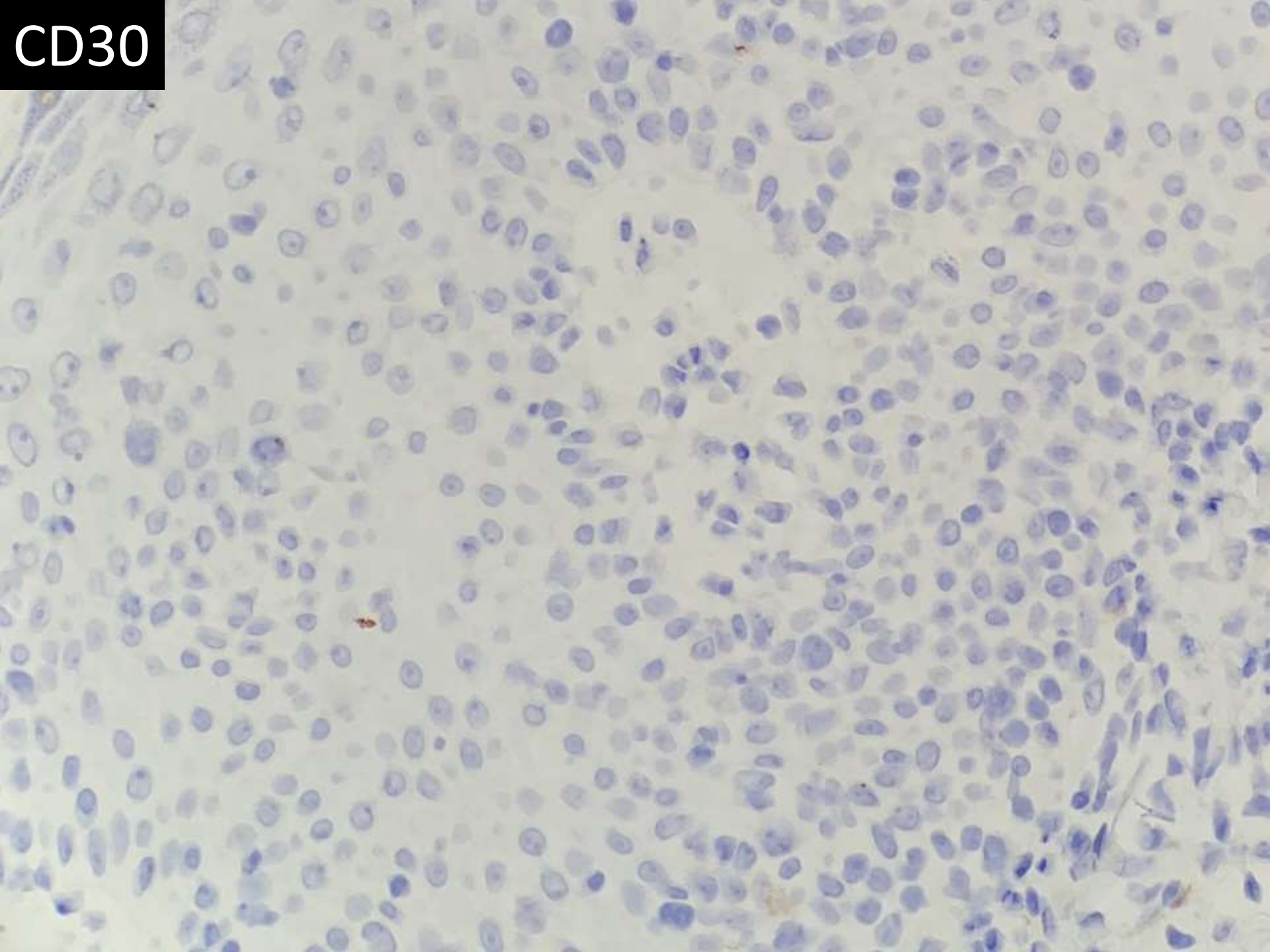
TIA1



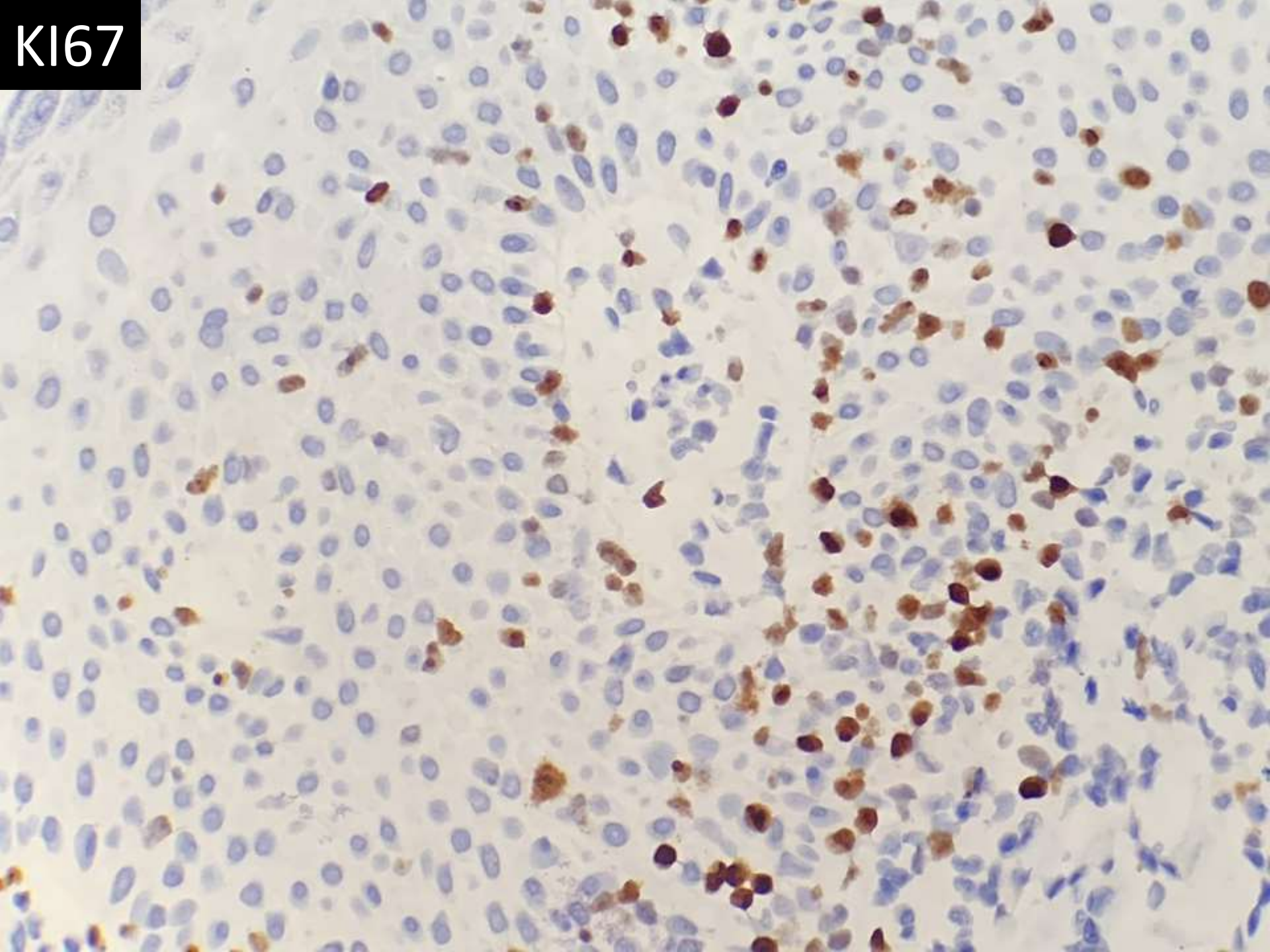
CD56



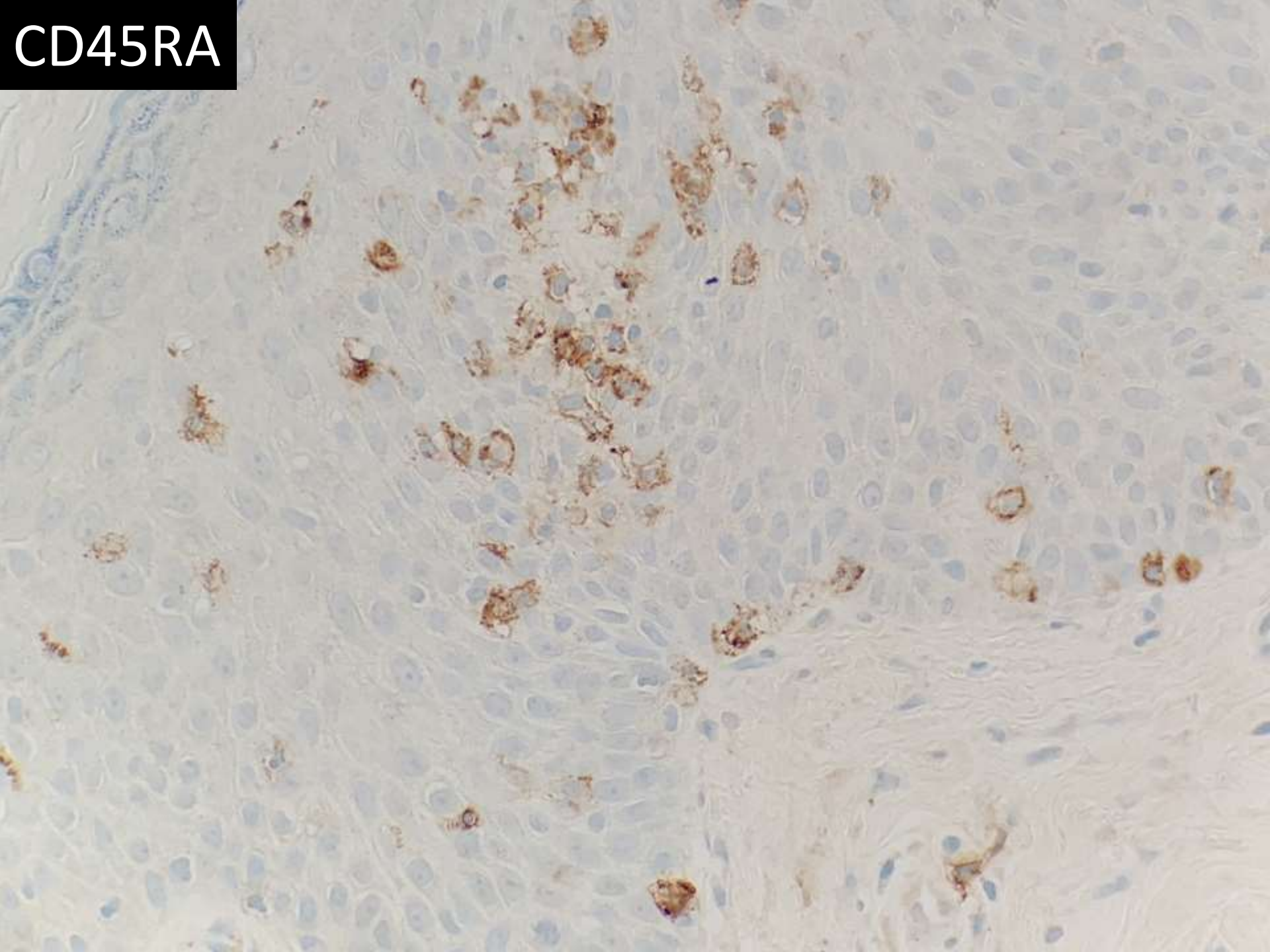
CD30



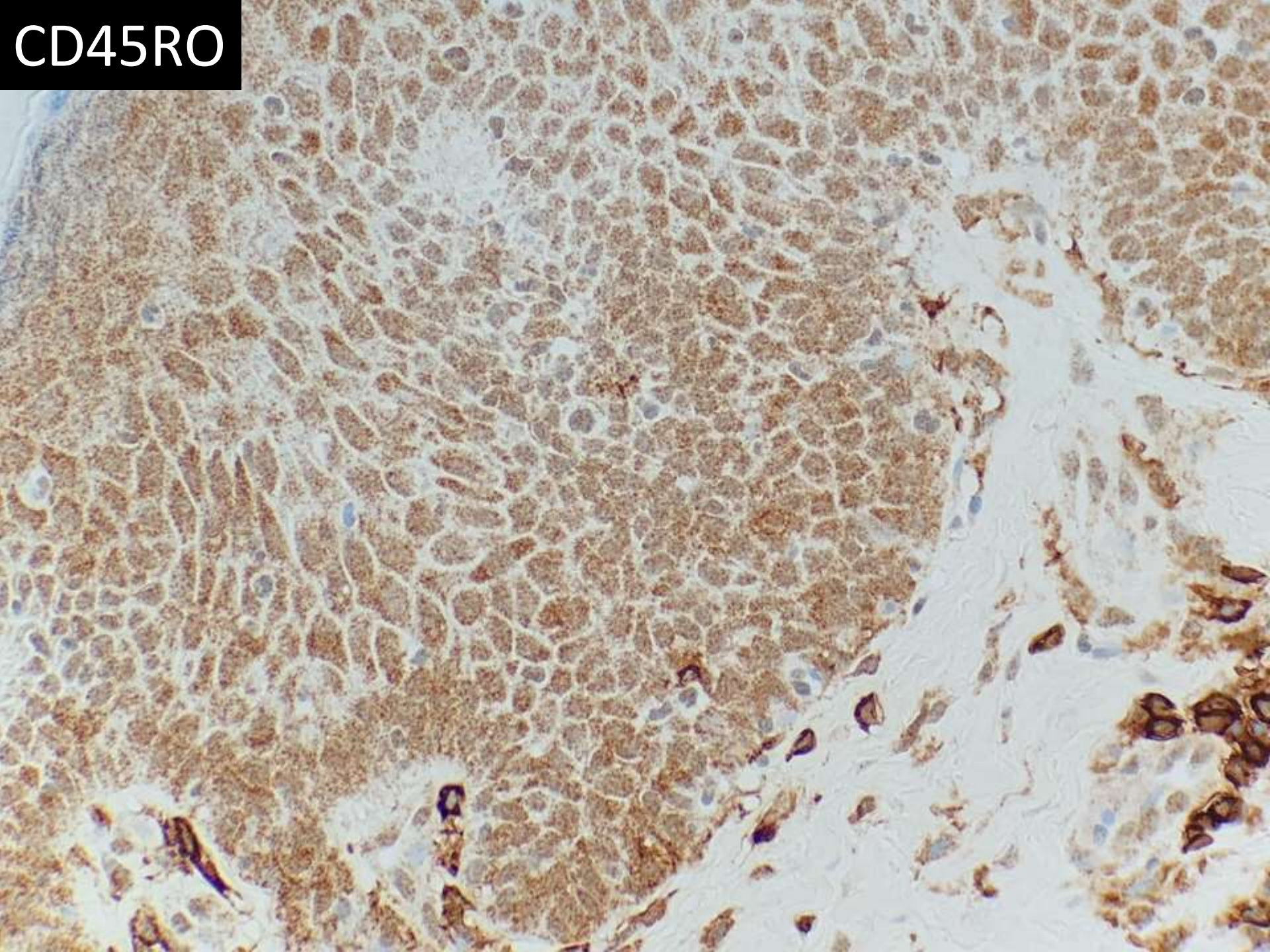
KI67



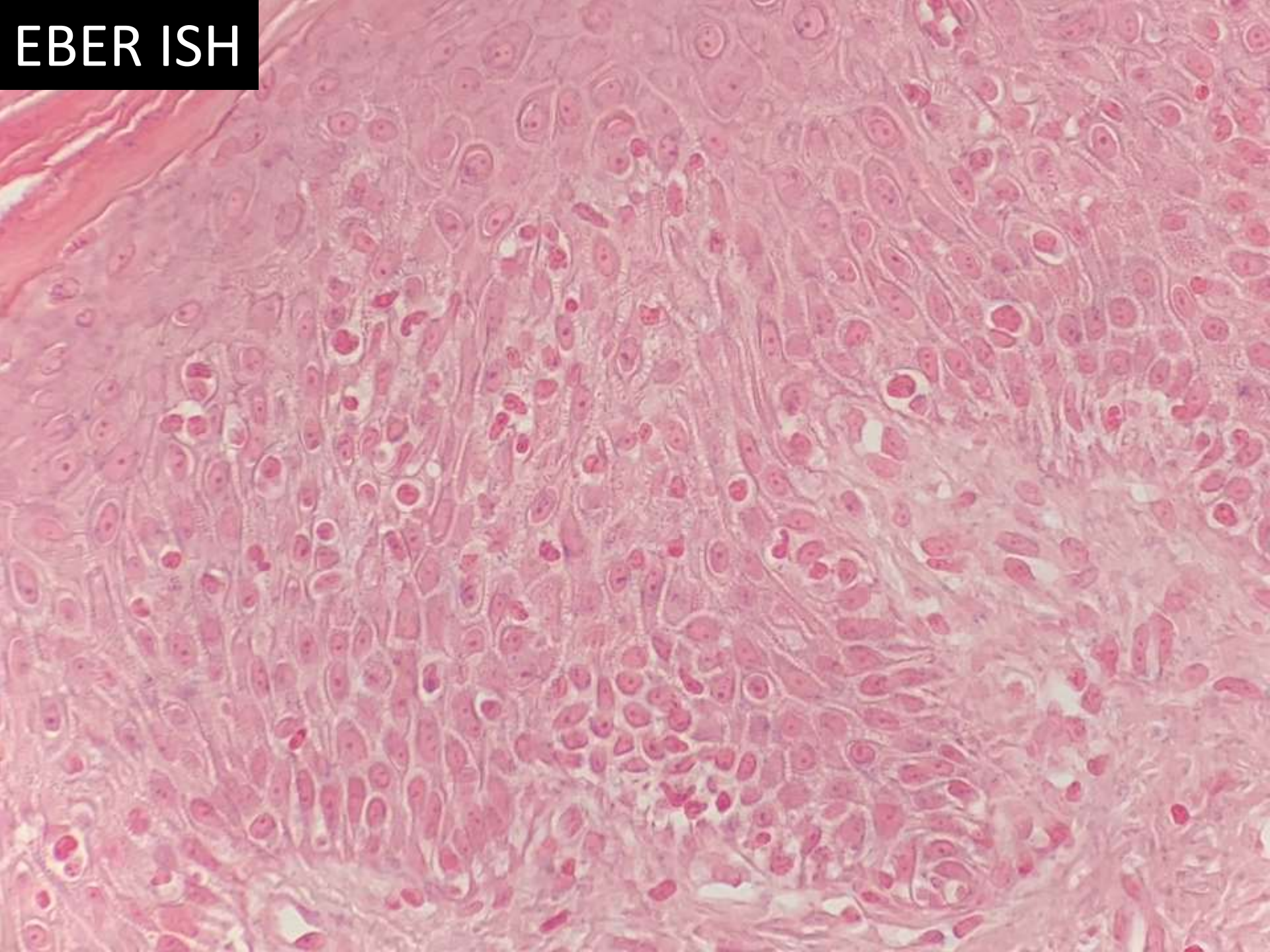
CD45RA



CD45RO



EBER ISH



DIAGNOSIS

- CD8-positive cutaneous t-cell lymphoma with epidermotropism and cytotoxic marker expression (see comment)
- COMMENT: Although CD8+ mycosis fungoides is a consideration based on the histomorphologic appearance, the overall clinical picture (rapidly progressive diffuse patches and plaques) and immunophenotypic profile (CD3+/CD8+/CD2-/CD7+/CD45RA+/CD45RO-/TCR-beta) is worrisome for primary cutaneous CD8+ aggressive epidermotropic cytotoxic T-cell lymphoma. Mycosis fungoides, in contrast, is typically CD2+/CD7-/CD45RA-/CD45RO+.

Primary cutaneous CD8+ aggressive epidermotropic T-cell lymphoma

- Epidemiology
 - <1% of all cutaneous T-cell lymphomas
 - Mainly in adults
- Clinical Presentation
 - Commonly: generalized skin lesions (eruptive papules, nodules, and tumors with central ulceration and necrosis)
 - Less frequently: localized ulcerated nodules, tumors, or plaques
 - May disseminate to viscera ; lymph nodes typically spared

Primary cutaneous CD8+ aggressive epidermotropic T-cell lymphoma

- Histopathology
 - Small -to-medium or medium-to-large with pleomorphic or blastic nuclei
 - Variably prominent epidermotropism
 - +/- epidermal necrosis, ulceration, and blistering
- Immunophenotype
 - +: CD3, CD8, TCR-beta, CD45RA, TIA1, granzyme B, perforin
 - +/-: CD7
 - -/+: CD5, CD4, CD30 (not diffuse)
 - -: CD2, TCR-delta, CD45RO, EBER ISH

Primary cutaneous CD8+ aggressive epidermotropic T-cell lymphoma

- Differential diagnosis
 - Mycosis fungoides (may be CD8+ and express cytotoxic markers)
 - Slow progression (years to decades): patches → plaques → tumors
 - Typically CD2+/CD7-/CD45RA-/CD45RO+
 - Lymphomatoid papulosis, type D (CD30+, CD8+)
 - Many relapsing-remitting papular, papulonecrotic, or nodular skin lesions in various stages
 - CD30-positive (diffuse, strong)
 - Primary cutaneous $\gamma\delta$ T-cell lymphoma
 - TCR-delta positive, TCR-beta negative

Primary cutaneous CD8+ aggressive epidermotropic T-cell lymphoma

- Prognosis
 - Aggressive: median survival 12 months
 - No known difference in survival between small-to-medium and medium-to-large cytomorphology or between localized and diffuse disease involvement