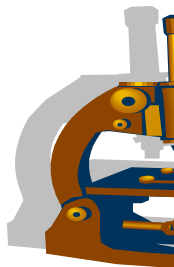


SBPS



**SOUTH BAY PATHOLOGY SOCIETY**

**CASE ACCESSIONS**

**WEB SITE: SOUTH BAY PATH.ORG**

**Garden Court Hotel  
520 Cowper Street  
Palo Alto, CA 94301**

FOR THE MEETING ON JAN 14, 2019 @ 7pm

**SB 6341 Mahendra Ranchod; Good Samaritan Hospital**

38-year-old male (recent immigrant from Mexico), presents with back pain. CT scan shows destructive lesions of T12, L2, L3. Biopsy of bone was non-diagnostic. Biopsy of right lung infiltrate performed.

**DIAGNOSIS:** \_\_\_\_\_

**SB 6342 (scanned slide available) Thuy Nguyen; Mills-Peninsula Health Services**

75-year-old female with colon polyps seen in routine colonoscopy.

**DIAGNOSIS:** \_\_\_\_\_

**SB 6343 Kelly Mooney/Megan Troxell; Stanford**

30-year-old BRCA positive female with left breast invasive ductal carcinoma, with contralateral breast ultrasound revealing 3.5cm oval mass with circumscribed margins with mixed echogenicity including hypo/hyper-echoic areas. Bilateral mastectomy performed.

**DIAGNOSIS:** \_\_\_\_\_

**SB 6344 (scanned slide available) Ankur Sangoi; El Camino Hospital**

57-year-old male with h/o prostate cancer s/p prostatectomy (Gleason grade 3+4 with tertiary pattern 5, mixed acinar/ductal adenocarcinoma, pT3aN0). Now presents with cystic neck mass diagnosed as metastatic squamous cell carcinoma by FNA. Work-up revealed tonsillar mass identified. Tonsillectomy performed at time of oropharyngeal mapping.

**DIAGNOSIS:** \_\_\_\_\_

**SB 6345 (scanned slide available) Yue Peng/Cathryn Cadwell/Mark Lu; SF VA Medical Center**

76-year-old female with COPD, recurrent pneumonia who presents with hypermetabolic 3.6cm right RLL lung mass with endobronchial extension and ipsilateral hilar and subcarinal lymph node FDG uptake compatible with nodal metastasis. FNA subcarinal lymph node performed.

**DIAGNOSIS:** \_\_\_\_\_

**SB 6346 Sharon Wu; El Camino Hospital**

68-year-old male heavy smoker with right pleural effusion.

**DIAGNOSIS:** \_\_\_\_\_

**SB 6347 Hannes Vogel; Stanford**

39-year-old female with a history of seizures dating back to age 15, possibly related to head trauma in her youth. An MRI from 2016 demonstrates encephalomalacia in the left parietal lobe.

**DIAGNOSIS:** \_\_\_\_\_

**SB 6348 Mahendra Ranchod; Good Samaritan Hospital**

72-year-old male with multiple liver lesions and a pancreatic mass. Liver biopsy performed.

**DIAGNOSIS:** \_\_\_\_\_

**SB 6349 Megan Troxell/Dean Fong; Stanford/Kaiser SF**

19-year-old female with nausea, vomiting, abdominal pain, edema. Upper endoscopy demonstrated mild gastritis. Found to have proteinuria (4.4g), normal serum creatine (0.7mg/dl). Kidney biopsy performed.

**DIAGNOSIS:** \_\_\_\_\_

**SB 6350 Ankur Sangoi; El Camino Hospital**

52-year-old male found to have bilateral breast enlargement. Upon work-up, elevated serum PSA discovered. MRI-guided prostate biopsy performed of abnormal area seen on imaging.

**DIAGNOSIS:** \_\_\_\_\_

*\* Ankur Sangoi, MD asangoi2@yahoo.com  
Registrar, SouthBay Pathology Society  
El Camino Hospital, Dept of Pathology, GC-33  
Mountain View, CA 94040*

*\* Kristin Jensen, MD (CME co-Chair) kjensen1@stanford.edu  
\* Megan Troxell, MD (CME co-Chair) megant@stanford.edu  
\* Planning Committee Members*

The South Bay Pathology Society is accredited by the Institute for Medical Quality/California Medical Association (IMQ/CMA) to provide continuing medical education for physicians.

The South Bay Pathology Society designates this live activity for a maximum of 1 *AMA PRA Category I Credit*<sup>™</sup>. Physicians should claim only the credit commensurate with the extent of their participation in the activity.

For physicians participating in Continuing Certification (CC) through the American Board of Pathology, this activity meets requirements for both Lifelong Learning (Part II) and Self-Assessment Module (SAM) credit hours (upon successful completion of a post-activity test with a passing rate of 80% correct answers).