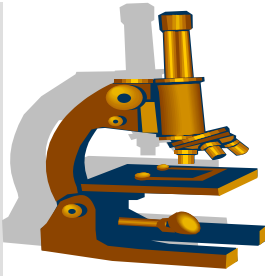


SBPS



SOUTH BAY PATHOLOGY SOCIETY

CASE ACCESSIONS

WEB SITE: SOUTHBAYPATH.ORG

**Garden Court Hotel
Cowper Street
Palo Alto, CA**

FOR THE MEETING ON JUNE 5TH, 2017

SB 6161 Claude Burdick; St. Rose Hospital

53-year-old woman on dialysis and bleeding from gastric fundus requiring 20 transfusions. No h/o chronic inflammatory disease. Gastric biopsy submitted.

DIAGNOSIS: _____

SB 6162 (scanned slide available) Mahendra Ranchod; Good Samaritan Hospital

34-year-old woman with colostomy performed for imperforate anus. Draining cutaneous fistula after take of colostomy. Segment of colon resection.

DIAGNOSIS: _____

SB 6163 Peyman Samghabadi/Donald Born; Stanford

17-year-old previously healthy male presents with 2 month h/o of intermittent headache, nausea, emesis, and slow cognition thought to be post-concussive from a collision during a basketball game. MRI reveals a contrast-enhancing mass in the right temporoparietal area associated with a cyst and edema.

DIAGNOSIS: _____

SB 6164 Yiting Li/Yi Xie; UCSF

44-year-old HIV positive man with retroperitoneal lymphadenopathy.

DIAGNOSIS: _____

SB 6165 Michael DiMaio; Marin General Hospital

55-year-old man with post-auricular 2 to 3cm rubbery, mobile, painless nodule present for several years covered by his hairline, and has not grown noticeably. It was noticed when his wife touched his head. He presented initially for FNA, then 3 months later for excision.

DIAGNOSIS: _____

SB 6166 Greg Charville/Dean Fong; Stanford & Palo Alto VA

73-year-old man with a unilateral pleural effusion. Biopsy of thickened pleura submitted.

DIAGNOSIS: _____

SB 6167 (scanned slide available) Greg Charville/Megan Troxell; Stanford
Woman with large renal mass.

DIAGNOSIS: _____

SB 6168 (scanned slide available) Serena Tan/Megan Troxell; Stanford
55-year-old man with diabetes, pancreatitis, and elevated creatinine. Needle biopsy of renal mass.

DIAGNOSIS: _____

SB 6169 (scanned slide available) Kelly Mooney/Dean Fong; VA Palo Alto
Bleeding tumor/mass in rectum.

DIAGNOSIS: _____

SB 6170 Alana Shain/Christine Louie; VA Palo Alto
61-year-old man with mediastinal mass. Endoscopic ultrasound-guided FNA performed.

DIAGNOSIS: _____

** Ankur Sangoi, MD asangoi2@yahoo.com*
Registrar, SouthBay Pathology Society
El Camino Hospital, Dept of Pathology, GC-33
Mountain View, CA 94040

** Kristin Jensen, MD (CME Chair) kjensen1@stanford.edu*
** Planning Committee Members*

The South Bay Pathology Society is accredited by the Institute for Medical Quality/California Medical Association (IMQ/CMA) to provide continuing medical education for physicians.

The South Bay Pathology Society designates this live activity for a maximum of 1 *AMA PRA Category 1 Credit*[™]. Physicians should claim only the credit commensurate with the extent of their participation in the activity. "For physicians participating in Maintenance of Certification (MOC) through the American Board of Pathology, CME credit hours can be converted to Self-Assessment Modules (SAMs) credit hours upon successful completion of a post-activity test with a passing rate of 80% correct answers."