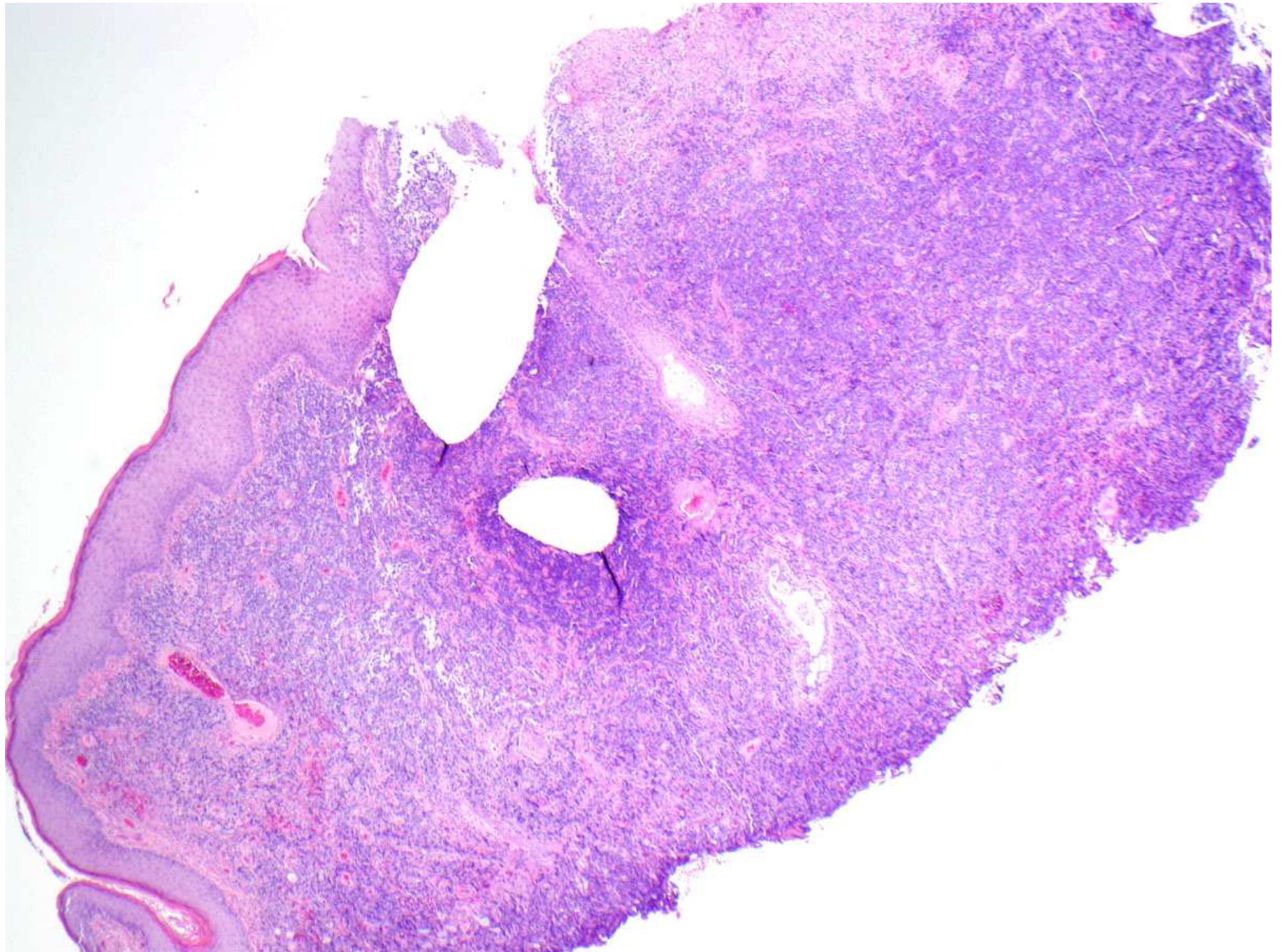
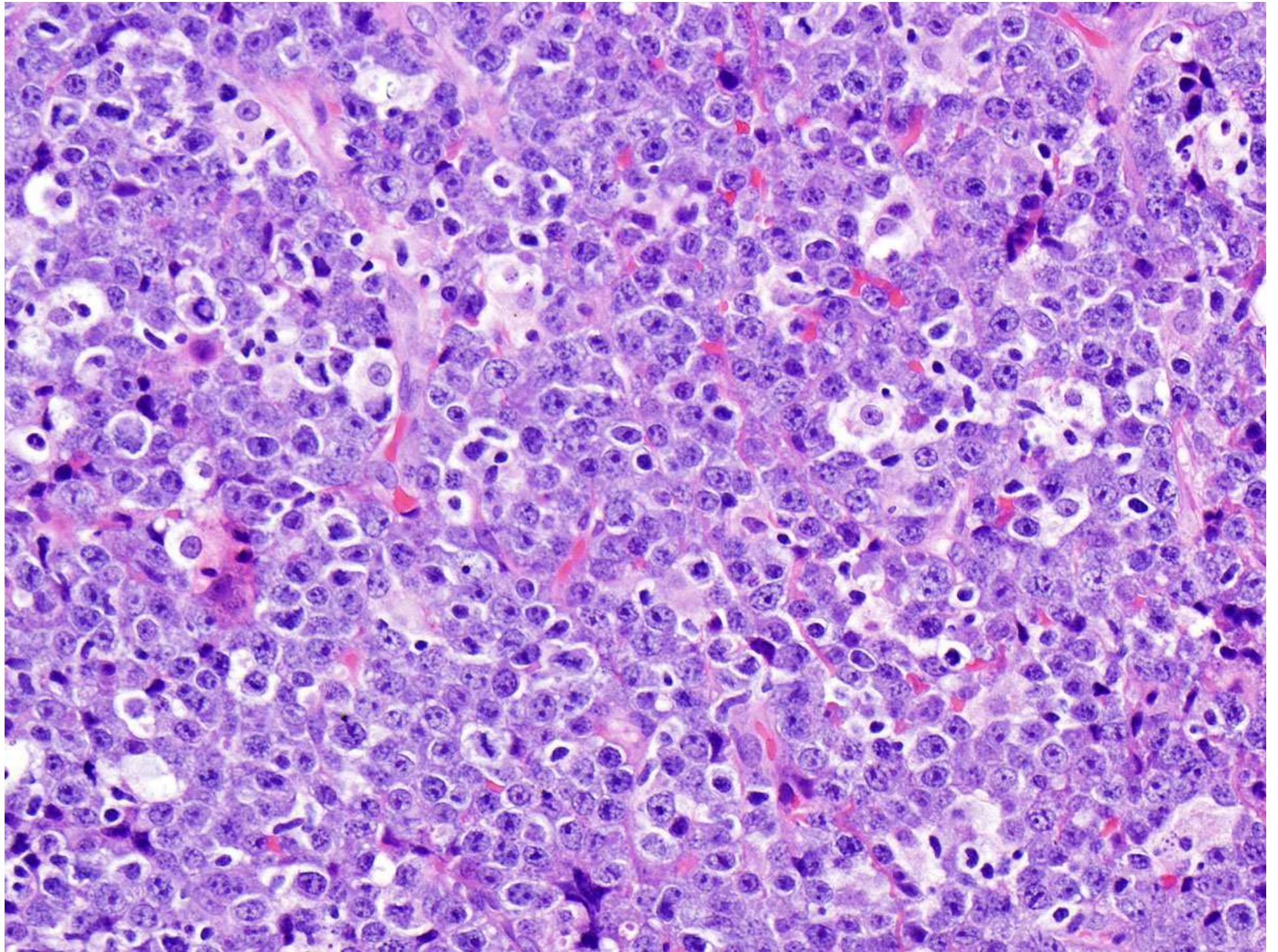
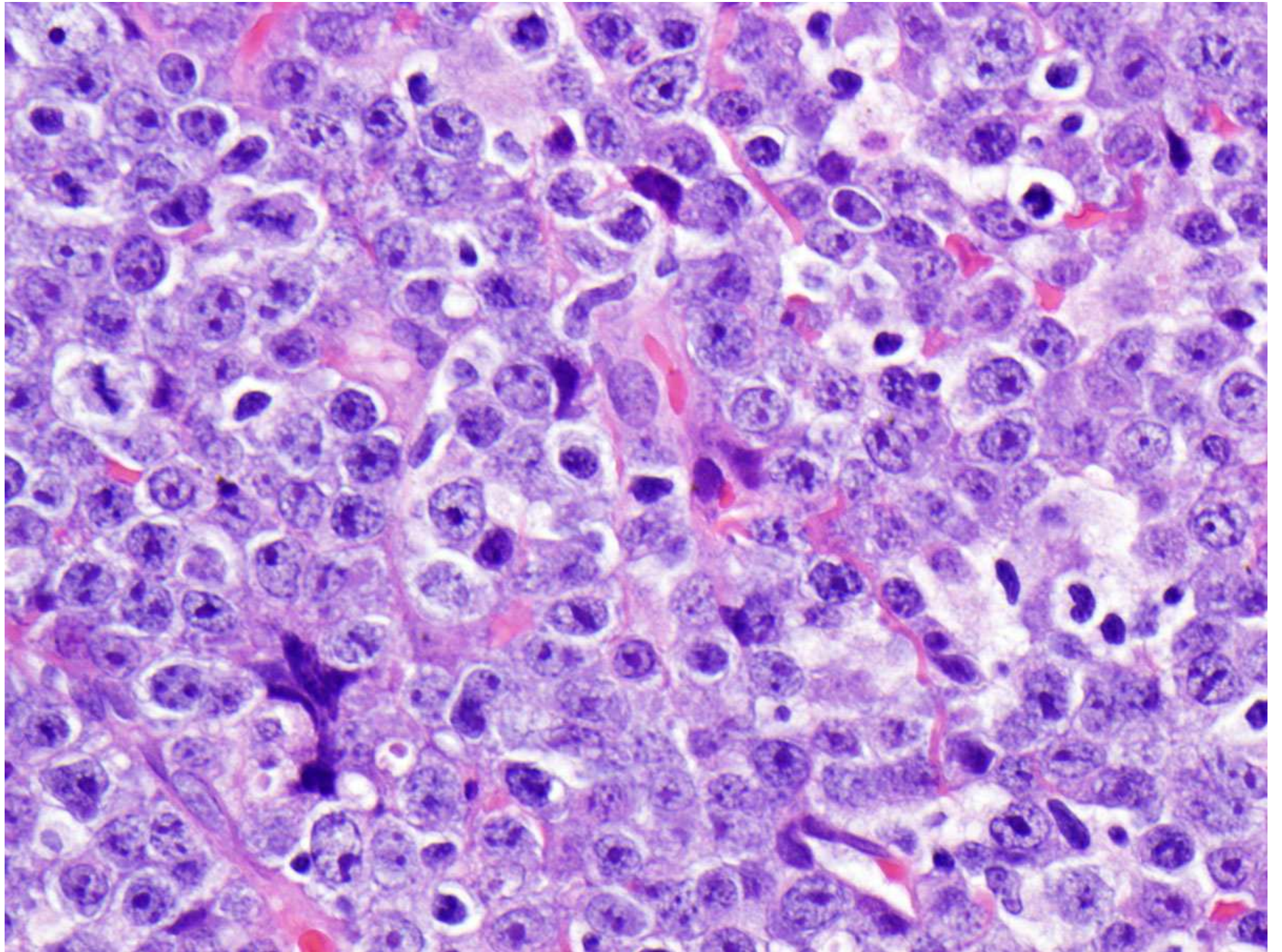


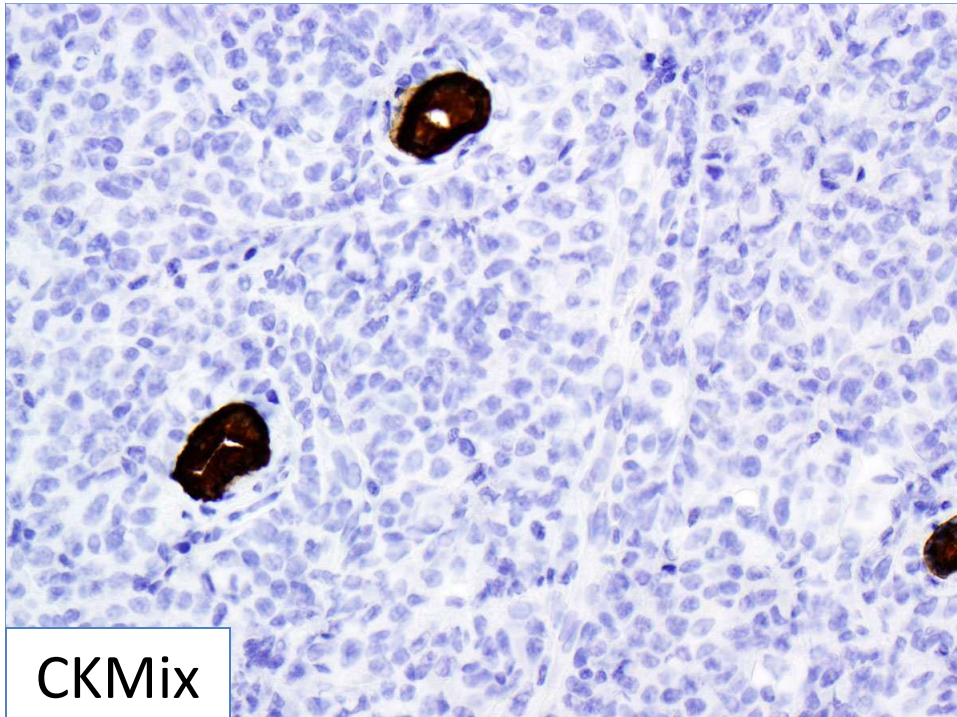
# Case 7

- 40 year old HIV-positive man presents with a rectal abscess and underwent a perianal biopsy.

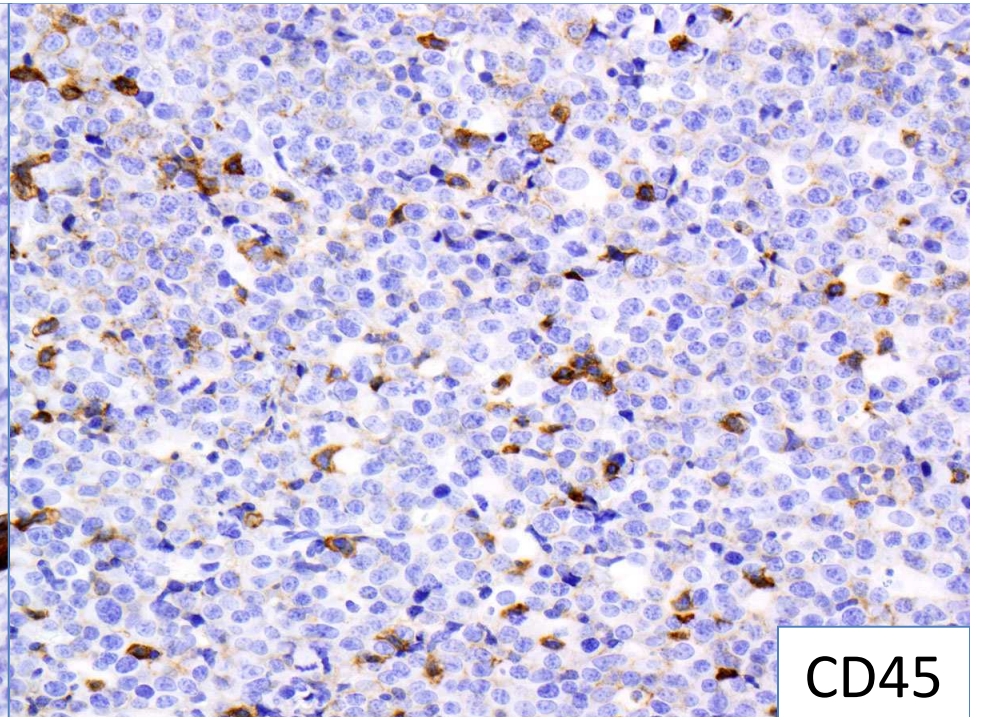




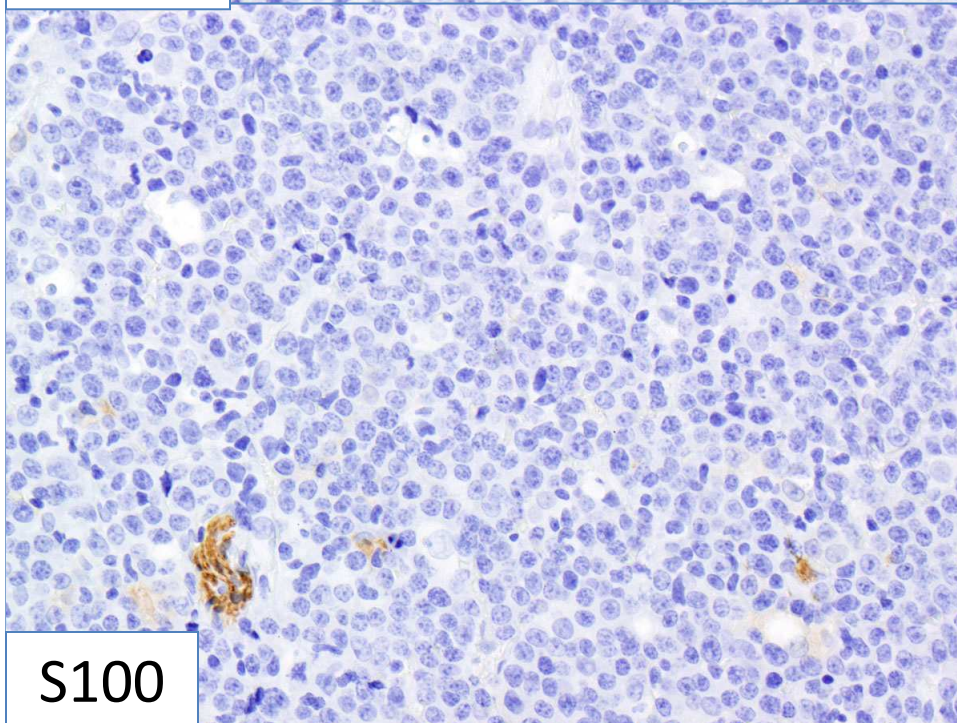




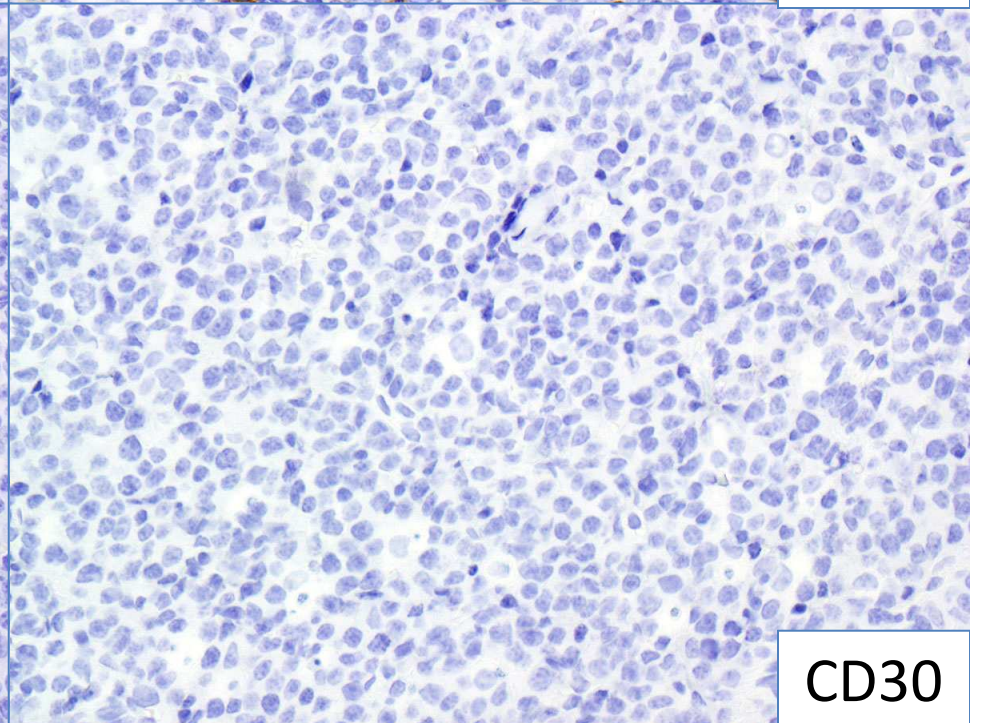
CKMix



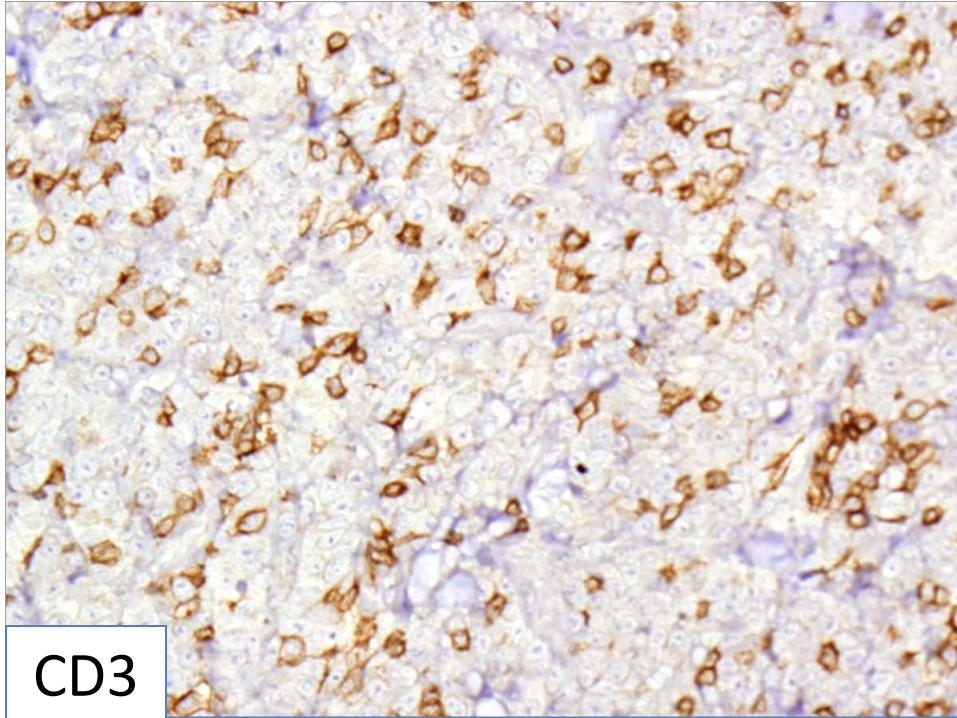
CD45



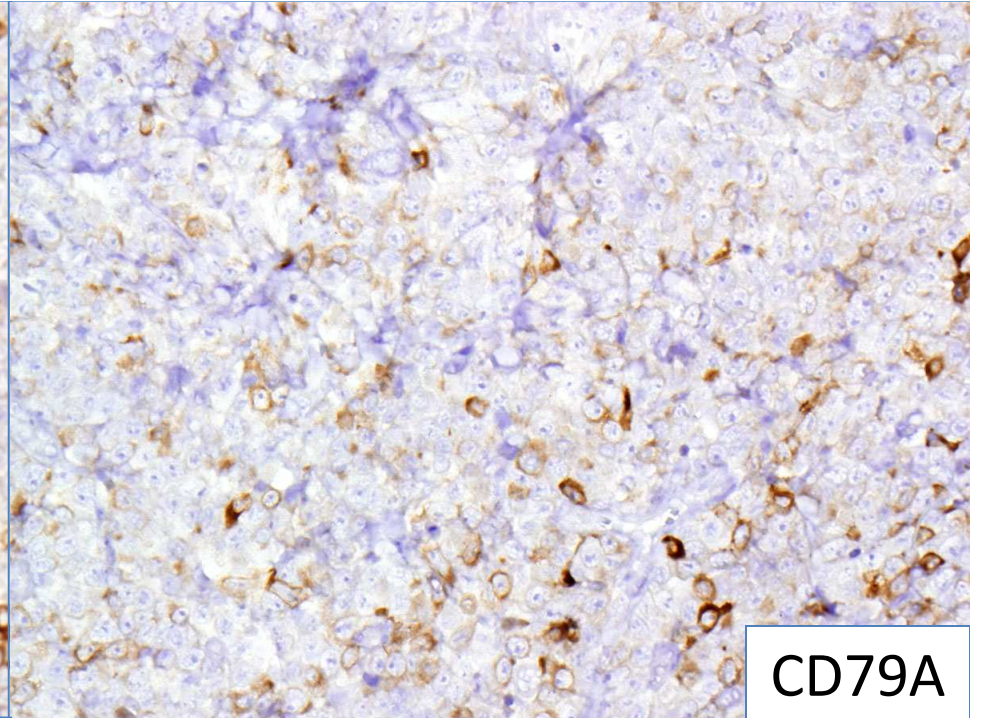
S100



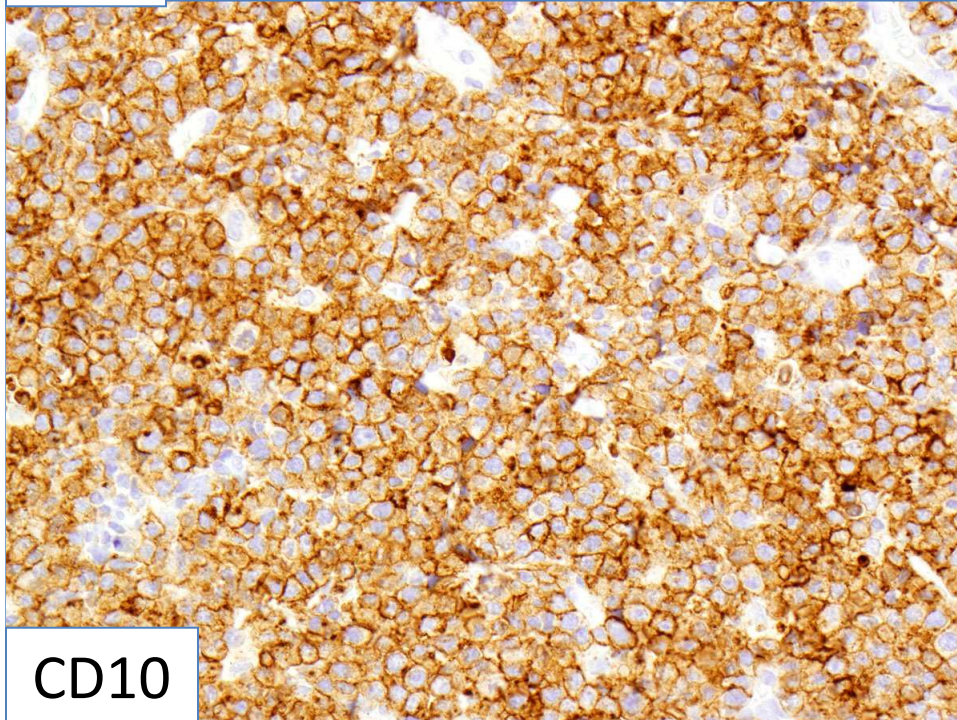
CD30



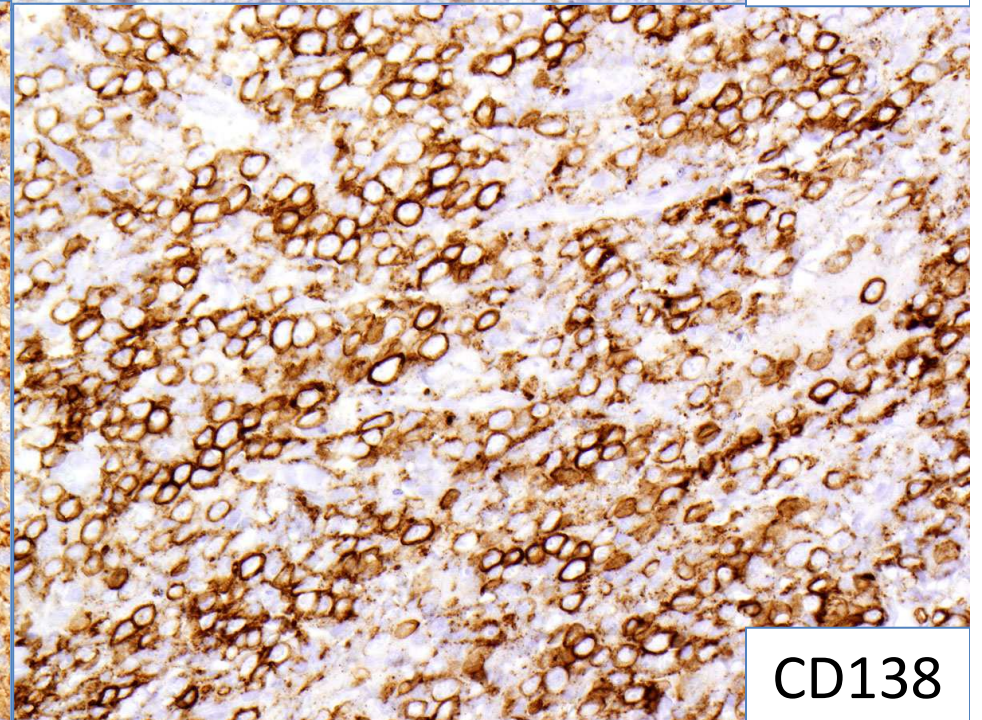
CD3



CD79A



CD10



CD138