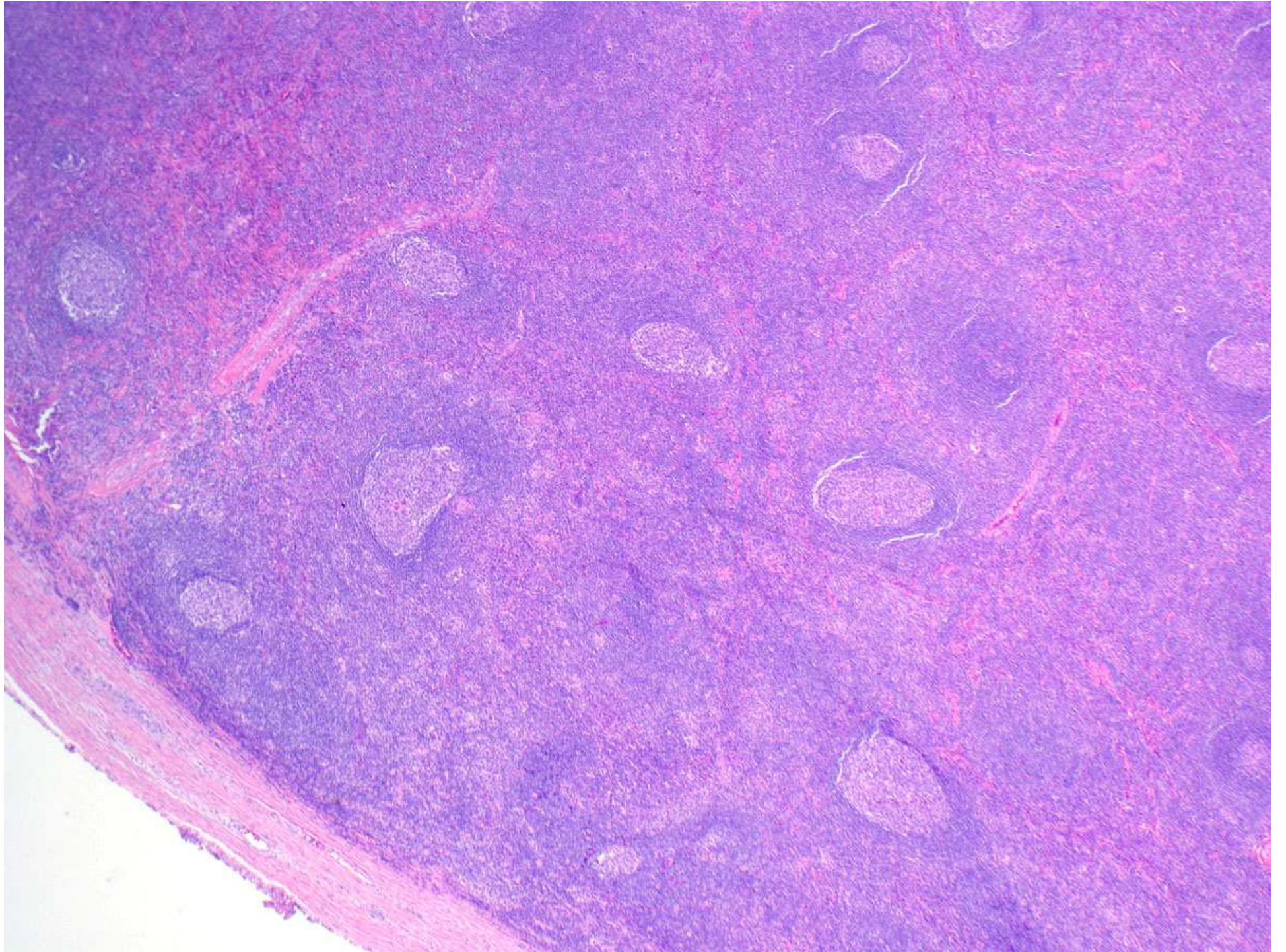
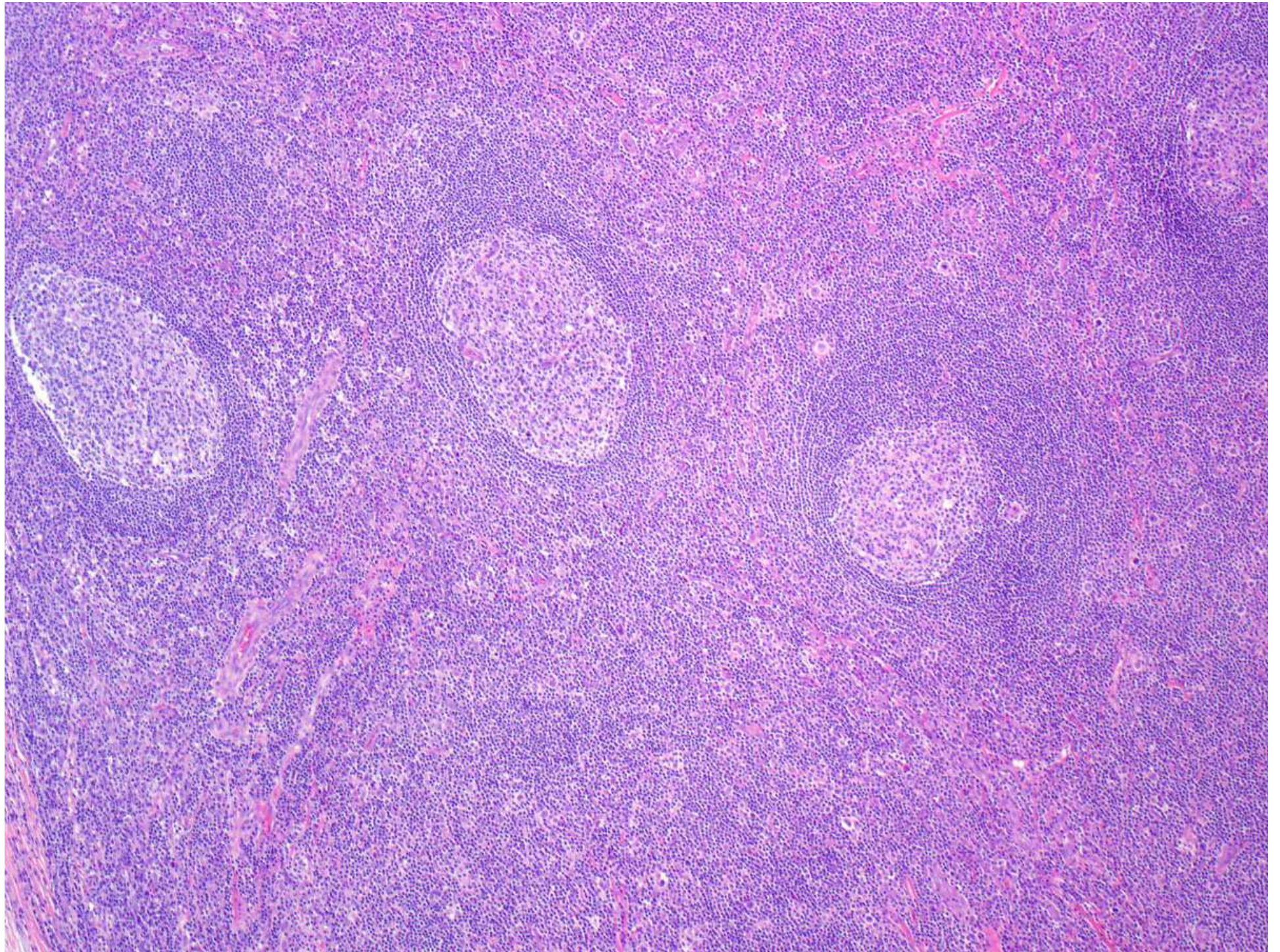
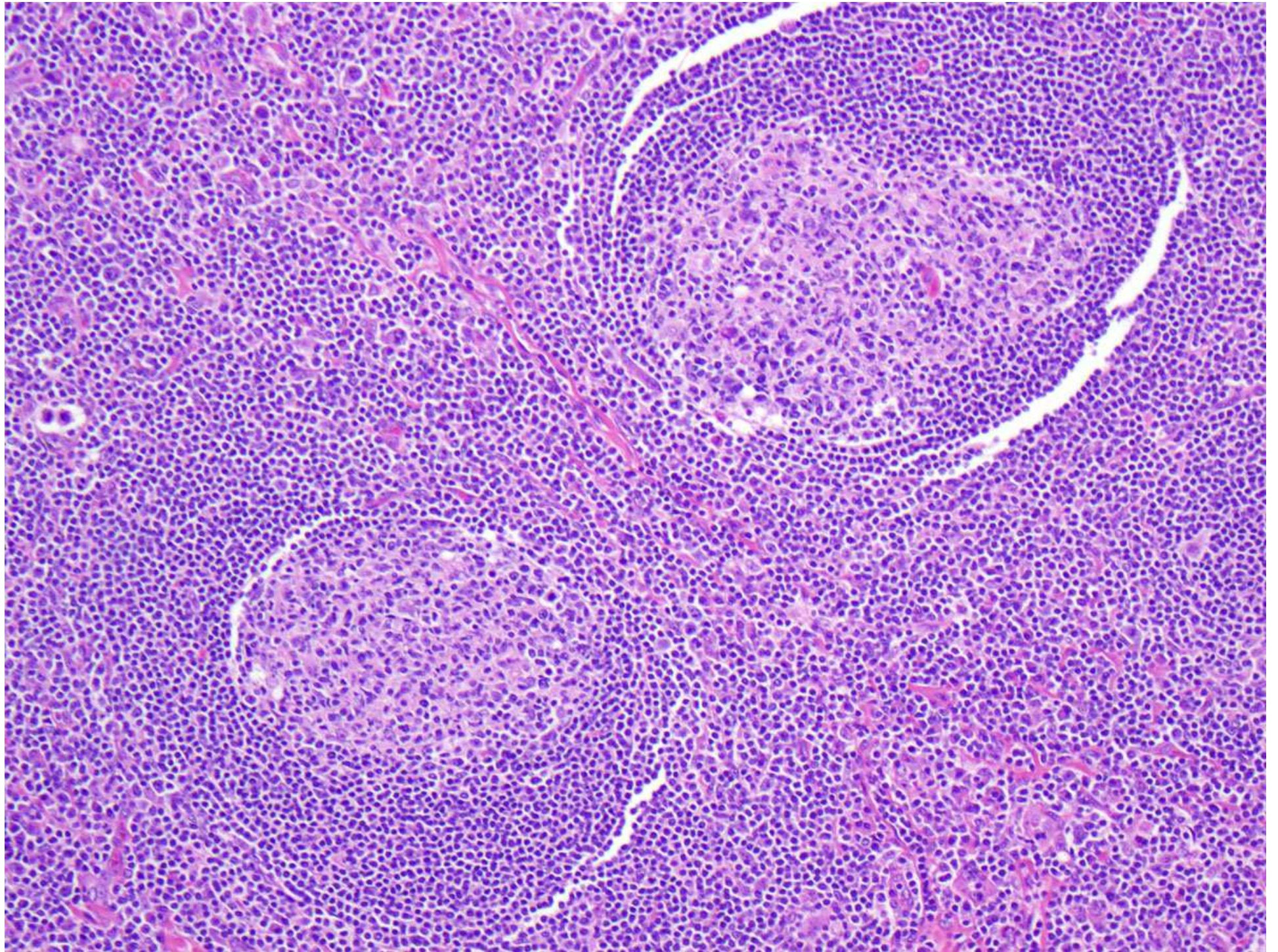


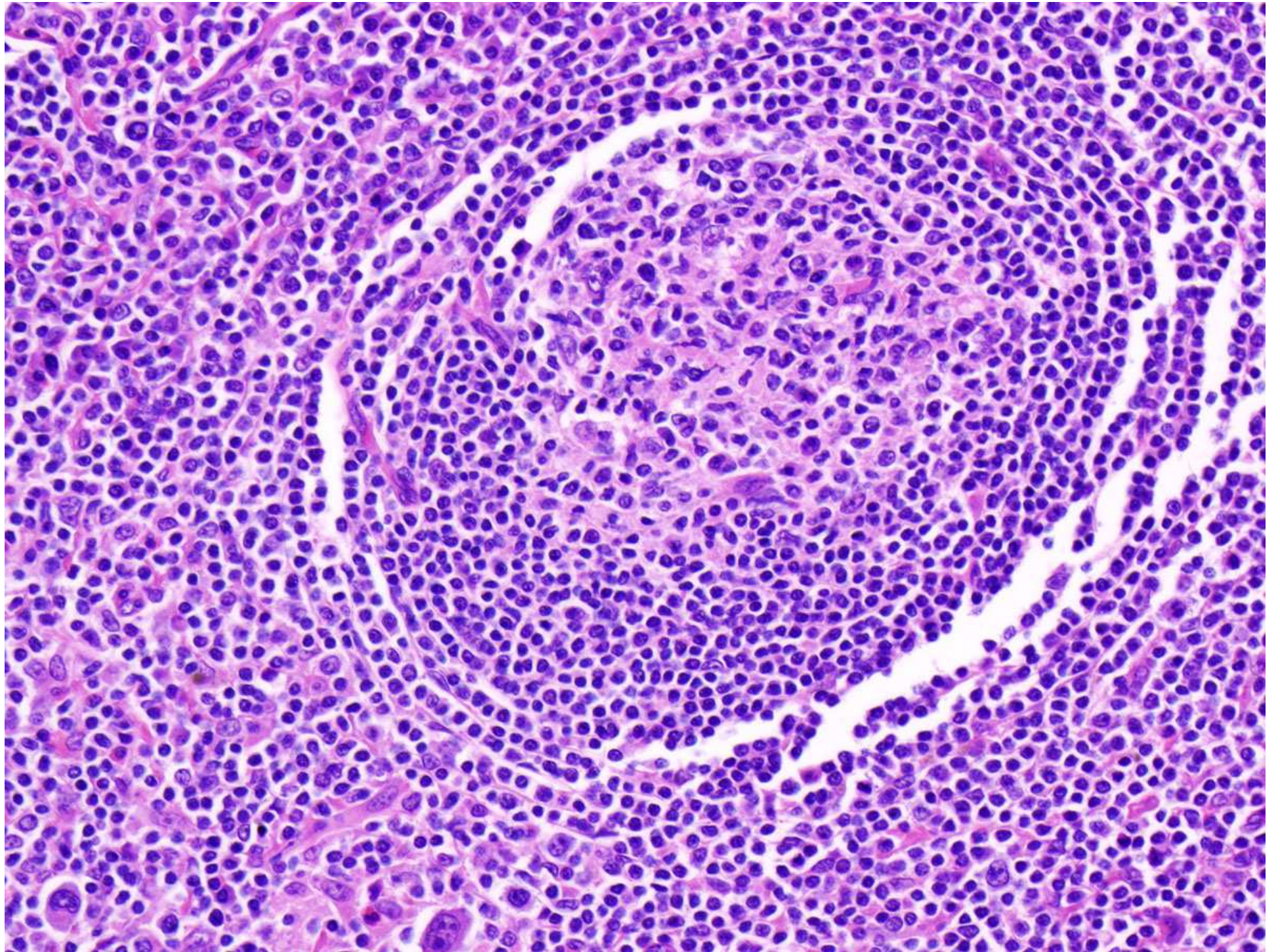
Case 3

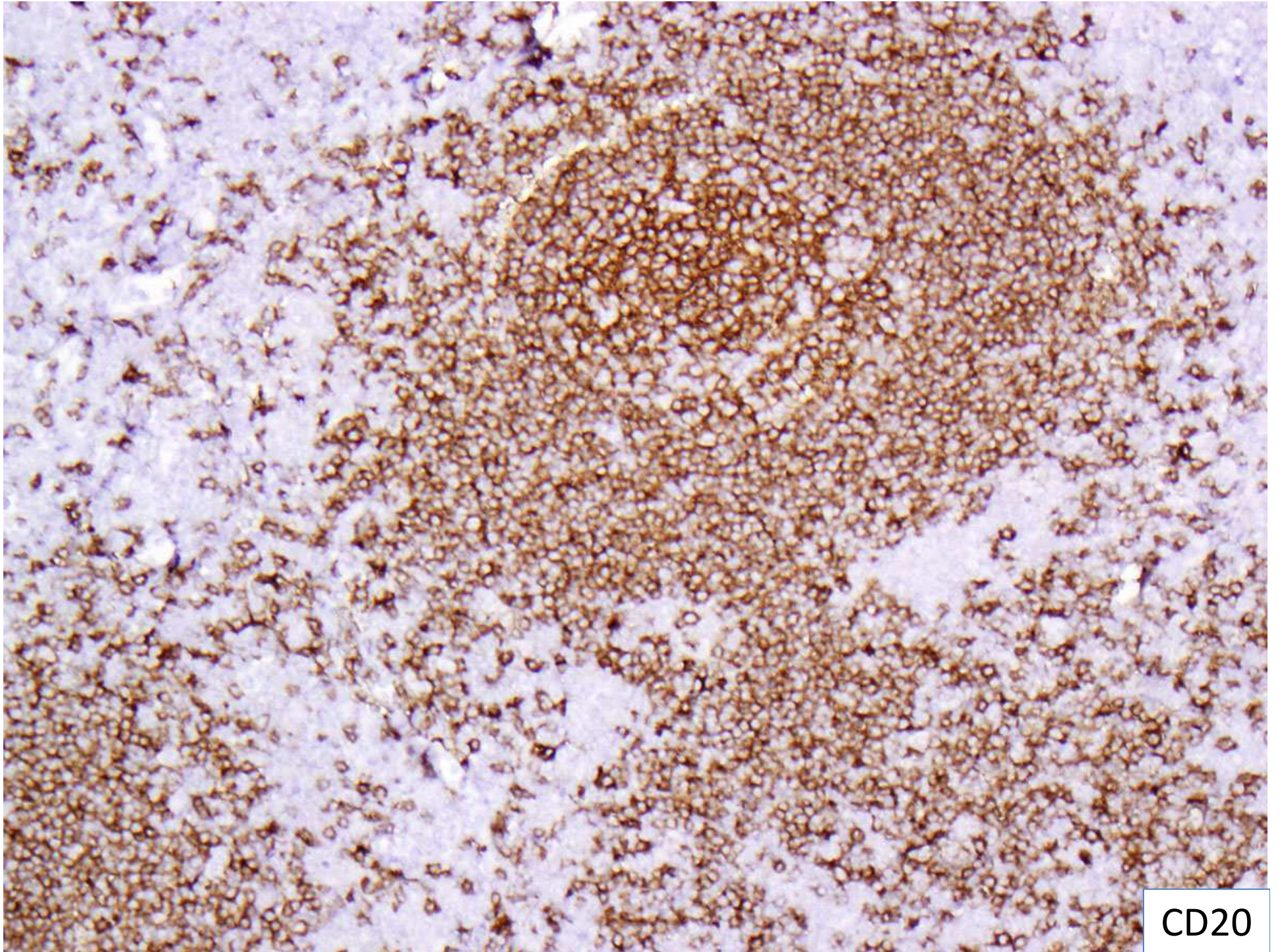
- 50 year old man with fevers for six months presents with an enlarged supraclavicular lymph node.



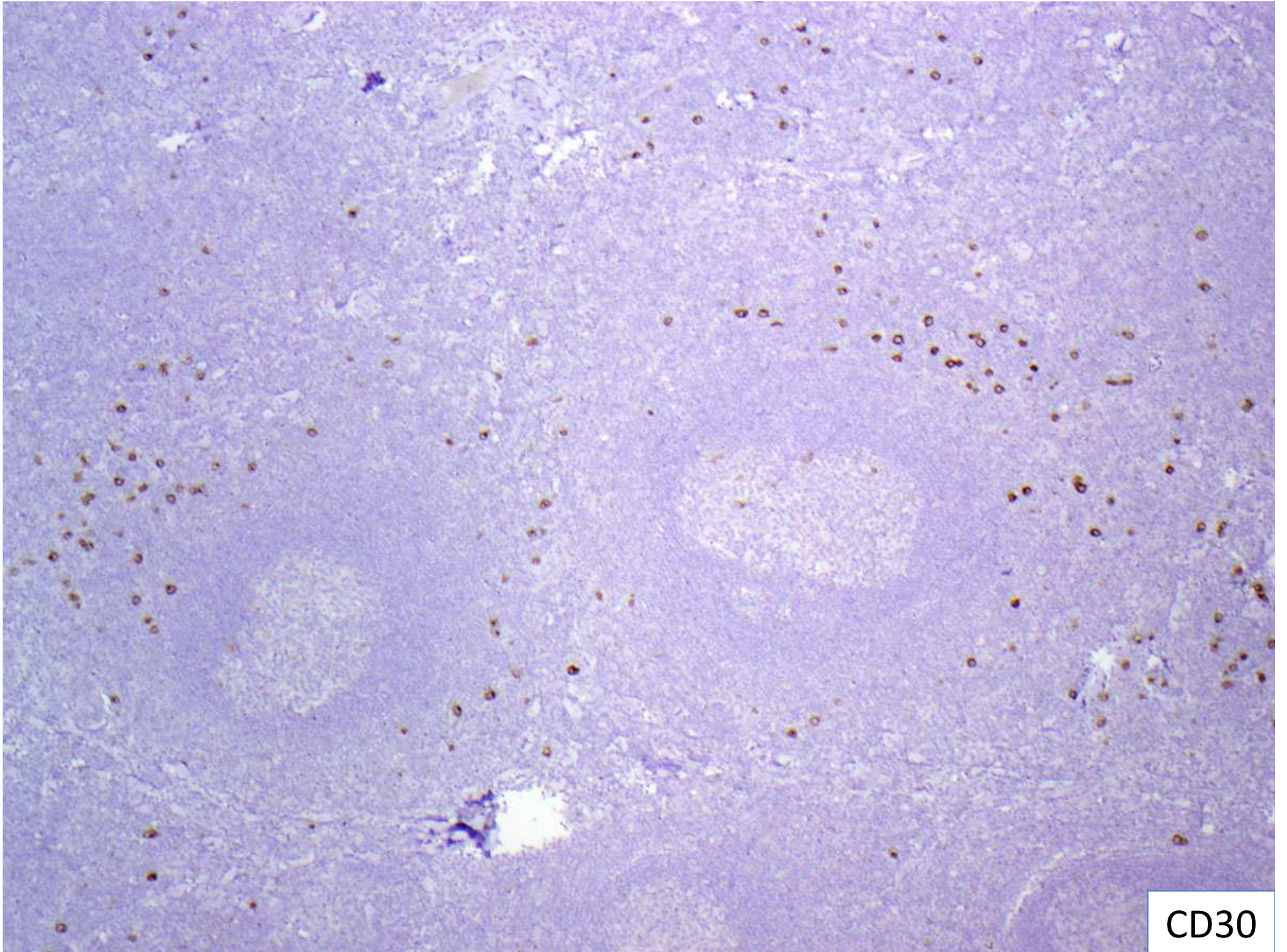








CD20



CD30