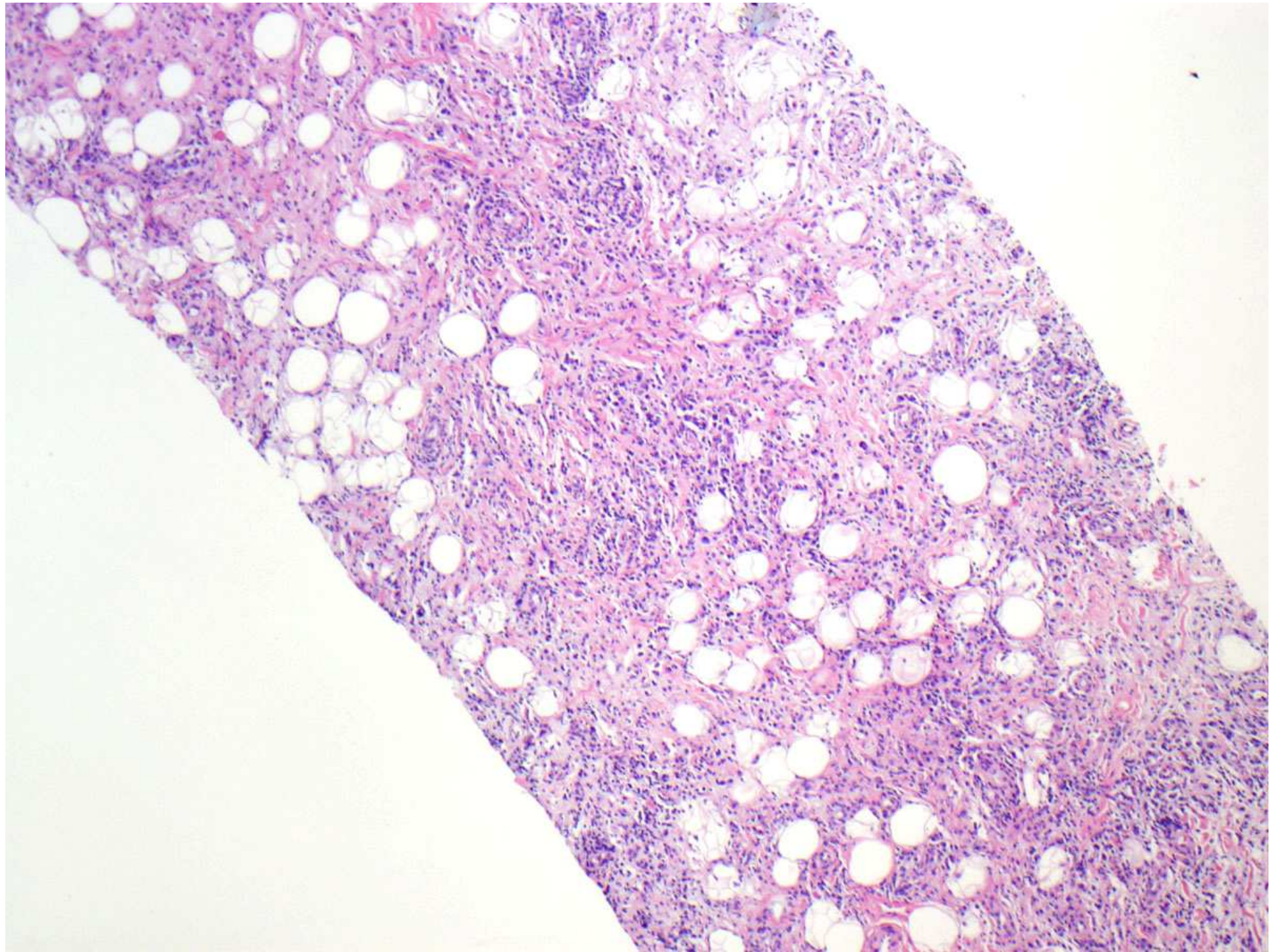
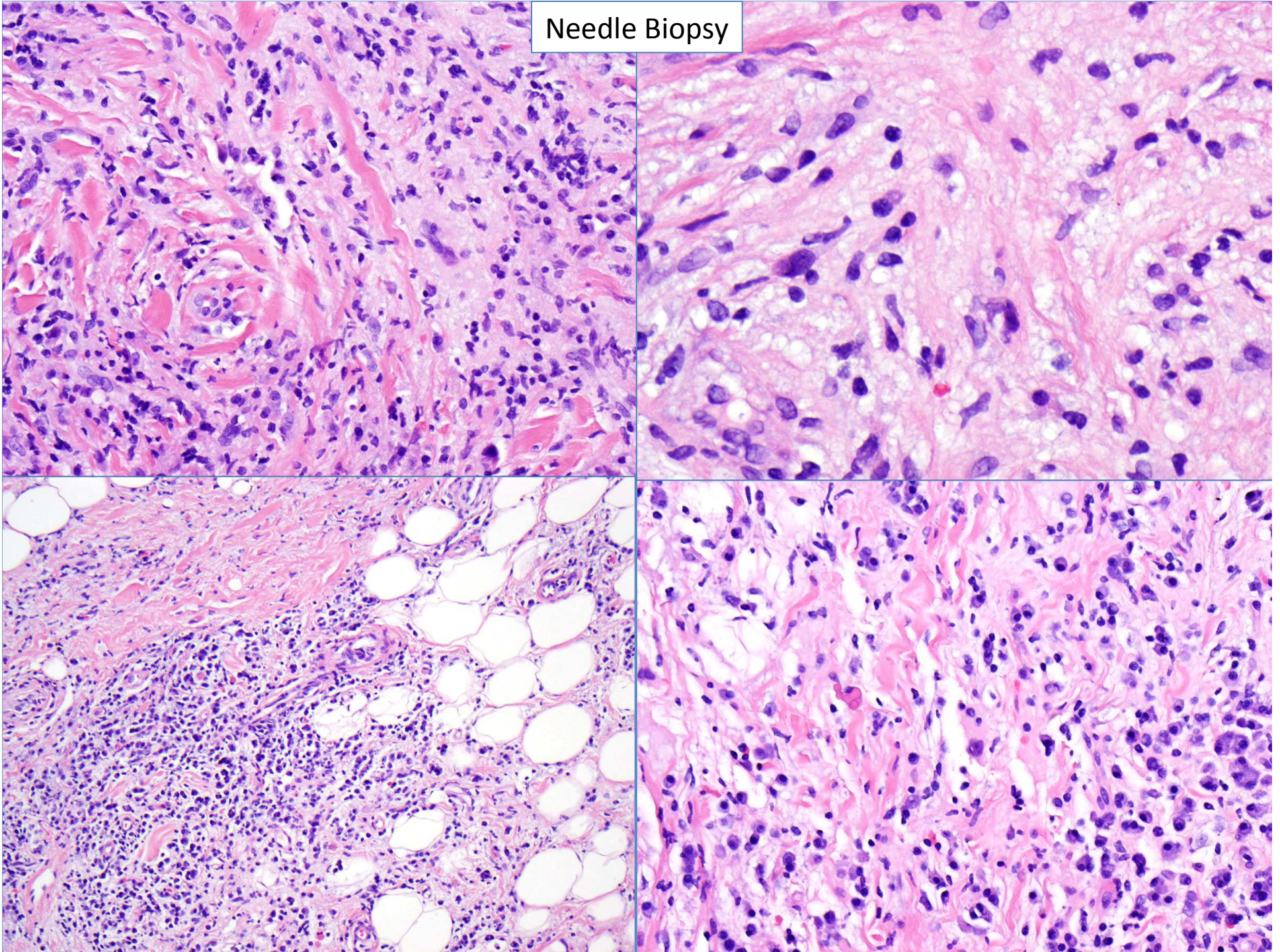


# Case 10

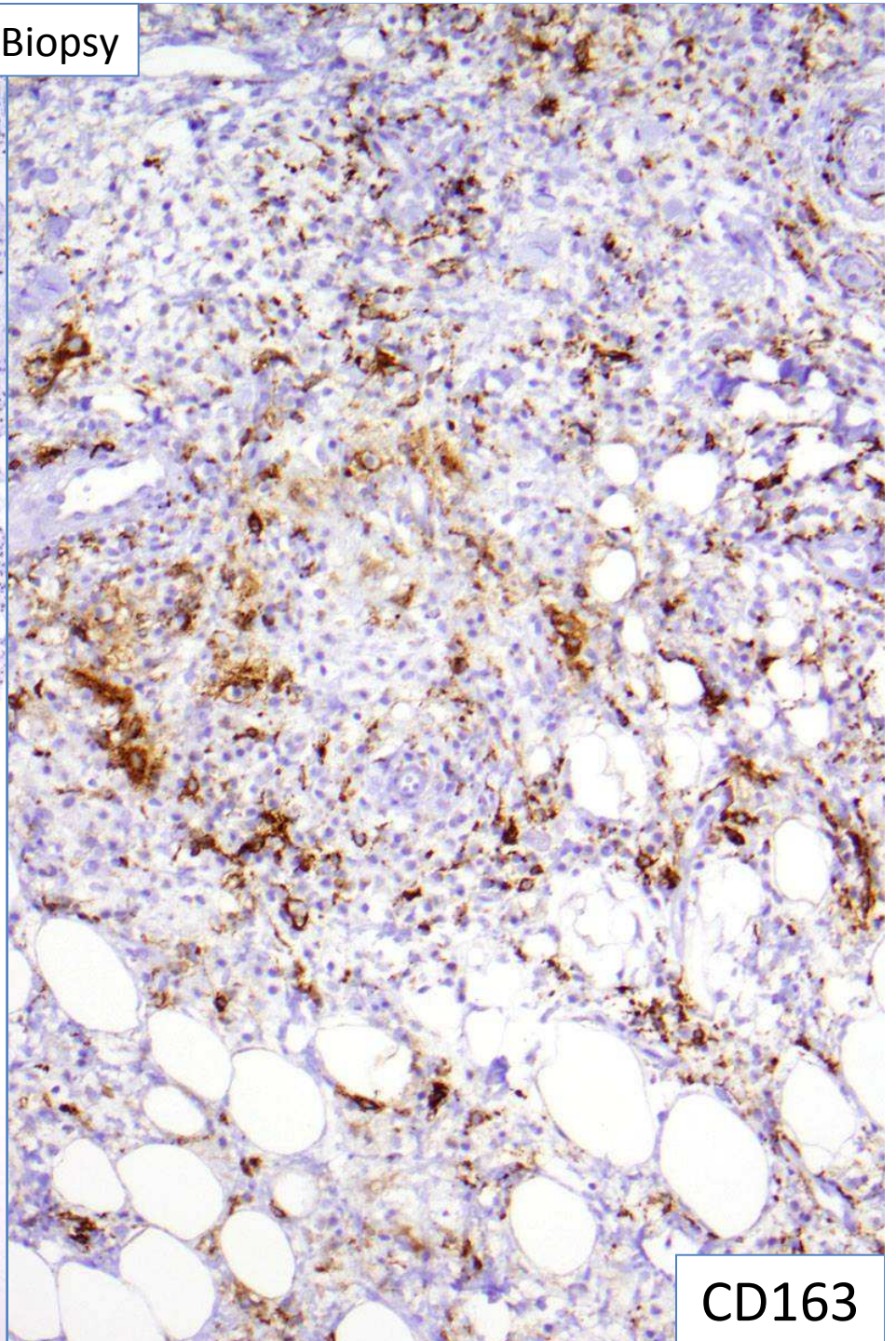
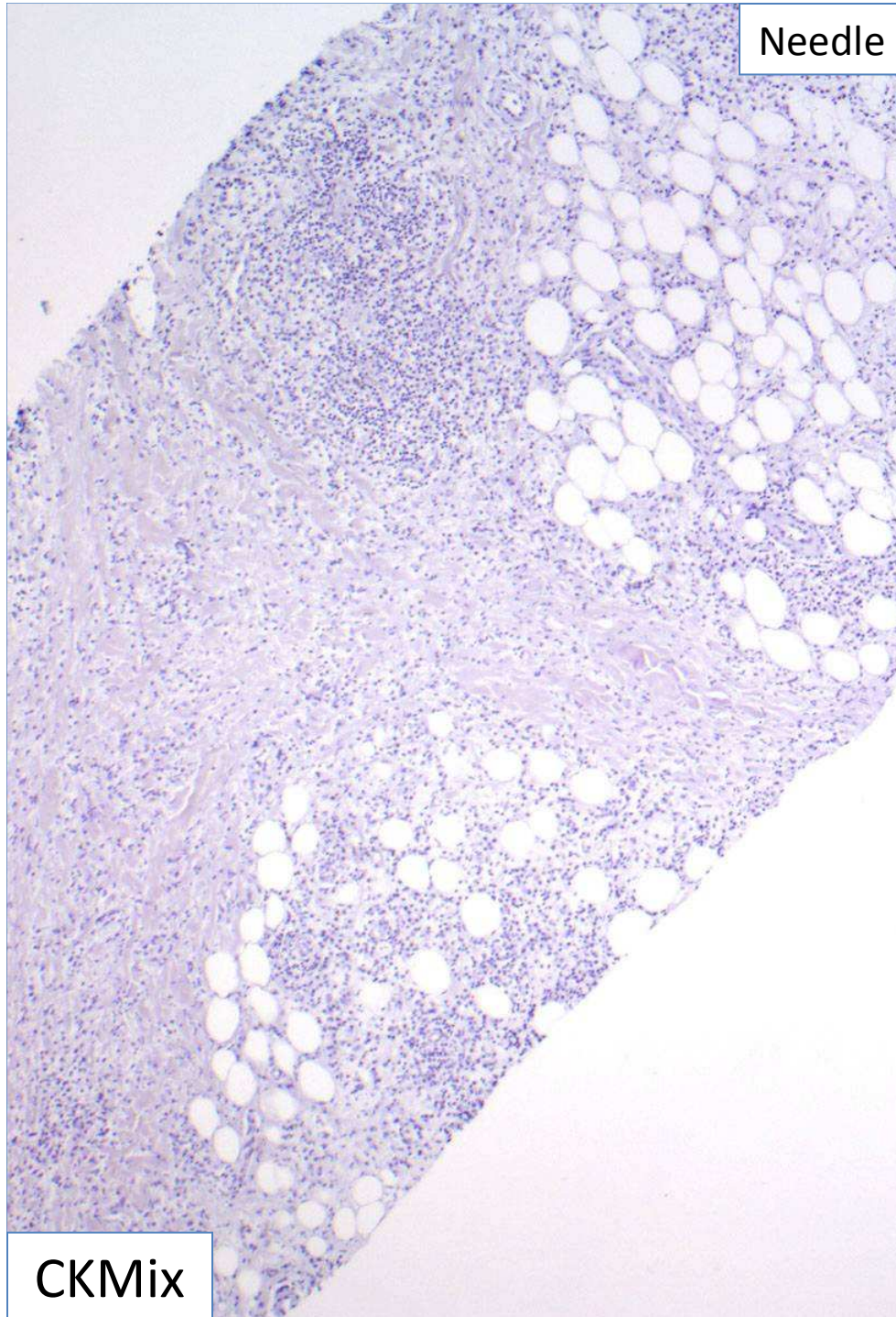
- 50 year old woman who presented with a two year history of an enlarging subcutaneous left thigh mass that is now 6.0 cm. A tru-cut needle biopsy of the thigh mass was diagnosed as most consistent with inflammatory myofibroblastic tumor with a recommendation for excision of the lesion.



Needle Biopsy



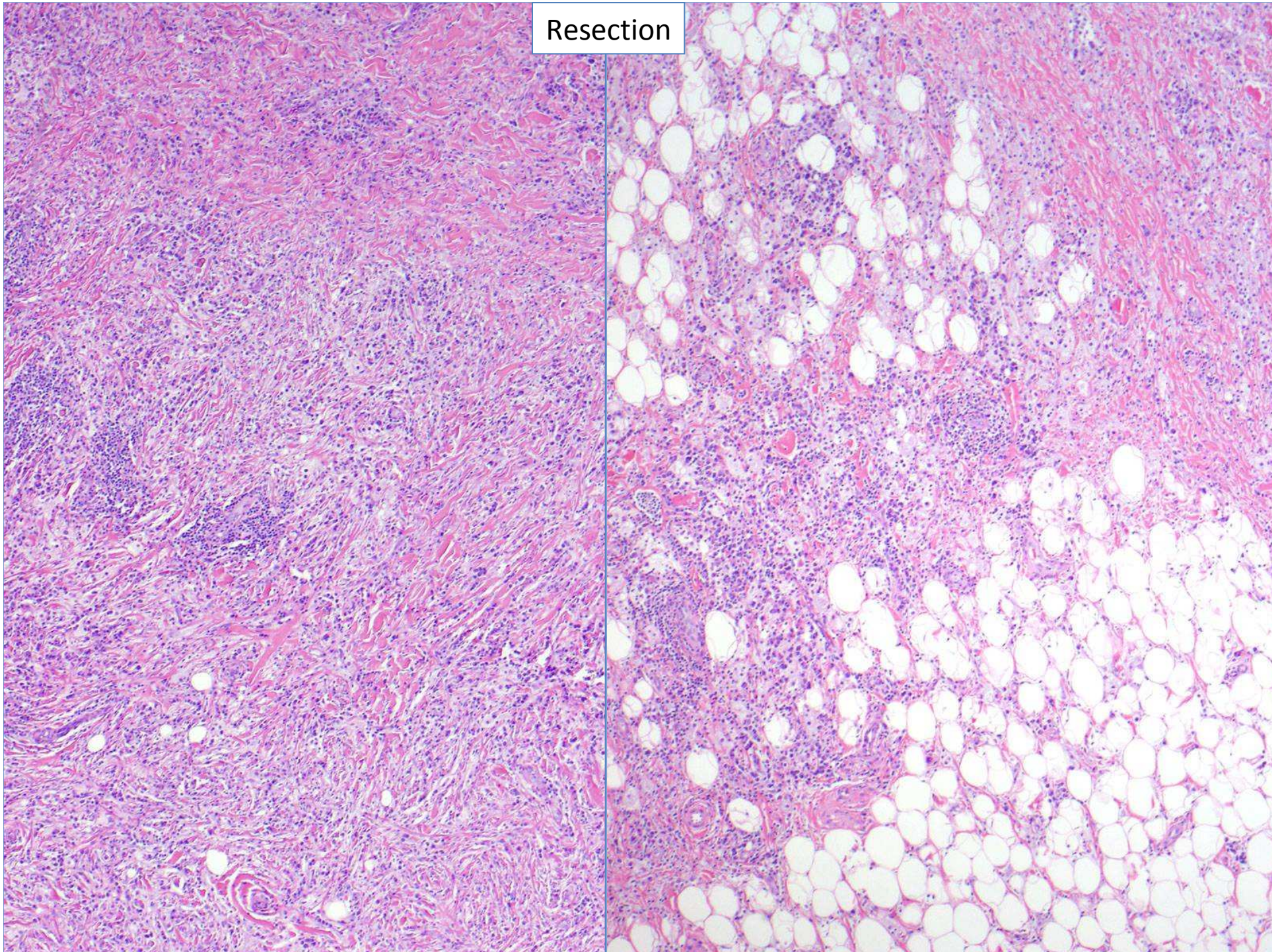
Needle Biopsy



CKMix

CD163

Resection



Resection

