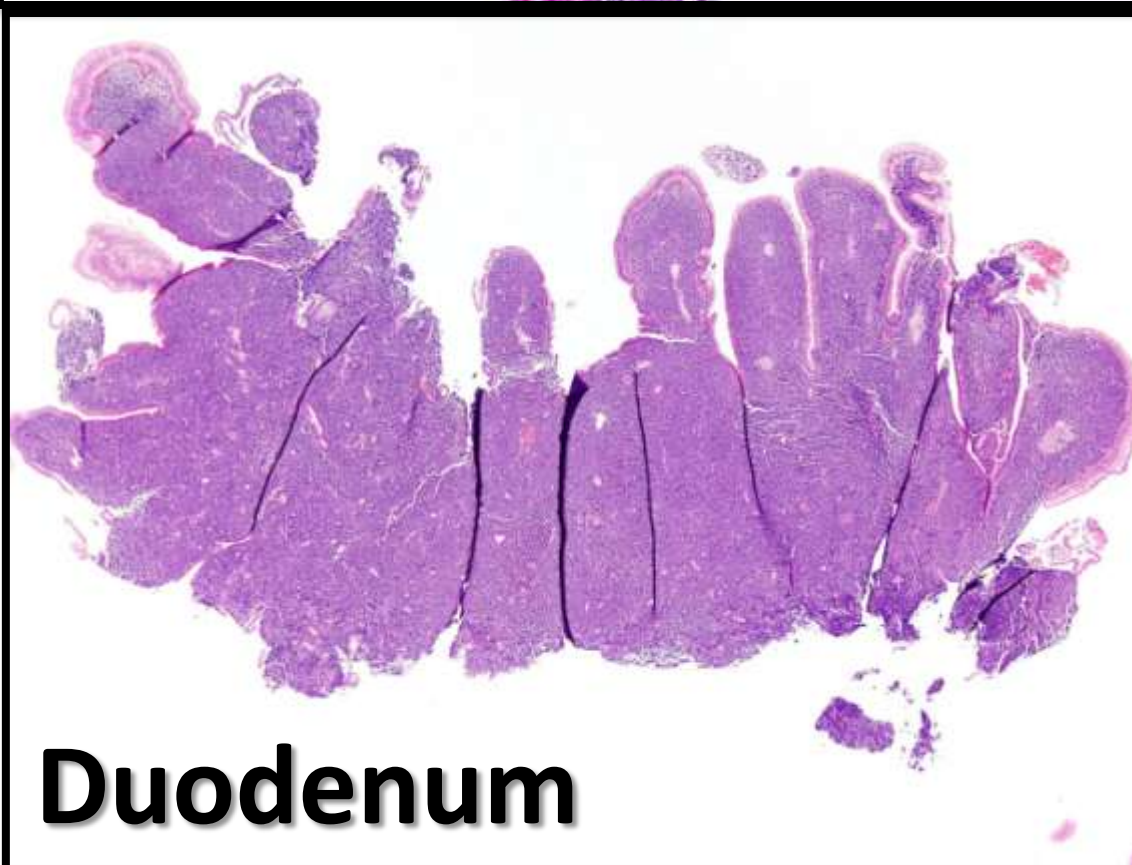
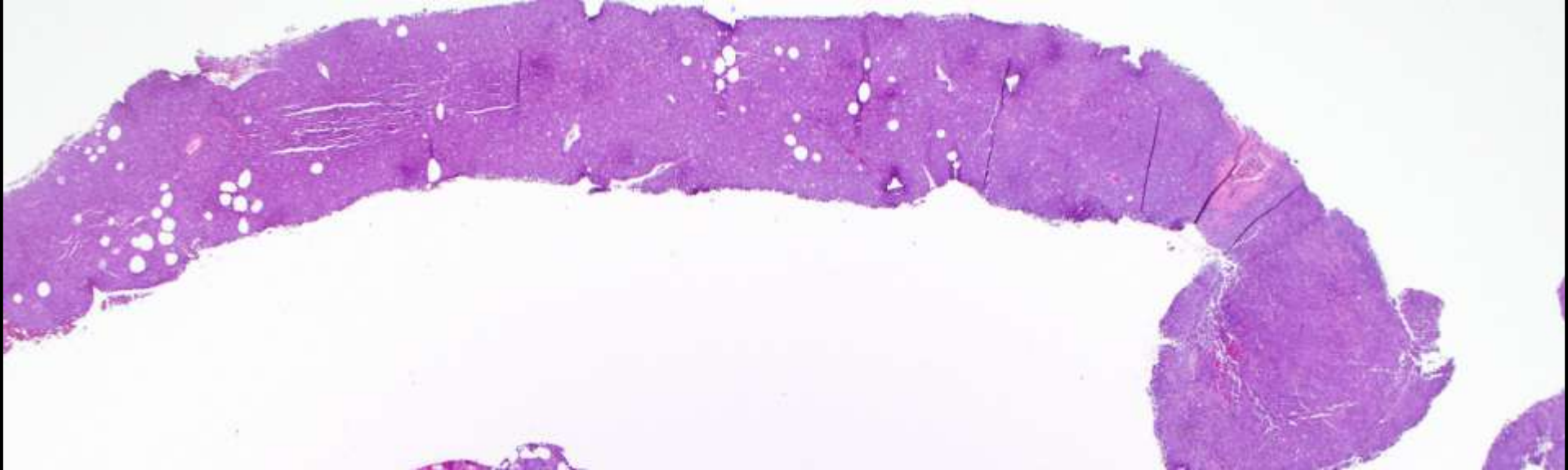
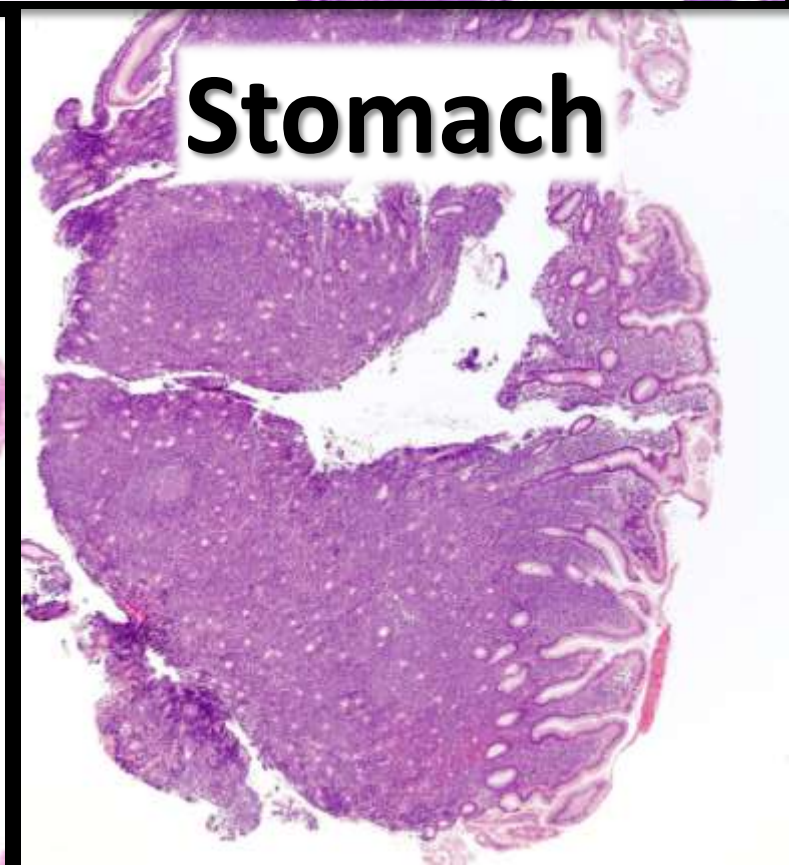

Case 8

- 49 year old previously healthy female with nausea and vomiting found to have retroperitoneal lymphadenopathy, gastric and duodenal masses, all of which were biopsied.

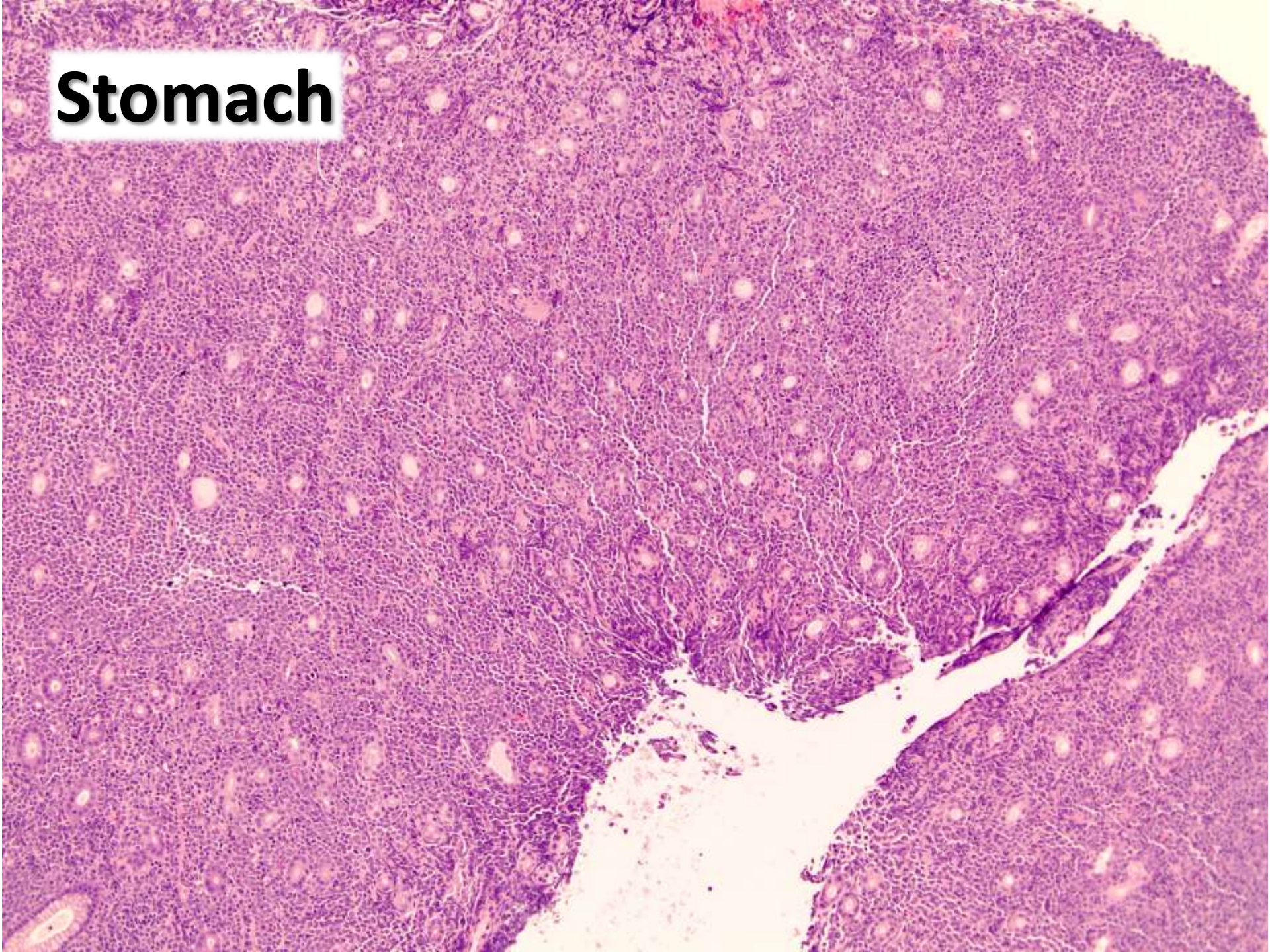


Duodenum

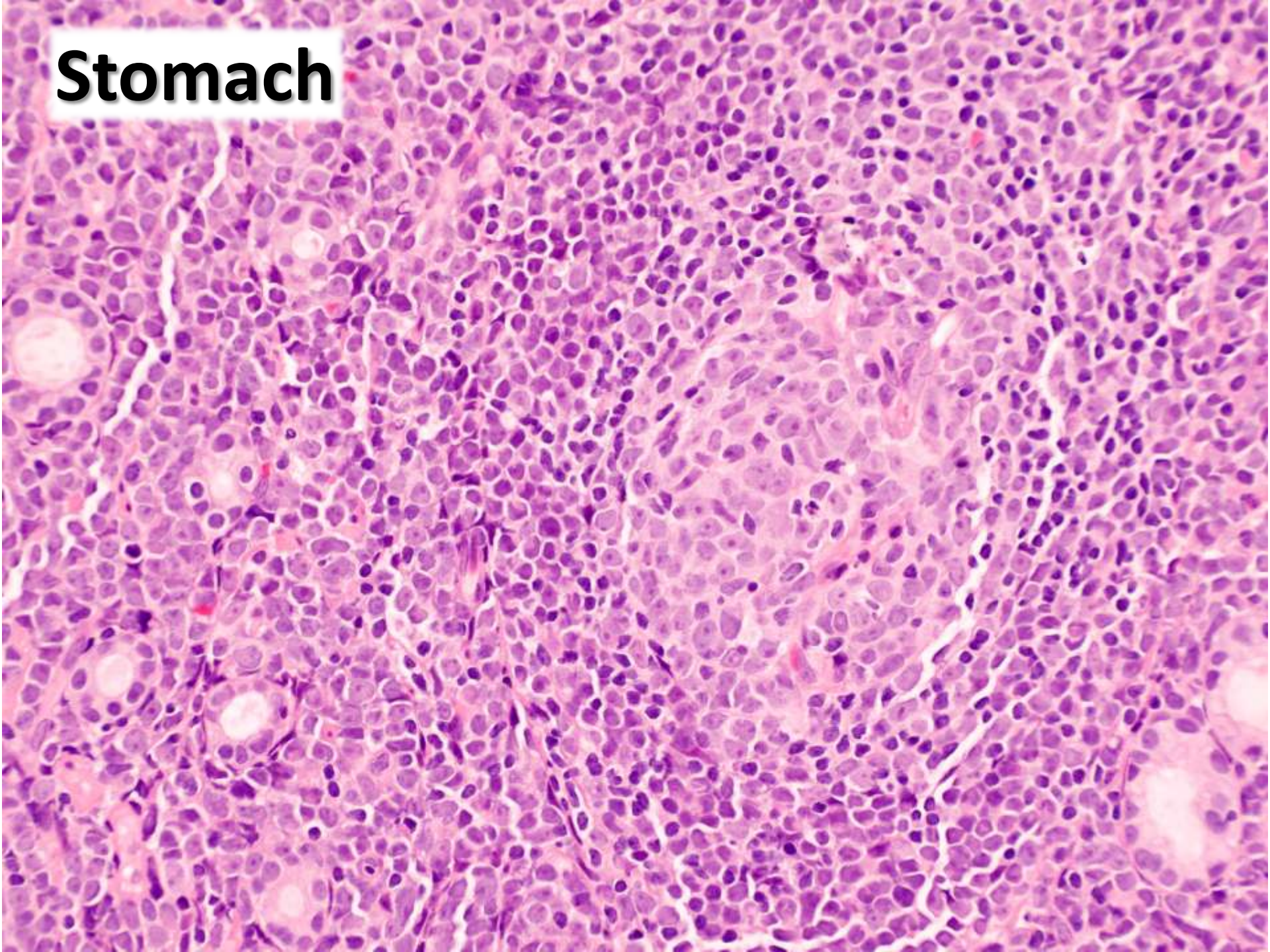


Stomach

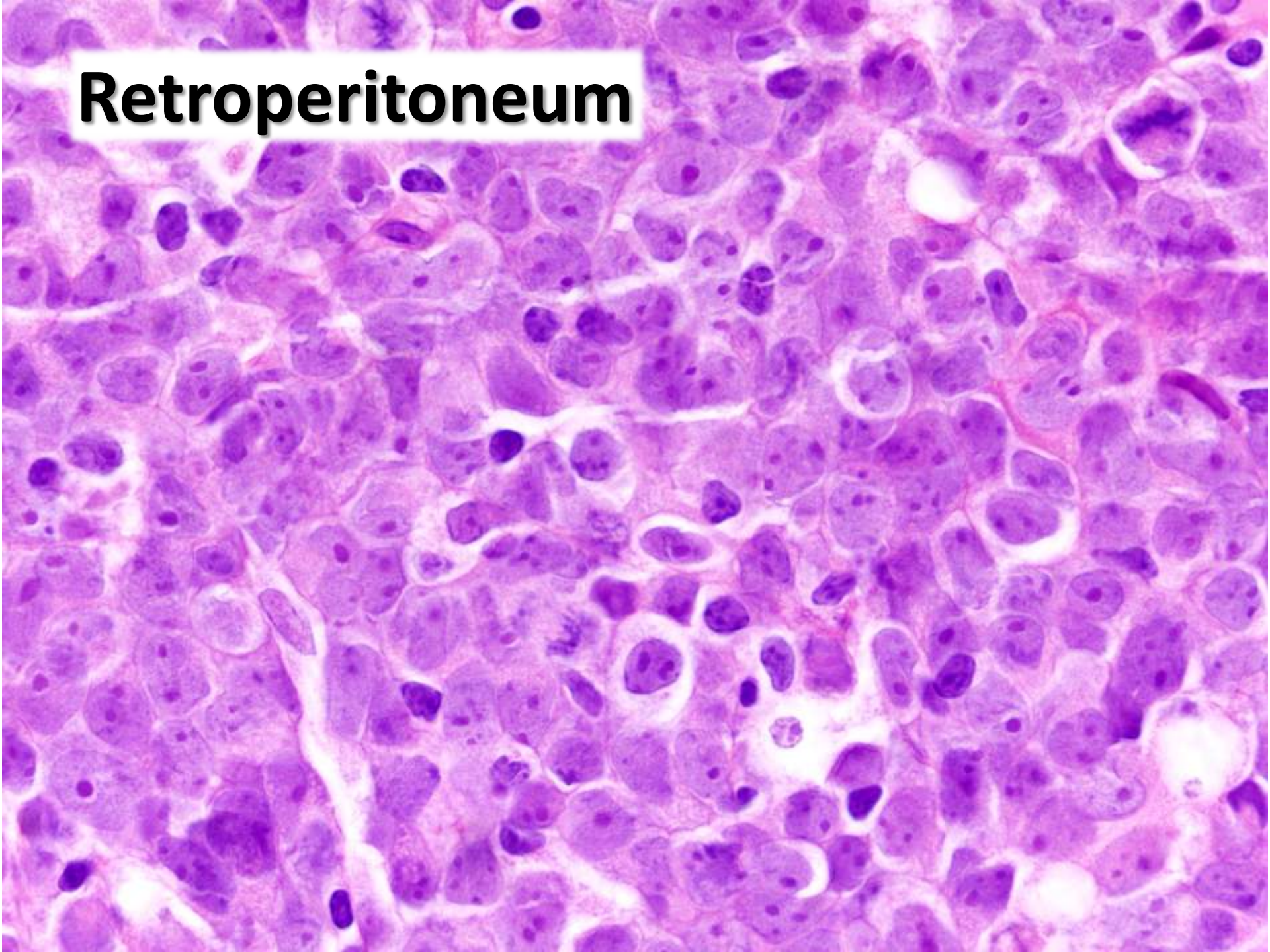
Stomach



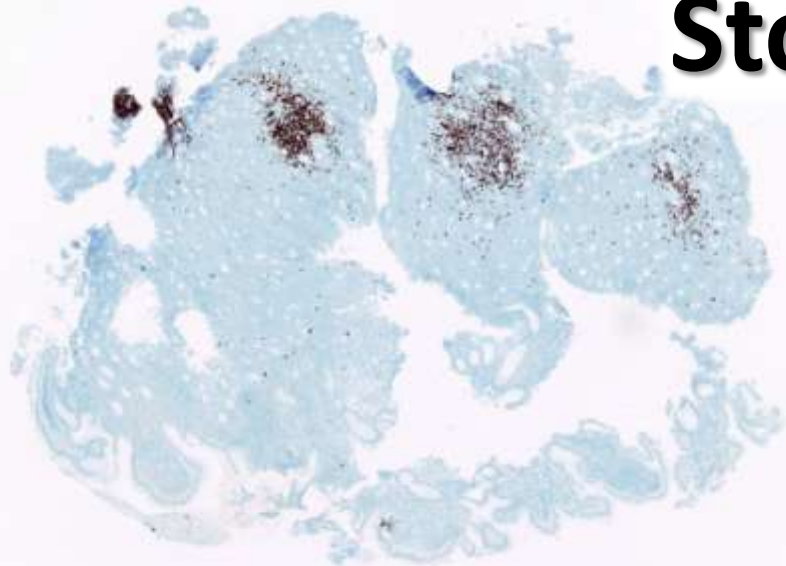
Stomach



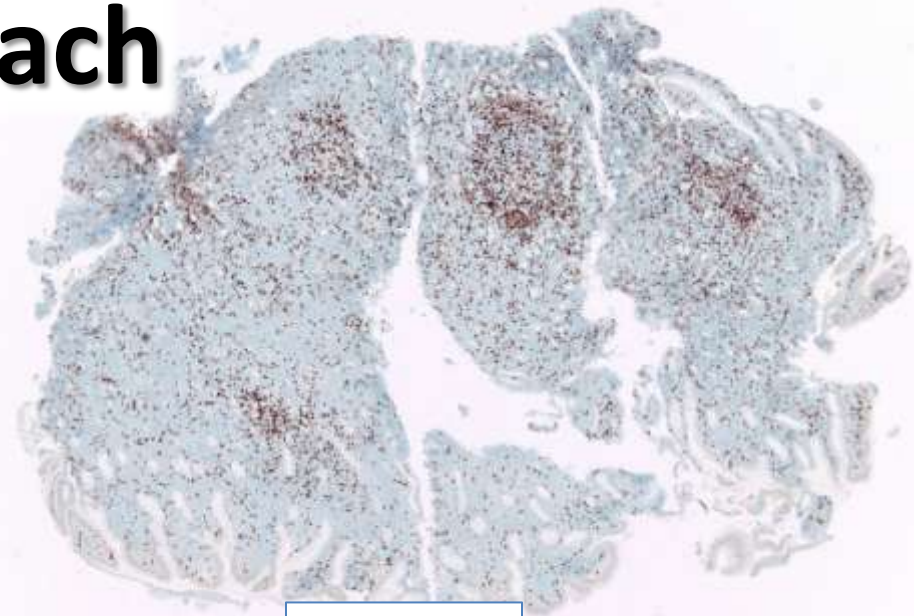
Retroperitoneum



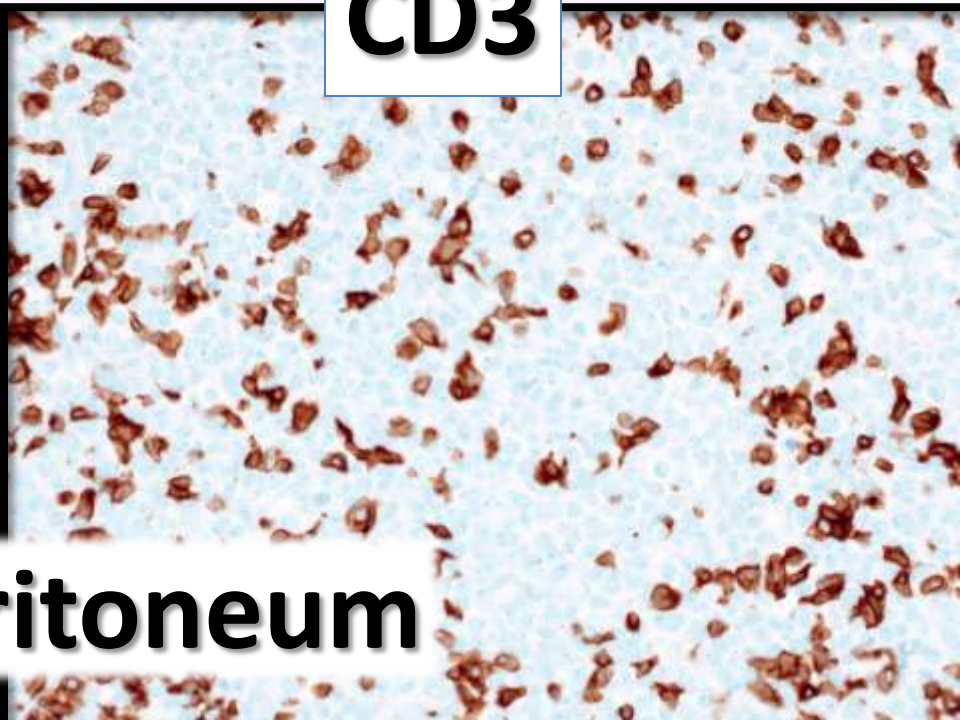
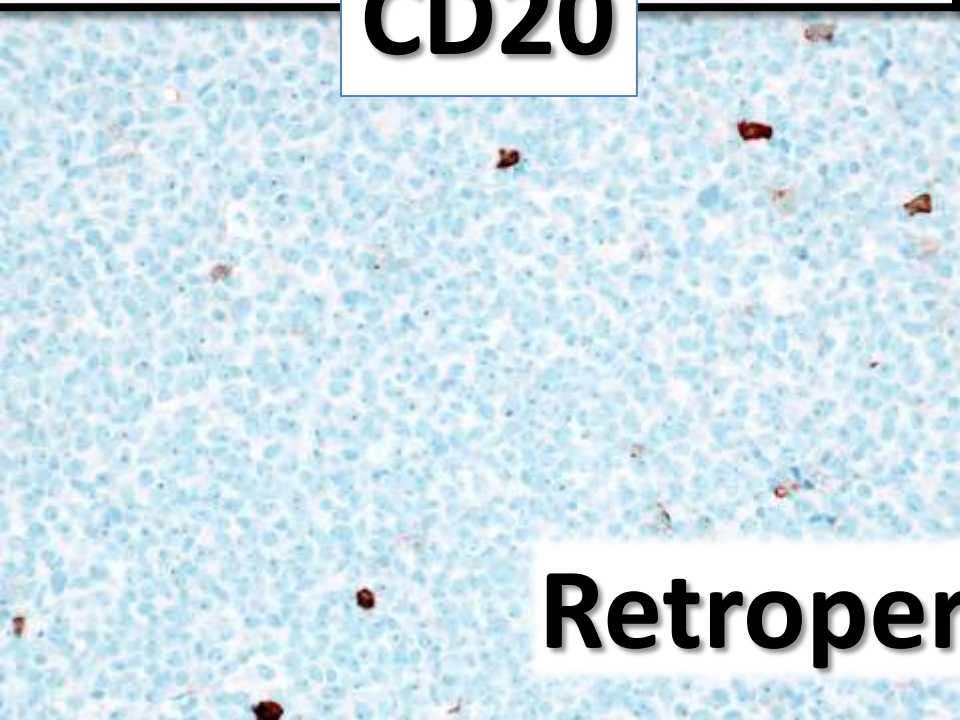
Stomach



CD20



CD3



Retroperitoneum