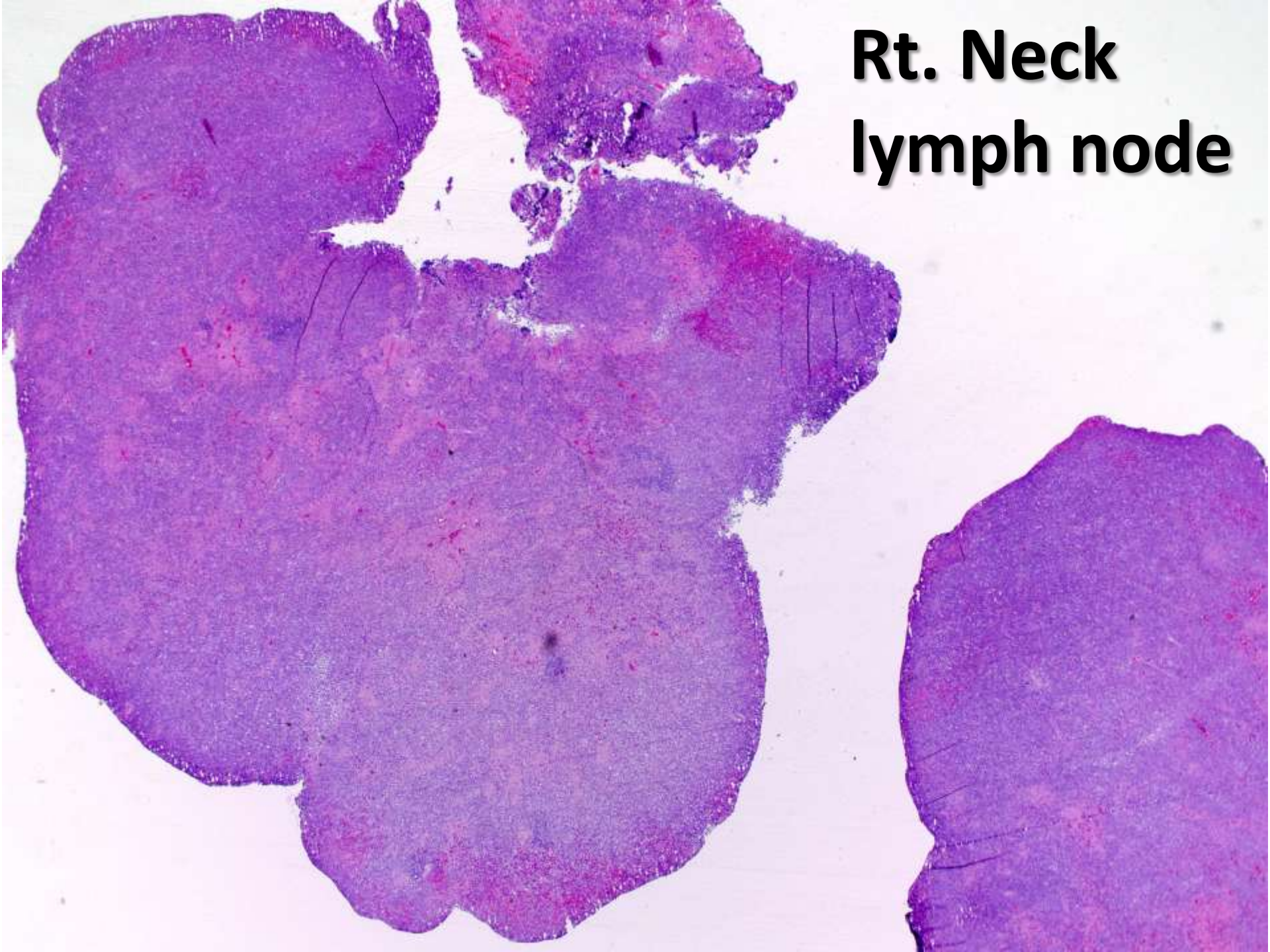


Case 2

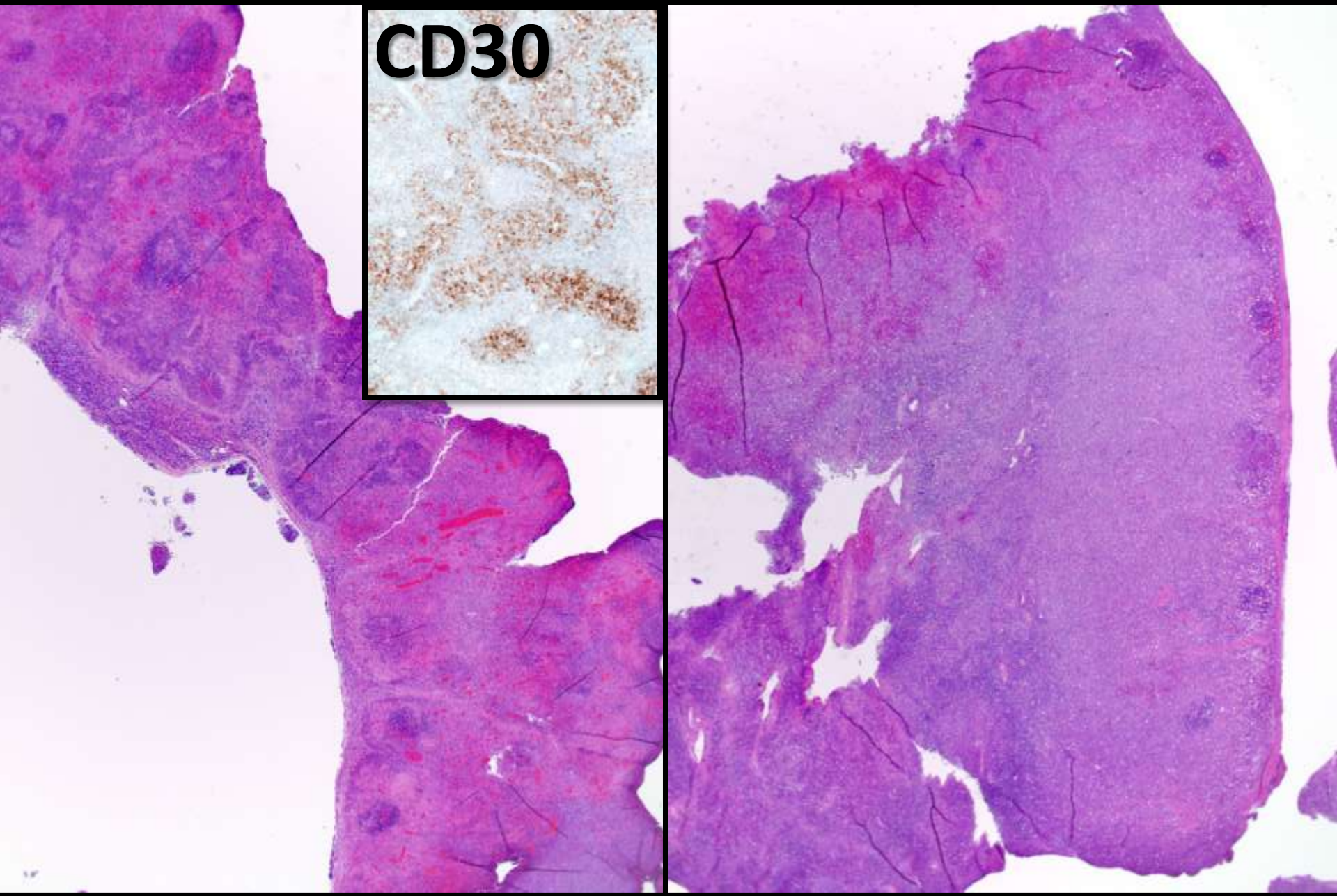
- 18 year old male who presented with a sore throat that did not respond to antibiotics or steroids – monospot, throat cultures and strep screens were reported to be negative. His symptoms progressed with severely enlarged tonsils, soft palate hypertrophy, bilateral bulky tender cervical adenopathy and splenomegaly. In spite of additional steroids, he developed jugular vein compression and also ultimately had to be intubated. He then underwent a tracheostomy, bilateral neck lymph node biopsies and a right tonsillar biopsy.

**Rt. Neck
lymph node**

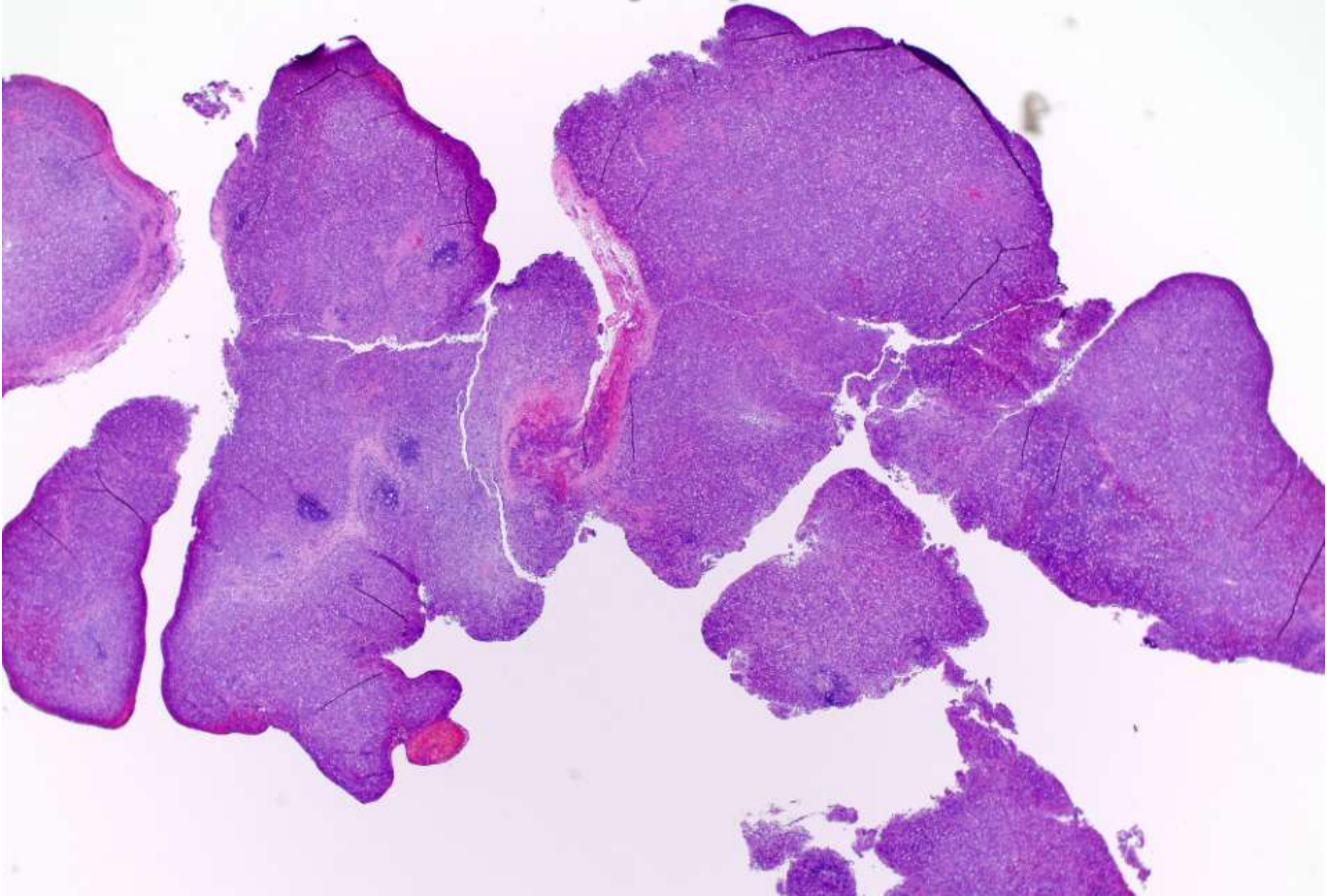


Lt. neck lymph node

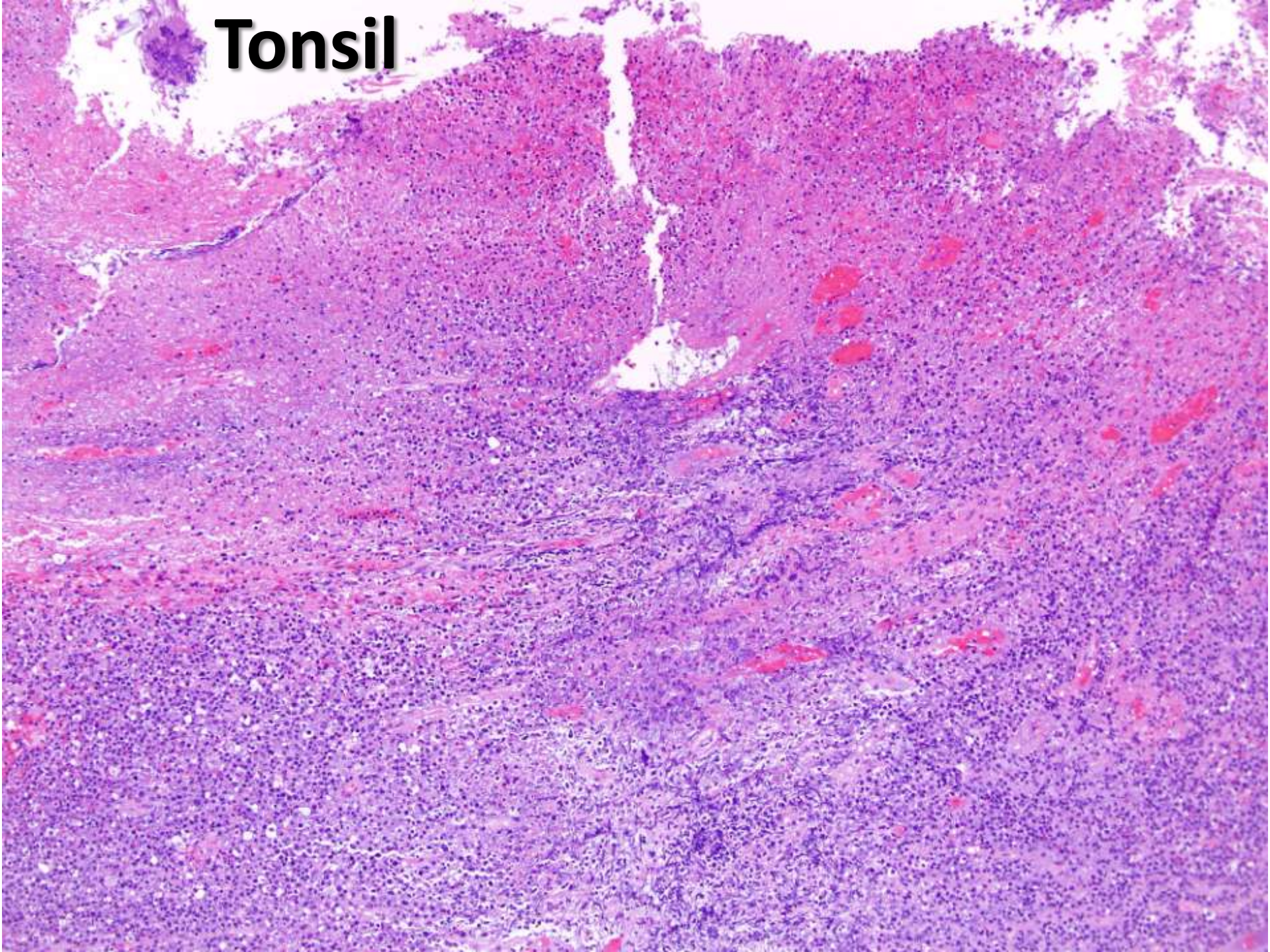
CD30



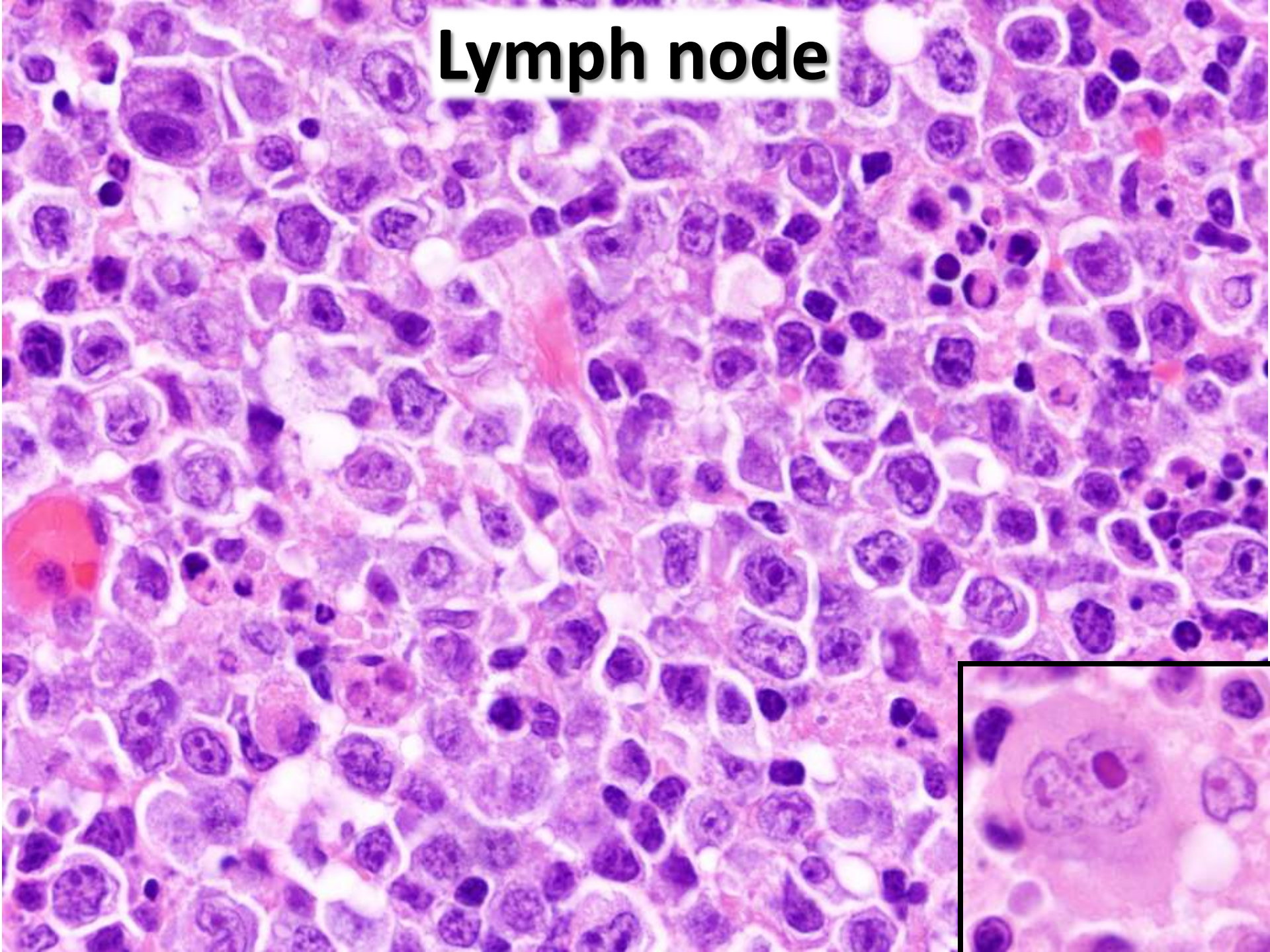
Lt. neck lymph node



Tonsil



Lymph node



Tonsil

