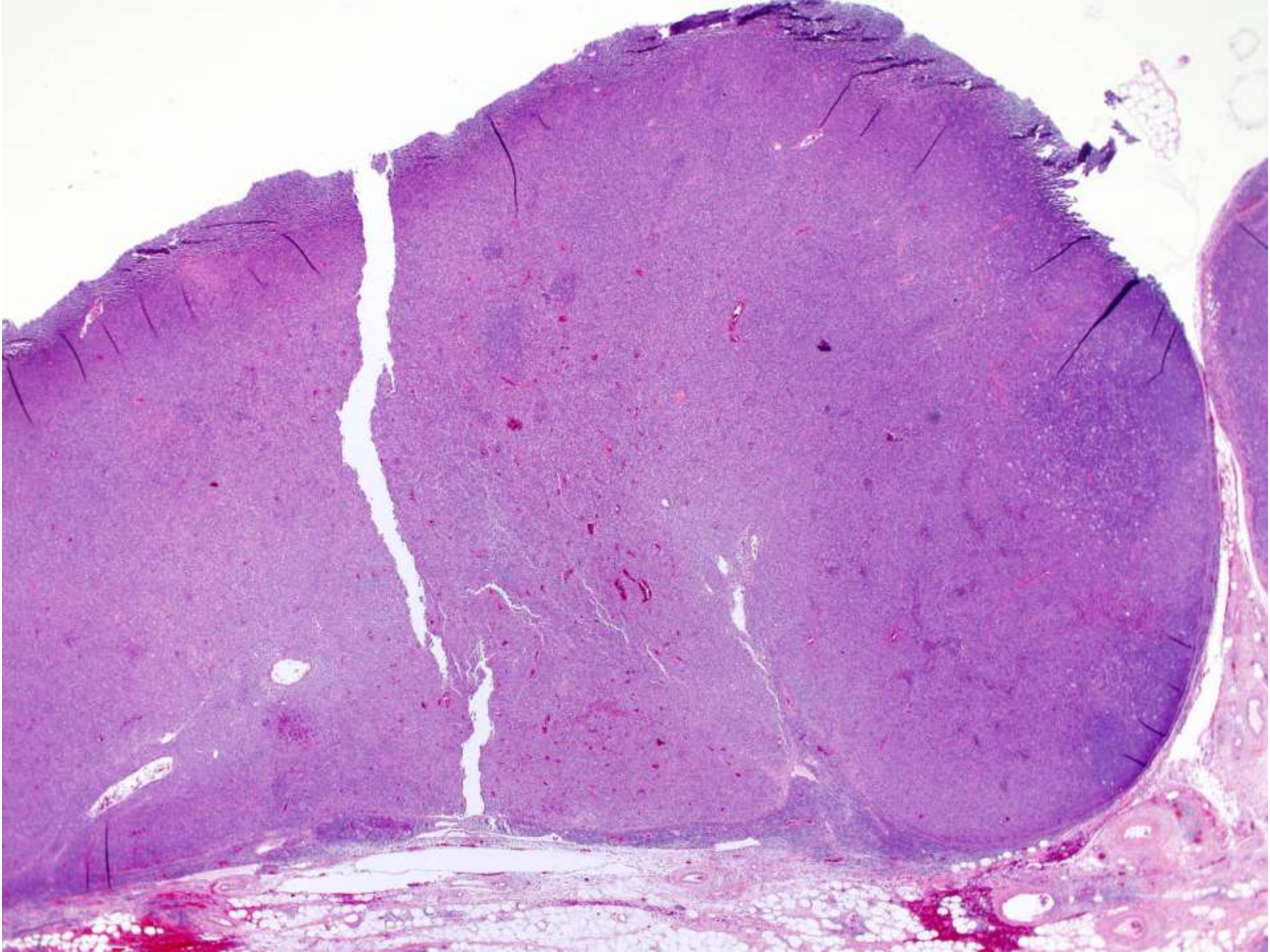
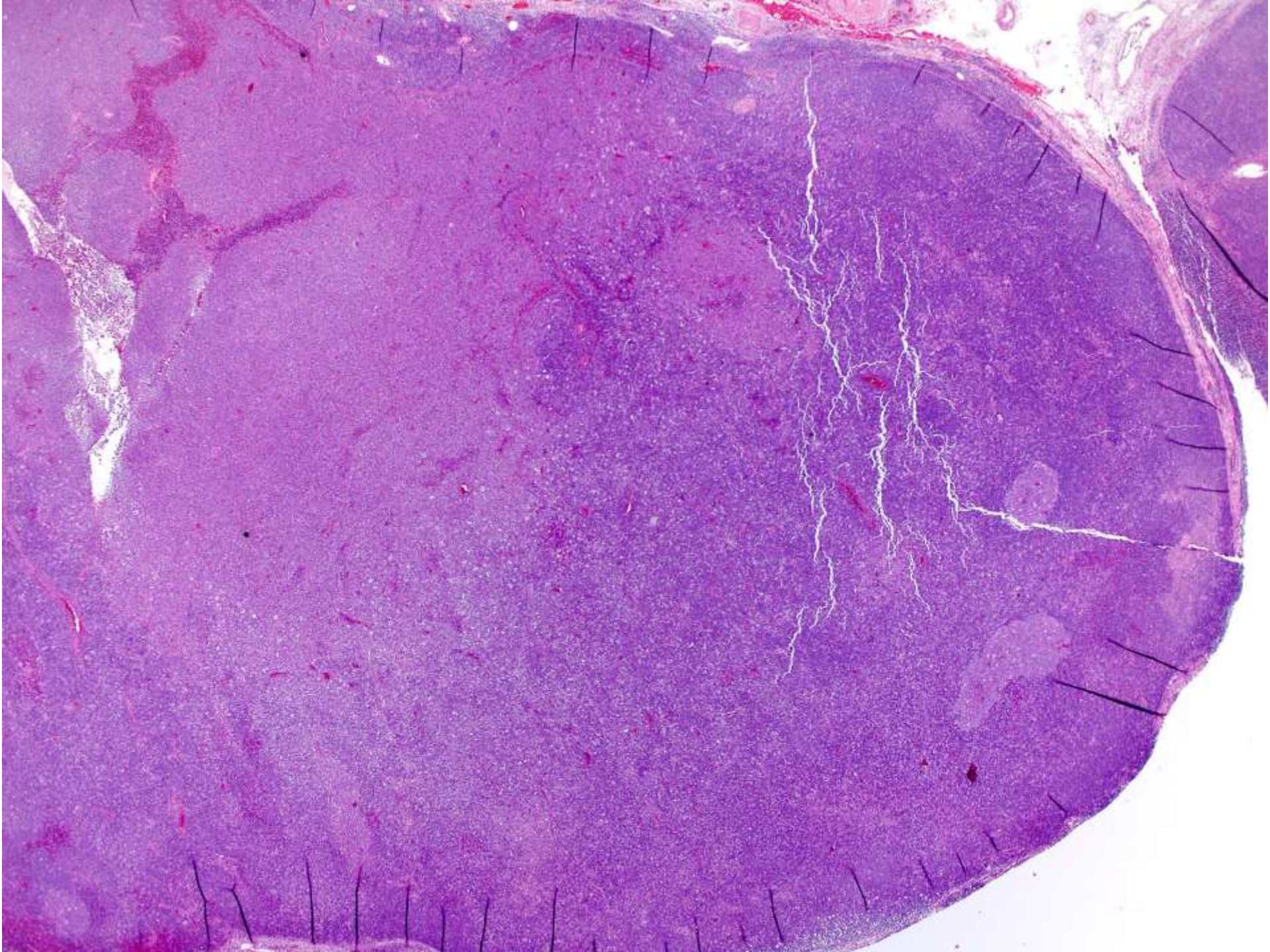


# Case 1

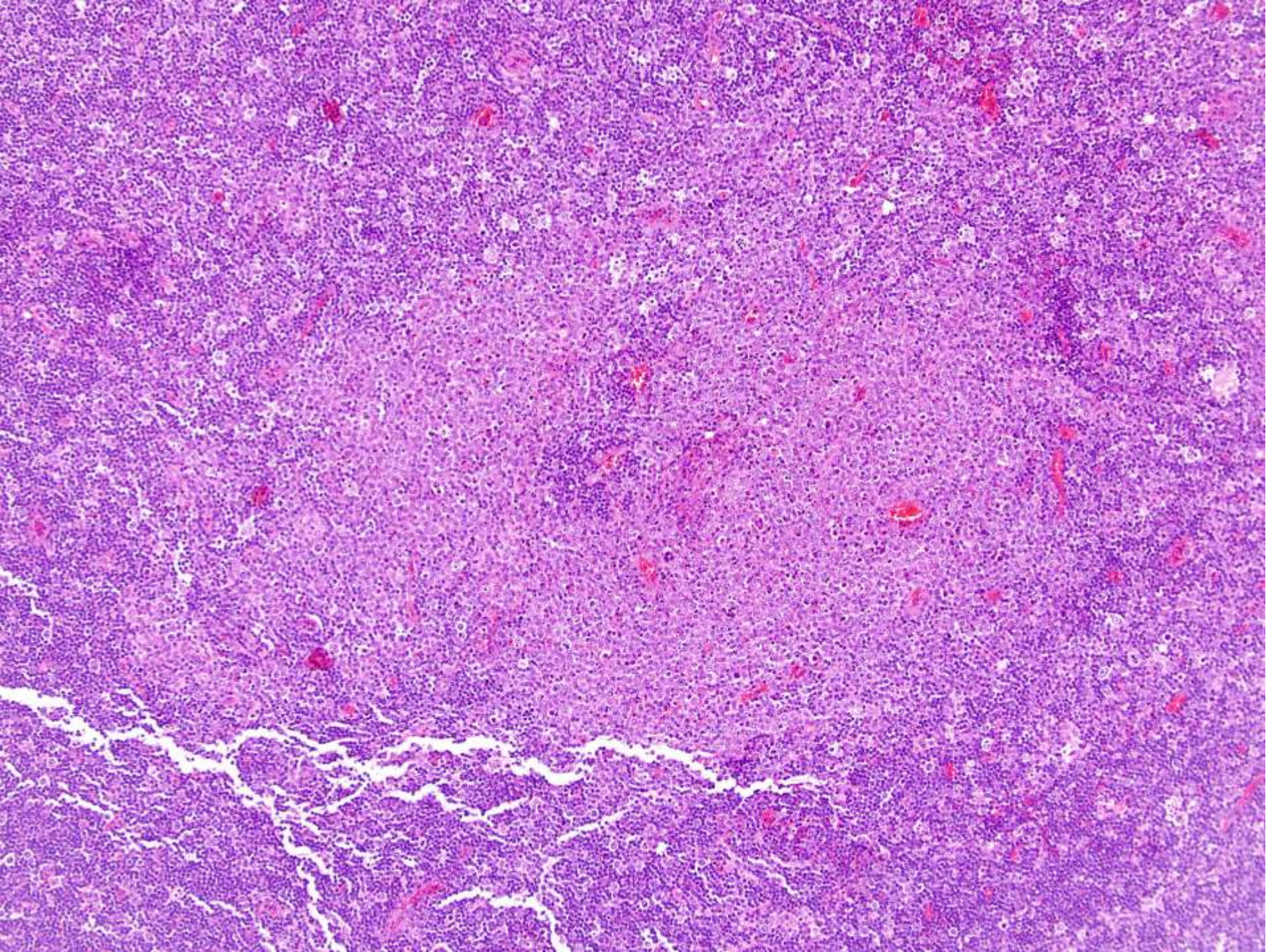
- 46 year old female who noticed some swollen lymph nodes in the left lower neck but was otherwise asymptomatic. The adenopathy progressed under observation. A CT scan showed “mildly inflamed” left-sided neck lymph nodes and slightly prominent right-sided lymph nodes with a differential diagnosis provided of inflammatory adenopathy versus lymphoma. A left posterior cervical lymph node biopsy was performed several months following her initial presentation.



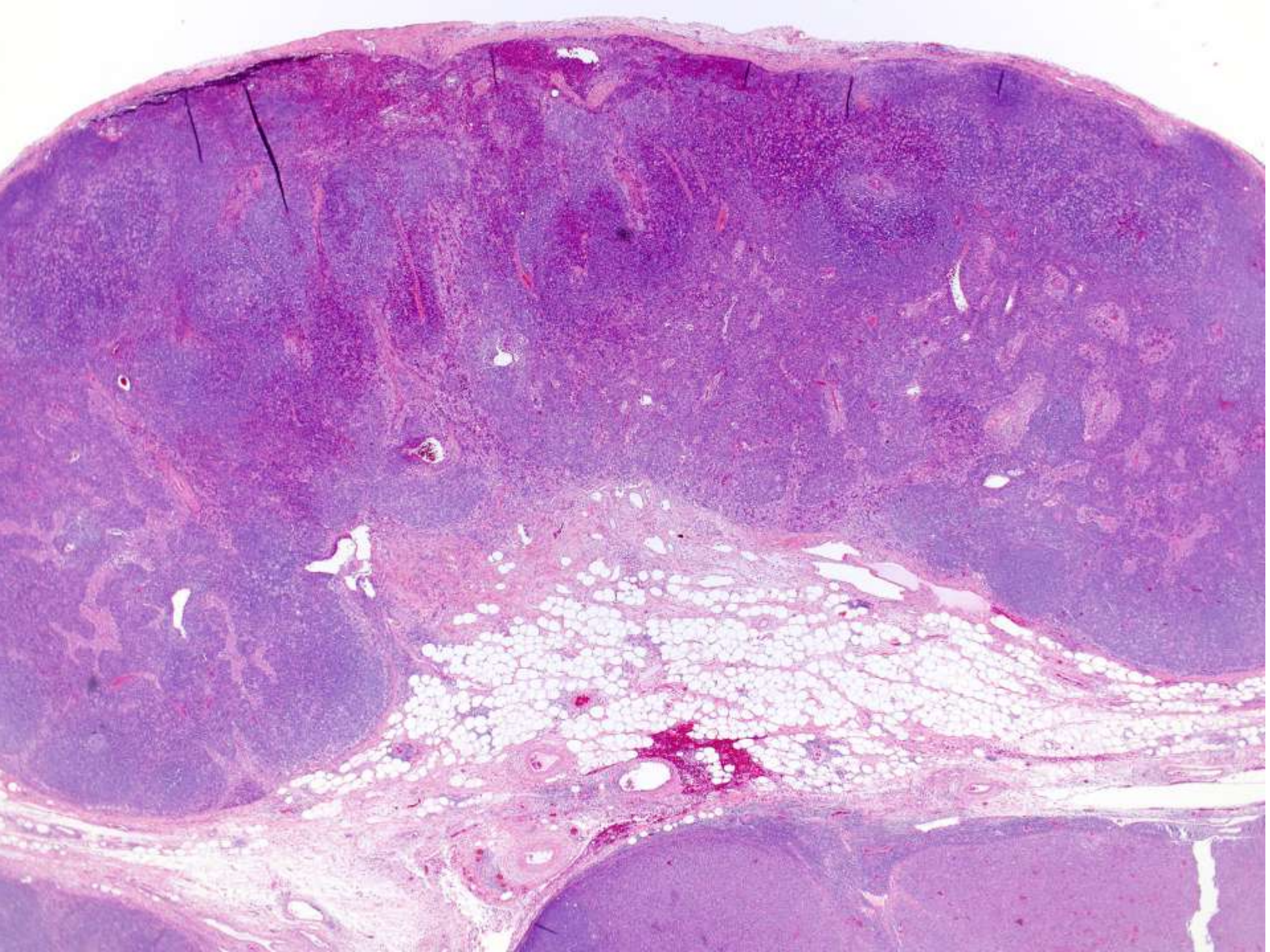




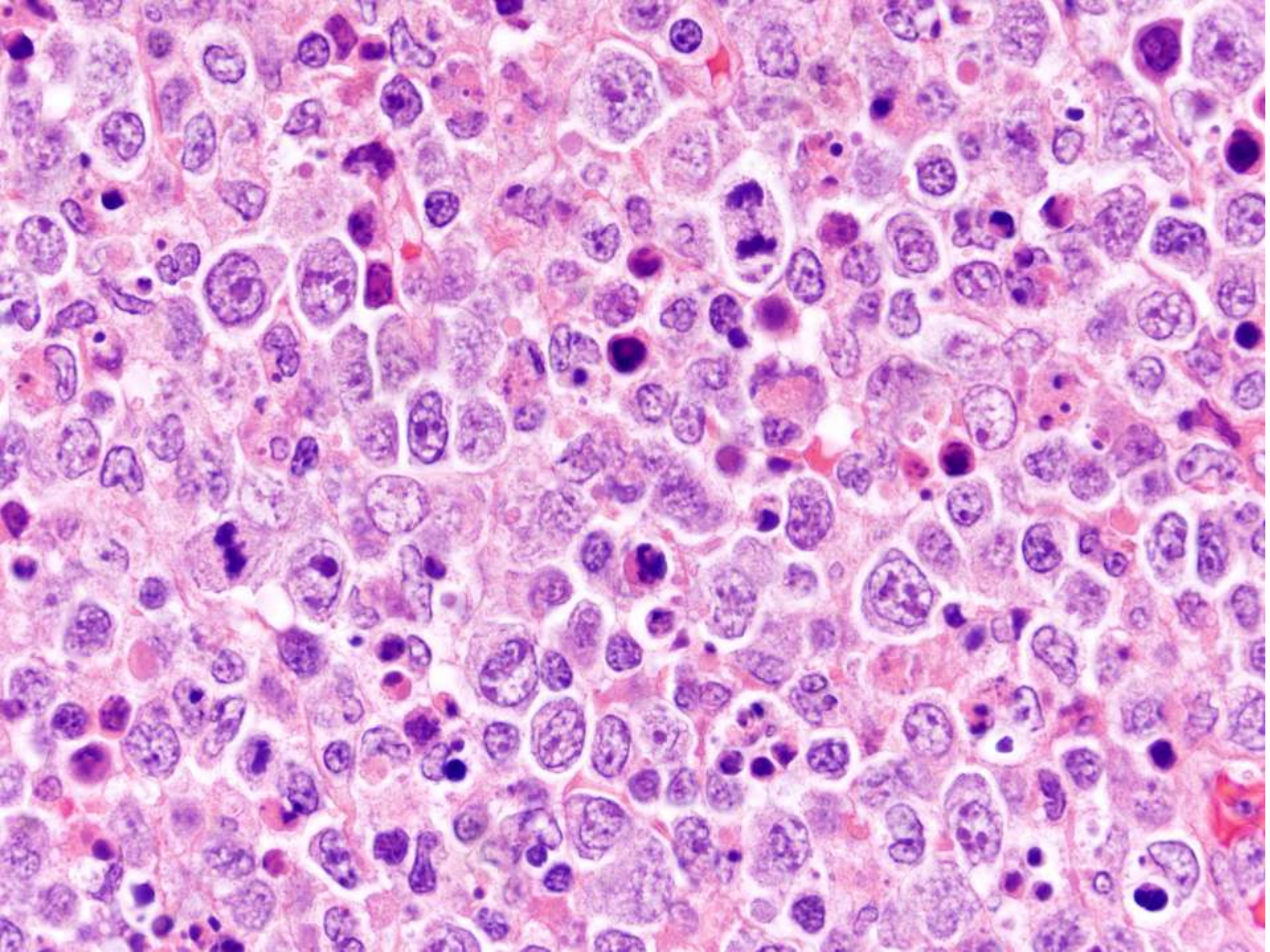






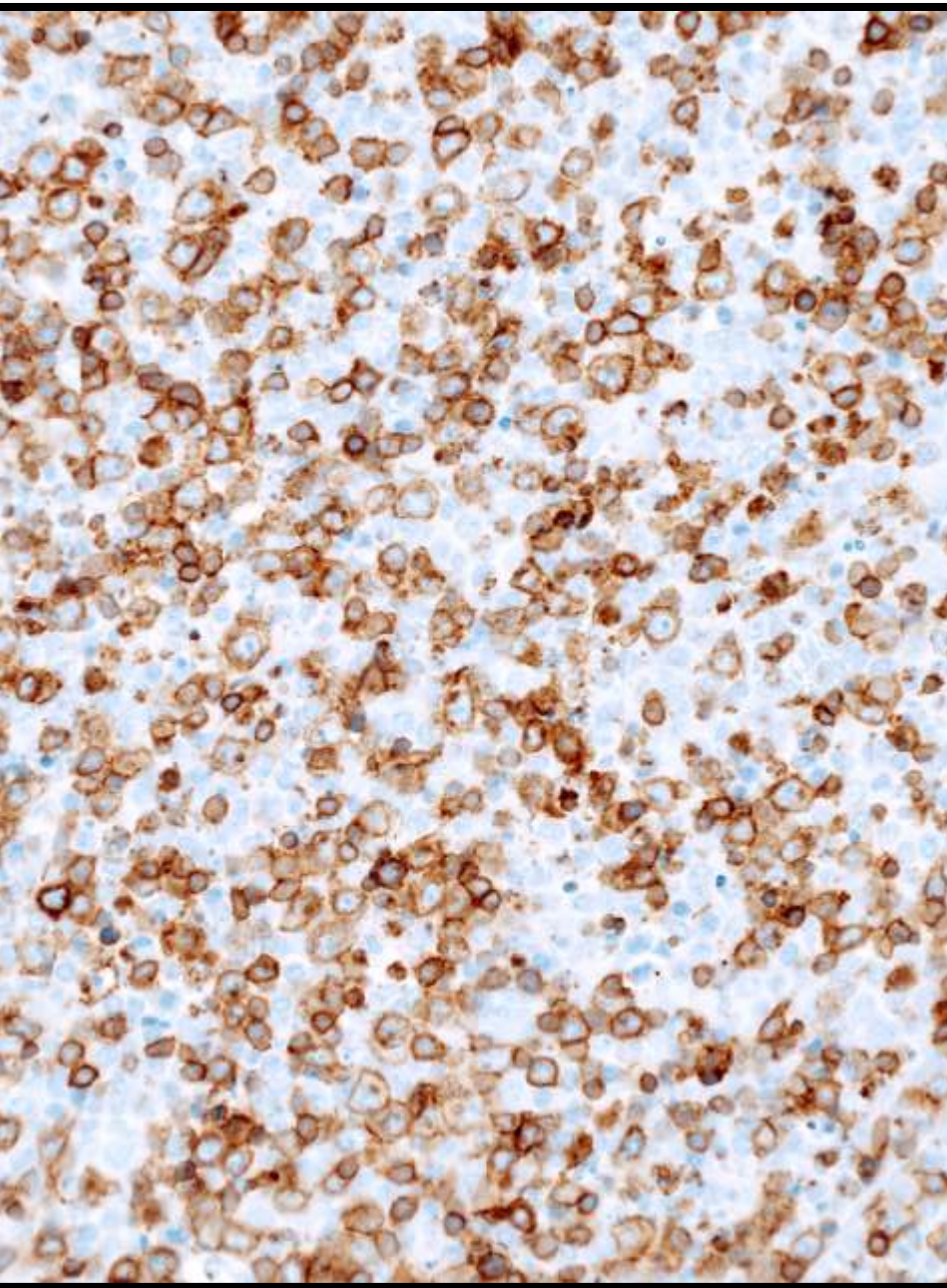








**CD3**



**Ki-67**

