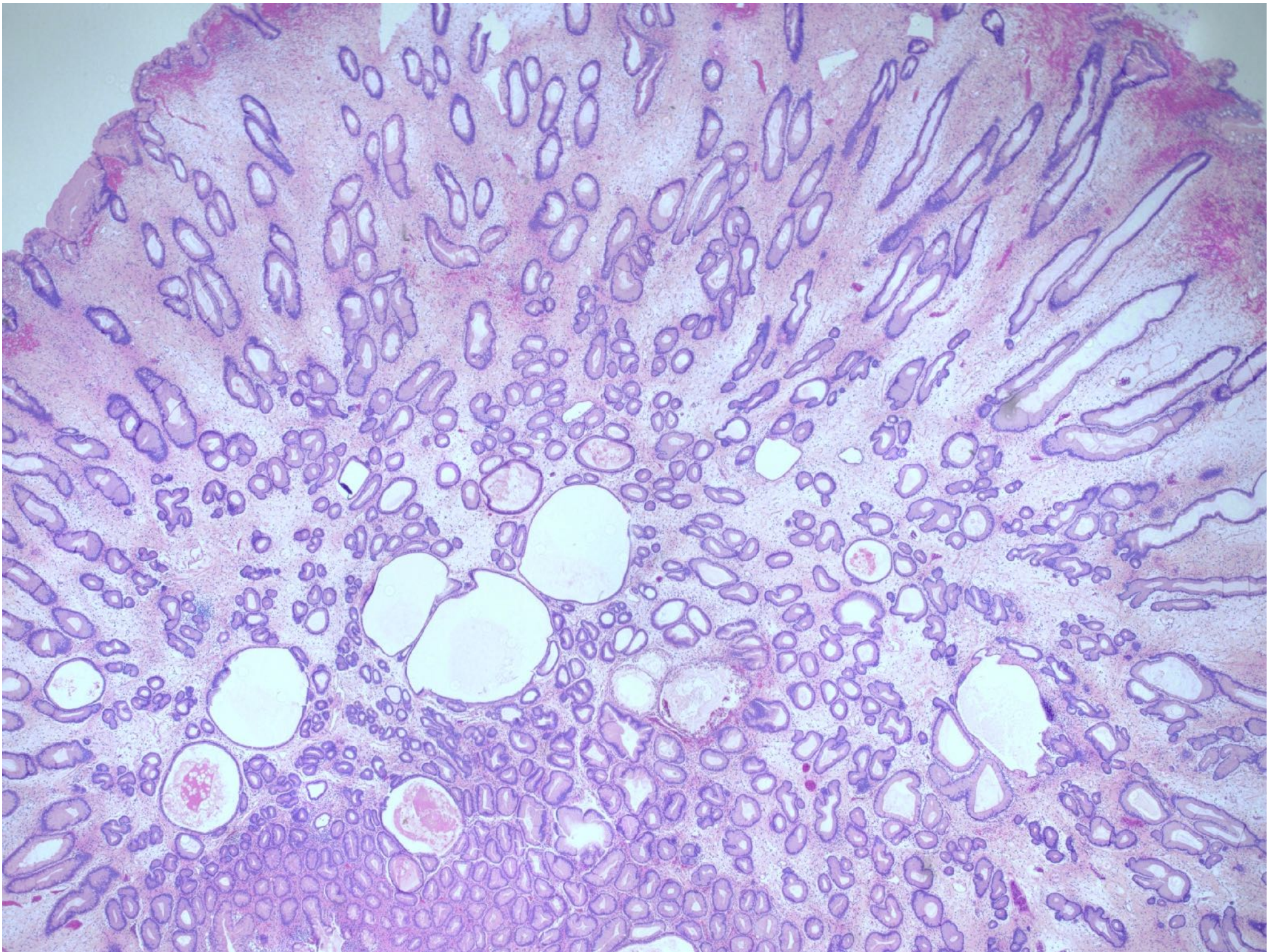
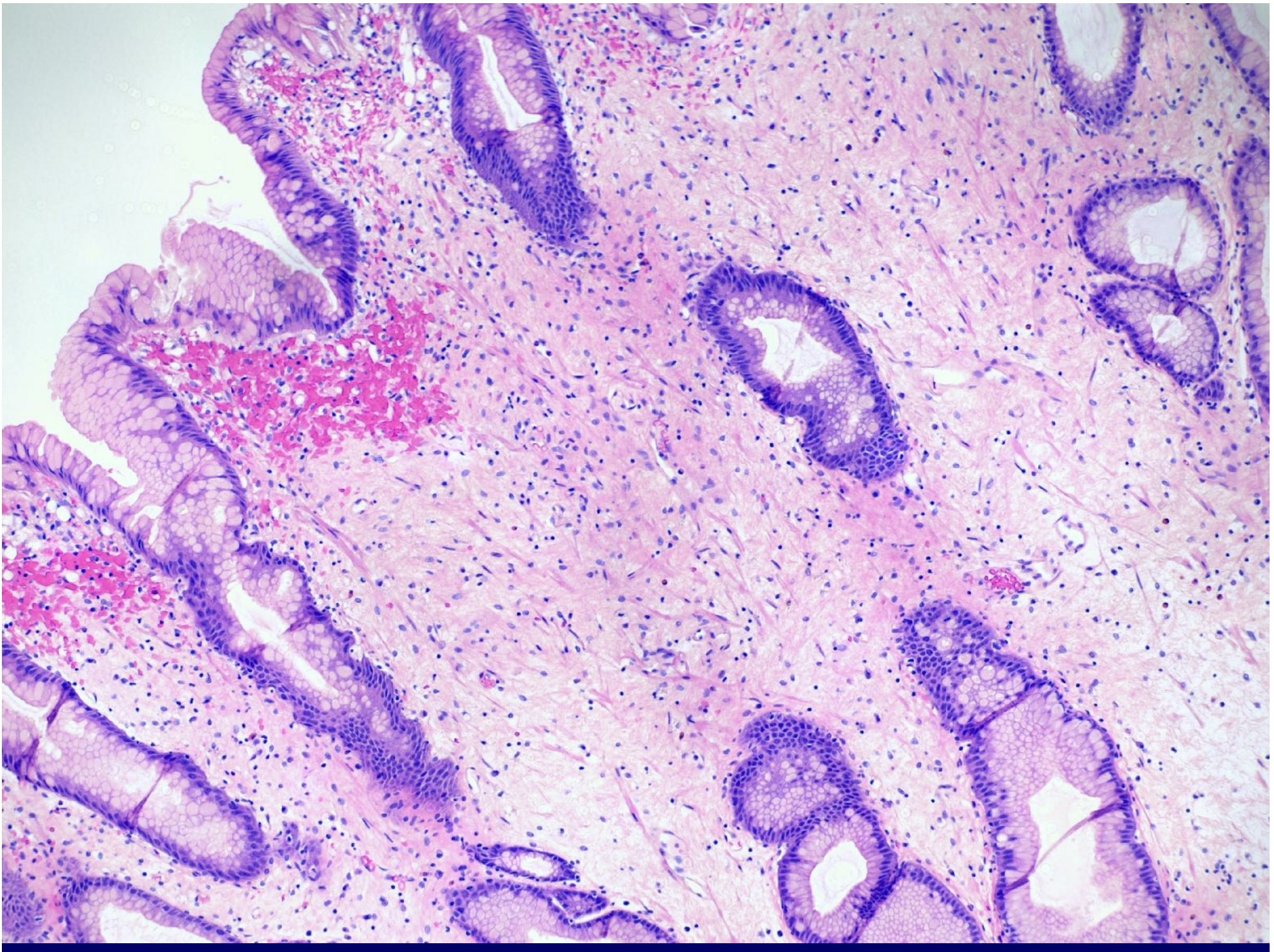
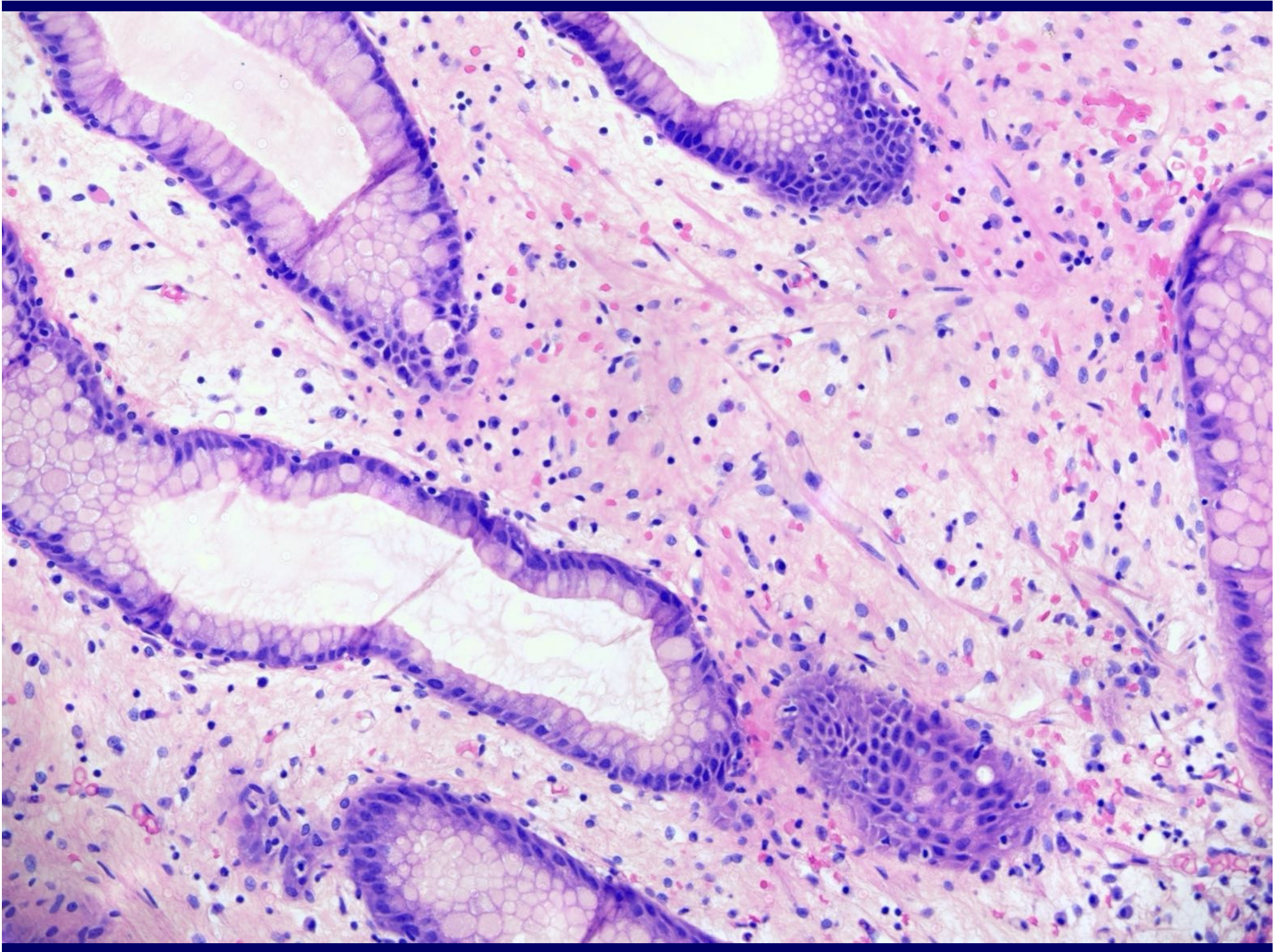


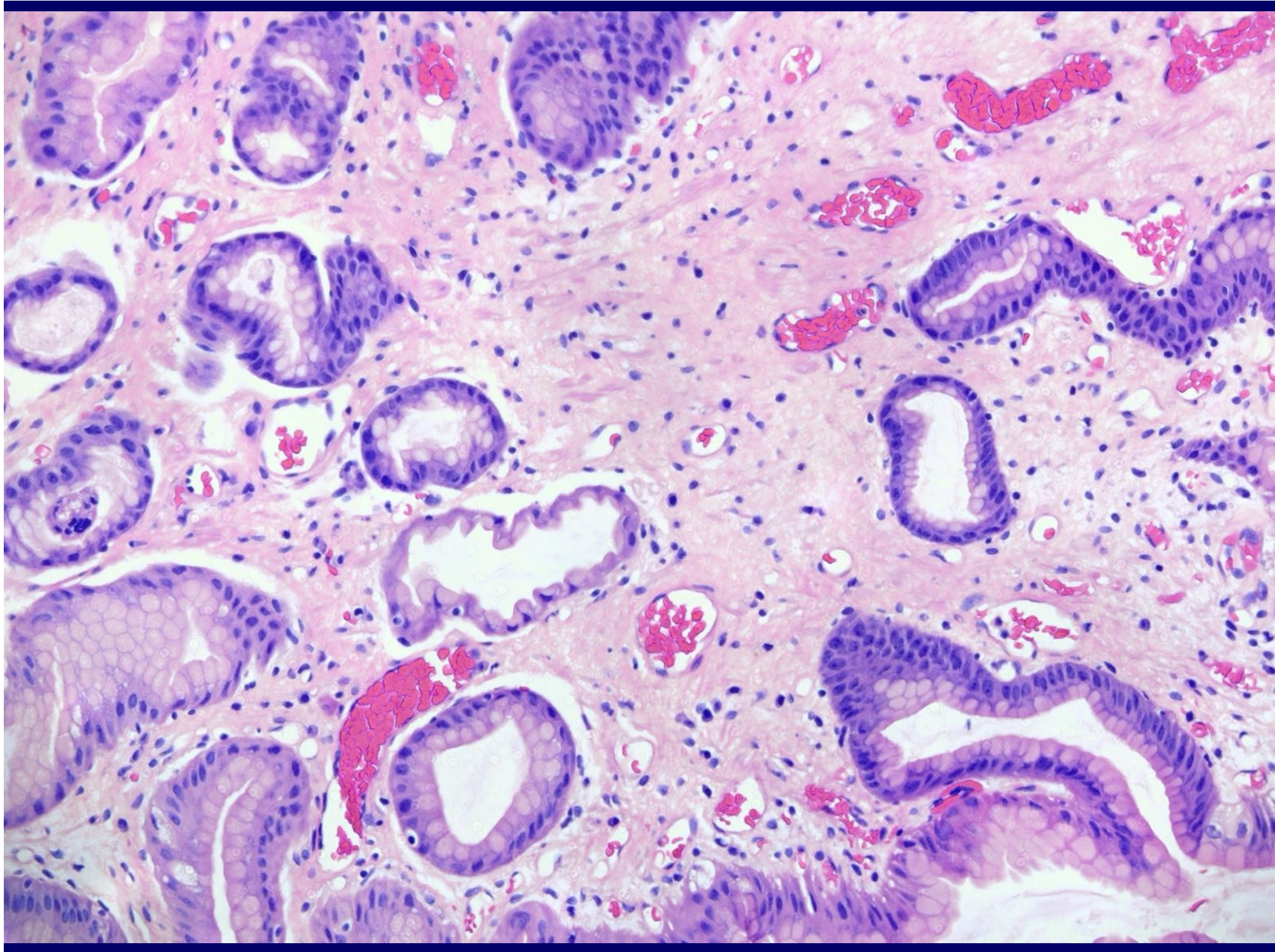
# Case History

- 65-year-old male with weight loss, watery diarrhea, malabsorption, & hypoproteinemia









# Case History

- 54-year-old female with dysphagia, rule out EoE

