

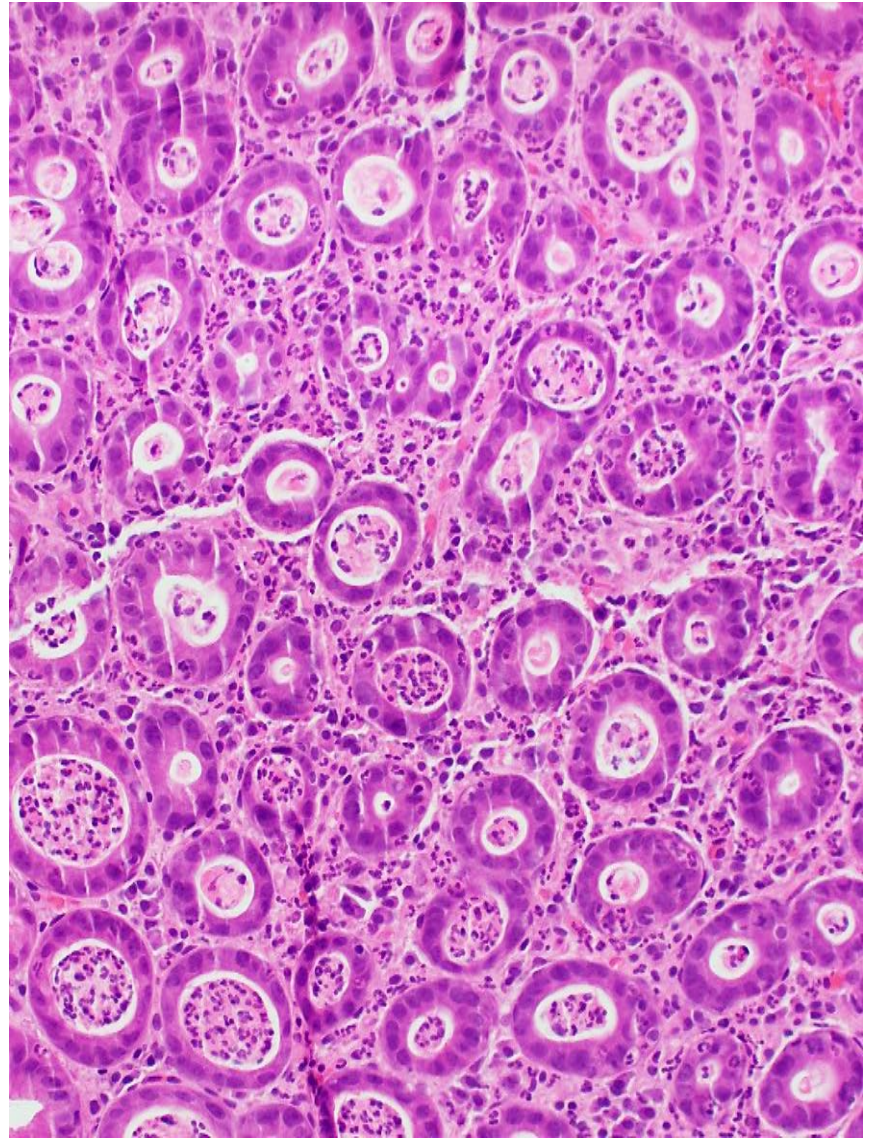
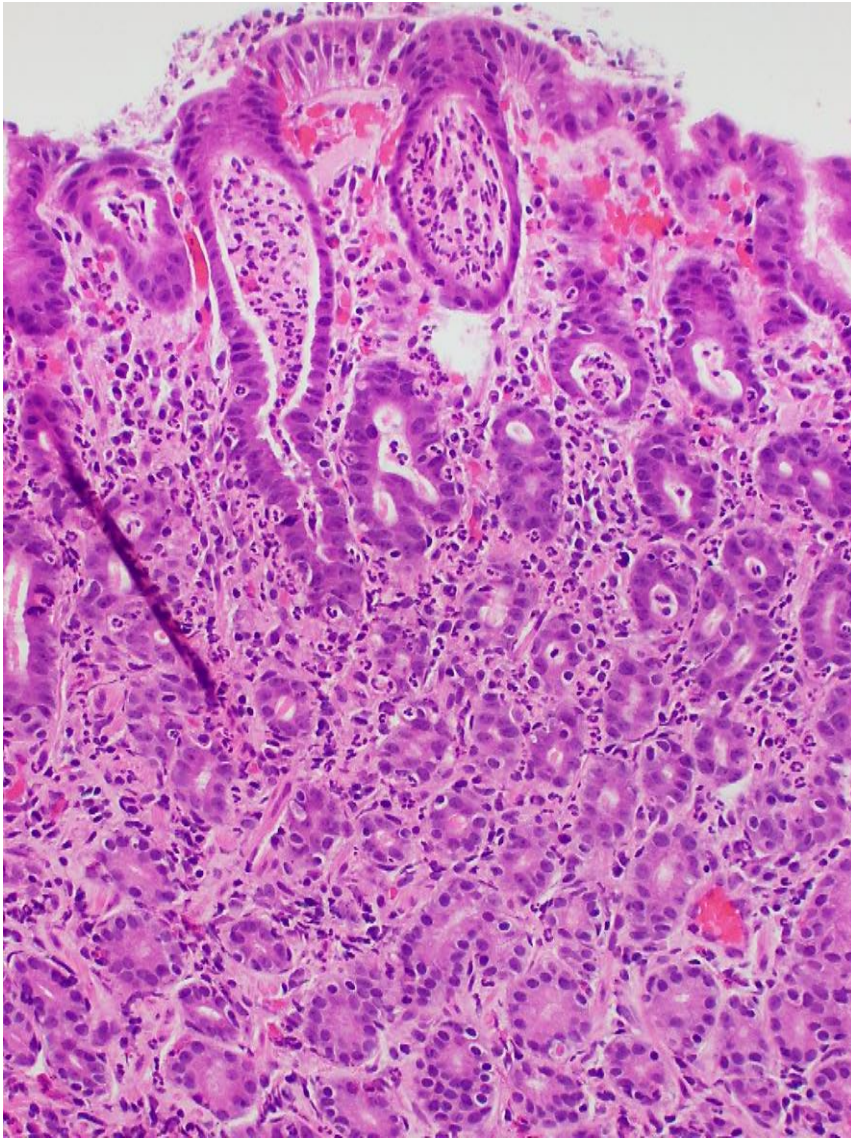
SOUTH BAY PATHOLOGY SOCIETY

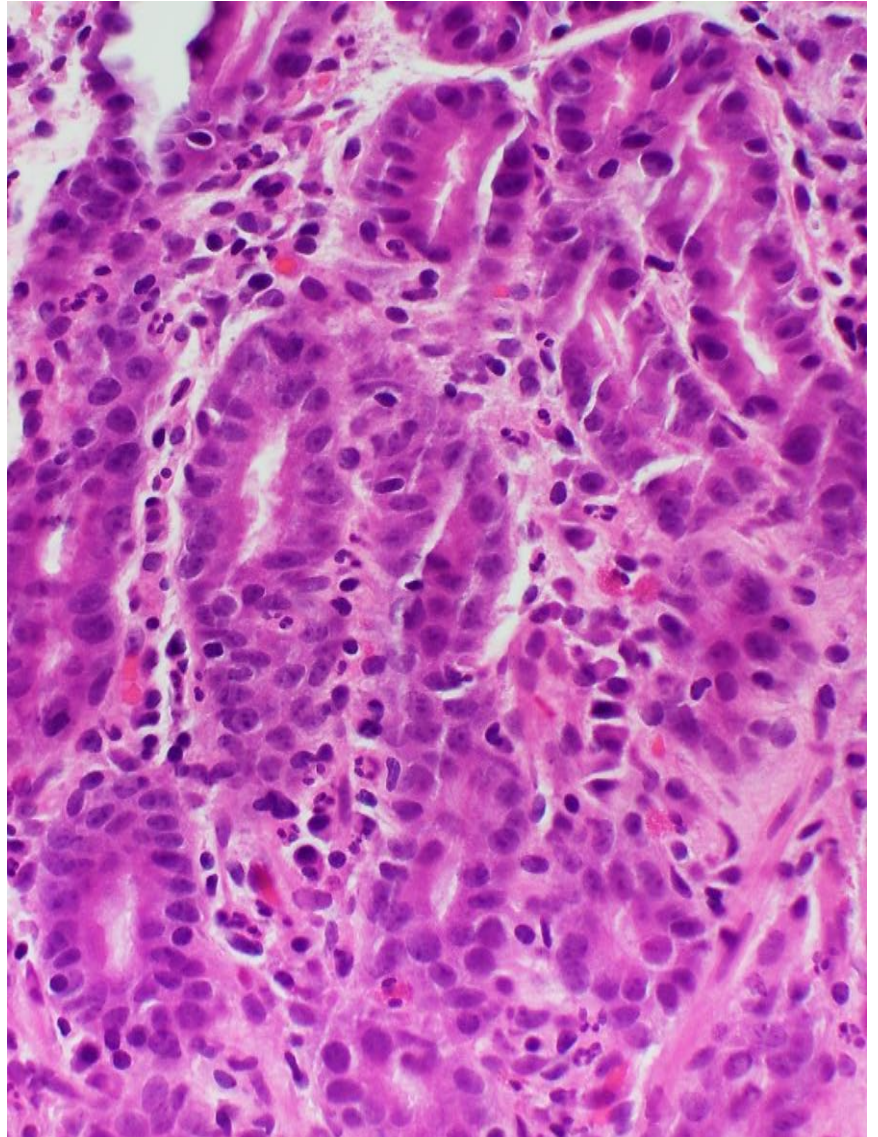
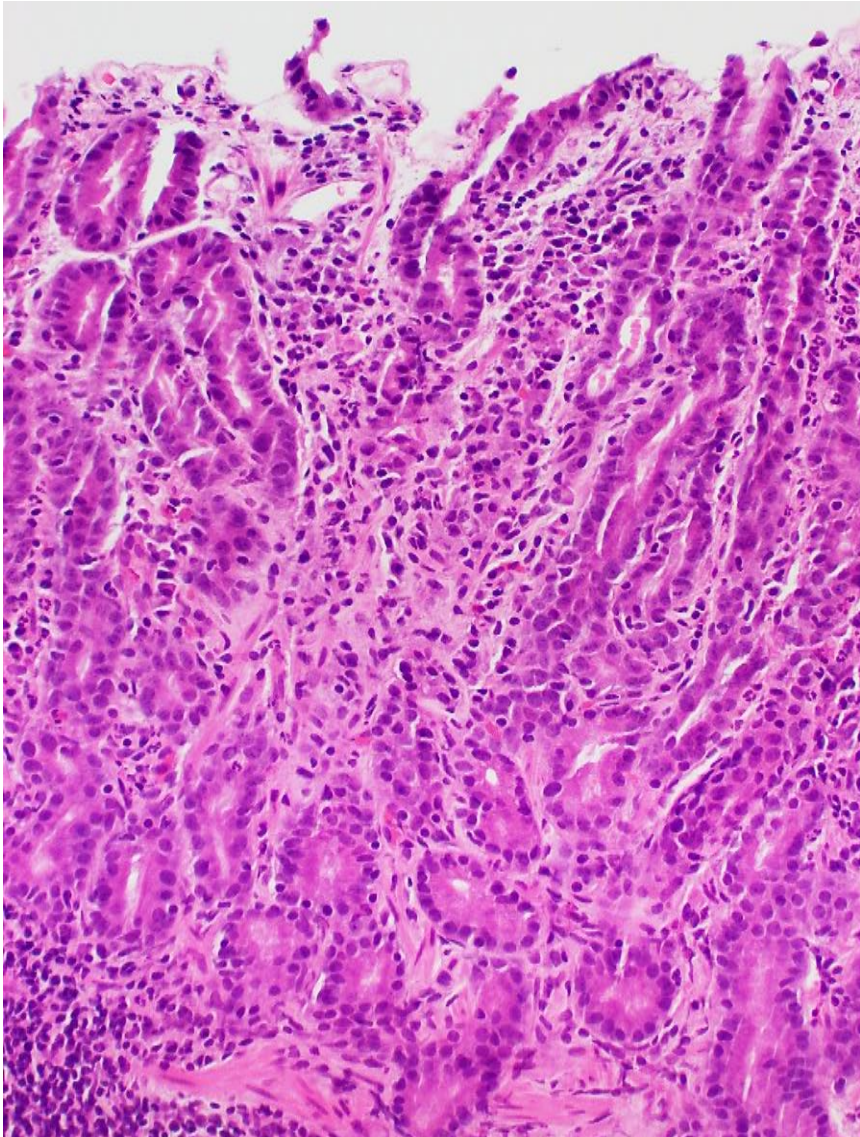
Case preview

G.Y. Lauwers, MD
Moffitt Cancer Center

Clinical History – Case 1

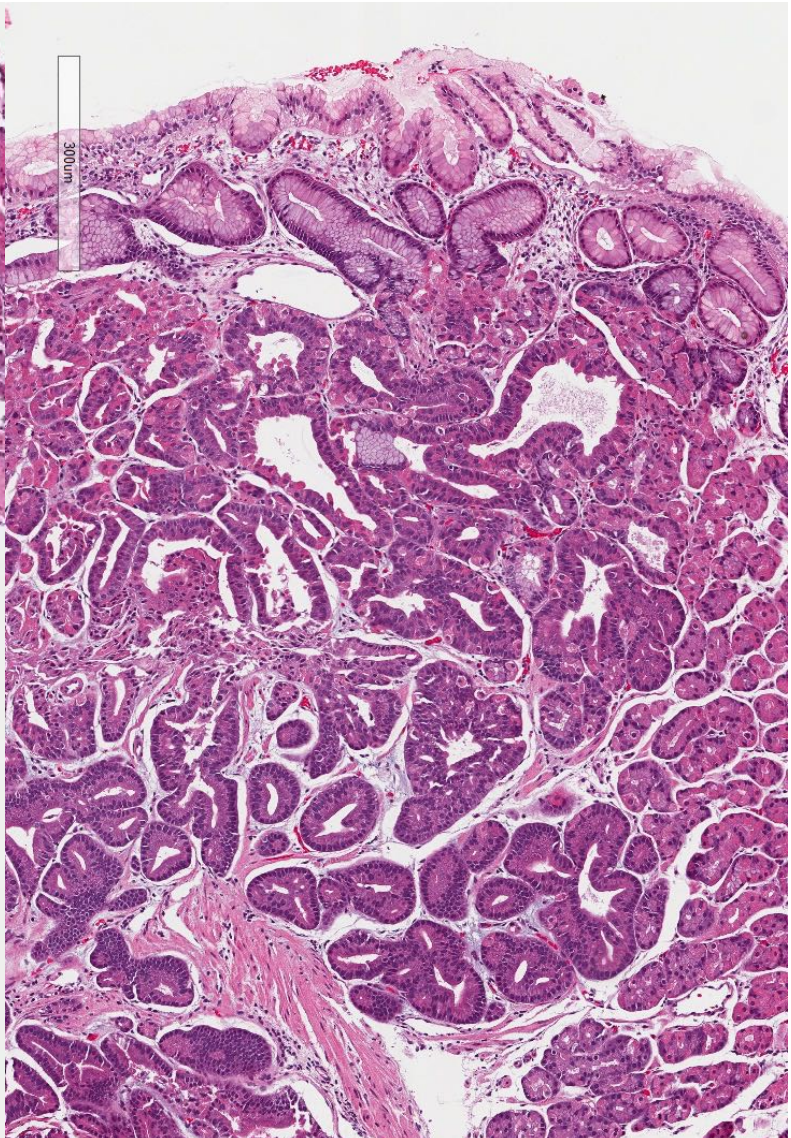
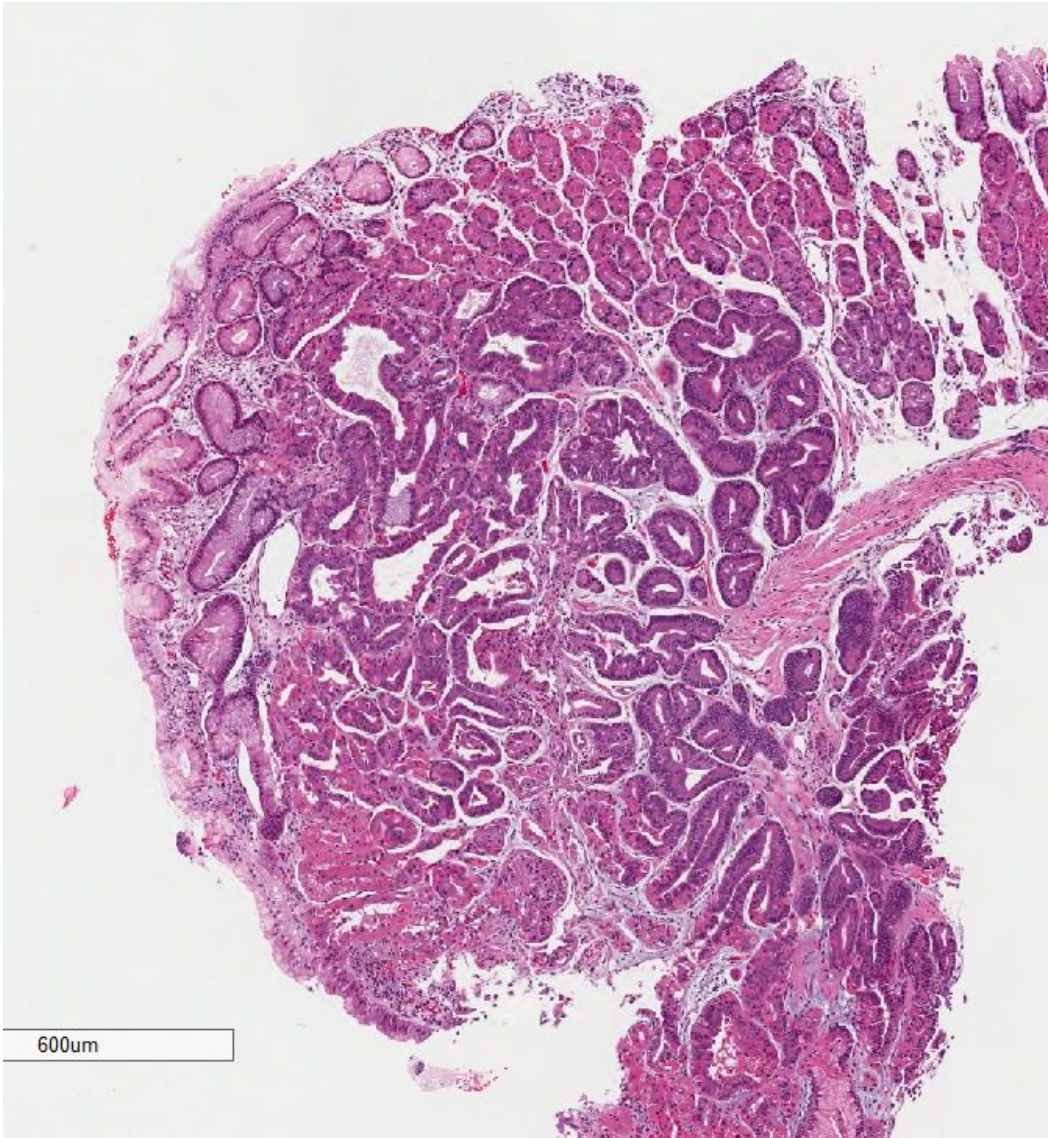
- These gastric biopsies were obtained from a 68 male.
- His chief complaints were dyspepsia and diarrhea.
- His PMH included a successfully treated malignant melanoma.

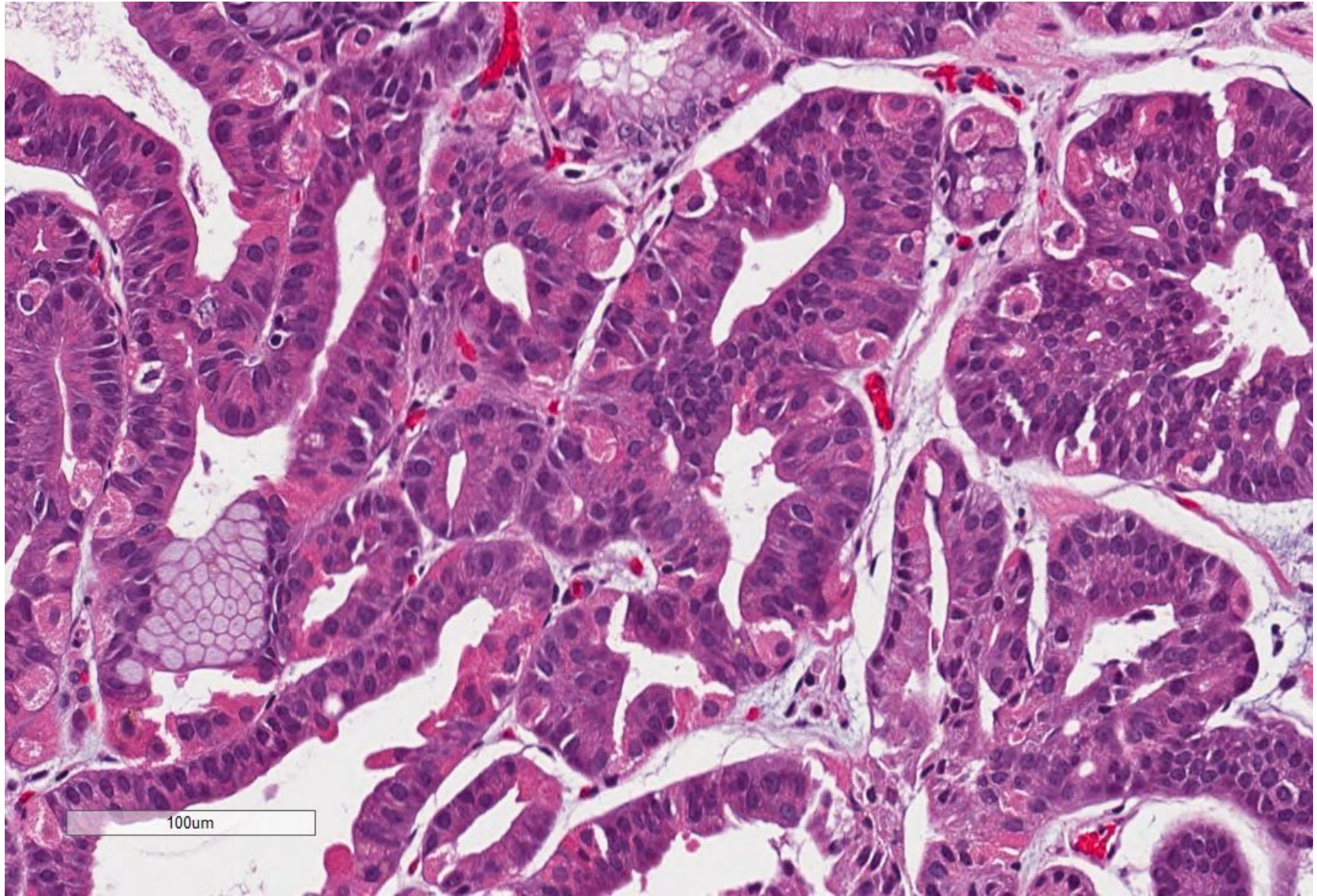


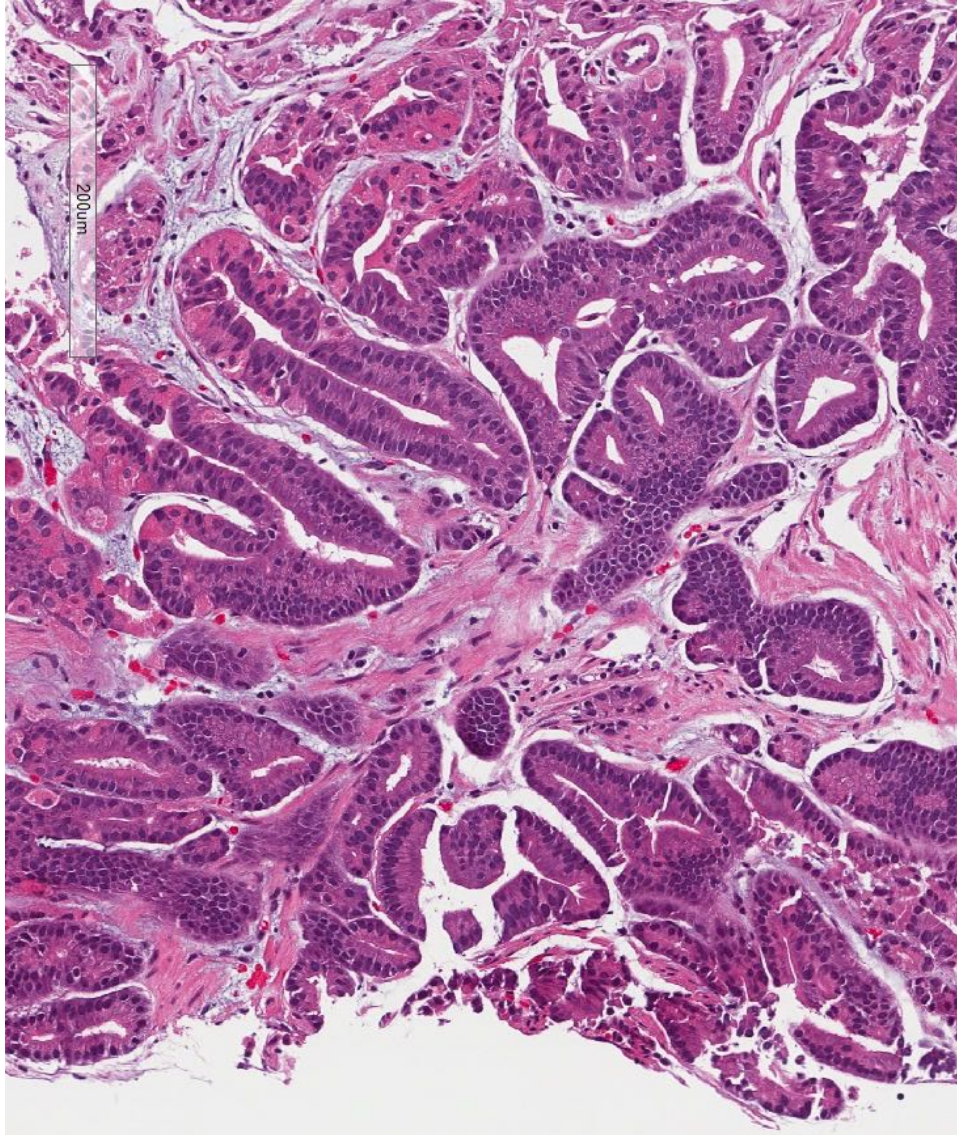


Clinical History – Case 2

- This gastric fundus polyp was resected from a 57 year old male treated by PPI.
- The upper endoscopy was performed as part of routine surveillance for Barrett esophagus.

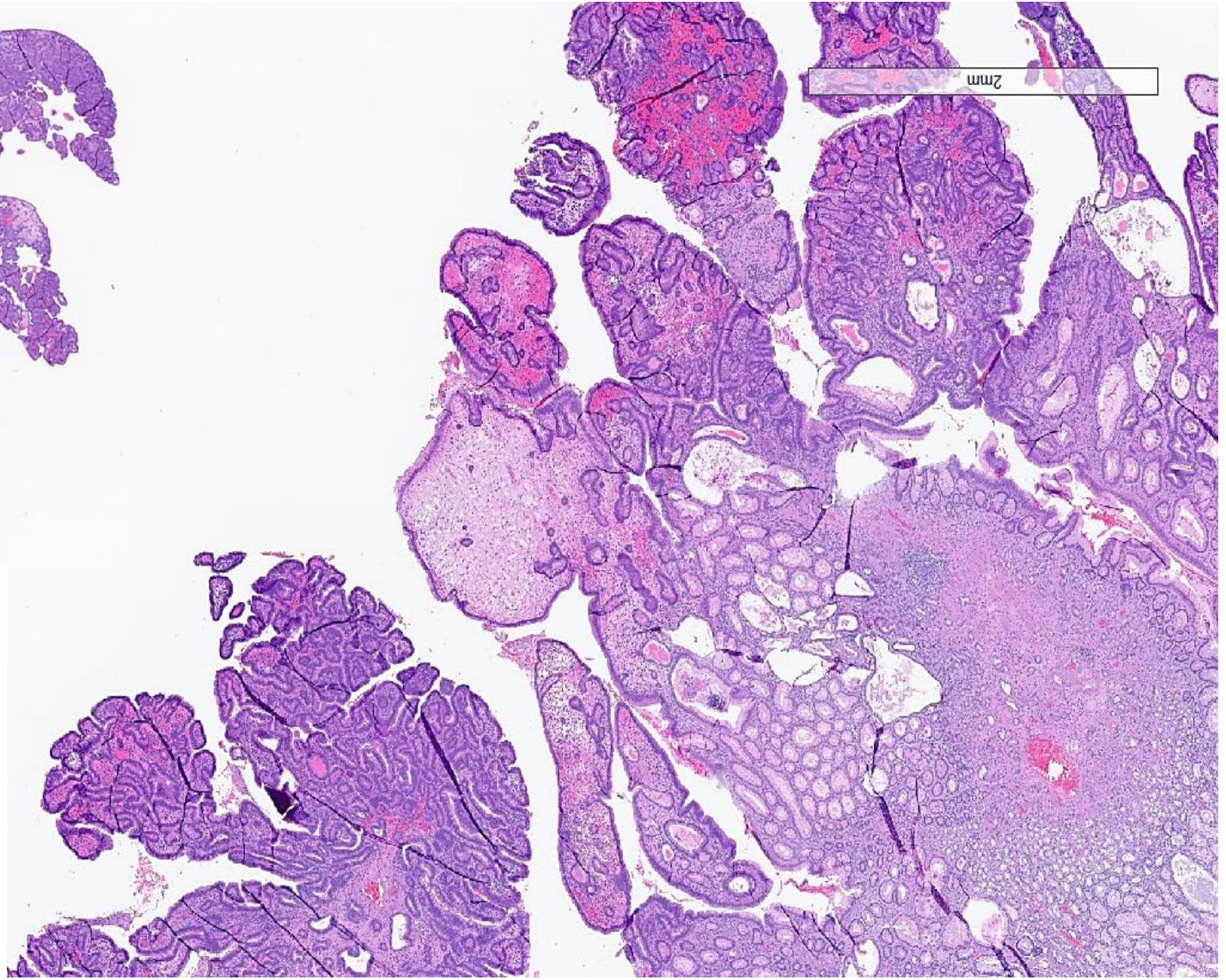
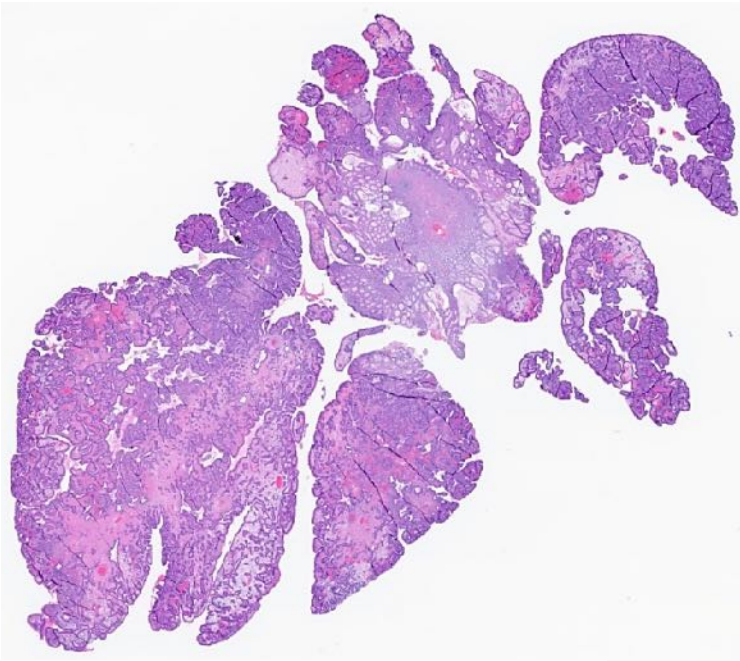


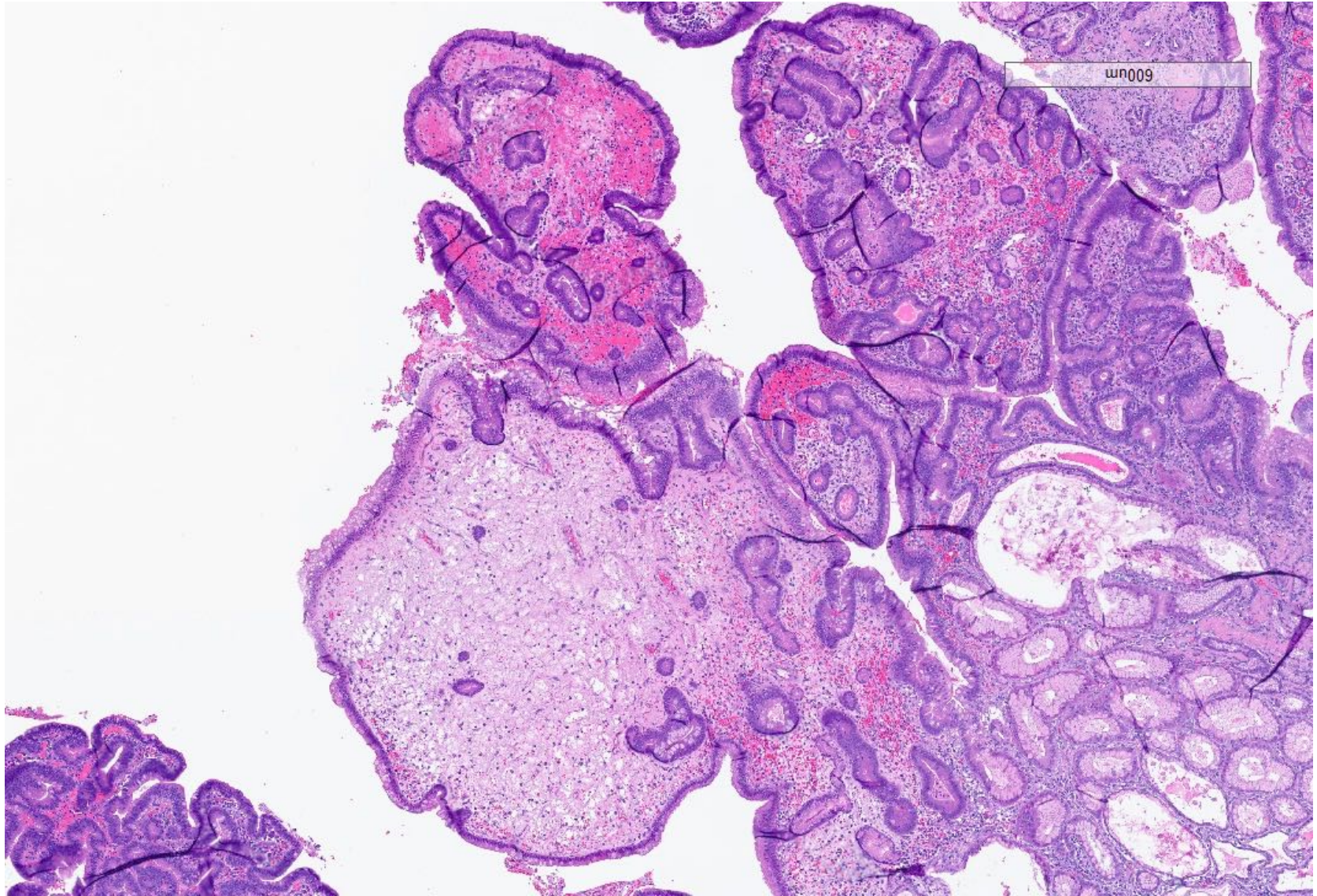


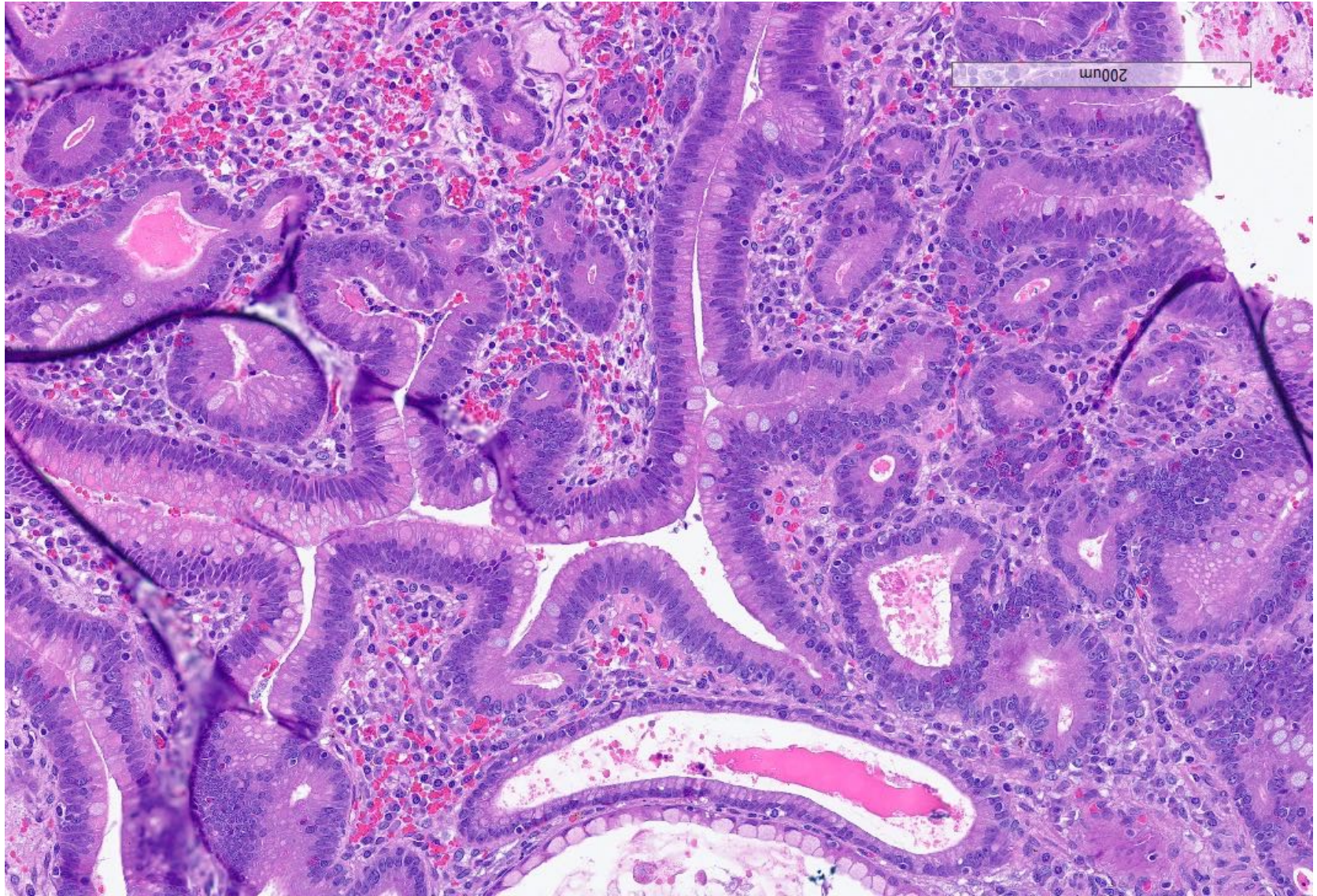


Clinical History – Case 3

- This gastric polyp was obtained from a 46 male.
- A previous series of upper + lower endoscopy had removed a couple of hyperplastic like polyps.
- The mother of the patient was also previously diagnosed with colonic polyps







Clinical History – Case 4

- This 68 year patient was recently complaining of melena.
- A full GI work-up detected a large fundic mass.
- A partial gastrectomy was performed.

