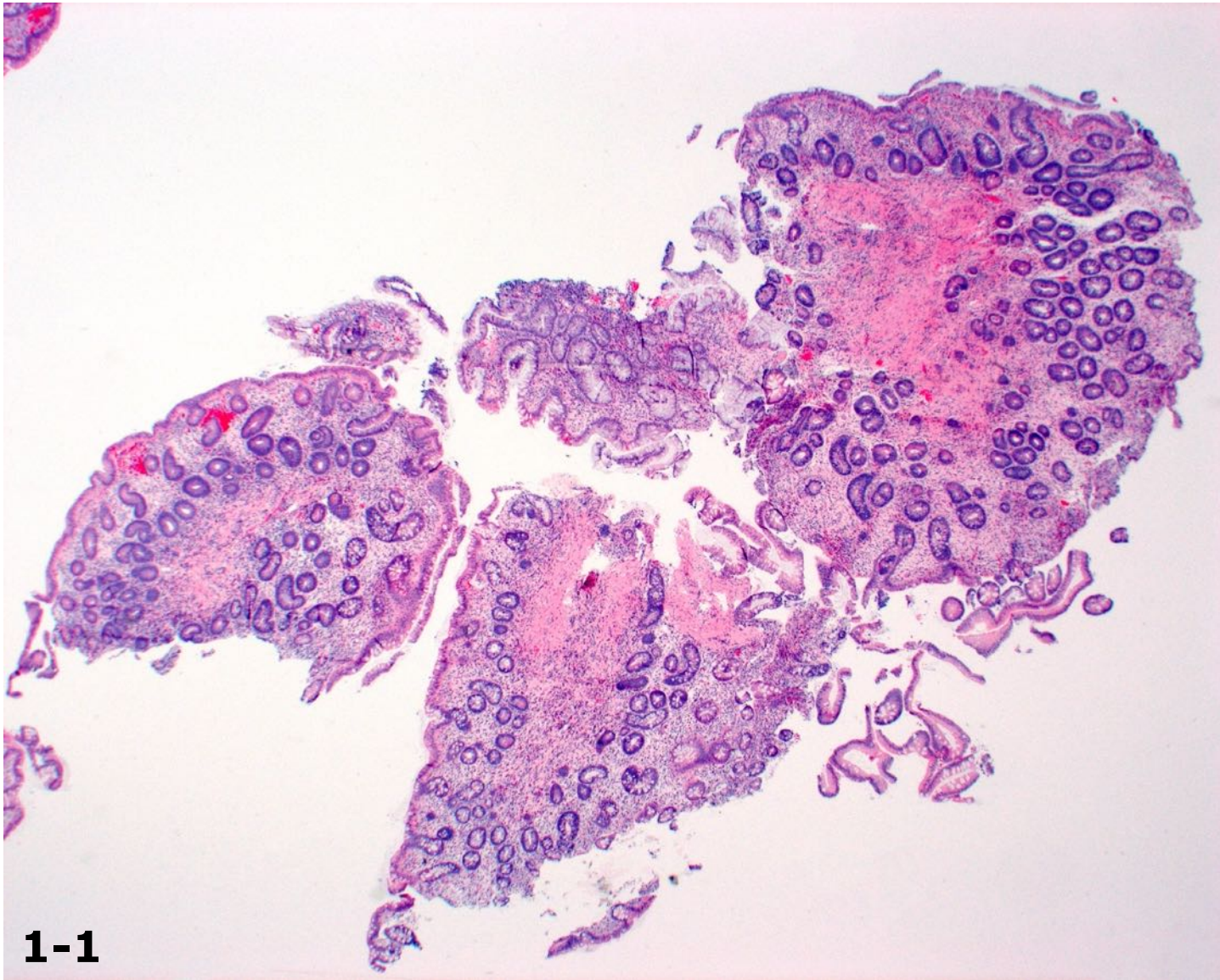


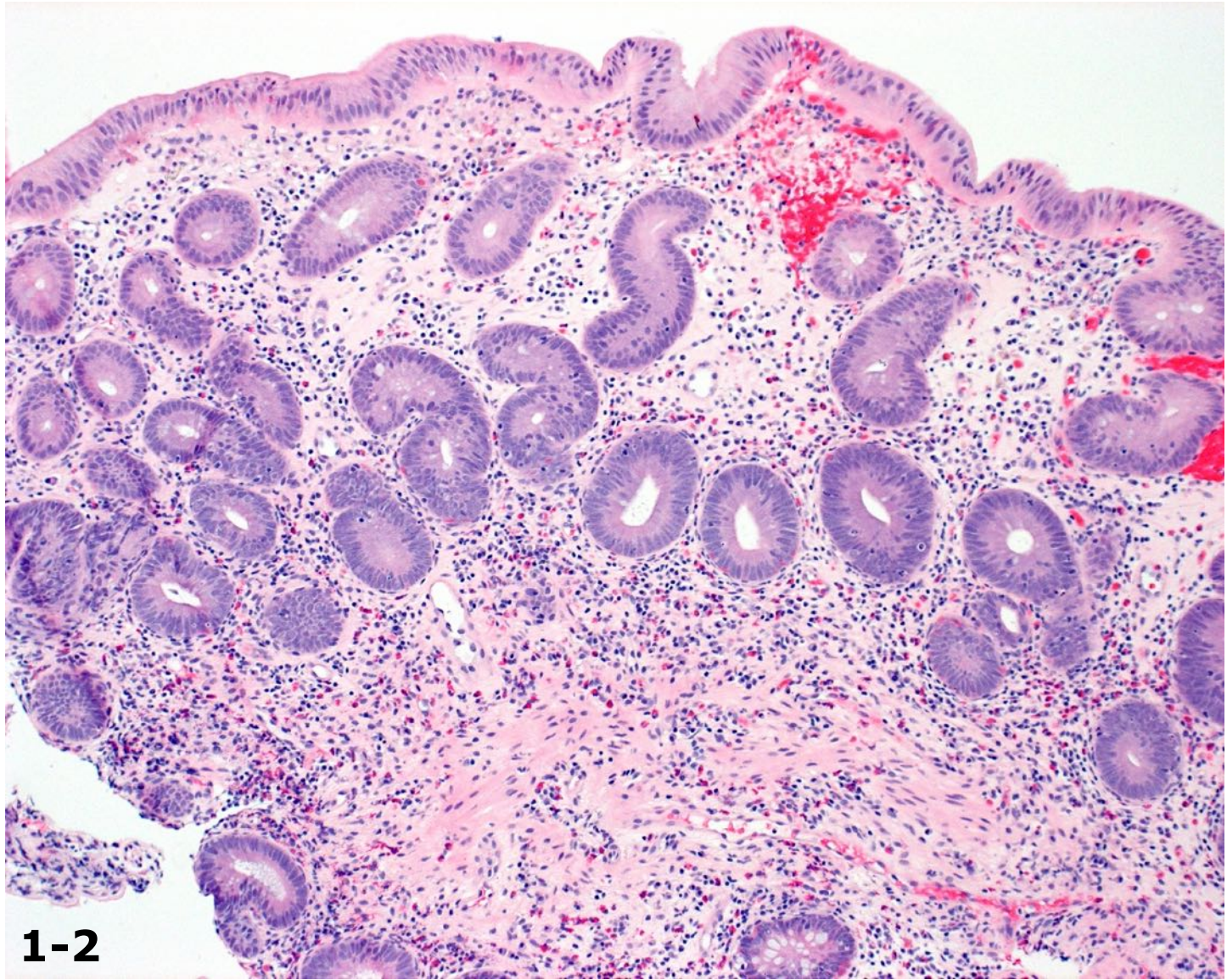
Dr. Won-Tak Choi Cases

Case #1

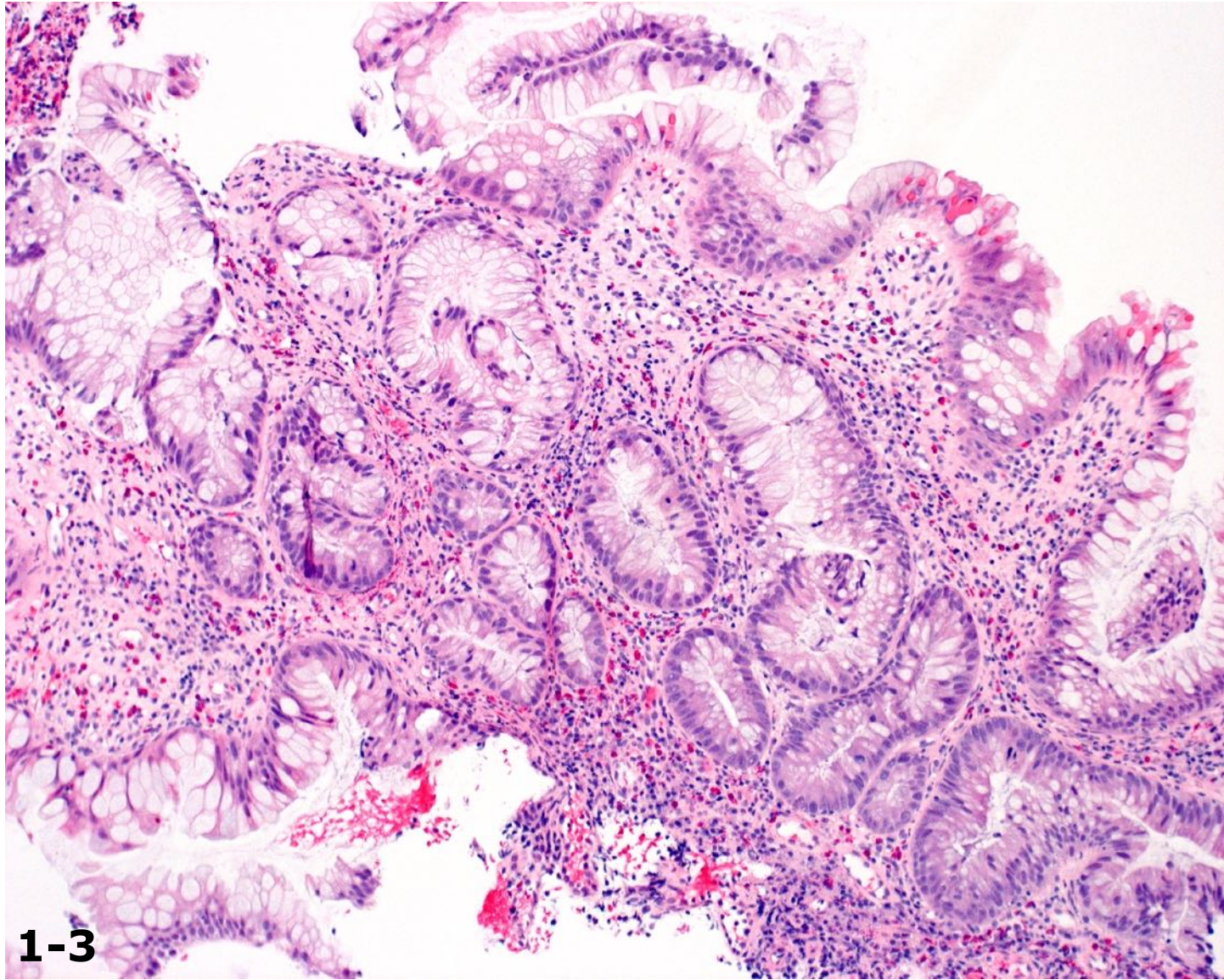
The patient was a 40-year-old male with a history of ulcerative colitis. Surveillance colonoscopy was normal, so random biopsies were performed in the right colon, transverse colon, left colon, and rectum. Sections of the left colon showed three atypical biopsy fragments (images 1-1, 1-2, 1-3, and 1-4).



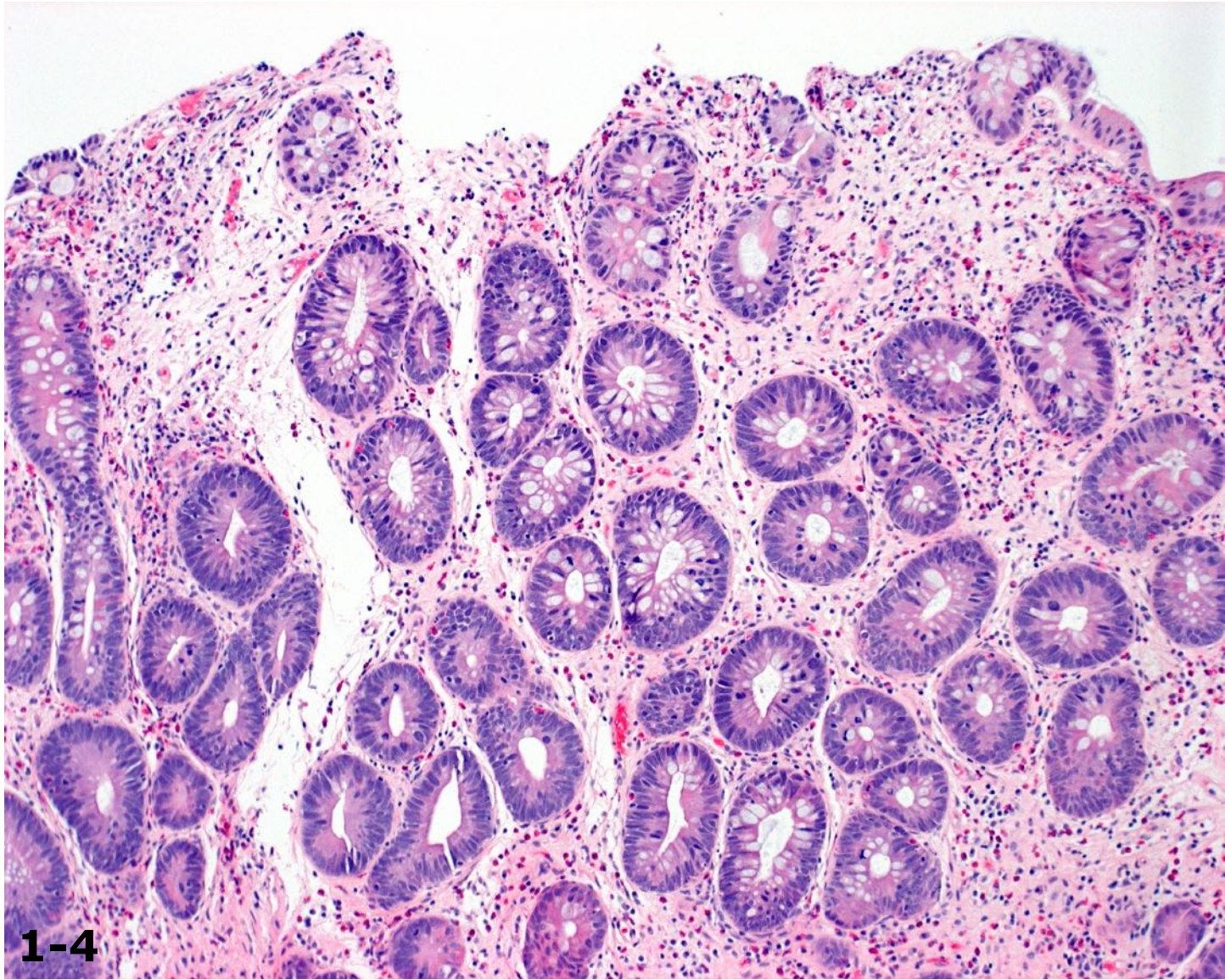
1-1



1-2



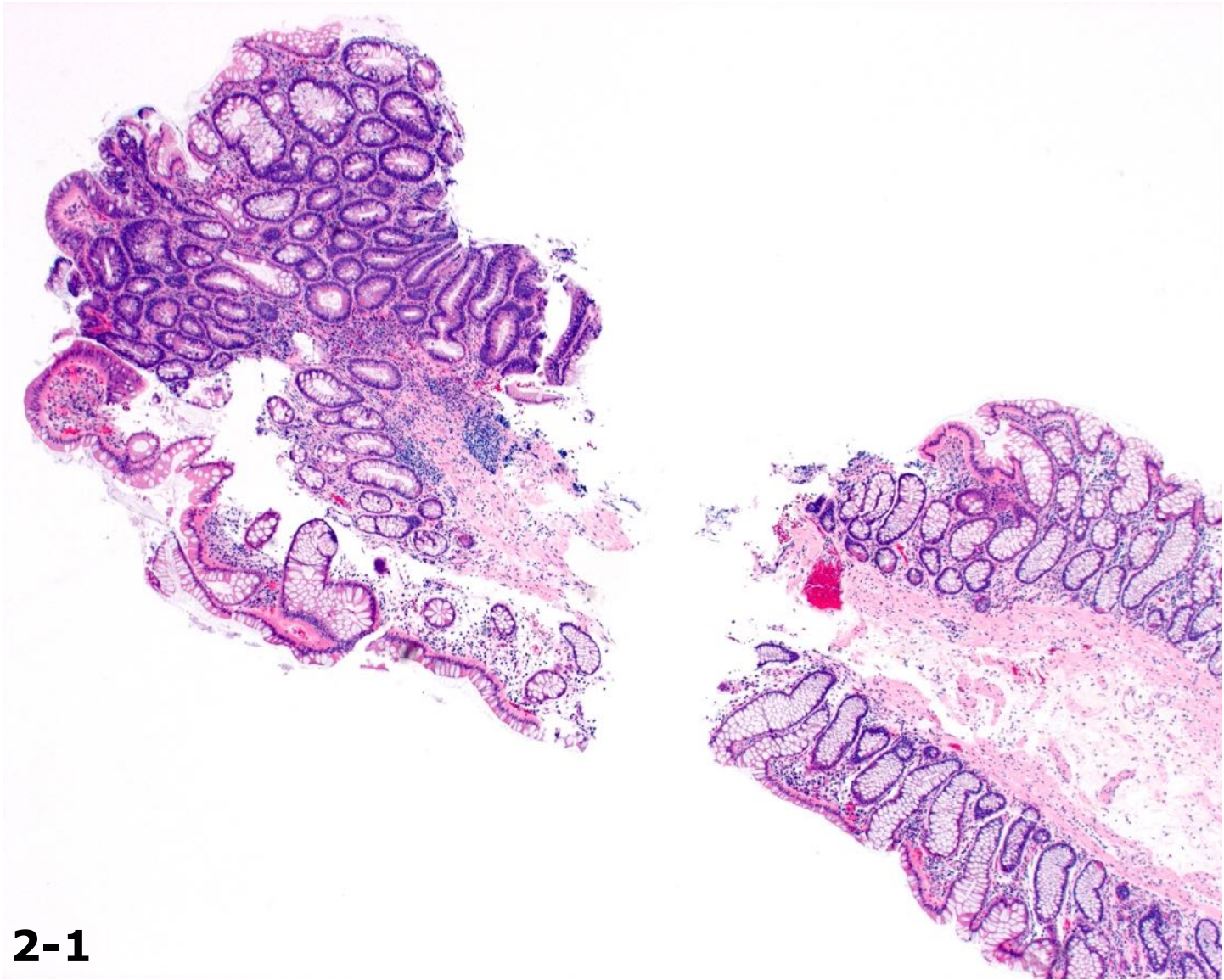
1-3



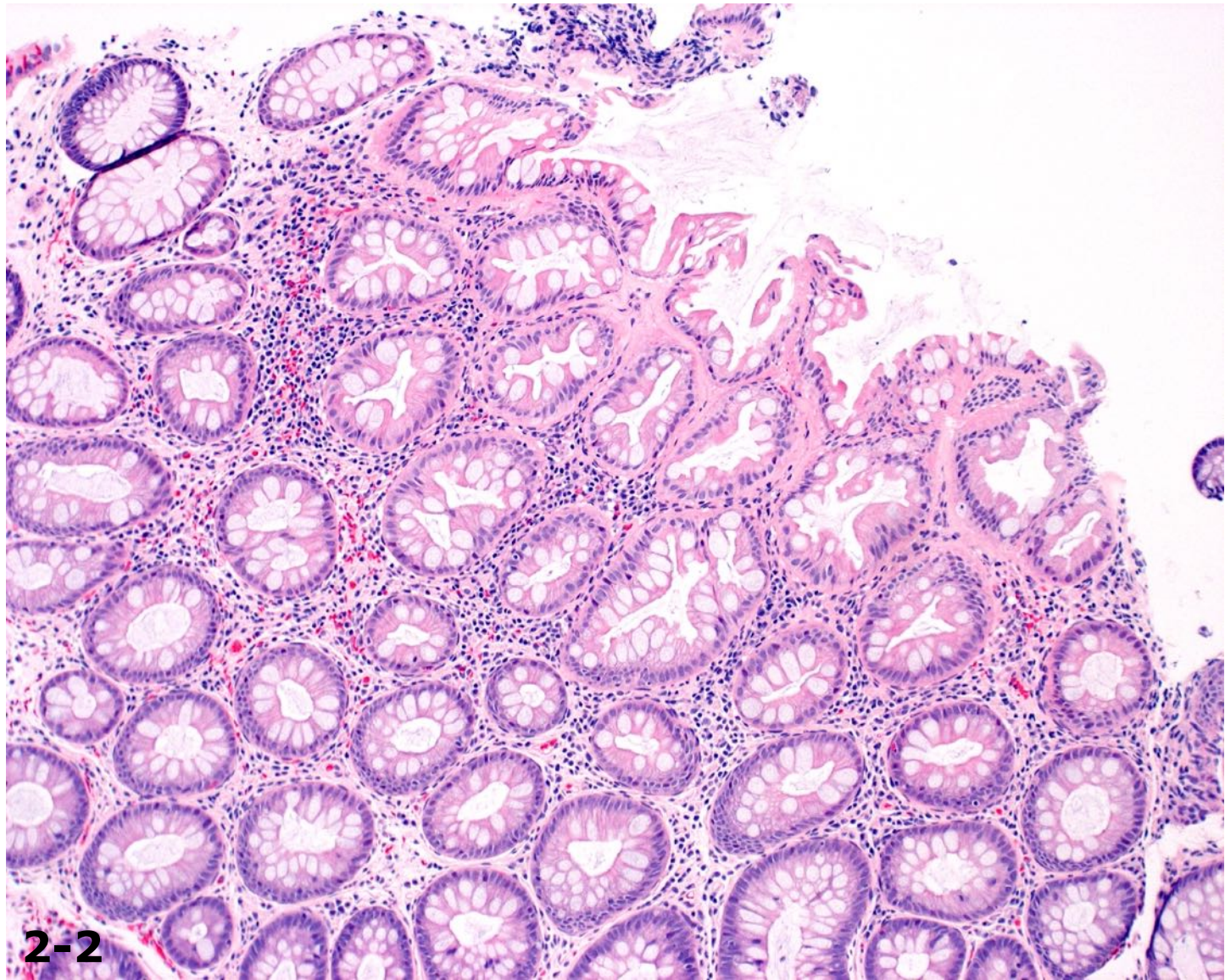
1-4

Case #2

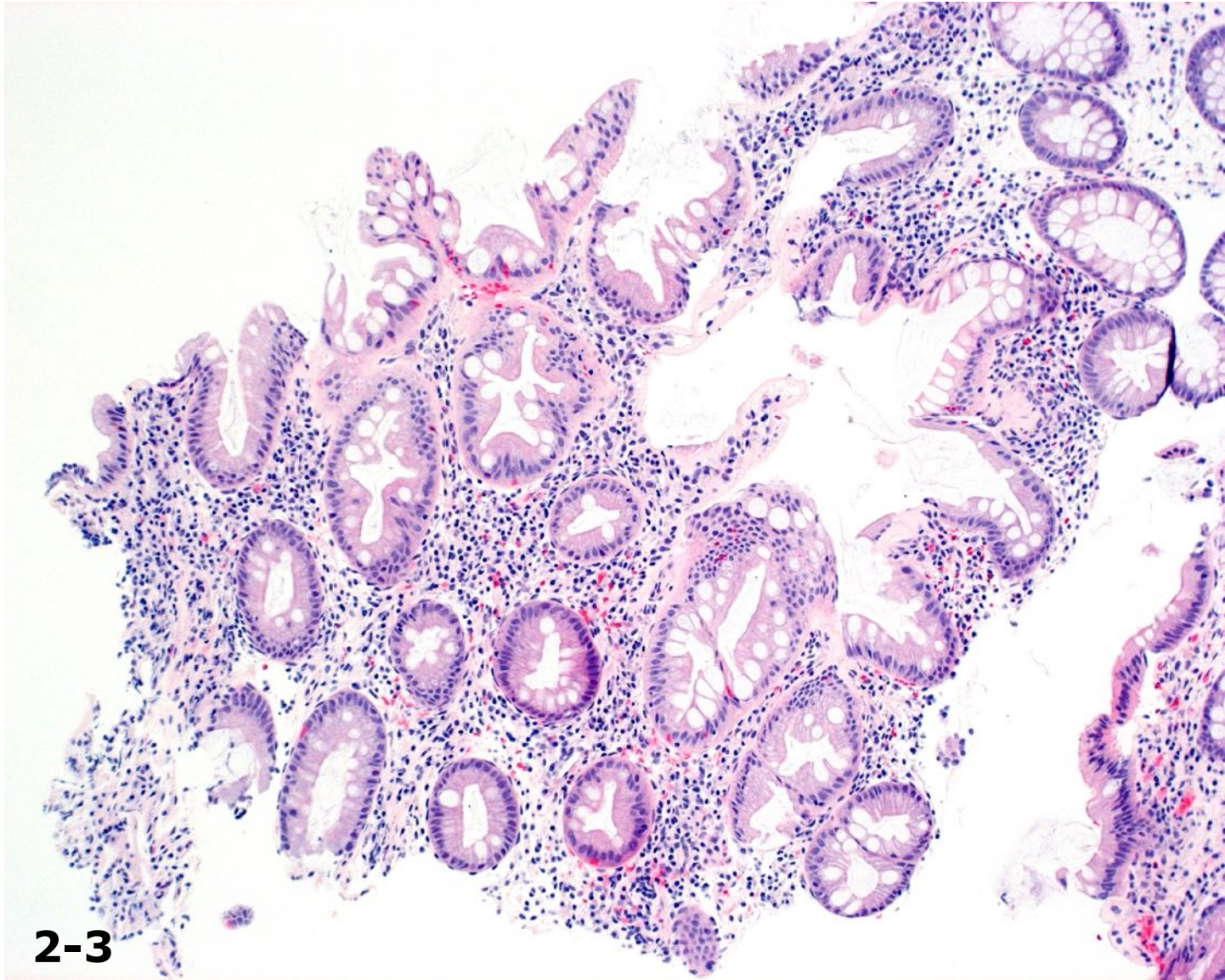
The patient was a 58-year-old male with a history of ulcerative colitis. Surveillance colonoscopy showed mild erythema in the left colon but was otherwise normal. A biopsy of erythema in the left colon was performed (image 2-1), along with random biopsies in the right colon, transverse colon, left colon (image 2-2), and rectum (image 2-3).



2-1



2-2



2-3